

# We are IntechOpen, the world's leading publisher of Open Access books Built by scientists, for scientists

6,900

Open access books available

186,000

International authors and editors

200M

Downloads

Our authors are among the

154

Countries delivered to

TOP 1%

most cited scientists

12.2%

Contributors from top 500 universities



WEB OF SCIENCE™

Selection of our books indexed in the Book Citation Index  
in Web of Science™ Core Collection (BKCI)

Interested in publishing with us?  
Contact [book.department@intechopen.com](mailto:book.department@intechopen.com)

Numbers displayed above are based on latest data collected.  
For more information visit [www.intechopen.com](http://www.intechopen.com)



---

## C3 Glomerulopathy

---

Nika Kojc

Additional information is available at the end of the chapter

<http://dx.doi.org/10.5772/intechopen.79768>

---

### Abstract

Understanding the role of alternative complement pathway dysregulation in membranoproliferative glomerulonephritis (MPGN) has led to a new classification into two subgroups: immune complex-mediated MPGN and complement-mediated MPGN. Immune complex-mediated MPGN results from the deposition of immunoglobulin deposits and complements component C3 driven by classical complement pathway activation, while complement-mediated disease may be associated with complement alternative pathway dysregulation and is a new entity, C3 glomerulopathy. C3 glomerulopathy is an umbrella term, encompassing dense deposit disease (DDD), former MPGN type II, and C3 glomerulonephritis. C3 glomerulonephritis comprises examples of MPGN types I and III, in which immunofluorescence reveals predominant C3 deposits. By light microscopy, distinctive histologic patterns can be observed in both entities, including membranoproliferative, mesangial proliferative, crescentic and acute proliferative and exudative patterns, of which the membranoproliferative pattern seems to be the most common. DDD is defined by the presence of dense osmiophilic transformation of the glomerular basement membrane (GBM) on electron microscopy (EM). Only EM enables definite distinction of DDD from C3 glomerulonephritis. C3 glomerulopathy is a heterogeneous disease; genetic or acquired complement alternative pathway abnormalities have been identified in up to 40% of patients, including mutations in complement factors or autoantibodies directed against them.

**Keywords:** C3 glomerulopathy, C3 glomerulonephritis, dense deposit disease, membranoproliferative glomerulonephritis, complement alternative pathway dysregulation, complement regulation, CFHR5 nephropathy, C3 nephritic factor, eculizumab

---

### 1. Introduction

C3 glomerulopathy is a recently defined glomerular disease, characterized by predominant C3 complement component (C3) deposits in the glomeruli in the absence of a significant

amount of immunoglobulin and without deposition of C1q and C4. The accumulation of C3 without a significant amount of classical or lectin complement component in the glomeruli suggests dysregulation of the alternative complement pathway as the underlying pathogenetic mechanism.

Glomerular C3 deposits confirmed by immunohistochemistry correspond to electron dense deposits seen on electron microscopy (EM). By light microscopy, distinctive histologic patterns can be observed, including membranoproliferative, mesangial proliferative, crescentic and acute proliferative and exudative patterns, of which the membranoproliferative pattern seems to be the most common [1–3]. The recognition of C3 glomerulopathy led to a major revision of the understanding of the entity of membranoproliferative glomerulonephritis (MPGN) [1, 4, 5].

## 2. Historical overview of membranoproliferative glomerulonephritis

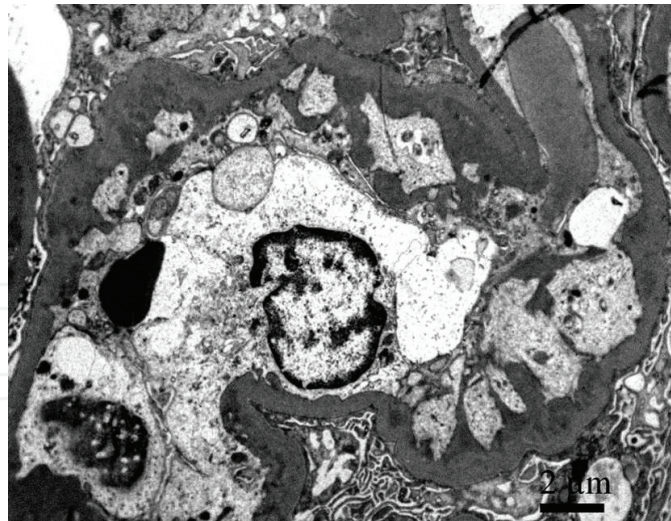Rather than a disease, MPGN is a morphologic pattern of glomerular injury, characterized on light microscopy by mesangial hypercellularity and thickening of the capillary walls, resulting in glomerular capillary wall remodeling. In the active phase, a proliferative and exudative pattern predominates, whereas in the reparative phase, mesangial expansion occurs, together with double contour formation and mesangial interposition seen on EM [6, 7].

Without knowledge of the pathogenesis, MPGN was traditionally classified based on histologic features defined by light microscopy and the location of the deposits as observed by EM. Three types of MPGN were recognized: MPGN types I, II and III [7–9].

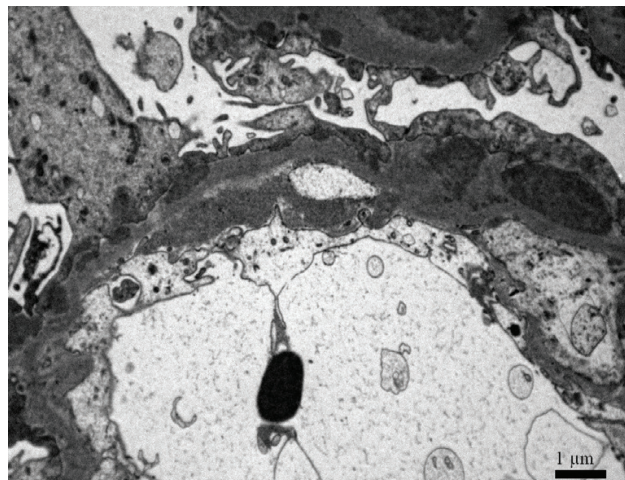
MPGN type I was characterized by mesangial and subendothelial deposits, with marked mesangial interposition and double contour formation (**Figure 1**) [9]. Type III, defined by mesangial, subendothelial and subepithelial deposits, was further subdivided into two variants: the Burkholder variant and Anders-Strife variant, describing different patterns of electron dense deposits and disorganization of the glomerular basement membrane (GBM) [8, 10]. In the Burkholder variant, there were discrete subendothelial and subepithelial deposits (**Figure 2**), while in the Anders-Strife variant, the deposits produced complex transmembranous, ribbon-like subendothelial and subepithelial deposits with fraying of the lamina densa (**Figure 3**).

MPGN type II was first described by Berger and Galle in 1963 as a dense deposit disease (DDD) characterized by extremely electron dense transformation of the GBM (**Figure 4**) [11]. Little attention was paid to this entity until 1975, when Habib indicated an association between dense transformation of the GBM and the MPGN histologic pattern and therefore classified it as a type II variant of MPGN, which was followed by long-term consequences [12].

From the beginning, an MPGN lesion delineated a group of patients with no evidence of underlying disease—an idiopathic MPGN [9, 13]. Over time, as serological and other methodology improved, many secondary forms with clear etiologic associations were differentiated from idiopathic MPGN. It became apparent that MPGN is often associated with chronic infections (hepatitis B and C, with or without cryoglobulinemia), autoimmunity or deposition



**Figure 1.** MPGN type I is characterized by mesangial and subendothelial deposits, with marked mesangial interposition and double contour formation.

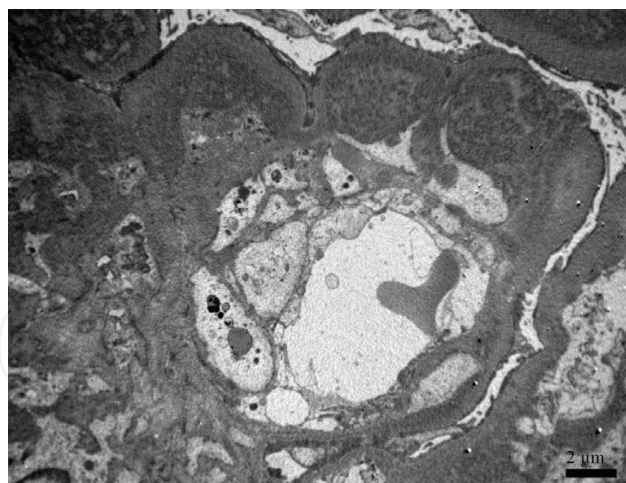


**Figure 2.** Burkholder variant of MPGN type III shows mesangial and discrete subendothelial and subepithelial deposits.

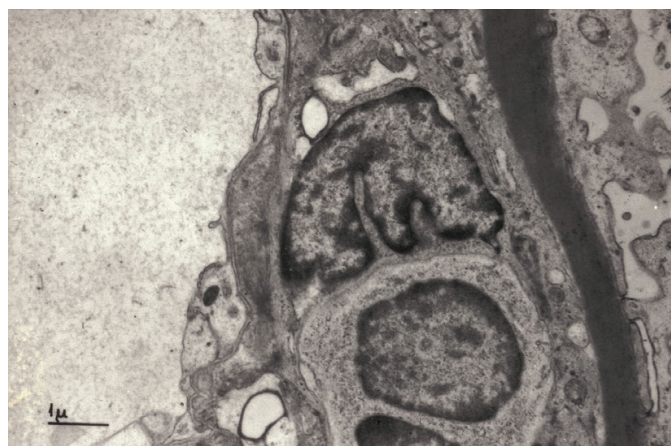
of a monoclonal immunoglobulin. A histologic pattern resembling the MPGN pattern could also be observed in a broad group of thrombotic microangiopathy: thrombotic thrombocytopenic purpura, atypical hemolytic uremic syndrome (aHUS), sickle cell anemia, diabetic glomerulosclerosis, transplant glomerulopathy and malignant hypertension [7, 14, 15]. In this group of diseases, there is little or no proliferation and neither marked mesangial interposition nor immune deposits are detected on immunofluorescence (IF) or EM. GBM double contours occur due to subendothelial neolamina formation in response to insudative changes, endothelial swelling and subendothelial plasma insudation.

This historical classification, based on histologic and ultrastructural findings and devoid of pathogenetic context, could not explain the diversity of underlying pathogenetic mechanisms, nor the various clinical pictures in MPGN patients [13]. It was tempting to speculate that other features, in addition to the peculiar description of deposits location, would clarify at least some group of





**Figure 3.** In Anders-Strife variant of MPGN type III, the deposits produce complex transmembranous, ribbon-like subendothelial, and subepithelial formations with fraying of the lamina densa.



**Figure 4.** Highly electron dense intramembranous and mesangial deposits are hallmark of DDD, classified historically as MPGN type II.

patients with features of MPGN [14, 16, 17]. The discovery that many children with DDD displayed persistent hypocomplementemia, with low levels of serum complement factors, was a harbinger of the identification of the heterogeneity of mechanisms underlying the MPGN pattern [17].

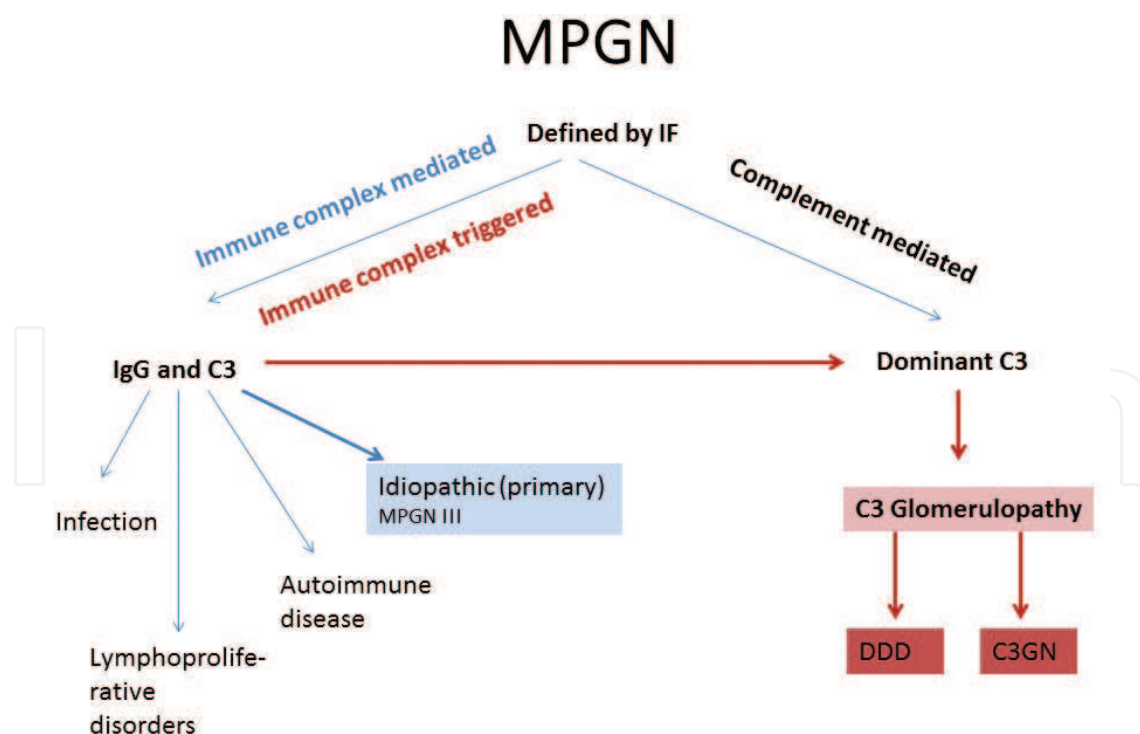
It was increasingly observed that many patients with dense deposits on EM, characteristic of MPGN type II lacked a MPGN pattern on light microscopy [18]. In order to disprove the relation between dense transformation of GBM and a MPGN histologic pattern, Walker collected 69 cases of DDD from centers in North America, Europe and Japan [19].

Surprisingly, four histologic patterns were identified: membranoproliferative, mesangial proliferative, crescentic, and acute proliferative and exudative. The MPGN pattern was found only in 25% of cases; the majority of patients presented with mesangial proliferative features. On light microscopy and IF, the acute proliferative and exudative variants can be difficult to distinguish from post-infectious glomerulonephritis [20, 21].

Concurrently, improving IF techniques enabled differentiation of the composition of the deposits detected by IF [9, 22]. Biopsies from patients with MPGN type II usually showed only C3 deposits, with little or without immunoglobulin deposition. Furthermore, even in some cases of MPGN types I and III, pathologists noticed the presence of dominant complement deposits, therefore setting these cases apart from more common variants of type I and III containing immunoglobulins and C3. These cases were initially called idiopathic MPGN with dominant C3 deposits [13, 23]. Moreover, patients with MPGN and dominant C3 deposits also presented with low serum C3, indicating complement alternative pathway dysregulation, while serum levels of classical complement factors were mainly normal. Laser micro dissection and mass spectrometry data of glomeruli from DDD and MPGN with dominant C3 deposits showed a similar proteomic profile, indicating a common pathogenesis of the two diseases [24, 25]. A major breakthrough was the discovery of genetic mutations or deficiencies in complement regulatory proteins in patients with predominant C3 deposits [14, 26].

## 2.1. Proposal for a new classification

The aforementioned elucidations of the possible pathogenesis of MPGN led to a new classification based on the composition of deposits: into immune complex-mediated and complement-mediated diseases [2, 4, 5, 27, 28].



**Figure 5.** The evolving classification of MPGN: the composition of the deposits seen on IF categorized MPGN as immune complex-mediated and complement-mediated disease, the later termed C3 glomerulopathy. Immune complex-mediated MPGN without known underlying cause (idiopathic MPGN) may be immune complex-mediated at the beginning, evolving into C3 glomerulopathy over time. MPGN membranoproliferative glomerulonephritis, IF immunofluorescence.

Immune complex-mediated MPGN results from the deposition of immunoglobulin deposits and C3 driven by classical complement pathway activation, while complement-mediated disease may be associated with complement alternative pathway dysregulation and is a new entity, C3 glomerulopathy. C3 glomerulopathy is characterized by predominant C3 deposits on IF (**Figure 5**) [5, 9, 29].

C3 glomerulopathy is an umbrella term, encompassing DDD (former MPGN type II) and examples of MPGN types I and III, in which IF reveals exclusive or predominant C3 deposits, now termed C3 glomerulonephritis (C3GN) [4, 5, 22, 29, 30]. DDD is defined by the presence of dense osmiophilic transformation of the GBM on EM. Only EM enables definite distinction of DDD from C3GN; however, a spectrum of appearances may be seen in some cases, even in the same glomerulus.

### 3. Diagnosing C3 glomerulopathy

Cases with a membranoproliferative pattern that have only glomerular C3, with absolutely no immunoglobulin, are relatively uncommon; most cases will have dominant C3 staining with some immunoglobulin. The original definition of C3 glomerulopathy as “C3 only” appeared too stringent if the goal of diagnosis is to identify all complement-mediated cases for evaluation of complement alternative pathway dysregulation [2, 28, 30, 31].

In a study of over 300 cases of idiopathic MPGN, Hou et al. applied a hierarchical set of criteria to define the optimal cut-off for a diagnosis of C3 glomerulopathy, using DDD as a gold standard [22]. A new definition of C3 glomerulopathy was therefore proposed, for when C3 dominance is at least two orders of magnitude stronger than any other immune reactant. The new definition identified 31% of MPGN type 1, 88% of DDD (MPGN type II) and 39% of MPGN type III cases, indicating a sensitivity of 88% and acceptable specificity.

In terms of the modern approach to MPGN, 39% of the Anders-Strife variant would be classified as C3GN, whereas the majority of the Burkholder variant and approximately 70% of MPGN type I presented with immunoglobulin and C3 deposits as immune complex-mediated MPGN [22]. In many of those cases, an underlying cause could be identified, such as autoimmunity, chronic infection or deposition of a monoclonal immunoglobulin, indicating that idiopathic MPGN might now be considered a rare condition. It encompasses historical MPGN types I and III with immunoglobulin and complement deposits without known underlying cause [9, 31].

However, such rare cases might represent C3GN with immunoglobulin deposits, which did not fulfill the diagnostic criteria for C3 glomerulopathy at the time of diagnosis, and therefore an underlying complement dysregulation has to be excluded [31, 32].

It has already been proposed that, in some patients, immune complexes may initiate MPGN, but the disease is accelerated and sustained by complement alternative pathway dysregulation [30]. When a complement activating infection occurs, it may overwhelm the compensatory regulatory mechanisms, leading to augmented and perpetuated activation of dysregulated

complement alternative pathway. MPGN may therefore be immune complex-mediated at the beginning, evolving into C3 glomerulopathy over time (**Figure 5**).

Although the proposed classification seems to be widely accepted, a recent study indicates that understanding MPGN by classification into immunoglobulin-mediated and C3 dominant forms might be too simplistic and may not provide sufficient information on prognosis and prevention of the disease [33]. In the future, novel research methods, probably based on mathematical models, will be employed in order to provide detailed insights into management of C3 glomerulopathy [33].

## 4. Dense deposit disease

### 4.1. Clinical presentation

DDD is a rare disease, with a reported incidence between 2 and 3 per million of the population, primarily affecting children and young adults, although the range is broad, varying from 1 to 64 years [19]. Recently, a study with the largest American cohort to date, including 111 patients with C3 glomerulopathy, 24 of them with DDD, found 29% of patients older than 50 years [3]. Males and females are usually equally involved, but some studies have reported a female predominance [1].

The clinical presentation is usually unspecific, with a slow deterioration of renal function. In the past, approximately 50% of patients presented with nephrotic syndrome at the time of diagnosis [12, 34, 35]. A recent study showed that most patients displayed proteinuria and hematuria with preserved kidney function, although about 25% of patients showed significant chronic kidney disease at the time of diagnosis [3]. Acute, often a respiratory tract infection prior to DDD onset was reported in approximately half of the patients, and this did not differ between pediatric and adult populations [1, 3, 12]. Progression to ESRD has been reported in up to 50% of patients within 10 years of diagnosis [2, 36].

Approximately 65–80% of patients with DDD present with persistently low serum C3 but serum levels of the early classic pathway components C1q and C4 are usually normal [1–3, 12]. Pediatric patients had lower C3 levels than adults [1, 3]. Up to 80% of patients with DDD showed positive serum C3 nephritic factor (C3Nef), an autoantibody directed against alternative pathway convertase, although it is not specific and is also found in patients with MPGN type I, post-infectious glomerulonephritis and even lupus nephritis [2, 35, 37–40]. Other autoantibodies against complement factors, including anti factor H antibody, anti-factor B antibody and complement factor gene variant and mutations have been found in various percentages of DDD patients [2, 3].

Rarely, patients with DDD may present with two other conditions, either separately or together: ocular drusen or acquired partial lipodystrophy. Both conditions are associated with dysregulation of the alternative complement pathway [14, 19, 41].

Ocular drusen are yellow deposits localized between the retinal pigment epithelium and Bruch's membrane, consisting of lipoproteinaceous deposits of complement-containing



debris [42, 43]. Similar drusen are found in patients with age-related macular degeneration (AMD) but in contrast to patients with AMD, drusen in DDD patients occur at an early age. The same polymorphisms in factor H have been identified in patients with AMD and DDD, implicating AP complement dysregulation in the pathogenesis of both diseases [41, 44].

DDD can be rarely associated with acquired partial lipodystrophy (APL), the symmetrical loss of subcutaneous fat in the upper half of the body (face, arms and upper part of the trunk) [45]. Approximately 20% of patients with APL develop MPGN. APL usually precedes the onset of kidney disease by several years. Frequent detection of C3Nef and low C3 level in these patients indicates an underlying dysregulation of AP complement on both kidneys and adipose tissue. The deposition of activated complement factors in adipose tissue may result in the destruction of adipocytes [45].

## 4.2. Pathologic findings

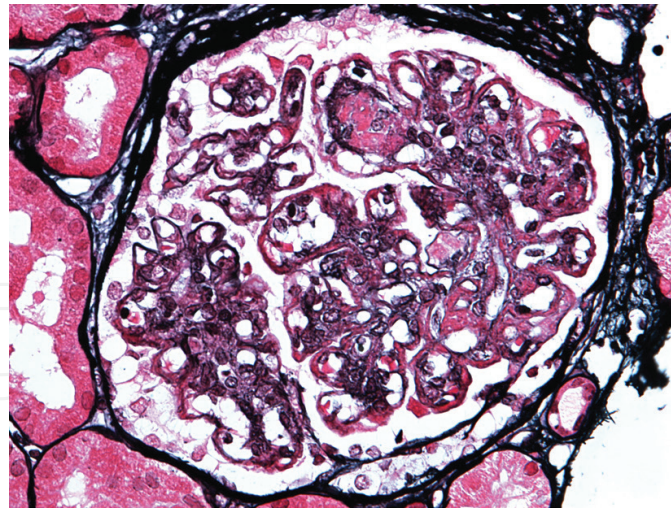
### 4.2.1. *Light microscopy*

A specific feature of DDD is the presence of dense osmiophilic transformation of the GBM on EM [19, 20]. Due to the association between dense GBM transformation and an MPGN histological pattern described decades ago, it was classified historically as MPGN type II [12]. However, the appearance of DDD on light microscopy is quite variable, showing membrano-proliferative, mesangial proliferative, crescentic and acute proliferative, and exudative histologic patterns [1, 20]. In some cases, glomeruli show prominent endocapillary hypercellularity with exudation of neutrophils reminiscent of post-infectious glomerulonephritis, while others present with a prominent crescent formation. In an American cohort of 24 patients, membranoproliferative and mesangial patterns were demonstrated in 46 and 29% of patients, respectively [3]. The clinical significance of the different patterns needs further evaluation, but in some patients, it might depend on the timing of the biopsy; patients with long-lasting disease may develop chronic glomerular changes with double contours characteristic of a membranoproliferative pattern.

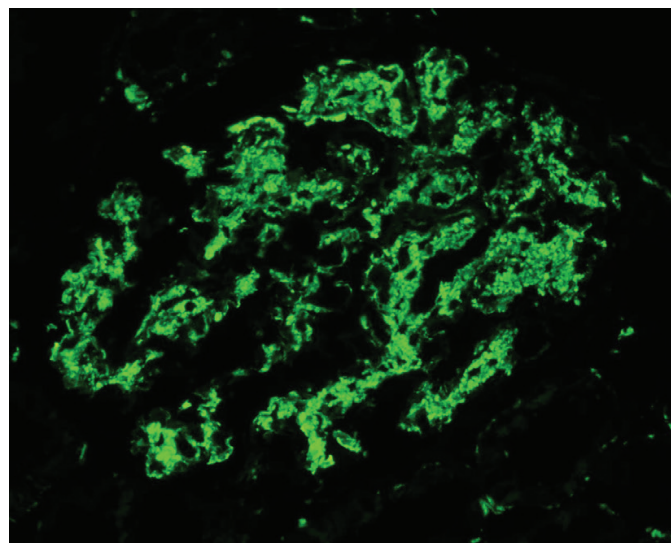
On light microscopy, GBM dense deposits are recognized as thickening of the glomerular capillary walls by ribbon-like intramembranous deposits. They are intensely periodic acid-Schiff (PAS) positive and stain strongly fuchsinophilic (red) with trichrome stain. Methenamine silver staining discloses characteristic defects in the GBM because dense deposits are not argyrophilic and therefore fail to stain with silver stains. Thin, silver-positive lines border the GBM on each side, resulting in typical double contours (**Figure 6**). Although light microscopy in typical cases is fairly characteristic, the glomerular intramembranous deposits may vary in size and number and a definitive diagnosis can be established only by EM [20, 32].

### 4.2.2. *Immunofluorescence*

DDD is characterized by the presence of intense C3 deposits in the glomerular mesangium, as well as along capillary walls, with minimal or no immunoglobulin deposition. There are usually abundant mesangial C3 deposits, described as coarse granules, spherules or small rings (**Figure 7**). The IF pattern along the glomerular capillary walls is described as pseudolinear,



**Figure 6.** Extensive mesangial deposits and thickening of the glomerular capillary walls by ribbon-like intramembranous deposits. Deposits stain strongly fuchsinophilic (red) with trichrome stain. Methenamine silver staining discloses characteristic defects in the GBM. (silver and trichrome stain—Jones and Azan, 400×).

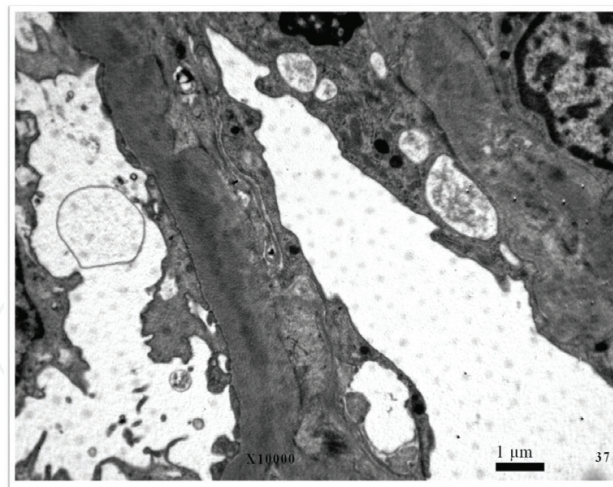


**Figure 7.** Intense ring-like C3 deposits in the glomerular mesangium and pseudolinear along capillary walls in DDD.

smooth, ribbon-like or coarsely granular. Classical complement components and immunoglobulin staining are usually absent; if present, they stain less intensely than C3 and may be focal and segmental [20, 34]. C3 deposits may be also found in the basal lamina of the Bowman capsule and along the tubular basement membranes of proximal and distal tubules.

#### 4.2.3. Electron microscopy

DDD is characterized by the presence of dense transformation of the GBM found by EM. This special appearance of the lamina densa may be continuous and diffuse in distribution (**Figure 4**) or interrupted and fusiform, with native GBM found between deposits (**Figure 8**). In less severe cases, dense deposits may be focal, affecting only a few loops. The deposits



**Figure 8.** In less extensive cases of DDD deposits occupy only part of the GBM width.

may replace the entire width of the lamina densa, whereas in less extensive involvement they occupy only part of the GBM width (**Figure 8**). Mild cases may present only in the inner (sub-endothelial) aspect of the GBM. Subendothelial electron dense deposits sometimes evolve to more hyaline transmembrane deposits, with a lower electron density found in C3GN [18, 20, 34]. Many patients show subepithelial electron dense deposits, in some cases reminiscent of hump-like deposits seen in post-infectious glomerulonephritis.

In addition to glomerular deposits, electron dense transformation has been described in the basement membrane of Bowman's capsule and renal tubules, although usually focal and segmental [1, 12, 19, 34]. Dense electron change has also been found in the afferent arterioles and the area of the macula densa [12].

It is noteworthy that drusen, a characteristic pathologic finding in the Bruch's membrane in patients with DDD, and macular degeneration have the same ultrastructural appearance as the GBM in DDD [42]. Except for a report of electron dense transformation in the sinusoidal BM of the spleen in two patients with DDD, in no other organ systems have similar electron dense deposits been identified so far [46, 47].

The exact ultrastructure of electron dense deposits and the mechanism of unique GBM transformation remain to be elucidated. The three-dimensional ultrastructural findings of GBM in DDD patients suggest rigid and thickened GBM with a coarsely granular or undulating surface punctuated by single or clustered crater-like deformities unique to DDD [48].

## 5. C3 glomerulonephritis

C3 glomerulonephritis is characterized by exclusive or predominant C3 deposits on IF and electron dense mesangial and glomerular capillary walls deposits on EM, without electron dense osmiophilic transformation of the GBM characteristic of DDD. It encompasses examples of historical MPGN types I and III and other histological patterns in which IF reveals



dominant C3 deposits, indicating complement alternative pathway dysregulation as the underlying pathogenetic mechanism [24].

## 5.1. Clinical presentation

C3GN is a heterogeneous disease with respect to pathogenesis, clinical course and prognosis. Numerous mutations and polymorphisms in genes that code for proteins involved in complement alternative pathway and acquired abnormalities have been identified in patients with C3GN. There are two examples of familial forms of the disease with specific mutations, including CFHR5 nephropathy endemic in Cyprus and familial MPGN from Ireland [49, 50].

A recent study of a diverse American cohort including 111 patients with C3 glomerulopathy provided detailed information on the clinical presentation of C3GN and DDD [3]. Whites comprised the majority of C3GN patients (63.2%), followed by Hispanic, Asian and African-American patients, accounting for 19.5, 12.6 and 4.6% of the cohort, respectively. Surprisingly, patients with C3GN (mean age 28.3) were significantly younger than patients with DDD (mean age 40.0 years). The most common clinical presentation was hematuria and proteinuria with normal kidney function in both groups, but chronic kidney disease with proteinuria and hematuria was more frequent in DDD patients (41.7% in DDD vs. 18.6% in C3GN). Patients with C3GN more often presented with nephrotic syndrome than did DDD patients (32.6 vs. 16.7%). The prevalence of low complement level was the same in both groups, although the pediatric population demonstrated a significantly higher prevalence of low C3 levels and twice the rate of detectable genetic variants and/or autoantibodies.

Progression to end-stage renal disease (ESRD) was found in 40% of C3G patients, with no detectable difference between those with C3GN versus DDD, although previous reports have suggested a more favorable clinical course in C3GN patients [2, 26, 51, 52]. Markers of chronicity, whether clinical (reduced estimated glomerular filtration rate (eGFR), elevated serum creatinine) or histologic (interstitial fibrosis, glomerulosclerosis) at the time of diagnosis appeared the strongest predictors of outcome.

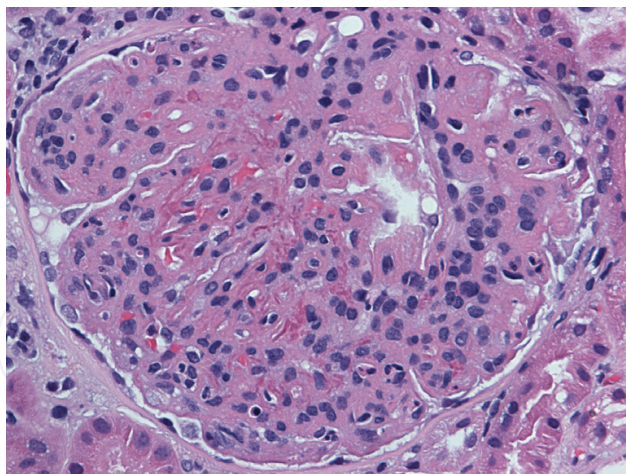
## 5.2. Pathologic findings

### 5.2.1. *Light microscopy*

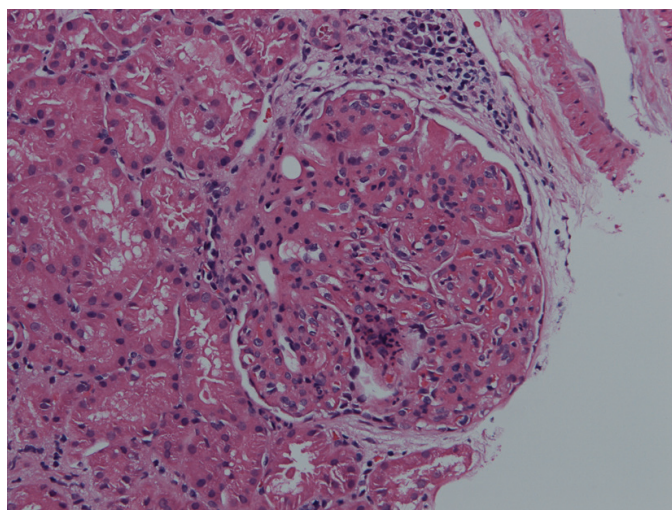
C3GN is defined by dominant C3 deposits on IF and deposits on EM. The light microscopic features are variable, including mesangial proliferation, a membranoproliferative pattern, crescent formation and endocapillary hypercellularity (**Figures 9–11**). There is no known association of the various histologic patterns with the underlying genetic or functional abnormalities of complement dysregulation [3, 24].

Bomback proposed a C3 Glomerulopathy Histologic Index to score biopsy activity and chronicity, in order to determine predictors of progression to ESRD in patients with C3GN [3, 24]. The activity score included mesangial hypercellularity, endocapillary hypercellularity, membranoproliferative morphology, leukocyte infiltration, crescent formation, fibrinoid necrosis and interstitial inflammation, while the chronicity score encompassed

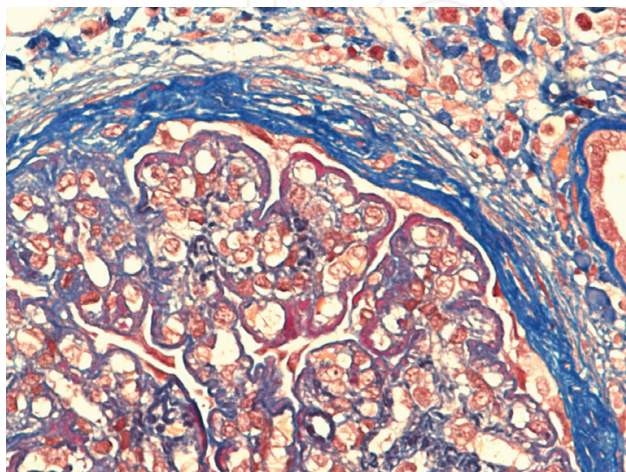




**Figure 9.** C3GN with membranoproliferative pattern (HE, 400×).



**Figure 10.** C3GN with membranoproliferative pattern with exudation of neutrophils (HE, 200×).



**Figure 11.** C3GN with membranoproliferative pattern with abundant transmembranous deposits staining with trichrome stain reminiscent of DDD (Trichrome stain, 600×).

glomerulosclerosis, tubular atrophy/interstitial fibrosis and arterio-arteriosclerosis. Patients with C3GN showed a higher activity score than DDD patients, and the latter revealed a higher chronicity score. In multivariable models, the strongest predictors of progression were eGFR at the time of diagnosis and tubular atrophy/interstitial fibrosis. The C3 Glomerulopathy Histologic Index might emerge as a useful tool for predicting the prognosis and management of patients with C3 glomerulopathy [3].

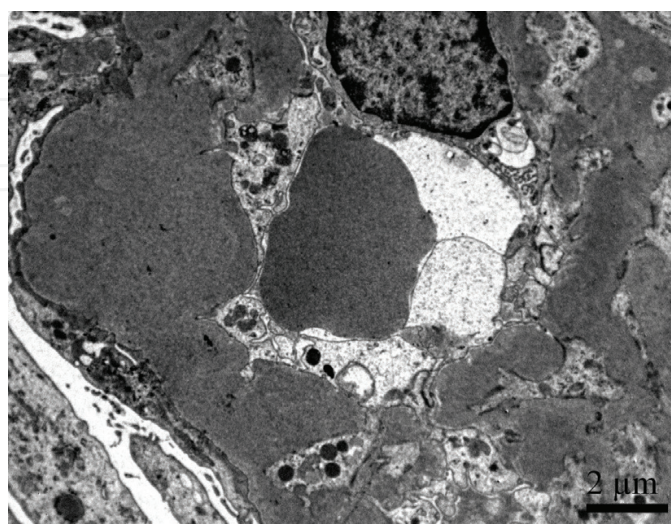
#### 5.2.2. Immunofluorescence

The defining feature on IF is the presence of dominant C3 glomerular deposits, at least two orders of magnitude stronger than any other immune reactant. It is noteworthy that a proposed cut-off does not encompass all patients with alternative pathway dysregulation, and there are overlaps between C3GN and immune complex glomerulonephritis [27, 29, 31].

In cases presenting with a mesangial histological pattern, C3 staining is mainly mesangial, while in the membranoproliferative pattern, there are abundant capillary wall as well as mesangial C3 deposits. In some cases, C3 staining was also found on the TBM [24, 53].

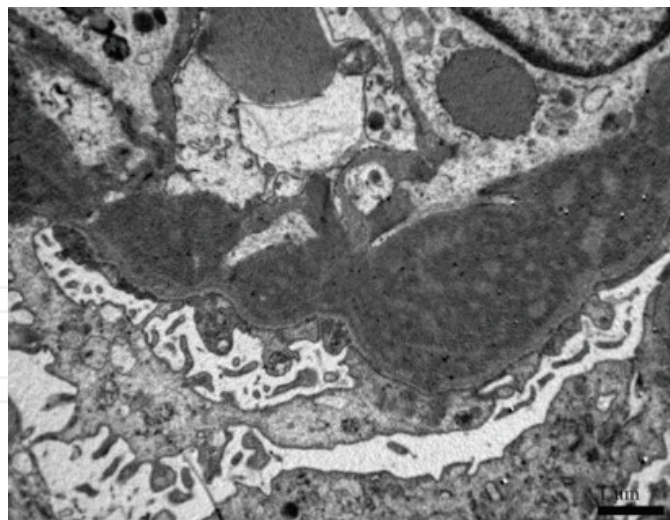
#### 5.2.3. Electron microscopy

EM revealed electron dense deposits in the mesangium and along or within the GBM, which correspond to C3 deposits on IF. Consistent with the definition of C3 glomerulopathy, deposits are composed predominantly of complement factors, although they may show similar density and appear at the same locations as deposits composed of immunoglobulins and C3 [24]. In some cases, deposits may be less dense and less sharply demarcated than typical immune complex deposits (**Figure 12**). In the glomerular capillary walls, there are abundant transmembrane deposits that appear to replace areas of the lamina densa, separated by material of similar density as the lamina densa, similar to the Anders Strife variant of MPGN type III (**Figure 13**). In some cases, there are curvilinear deposits of more electron dense material in the mesangium and



**Figure 12.** Abundant transmembrane deposits in C3GN may be less dense and less sharply demarcated than typical immune complex deposits.





**Figure 13.** Abundant transmembrane deposits that replace areas of the lamina densa, separated by material of similar density as the lamina densa, similar to the Anders Strife variant of MPGN type III.

beneath the endothelium, reminiscent of deposits in DDD. Occasional cases display substantial overlapping features between DDD and C3GN, making the subcategorization difficult [32].

Many C3GN patients present with subepithelial deposits. They may sometimes appear as subepithelial projections of intramembranous deposits but, in some cases, they resemble typical subepithelial humps seen in post-infectious glomerulonephritis. It is tempting to speculate that they may be related to C3GN exacerbated by infections [21].

## 6. Overview of the complement system

The complement system is a complex cascade in which proteolytic cleavage of glycoproteins induces an inflammatory response, phagocyte chemotaxis, opsonization, and cell lysis. It is triggered through three different pathways: the classical, alternative and mannose binding lectin, which converge on C3 to form an enzyme complex C3 convertase. C3 convertase cleaves C3, generating C3a, an anaphylatoxin, and C3b, a potent opsonin. A positive feedback loop, termed the C3 amplification loop, enables rapid amplification of C3b, which can generate millions of C3b molecules. C3b then deposit on cell surfaces, triggering complement cascade activation. Through the binding of an additional C3b molecule, C3 convertase becomes C5 convertase (C3bBbBB), which is capable of cleaving complement C5 into C5a and C5b. C5b, through sequential interaction with complements C6, C7, C8 and C9, generates membrane attack complex (MAC) [32, 54, 55].

In contrast to classical and lectin pathways, the alternative pathway is continually active in the circulation, by spontaneous hydrolysis of an internal thioester bond in C3 (tick over mechanism). Hydrolyzed C3 interacts with complement factor B (CFB) to form C3iB. CFB within C3iB is cleaved by complement factor D, resulting in C3 convertase (C3iBb), which cleaves C3 to a small amount of C3b. Cleaved C3b, similar to C3i, interacts with complement factors B to form C3 convertase (C3bBbBB). If the generation of C3 is not tightly regulated, it can

be rapidly amplified through a positive feedback pathway (C3b amplification loop), which results in activation of downstream convertase C5 and MAC formation. Several complement degradation products, including iC3b, are delivered to the endothelial surfaces, including the glomeruli. The deposition of complement products in the mesangium and in the subendothelial region triggers glomerular inflammation, leading to GN, often with a MPGN pattern [32].

Complement regulation is achieved by complement activator proteins and regulatory proteins present in plasma (fluid phase) and on cell surfaces (solid phase). Both regulate complement activation at different steps and pathways. If complement activator proteins are deficient, there is too little complement and these patients predispose to infections and autoimmune diseases. In regulatory protein deficiency, the complement system is upregulated, which results in impaired regulation and too much complement. Due to spontaneous activation of the alternative pathway and potency of the C3b amplification loop, both pathways are tightly regulated by complement factor I (CFI) and complement factor H (CFH) [30, 56].

Fluid phase regulators include factors CFH and CFI, whereas decay accelerating factor (DAF, CD55), complement receptor 1, CD 59 and membrane cofactor protein (MCP), are cell-bound regulators that act on cell surfaces [30]. Dysregulation between activating and regulatory factors in the fluid phase results in permanent activation of C3 convertase and at least partial activation of downstream complement factors, including C5 convertase and other proteins of the terminal complement cascade.

### 6.1. Complement factor I

CFI is a serine protease that cleaves C3b to iC3b and C3. While C3b can form C3 convertase, iC3b and C3d cannot, so the CFI-mediated cleavage of C3b stops further C3b activation. CFI can cleave C3b in the presence of cofactors, including CFH, membrane-bound protein (CD 46) and complement receptor 1 (CR1, CD35). In CFI deficiency, the spontaneous activation of the AP and, consequently, C3b amplification continue uncontrolled, leading to severe depletion of C3 in the plasma. Because CFI is crucial for generation of iC3b, iC3b cannot arise in complete CFI deficiency. Mice models have shown that the presence of CFI is crucial for deposits in the GBM and these deposits might be in the form of iC3b [30].

### 6.2. Complement factor H

Plasma protein CFH is the major negative regulator of the complement alternative pathway synthesized predominantly in the liver. It regulates C3 activation in two different compartments: in plasma (fluid phase) and along surfaces (solid phase) [32].

CFH is composed of 20 short consensus repeat (SCR) domains, with two major binding sites. The first four amino terminal domains represent binding sites for C3 convertase, thus regulating C3 in the fluid phase. The last two carboxyl terminal domains are involved in C3 activation along surfaces (solid phase) [30].

In plasma, CFH regulates C3 activation in different ways: it blocks the formation of AP convertase by binding to C3b, in order to inhibit interaction between C3b and factor B. Second, it accelerates the spontaneous breakdown of AP C3 convertase and is a cofactor for CFI



mediated inactivation of C3b to iC3b [32]. CFH deficiency results in uncontrolled C3b generation and secondary C3 depletion, but generation of C3b, iC3b and C3d is possible. In contrast, in complete CFI deficiency, generation of iC3b and C3d cannot occur.

CFH also regulates C3 activation along surfaces, including the renal endothelium and GBM. Optimal functioning of CFH requires interaction with C3b and polyanions. Through the terminal two carboxyl terminal domains, CFH attaches to cell surfaces and extracellular membranes, adding a protective mechanism to prevent complement activity on cell surfaces.

CFH is therefore involved in both fluid phase and solid phase regulation and mutation on different binding sites of the same regulatory protein may lead to different diseases. Mutations that selectively affect C3 regulation domains are associated with C3 glomerulopathy, whereas those affecting surface recognition domains are responsible for aHUS. In aHUS, there is complement-mediated damage to the renal endothelium, with consequent development of thrombotic microangiopathy [30, 56, 57].

Mice models provide some insights into the pathogenesis of aHUS and DDD. CFH mutations in aHUS affect predominantly the carboxyl terminal domains, resulting in impaired surface regulation, but the ability to regulate plasma C3 convertase is preserved. If the mutation affects the amino terminal domains, uncontrolled fluid phase C3 convertase activation occurs, resulting in disease analogous to DDD. Therefore, in DDD, the critical step is activation of C3 convertase in the fluid phase. In aHUS, the critical step is activation of C5 convertase and impaired surface regulation at the level of the cell membrane, in the solid phase. This solid phase dysregulation makes aHUS a more homogeneous disease than C3 glomerulopathy, with implications for prognosis and response to therapy [57].

### 6.3. Complement factor H-related proteins 1–5

There are five genes adjacent to the CFH gene, which encode structurally related proteins complement factor H-related proteins 1–5 (CFHR1–5). There are many regions of sequence homology across the CFH-CFHR locus that, through recombination, enables structural variations of CFHR: partial deletion or whole gene deletion or duplication, implying that these proteins are biologically redundant. Several combined deletions of different CFHR are found in various frequencies in a healthy population. The most common variant is combined deletion of the CFHR1 and CFHR3 genes, presenting in 5 and 16% of Caucasian and African-American populations, respectively [50].

Polymorphic variations within the CFH-CFHR gene locus are associated with diverse pathologies, including age-related macular degeneration (AMD), meningococcal sepsis, thrombotic and inflammatory kidney diseases such as aHUS and C3 glomerulopathy, and autoimmune diseases. The significance of homozygous deletion of CFHR1, 3 genes and the mechanisms of action are poorly understood. It might increase the risk of developing SLE, but is protective to IgA nephropathy and AMD, pathologies associated with complement deposition in affected tissues [41, 58, 59]. Based on a protective role for CFHR1, 3 genes deletion in IgA nephropathy, Malik et al. developed the hypothesis that the presence of CFHR1, 3 proteins impairs complement processing within the kidney [50].

### 6.3.1. *The role of CFHR5 in complement regulation*

Previous reports based on in vitro studies have implicated the involvement of CFHR proteins in complement regulatory activity [60]. According to a recent approach, these proteins have no direct complement regulatory activity at physiologic concentrations, unlike CFH [32].

The investigators postulated that CFHR5 may compete with CFH for binding to activated C3b. If CFH binds, C3b is inactivated, preventing further complement activation. Conversely, if CFHR binds to activated C3b, this prevents CFH binding, therefore enabling C3 convertase formation and continued complement activation. Since these proteins are devoid of intrinsic regulatory complement activity, this has been termed CFH deregulation [61].

CFHR1, CFHR2, and CFHR5 have recently been shown to form homodimers and heterodimers via common dimerization domains within SCR1 and SCR2 [62]. The dimerization of CFHR1, CFHR2 and CFHR5 may enhance the avidity of these proteins for ligand in vivo, thereby preventing CFH binding and thus functioning as complement deregulators [62].

The deregulation hypothesis could also explain the protective effect of CFHR1, 3 genes deletion in IgA nephropathy. Fewer CFHRs in serum could lead to less CFH deregulation, enabling tighter control of complement activation and inflammation. Conversely, circulating CFHR proteins 1 and 5 may correlate with increased disease activity, as shown in a large cohort of patients with IgA nephropathy [63].

### 6.4. **Membrane cofactor protein**

MCP is a surface-bound complement regulatory protein acting as a cofactor for the CFI mediated cleavage of C3b to iC3b on the cell surface. Polymorphism in the promoter region may influence MCP expression at the cell surfaces, which may explain the various patterns of deposits in C3G [2]. The majority of mutations in CD46 are detected in the extracellular domains of CD46 responsible for C3b and C4b binding.

## 7. **Familiar forms of C3 glomerulopathy**

### 7.1. **CFHR5 nephropathy**

Heterozygous mutations in CFHR5 are characteristic findings in complement factor H-related protein 5 nephropathy (CFHR5 nephropathy) [49, 64]. CFHR5 nephropathy is a subtype of C3GN, with autosomal dominant inheritance discovered in Cypriot families. A heterozygous mutation in CFHR5 results in duplication of the first two protein subunits, termed short consensus repeat. Affected individuals possess both the wild-type nine-domain CFHR5 protein and an abnormally large mutant CFHR5, with 11 domains [64].

Clinically, patients present with microscopic hematuria, proteinuria and synpharyngitic macroscopic hematuria similar to IgA nephropathy. There is progression to end-stage renal disease over the age of 50, particularly in males. Renal biopsies show deposition of C3 in the

mesangium, and characteristic elongated subendothelial electron dense deposits, and occasional subepithelial deposits. The laboratory profile of patients is normal, without decreased C3 levels, indicating that the complement activation occurs locally in the kidney and not at a systemic level. It has been speculated that abnormal CFHR5 in CFHR5 nephropathy may prevent CFH mediated regulation of C3, leading to increased activation of C3 along the glomerular basement membrane [64].

## 7.2. Other familiar forms of C3 glomerulonephritis

Recently, an abnormal CFHR5 protein in a family without Cypriot ancestry, identical to the aberrant CFHR5 protein found in Cypriot CFHR5 nephropathy, was identified, related to familial C3 glomerulonephritis. The clinical characteristics of the nephropathy in this pedigree were remarkably similar to Cypriot CFHR5 nephropathy: the typical presentation was with microscopic and intermittent macroscopic hematuria, and renal disease was more severe in affected males [65]. The genomic rearrangement was distinct from that seen in Cypriot CFHR5 nephropathy, although identical protein was identified.

A duplication of SCR 1–4 of CFHR1 was revealed in another familial form of C3G [66]. In mutant CFHR1, duplication of the N-terminal domain resulted in the formation of unusually large multimeric CFHR complexes that exhibited enhanced binding of mutated CFHR1 to ligands C3b, iC3b and C3d, resulting in enhanced competition and replacement of CFH bound to C3b. Patients usually presented with decreased C3 plasma levels, suggesting fluid phase complement activation and systemic disease.

## 8. Genetic and acquired abnormalities of complement associated with C3 glomerulopathy

C3G is associated with genetic and acquired abnormalities that result in uncontrolled activation of the complement alternative pathway. With the exception of diacylglycerol kinase epsilon, all genes associated with C3 glomerulopathy encode proteins in the complement system [67]. Mutations in complement factors and complement regulators are rare, but certain genetic polymorphisms contributing to fine balancing of complement regulation are more common.

Due to the complexity of the disease, C3 glomerulopathy is rarely inherited in a simple Mendelian fashion [68]. Rare familial cases of C3 glomerulopathy comprise highly penetrant heterozygous copy number variants involving CFHR1–5 genes described in Cypriot families, a family of Irish ancestry and a recently described family of non-Cypriot origin [49, 65, 66].

Most pathogenic variants of the C3 gene affect the proper cleavage of C3 protein by affecting recognition sites for binding of CFH or CFI. Loss-of-function changes in CFH, gain-of-function changes in C3 and structural changes within the CFH-CFHR gene family have been identified [69].

Acquired abnormalities include antibodies to complement activating proteins, such as antibody to C3 convertase, and antibodies which target the inhibitory complement factors

(CFH or CFI autoantibodies). C3Nef, antibody to C3 convertase, stabilizes C3 convertase of the alternative pathway by preventing its inactivation and degradation. Recent studies have shown that some autoantibodies might arise due to underlying genetic abnormalities [68].

In the largest study to date, encompassing 134 patients, Servais et al. analyzed the presence of C3Nef and other genetic and acquired abnormalities in patients with DDD, C3GN and primary MPGN type I [2]. C3Nef was identified in 86% of patients with DDD, but it was also present in 24% of GNC3 patients and even in 53% of patients with primary MPGN type I. CFH mutations were found in a similar frequency in all three groups of patients. MCP mutations seem to be very rare, identified in only one patient with C3GN. Another very interesting report described three patients with known homozygous CFH deficiency, who presented with different histological patterns, varying from mesangial proliferative to membranoproliferative [70]. Studies from rare cases with known genetic abnormalities indicate that entities with predominant C3 deposits, DDD and C3GN, as well as immune complex MPGN, are heterogeneous diseases.

Genetic or acquired complement AP abnormalities have also been identified in association with immune complex-mediated glomerulonephritis, such as systemic lupus erythematosus, and particularly frequently in patients with immune complex-mediated MPGN and atypical post-infectious glomerulonephritis, the latter showing overlapping features with C3 glomerulopathy [2, 21]. The question of why some patients present with DDD while others with ill-defined intramembranous deposits consistent with C3GN remains to be answered. The processes driving the particular morphologic appearance of glomerular deposits seem to be very complex, including genetic and environmental factors.

## 9. Treatment in C3 glomerulopathy

There is no universally effective treatment for C3 glomerulopathy. The only double blind randomized control trial was performed on 80 children with MPGN types I, II and III in 1992. They received 40 mg/m<sup>2</sup> of prednisolone on alternate days. Long-term treatment with prednisolone appeared to improve the outcome of patients with MPGN [71]. Other studies have suggested some benefit from the use of cyclophosphamide, mycophenolate mofetil and a combination of aspirin and dipyridamole. Current guidelines suggest treatment with steroids and cytotoxic agents, with or without plasmapheresis, only in patients with progressive disease with nephrotic range proteinuria and a decline of renal function [72]. Because C3G is a new diagnostic category, long-term data on renal transplants are lacking, but recurrence is probably as high as in idiopathic MPGN type I (up to 65% in some series).

Rituximab has emerged in the last decade as a treatment option for patients with various primary glomerular diseases. Despite data on the use of rituximab in MPGN and C3G being limited, patients with immunoglobulin-associated and idiopathic MPGN treated with rituximab showed a partial or complete response in the majority of cases [72]. It can be hypothesized that, in the presence of autoantibodies such as C3Nef, B-cell depleting therapy may have led to decreased production of C3Nef and, subsequently, stable renal function [72]. However,



rituximab was not effective in a few reported cases of C3GN and DDD. Only one patient with DDD and positive C3Nef treated solely with rituximab showed stable renal function and improvement of nephrotic syndrome after 30 months of follow-up, but C3Nef remained positive and C3 levels were always low [73]. In contrast, other cases with DDD and C3G initially treated with rituximab achieved partial or complete remission on eculizumab [72, 74].

Eculizumab is a humanized monoclonal antibody that binds with high affinity to C5 and prevents the generation of MAC and release of the very potent inflammatory mediator C5a. It is the treatment of choice in aHUS and paroxysmal nocturnal hematuria, but it may also provide an effective targeted treatment for patients with C3GN sharing an abnormality in the regulation of complement AP [75]. However, it has been suggested that eculizumab might be effective in some cases of C3GN, and that elevation of sMAC, lower circulating C3, short disease duration, acute lesions and limited fibrosis before treatment may predict a favorable response [24, 31, 76]. Eculizumab seems also to be effective in the treatment of a recurrence of DDD on renal transplants [76].

In patients with immune complex-mediated MPGN, refractory to conventional immunosuppression, the presence of complement AP dysregulation should be considered. When special laboratory and molecular genetic tests reveal an underlying complement alternative pathway dysregulation, they might respond to eculizumab treatment. Due to an initial immune complex-mediated mechanism, which can mask an underlying complement alternative pathway abnormality and subsequently trigger unbalanced excessive complement terminal pathway activation, supplementary steroids, in addition to eculizumab, may be necessary to achieve an adequate response [53].

## 10. Conclusions

C3 glomerulopathy is a heterogeneous disease, recently defined by dominant C3 glomerular deposits on immunofluorescence suggesting dysregulation of the alternative complement pathway as the underlying pathogenetic mechanism. It encompasses C3GN and DDD; DDD is characterized by dense osmiophilic deposits on EM. The appearance on light microscopy is quite variable, showing membranoproliferative, mesangial proliferative, crescentic, and acute proliferative and exudative histologic patterns. Genetic or acquired complement AP abnormalities have been identified in up to 40% of patients with C3 glomerulopathy, including mutations in complement factors or autoantibodies directed against them. Various clinical courses and histological features among patients with the same genetic defect indicate that other genetic factors or triggers from the environment contribute to the initiation and progression of complement mediated diseases. Despite multiple genetic risk factors, glomerular injury due to complement dysregulation often develops late in life, suggesting that additional triggers are required.

## Acknowledgements

I would like to thank Jerica Pleško for performing electron microscopy examinations and electron micrographs.

## Conflict of interest

There is nothing to declare.

## Author details

Nika Kojc

Address all correspondence to: [nika.kojc@mf.uni-lj.si](mailto:nika.kojc@mf.uni-lj.si)

Institute of Pathology, Faculty of Medicine, University of Ljubljana, Ljubljana, Slovenia

## References

- [1] Nasr SH, Valeri AM, Appel GB, Sherwinter J, Stokes MB, Said SM, et al. Dense deposit disease: Clinicopathologic study of 32 pediatric and adult patients. *Clinical Journal of the American Society of Nephrology*. 2009;**4**:22-32
- [2] Servais A, Noël LH, Roumenina LT, Le Quintrec M, Ngo S, Dragon-Durey MA, et al. Acquired and genetic complement abnormalities play a critical role in dense deposit disease and other C3 glomerulopathies. *Kidney International*. 2012;**82**:454-464
- [3] Bomback AS, Santoriello D, Avasare RS, Regunathan-Shenk R, Canetta PA, Ahn W, et al. C3 glomerulonephritis and dense deposit disease share a similar disease course in a large United States cohort of patients with C3 glomerulopathy. *Kidney International*. 2018;**93**:977-985
- [4] Sethi S, Fervenza FC. Membranoproliferative glomerulonephritis: Pathogenetic heterogeneity and proposal for a new classification. *Seminars in Nephrology*. 2011;**31**:341-348
- [5] Sethi S, Fervenza FC. Membranoproliferative glomerulonephritis—A new look at an old entity. *The New England Journal of Medicine*. 2012;**366**:1119-1131
- [6] Sethi S, Fervenza FC, Zhang Y, Nasr SH, Leung N, Vrana J, et al. Proliferative glomerulonephritis secondary to dysfunction of the alternative pathway of complement. *Clinical Journal of the American Society of Nephrology*. 2011;**6**:1009-1017
- [7] Rennke HG. Secondary membranoproliferative glomerulonephritis. *Kidney International*. 1995;**47**:643-656
- [8] Strife CF, McEnery PT, McAdams AJ, West CD. Membranoproliferative glomerulonephritis with disruption of the glomerular basement membrane. *Clinical Nephrology*. 1977;**7**:65-72
- [9] Fervenza FC, Sethi S, Glassock RJ. Idiopathic membranoproliferative glomerulonephritis: Does it exist? *Nephrology, Dialysis, Transplantation*. 2012;**27**:4288-4294

- [10] Burkholder PM, Marchand A, Krueger RP. Mixed membranous and proliferative glomerulonephritis. A correlative light, immunofluorescence, and electron microscopic study. *Laboratory Investigation*. 1970;**23**:459-479
- [11] Berger J, Galle P. Dense deposits within the basal membranes of the kidney. Optical and electron microscopic study. *Presse Médicale*. 1963;**71**:2351-2354
- [12] Habib R, Kleinknecht C, Gubler MC, Levy M. Idiopathic membranoproliferative glomerulonephritis in children. Report of 105 cases. *Clinical Nephrology*. 1973;**1**:194-214
- [13] D'Agati VD, Bomback AS. C3 glomerulopathy: What's in a name? *Kidney International*. 2012;**82**:379-381
- [14] Appel GB, Cook HT, Hageman G, Jennette JC, Kashgarian M, Kirschfink M, et al. Membranoproliferative glomerulonephritis type II (dense deposit disease): An update. *Journal of the American Society of Nephrology*. 2005;**16**:1392-1403
- [15] Roccatello D, Fornasieri A, Giachino O, Rossi D, Beltrame A, Banfi G, et al. Multicenter study on hepatitis C virus-related cryoglobulinemic glomerulonephritis. *American Journal of Kidney Diseases*. 2007;**49**:69-82
- [16] Smith KD, Alpers CE. Pathogenic mechanisms in membranoproliferative glomerulonephritis. *Current Opinion in Nephrology and Hypertension*. 2005;**14**:396-403
- [17] Strife CF, McAdams AJ, McEnery PT, Bove KE, West CD. Hypocomplementemic and normocomplementemic acute nephritis in children: A comparison with respect to etiology, clinical manifestations, and glomerular morphology. *The Journal of Pediatrics*. 1974;**84**:29-38
- [18] Joh K, Aizawa S, Matsuyama N, Yamaguchi Y, Kitajima T, Sakai O, et al. Morphologic variations of dense deposit disease: Light and electron microscopic, immunohistochemical and clinical findings in 10 patients. *Acta Pathol Jpn*. 1993;**43**:552-565
- [19] Walker PD. Dense deposit disease: New insights. *Current Opinion in Nephrology and Hypertension*. 2007;**16**:204-212
- [20] Walker PD, Ferrario F, Joh K, Bonsib SM. Dense deposit disease is not a membranoproliferative glomerulonephritis. *Modern Pathology*. 2007;**20**:605-616
- [21] Sethi S, Fervenza FC, Zhang Y, Zand L, Meyer NC, Borsa N, et al. Atypical postinfectious glomerulonephritis is associated with abnormalities in the alternative pathway of complement. *Kidney International*. 2013;**83**:293-299
- [22] Hou J, Markowitz GS, Bomback AS, Appel GB, Herlitz LC, Barry Stokes M, et al. Toward a working definition of C3 glomerulopathy by immunofluorescence. *Kidney International*. 2014;**85**:450-456
- [23] Levy M, Gubler MC, Sich M, Beziau A, Habib R. Immunopathology of membranoproliferative glomerulonephritis with subendothelial deposits (Type I MPGN). *Clinical Immunology and Immunopathology*. 1978;**10**:477-492

- [24] Sethi S, Fervenza FC, Zhang Y, Zand L, Vrana JA, Nasr SH, et al. C3 glomerulonephritis: Clinicopathological findings, complement abnormalities, glomerular proteomic profile, treatment, and follow-up. *Kidney International*. 2012;**82**:465-473
- [25] Sethi S, Gamez JD, Vrana JA, Theis JD, Bergen HR, Zipfel PF, et al. Glomeruli of dense deposit disease contain components of the alternative and terminal complement pathway. *Kidney International*. 2009;**75**:952-960
- [26] Zhang Y, Meyer NC, Wang K, Nishimura C, Frees K, Jones M, et al. Causes of alternative pathway dysregulation in dense deposit disease. *Clinical Journal of the American Society of Nephrology*. 2012;**7**:265-274
- [27] Fakhouri F, Frémeaux-Bacchi V, Noël LH, Cook HT, Pickering MC. C3 glomerulopathy: A new classification. *Nature Reviews. Nephrology*. 2010;**6**:494-499
- [28] Larsen CP, Walker PD. Redefining C3 glomerulopathy: 'C3 only' is a bridge too far. *Kidney International*. 2013;**83**:331-332
- [29] Sethi S, Nester CM, Smith RJ. Membranoproliferative glomerulonephritis and C3 glomerulopathy: Resolving the confusion. *Kidney International*. 2012;**81**:434-441
- [30] Pickering M, Cook HT. Complement and glomerular disease: New insights. *Current Opinion in Nephrology and Hypertension*. 2011;**20**:271-277
- [31] Pickering MC, D'Agati VD, Nester CM, Smith RJ, Haas M, Appel GB, et al. C3 glomerulopathy: Consensus report. *Kidney International*. 2013;**84**:1079-1089
- [32] Cook H, Pickering M. C3 glomerulopathies, including dense deposit disease. In: Jennete J, Olson J, Silva F, D'Agati V, editors. *Heptinstall's Pathology of the Kidney*. Philadelphia: Wolters Kluwer; 2015. pp. 341-366
- [33] Cook HT. Evolving complexity of complement-related diseases: C3 glomerulopathy and atypical haemolytic uremic syndrome. *Current Opinion in Nephrology and Hypertension*. 2018;**27**:165-170
- [34] Sibley RK, Kim Y. Dense intramembranous deposit disease: New pathologic features. *Kidney International*. 1984;**25**:660-670
- [35] Schwartz R, Rother U, Anders D, Gretz N, Schärer K, Kirschfink M. Complement analysis in children with idiopathic membranoproliferative glomerulonephritis: A long-term follow-up. *Pediatric Allergy and Immunology*. 2001;**12**:166-172
- [36] Lu DF, Moon M, Lanning LD, McCarthy AM, Smith RJ. Clinical features and outcomes of 98 children and adults with dense deposit disease. *Pediatric Nephrology*. 2012;**27**:773-781
- [37] Walport MJ, Davies KA, Botto M, Naughton MA, Isenberg DA, Biasi D, et al. C3 nephritic factor and SLE: Report of four cases and review of the literature. *QJM*. 1994;**87**:609-615
- [38] Sheeran TP, White RH, Raafat F, Jackson MA, Kumararatne DS, Situnayake RD. Hypocomplementaemia, C3 nephritic factor and type III mesangiocapillary glomerulonephritis progressing to systemic lupus erythematosus. *British Journal of Rheumatology*. 1995;**34**:90-92



- [39] Cronin CC, Higgins TJ, Molloy M. Lupus, C3 nephritic factor and partial lipodystrophy. *QJM*. 1995;**88**:298-299
- [40] Frémeaux-Bacchi V, Weiss L, Demouchy C, May A, Palomera S, Kazatchkine MD. Hypocomplementaemia of poststreptococcal acute glomerulonephritis is associated with C3 nephritic factor (C3NeF) IgG autoantibody activity. *Nephrology, Dialysis, Transplantation*. 1994;**9**:1747-1750
- [41] Hageman GS, Hancox LS, Taiber AJ, Gehrs KM, Anderson DH, Johnson LV, et al. Extended haplotypes in the complement factor H (CFH) and CFH-related (CFHR) family of genes protect against age-related macular degeneration: Characterization, ethnic distribution and evolutionary implications. *Annals of Medicine*. 2006;**38**:592-604
- [42] Colville D, Guymer R, Sinclair RA, Savige J. Visual impairment caused by retinal abnormalities in mesangiocapillary (membranoproliferative) glomerulonephritis type II ("dense deposit disease"). *American Journal of Kidney Diseases*. 2003;**42**:E2-E5
- [43] Holz FG, Pauleikhoff D, Klein R, Bird AC. Pathogenesis of lesions in late age-related macular disease. *American Journal of Ophthalmology*. 2004;**137**:504-510
- [44] Abrera-Abeleda MA, Nishimura C, Smith JL, Sethi S, McRae JL, Murphy BF, et al. Variations in the complement regulatory genes factor H (CFH) and factor H related 5 (CFHR5) are associated with membranoproliferative glomerulonephritis type II (dense deposit disease). *Journal of Medical Genetics*. 2006;**43**:582-589
- [45] Misra A, Peethambaram A, Garg A. Clinical features and metabolic and autoimmune derangements in acquired partial lipodystrophy: Report of 35 cases and review of the literature. *Medicine (Baltimore)*. 2004;**83**:18-34
- [46] Ormos J, Mágóri A, Sonkodi S, Streitmann K. Type 2 membranoproliferative glomerulonephritis with electron-dense basement membrane alteration in the spleen. *Archives of Pathology & Laboratory Medicine*. 1979;**103**:265-266
- [47] Thorner P, Bauml R. Extraglomerular dense deposits in dense deposit disease. *Archives of Pathology & Laboratory Medicine*. 1982;**106**:628-631
- [48] Weidner N, Lorentz WB. Three-dimensional studies of acellular glomerular basement membranes in dense-deposit disease. *Virchows Archiv. A, Pathological Anatomy and Histopathology*. 1986;**409**:595-607
- [49] Gale DP, de Jorge EG, Cook HT, Martinez-Barricarte R, Hadjisavvas A, McLean AG, et al. Identification of a mutation in complement factor H-related protein 5 in patients of Cypriot origin with glomerulonephritis. *Lancet*. 2010;**376**:794-801
- [50] Malik TH, Lavin PJ, Goicoechea de Jorge E, Vernon KA, Rose KL, Patel MP, et al. A hybrid CFHR3-1 gene causes familial C3 glomerulopathy. *Journal of the American Society of Nephrology*. 2012;**23**:1155-1160
- [51] Medjeral-Thomas NR, O'Shaughnessy MM, O'Regan JA, Traynor C, Flanagan M, Wong L, et al. C3 glomerulopathy: Clinicopathologic features and predictors of outcome. *Clinical Journal of the American Society of Nephrology*. 2014;**9**:46-53

- [52] Okuda Y, Ishikura K, Hamada R, Harada R, Sakai T, Hamasaki Y, et al. Membrano-proliferative glomerulonephritis and C3 glomerulonephritis: Frequency, clinical features, and outcome in children. *Nephrology (Carlton)*. 2015;**20**:286-292
- [53] Kersnik Levart T, Ferluga D, Vizjak A, Mraz J, Kojc N. Severe active C3 glomerulonephritis triggered by immune complexes and inactivated after eculizumab therapy. *Diagnostic Pathology*. 2016;**11**:94
- [54] Berger SP, Roos A, Daha MR. Complement and the kidney: What the nephrologist needs to know in 2006? *Nephrology, Dialysis, Transplantation*. 2005;**20**:2613-2619
- [55] Thurman JM, Holers VM. The central role of the alternative complement pathway in human disease. *Journal of Immunology*. 2006;**176**:1305-1310
- [56] Zipfel PF, Smith RJ, Skerka C. Factor I and factor H deficiency in renal diseases: Similar defects in the fluid phase have a different outcome at the surface of the glomerular basement membrane. *Nephrology, Dialysis, Transplantation*. 2009;**24**:385-387
- [57] Vernon KA, Ruseva MM, Cook HT, Botto M, Malik TH, Pickering MC. Partial complement factor H deficiency associates with C3 glomerulopathy and thrombotic microangiopathy. *Journal of the American Society of Nephrology*. 2016;**27**:1334-1342
- [58] Gharavi AG, Kiryluk K, Choi M, Li Y, Hou P, Xie J, et al. Genome-wide association study identifies susceptibility loci for IgA nephropathy. *Nature Genetics*. 2011;**43**:321-327
- [59] Hughes AE, Orr N, Esfandiary H, Diaz-Torres M, Goodship T, Chakravarthy U. A common CFH haplotype, with deletion of CFHR1 and CFHR3, is associated with lower risk of age-related macular degeneration. *Nature Genetics*. 2006;**38**:1173-1177
- [60] Hebecker M, Józsi M. Factor H-related protein 4 activates complement by serving as a platform for the assembly of alternative pathway C3 convertase via its interaction with C3b protein. *The Journal of Biological Chemistry*. 2012;**287**:19528-19536
- [61] Skerka C, Chen Q, Fremeaux-Bacchi V, Roumenina LT. Complement factor H related proteins (CFHRs). *Molecular Immunology*. 2013;**56**:170-180
- [62] Goicoechea de Jorge E, Caesar JJ, Malik TH, Patel M, Colledge M, Johnson S, et al. Dimerization of complement factor H-related proteins modulates complement activation in vivo. *Proceedings of the National Academy of Sciences of the United States of America*. 2013;**110**:4685-4690
- [63] Medjeral-Thomas NR, Lomax-Browne HJ, Beckwith H, Willicombe M, McLean AG, Brookes P, et al. Circulating complement factor H-related proteins 1 and 5 correlate with disease activity in IgA nephropathy. *Kidney International*. 2017;**92**:942-952
- [64] Athanasiou Y, Voskarides K, Gale DP, Damianou L, Patsias C, Zavros M, et al. Familial C3 glomerulopathy associated with CFHR5 mutations: Clinical characteristics of 91 patients in 16 pedigrees. *Clinical Journal of the American Society of Nephrology*. 2011;**6**:1436-1446

- [65] Medjeral-Thomas N, Malik TH, Patel MP, Toth T, Cook HT, Tomson C, et al. A novel CFHR5 fusion protein causes C3 glomerulopathy in a family without Cypriot ancestry. *Kidney International*. 2014;**85**:933-937
- [66] Tortajada A, Yébenes H, Abarrategui-Garrido C, Anter J, García-Fernández JM, Martínez-Barricarte R, et al. C3 glomerulopathy-associated CFHR1 mutation alters FHR oligomerization and complement regulation. *The Journal of Clinical Investigation*. 2013;**123**:2434-2446
- [67] Wong EKS, Kavanagh D. Diseases of complement dysregulation—An overview. *Seminars in Immunopathology*. 2018;**40**:49-64
- [68] Zhao W, Ding Y, Lu J, Zhang T, Chen D, Zhang H, et al. Genetic analysis of the complement pathway in C3 glomerulopathy. *Nephrology, Dialysis, Transplantation*. 2018;1-9. DOI: 10.1093/ndt/gfy033
- [69] Martínez-Barricarte R, Heurich M, Valdes-Cañedo F, Vazquez-Martul E, Torreira E, Montes T, et al. Human C3 mutation reveals a mechanism of dense deposit disease pathogenesis and provides insights into complement activation and regulation. *The Journal of Clinical Investigation*. 2010;**120**:3702-3712
- [70] Servais A, Noël LH, Dragon-Durey MA, Gübler MC, Rémy P, Buob D, et al. Heterogeneous pattern of renal disease associated with homozygous factor H deficiency. *Human Pathology*. 2011;**42**:1305-1311
- [71] Tarshish P, Bernstein J, Tobin JN, Edelmann CM. Treatment of mesangiocapillary glomerulonephritis with alternate-day prednisone—A report of the International Study of Kidney Disease in Children. *Pediatric Nephrology*. 1992;**6**:123-130
- [72] Rudnicki M. Rituximab for Treatment of Membranoproliferative Glomerulonephritis and C3 Glomerulopathies. *BioMed Research International*. 2017;**2017**:2180508
- [73] Giaime P, Daniel L, Burtey S. Remission of C3 glomerulopathy with rituximab as only immunosuppressive therapy. *Clinical Nephrology*. 2015;**83**:57-60
- [74] Daina E, Noris M, Remuzzi G. Eculizumab in a patient with dense-deposit disease. *The New England Journal of Medicine*. 2012;**366**:1161-1163
- [75] Nester CM, Brophy PD. Eculizumab in the treatment of atypical haemolytic uraemic syndrome and other complement-mediated renal diseases. *Current Opinion in Pediatrics*. 2013;**25**:225-231
- [76] Herlitz LC, Bomback AS, Markowitz GS, Stokes MB, Smith RN, Colvin RB, et al. Pathology after eculizumab in dense deposit disease and C3 GN. *Journal of the American Society of Nephrology*. 2012;**23**:1229-1237