

We are IntechOpen, the world's leading publisher of Open Access books Built by scientists, for scientists

6,900

Open access books available

186,000

International authors and editors

200M

Downloads

Our authors are among the

154

Countries delivered to

TOP 1%

most cited scientists

12.2%

Contributors from top 500 universities



WEB OF SCIENCE™

Selection of our books indexed in the Book Citation Index
in Web of Science™ Core Collection (BKCI)

Interested in publishing with us?
Contact book.department@intechopen.com

Numbers displayed above are based on latest data collected.
For more information visit www.intechopen.com



Optic Nerve: Developmental Anomalies and Common Tumors

Hind Alkatan, Daniah Alshowaeir and
Tariq Alzahem

Additional information is available at the end of the chapter

<http://dx.doi.org/10.5772/intechopen.80326>

Abstract

The optic nerve, also known as the second cranial nerve, is composed of axons that transmit visual information from the neurosensory retina to the visual cortex. There are multiple pathologies that can affect the human optic nerve. Congenital anomalies of the optic nerve include myelinated nerve fibers, morning glory syndrome, optic nerve choristoma, optic nerve coloboma, optic nerve hypoplasia and aplasia, and others. Tumors that can affect the optic nerve (ON) may occur primarily from within the nerve itself, from the surrounding optic nerve sheath (ONS), or secondarily spreading to the nerve from a distant site. They include optic pathway glioma, medulloepithelioma, oligodendroglioma, optic nerve sheath meningioma, and others. Here in this chapter, we will review the optic nerve anatomy, embryology, and physiology in addition to assessment of optic nerve function. Moreover, the clinical features, imaging findings, pathology, and treatment options of the most common and some rare congenital anomalies and primary tumors of the ON and sheath will be reviewed.

Keywords: myelinated nerve fibers, morning glory syndrome, optic nerve choristoma, optic nerve coloboma, optic nerve hypoplasia, aplasia, optic nerve tumor, glioma, meningioma, ganglioglioma, medulloepithelioma, hemangioblastoma, oligodendroglioma

1. Introduction

Visual perception occurs when light stimulus in the surrounding environment converts to nerve impulses at the level of photoreceptors, which then reach the brain to be processed. The light energy is converted to neuronal signals that are transmitted through several layers

in the retina to reach the ganglion cells. The axons of the ganglion cells form the optic nerve. Signals are carried out from the optic nerve through the optic chiasm and optic tract, which is connected to the lateral geniculate body. From there, signals reach the visual cortex in the occipital lobe through the optic radiation.

The chapter is divided into three main sections. Section 1 describes the basic embryology, anatomy, and physiology of the optic nerve. Section 2 briefly discusses optic nerve developmental anomalies, and the last section briefly reviews the most common optic nerve tumors and discusses their management modalities.

2. Optic nerve embryology, anatomy, physiology, and function

2.1. Optic nerve embryology

The optic nerve has a neural ectoderm origin. It develops within the optic stalk, which appears by 22–28 days of gestation. The optic stalk connects the optic vesicle to the cavity of the fore-brain [1]. It has two layers, the inner layer is the axons of the ganglion cell layer and the outer layer is a neuroglial supporting cells. At 8 weeks of gestation, neuroepithelial cells including astrocytes and oligodendrocytes proliferate and participate in the formation of the connective tissue and myelination of the optic nerve. Myelination starts centrally and reaches the lamina cribrosa at or shortly after birth [2].

2.2. Optic nerve anatomy and physiology

The nerve fiber layer in the retina is the ganglion cell axons, which are generally unmyelinated and receive blood supply from the central retinal artery. Ganglion cell axons turn 90° to enter the optic disc, where they form the optic nerve. The optic disc is supplied by a ring of branches from the short ciliary arteries called the circle of Zinn. Peripapillary arteries also contribute to the optic disc blood supply. The optic nerve consists of 1.2 million fibers with different sizes of diameter, ranging from 0.7 to 10 μm . Smaller fibers serve the central vision, while larger ones come from the peripheral retina [3]. The macular fibers are deep in the center of the optic nerve, while the fibers of the peripheral retina are more superficial.

The length of the optic nerve is around 6 cm and can be divided anatomically into four segments: intraocular (0.7–1 mm), intraorbital (30 mm), intracanalicular (6–10 mm), and intracranial (10–16 mm). The lamina cribrosa divides the intraocular part into prelaminar and laminar sections [4]. It is important to note that this part of the nerve is not myelinated. Oligodendrocytes are responsible for the myelination of nerves, and it is believed that the lamina cribrosa acts as a barrier preventing them from myelinating the intraocular section of the optic nerve [5].

Beyond the lamina cribrosa, the optic nerve is myelinated and surrounded by a dural sheath and cerebrospinal fluid. The extraocular muscles surround the optic nerve in the orbit. The optic nerve sheath is adherent to the superior and medial rectus muscle, hence the pain with eye movement when the optic nerve is inflamed in cases such as optic neuritis. The ophthalmic artery is the first branch from the internal carotid artery, and it forms the main blood

supply for intraorbital and intracanalicular division of the optic nerve. The ophthalmic artery passes through the dural sheath of the optic nerve in the intracanalicular section. The intracranial optic nerve division is supplied by branches from the ophthalmic, anterior cerebral, anterior communicating, and internal carotid arteries. Ninety percent of the optic nerve fibers from both sides join in the optic chiasm, while the remaining 10% of fibers project to areas controlling pupillary responses [5].

2.3. Assessment of optic nerve function

The optic nerve function is assessed by evaluating several elements including the visual acuity, color vision and contrast testing, relative afferent pupillary defect in cases of asymmetric optic neuropathy, and visual field testing. These parameters should be evaluated in every patient with suspected optic neuropathy. In addition, electrophysiological testing is another adjunctive test used to assess optic neuropathies.

2.3.1. Visual acuity (VA)

Visual acuity is a vital function of the optic nerve and an important measure of the visual function. The smallest visual angle at which two distinct objects can be distinguished is referred to as the minimum separable threshold. The best-corrected visual acuity (BCVA) should be obtained with refraction to exclude any refractive errors. The physician can expect a refractive error when there is an improvement of visual acuity with pinhole viewing.

Snellen acuity is measured with test letters (optotypes), and they are designed in a way so that the letter as a whole subtends an angle of 5 min of arc at a specified distance. A 20/40 Snellen acuity (6/12 in m) means that the patient can see the 20/40 line 20 feet away from the chart what a normal person can see clearly 40 feet away.

2.3.2. Color vision

Optic nerve diseases, especially optic neuritis, may disproportionately affect color vision compared with BCVA. In macular disease, however, both visual acuity and color vision tend to be affected congruently. In addition, color vision deficit (dyschromatopsia) can persist even after recovery of visual acuity in optic neuropathy.

Color vision testing is done monocularly. Pseudoisochromatic color plate is widely available and frequently used to evaluate color vision. Bilateral, symmetric, color vision deficit in males may indicate congenital dyschromatopsia. The most detailed color vision test is the Farnsworth-Munsell 100-hue test. It uses 85 colored discs, and thus, it needs a considerable amount of time that limits its use in routine clinical practice.

2.3.3. Contrast sensitivity

Contrast sensitivity is simply defined as the ability to recognize the degree of contrast between the optotype and its background. The higher the contrast, the easier the optotype is to be seen. Increasing the illumination makes it easier to read because this creates a higher contrast against the black letters. Snellen acuity optotypes are projecting at approximately

100% contrast that can be resolved more easily by the visual system. However, 100% contrast is rarely encountered in everyday life, and therefore, 20/20 vision does not always mean good vision as low-contrast sensitivity may significantly compromise the visual quality.

Contrast sensitivity testing can detect and quantify vision loss in the presence of normal visual acuity. The Pelli-Robson contrast sensitivity letter consists of rows of letters of equal size but with decreasing contrast for groups of three letters. Sinusoidal gratings require the test subject to view a sequence of increasingly lower contrast gratings. Many conditions reduce contrast sensitivity. They include optic neuropathy, posterior subcapsular cataracts, and amblyopia. Contrast sensitivity testing is not commonly used in clinical practice.

2.3.4. Pupillary examination

Pupillary examination and particularly testing for relative afferent pupillary defect (RAPD) is highly sensitive for optic nerve diseases. Under normal conditions, light source directed at one pupil causes symmetric ipsilateral and contralateral pupillary constriction (direct and consensual response). When the optic nerve of one eye is damaged or inflamed more than the other eye, a relative afferent pupillary defect is seen in the more affected eye. In other words, shining the light over the normal, or less affected, eye will result in bilateral pupillary constriction. However, when the light is swung to the more affected eye, we will see a bilateral pupillary dilation as the signal conduction along the optic nerve is relatively compromised compared to the other eye.

An absence of RAPD usually indicates a bilaterally normal optic nerves or a bilateral symmetric optic neuropathy. RAPD can be seen in patients with significant retinal dysfunction including central retinal artery occlusion, ischemic central retinal vein occlusion, or retinal detachment.

2.3.5. Visual field

Visual field is another important function of the optic nerve in which a visual field defect testing can describe, quantify, monitor, and localize the different patterns of visual loss. There are different techniques available to evaluate visual field. The choice of technique depends on the degree of detail required and the cooperation of the patient.

Confrontation visual field testing is a simple test that can be done at the bedside or in the clinic providing a gross evaluation of the visual fields. The examiner sits 1 m from the patient. The patient is asked to cover one eye and fixate on the examiner's nose by the other eye. Then, the examiner requests the patient to identify the numbers (1, 2, or 5) presented by the examiner's fingers at the midpoint of each of the four quadrants for each eye.

A more detailed evaluation of the visual field is assessed by perimetry. There are two main types: static and kinetic perimetry. In static testing, stimuli are static and turn on and off at different points within area the visual field to be tested. In kinetic testing, a stimulus is moved from a nonseeing peripheral area to a seeing area of the visual field. In kinetic testing, an isopter is drawn by connecting all points of equal sensitivity for a specific stimulus.

2.3.6. Visual evoked potentials (VEP) in the assessment of optic nerve function

Visual evoked potential (VEP) is an electrical response recorded mainly from the visual cortex in response to light stimulus. It was first introduced in 1930s, and its role has evolved over the years [6]. In 1961, Ciganek was the first to describe an electroencephalography (EEG) response to a flashlight stimulus in humans, followed by one of the earliest clinical studies of VEP reported by Halliday and colleagues on patients with optic neuritis [7, 8].

VEP provides an objective and reproducible measure of visual function and continues to have an imperative complementary role to other tests that provide information on the structure of the visual system such as MRI and optical coherence tomography (OCT).

The recording of VEP is performed using occipital mounted electrodes with, typically, monocular stimulation. Several forms of visual stimulus can be used to generate a VEP. The most common stimuli used are flash visual evoked potential (fVEP), pattern-onset VEP, and reversing black and white checkerboard pattern (PVEP). Because of fVEP's high intersubject variability and low sensitivity, PVEP is preferred in most clinical setting. fVEP is frequently used in infants, uncooperative patients or if significant media opacity is present. The pattern-onset VEP is preferred in patients with fixation instability such as nystagmus since the PVEP is severely reduced in those patients due to the effect of retinal image motion on the stimulus efficiency [9, 10].

The testing technique for both stimulus conditions has been standardized by the International Society of Clinical Electrophysiology of Vision (ISCEV) to reach a better consistency of results between different electrophysiology laboratories [11]. The PVEP waveform is triphasic with a prominent positive peak (P100) at around 100 ms, an earlier negative peak at around 75 ms, and a late negative peak at around 135 ms after stimulation (**Figure 1**). The amplitude of the P100 reflects the number of functional afferent axons reaching the cortex. The implicit time (latency) is believed to reflect the degree of demyelination. An abnormal VEP response

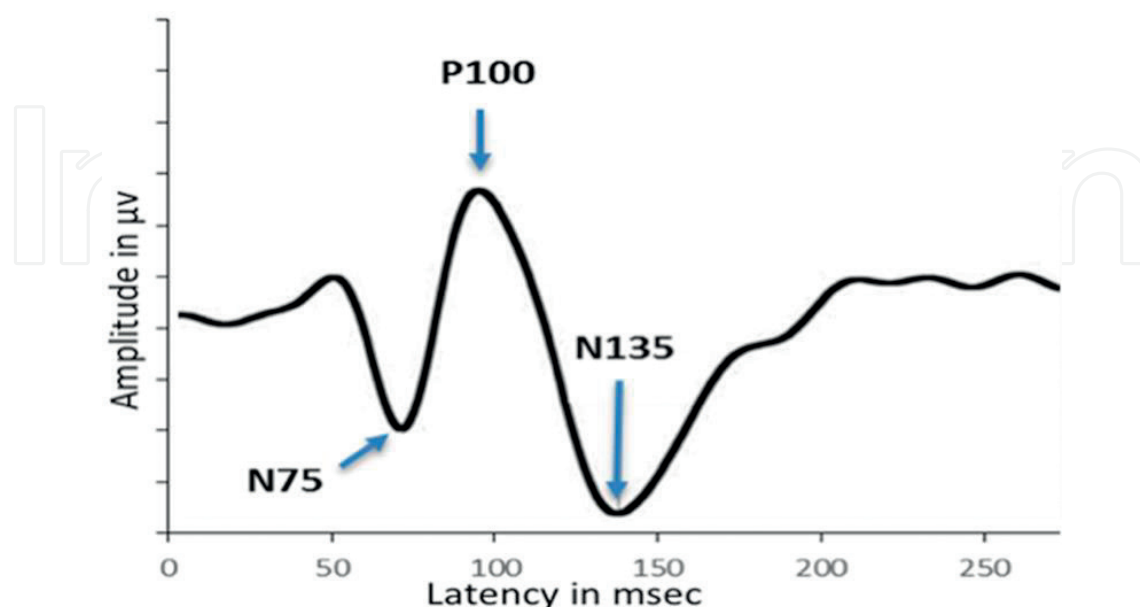


Figure 1. Normal waveform of a standard PVEP. Arrows showing first negative peak (N75), positive peak (P100), and a late negative peak (N135).

indicates a functional disturbance in the afferent visual pathway, and occasionally, conventional VEP may provide some information on the location of the lesion [12]. For example, based on the neuroanatomy of the visual system, a unilateral VEP abnormality implies an abnormality in the anterior optic pathway. Localization is less likely when the delay is bilateral.

3. Developmental anomalies of the optic nerve

3.1. Myelinated nerve fibers

The prevalence of myelinated nerve fibers (MNF) is around 1% in autopsy studies [13]. MNF are typically congenital, and therefore likely represent anomalies of myelination control in utero. They appear as gray or white striated patches with feathered borders, which are most commonly unilateral, with only 7.7% of cases estimated to occur bilaterally (**Figure 2**) [13, 14]. The mechanism by which MNF occur might be linked to unknown level of communication between adjacent oligodendrocytes (which are responsible for myelinating the axons of subsets of neurons in the central nervous system) in the selection of axons for myelination [15]. Recently, a case of bilateral extensive peripapillary MNF has been reported in a patient with Crouzon syndrome, an inherited form of craniosynostosis caused by over-activation of fibroblast growth factor receptor 2 [16].

3.2. Morning glory syndrome (MGS)

MGS is a rare congenital optic disc anomaly, first reported by Pendler [17] then more accurately described 10 years later [18]. The pathogenesis of MGS is uncertain, but probably is an embryological form of optic disc dysplasia and is thought not to be a true coloboma, but rather a posterior ectasia, which is the consequence of developmental disturbance of sclera [19, 20]. MGS is characterized by a funnel-shaped enlarged optic disc with a central mass of glial tissue and emerging radial retinal vessels that emerge from the central core toward the peripheral retina (**Figure 3**) [21]. MGS is a nonprogressive and untreatable condition, which

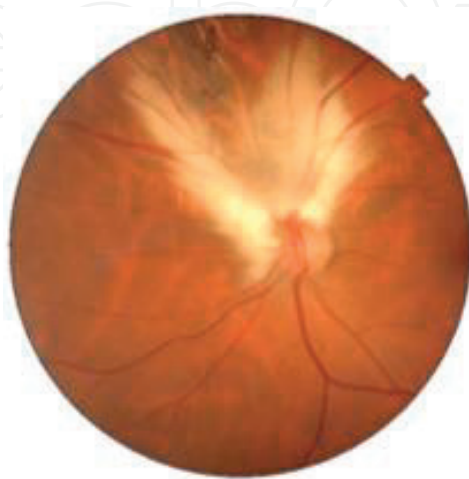

Figure 2. Myelinated nerve fibers (MNF).

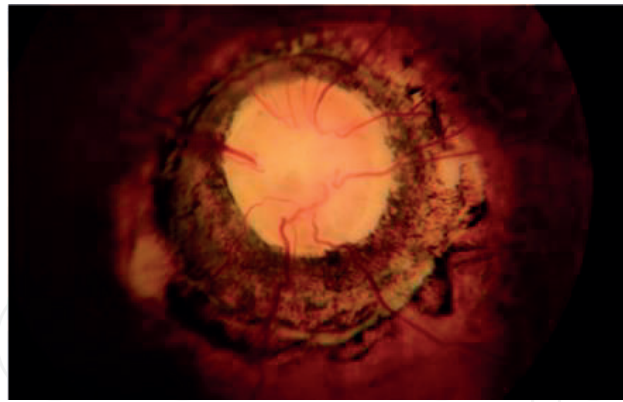


Figure 3. Morning glory syndrome.

usually occurs as an isolated ocular anomaly, or can also be associated with other ocular abnormalities such as strabismus, afferent pupillary defect, visual field defects, preretinal gliosis, and open angle glaucoma [22–25]. The optic nerve has been reported to present with characteristics of coloboma, hypoplasia, and morning glory anomaly, as an overlapping phenotypic profile that has been described in relation to *PAX6* mutations, which influences the phenotypes of optic nerve malformations [26].

3.3. Optic nerve choristoma

Choristoma is an uncommon congenital tumor where normal-looking tissue (epithelial, glandular, cartilaginous, osseous, smooth muscle, and fat) is present in an area where it should not be normally present. Most ocular choristomas are periocular but can also be rarely found as an intraocular choristoma involving the iris, ciliary body, choroid, and optic nerve head [27]. The largest series on optic nerve choristomas in the English literature was published in 1972 including 26 cases of optic nerve colobomas in enucleated eyes, and all cases were diagnosed to have associated heterotopic adipose and/or smooth muscle tissue on pathological examination. The age at enucleation ranged from 6 weeks to 70 years [28]. An interesting case presenting with mixed clinical features of optic nerve coloboma and morning glory—as previously described by others—has been reported by Mishra but unexpectedly had histopathological evidence of a choristoma [29, 30]. The authors commented that there is insufficient knowledge in the literature about the natural history and outcome of optic nerve choristoma, but their 15-year old girl has shown dramatic rapid deterioration of vision. They attributed this to the abnormal architecture of the colobomatous nerve that resulted in the patient's vulnerability to the critical growth of the choristomatous tissue during adolescence, on the top of the slow axonal loss from the choristoma, as evident by the pallor of the optic nerve head at the time of presentation [30].

3.4. Optic nerve coloboma

Ocular coloboma occurs in relation to the failure of the closure of the embryonic fissure that results from the evagination of the developing optic vesicle during embryogenesis and eye development. The fissure is located inferiorly and includes the optic stalk (future optic nerve)

that connects the developing forebrain to the eye. The extent of the colobomatous defect depends on the location of the arrested closure of that fissure. Colobomas in the eye can be seen anteriorly involving the iris and ciliary body or posteriorly involving the optic nerve. The optic nerve coloboma appears as a sharp whitish excavation inferiorly with a thin neuroretinal rim and may even extend to involve the adjacent choroidal and retinal tissue. Optic disc colobomas can occur bilaterally, can be sporadic, or can have an autosomal dominant inheritance. Ocular coloboma is known to show extensive locus heterogeneity associated with causative mutations identified in genes encoding developmental transcription factors or components of signaling pathways that are involved in the posterior segment development as a whole. Optic nerve coloboma can be associated with similar colobomatous anterior uveal or posterior chorioretinal defect as well as possible more extensive manifestations (anophthalmia/microphthalmia) related to the defective and/or failure of embryonic fissure closure [30]. The term microphthalmia is used to indicate the marked reduction in the size of an eye. Microphthalmia, anophthalmia, and coloboma resulting from failure of optic fissure closure during embryogenesis have been grouped as a single phenotype or spectrum (MAC) in most of the recent studies aiming at identification of responsible genes [31, 32]. Heterozygous loss-of-function mutations in *SOX2*, *PAX6*, and *OTX2* (involving dosage-sensitive transcription factors) are the most common genetic pathology associated with severe eye malformations (anophthalmos/severe microphthalmos) [33–36], and bi-allelic loss-of-function in *STRA6*, *ALDH1A3*, and *RARB* (related to the regulation of retinoic acid metabolism or transport) is confirmed as an emerging cause of nonsyndromic eye malformations [37–40]. In the coloboma/microphthalmia patients, Prokudin reported other variants in *CYP11B1* that are emerging with *CYP11B1* being considered a possible candidate gene as a modifier in coloboma/microphthalmia [41] and commented on the heterogeneity and the complex pattern associated with MAC phenotype. This is nicely summarized by Reis and Semina [32]. Two novel heterozygous *SOX11* variants were identified in patients with coloboma [42]. In general, an identifiable genetic cause is found by molecular genetic testing in 80% of individuals with bilateral anophthalmia/severe microphthalmia and in up to 20% of individuals with an ocular malformation in the MAC spectrum [43]. Microphthalmos is one of the ocular anomalies described in fetal alcohol syndrome, which causes multiple teratogenic effects on ocular embryogenesis [44]. Lenz microphthalmia syndrome (LMS) is a specific entity characterized by unilateral or bilateral microphthalmia and/or clinical anophthalmia with malformations of the ears, teeth, fingers, skeleton, and/or genitourinary system in addition to coloboma, which is present in 60% of microphthalmic eyes. The coloboma ranges from simple iris coloboma to coloboma of the ciliary body, choroid, and ON. The diagnosis of LMS depends on clinical findings; however, molecular testing showed that *NAA10* and *BCOR* (BCL6 corepressor) are known to be associated with LMS.

3.5. Optic nerve aplasia

Optic nerve (ON) aplasia is a rare developmental anomaly that implies complete absence of the ON including the disc and is usually seen in unilateral deformed globe in a healthy person with no hereditary predisposition. There are only three previous reports of bilateral ON aplasia in otherwise normal children [45–47]. The radiological finding of thinned ON indicates the presence of ON sheath with some glial tissue and can aid in the diagnosis. In

the most recent case, flash visually evoked potentials (VEP) was performed to distinguish ON hypoplasia from ON aplasia and VEP was not recordable [47]. The ON is formed of axons of the retinal ganglion cells, which form the ON that is derived embryologically from the inner neuroblastic layer of the optic cup, and failure of development of these cells is rare [48]. When there is accompanying failure of development of mesodermal elements as well, it is termed aplasia of the ON, which is defined as an absence of optic nerve, ganglion cells, and central retinal vessels [28, 49]. Many previously reported cases in literature as ON aplasia are, actually, cases of ON hypoplasia because of some overlapping features [50]. Variable ophthalmic features associated with ON aplasia include microphthalmos, enophthalmos, ptotic lids, squint, microcornea, trabeculodysgenesis, iris hypoplasia, iris coloboma, aniridia, and persistent hyperplastic primary vitreous [28, 49].

3.6. Optic nerve hypoplasia (ONH)

Unilateral ONH is a congenital disorder characterized by an underdevelopment of one of the ONs with marked intracranial asymmetry. Clinically, the ON head looks small with a characteristic “double-ring sign” (**Figure 4**). Visual acuity ranges from 20/20 to amaurosis presenting variable visual field defects but the visual impairment is nonprogressive. The diagnosis of ONH is typically clinical, but the confirmation is more accurately established by MRI [51, 52]. Several associations have also been reported between ONH and central nervous system (CNS) anomalies: such as septo-optic dysplasia (SOD), which is a heterogeneous inconstant combination of different CNS parenchymal malformations: ONH, pituitary hypoplasia (with hormonal deficiency), and midline malformations of the brain (absence of the septum pellucidum or thinning of the corpus callosum) [52]. On the other hand, several anomalies have been reported in fetal alcohol syndrome including optic nerve hypoplasia in 48%, and abnormal tortuosity of retinal arteries in 49% in addition to anterior segment anomalies such as microcornea, cataract, and iris defects in 10% [53]. The ONH is thought to occur because of the teratogenic of alcohol on the developing optic nerve at sixth week of gestation when the first retinal ganglion cells first appear until after birth [44]. It is recommended to perform neuroimaging when ONH is

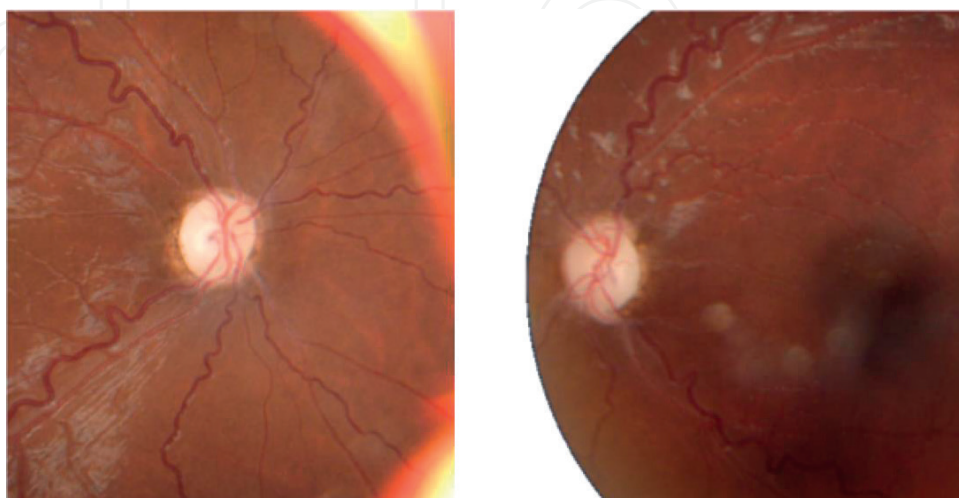


Figure 4. Bilateral optic nerve hypoplasia in a patient with septo-optic dysplasia.

detected to rule out other associated CNS anomalies and internal carotid artery hypoplasia, which has been recently reported advocating the theory of vascular disruption sequence at the time of neuroembryogenesis and restriction of intrauterine blood supply as the cause for ONH [54]. Patients with ONH should also have endocrinological work-up to rule out de Morsier syndrome since hypothalamic/pituitary dysfunction has been found in 69% of unilateral cases and 81% in bilateral [55, 56]. ONH has been reported in association with Down's syndrome in the United States [57]. Optic nerve dysplasia and vascular anomalies have also been found in 4–38% of patients with Down's syndrome in emerging countries [58, 59]. Afifi and co-authors also reported tilted (dysplastic) optic nerve heads in two cases out of their studied series of Down's syndrome children but related their finding to an associated myopia in the same two patients [60]. ONH is the most common congenital ON anomaly and a major cause of blindness in the USA, and even though most cases are isolated, the new molecular diagnostic techniques have recently raised the fact that a significant portion of ONH cases has underlying genetic causes, typically de novo mutations [61]. Also, two missense mutations in *SALL4* were found in a patient with bilateral ONH, unilateral microphthalmos, and coloboma, in addition to cardiac septal defects and delayed growth. *SALL4* is expressed in the developing lens and regulates *BMP4*; therefore, authors speculated that altered *BMP4* expression is the cause for the eye anomalies [62]. Finally, it has been suggested to perform behavioral assessment in ONH children who have mild to moderate or even no visual impairment [63].

3.7. Optic tract hypoplasia

Congenital optic tract hypoplasia is rare and most of the optic tract abnormalities are acquired [64]. They are usually attributed to tumor, hemorrhage, aneurism, and CNS demyelinating disease, while some are associated with anophthalmos. Isolated optic tract aplasia/hypoplasia was reported in three cases, all of which are unilateral [65–67].

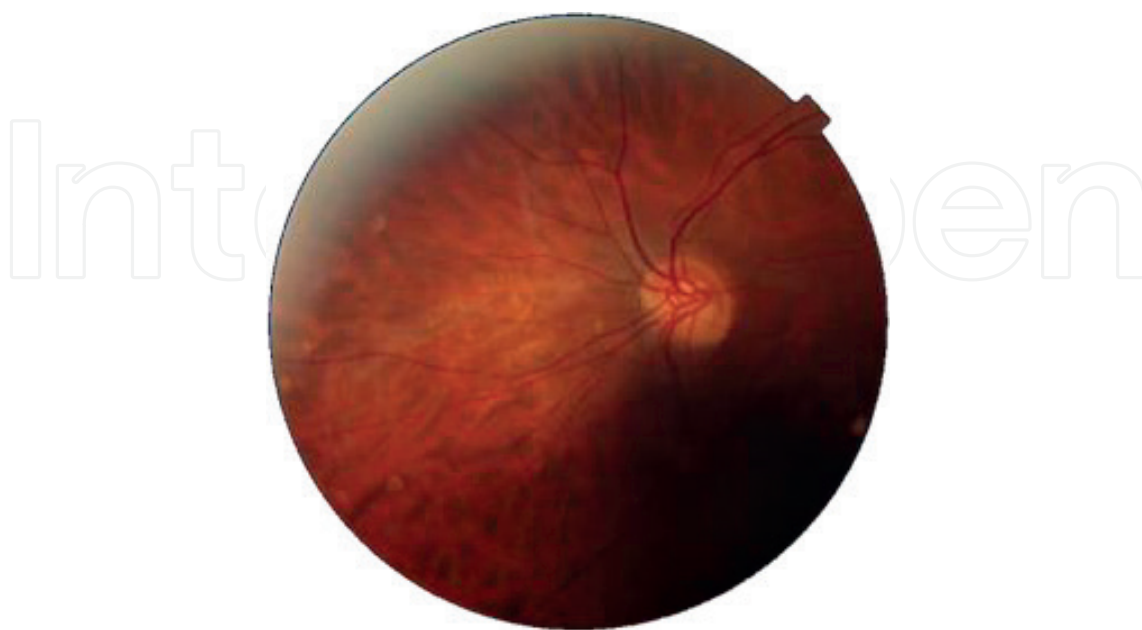

Figure 5. Tilted disc syndrome.

3.8. Optic nerve (ON) tilt

ON tilt has been described in association with myopia and more strongly in association with the presence of crescent regardless of the refractive error (**Figure 5**). Crescent was observed approximately five times more frequently in myopic eyes when compared with nonmyopic eyes (49 vs. 10%), and the median degree of tilt was about double (6.08 vs. 2.48). Ethnicity was also strongly associated with tilt and crescent, with ON heads in Asian eyes having the most tilt [68].

4. Primary tumors of the optic nerve

4.1. Optic pathway glioma (OPG or pilocytic astrocytoma)

Optic pathway gliomas (OPGs) comprise tumors that arise from the visual pathway including the optic nerve (ON) and chiasm. Tumors that only affect the ON are referred to as optic nerve gliomas (ONGs). In general, OPGs are uncommon and account for only about 1% of intracranial tumors [69]. However, they are the most common primary tumors of the optic nerve, comprising about 65% of all intrinsic ON tumors [70].

More than two-thirds of OPGs are detected in the first decade of life and up to 90% before the end of the second decade [69]. The median age of diagnosis of ONGs is 6.5 years with an age range of 2–46 years. Whereas the median age of chiasmal gliomas is 11 years with an age range of 0.75–50 years [71]. There is no sex predilection. Those lesions are considered hamartomas by some authors. ONGs are considered by the 2016 World Health Organization (WHO) as low-grade I juvenile pilocytic astrocytomas or grade II diffuse fibrillary astrocytomas [72].

ONGs are most often benign and slowly growing. The most common presenting findings in descending order are proptosis (94%), vision loss (87.5%), optic disc pallor (59%), disc edema (35%), and strabismus (27%) [69]. However, the presentation of ONGs is variable and mostly depends on the segment of the optic nerve affected by the tumor. The “anterior” involvement presents with signs of an anterior optic neuropathy and is more likely to be associated with optic disc swelling. The “posterior” involvement is associated with either normal or pale optic disc. Patients infrequently present with isolated optic atrophy. A relative afferent pupillary defect (RAPD) is usually present in unilateral or asymmetric cases with affected visual field. The occurrence of nystagmus represents severe visual loss. The nystagmus is monocular, vertical, of low-frequency and variable amplitude. This can differentiate it from spasmus nutans, which is known to be seen in gliomas that involve the optic chiasm [73]. Other rare presentations of ONGs include central retinal vein occlusion (CRVO), retinochoroidal collaterals, or neovascular glaucoma (NVG) [74].

Most cases of ONGs are sporadic. However, there is a clear genetic relationship between ONGs and neurofibromatosis type 1 (NF1). NF1 is an autosomal dominant disorder that occurs in 1 in 3000 individuals. It is caused by a mutation in the gene coding for neurofibromin, a tumor suppressor gene, situated in chromosome 17. About 8–31% of NF1 patients have ONGs. On the other hand, 10–70% of patients with ONGs have NF1 [75]. The wide range of incidence can be explained by referral bias, radiologic detection rate, and the used diagnostic criteria.

The etio-pathogenesis for the development of gliomas in patients with NF1 is related to the activation of the retro-virus-associated sequence (RAS) oncogene (that is inhibited by neurofibromin in normal individuals) and the B1 homolog of the retrovirus-associated function (BRAF) oncogene [73]. The end result is increased protein synthesis and glial cell proliferation. The association between NF1 and the behavior of the glioma is poorly understood. Classically, optic nerve gliomas in patients with NF1 have a more benign prognosis, although this concern is unresolved [69]. Rarely, ONGs can be found in patients with neurofibromatosis type 2 (NF2) [76]. In addition, ipsilateral optic nerve glioma can occur in association with morning glory disc anomaly [77].

Regarding the radiologic findings (**Figure 6**), ONGs may show one of two patterns. The most common pattern is the classic fusiform swelling of the ON. In magnetic resonance imaging (MRI), they are hypo- or isointense in T1-weighted images, hyperintense in T2-weighted images, enhancing after intravenous injection gadolinium. The subarachnoid space (SAS) surrounding the ONGs is distended and thought to be occupied by trapped cerebrospinal fluid (CSF) in some patients. However, ultrasonographic examination in such cases characteristically discloses signs of solid component in the SAS. This indicates that the distension is most likely due to the spread of tumor into the SAS (the “pseudo-CSF sign”) and does not represent trapped CSF [78].

The second and less common radiologic pattern is the appearance of a thickened and kinked nerve in the portion affected by the ONG [75, 76]. Like the first pattern, enlargement of the subarachnoid space is due to extension of the tumor. It was suggested that this pattern (i.e., thickening and kinking) is more commonly observed in patients with NF1 and the fusiform enlargement pattern is more commonly seen in patients with sporadic ONG [79]. Nevertheless, no pattern is indicative of a specific diagnosis as both can be seen in sporadic ONGs and ONGs related to NF1. In both patterns, the margin of the nerve is usually well defined and smooth due to an intact optic nerve sheath. This is a differentiating feature between ONG and optic nerve sheath meningioma (ONSM).

ONGs can either show an isolated involvement of the orbital portion of the optic nerve or combined involvement of both orbital and intracranial portions. The optic foramen may still be distended even if the ONG is restricted to the orbital or intracranial portion of the optic

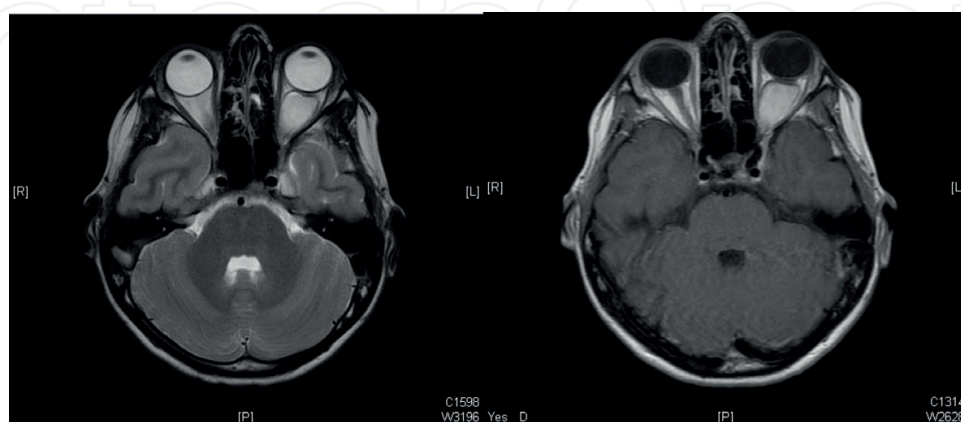


Figure 6. Optic nerve glioma. The left figure is a T2-weighted axial MRI showing left orbital and intraconal mass with high signal intensity. The right figure is a T1-weighted axial MRI showing postcontrast enhancement.

nerve. This is caused by secondary meningeal hyperplasia traveling proximally (or distally) and not the tumor itself. Therefore, enlargement of the optic foramen is not a proof of intracranial extension of an orbital ONG. Furthermore, the optic foramen may still be of normal diameter in the setting of intracranial or chiasmal ONG [80]. Histopathologic examination performed on a resected ONG, which did not reveal spread intracranially by MRI as well as by gross examination, showed an evidence of intracranial spread [81].

Histopathologically (**Figure 7**), ONGs are characterized by three main patterns that may all be present in different cuts of the same tumor: **A.** Transitional area, in which the tumor blends into the normal tissue of optic nerve and shows more abundant and less arranged glial nuclei than in the normal nerve. Increased number and size of glial cells results in enlarged nerve bundles. **B.** Coarsely reticulated and myxomatous areas with microcystoid spaces perhaps representing tumor necrosis. **C.** Astrocytic areas, in which spindle cell formation with Rosenthal fibers, which are cytoplasmic and eosinophilic structures in astrocytes, are seen [80]. Immunohistochemically, the neoplastic astrocytes stain positively for glial fibrillary acidic protein, HNK-1 (type 1 astrocyte precursor marker), S-100, and vimentin. Thus, this suggests that type 1 astrocytes are the origin of the tumor [82]. ONGs nearly always remain confined to the dural sheath, but a spread into the subarachnoid space surrounding the nerve is not uncommon [75].

The diagnosis of an ONG is usually reached on the basis of the clinical signs and radiologic findings. Biopsy of the lesion is largely not required because of the presence of high-resolution neuroimaging with enhanced diagnostic accuracy, biopsy of the sheath alone may show secondary meningeal hyperplasia seen in ONGs and falsely suggesting optic nerve sheath meningioma, and the low predictive value of the histologic appearance of the tumor in its clinical behavior [82]. Most importantly, the procedure could be complicated by permanent visual loss [83].

There is no universally recognized management for ONGs, and it should be individualized to the patient. ONGs are usually very slow growing tumors and some lesions will spontaneously regress. Therefore, observation is indicated for patients with reasonably good vision

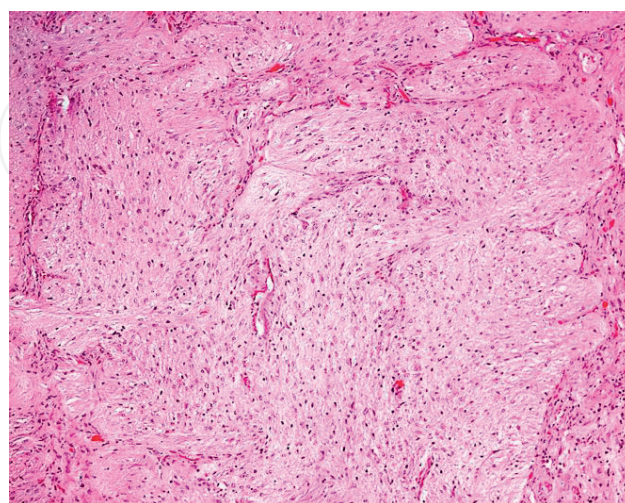


Figure 7. Histopathological appearance of an optic nerve pilocytic astrocytoma (Original magnification $\times 100$ hematoxylin and eosin).

and stable radiologic appearance on serial imaging [84, 85]. For patients presenting with reduced vision and particularly if it is deteriorating or there is a radiologic evidence of tumor growth, a number of treatment options exists.

Chemotherapy is evolving as an initial treatment modality for patients with severe or progressive visual deterioration. It may be especially beneficial in children younger than 5 years of age. The recommended chemotherapeutic agents include vincristine, carboplatin, vinblastine, and temozolomide with remarkable outcomes observed in some patients [86]. Combining carboplatin and vincristine is the most accepted regimen [69]. Additionally, treatment with topical nerve growth factor improved the vision in patients with known or presumed ONGs. A 10-day course of topical murine nerve growth factor in five children with ONGs and severe optic disc pallor showed an increase in visual evoked potential amplitudes that lasted for 90 days in all patients [87].

Fractionated stereotactic radiotherapy is another option for some patients with ONGs and can be used as a monotherapy or adjunctive to other treatment modalities [88, 89]. It is usually kept for patients who are older than 5 years of age and, preferably, after puberty. Shrinkage of ONGs, with subsequent improvement in vision and halting of progressive visual loss, reduction in optic disc swelling, and decreasing proptosis have been reported in two studies [90, 91]. In contrast, a third study concluded that radiation of ONGs has no significant benefit in the overall outcome when compared to observation or surgical intervention [71]. Thus, radiotherapy is still controversial because of questionable results and possible complications including pituitary dysfunction and intellectual disabilities [69].

Surgical excision or debulking of ONGs may be indicated in patients with severe deterioration of visual function associated with cosmetically disfiguring proptosis [92, 93]. In some cases, optic nerve sheath fenestration is performed to release the trapped CSF surrounding the tumor. Surgery has been suggested to prevent progression into the intracranial optic nerve and chiasm. However, involvement of the chiasm is rare and prevention is not proven as the tumor was commonly found in the margins during histopathologic examination of the resected ONGs [82].

4.2. Malignant optic nerve glioma (malignant astrocytoma)

Malignant ONGs are rare neoplasms that involve the anterior visual pathway (i.e., proximal to the lateral geniculate nucleus). According to the WHO 2016, malignant ONGs are classified as grade III (anaplastic astrocytoma) or grade IV (glioblastoma) [72]. In contrast to ONGs mentioned above, malignant ONGs predominantly affects adults. The mean age of onset is 57 years with an age range between 22 and 83 years. There is no gender predilection [94]. Patients present acutely with unilateral or bilateral orbital pain and progressive vision loss. The optic disc appearance can be either normal or pale in most cases although disc swelling and CRVO can also occur [75, 94].

MRI scan shows diffusely enlarged optic nerve, chiasm, or optic tract with heterogeneous enhancement [69]. Histopathologically, malignant ONGs are show areas of anaplasia and are classified as anaplastic astrocytomas or glioblastoma multiforme [78]. Treatment involves radiotherapy, chemotherapy, or both but is rarely successful. The visual and the survival rate

are very poor. Blindness typically occurs 2 to 4 months after onset of vision loss and mortality from hypothalamic and brainstem involvement usually follows after 6–12 months [69].

4.3. ON medulloepithelioma

Medulloepithelioma refers to tumors arising from the cells of the primitive neural tube and the medullary plate. These tumors are extremely rare [95]. They can arise in any part of the central or peripheral nervous system [96, 97]. They may also arise from the globe, principally the ciliary body. Medulloepitheliomas arising from the optic nerve are very rare. Patients present with proptosis, progressive visual loss, disc swelling, and later disc pallor [73].

Imaging initially may show fusiform enlargement of the ON resembling an ONG [75]. At the time of surgery, the diagnosis of an ON medulloepithelioma is usually reached. Histopathologic examination of ON Medulloepithelioma shows hyperchromatic nuclei with high mitotic index. The neoplastic cells are arranged in tubes and cords. Hyaluronidase-sensitive material is observed and stains positively with Alcian blue [75, 98, 99]. More differentiated cells are arranged in rosettes [73]. Teratoid variants of medulloepithelioma have other elements such as striated muscle or cartilage [78, 98].

The most commonly used treatment modality is resection of the involved ON. Even with complete resection, however, recurrences and metastases can be seen. Therefore, other treatment options include adjuvant radiotherapy, chemotherapy, or both [75, 99].

4.4. ON oligodendroglioma

Oligodendroglioma is a type of glioma that is believed to originate from oligodendrocytes. Up to 12% of all intracranial tumors are caused by oligodendrogliomas [100], and there is no gender predilection. They can affect individuals on all ages although they are more prevalent in middle aged adults. The most common location of oligodendrogliomas is in the cerebral hemispheres, particularly the frontal lobes. However, oligodendrogliomas of the cerebellum, the spinal cord, and the brainstem have been reported [101].

Histopathologically, compact masses of swollen oligodendrocytes were separated by an extremely thin stroma. Mitoses are generally rare and variable [100]. They have been reported to be associated with orbital non-Hodgkin lymphoma [102]. Another study described a case of a 14-year-old girl who presented with monocular progressive proptosis, vision loss, and limited extraocular muscle motility. Imaging showed a large fusiform enlargement of the orbital portion of the ON. Microscopic examination of the resected ON proved changes indicative of an oligodendroglioma [103].

4.5. ON ganglioglioma

As the name implies, gangliogliomas are composed of both ganglion cells and astrocytes. They are rare tumors and classified as grade I by the WHO [72]. Gangliogliomas of the ON have been described in few studies [104–106]. In noncontrast enhanced imaging, ON ganglioglioma resembles a benign ONG. However, gangliogliomas characteristically do not show enhancement on MRI after intravenous injection of gadolinium [104]. However, the diagnosis

of ON gangliogliomas is usually reached after microscopic examination that shows many ganglion cells with an increased population of glial cells. Treatment involves partial or total ON nerve resection and radiotherapy [73].

4.6. ON hemangioblastoma

ON hemangioblastomas may be sporadic or occur in the setting of Von Hippel-Lindau disease (VHL). It is an extremely rare tumor, which affects males and females equally with an age of onset ranging from 15 to 44 years. Presentation includes vision loss, headaches or pain with ocular movement, and proptosis accompanied by optic disc swelling or pallor [107]. Radiologically, they look like ONGs except that hemangioblastomas show more homogenous enhancement. Histopathologically, these tumors are comprised of endothelial cells and pericytes with variably sized vascular channels [73].

4.7. ON schwannoma

Schwannomas are benign tumors of peripheral nervous systems derived from Schwann cells. The vestibular location of the schwannoma is more frequent, followed by the involvement of the trigeminal nerve. In the orbit, schwannomas account for 1–6% of intraorbital tumors. Although it is theoretically impossible for a schwannoma to develop from the sheath of the optic nerve, which is devoid of Schwann cells, there are some exceptional cases of schwannoma of the nerve [108–111].

Several histopathogenic explanations have been reported. These include the presence of ectopic Schwann cells that may have migrated at the time of embryogenesis [110, 112]. Another explanation would be a transformation of the pial mesenchymal cells [112, 113]. A final hypothesis is that schwannoma does not develop from the sheath of the optic nerve but from sympathetic nerves running on it [75, 110]. T1-weighted MRI typically demonstrates a homogeneously enhancing lesion. The complete excision of these tumors most often allows a definitive cure without recurrence [114, 115].

5. Primary tumors of the optic nerve sheath (optic nerve sheath meningioma)

The only tumor that can develop solely from the optic nerve sheath is optic nerve sheath meningioma (ONSM) [73]. ONSMs result from proliferations of the meningoepithelial cells covering the sheath of the intraorbital or intracanalicular optic nerve [69]. ONSMs are uncommon, accounting for 1–2% of all orbital tumors [116–118]. However, ONSMs are the second most common cause of primary optic nerve and sheath tumors, second only to optic nerve glioma [69]. Moreover, 90% of all orbital meningiomas were secondary to intracranial extension and the remaining 10% were primary ONSMs [116].

Almost all ONSMs are unilateral although they may be bilateral especially in patients with NF2 [119]. ONSMs are typically discovered in adults during the fourth or fifth decade. Females

are affected three times as often as males. Up to 7% of all ONSMs occur in children [69]. A classification system of ONSMs was suggested and includes three types: type I ONSMs, in which the tumor involves the orbital portion of the ON manifesting as fusiform, tubular, or globular enlargement of the nerve; type II ONSMs, where the tumor extends through the optic canal or supraorbital fissure; and type III ONSMs, with more than 10-mm intracranial extension or involvement of the contralateral ON [120].

The classic diagnostic triad of ONSMs includes painless, slowly progressive, unilateral vision loss associated with optic atrophy, and retinochoroidal collaterals. These collateral vessels connect the retinal venous circulation to the choroidal venous circulation and are seen in approximately 30% of patients [69]. Transient visual obscuration may also occur. In addition, reduced color vision, visual field defect, an ipsilateral RAPD with variable proptosis and limitation of ocular motility are observed [73]. The ON head maybe normal, swollen, or atrophic, depending on duration of symptoms and the location of the tumor [75, 116–118].

Radiological findings of ONSMs are variable (**Figure 8**). Computed tomography (CT) scanning characteristically shows fusiform or tubular expansion of the affected with a thickened and enhanced optic nerve sheath. Calcification of the sheath gives the classic “tram-track” sign. MRI is more accurate in soft tissue definition and proves that the ON parenchyma is of normal diameter. The ON is hypointense in T1-weighted images with the optic nerve sheath showing increased thickness and marked enhancement. In contrast to ONGs that show a smooth dural outline, ONSMs show rough outlines with thin extensions from the affected sheath [116–118].

Histopathologically (**Figures 9 and 10**), ONSMs have a meningotheliomatous or a mixed-type pattern. Psammoma bodies, which are hyalinized calcium deposits, are usually seen. Commonly, meningiomas spread to the extradural space invading the orbital tissue. Rarely, optic nerve, sclera, choroid, and retina are invaded [73, 80]. The diagnosis of ONSM primarily depends on the clinical presentation and imaging without the need for a biopsy in most cases [72].

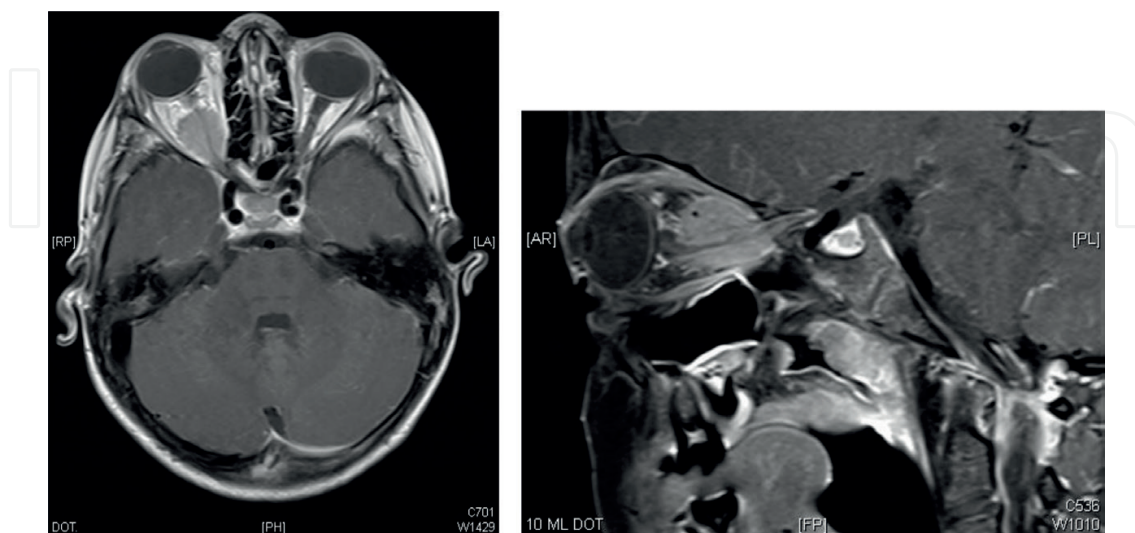


Figure 8. Optic nerve sheath meningioma. T1-weighted MRI showing right oval orbital space occupying lesion encasing the mid and posterior right optic nerve.

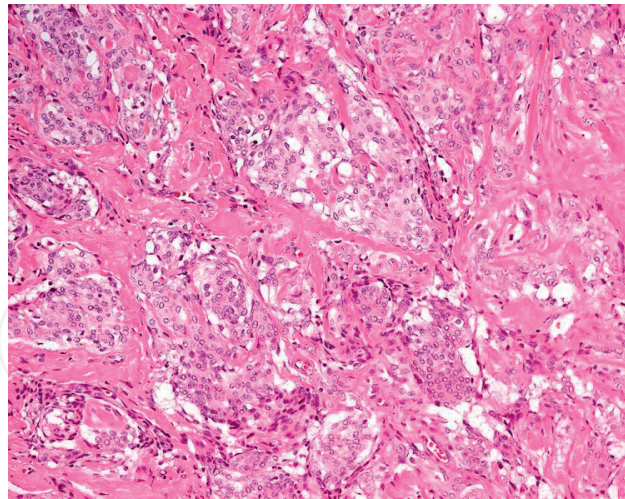


Figure 9. The histopathological appearance of the whorl-configuration of meningotheelial cell proliferation (original magnification $\times 200$ hematoxylin and eosin).

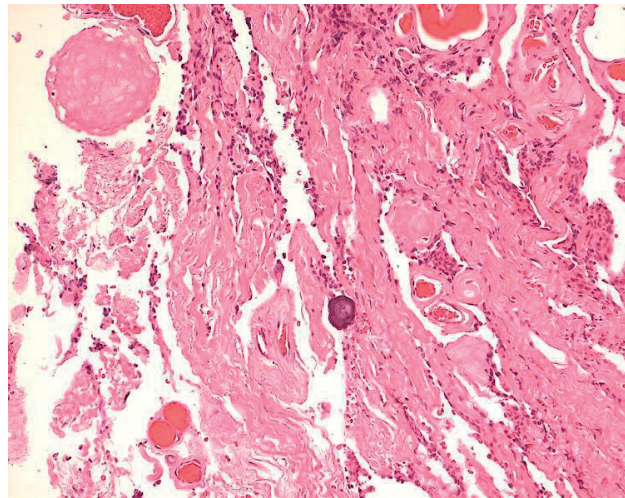


Figure 10. The appearance of the typical psammoma bodies in the same case of the optic nerve meningioma above (original magnification $\times 200$ hematoxylin and eosin).

The only ONSMs related morbidity is visual loss from injury to the ipsilateral ON. These tumors typically do not cause neurological dysfunction or death. Therefore, the management of patients with ONSMs should be tailored to the individual case. Observation is suitable if there is no significant visual loss at presentation or follow-up, and there is no significant intracranial extension. Those patients can be observed twice per year with serial imaging [73]. ONSMs in pediatric population maybe more aggressive, and thus, they must be monitored with increased frequency [69].

Fractionated radiation therapy is the mainstay treatment of ONSM. More than 94% of patients' vision has stabilized or improved. However, late radiation complications include radiation retinopathy and pituitary dysfunction [73]. Surgical excision is rarely advised because of the potential risk of significant visual deterioration. Indications for surgical intervention include intracranial extension of the tumor if there is a risk of contralateral ON involvement [69, 121].

6. Secondary tumors of the optic nerve and sheath

Secondary tumors of the optic nerve are more common than the primary tumors [122]. These tumors can damage the ON by either infiltration, compression, or both. Secondary tumors include retinoblastoma, malignant melanoma of choroid, pseudotumor of the RPE, intracranial meningioma, metastatic carcinoma to the ON parenchyma or ONS, glioblastoma multiforme of the brain, lymphoma, or leukemia [73]. The clinical signs and management of secondary tumors depend on the particular tumor and the location of damage to the ON.

Conflict of interest

We do not have any financial interests in any of the listed items in this manuscript.

Author details

Hind Alkatan*, Daniah Alshowaeir and Tariq Alzahem

*Address all correspondence to: hindkatan@yahoo.com

King Saud University, Riyadh, Kingdom of Saudi Arabia

References

- [1] Miller NR, Walsh FB, Hoyt WF. Walsh and Hoyt's Clinical Neuro-Ophthalmology. Pennsylvania, United States: Lippincott Williams & Wilkins; 2005
- [2] Zhang J, Rubin R, Rao N. Anatomy and Embryology of the Optic Nerve: Duane's Foundations of Clinical Ophthalmology. Philadelphia: Lippincott Williams & Wilkins; 2005. pp. 1-10
- [3] Mikelberg FS, Drance SM, Schulzer M, Yidegiligne HM, Weis MM. The normal human optic nerve: Axon count and axon diameter distribution. *Ophthalmology*. 1989;**96**(9):1325-1328
- [4] Remington LA. Clinical Anatomy of the Visual System. Butterworths-Heinemann. Oxford, United Kingdom: Elsevier Health Sciences; 2011
- [5] Adler FH, Kaufman PL, Levin LA, Alm A. Adler's Physiology of the Eye. Saunders. Philadelphia, United States: Elsevier Health Sciences. 2011
- [6] Adrian ED, Matthews BHC. The Berger rhythm: Potential changes from the occipital lobes in man. *Brain*. 1934;**57**:355-385
- [7] Ciganek L. The EEG response (evoked potential) to light stimulus in man. *Electroencephalography and Clinical Neurophysiology*. 1961;**13**(2):165-172

- [8] Halliday A, McDonald W, Mushin J. Delayed visual evoked response in optic neuritis. *Lancet*. 1972;**299**(7758):982-985
- [9] Hoffmann MB, Seufert PS, Bach M. Simulated nystagmus suppresses pattern-reversal but not pattern-onset visual evoked potentials. *Clinical Neurophysiology*. 2004;**115**(11):2659-2665
- [10] Saunders KJ, Brown G, McCulloch DL. Pattern-onset visual evoked potentials: More useful than reversal for patients with nystagmus. *Documenta Ophthalmologica*. 1997;**94**(3):265-274
- [11] Odom JV, Bach M, Brigell M, Holder GE, McCulloch DL, Tormene AP. ISCEV standard for clinical visual evoked potentials (2009 update). *Documenta Ophthalmologica*. 2010;**120**(1):111-119
- [12] Heckenlively JR, John R, Arden GB, editors. *Principles and Practice of Clinical Electrophysiology of Vision*. Cambridge, Massachusetts, United States: MIT Press; 2006
- [13] Straatsma BR, Foos BY, Heckenlively JR, Taylor GN. Myelinated retinal nerve fibers. *American Journal of Ophthalmology*. 1981;**91**:25-38
- [14] Shelton JB, Digre KB, Gilman J, Warner JE, Katz BJ. Characteristics of myelinated retinal nerve fiber layer in ophthalmic imaging: Findings on autofluorescence, fluorescein angiographic, infrared, optical coherence tomographic, and red-free images. *JAMA Ophthalmology*. 2013;**131**(1):107e109
- [15] Walsh DM, Merson TD, Landman KA, Hughes BD1. Evidence for cooperative selection of axons for myelination by adjacent oligodendrocytes in the optic nerve. *PLoS One*. 2016;**11**(11):e0165673. DOI: 10.1371/journal.pone.0165673. eCollection 2016
- [16] Garcia GA, Tian JJ, Apinyawasisuk S, Kim S, Aki H, Sadun AA. Clues from Crouzon: Insights into the potential role of growth factors in the pathogenesis of myelinated retinal nerve fibers. *Journal of Current Ophthalmology*. 2016;**28**:232e236. <http://www.journals.elsevier.com/journal-of-current-ophthalmology>
- [17] Pendler C. Unusual coloboma of the optic nerve entrance. *The British Journal of Ophthalmology*. 1961;**45**:803-807
- [18] Kindler P. Morning glory syndrome: Unusual congenital optic disc anomaly. *American Journal of Ophthalmology*. 1970;**69**:376-384
- [19] Ribeiro-da-Silva J. Congenital optic disc deformities. A clinical approach. *Ophthalmic Paediatrics and Genetics*. 1985;**5**(1-2):67-70
- [20] Brodsky MC. Congenital optic disk anomalies. *Survey of Ophthalmology*. 1994;**39**:89-112
- [21] Steinkuller PG. The morning glory disk anomaly: Case report and literature review. *Journal of Pediatric Ophthalmology and Strabismus*. 1980;**17**:81-87
- [22] Jackson W, Freed S. Ocular and systemic abnormalities associated with morning glory syndrome. *Ophthalmic Paediatrics and Genetics*. 1985;**5**:111-115

- [23] Jacobs M, Taylor D. The systemic and genetic significance of congenital optic disc anomalies. *Eye*. 1991;**5**:470-475
- [24] Manschot W. Morning glory syndrome: A histopathological study. *The British Journal of Ophthalmology*. 1990;**74**:56-58
- [25] Marija B, Paraskeva H-S, Vujica M, Ivan M. Morning glory syndrome associated with primary open angle glaucoma: Case report. *Srpski Arhiv za Celokupno Lekarstvo*. 2014;**142**(3-4):223-225. DOI: 10.2298/SARH1404223B
- [26] Azuma N, Yamaguchi Y, Handa H, Tadokoro K, Asaka A, Kawasi E, Yamada M. Mutations of the *PAX6* gene detected in patients with a variety of optic-nerve malformations. *American Journal of Human Genetics*. 2003;**72**:1565-1570
- [27] Kim BH, Henderson BA. Intraocular choristoma. *Seminars in Ophthalmology*. 2005;**20**(4):223-229
- [28] Willis F, Zimmerman LE, O'Grady R, Smith RS, Crawford B. Heterotopic adipose tissue and smooth muscle in the optic disc: Association with isolated colobomas. *Archives of Ophthalmology*. 1972;**88**:139-146
- [29] Brodsky M. Congenital optic disc anomalies. In: Hoyt C, Taylor D, editors. *Pediatric Ophthalmology and Strabismus*. London: Elsevier; 2013. pp. 543-560
- [30] Mishra A, Heathcote JG, LaRoche GR. Optic nerve choristoma causing vision loss in an adolescent. *Canadian Journal of Ophthalmology*. 2017;**52**(4):e138-e140. DOI: 10.1016/j.jcjo.2016.12.004
- [31] Berk AT1, Yaman A, Saatçi AO. Ocular and systemic findings associated with optic disc colobomas. *Journal of Pediatric Ophthalmology and Strabismus*. 2003;**40**(5):272-278
- [32] Skalicky SE, White AJ, Grigg JR, Martin F. Microphthalmia, anophthalmia, and coloboma and associated ocular and systemic features: Understanding the spectrum. *JAMA Ophthalmology*. 2013;**131**(12):1517-1524. DOI: 10.1001/jamaophthalmol.2013.5305
- [33] Reis LM, Semina EV. Conserved genetic pathways associated with microphthalmia, anophthalmia, and coloboma. *Birth Defects Research. Part C, Embryo Today*. 2015;**105**(2): 96-113. DOI: 10.1002/bdrc.21097. Epub 2015 Jun 3
- [34] Fantes J, Ragge NK, Lynch SA, McGill NI, Collin JR, Howard-Peebles PN, Hayward C, Vivian AJ, Williamson K, van Heyningen V, FitzPatrick DR. Mutations in *SOX2* cause anophthalmia. *Nature Genetics*. 2003;**33**:461-463
- [35] Ragge NK, Lorenz B, Schneider A, Bushby K, de Sanctis L, de Sanctis U, Salt A, Collin JR, Vivian AJ, Free SL, et al. *SOX2* anophthalmia syndrome. *American Journal of Medical Genetics. Part A*. 2005;**135**:1-7. Discussion 8
- [36] Ragge NK, Brown AG, Poloschek CM, Lorenz B, Henderson RA, Clarke MP, Russell-Eggitt I, Fielder A, Gerrelli D, Martinez-Barbera JP, et al. Heterozygous mutations of *OTX2* cause severe ocular malformations. *American Journal of Human Genetics*. 2005;**76**:1008-1022

- [37] Glaser T, Jepeal L, Edwards JG, Young SR, Favor J, Maas RL. PAX6 gene dosage effect in a family with congenital cataracts, aniridia, anophthalmia and central nervous system defects. *Nature Genetics*. 1994;**7**:463-471
- [38] Pasutto F, Sticht H, Hammersen G, Gillessen-Kaesbach G, Fitzpatrick DR, Nurnberg G, Brasch F, Schirmer-Zimmermann H, Tolmie JL, Chitayat D, et al. Mutations in STRA6 cause a broad spectrum of malformations including anophthalmia, congenital heart defects, diaphragmatic hernia, alveolar capillary dysplasia, lung hypoplasia, and mental retardation. *American Journal of Human Genetics*. 2007;**80**:550-560
- [39] Fares-Taie L, Gerber S, Chassaing N, Clayton-Smith J, Hanein S, Silva E, Serey M, Serre V, Ge'ard X, Baumann C, et al. ALDH1A3 mutations cause recessive anophthalmia and microphthalmia. *American Journal of Human Genetics*. 2013;**92**:265-270
- [40] Srour M, Chitayat D, Caron V, Chassaing N, Bitoun P, Patry L, Cordier MP, Capo-Chichi JM, Francannet C, Calvas P, et al. Recessive and dominant mutations in retinoic acid receptor beta in cases with microphthalmia and diaphragmatic hernia. *American Journal of Human Genetics*. 2013;**93**:765-772
- [41] Gerth-Kahlert C, Williamson K, Ansari M, Rainger JK, Hingst V, Zimmermann T, Tech S, Guthoff RF, van Heyningen V, FitzPatrick DR. Clinical and mutation analysis of 51 probands with anophthalmia and/or severe microphthalmia from a single center. *Molecular Genetics & Genomic Medicine*. 2013;**1**:15-31. DOI: 10.1002/mgg3.2
- [42] Prokudin I, Simons C, Grigg JR, Storen R, Kumar V, Phua ZY, Smith J, Flaherty M, Davila S, Jamieson RV. Exome sequencing in developmental eye disease leads to identification of causal variants in GJA8, CRYGC, PAX6 and CYP1B1. *European Journal of Human Genetics*. 2014;**22**(7):907-915. DOI: 10.1038/ejhg.2013.268. Epub 2013 Nov 27
- [43] Pillai-Kastoori L, Wen W, Wilson SG, Strachan E, Lo-Castro A, Fichera M, Musumeci SA, Lehmann OJ, Morris AC. Sox11 is required to maintain proper levels of Hedgehog signaling during vertebrate ocular morphogenesis. *PLoS Genetics*. 2014;**10**(7):e1004491. DOI: 10.1371/journal.pgen.1004491. eCollection 2014 Jul
- [44] Bardakjian T, Weiss A, Schneider A. Microphthalmia/anophthalmia/coloboma spectrum. In: Pagon RA, Adam MP, Ardinger HH, Wallace SE, Amemiya A, LJH B, Bird TD, Ledbetter N, Mefford HC, RJH S, Stephens K, editors. *Gene Reviews* [Internet]. Seattle, WA: University of Washington; 1993-2017. 2004 Jan 29 [Updated 2015 Jul 9]
- [45] Chan T, Bowell R, O'Keefe M, Lanigan B. Ocular manifestations in fetal alcohol syndrome. *British Journal of Ophthalmology*. 1991;**75**:524-552
- [46] Scott IU, Warman R, Altman N. Bilateral aplasia of the optic nerves, chiasm, and tracts in an otherwise healthy infant. *American Journal of Ophthalmology*. 1997;**124**:409-410. [PubMed: 9439374]
- [47] Sanjari MS, Ghasemi Falavarjani K, Parvaresh MM, Kharazi HH, Kashkooli MB. Bilateral aplasia of the optic nerve, chiasm, and tracts in an otherwise healthy infant. *British Journal of Ophthalmology*. 2006;**90**:513-514. [PMCID: PMC1857006] [PubMed: 16547339]

- [48] Khandgave TP, Kulkarni VN, Muzumdar DV, Puthran N. Bilateral optic nerve aplasia: A rare isolated central nervous system anomaly. *Middle East African Journal of Ophthalmology*. 2014;**21**(3):262-264. DOI: 10.4103/0974-9233.134690
- [49] Nathalie F, Davis EA. Embryology of the eye. In: Yanoff M, Duker JS, editors. *Ophthalmology*. 2nd ed. Vol. 1. New Delhi: Elsevier; 2006. p. 24
- [50] Brodsky MC. Anomalies of the optic disc. In: Miller NR, Newman NJ, editors. *Walsh and Hoyt Clinical Neuro Ophthalmology*. 5th ed. Vol. 1. Baltimore: Williams and Wilkins; 1998. pp. 799-800
- [51] Alqahtani J. Optic nerve aplasia: A case report and literature review. *Journal of Pediatric Neurosciences*. 2008;**2**:150-153
- [52] Lenhart PD, Desai NK, Bruce BB, Hutchinson AK, Lambert SR. The role of magnetic resonance imaging in diagnosing optic nerve hypoplasia. *American Journal of Ophthalmology*. 2014;**158**:1164-1171
- [53] Brodsky MC. *Pediatric Neuroophthalmology*. 3rd ed. New York: Springer; 2016
- [54] Strömland K, Ventura LO, Mirzaei L, Fontes de Oliveira K, Marcelino Bandim J, Parente Ivo A, Brandt C. Fetal alcohol spectrum disorders among children in a Brazilian orphanage. *Birth Defects Research. Part A, Clinical and Molecular Teratology*. 2015;**103**(3):178-185. DOI: 10.1002/bdra.23326. Epub 2014 Nov 5. PMID: 25371388
- [55] Garcia-Medina JJ, del-Rio-Vellosillo M, Fares-Valdivia J, Alemañ-Romero L, Zanon-Moreno V, Pinazo-Duran MD. Optic nerve hypoplasia and internal carotid artery hypoplasia: A new association. *Canadian Journal of Ophthalmology*. Oct 2017;**52**(5):e173-e177. DOI: 10.1016/j.jcjo.2017.05.006
- [56] Patel L, McNally RJ, Harrison E, et al. Geographical distribution of optic nerve hypoplasia and septo-optic dysplasia in Northwest England. *The Journal of Pediatrics*. 2006;**148**:85-88
- [57] Harvey JP. Incidental bilateral optic nerve hypoplasia. *BMJ Case Reports*. 2017;**2017**:pii: bcr-2017-220343. DOI: 10.1136/bcr-2017-220343
- [58] Awan KJ. Uncommon ocular changes in Down's syndrome (Mongolism). *Journal of Pediatric Ophthalmology*. 1977;**14**(4):215-216
- [59] Berk AT, Saatci AO, Erçal MD, Tunç M, Ergin M. Ocular findings in 55 patients with Down's syndrome. *Ophthalmic Genetics*. 1996;**17**(1):15-19
- [60] Ebeigbe JA, Akpalaba R. Ocular health status of subjects with Down's syndrome in Benin City, Nigeria. *African Journal of Medicine and Medical Sciences*. 2006;**35**(3):365-368
- [61] Afifi HH, Abdel Azeem AA, El-Bassyouni HT, Gheith ME, Rizk A, Bateman JB. Distinct ocular expression in infants and children with down syndrome in Cairo, Egypt: Myopia and heart disease. *JAMA Ophthalmology*. 2013;**131**(8):1057-1066. DOI: 10.1001/jamaophthalmol.2013.644

- [62] Chen CA, Yin J, Lewis RA, Schaaf CP. Genetic causes of optic nerve hypoplasia. *Journal of Medical Genetics*. 2017;**54**(7):441-449. DOI: 10.1136/jmedgenet-2017-104626. Epub 2017 May 1
- [63] Ullah E, Wu D, Madireddy L, Lao R, Ling-Fung Tang P, Wan EB, Kopinsky S, Kwok PY, Schneider A, Baranzini S, Ansar M, Slavotinek A. Two missense mutations in SALL4 in a patient with microphthalmia, coloboma, and optic nerve hypoplasia. *Ophthalmic Genetics*. 2016;**23**:1-5
- [64] Webb EA, O'Reilly MA, Clayden JD, Seunarine KK, Dale N, Salt A, Clark CA, Dattani MT. Reduced ventral cingulum integrity and increased behavioral problems in children with isolated optic nerve hypoplasia and mild to moderate or no visual impairment. *PLoS One*. 2013;**8**(3):e59048. DOI: 10.1371/journal.pone.0059048. Epub 2013 Mar 12
- [65] Newman SA, Miller NR. Optic tract syndrome. Neuro-ophthalmologic considerations. *Archives of Ophthalmology*. 1983;**101**:1241-1250
- [66] Gammal TE, Brooks B, Harbour R, Kline L, Jacob P. MR of uncommon congenital and vascular lesions of the intracranial visual pathways. *Neuroradiology*. 1990;**32**:488-491
- [67] Margo CE, Hamed LM, McCarty J. Congenital optic tract syndrome. *Archives of Ophthalmology*. 1991;**109**:1120-1122
- [68] Hatsukawa Y, Fujio T, Nishikawa M, Taylor D. Congenital optic tract hypoplasia. *Journal of AAPOS*. 2015;**19**(4):383-385. DOI: 10.1016/j.jaapos.2015.03.018. Epub 2015 Jul 27
- [69] Marsh-Tootle WL, Harb E, Hou W, Zhang Q, Anderson HA, Weise K, Norton TT, Gwiazda J, Hyman L. For the correction of myopia evaluation trial (COMET) study group. Optic nerve tilt, crescent, ovality, and torsion in a multi-ethnic cohort of young adults with and without myopia. *Investigative Ophthalmology & Visual Science*. 2017;**58**(7):3158-3171. DOI: 10.1167/iovs.16-20860
- [70] American Academy of Ophthalmology. Basic and Clinical Science Course. Section 5: Neuroophthalmology. San Francisco, CA: American Academy of Ophthalmology; 2014. pp. 135-140
- [71] Dutton JJ. Gliomas of the anterior visual pathway. *Survey of Ophthalmology*. 1994;**38**:427-452
- [72] Rush JA, Younge BR, Campbell RJ, et al. Optic glioma: Long-term follow-up of 85 histologically verified cases. *Ophthalmology*. 1982;**89**:1213-1219
- [73] Louis DN, Perry A, Reifenberger G, et al. The 2016 World Health Organization classification of tumors of the central nervous system: A summary. *Acta Neuropathologica*. 2016;**131**:803-820
- [74] Ediriwickrema LS, Miller NR. Tumors of the optic nerve and its sheath. *International Ophthalmology Clinics*. 2018;**58**:237-260
- [75] Miller NR. Optic gliomas: Past, present, and future. *Journal of Neuro-Ophthalmology*. 2016;**36**:460-473

- [76] Miller NR. Primary tumours of the optic nerve and its sheath. *Eye*. 2004;**18**:1026-1037
- [77] Brodsky MC. The Apparently Blind Infant In *Pediatric Neuro-Ophthalmology*. New York, NY: Springer; 2016. pp. 34-43
- [78] Bandopadhyaya P, Dagi L, Robinson N, et al. Morning glory disc anomaly in association with ipsilateral optic nerve glioma. *Archives of Ophthalmology*. 2012;**130**:1082
- [79] Brodsky MC. The “pseudo-CSF” signal of orbital optic glioma on magnetic resonance imaging: A signature of neurofibromatosis. *Survey of Ophthalmology*. 1993;**38**:213-218
- [80] Stern J, Jakobiec FA, Housepian EM. The architecture of optic nerve gliomas with and without neurofibromatosis. *Archives of Ophthalmology*. 1980;**98**:505-511
- [81] Myron Y, Sassani JW. Chapter 13: Optic nerve. In: *Ocular Pathology*. 7th ed. London: W.B. Saunders; 2015. pp. 441e4-465e4. DOI: 10.1016/B978-1-4557-2874-9.00013-2
- [82] Spicer GJ, Kazim M, Glass LR, et al. Accuracy of MRI in defining tumor-free margin in optic nerve glioma surgery. *Ophthalmic Plastic and Reconstructive Surgery*. 2013;**29**:277-280
- [83] Yanoff M, Davis R, Zimmerman LE. Juvenile pilocytic astrocytoma (“glioma”) of optic nerve: Clinicopathologic study of 63 cases. In: Jakobiec FA, editor. *Ocular and Adnexal Tumors*. Birmingham, AL: Aesculapius; 1978. p. 685
- [84] Revere KE, Katowitz WR, Katowitz JA, et al. Childhood optic nerve glioma: Vision loss due to biopsy. *Ophthalmic Plastic and Reconstructive Surgery*. 2017;**33**:S107-S109
- [85] Tow SL, Chandela S, Miller NR, et al. Long-term prognosis in children with gliomas of the anterior visual pathway. *Pediatric Neurology*. 2003;**28**:262-270
- [86] Parsa CF, Hoyt WF, Lesser RL, et al. Spontaneous regression of optic gliomas. Thirteen cases documented by serial neuroimaging. *Archives of Ophthalmology*. 2001;**119**:516-529
- [87] Parentin F, Rabusin M, Zannaro F, et al. Chemotherapy for optic nerve glioma in a child with neurofibromatosis type-1. *Neuro-Ophthalmology*. 2008;**32**:159-162
- [88] Falsini B, Chiaretti A, Barone G, et al. Total nerve growth factor as a visual rescue strategy in pediatric optic gliomas: A pilot study including electrophysiology. *Neurorehabilitation and Neural Repair*. 2011;**25**:512-520
- [89] McDonnell P, Miller NR. Chiasmatic and hypothalamic extension of optic nerve glioma. *Archives of Ophthalmology*. 1983;**101**:1412-1415
- [90] Marwaha G, Macklis R, Singh AD. Radiation therapy: Orbital tumors. *Developments in Ophthalmology*. 2013;**52**:94-101
- [91] Taveras JM, Mount LA, Wood EH. The value of radiation therapy in the management of glioma of the optic nerves and chiasm. *Radiology*. 1956;**66**:518-528
- [92] Throuvalas N, Bataini P, Ennuyer A. Les gliomes du chiasma et du nerf optique: L’apport de la radiothérapie transcutanée dans leur traitement [Gliomas of the chiasm and optic

- nerve: The role of external radiation therapy in their treatment]. *Bulletin du Cancer Association Française Pour L'étude du Cancer*. 1969;**56**:231-264
- [93] Wolter JR. Large optic nerve glioma removed by the transconjunctival approach. *Journal of Pediatric Ophthalmology*. 1973;**10**:142-146
- [94] Althekair FY. Debulking optic nerve gliomas for disfiguring proptosis: A globe-sparing approach by lateral orbitotomy alone. In: Presented as a Poster at the 42nd Annual Meeting of the North American Neuro-Ophthalmology Society; Tucson, AZ; February 28, 2016
- [95] Spoor TC, Kennerdell JS, Martinez Z, et al. Malignant gliomas of the optic nerve pathways. *American Journal of Ophthalmology*. 1980;**89**:284-292
- [96] Bailey P, Cushing H. A Classification of the Tumour of the Glioma 5: Group on a Histogenetic Basis with a Correlated Study of Prognosis. Philadelphia: Lippincott; 1926. pp. 26-48, 54-56
- [97] Karch SB, Urich H. Medulloepithelioma: Definition of an entity. *Journal of Neuropathology & Experimental Neurology*. 1972;**31**:27-53
- [98] Nakamura Y, Becker LE, Mancor K, Gillespie R. Peripheral medulloepithelioma. *Acta Neuropathology (Berlin)*. 1982;**57**:137-142
- [99] Chidambaram B, Santosh V, Balasubramanian V. Medulloepithelioma of the optic nerve with intradural extension: Report of two cases and a review of the literature. *Child's Nervous System*. 2000;**16**:329-333
- [100] Chavez M, Mafee MF, Castillo B, et al. Medulloepithelioma of the optic nerve. *Journal of Pediatric Ophthalmology and Strabismus*. 2004;**41**:48-52
- [101] McLendon RE, Kros JM, Bruner J, et al. Oligodendrogliomas. In: McLendon RE, Rosenblum MK, Bigner DD, editors. *Russell and Rubinstein's Pathology of Tumors of the Nervous System*. 7th ed. London: Hodder Arnold; 2006. pp. 167-186
- [102] Hedges TR III. Tumors of neuroectodermal origin. In: Miller NR, Newman NJ, Bioussé V, Kerrison JB, editors. *Walsh and Hoyt's Clinical Neuro-Ophthalmology*. 6th ed. Philadelphia, PA: Lippincott Williams & Wilkins; 2005. pp. 1439-1442
- [103] Lucarini C, Tomei G, Gaini SM, et al. A case of optic nerve oligodendroglioma associated with an orbital non-Hodgkin's lymphoma in adult. Case report. *Journal of Neurosurgery Science*. 1990;**34**:319-321
- [104] Offret H, Gregoire-Cassoux N, Frau E, et al. Solitary oligodendroglioma of the optic nerve. Apropos of a case. *Journal Français d'Ophtalmologie*. 1995;**18**:158-163
- [105] Rolston JD, Han SJ, Cotter JA, et al. Gangliogliomas of the optic pathway. *Journal of Clinical Neuroscience*. 2014;**21**:2244-2249
- [106] Gritzman MCD, Snyckers FD, Proctor NS. Ganglioglioma of the optic nerve. A case report. *South African Medical Journal*. 1983;**63**:863-865

- [107] Bergin DJ, Johnson TE, Spencer WH, et al. Ganglioglioma of the optic nerve. *American Journal of Ophthalmology*. 1988;**105**:146-149
- [108] Kerr DJ, Scheithauer BW, Miller GM, et al. Hemangioblastoma of the optic nerve: Case report. *Neurosurgery*. 1995;**36**:573-581
- [109] Simpson RK Jr, Harper RL, Kirkpatrick JB, Cooper B. Schwannoma of the optic sheath. *Journal of Neuro-Ophthalmology*. 1987;**7**:219-222
- [110] Kim DS, Choi JU, Yang KH, Jung JM. Optic sheath schwannomas: Report of two cases. *Child's Nervous System*. 2002;**18**:684-689
- [111] Kinoshita Y, Kurosaki M, Kamitani H, Watanabe T. Schwannoma originating in the optic canal. *Acta Neurochirurgica*. 2008;**150**:89-90
- [112] Birkholz ES, Lee AG, Nerad JA, Lane KA, Bilyk JR. A pregnant pause. *Survey of Ophthalmology*. 2010;**55**:162-168
- [113] Russel DS, Rubenstein EJ. *Pathology of Tumours of the Nervous System*. 4th ed. London: Edward Arnold; 1977. pp. 372-379
- [114] Haga Y, Shoji H, Oguro K, Mori S, Kawai T, Shinoda S, et al. Intra-cerebral schwannoma—Case report. *Neurologia Medico-Chirurgica (Tokyo)*. 1997;**37**:551-555
- [115] Rootman J, Goldberg C, Robertson W. Primary orbital schwannomas. *The British Journal of Ophthalmology*. 1982;**66**:194-204
- [116] Civit T, Freppel S. Intraorbital Schwannomas and solitary neurofibromas. *Neuro-Chirurgie*. 2010;**56**:137-141
- [117] Dutton JJ. Optic nerve sheath meningiomas. *Survey of Ophthalmology*. 1992;**37**:167-183
- [118] Miller NR. New concepts in the diagnosis and management of optic nerve sheath meningioma. *Journal of Neuro-Ophthalmology*. 2006;**26**:200-208
- [119] Shapey J, Sabin HI, Danesh-Meyer HV, et al. Diagnosis and management of optic nerve sheath meningiomas. *Journal of Clinical Neuroscience*. 2013;**20**:1045-1056
- [120] Bosch MM, Wichmann WW, Boltshauser E, et al. Optic nerve sheath meningiomas in patients with neurofibromatosis type 2. *Archives of Ophthalmology*. 2006;**124**:379-385
- [121] Schick U, Dott U, Hassler W. Surgical management of meningiomas involving the optic nerve sheath. *Journal of Neurosurgery*. 2004;**101**:951-959
- [122] Christmas NJ, Mead MD, Richardson EP, Albert DM. Secondary optic nerve tumors. *Survey of Ophthalmology*. 1991;**36**(3):196-206

