

We are IntechOpen, the world's leading publisher of Open Access books Built by scientists, for scientists

6,900

Open access books available

186,000

International authors and editors

200M

Downloads

Our authors are among the

154

Countries delivered to

TOP 1%

most cited scientists

12.2%

Contributors from top 500 universities



WEB OF SCIENCE™

Selection of our books indexed in the Book Citation Index
in Web of Science™ Core Collection (BKCI)

Interested in publishing with us?
Contact book.department@intechopen.com

Numbers displayed above are based on latest data collected.
For more information visit www.intechopen.com



Diastasis Recti and Other Midline Defects: Totally Subcutaneous Endoscopic Approach

Pablo José Medina, Guido Luis Busnelli and
Walter Sebastián Nardi

Additional information is available at the end of the chapter

<http://dx.doi.org/10.5772/intechopen.75653>

Abstract

Diastasis of the rectus is defined as the separation of the midline or alba line, which originates in a laxity of the interlocking fibers from the aponeurosis of both rectus muscles. At present, its surgical correction continues to be discussed. However, there is a multiplicity of factors that justify it.

Keywords: diastasis recti, endoscopic rectus plication, mini-invasive, midline defects

1. Introduction

Diastasis recti is an anatomic term used to describe a condition in which both rectus muscles are separated by a distance greater than expected. Usually caused by the reduction of the consistency of the intercrossed fibers that make the linea alba, generating a separation of both aponeurosis of the rectus abdominis muscles. It can be congenital or acquired, favored by situations like pregnancy, obesity or previous surgeries.

Clinically represents an aesthetic and symptomatic problem. It produces malfunction of the abdominal wall muscles with an associated muscular imbalance and chronic back pain [1, 2].

Nowadays, there is no consensus on the surgical technique or indications for the treatment of diastasis recti, specially in patients without lipodystrophy. If is symptomatic, causes esthetic problems (specially in young women after pregnancy [3]) or associated with midline hernias (**Figure 1a–c**), the surgical treatment of both pathologies at the same time could be recommended. The most common technique used is by the way of an abdominoplasty

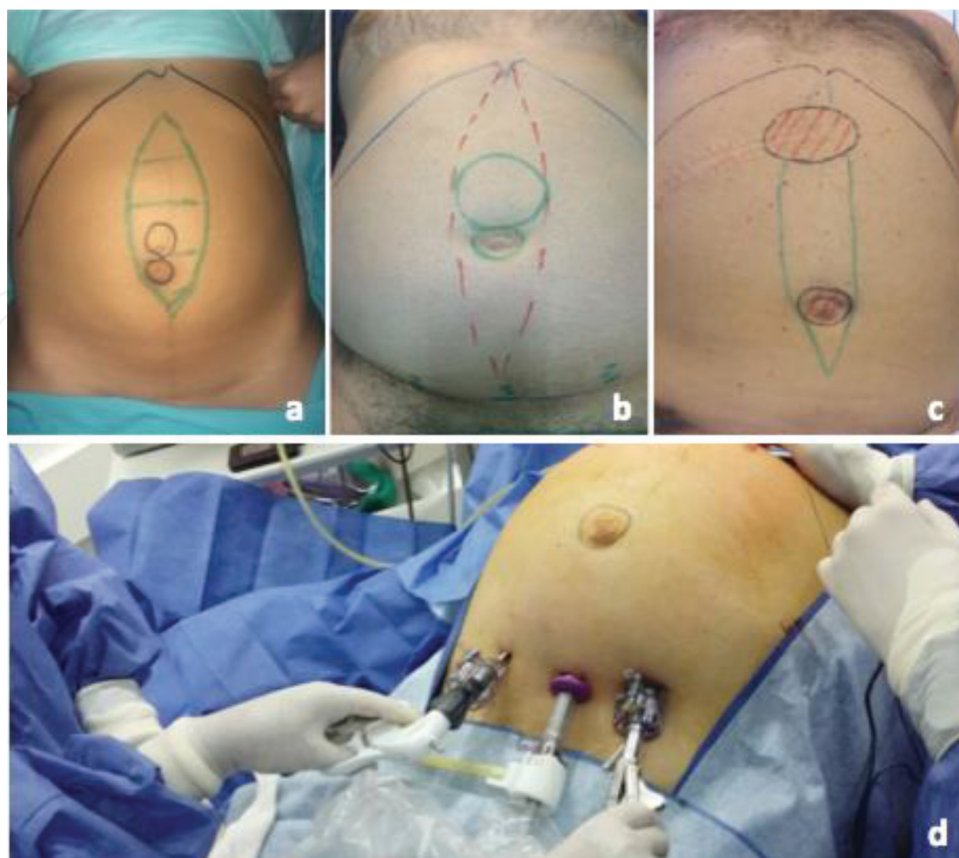


Figure 1. (a–c) External marking of the diastase recti and its associated midline defects. (d) Position of the trocars and surgeon.

in patients with excess abdominal skin and subcutaneous cellular tissue [4]. However, a mini-invasive approach presents as an alternative procedure to the most commonly used technique for its treatment.

2. Surgical technique/technical aspects

Different options have been proposed such as conventional surgery, with abdominoplasty, laparoscopic or endoscopic approach.

For the endoscopic approach, under general anesthesia, the patient is positioned in supine position with both legs open and the surgeon is located between them. The monitor is located at the head of the patient and the assistant on his left. A 10 mm incision is made in the supra-pubic midline and a space is created between the subcutaneous cellular tissue and the superficial aponeurosis with blunt dissection. A 10 mm trocar is introduced for the optic and, favored by a 10 mm Hg pneumatic pressure, two 5-mm trocars are placed under direct vision on each side of the midline by around 5 cm (**Figure 1d**).

10 mm Hg CO₂ is used to maintain a correct work space. Under endoscopic vision, the supra-aponeurotic space is dissected exposing the linea alba and superficial aponeurosis until

reaching the umbilical region. The umbilicus is disinserted above the hernia sac if present, reintroducing it into the intra-abdominal compartment. If other supraumbilical abdominal wall defects are present, the dissection is done as previously described. Finally, the dissection of the supra-aponeurotic space continues until reaching the subxiphoid region. Once dissection is completed, the diastasis recti and associated aponeurotic defects can be identified (**Figure 2a and b**).

The plication of the aponeurosis of the recti muscles is done with two continuous absorbable barbed sutures from the subxiphoid to suprapubic region (**Figure 2c and d**).

In patients with associated large abdominal wall defects, the plication of both muscles can be difficult and the release of one or both rectus abdominis muscle aponeurosis could be convenient for a tension-free plication. The *component separation technique* allows a better compliance and 4–5 cm (each side) for the approximation of the muscles to the midline.

If the defect/s measures more than 4 cm, a prosthetic material is preferred to complete the abdominal wall repair. Usually, a polypropylene mesh is introduced in the supra-aponeurotic space (onlay) and fixed with knots of an absorbable suture or tracks (**Figure 3a–c**).

Finally, the umbilicus is reinserted to its normal position to the plicated fascia with an intra-corporeal knotting (**Figure 3d**). Drainage is placed through one of the 5 mm wounds used in the surgery and a compressive bandage is used to decrease the dead space between the aponeurosis and the subcutaneous cellular tissue.

For the laparoscopic approach, the patient is placed supine with both arms outstretched. The monitor is located on the right flank. Pneumoperitoneum to 12 mm Hg is achieved via open

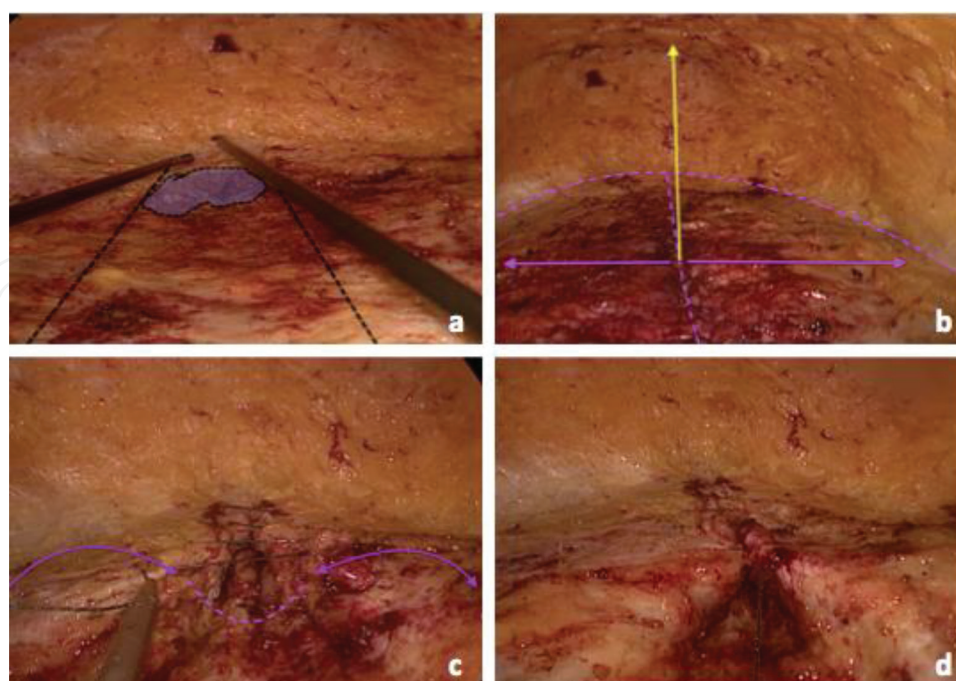


Figure 2. (a) Visualization of the diastasis recti and associated midline defect. (b) Final dissection of the supra-aponeurotic space until the subxiphoid region. (c and d) Plication of the aponeurosis of diastase recti with absorbable barbed suture.

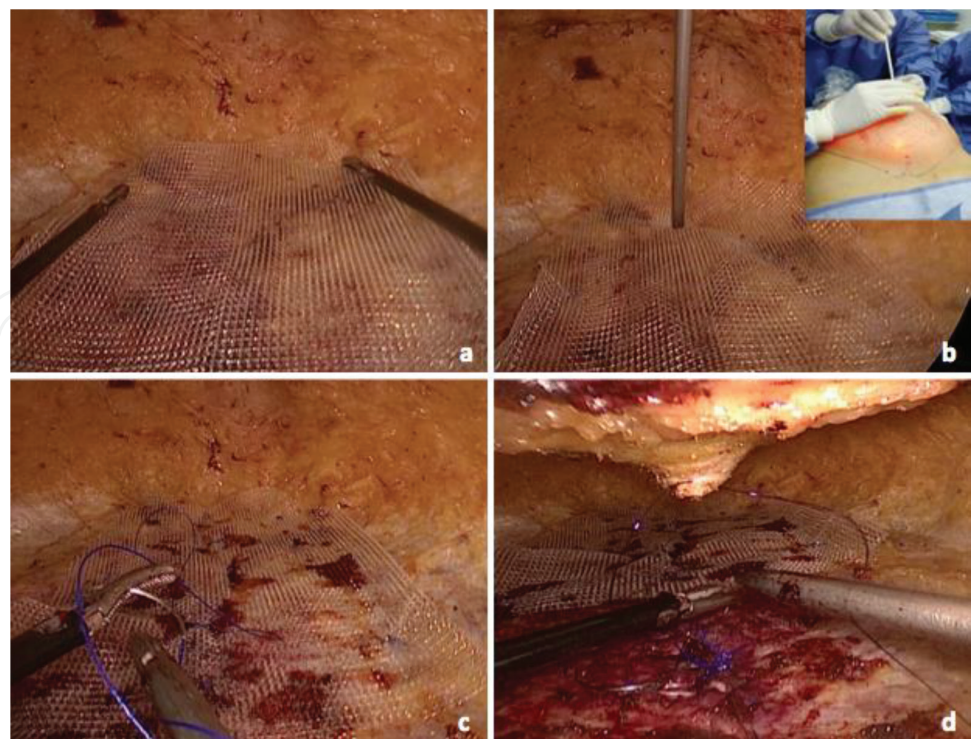


Figure 3. (a) Supra-aponeurotic polypropylene mesh is necessary to complete the abdominal wall repair. (b and c) Fixation with tracks and absorbable suture. (d) Reinsertion of the umbilicus with an intracorporeal knotting.

access of 12 mm in left flank and two additional trocars are placed in left upper quadrant (12 mm) and the left iliac fossa (5 mm).

Is better to start with laparoscopic time because sometimes is necessary to make extensive enterolysis and this is usually the most laborious process (**Figure 4**). All previous wall adhesions must be released.

Diastasis of rectus abdominis is observed and measured in all its extension (**Figure 5**).

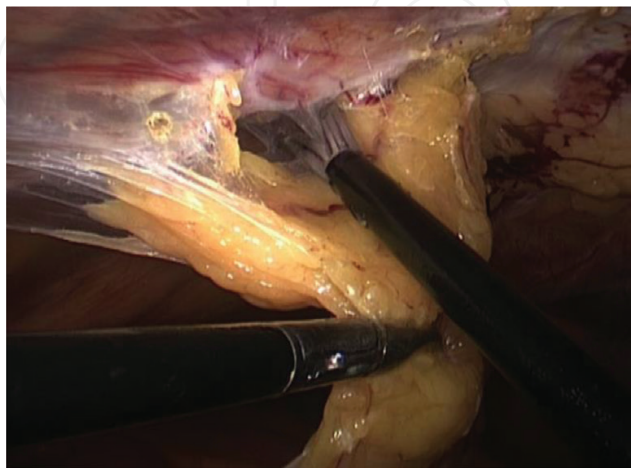

Figure 4. Release of anterior wall adhesions.

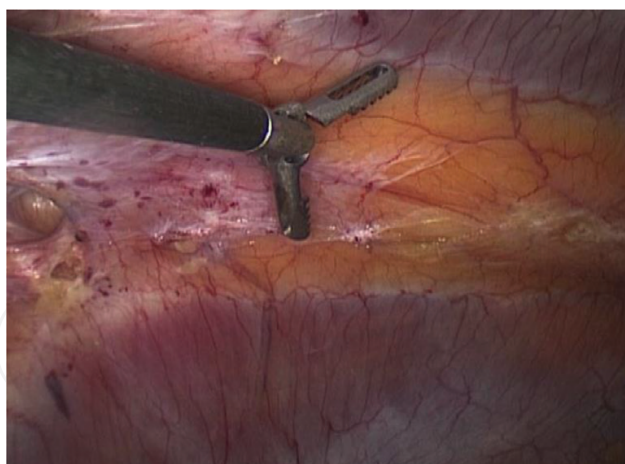

Figure 5. Measurement of diastasis recti using the diameter of the grasper.

Later on, some cases can use the *videoscopic component separation technique* to release rectus abdominis muscle and allow a tension-free plication. Exsufflation is performed and the same port sites are used. The external oblique muscle aponeurosis is identified in the upper 12 mm incision and is sectioned to access the avascular space between the external oblique and internal oblique muscles. This plane is developed with a blunt instrument. The space is then insufflated under vision and the semilunar line is visualized. The insufflation pressure is maintained at 12 mm Hg and the other two abdominal trocars are removed up to the space between both oblique muscles. This space is developed with blunt grasper maneuvers all the way between the costal margin and the inguinal ligament inferiorly. Finally, the release of the rectus is obtained by making an incision in the external oblique fascia lateral to the semilunar line. Hence, a release of the abdominis rectus sheath of about 6–8 cm is reached (**Figure 6a and b**). It is important to remember that nerve supply to the rectus muscle is medial to the semilunar line, hence the procedure prevents any injury to the nerves. If the diastasis is very large, greater than about 6 or 7 cm, the same procedure can be reproduced on the other side. Hemostasis is ensured and no drains are left in the dissected space. The abdominal cavity is then entered again.

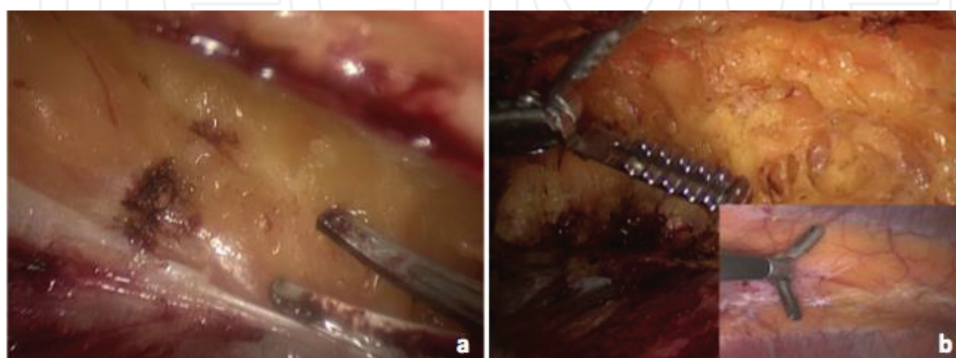


Figure 6. (a) Section of the external oblique aponeurosis. (b) Comparison between the distance between the external oblique fascia sectioned and the diameter of the diastasis.

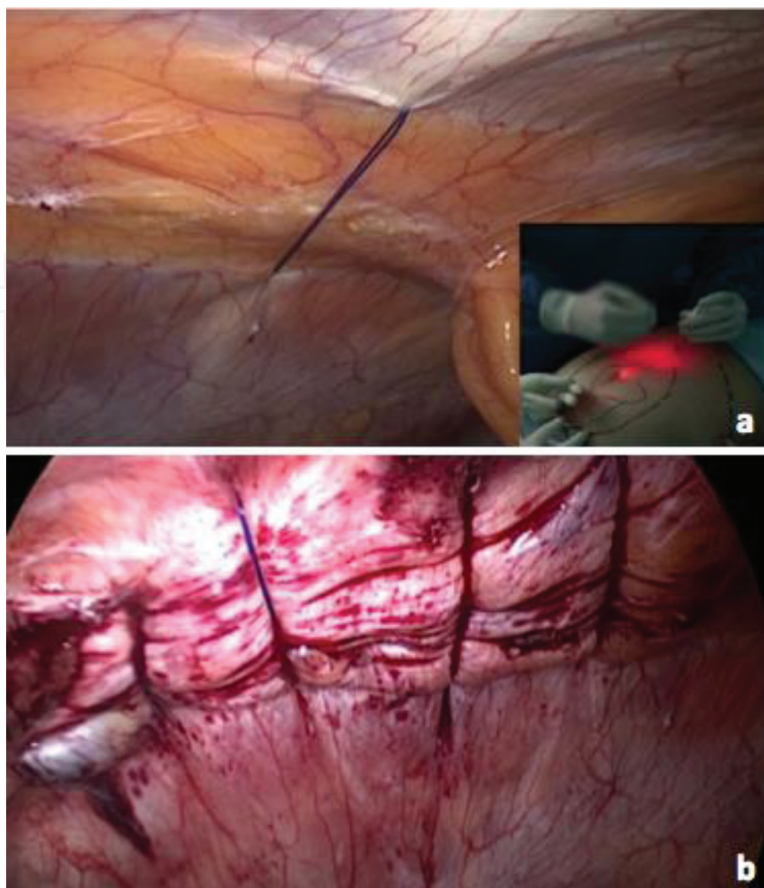


Figure 7. (a) and (b) Transmural stitches of polypropylene are placed along the entire diastasis including both rectus abdominis muscles with a laparoscopic suture passer device.

Transmural stitches of polypropylene suture are placed along the entire diastasis including both rectus abdominis muscles with a laparoscopic suture passer device such as “Endo Close™” (**Figure 7a** and **b**). Each stitch is introduced through a punctate stab incision in the skin and the knots are hidden in the subcutaneous tissue. After that, a composite mesh is prepared with permanent sutures that are placed at the midpoint of each side of the mesh before it is introduced into the abdominal cavity through a 12-mm trocar. Once the mesh is placed inside the abdominal cavity, it is secured to the abdominal wall with the preplaced sutures. Metal or absorbable tacks are then used circumferentially at approximately 1-cm intervals to prevent intestinal herniation.

3. Discussion

For the study of diastasis recti, CT scan or ultrasonography can be used. Both methods are reliable for the measurement of the separation of the rectus muscles. CT scan has the advantage of using bony ridges for that measurement and also can show other associated hernias [5]. Some authors propose that ultrasonography is an accurate method to measure rectus diastasis above the umbilicus and at the umbilical level. However, below umbilicus ultrasound can show smaller values [6].

Several ways to define and assess rectus muscle diastasis can be found in the literature. In addition, there is no consensus on the values considered relevant. Some authors consider any separation of the rectus abdominis as a diastasis and others consider a distance greater than 1 cm, 2 fingers or 3 cm.

The standard treatment of this condition is abdominoplasty with periumbilical incision, which often results in an umbilical circumcision or even an inverted T scar [7]. Limited incision abdominoplasty, sometimes called extended miniabdominoplasty, has been described in the literature but has received little attention. In conclusion, the majority of these techniques are for an open approach, while laparoscopy or endoscopy was not frequently reported at first. Nowadays plication of the diastasis without skin resection using only laparoscopic or endoscopic approach has been reported.

It is frequent to observe the coexistence of diastasis recti with one or more hernia or symptomatic incisional midline hernia. If only the hernia were treated, it would be done over an anatomic weak and deficient tissue, which is the damaged linea alba. This situation could lead to a higher possibility of hernia recurrence and also the aesthetic results would be uncertain. Thus, in these cases, simultaneous correction of all existent pathologies is highly recommended [8].

One option described for the plication of diastasis recti with skin resection is the laparoscopic approach [9]. Transmural stitches or even intracorporeal continuous suture can be done to reduce the diastasis. Finally an intra-peritoneal mesh is used to complete the procedure.

Bellido Luque et al. described the subcutaneous endoscopic approach as a new alternative to treat diastasis recti [4]. As explained before, with three supra-pubic trocars and using a pressure of CO₂ maintained between 8 and 10 mm Hg, a totally endoscopic treatment is used for the plication of diastasis recti and also to treat associated abdominal wall defects. The utilization of barbed sutures for the plication allows more rapid surgical maneuvers and therefore diminishing surgical times. Even though this suture is absorbable (180 days), a second continuous non-absorbable monofilament suture is added to ensure more stability [10].

Moreover, in some cases diastasis recti plication, even though is effective, can lead to and excessive tension and therefore increased postoperative pain. In these cases, in our opinion, is necessary to reduce the rectus abdominis suture tension by dividing the external oblique muscle fascia close to the semilunar line and hence medializing the rectus abdominis muscle (*component separation*).

In 1990, Ramirez et al. described the “component separation” technique for the reconstruction of ventral hernias without the use of prosthetic material. Using this technique, up to 10 cm of unilateral recti advancement can be achieved.

On the other hand, it is well known that when an extensive dissection is needed to reach a “component separation”, several complications are described (such as hematomas, wound infections, seromas, skin flaps necrosis, etc.). However, many studies report that an optimal compliance of the abdominal wall can be obtained by minimally invasive component separation. It provides up to 86% myofascial advancement compared with an open release [11]. Giurgius et al. compared the conventional component separation technique versus the mini invasive approach for ventral hernias. They concluded that the last one has advantages over the open technique due to a reduction in wound complications. The reduced incidence of

seromas seen in the mini invasive approach is likely attributable to the ability to perform the procedure without the creation of undermining skin flaps.

The videoscopic component separation preserves the rectus abdominis myocutaneous perforators supplying the overlying skin and the connection between the subcutaneous fat and anterior rectus sheath, thereby reducing subcutaneous dead space and potentially improving overlying skin flap vascularity. In our opinion, this technique is not only useful for ventral hernia repairs, but also for abdominis diastasis recti surgery. The use of a reinforcing mesh aims to reduce the rate of recurrence.

4. Our experience and conclusion

A total of 42 patients underwent endoscopic surgery between March/2014 and Feb/2017 at British Hospital of Buenos Aires. Most of the patients (76%) were women with a mean age of 39 years and all of them (32) had a history of pregnancy. In 93% (39) of the cases, the diastasis was supra and infraumbilical and its average size was 5.5 cm (range 4–7 cm). About 100% of the patients had at least one associated abdominal wall defect, with the following distributions: 23 umbilical hernias, 18 epigastric hernias, 9 umbilical incisional hernias, and 1 subcostal incisional hernia. We had no intraoperative complications. The mean surgical time was 80 min (55–105 min). Polypropylene meshes were used in 38 patients (91%). Pain intensity at 12 h and at 7 postoperative days was evaluated by analogous visual scale (VAS) and was 4.1 points on average (range 1–6 pts.). The average degree of satisfaction with the cosmetic result was 9.5 with a range of 8–10. All the patients reported being very satisfied with the aesthetic and functional result and the procedure met their preoperative expectations.

Between the 8–10^o postoperative months, the abdominal wall was assessed by ultrasound in 39 patients (93%). After a follow-up of 7–35 months (mean, 10 months), we had no recurrences.

In conclusion, in patients without excess skin or subcutaneous cellular tissue, endoscopic approach to diastasis recti associated with midline hernias is a feasible and reproducible method. It has esthetic advantages, allowing simultaneous correction of all existent pathologies, with minimal complications. Diastasis recti measuring more than 6 cm may benefit with an additional videoscopic component separation technique and/or by using prosthetic mesh.

Laparoscopic approach is also another option for its repair. In this mini-invasive technique, using videoscopic component separation to decrease the tension of the suture between both rectus abdominis is the key to a proper reconstruction.

Author details

Pablo José Medina, Guido Luis Busnelli and Walter Sebastián Nardi*

*Address all correspondence to: nardi.ws@gmail.com

British Hospital of Buenos Aires, Buenos Aires, Argentina

References

- [1] Carreirao S, Correa WE, Dias LC, Pitanguy I. Treatment of abdominal wall eventrations associated with abdominoplasty techniques. *Aesthetic Plastic Surgery*. 1984;**8**(3):173-179
- [2] Ramirez OM. Abdominoplasty and abdominal wall rehabilitation: Comprehensive approach. *Plastic and Reconstructive Surgery*. 2000;**105**(1):425-435
- [3] Beer GM, Schuster A, Seifert B, Manestar M, Mihic-Probst DA, Weber SA. The normal width of the linea alba in nulliparous women. *Clinical Anatomy*. 2009;**22**:706-711
- [4] Bellido Luque J, Bellido Luque A, Valdivia J, Suarez Gráu JM, Gomez Menchero J, et al. Totally endoscopic surgery on diastasis recti associated with midline hernias. The advantages of a minimally invasive approach. Prospective cohort study. *Hernia*. 2015;**19**(3):493-501
- [5] Nahas FX, Ferreira LM, Augusto SM, Ghelfond. Long-term follow-up of correction of rectus diastasis. *Plastic and Reconstructive Surgery*. 2015;**115**(6):1736-1741
- [6] Mendes Dde A, Nahas FX, Veiga DF. Ultrasonography for measuring rectus abdominis muscles diastasis. *Acta Cirúrgica Brasileira*. 2007;**22**:182-186
- [7] Yousif NJ, Lifchez SD, Nguyen HH. Transverse rectus sheath plication in abdominoplasty. *Plastic and Reconstructive Surgery*. 2004;**114**:778
- [8] Al-Qattan M. Abdominoplasty in multiparous women with severe musculoaponeurotic laxity. *British Journal of Plastic Surgery*. 1997;**50**:450-455
- [9] Champault G. Video-laparoscopic surgery of the abdominal wall. A study of 15 cases. *Chirurgie*. 2004;**123**(5):474-477
- [10] Rosen A. Repair of the midline fascial defect in abdominoplasty with long-acting barbed and smooth absorbable sutures. *Aesthetic Surgery Journal*. 2011;**31**(6):668-673
- [11] Rosen MJ, Williams C, Jin J, McGee MF, Schomisch S, Marks J, Ponsky J. Laparoscopic versus open-component separation: A comparative analysis in porcine model. *American Journal of Surgery*. 2007;**194**(3):385-389

