

We are IntechOpen, the world's leading publisher of Open Access books Built by scientists, for scientists

6,900

Open access books available

186,000

International authors and editors

200M

Downloads

Our authors are among the

154

Countries delivered to

TOP 1%

most cited scientists

12.2%

Contributors from top 500 universities



WEB OF SCIENCE™

Selection of our books indexed in the Book Citation Index
in Web of Science™ Core Collection (BKCI)

Interested in publishing with us?
Contact book.department@intechopen.com

Numbers displayed above are based on latest data collected.
For more information visit www.intechopen.com



Harmonic Contrast-Enhanced Ultrasound (CEUS) of Kidney Tumors

Lidia Ciobanu, Attila Tamas Szora,
Alexandru Florin Badea, Mihai Suciu and
Radu Badea

Additional information is available at the end of the chapter

Abstract

Nowadays, kidney tumor diagnosis benefits from large and highly accurate imagistic methods. A new imagistic method is contrast-enhanced ultrasound (CEUS) that accurately depicts the circulatory pattern of tumors. In kidney pathology, any mass or even capsular deformation depicted by B mode ultrasound represents an indication for CEUS. The kidney is completely and uniformly vascularized. In cystic tumors, there is a lack of contrast loading. In “impure” cystic masses (Bosnian 3 and 4), CEUS reveals vascularized septa and walls. In malignant tumors, accelerated and heterogeneous loading of contrast agent is observed in arterial phase followed by early, inhomogeneous washout of the contrast agent compared to normal renal parenchyma. In the abscesses, the appearance is the early loading of the walls associated with moderate hyperemia of the normal circulatory bed. This chapter details the CEUS in kidney tumor pathology, emphasizing the accurate information for the circulatory pattern of renal masses. It requires correlations with clinical data and information provided by other imaging explorations to make a final diagnosis.

Keywords: contrast-enhanced ultrasonography, Doppler ultrasonography, kidney tumors, kidney cysts, kidney abscesses

1. Introduction

Ultrasonography (US) is a diagnostic method based on the transmission and reception of ultrasounds in biological media, being frequently used in the “native” version without added procedures. It is the most widely available imaging method. In recent years,

“conventional” ultrasound was optimized by numerous procedures, including those using “contrast agents.” It consists of intravenous administration of specific substances in order to improve the diagnostic information. The technique is called “contrast-enhanced ultrasound” (CEUS). It allows simultaneously visualization of the flows from the large vessels and from the microcirculation [1]. CEUS is independent of the characteristics of blood column movement (velocity and angle of incidence of the ultrasound beam), being more sensitive than the Doppler technique. It permits the study of capillary circulation and detection of blood extravasations.

The CEUS method was first used for hepatic tumor pathology, but also for abdominal emergencies (detection of infarct or parenchymal dilacerations). The indication of CEUS has evolved and expanded rapidly in recent years, with the development of new contrast agents as well as the identification of new directions called “clinical applications” [2]. In urology, CEUS may have clinical implications with diagnostic values added to the detection and characterization of focal and diffuse renal, prostatic, testicular, and bladder lesions.

2. Principles

Ultrasound contrast agents are gas-filled microbubbles and are used clinically as blood pool tracers to significantly enhance the acoustic backscatter from blood. Definity (Lantheus Medical Imaging, North Billerica, MA, USA) and SonoVue (Bracco S.P.A., Milan, Italy) are two clinically licensed ultrasound contrast agents. MicroMarker (targeted and untargeted) (Bracco, Geneva, Switzerland; VisualSonics, Toronto, ON, Canada) is marketed as a preclinical UCA for contrast enhancement and molecular imaging in small animals. The microbubbles are made up of a lipid coating and a gaseous content (sulfur hexafluoride). The substance has a much lower solubility than air, which gives it good blood balance [3]. The diameter of the microbubbles is similar to that of the red blood cells (7 microns), which allow the passage of the contrast agent through the pulmonary and peripheral capillary circulation without any impediment. One of the main physic principles relies on the compressibility of the gases exposed to the pressure of an ultrasound beam. Microbubbles generate (through the mechanism called “non-linear vibration”) harmonic echoes (higher frequency multiples) that are recorded by the transducer. This behavior is significantly different from that of tissues. Ultrasound devices use ultrasound emissions to cancel the tissue signals and to accentuate the microbubble signals.

After intravenously administration of the contrast agent, an increased intensity signal coming from the vessels is depicted on the ultrasound screen. This enhanced signal can be evaluated in the gray scale, in the color-coded modes or in the hybrid mode (the combination of the two). The CEUS technique has a dynamic character, being possible a continuous tracking of the contrast agent through a region of interest (ROI). In the case of the kidney, the contrast agent is initially visualized in the renal artery, progressing to the sinus, the renal cortical, and after a delay of several seconds to the renal medulla. The first 30–40 s (sec) postinjection is appropriate for the arterial phase and then 30–40 s for the venous phase [4] (**Figure 1**).

The CEUS examination might be focused on a region of interest (ROI). The operator might analyze this ROI in real time, during the examination or through a dedicated soft that traces the time-intensity curves. The parameters obtained describe the vascular and temporal behavior, depending on the different postadministration phases (<30–40 sec = arterial time; >30–40 sec = venous time). The time-intensity curve (TIC) represents a quantitative analysis of the variability of the mean intensity within the selected sample over a period of time (**Figure 2**). They can be postprocessed on any video clip saved during CEUS [5].

Other qualitative useful information is represented by: the intensity of fill-in with contrast agent, the sense of fill-in, the fill-in pattern, the degree of wash-out of the contrast agent, the sense of wash-out, and the pattern of wash-out [6]. The evaluation of the lesions of interest is carried out as compared to the normal parenchyma.

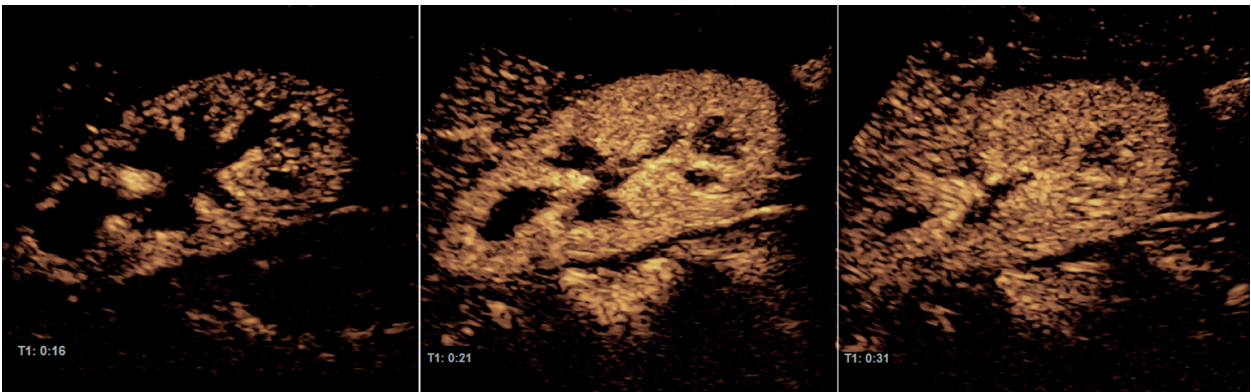


Figure 1. CEUS evaluation of the kidney. In very short time, there is a replenishment with microbubbles of cortex (periphery), cortex (columns), and the medulla.

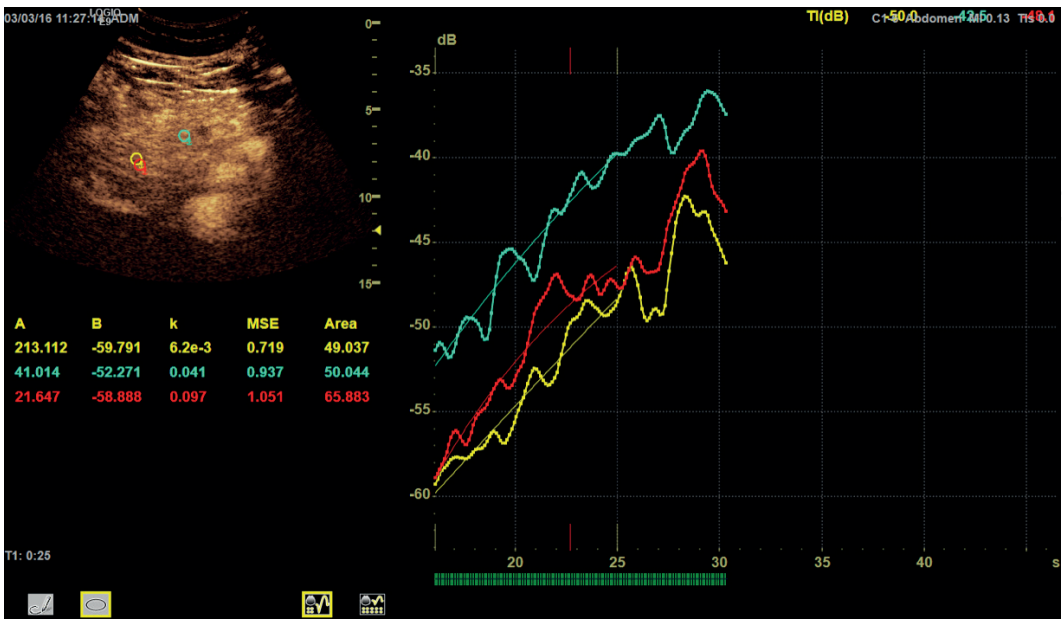


Figure 2. Representation of time-intensity transit curves. A sample area mounted in a specific area considered “target.” Special software is representing the characteristics of perfusion.

3. Equipment

For CEUS technique, the ultrasound device must be capable of functioning in harmonic mode and benefit from the acoustic power adjustment. The transducers, similar to those currently used for B and Doppler mode examinations, differ in the ability to operate in contrast mode. The harmonic mode allows a real and effective discrimination of the echoes from the blood column to those from the tissues. The acoustic power regulation is set to a value of 0.09–0.11, which leads to the generation of harmonic echoes at the microbubble level, minimizing the harmonic echoes at the tissue level and the artifacts.

4. The examination technique

Prior to the examination, a peripheral vein (preferably the antecubital vein) is catheterized with a 20–22 Gauge needle. The examination methodology goes through the following steps: gray scale (for ROI detection), Doppler technique (for circulatory specificity assessment), and contrast media assessment (for ROI characterization).

The patient's position is adapted for examination of the organ of interest. For retroperitoneal organs, it is recommended that the patient adopts a shallow breath to facilitate the maintenance of the area of interest in the ultrasound examination plan.

After activating the contrast mode, the following settings of the ultrasound equipment must be done: the "Focus" position below the region of interest, the mechanical index at 0.09–0.11, and reduce "Gain" function.

The injection of the contrast agent (at an average dose of 2.4 ml) is followed by 10 ml of saline solution is bolus. At the time of injection, the ultrasound timer and record videos are started. The region of interest is dynamically tracked for up to 5 min postinjection. Theoretically, a second injection can be made immediately, although this is rarely necessary in clinical practice [7].

The quality of the CEUS image is limited, as in the case of the B mode ultrasound, by the localization of the region of interest, the presence of the intestinal gas or bone margins, and the patient weight [7].

For kidney CEUS examination, the literature proposed various contrast phase terminologies. One is similar to the terminology used by multiphase contrast-enhanced computer tomography (CE-CT) and magnetic resonance imaging (MRI) [8]. This terminology uses three phases: corticomedullary (enhancing cortex with medullary pyramids not yet perfused, approximately 15–30 s after contrast agent injection), nephrographic (homogenously enhancing renal parenchyma, approximately 30–70 s postinjection), and delayed (>70 s postinjection) [8]. Other groups used the following terminology: arterial phase <30 s postinjection and delayed phase 30–90 s postinjection [9]. Other authors proposed other terminologies: cortical (8–35 s after injection), corticomedullary (36–120 s), and delayed (>120 s) [10].

5. Precautions

The sulfur hexafluoride, the gaseous part of the contrast agent is inert, nontoxic, with biocompatible membranes and easily eliminated by breathing. The metabolism of the membranes covering the microbubbles is done in the liver. These features make CEUS exploration independent of renal or thyroid functions, being an alternative to computer tomography in cases of renal failure or patients with history of thyrotoxicosis.

Very rare side effects are possible due to the interaction of ultrasound with microbubbles. These interactions may be mechanical or chemical. Mechanical features include bubble expansion and capillary rupture. Transient hyperthermia during bubbles recovering after expansion can generate free radicals. The precipitating factor for these reactions is the use of a mechanical index of about 0.4 [11]. Anaphylactic reactions were reported in 0.002% of examinations [12, 13].

6. Contraindications

CEUS contraindications are: severe coronary artery disease and pulmonary hypertension, unstable ischemic heart disease, age <18 years, and pregnancy [14]. No renal side effects have been reported so far after using CEUS.

7. CEUS in renal pseudo-tumors

Renal pseudotumors refer to persistent fetal lobulation, dromedary hump, and hypertrophied column of Bertin. These mass-like lesions are frequently detected on conventional ultrasound. The characteristic features are: location between overlapping portions of two renal sinus systems, clear demarcation from the renal sinus, size <3 cm, similar echogenicity to renal parenchyma, and lesions being bordered by a junctional parenchyma line; the Doppler mode demonstrates the regular, branch-like blood flow in the lesion [15].

There are, however, a number of situations in which their diagnosis is difficult—they may be miss-interpreted as kidney tumors through 2D gray scale techniques. This confounding is found in the following circumstances: modified echogenicity compared to the parenchymal environment, infiltrative tumor formations (metastases and lymphomas) [16], abnormal vascular tracts [17], and obese or noncooperative patients (**Figure 3**).

As CEUS is able to depict the microcirculation, this procedure could make the differential diagnosis between a pseudotumor and a solid mass. The vascular pattern of the “pseudo-tumors” is similar to adjacent parenchyma [18] (**Figures 4 and 5**). The accuracy of CEUS is similar to contrast-enhanced computer tomography (CE-CT) or magnetic resonance imaging (MRI) for the depiction of a normal vascular pattern in a pseudotumor mass [18].

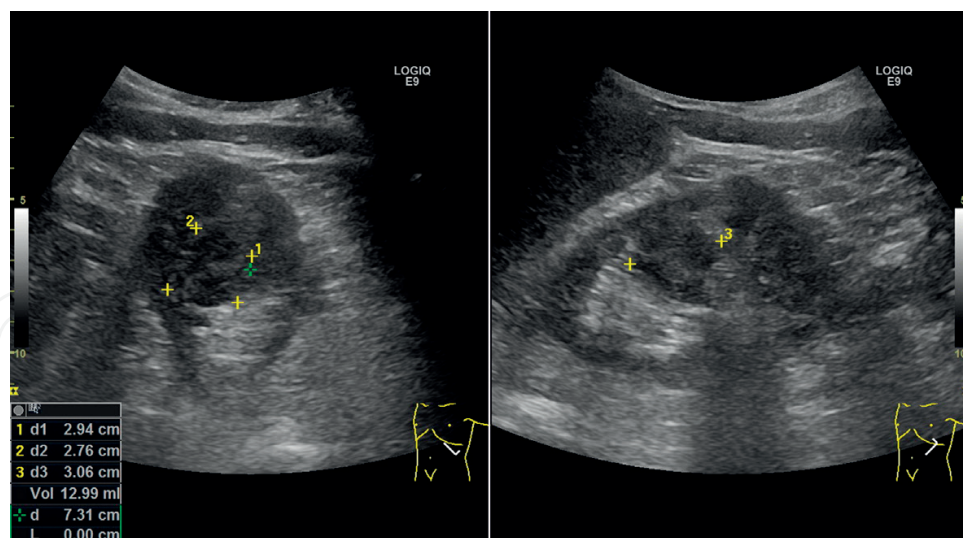


Figure 3. (a and b) Pseudotumor of the left kidney. In the middle part of the kidney, there is an area of parenchyma with hypoechoic and heterogeneous pattern suggesting a tumor. The aspect is uncertain and needs additional data especially from the vascular point of view.

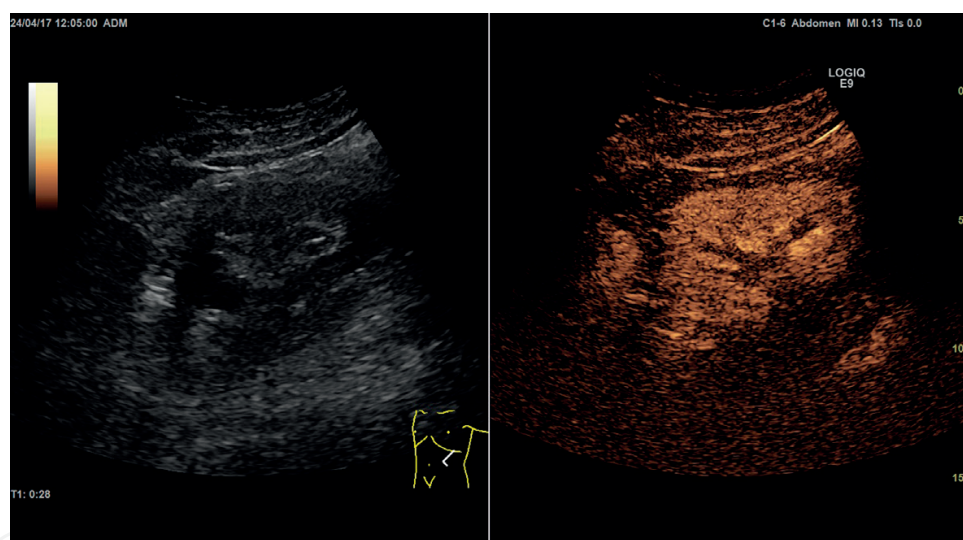


Figure 4. (a and b) Pseudotumor of the left kidney (same case as previous). Evaluation with microbubbles demonstrates no tumor in the middle of the kidney. This is a proof of how useful can be CEUS in suspicion of tumors of the kidney.

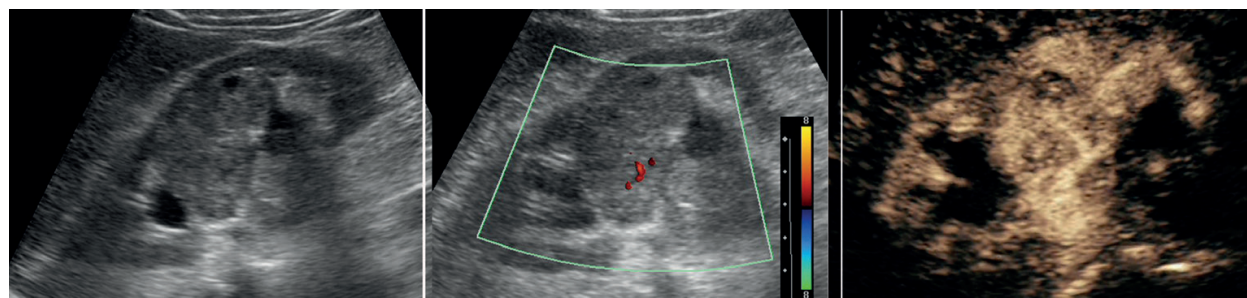


Figure 5. (a–c) Pseudotumor of the left kidney. In gray scale ultrasonography (a), there is a suspicion of a tumor in the middle of the organ. In Doppler color mode (b), there is a small vessel in the suspected tumor, insufficient for an accurate diagnosis. In CEUS focused on the middle of the kidney, there is no specific pattern for neoplasia.

8. CEUS for solid renal lesions

For solid renal masses, revealed by mode B ultrasonography, the differentiation between benign and malignant lesions is very important. The most frequent malignant lesion is renal cell carcinoma (RCC). Angiomyolipoma (AML) and oncocytoma are renal benign lesions [19]. The vascular pattern is a major criterion of differentiation and might be done with CEUS. A different vascular behavior of the renal mass compared with the adjacent parenchyma is specific for a tumor lesion and might be suggestive for malignancy [20]. CEUS has a higher accuracy than Doppler technique for renal cancer detection (100% compared to 71%) [21].

Tumor thrombus in the renal vein is a parenchymal structure with similar vascularization as the origin tumor. CEUS identifies the arterial vessels inside this parenchymal structure developed in the renal vein for the identification of the tumor's nature due to the presence of arterial time within the thrombus of the vascular signal (**Figure 6**). However, an emphasis on this character depicted in the renal vein regions of interest requires an experienced operator [11].

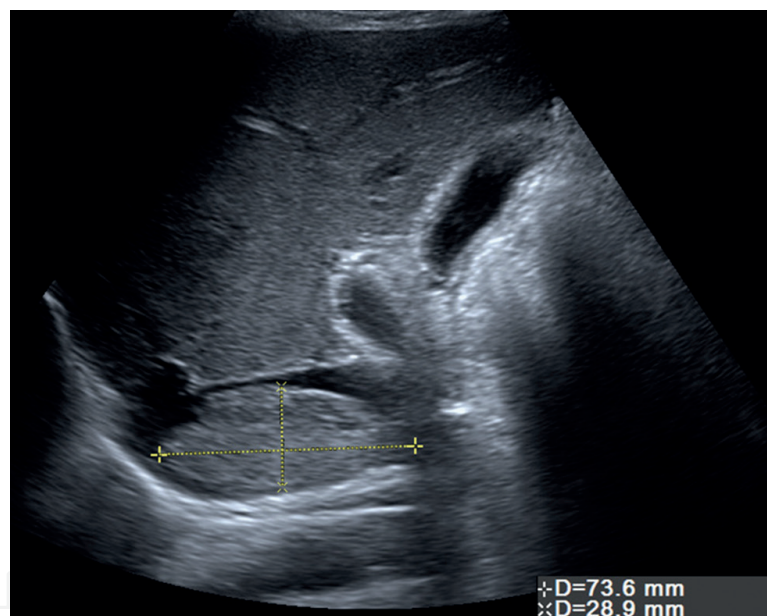


Figure 6. Malignant thrombus in inferior vena cava. Sagittal evaluation of the retroperitoneal space with representation of inferior vena cava and a large parenchymal structure in the vessel. The aspect is typical for a thrombus. In the presence of a kidney tumor, the aspect suggests a vascular invasion.

9. Renal cell carcinoma (RCC)

The clear cell renal cell carcinoma (ccRCC) is the most frequent common variant of renal cancer. Histologically is characterized by numerous thin-walled blood vessels with rich blood flow. The frequent morphological features correspond to intratumoral necrosis, hemorrhage, and calcifications [22]. In ultrasound B mode, the small tumors are often hyperechoic, corresponding to the thin-walled blood vessels with rich blood flow and can mimic angiomyolipoma (**Figure 7**) [8]. Larger tumors are hypoechoic and exophytic, with central anechoic necrosis (**Figure 8**) [8].

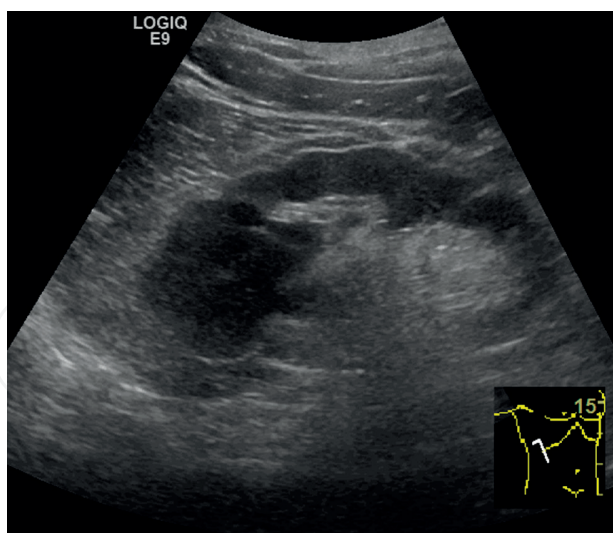


Figure 7. Renal cell carcinoma. Gray scale ultrasonography of the right kidney. At the upper pole, there is a hypoechoic tumor, relatively well defined.

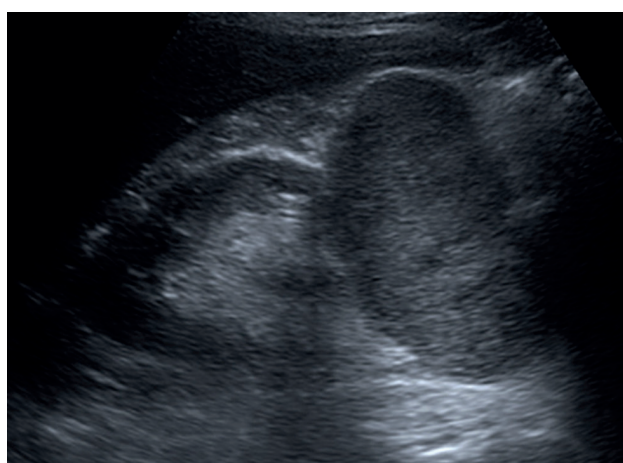

Figure 8. Renal cell carcinoma. Gray scale ultrasonography of the right kidney. At the lower pole, there is a round, well defined parenchymal tumor. The aspect is typical for a renal cell carcinoma.

The accuracy of CEUS to predict malignancy was intensively studied, but the results were not similar among authors. These confounding results are due in part to different terminology regarding the arterial and delayed phases, in part due to different contrast agents, and in part due to different features corresponding to natural development of the tumor (different CEUS characteristics depending on size) [8]. Reviewing the literature, ccRCC shows on CEUS the following vascular pattern: early hyperenhancement compared no normal adjacent parenchyma, wash-out on delayed phase, and perilesional enhancement, rim-like, corresponding to a pseudocapsule. There is also a heterogeneous enhancement, which increases with the lesion size [8].

A meta-analysis studied 11 comparable studies (including 567 malignant lesions and 313 benign lesions) and found a sensitivity of 88% and a specificity of 80% for CEUS to differentiate between malignant and benign renal tumors [23].

The papillary renal cell carcinoma are described in B mode ultrasound as unilocular and hypoechoic. The CEUS features of this type of RCC are: hypoenhance to renal parenchyma throughout examination and homogeneous [8].

10. Angiomyolipoma

Typically, AMLs contain macroscopic fat and in B mode ultrasound, there are homogeneously echogenic. There are lipid-poor AMLs that correspond to isoechoic feature on B mode ultrasound. The CEUS reveals for AMLs the following vascular pattern: homogeneous, hypoenhanced compared to adjacent renal parenchyma (**Figure 9**). The contrast agent persists in delayed phases. This characteristic is very important in differential algorithm for RCC [8].

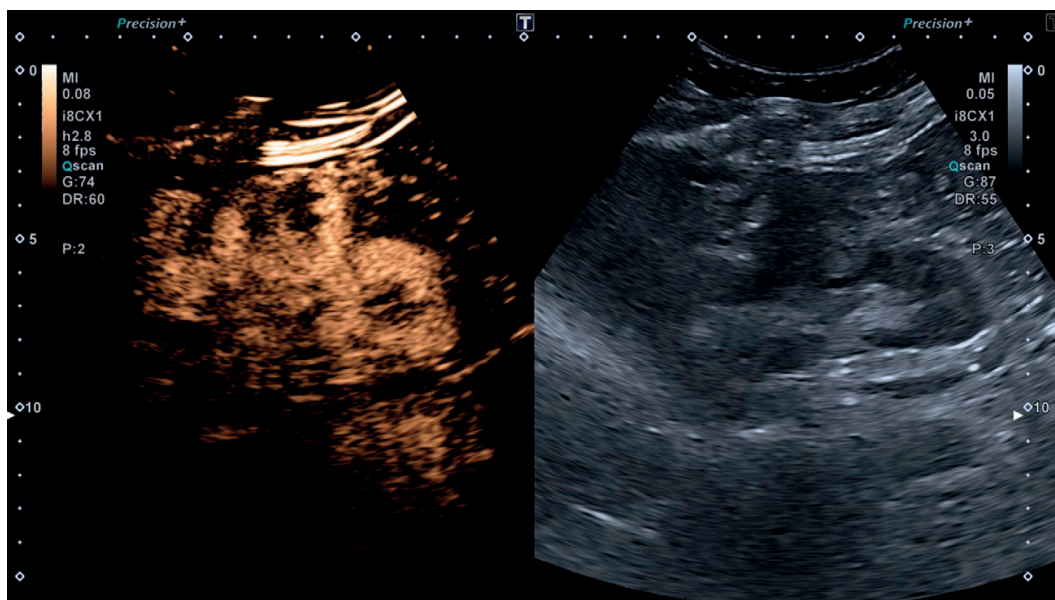


Figure 9. (a and b) Angiomyolipoma. CEUS (left) and gray scale ultrasonography (right). There is a tumor, round, well defined, and hypoechoic, with peripheral vascularity. The aspect suggests the presence of a neoplasia, but is not entirely typical for angiomyolipoma.

11. Oncocytoma

Oncocytoma are considered benign lesions. In B mode ultrasound, a hypoechoic central scar might be present, and color Doppler might show central radiating vessels (**Figure 10**) [8]. The differential diagnosis with chromophobe RCC of low malignant potential might be difficult. The vascular pattern depicted on CEUS was described differently in published case reports. It was documented a spoke wheel configuration of vessels on CEUS in an oncocytoma [20]. But other authors depicted an enhancement from periphery to center [8, 23]. The majority of the reports found hyperenhancement early compared with normal renal parenchyma and persistent (greater delayed) compared to ccRCC [8, 23].

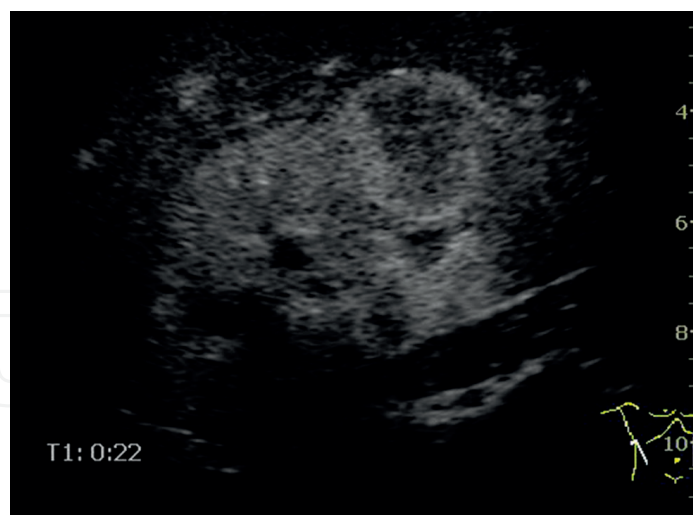


Figure 10. Oncocytoma. Round, parenchymal mass with enhancement of the peripheral vascular bed in the arterial time (Section 22).

12. Metastases and lymphoma

Imaging features suggestive for metastasis or lymphoma are: size <3 cm, lack of spherical shape, “infiltrative” growth, multiplicity, and bilaterality. There are no capsules or calcifications [8].

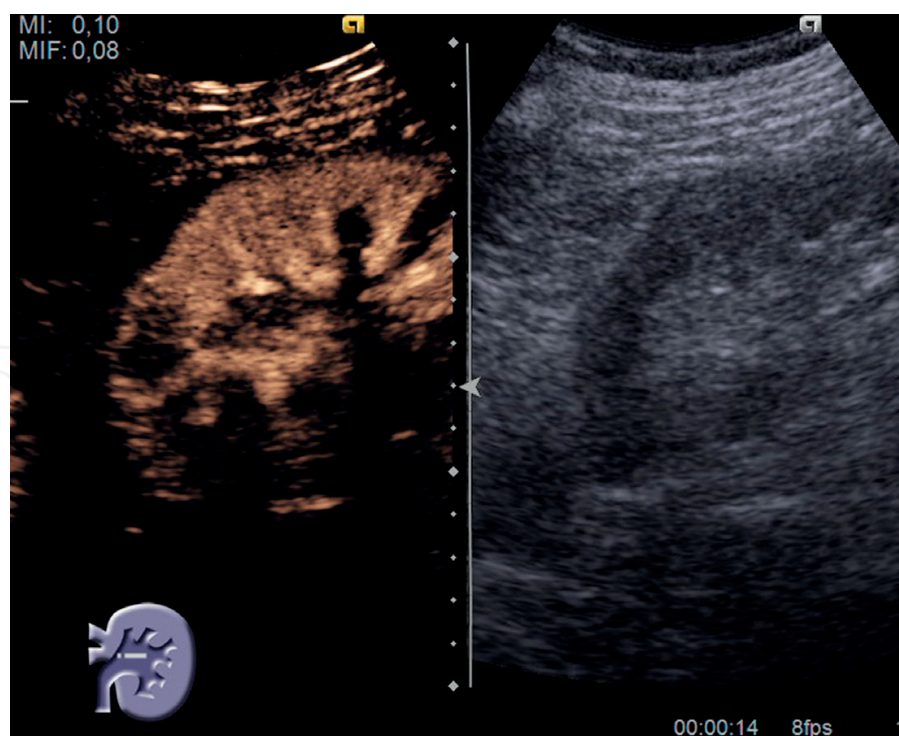


Figure 11. Renal lymphoma. CEUS evaluation (left) with an area of hypoenhancement at the upper pole; gray scale evaluation (right) with no signs of tumor. Vascular evaluation seems to be superior for the diagnostic than the morphometric pattern.

Few case reports depicted CEUS vascular pattern of renal metastasis, which are hypovascular on all phases [8]. Renal lymphoma was also described as hypovascular throughout renal perfusion after contrast agent administration on ultrasound (**Figure 11**) [8].

13. Cystic renal lesions

At imaging studies, approximately 10% of kidney cancers have a complex cystic appearance. Nonmalignant renal tumors may also have a complex appearance. This is most commonly due to the hemorrhage, infection, inflammation or ischemia. Differentiation between complex cysts requiring surgical treatment or monitoring is essential. The identification of vascularity in the solid area or septa of cystic lesions by CEUS simplifies the diagnosis of lesions with high malignancy potential [24].

The Bosniak classification differentiates five categories of renal cysts named I, II, IIf, III, and IV based on the imaging criteria (ultrasound and CT), being used for further clinical management of the patient [8, 25].

First Bosniak category, called I, depicts thin walls of the cyst, without septa and sharp margins. There are no solid components or calcifications. No enhancement is depicted on CEUS. There is no malignancy potential (**Figure 12**) [8, 25].

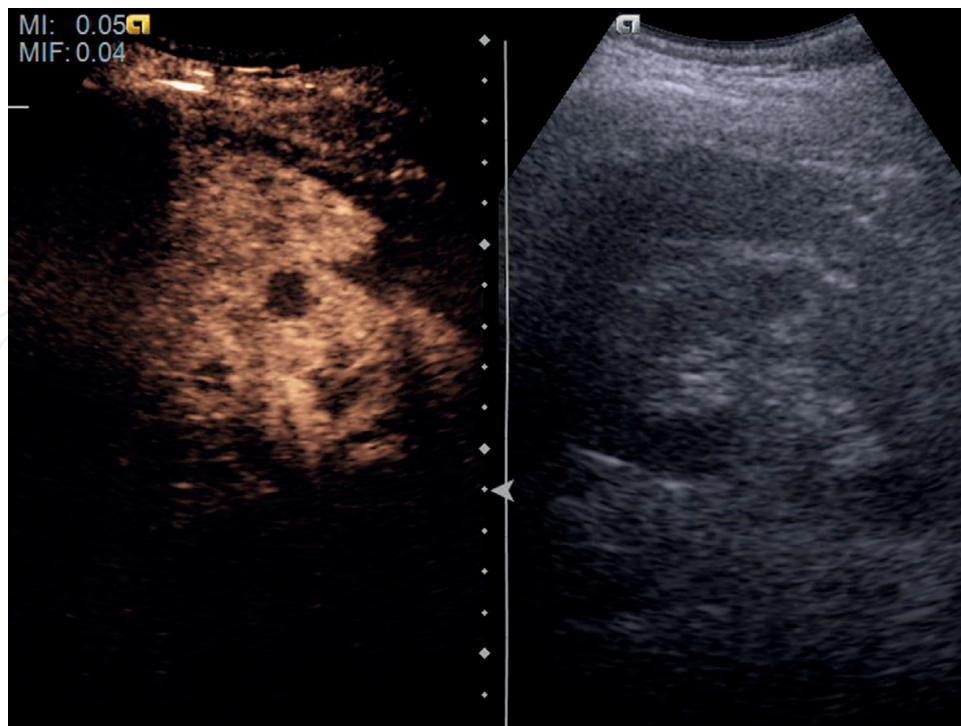


Figure 12. (a and b) Renal cyst. CEUS evaluation (a); an gray scale evaluation (b). In CEUS (asterisc), the lack of vascular signal suggests an avascular lesion compatible with the diagnosis of cyst.

Renal cysts from second category, II, are characterized by septa thinner than 1 mm, which might have fine calcifications. No contrast enhancement or very discrete enhancement is observed. The malignant potential is 0% [8, 25].

In the third category, called IIF, the cysts have multiple septa, minimally thickened walls, thin or thick calcifications. On CEUS, a discrete enhancement of the walls and septa is depicted. The malignant potential is 5%, and these lesions need regular monitoring for 6 months [8, 25].

Renal cysts from the fourth category, called III, present homogeneous or irregular thickening of the walls and/or septa and irregular calcifications. The CEUS examination reveals multiple contrast enhancing septa. The malignant potential is 50% [8, 25].

In the last category, called IV, the cysts present solid components together with homogeneous or irregular thickening of the walls and/or septa and irregular calcifications. The CEUS examination depicts multiple contrast enhancing septa and irregular contrast enhancing soft tissue components. These lesions are considered malignant [8, 25].

The accuracy of CEUS in differentiating renal cystic lesions as benign or malignant is similar to CE-CT [11]. The sensitivity of CEUS for depicting the vascular signal at the level of the cystic components (septa, walls, and nodules) is superior to CE-CT [26]. However, CEUS does not have the same sensitivity as CT in detecting calcifications, a confounding factor for the measurement of wall thickness and septum [27].

14. CEUS for monitoring renal interventions

CEUS is a very accurate method to depict blood extravasation after kidney surgery.

In the last years, CEUS became a useful tool for monitoring during and after radiofrequency ablations (RFA) and cryoablation (CA). The CEUS score system for monitoring after these interventions was proposed by Wink et al. [28] in which 0 = no enhancement, 1 = rim enhancement, 2 = diffuse enhancement, 3 = localized enhancement, and 4 = no defect in enhancement. The accuracy of CEUS compared to CE-CT or MRI was lower at 3 months post-treatment, but similar to these procedures at 12 month after [29].

15. Future expectations and developments in the field of kidney CEUS

A better quantification of blood flow could be achieved using contrast enhanced three-dimensional (3D) harmonic ultrasound imaging (HI) and subharmonic ultrasound imaging (SHI) [30]. In this preliminary study, 3D contrast-enhanced nonlinear ultrasound was able to quantify perfusion in vivo, in canine kidneys. Three-dimensional SHI resulted in better overall agreement with the reference standard than 3D HI did and was superior to previously reported 2D SHI results. Three-dimensional SHI outperformed the other methods for estimating blood perfusion because of the improved visualization of the complete perfused vascular networks [30]. This 3D technique based on CEUS proved an accurate examination for detecting renal transplant perfusion defects [31].

Another future application is related to robotic-assisted partial nephrectomy, which has gained prominence recently, as this approach has a shorter learning curve and a shorter warm ischemia time as compared to laparoscopic partial nephrectomy [32]. CEUS is capable of dynamic evaluation and quantification of microvasculature blood (capillary perfusion) in real time, without affecting renal function. When used in conjunction with a robotic ultrasound probe, CEUS can facilitate better visualization of renal vasculature and tumor and ultimately improving acumen and precision. CEUS is a valuable and a cost-effective tool for the identification of renal blood flow in robotic-assisted partial nephrectomy, especially with complex, challenging tumors [32].

16. Conclusions

The CEUS examination is an important progress for ultrasonography. The procedure depicts dynamic angio-perfusion. It is valuable in strengthening the diagnosis of renal cancer by evidencing neo-angiogenesis. It is useful in detecting tumor and nontumor circulatory abnormalities.

Acknowledgement

This work was supported by a grant of the Romanian Ministry of Research and Innovation, CCDI-UEFISCDI, project number PN-III-P1-1.2-PCCDI-2017-0056/3, within PNC DI III.

Author details

Lidia Ciobanu*, Attila Tamas Szora, Alexandru Florin Badea, Mihai Suciuc and Radu Badea

*Address all correspondence to: ciobanulidia@yahoo.com

University of Medicine and Pharmacy "Iuliu Hatieganu", Cluj-Napoca, Romania

References

- [1] Badea R, Ciobanu L. Contrast enhanced and Doppler ultrasonography in the characterization of the microcirculation. Expectancies and performances. *Medical Ultrasonography*. 2012;**14**(4):307-317
- [2] Cosgrove D, Eckersley R. Contrast-enhanced ultrasound: Basic physics and technology overview. In: Lencioni R, editor. *Enhancing the Role of Ultrasound with Contrast Agents*. Milan: Springer; 2006. pp. 3-14
- [3] Kono Y, Mattrey RF. Ultrasound of the liver. *Radiologic Clinics of North America*. 2005; **43**(5):815-826
- [4] Nilsson A. Contrast-enhanced ultrasound of the kidneys. *European Radiology*. 2004; **14**(Suppl 8):104-109

- [5] Cosgrove D, Lassau N. Imaging of perfusion using ultrasound. *European Journal of Nuclear Medicine and Molecular Imaging*. 2010;**37**(Suppl 1):S65-S85
- [6] Tranquart F, Mercier L, Frinking P, Gaud E, Arditi M. Perfusion quantification in contrast-enhanced ultrasound (CEUS)—Ready for research projects and routine clinical use. *Ultraschall in der Medizin*. 2012;**33**(Suppl 1):S31-S38
- [7] Setola SV, Catalano O, Sandomenico F, Siani A. Contrast-enhanced sonography of the kidney. *Abdominal Imaging*. 2007;**32**(1):21-28
- [8] Gulati M, King KG, Gill IS, Pham V, Grant E, Duddalwar VA. CEUS of cystic and solid renal lesions. *Abdominal Imaging*. 2015;**40**(6):1982-1996
- [9] Fan L, Lianfang D, Jinfang X, Yijin S, Ying W. Diagnostic efficacy of contrast-enhanced ultrasonography in solid renal parenchymal lesions with maximum diameters of 5 cm. *Journal of Ultrasound in Medicine*. 2008;**27**(6):875-885
- [10] Xu ZF, Xu HX, Xie XY, Liu GJ, Zheng YL, Liang JY, Lu MD. Renal cell carcinoma: Real-time contrast-enhanced ultrasound findings. *Abdominal Imaging*. 2010;**35**(6):750-756
- [11] Piscaglia F, Nolsøe C, Dietrich CF, et al. The EFSUMB guidelines and recommendations on the clinical practice of contrast enhanced ultrasound (CEUS): Update 2011 on non-hepatic applications. *Ultraschall in der Medizin*. 2012;**33**(1):33-59
- [12] Piscaglia F, Bolondi L. Italian society for ultrasound in medicine and biology (SIUMB) study group on ultrasound contrast agents. The safety of Sonovue in abdominal applications: Retrospective analysis of 23188 investigations. *Ultrasound in Medicine & Biology*. 2006;**32**(9):1369-1375
- [13] Ter Haar G. Safety and bio-effects of ultrasound contrast agents. *Medical & Biological Engineering & Computing*. 2009;**47**(8):893-900
- [14] Main ML, Goldman JH, Grayburn PA. Ultrasound contrast agents: Balancing safety versus efficacy. *Expert Opinion on Drug Safety*. 2009;**8**(1):49-56
- [15] Leekam RN, Matzinger MA, Brunelle M, Grey RR, Grosman H. The sonography of renal columnar hypertrophy. *Journal of Clinical Ultrasound*. 1983;**11**(9):491-494
- [16] Ascenti G, Zimbaro G, Mazziotti S, Gaeta M, Lamberto S, Scribano E. Contrast-enhanced power Doppler US in the diagnosis of renal pseudotumors. *European Radiology*. 2001;**11**(12):2496-2499
- [17] Robbin ML, Lockhart ME, Barr RG. Renal imaging with ultrasound contrast: Current status. *Radiologic Clinics of North America*. 2003;**41**(5):963-978
- [18] Mazziotti S, Zimbaro F, Pandolfo A, Racchiusa S, Settineri N, Ascenti G. Usefulness of contrast-enhanced ultrasonography in the diagnosis of renal pseudotumors. *Abdominal Imaging*. 2010;**35**(2):241-245
- [19] Ignee A, Straub B, Schuessler G, Dietrich CF. Contrast enhanced-ultrasound of renal masses. *World Journal of Radiology*. 2010;**2**(1):15-31

- [20] Tamai H, Takiguchi Y, Oka M, et al. Contrast-enhanced ultrasonography in the diagnosis of solid renal tumors. *Journal of Ultrasound in Medicine*. 2005;**24**(12):1635-1640
- [21] Dong XQ, Shen Y, Xu LW, Xu CM, Bi W, Wang XM. Contrast-enhanced ultrasound for detection and diagnosis of renal clear cell carcinoma. *Chinese Medical Journal*. 2009;**122**(10):1179-1183
- [22] Reese JH. Renal cell carcinoma. *Current Opinion in Oncology*. 1992;**4**(3):427-434
- [23] Wang C, Yu C, Yang F, Yang G. Diagnostic accuracy of contrast-enhanced ultrasound for renal cell carcinoma: A meta-analysis. *Tumor Biology*. 2014;**35**(7):6343-6350
- [24] Aoki S, Hattori R, Yamamoto T, Funahashi Y, Matsukawa Y, Gotoh M, Yamada Y, Honda N. Contrast-enhanced ultrasound using a time-intensity curve for the diagnosis of renal cell carcinoma. *BJU International*. 2011;**108**(3):349-354
- [25] Rubenthaler J, Bogner F, Reiser M, Clevert DA. Contrast-enhanced ultrasound (CEUS) of the kidney by using the Bosniak classification. *Ultraschall in der Medizin*. 2016;**37**:234-252
- [26] Park BK, Kim B, Kim SH, Ko K, Lee HM, Choi HY. Assessment of cystic renal masses based on Bosniak classification: Comparison of CT and contrast-enhanced US. *European Journal of Radiology*. 2007;**61**(2):310-314
- [27] Israel GM, Hindman N, Bosniak MA. Evaluation of cystic renal masses: Comparison of CT and MR imaging by using the Bosniak classification system. *Radiology*. 2004;**231**(2):365-371
- [28] Wink MH, Laguna MP, Lagerveld BW, de la Rosette JJ, Wijkstra H. Contrast-enhanced ultrasonography in the follow-up of cryoablation of renal tumours: A feasibility study. *BJU International*. 2007;**99**(6):1371-1375
- [29] Barwari K, Wijkstra H, van Delden OM, de la Rosette JJ, Laguna MP. Contrast-enhanced ultrasound for the evaluation of the cryolesion after laparoscopic renal cryoablation: An initial report. *Journal of Endourology*. 2013;**27**(4):402-407
- [30] Sridharan A, Eisenbrey JR, Liu JB, Machado P, Halldorsdottir VG, Dave JK, Zhao H, He Y, Park S, Dianis S, Wallace K, Thomenius KE, Forsberg F. Perfusion estimation using contrast-enhanced 3-dimensional subharmonic ultrasound imaging: An in vivo study. *Investigative Radiology*. 2013;**48**(9):654-660. DOI: 10.1097/RLI.0b013e3182925160
- [31] Stenberg B, Chandler C, Wyrley-Birch H, Elliott ST. Post-operative 3-dimensional contrast-enhanced ultrasound (CEUS) versus Tc99m-DTPA in the detection of post-surgical perfusion defects in kidney transplants—Preliminary findings. *Ultraschall in der Medizin*. 2014;**35**(3):273-278. DOI: 10.1055/s-0033-1355964
- [32] Alenezi AN, Karim O. Role of intra-operative contrast-enhanced ultrasound (CEUS) in robotic-assisted nephron-sparing surgery. *Journal of Robotic Surgery*. 2015;**9**(1):1-10. DOI: 10.1007/s11701-015-0496-1

