

We are IntechOpen, the world's leading publisher of Open Access books Built by scientists, for scientists

6,900

Open access books available

186,000

International authors and editors

200M

Downloads

Our authors are among the

154

Countries delivered to

TOP 1%

most cited scientists

12.2%

Contributors from top 500 universities



WEB OF SCIENCE™

Selection of our books indexed in the Book Citation Index
in Web of Science™ Core Collection (BKCI)

Interested in publishing with us?
Contact book.department@intechopen.com

Numbers displayed above are based on latest data collected.
For more information visit www.intechopen.com



Bipolar Endoscopic Enucleation of Big Benign Prostate Enlargement

Wai Hee Steve Chan, Chi Fai Kan and
Churk Fai Trevor Li

Additional information is available at the end of the chapter

<http://dx.doi.org/10.5772/intechopen.79125>

Abstract

Large benign prostatic enlargement (BPE) has been a major health problem and the surgical management could be technically challenging to urologists due to the limitation of conventional monopolar transurethral resection of prostate. Bipolar endoscopic enucleation of prostate aimed to remove the adenoma of BPE by stepwise adenoma devascularization and maximal adenoma removal through minimally invasive surgery. In this chapter we described the general principle, the surgical techniques of bipolar endoscopic enucleation and the related modifications of the technique in the recent years. As compared with open prostatectomy, bipolar endoscopic enucleation avoided the wound complications but achieved similar functional outcome. Bipolar endoscopic enucleation also allowed much more adenoma removal comparing with transurethral resection of the prostate. Unlike Holmium laser or thulium laser enucleation of the prostate, the required instruments for bipolar endoscopic enucleation of the prostate were familiar and more readily available to most urologists.

Keywords: benign prostatic hyperplasia, bipolar, enucleation, plasmakinetic, transurethral surgery

1. Introduction

Benign prostatic hyperplasia (BPH) has been a common and important health condition in the modern society. With the aging population, benign prostatic obstruction (BPO) can affect the patients with different degree of bothersome lower urinary tract symptoms or the associated complications. Transurethral resection of the prostate has been the gold standard treatment

for benign prostatic obstruction (BPO) with prostate volume 30–80 gm [1]. However, despite its minimally invasive nature and more advanced endoscopes, large benign prostatic enlargement especially over 80 gm remains challenging to urologists due to the increased morbidities related to glycine over-absorption during prolonged operation and transurethral resection of the prostate can resect up to 30–53% of the prostate volume only, leading to problems related to inadequate resection e.g. persistent retention of urine in retention patients and recurrent symptoms [1, 2]. Open prostatectomy provides effective treatment for prostate glands larger than 80 gm through more thorough adenoma removal but yet being most invasive comparing the currently available endoscopic enucleation treatment [1, 3]. However, there were associated problems like wound related complications, prolonged post-operative catheterization and risks of severe hemorrhage [3–6].

Hiraoka described the first endoscopic enucleation of the prostate through monopolar current system in 1983 [7]. However not until the development of model endoscopy system, Holmium:YAG laser, bipolar plasmakinetic system and morcellator, endoscopic enucleation was popularized in the urology field [8]. Gilling reported the technique and outcome of Holmium laser enucleation of the prostate in 1998 [9] but the technique has not been widely adopted due to the learning curve of the procedure and the requirement of high-powered Holmium:YAG laser generator and morcellator.

With the development of bipolar plasmakinetic system in transurethral surgery, transurethral resection can be performed with normal saline irrigation with provides better patient safety and comparable outcome with monopolar system [1]. Neill described the result of his randomized controlled result comparing plasmakinetic enucleation of the prostate with Holmium laser enucleation with Gilling's group in 2006 [9]. Bipolar endoscopic enucleation of prostate is further popularized by Prof Liu CX's group [10] which presented their experience in 1100 patients in 2003–2009, using the technique with only the bipolar transurethral surgery system without the use of morcellator. In the last 15 years, bipolar endoscopic enucleation of the prostate has been reported in many centers with different bipolar transurethral systems, electrodes, modified resection devices and tissue removal technique [3–8, 10–21], so that there was no single unified terminology to describe this technique. In this chapter the term “bipolar endoscopic enucleation of prostate” [12] is used to highlight to key component of this transurethral technique [10–15] and to concur with the term “endoscopic enucleation of the prostate” used in the current guideline in European Association of Urology [1].

2. Surgical technique of bipolar endoscopic enucleation of prostate

2.1. Patient preparation

The indications of bipolar endoscopic enucleation of prostate follow the principle of benign prostate enlargement treatment [1]. The patient would have pre-operative urine culture be performed and treated accordingly to prevent peri-operative urosepsis [22]. Transrectal ultrasound of prostate is recommended in addition to a regular digital rectal examination to evaluate the size of the prostate to avoid prostate size underestimation and the operating surgeons can have a mental image about the shape of the prostate under treatment [1]. This is especially

recommended for surgeons at their initial learning curves to measure the prostate size which provides an insight of anticipated difficulty especially in huge prostates. Oral anticoagulant therapy and/or platelet aggregation inhibitors would be stopped pre-operatively according to the patient's medical condition or regional medical guidelines, though it has been reported that these agents can be continued peri-operatively without excessive increase in transfusion rate and clot retention [16, 23].

2.2. Operative description of bipolar endoscopic enucleation of prostate

Our technique and experience of bipolar endoscopic enucleation of prostate has previously been reported [12]. The patient is put on general or spinal anesthesia with Lloyd-Davis position or lithotomy position. The operation is performed with continuous normal saline irrigation, 60–70 cm above the patient level. Cystoscopic examination of the lower urinary tract is performed to rule out any bladder malignancy or calculus. The ureteric orifice, bladder neck and the verumontanum are identified as the important landmark of bipolar endoscopic enucleation of the prostate.

Enucleation of the adenoma started from just proximal to the verumontanum at 5 and 7 o'clock. It aims to cleave the plane between the adenoma to the surgical capsule just proximal to the external urinary sphincter. The beak of the resectoscope could directly enter this plane through blunt dissection or an incision could be made over the urethral mucosa to the surgical capsule to start the enucleation but it may result in more bleeding and obscure the vision [18, 19]. This landmark is easily identifiable and the thickness of tissue that required to be cut is the thinnest. The surgeon should be able to visualize the whitish smooth surgical capsule of the prostate soon after opening up the urethral mucosa here. For bilobar BPE patient, enucleation is started just proximal to the verumontanum (**Figure 1**). Then, the plane between

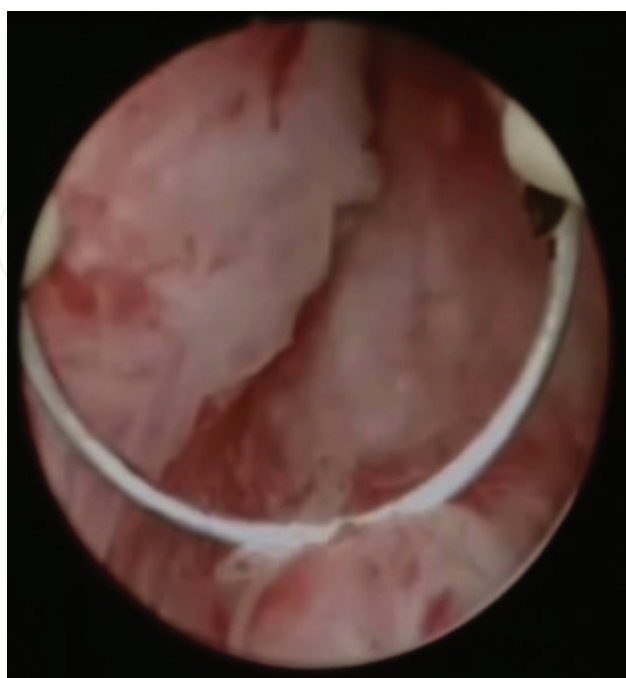

Figure 1. Incision of the urethral mucosa just proximal to verumontanum in case of enucleating bilobar enlarged prostate.

the adenoma and the capsule is developed by the beak of the resectoscope or by the bipolar electrode (**Figure 2**), depending on the preference of the surgeon and the available electrode. The distal mid lobe is dissected in retrograde fashion to the bladder neck. The blood vessels are coagulated by the bipolar electrode and the adhesive fibers are cut to open up the plane. The procedure is continued till the circular fiber of the bladder neck is identified (**Figure 3**). The bladder mucosa is incised to enter the bladder at 5 or 7 o'clock. Caution should be taken to dissect the posterior mid gland from the surgical capsule along the contour of the prostate posterior surface, so as to avoid perforation of the prostatic capsule and undermining the bladder neck at 6 o'clock.

The plane is further developed laterally with the supplying vessels coagulated. Both lateral lobes are enucleated laterally (**Figure 4**) to reach the 11 o'clock and 1 o'clock of the anterior fibromuscular stroma, where the adenoma is usually adhered more densely than the other region [17]. The attachment at 12 o'clock allows the adenoma be resected in the prostatic fossa rather than free floating inside the bladder.

Some urologists prefer to have enucleation of the prostate by starting from 5 or 7 o'clock proximal to the verumontanum and then bluntly dissected the adenoma laterally. The bladder was entered at 11 and 1 o'clock of the bladder neck to avoid entering the bladder over the trigone area. The anterior fibromuscular stroma at 12 o'clock was joined through the bilateral dissection plane and the adenoma was left attached to the bladder neck to facilitate adenoma resection.

After majority of the adenoma is devascularized, the adenoma is resected from the bladder neck by the loop electrode in an almost bloodless manner (**Figure 5**). The prostate chips are removed by Ellik's evacuator. As in usual bipolar transurethral resection of the prostate, gas

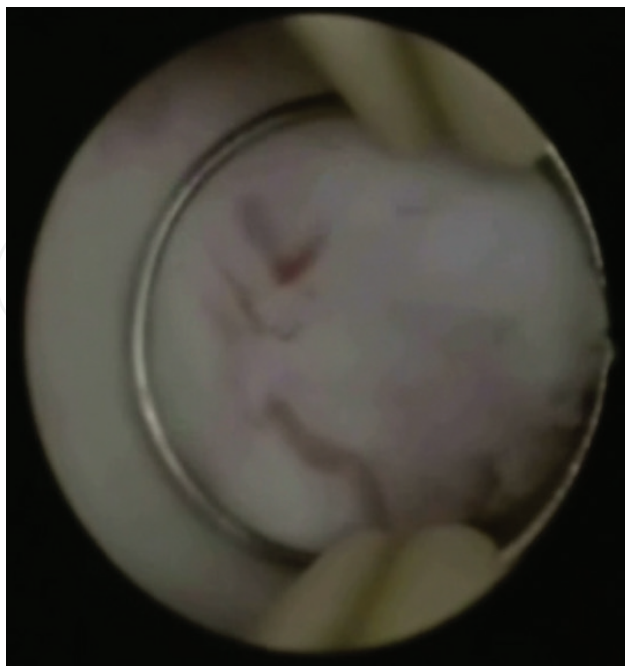


Figure 2. Development of the enucleation plane by using the beak and the bipolar electrode. The feeding vessels to the adenoma were coagulated.

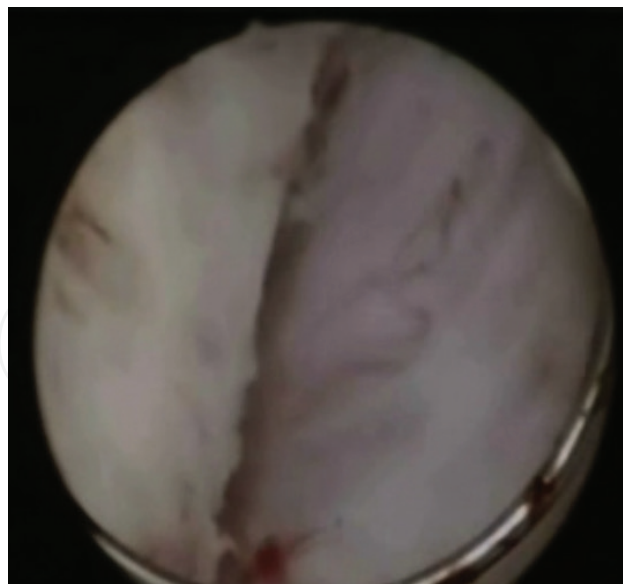


Figure 3. The enucleation process is continued till the circular muscle fiber of the bladder is noted.

will be accumulated inside the bladder and the intravesical pressure has been measured to be around 25 mmHg [17]. The increased intravesical pressure may obscure some venous bleeding. Careful hemostasis should be obtained after drainage of the intravesical gas.

2.3. Tips and tricks of the technique of bipolar endoscopic enucleation of prostate

There are different kinds of bipolar transurethral systems reported in literature such as Gyrus PlasmaKinetic (PK) system, Olympus system through SurgMaster™ USE 40 generator

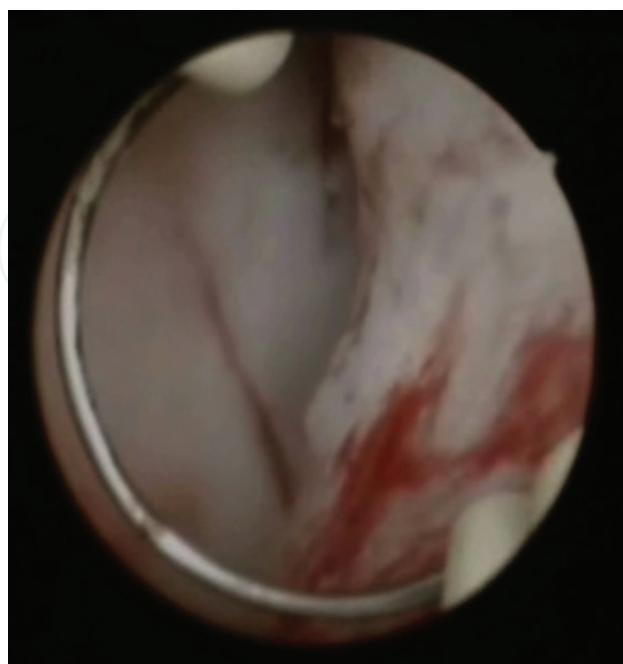


Figure 4. Enucleation of the lateral lobe of the adenoma.

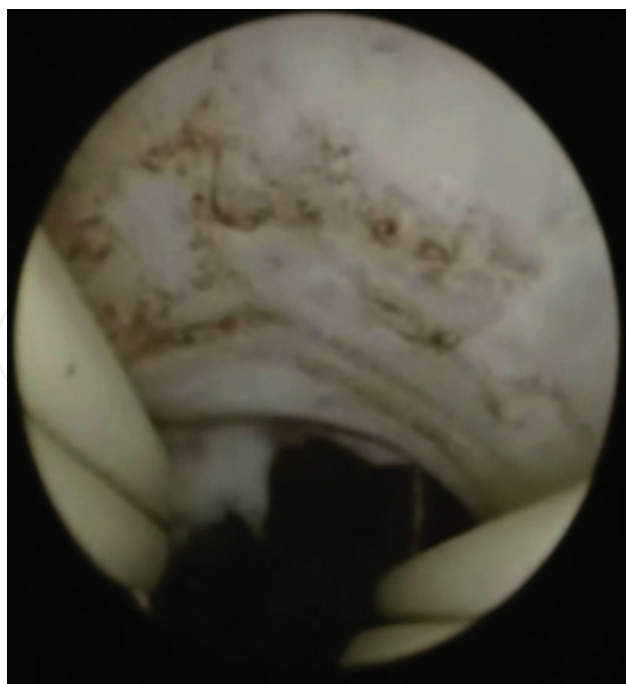


Figure 5. Resection of the devascularized adenoma from 6 o'clock from the bladder neck with the scope oriented upwards.

(Olympus Tokyo Japan) and Scanned Plasmakinetic System (Scanmed, Zhuhai, China) [3, 7–19, 22]. However, it has been shown in that in Quasi-bipolar system which the electrical current is returned to the generator through the outer sheath of the bipolar resectoscope, the urethral stricture rate can be higher if the procedure is prolonged in larger prostate size >70 gm resection [24]. It is postulated that the return current over the out sheath may damage the bulbous urethra and causes an higher incidence of urethral stricture. However, this finding was reported in a single centre's experience [24] and was not observed in other groups' results using similar instruments [10, 19]. There will be some difference in design of the beak of the resectoscope and the strength of the electrode in different bipolar systems. The surgeon should be familiarized with their instrument before deciding to use the beak or the electrode for enucleation.

Button electrode has been developed in both Gyrus PK and Olympus system. The button electrode has larger contact surface area and allows easier contact coagulation and vaporization. Button electrode has been used in bipolar endoscopic enucleation of the prostate [14, 15, 23] and it has been shown to provide better hemostasis especially for patients on anti-coagulation therapy [23]. The learning curve is also proposed to be shorter than the conventional bipolar endoscopic enucleation of prostate by using loop electrode [15]. However, these button electrodes are designed as single use items. Extra instruments such as loop electrode or morcellator are required for prostate adenoma resection on top of the use of button electrode. The Japanese group also reported the use of loop electrode with a specially designed spatula for blunt enucleation [13], though it is not readily available in other parts of the world.

In case of gross trilobar enlargement with prominent median lobe, 3-lobe technique can be considered [11, 18]. Incision is made at 5 and 7 o'clock of from the bladder neck to the verumontanum. The median lobe is enucleated and removed first. The procedure is continued with further enucleation of the lateral lobes through the same plane. The continuous normal saline irrigation is improved with the median lobe removed first.

A Chinese group described another enucleation technique to overcome the problem of enucleation of the prostate over the more densely adhered anterior fibromuscular stroma at 12 o'clock [17]. That region was firstly resected by bipolar transurethral resection of prostate down to the surgical capsule. The enucleation of the prostate is then started from verumontanum and then directed laterally to the 10 and 2 o'clock position. The adenoma is left attached to the bladder neck at 6 o'clock to avoid adenoma dislodgement into the bladder.

Despite adequate devascularization of the adenoma after enucleation, resection of the large adenoma with loop electrode can be difficult due to its size and disorientation, especially at the early learning curve. Our group resects the adenoma from 6 o'clock from the bladder neck with the scope oriented upwards, so that the resection of adenoma directed at 12 o'clock will not damage the surgical capsule [12]. Prof Liu utilized both forward and backward movement of the working element to resect the devascularized adenoma, in order to reduce the operative time [11]. Besides using the loop electrode for adenoma resection, morcellator is also used in some centers to reduce the adenoma resection time [13, 25], though caution should be taken to avoid bladder injury by the morcellator.

Although bipolar transurethral system allows the procedure to be safely performed in a longer period of time, it has been a concern if there is over-absorption of normal saline during the enucleation procedure especially with potential capsular perforation. Ran and his colleagues have compared the irrigation fluid absorption volume with bipolar enucleation and bipolar resection technique using 1% ethanol containing saline solution. It is found that there would be around 900 ml fluid absorbed for bipolar endoscopic enucleation with around 70 gm prostate [26] and it was not different from bipolar transurethral resection of the prostate with similar size. Especially in patients with underlying cardiovascular conditions, it is advisable to give frusemide intra-operatively to reduce the chance of fluid overload [11].

3. Surgical outcome of bipolar endoscopic enucleation of prostate

3.1. Functional outcome

Current literature demonstrated bipolar endoscopic enucleation of prostate could achieve functional outcome comparable to open prostatectomy. Data drawn from bipolar endoscopic enucleation of prostate arm of 5 randomized control trials for prostate size >80 ml [3, 17] showed that bipolar endoscopic enucleation of prostate reduced lower urinary tract symptoms by 83% (76–86%, with reduction of IPSS point 17.6–22.1), improved quality of life (QOL) score by 70% (50–82%), increased mean maximum urine flow (Q_{max}) by 331% (152–535%, +9.6–21.4 ml/s), and reduced post voiding residual volume (PVR) by 86% (68–93%). Efficacy was maintained for up to 6 years [5].

For perioperative outcomes, it was reported that the resected specimen's weight could reach a mean of 80.4% of the preoperative prostate size. Average operative time was 109 min [3, 5, 6, 17] with a mean prostate size of 111 cc, and this was likely achieved by surgeons that have passed the learning curve. With the use of morcellator operative time could be further shortened, as demonstrated in one randomized control trial [4] the operative time was 87 mins with a mean prostate size of 123 cc.

The randomized controlled trials reported the catheterization time to be 2.3 days, and the average length of stay was 4.2 days. Re-catheterization due to retention ranged from 0 to 4.3%.

3.2. Complications

For early complications, transient stress urinary incontinence was reported ranging from 0 to 8.75%. One randomized controlled trial reported early storage urinary symptoms to be 2.1% [17]. Mean hemoglobin drop of 1.16 g/dL with blood transfusion rate ranging from 0 to 6.4%. UTI was reported ranging 3.6–7%. There was a small chance of clot retention 0–1.1%.

For late complications, bladder neck contracture/stenosis was reported to be 0–2.4%, urethral stricture was reported as 2.1–3.75%. There was no permanent incontinence reported in this 5 RCT, and no reoperation for regeneration of adenoma was reported.

3.3. Learning curve

Xiong et al. evaluated the learning curve of the initial 100 cases of 2 surgeons. It was reported that the surgeons required 30 operations until a few conversions to conventional bipolar TURP occurred [19]. It also noted that 50 operations were required to achieved a stable surgical efficiency, as measured by mL/minute of tissue being enucleated and resected. This was echoed by another Japanese single surgeon cohort [13], which showed the efficiency improved markedly when the surgeon experience exceeded the initial 50 cases. With the presence of mentor, 40 cases was required to reach plateau in terms of operation or enucleation efficiency in g/min, as shown in one retrospective study [27].

Barriers during the learning curve focused on properly identifying and handling the right plane in the absence of mentorship. The anatomic landmarks that prompt the surgeon to identify the surgical plane mainly include capsule transverse fibers or fiber strands, capsule vessel reticula, capsule prostate calculi [19].

The advantage of bipolar endoscopic enucleation of prostate during the learning curve is that it can be converted to conventional bipolar transurethral resection of prostate, using the same set of instrument with no harm to patients. Though Tracey et al. reported a higher rate of capsular perforation or undermining of the bladder neck in the initial learning curve in up to 8% [28].

4. Comparison with other surgical modality for BPH

4.1. Open prostatectomy

Bipolar endoscopic enucleation of prostate was most frequently compared with open prostatectomy in the current available literature as open prostatectomy is still be regarded as the gold standard surgical procedure for large benign prostate enlargement. Four randomized control trials were available [3–6]. All these studies showed the functional outcome were similar but bipolar endoscopic enucleation of the prostate improved perioperative parameters in terms of less hemoglobin drop, less transfusion, shorter catheterization time and shorter

length of stay. The wound complications related to open surgery were avoided including wound dehiscence, wound infection and paralytic ileus reported [5]. There was no significant difference in other mid and long term complications in terms of bladder neck stenosis, urethral stricture. In the European Association of Urology guideline 2018, endoscopic enucleation (including bipolar energy) was rated as first recommended choice for treating substantially enlarged prostate ≥ 80 gm, same as open prostatectomy (previous gold standard), with a more favorable peri-operative safety profile [1].

4.2. Bipolar transurethral resection of prostate

Two randomized control trials [4, 17] compared bipolar TURP with bipolar endoscopic enucleation of prostate. The surgical efficacy was higher for bipolar endoscopic enucleation of prostate with more resected weight as compare to bipolar TURP. At 12 month follow-up, persistent significant difference in Qmax, IPSS and QOL was shown in one randomized controlled trial [17] but not for another one [4]. Significantly higher perioperative complications in terms of clot retention, dysuria, re-catheterization, blood transfusion, and reoperation for bipolar TURP were reported in one randomized controlled study [17].

4.3. Photoselective vaporization of prostate (PVP)

One prospective cohort compared PVP (160 W LBO green laser system) with bipolar endoscopic enucleation of prostate. It demonstrated that significant improvement of IPSS, QOL, Qmax, PVR and PSA changes in favor of bipolar endoscopic enucleation of prostate in 12 months (mean prostate size 88.3 ml) [21]. There was no difference in terms of perioperative complications and no transfusion was required in both group of patient.

4.4. Holmium laser enucleation of prostate (HoLEP)

One small randomized control trial ($n = 40$) compared HoLEP and bipolar endoscopic enucleation of prostate in medium sized prostate (mean 51 cc) [10]. The author commented bipolar endoscopic enucleation of prostate had more pronounced postoperative irrigation requirement because of reduced visibility and a greater propensity for bleeding as compared with HoLEP. Longer operative time was noted for bipolar endoscopic enucleation of prostate. However, it was still the early infancy of the development in bipolar endoscopic enucleation of prostate on the study period. The result was likely due to the comparison of initial development of bipolar endoscopic enucleation of prostate to more well established HoLEP technique in the study period. Other perioperative parameters/complications are similar without significant difference between both groups.

4.5. Thulium laser enucleation of prostate (ThuLEP)

A randomized control trial [20] compared ThuLEP with bipolar endoscopic enucleation of prostate in medium sized prostate (mean 67.1 cc). ThuLEP provided less risk of hemorrhage and shorter catheter time, although the differences may be of little clinical relevance. No statistical differences in complications between the two groups. Assessment at 12-month follow-up showed no difference in urinary parameters between the two groups.

5. Conclusion

Bipolar endoscopic enucleation of prostate provides an excellent minimally invasive modality for surgical treatment of large BPE especially for those ≥ 80 gm. It allowed better functional outcome than transurethral resection and stepwise adenoma devascularization with minimally invasive technique. The instruments were familiar to most urologists and were available in most modernly equipped urology centers. In addition, it allows easy and quick conversion to traditional transurethral resection. The authors believe endoscopic enucleation of the prostate including bipolar energy has replaced open prostatectomy as the standard of care in the surgical management of large BPE.

Conflict of interest

There is no conflict of interest to be declared by the authors.

Author details

Wai Hee Steve Chan^{1*}, Chi Fai Kan² and Churk Fai Trevor Li²

*Address all correspondence to: stevewh@gmail.com

1 Hong Kong Sanatorium and Hospital, Hong Kong SAR, China

2 Queen Elizabeth Hospital, Hong Kong SAR, China

References

- [1] Gravas S, Cornu JN, Drake MJ, et al. Non-neurogenic male lower urinary tract symptoms (LUTS), incl. Benign prostatic obstruction (BPO). EAU guidelines. Edn. Presented at the EAU Annual Congress Copenhagen; 2018. ISBN 978-94-92671-01-1
- [2] Mayer EK, Kroeze SGC, Chopra S, Bottle A, Patel A. Examining the 'gold standard': A comparative critical analysis of three decades of monopolar transurethral resection of the prostate (TURP) outcome. *BJU International*. 2012 Dec;**110**(11):1595-1601. DOI: 10.1111/j.1464-410X.2012.11119.x.a
- [3] Rao JM, Yang JR, Ren YX, He J, Ding P, Yang JH. Plasmakinetic enucleation of the prostate versus transvesical open prostatectomy for benign prostatic hyperplasia >80 mL: 12-month follow-up results of a randomized clinical trial. *Urology*. 2013;**82**:176
- [4] Geavlete B, Bulai C, Ene C, Checherita I, Geavlete P. Bipolar vaporization, resection, and Enucleation versus open prostatectomy: Optimal treatment alternatives in large prostate cases? *Journal of Endourology*. 2015;**29**(3):323-331. <http://doi.org/10.1089/end.2014.0493>

- [5] Chen S, Zhu L, Cai J, Zheng Z, Ge R, Wu M, et al. Plasmakinetic enucleation of the prostate compared with open prostatectomy for prostates larger than 100 grams: A randomized noninferiority controlled trial with long-term results at 6 years. *European Urology*. 2014;**66**(2):284-291. <http://doi.org/10.1016/j.eururo.2014.01.010>
- [6] Ou R, Deng X, Yang W, Wei X, Chen H, Xie K. Transurethral enucleation and resection of the prostate vs transvesical prostatectomy for prostate volumes >80 mL: A prospective randomized study. *BJU International*. 2013;**112**(2):239-245. <http://doi.org/10.1111/bju.12181>
- [7] Hiraoka Y. A new method of prostatectomy, transurethral detachment and resection of benign prostatic hyperplasia. *Nihon Ika Daiqaku Zasshi*. 1983 Dec;**50**(6):896-898
- [8] Lin Y, Wu X, Xu A, Ren R, et al. Transurethral enucleation of the prostate versus transvesical open prostatectomy for large benign prostatic hyperplasia: A systematic review and meta-analysis of randomized controlled trials. *World Journal of Urology*. 2016;**34**:1207-1219. DOI: 10.1007/s00345-015-1735-9
- [9] Fraundorfer MR, Gilling PJ. Holmium:YAG laser enucleation of the prostate combined with mechanical morcellation: Preliminary results. *European Urology*; **33**(1):69-72
- [10] Neill MG, Gilling PJ, Kennett KM, Frampton CM, Westenberg AM, Fraundorfer MR, Wilson LC. Randomized trial comparing holmium laser enucleation of prostate with plasmakinetic enucleation of prostate for treatment of benign prostatic hyperplasia. *Urology*. 2006;**68**(5):1020-1024. DOI: 10.1016/j.urology.2006.06.021
- [11] Liu C, Zheng S, Li H, Xu K. Transurethral enucleation and resection of prostate in patients with benign prostatic hyperplasia by plasma kinetics. *Journal of Urology*. 2010;**184**:2440-2445. DOI: 10.106/j.juro.2010.08.037
- [12] Kan CF, Tsu HL, Chiu Y, To HC, Sze B, Chan SWH. A prospective study comparing bipolar endoscopic enucleation of prostate with bipolar transurethral resection in saline for management of symptomatic benign prostatic enlargement larger than 70g in a matched cohort. *International Urology and Nephrology*. 2014;**46**:51-517. DOI: 10.1007/s11255-013-0546-4
- [13] Hirasawa Y, Kato Y, Fujita. Transurethral enucleation with bipolar for benign prostatic hyperplasia: 2-year outcomes and the learning curve of a single surgeon's experience of 603 consecutive patients. *Journal of Endourology*. 2017;**31**(7):679-685. DOI: 10.1089/end.2017.0092
- [14] Geavlete B, Stanescu F, Lacobaie C, Geavlete P. Bipolar plasma enucleation of the prostate vs open prostatectomy in large benign prostatic hyperplasia cases – A medium term, prospective, randomized comparison. *BJU International*. 2013;**111**:793-803. DOI: 10.1111/j.1464-410X.2012.11730.x
- [15] Abou-Taleb A, El-Shaer W, Kandeel W, Gharib T, Elshaer A. Bipolar plamakinetic enucleoresection of the prostate: Our experience with 245 patients for 3 years of follow-up. *Journal of Endourology*. 2017;**31**(3):300-306. DOI: 10.1089/end.2016.0746
- [16] El-Shaer W, Abou-Taleb A, Kandeel W. Transurethral bipolar plasmakinetic vapo-enucleation of the prostate: Is it safe for patients on chronic oral anticoagulants and/or platelet

- aggregation inhibitors? Arab Journal of Urology. 2017;**15**:347-354. <https://doi.org/10.1016/j.aju.2017.09.005>
- [17] Li K, Wang D, Hu C, et al. A novel modification of transurethral enucleation and resection of the prostate in patients with prostate glands larger than 80 ml: Surgical procedures and clinical outcomes. Urology. 2018;**113**:153-159. <http://doi.org/10.1016/j.urology.2017.11.036>
- [18] Cho CL, Leung CLH, Chan WKW, Chu RWH, Law IC. Early post-operative outcome of bipolar transurethral enucleation and resection of the prostate. Hong Kong Medical Journal. 2015;**21**(6):528-535
- [19] Xiong W, Sun M, Ran Q, Chen F, Du Y, Dou K. Learning curve for bipolar transurethral enucleation and resection of the prostate in saline for symptomatic benign prostatic hyperplasia: Experience in the first 100 consecutive patients. Urologia Internationalis. 2013; **90**:68-74. DOI: 10.1159/000343235
- [20] Feng L, Zhang D, Tian Y, Song J. Thulium laser Enucleation versus Plasmakinetic Enucleation of the prostate: A randomized trial of a single center. Journal of Endourology. 2016;**30**(6):665-670. <http://doi.org/10.1089/end.2015.0867>
- [21] Mu XN, Wang SJ, Chen J, Jin XB, Huang ZX, Zhang LY. Bipolar Transurethral Enucleation of Prostate Versus Photoselective Vaporization for Symptomatic Benign Prostatic Hyperplasia (>70 Ml); 2017. pp. 608-612. <http://doi.org/10.4103/1008-682X.178484>
- [22] Nicolle L, Bradley S, Colgan R, Rice JC, Schaeffer A, Hooton T. Clinical Infectious Diseases. 2005;**40**(5):643-654
- [23] Giolianelli R, Gentile B, Albanesi L, Tariciotti P, Mirabile G. Urology. 2015;**86**(2):407-414. <http://dx.doi.org/10.1016/j.urology.2015.03.045>
- [24] Komura K, Inamoto T, Takai T, et al. Incidence of urethral stricture after bipolar transurethral resection of the prostate using TURis: Results from a randomized trial. BJU International. 2015 Apr;**115**(4):644-652. DOI: 10.1111/bju.12831
- [25] Naspro R, Sancha FG, Manica M, et al. From “gold standard” resection to reproducible “future standard” endoscopic enucleation of the prostate: What we know about anatomical enucleation. Minerva Urologica e Nefrologica. 2016 Oct;**69**(5):446-458. DOI: 10.23736/S0393-2249.17.02834-X
- [26] Ran L, He W, Zhu X, Zhou Q, Gou X. Comparison of fluid absorption between transurethral enucleation and transurethral resection for benign prostate hyperplasia. Urologia Internationalis. 2013;**91**:26-30. DOI: 10.1159/000348793
- [27] Feng L, Song J, Zhang D, Tian Y. Evaluation of the learning curve for transurethral plasmakinetic enucleation and resection of prostate using a mentor-based approach. International Brazilian Journal of Urology. 2017;**43**(2):245-255. <http://doi.org/10.1590/S1677-5538.IBJU.2016.0237>
- [28] Tracey JM, Warner JN. Transurethral bipolar Enucleation of the prostate is an effective treatment option for men with urinary retention. Urology. 2016;**87**:166-171. <http://doi.org/10.1016/j.urology.2015.10.011>