

# We are IntechOpen, the world's leading publisher of Open Access books Built by scientists, for scientists

6,900

Open access books available

185,000

International authors and editors

200M

Downloads

Our authors are among the

154

Countries delivered to

TOP 1%

most cited scientists

12.2%

Contributors from top 500 universities



WEB OF SCIENCE™

Selection of our books indexed in the Book Citation Index  
in Web of Science™ Core Collection (BKCI)

Interested in publishing with us?  
Contact [book.department@intechopen.com](mailto:book.department@intechopen.com)

Numbers displayed above are based on latest data collected.  
For more information visit [www.intechopen.com](http://www.intechopen.com)



---

# Masseter Hypertrophy: Toxin Treatment Techniques, Causes of Complications, and Prevention

---

Hsien-Li Peter Peng

Additional information is available at the end of the chapter

<http://dx.doi.org/10.5772/intechopen.79616>

---

## Abstract

Botulinum neurotoxin (BoNT) injection for the correction of masseter muscle hypertrophy is an off-label but increasingly popular procedure, especially in Asians where masseter hypertrophy is a common facial feature. This chapter outlines and organizes the various possible complications of such a procedure and discusses their incidence rates, etiological explanations, and prevention methods. Complications were separated into four main categories: nonmuscular-related, neurotoxin-related, dosage- or injection-level-related, and injection-site-related categories. The ideal dosage and injection location are also described and discussed, with particular emphasis on the injection safe zone, where all injections to the masseter should be made in order to minimize complications and maximize safety.

**Keywords:** masseter hypertrophy, botulinum toxin treatment, complications and treatment, prevention

---

## 1. Introduction

Global consensus on facial beauty in different races shares certain common features, including an oval facial shape and a V-shaped chin and jawline [1, 2]. One of the characteristic features of an Asian face is a square-shaped lower face caused by masseter muscle hypertrophy, making this a popular request for esthetic treatment [3–7]. Since the first report on treating masseter hypertrophy with botulinum neurotoxin (BoNT) was published in 1994 [8], BoNT injections for masseter hypertrophy have become quite popular not just among Asian patients but among Caucasian patients as well [9, 10], despite being an off-label indication.

Generally, the treatment of masseter muscle hypertrophy with BoNT-A is very effective and quite safe, though the possibilities of side effects still exist and are prevalent enough to warrant attention [3, 5, 7, 9–12]. Recently, our group reported the collective data on 680 masseter hypertrophy patients receiving 2036 BoNT-A treatments over a 6-year period [13]. The causes of side effects after masseter toxin injection treatment were organized into four groups and summarized in **Table 1**. Each complication will be discussed separately below.

Category	Etiology/cause	Prevention/treatment	Incidence
Nonmuscular origin			
Bruising	Damaged vessels	Compression after inj.	2.5% [13]
Hematoma (rare)	Trauma to the arteriole or vein	Compression after inj.	N/A
Dizziness	Unknown	Rest	0.9% [12]
Headache	Unknown	Rest	0.58% [13]
Toxin effect-related			
Chewing weakness	Transient muscle weakness	Abates within a week	30% [13]
Temporalis m. hypertrophy	Compensatory m. overactivity	Injection over temporalis m.	N/A
Dosage-level-related			
Poor or no effect	Insufficient dosage/overly superficial inj.	Good inj. Dose/depth/toxin resistance	No effect (0.1%) [13]
Asymmetry	Same dose on different sizes of hypertrophy m.	Adjust dose according to muscular size	N/A
Jowling/sagging	High dosage in elderly patient	Reduce dose, multiple R, inj. lower face depressors (platysma)	0.20% [13]
Paradoxical bulging (muscle bulging during mastication)	Superficial masseter m. fiber overactivity	Inj. over superficial masseter if not abated after 1–2 weeks Prevent inj. deep and superficial m. fibers	0.49% [13]
Injection site-related			
Sunken temporal fossa	Atrophy of the temporalis m. and downward displacement of the temporal and cheek fat pads	Prevent inj. too high Filler injection over temporal area	0.05% [14]
Loss of full smile/asymmetric smile	Inj. too high or anterior, effect on zygomatic major or risorius m.	Inj. in the injection safe zone, and ideally keep 0.5–1 cm from each border of the safe zone Most complications resolve spontaneously after some time	0.15% [13]
Sunken lateral cheeks (infrazygomatic hollow)	Inj. too high, excess dose		0.44% [13]
Difficulty in mouth opening	Inj. too high, effect on lateral pterygoid m.		0.9% [12]
Xerostomia	Inj. too posterior, effect on parotid gland function		6.3% [14]
Neuropraxia (very rare)	Inj. too inferior, damage to marginal mandibular nerve		One case report [15]

**Table 1.** Summary of masseter toxin injection complications.

## **2. Category 1: Nonmuscular-related side effects**

This includes bruising, hematoma, headaches, and dizziness.

### **2.1. Bruising**

Injury of small vessels during injection may cause bruising. Bruising is one of the most common but least severe side effects and usually dissipates in 5–7 days without sequelae. Our study reported a bruising incidence rate of 2.5%.

### **2.2. Hematoma**

The masseter muscle is a relatively thick and strong muscle and is well vascularized. There are four major arteries that supply the upper, middle, lower, and medial parts of the masseter: the external carotid artery, the facial artery, the maxillary artery, and branches of the superficial temporal artery [16]. Needle penetration of these arteries and subsequent failure to apply compression may result in hematomas.

### **2.3. Headache**

Headaches after treatment is of unknown etiology and is also quite rare, with literature usually reporting below 1% (our study reported 0.58%). It may be linked to individual physiological differences, and the same individuals who have suffered from posttreatment headaches are likely to encounter headaches again in the future treatment. Headaches may occur immediately after injection and take about 2–4 days to recover.

## **3. Category 2: Neurotoxin-related side effects**

This includes chewing weakness and temporalis muscle compensatory hypertrophy.

### **3.1. Chewing weakness**

Decreased masticatory force is the most commonly encountered side effect of masseter toxin injection: our study reported a prevalence of 30%. This side effect is caused by BoNT physiology and is perhaps unavoidable in cases where higher dosages are required. Reduction of mastication force starts at around 1–4 weeks after treatment and gradually improves in the following weeks. Mastication force generally returns to pretreatment levels by the 12th week of postinjection [17, 18].

### **3.2. Temporalis muscle hypertrophy**

Since chewing weakness is the most commonly encountered side effect, it is theoretically possible, though not yet reported, for patients to develop compensatory overactivity and hypertrophy of another mastication muscle such as the temporalis muscle.

## 4. Category 3: Dosage- or injection-level-related side effects

This includes poor effect, asymmetricality, jowling, sagging, and paradoxical bulging.

### 4.1. Poor effect or lack of response

Poor effect of treatment is mostly due to insufficient dosage or a superficial placement of the toxin. However, it is also possible (though extremely rare; only one case was reported by our study) for a patient to exhibit a complete lack of response to treatment. The etiology of this may be due to individual immunity to the toxin.

### 4.2. Asymmetry

Asymmetry may occur if the physician fails to recognize the size differences between the left and right masseters before treatment. In many patients, unilateral preference in chewing will result in a bilateral discrepancy in masseter size. It is crucial to keep this in mind when doing pretreatment evaluations, which then allows the physician to adjust the dosage according to the patient's underlying asymmetry.

### 4.3. Worsened jowls or sagging

Worsened jowls is likely due to overly rapid posttreatment masseter atrophy, which results in volume reduction and sagging of the overlying soft tissue envelope [9]. The incidence of this complication is around 0.2% as reported by our study and usually occurs in patients over 40. To prevent this side effect, physicians should reduce the dose and separate treatment into multiple sessions, which will slow down the speed of muscular atrophy and provide enough time for the overlying skin to contract. Additional toxin injection into the platysma muscle may mitigate facial depressor action, making sagging less likely.

### 4.4. Paradoxical bulging

Paradoxical bulging, or masseter bulging during mastication [19], has an incidence rate around 0.49% as reported by our study. Excessive compensation of the untreated superficial layer of the masseter muscle may be a possible explanation for this complication. A recent published study [20] discovered a tendinous structure (deep inferior tendon (DIT)) located in the deeper part of the superficial masseter muscle layer in all cadaver specimens examined. The DIT may block toxin diffusion from the deep layer to the superficial layer; therefore, the superficial layer may be unaffected and prone to overcompensation in the event of masseter weakness [20]. The onset of paradoxical bulging is usually within 24 hours of treatment, and recovery is within 10 days [9]. If recovery has not been achieved within 10–14 days, a booster BoNT injection of about 5–10 units to the untreated superficial layer can usually correct this side effect. Injecting both deep and superficial muscle fibers should prevent this side effect [20].

## **5. Category 4: Injection site-related side effects**

This includes the loss of the full smile, asymmetrical smile, sunken lateral cheeks, difficulty in opening of the mouth, xerostomia, and neuropraxia.

### **5.1. Loss of the full smile**

Also called smile limitation, our study reported incidence rates of about 0.15%. Smile limitation may be due to toxin diffusion into the risorius muscle; in a cadaver study, the risorius attaches to the anterior or middle part of the masseter in more than 97% of cases [21]. Smile limitation usually takes around 1–3 months to recover [9]. Thorough knowledge of muscular anatomy is important to prevent this complication, and the physician should set an injection safe zone at least 1 cm from the anterior border of the masseter and keep to a deep injection level.

### **5.2. Asymmetric smile**

An asymmetric smile may be caused by paralysis of the zygomatic major muscle. This may occur if the physician injects in a position which is too high and too anterior. Keep the injections to the lower, more posterior part of the masseter muscle to avoid this complication.

### **5.3. Sunken lateral cheek**

The sunken lateral cheek, or concave below the zygomatic arch, is caused by over hollowing of the infrazygomatic region resulting from volume loss over the upper parts of the masseter muscle. Our study reports an incidence rate of about 0.44%. Sunken lateral cheeks may be due to a high position of injection and simply keep the injection sites over the lower part of the masseter to prevent it.

### **5.4. Difficulty in opening of the mouth**

Difficulty in opening of the mouth is a rare complication; according to one report, the incidence was 2 out of 220 treated patients [12]. This complication is caused by toxin paralysis of the lateral pterygoid muscles, possibly arising from an injection site that is high and deep enough to reach past the coronoid notch and affect the pterygoid muscle. Another possible etiology may be abnormal activity of the temporomandibular joint. For prevention, the physician should only inject the lower part of masseter muscle and keep at least a centimeter below the upper safety margin of masseter injection.

### **5.5. Sunken temporal fossa**

Sunken temporal fossa is a rare side effect with an incidence of about 0.05%, as reported by a Chinese study in 2017 [22]. This complication is likely from a combination of two etiologies: atrophy of the temporalis muscle as a result of drug dispersion and downward displacement

of the temporal and cheek fat pads as a result of masseter relaxation [22]. This side effect appears about 1 month after treatment.

### **5.6. Xerostomia**

Xerostomia is a complication due to toxin effect on the parotid gland. The reported incidence rate for xerostomia is around 6.3% [14]. Keeping the injection site 1 cm away from the posterior margin of the masseter (thus avoiding the usual location of the parotid gland) can be helpful for the prevention of xerostomia.

### **5.7. Neuropraxia**

Neuropraxia [11] is a very rare complication caused by paralysis of the marginal mandibular nerve. There has only been one case report in which the patient experienced temporary marginal mandibular nerve paralysis. Symptoms improved within 2 weeks [15].

In one cadaver study, the marginal mandibular nerve runs about 0.1–1.0 cm from the mandibular border [23]. Physicians should therefore keep the injection site 1 cm from the lower margin of the masseter.

### **5.8. Neurapraxia**

Neurapraxia is an exceedingly rare complication and is caused by paralysis of the marginal mandibular nerve. There were no cases in the author's two decades of experience with masseter toxin injections.

### **5.9. Other rare complications**

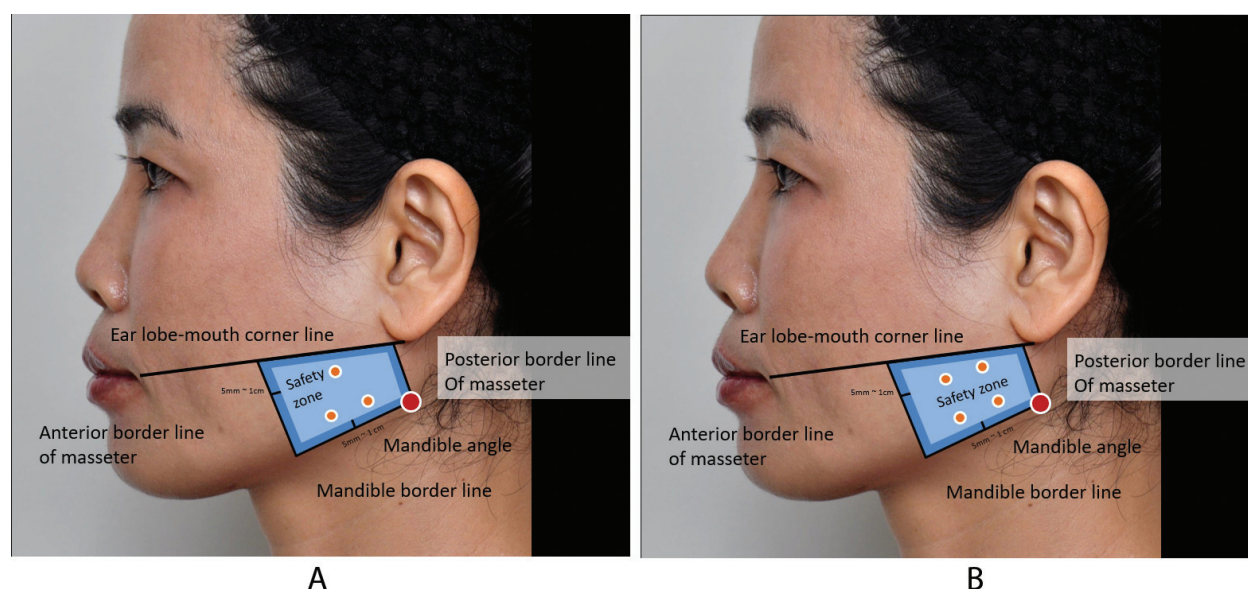
A range of other possible adverse effects may occur but are usually only reported in single case reports. These include speech disturbance, altered gustatory sensation, incidental aggravation of venous malformation, madarosis, facial alopecia, and acute visual loss [4–6, 24–27].

### **5.10. Dosage**

If the anterior to posterior width of the masseter is less than 3–5 cm, inject 20–30 units of onabotulinum toxin per side [28]. This amount may vary slightly by case depending on muscle size and individual needs. Repeated injection could be done every 3–6 months for optimized cosmetic outcome.

## **6. Injection safe zone**

Before injection, physician should mark the anterior, posterior, inferior, and superior borders of the “injection safe zone.” The anterior and posterior borders of the safe zone are the anterior and posterior edges of the masseter muscle, and the inferior border is the inferior edge of the



**Figure 1.** The recommended safety zone for masseter toxin injections is a quadrilateral with its upper border running from mouth corner to earlobe, its anterior and posterior borders the anterior and posterior edges of the masseter muscle, respectively, and its inferior border the inferior edge of the mandible. Injection safe zone, marked in lighter blue, and the ideal injection safe zone of 1cm away from each border, marked in darker blue. The mandible angle marked with large red circle. Suggested injection points mark with small red dot, with 3 points (A) or 4 points injection (B).

mandible. The upper border of safe zone runs from the mouth corner to the earlobe. Keep injections inside the safe zone and ideally in 3–4 different locations at least 0.5–1 cm from each border (Figure 1).

## 7. Conclusion

BoNT-A masseter injections can achieve satisfactory results with mostly mild and infrequent complications. However, adverse effects can still impact patient satisfaction, so an understanding of the regional muscular anatomy, appropriate dosing, injection location, and injection depth are all important aspects to consider when planning and performing treatment. In particular, the injection safety zone should be clearly demarcated by the physician before injection by identification of its four borders: upper border running from the mouth corner to the earlobe, anterior and posterior borders of the anterior and posterior edges of the masseter muscle, respectively, and inferior border of the inferior edge of the mandible. Keeping injections inside the safe zone, and ideally in 3–4 different locations at least 1 cm from any border, is crucial for the prevention of common side effects mentioned above (Figure 1A and B). Physicians should also know about the different characteristics of various complications, their etiological origin, their management, and their prevention.

## Disclosure

Nothing to disclose for this report.

## Author details

Hsien-Li Peter Peng

Address all correspondence to: pengskin@gmail.com

P-Skin Professional Clinic, Kaohsiung, Taiwan

## References

- [1] Rhee SC, Lee SH. Attractive composite face of different faces. *Aesthetic Plastic Surgery*. 2010;**34**:800-801
- [2] Liew S, Wu WTL, Chan HH, et al. Consensus on changing trends, attitudes, and concepts of Asian beauty. *Aesthetic Plastic Surgery*. 2016 April;**40**(2):192-201
- [3] Kim NH, Chung JH, Park RH, Park JB. The use of botulinum toxin type A in aesthetic mandibular contouring. *Plastic and Reconstructive Surgery*. 2005;**115**(3):919-930
- [4] Ahn J, Horn C, Blitzer A. Botulinum toxin for masseter reduction in Asian patients. *Archives of Facial Plastic Surgery*. 2004;**6**(3):188-191
- [5] Park MY, Ahn KY, Jung DS. Botulinum toxin type A treatment for contouring of the lower face. *Dermatologic Surgery*. 2003;**29**(5):477-483
- [6] Kim HJ, Yum KW, Lee SS, Heo MS, Seo K. Effects of botulinum toxin type A on bilateral Masseteric hypertrophy evaluated with computed tomographic measurement. *Dermatologic Surgery*. 2003;**29**(5):484-489
- [7] Choe SW, Cho WI, Lee CK, Seo SJ. Effects of botulinum toxin type A on contouring of the lower face. *Dermatologic Surgery*. 2005;**31**(5):502-508
- [8] Moore AP, Wood GD. The medical management of masseteric hypertrophy with botulinum toxin type A. *The British Journal of Oral and Maxillofacial Surgery*. 1994;**32**(1):26-28
- [9] Liew S, Dart A. Nonsurgical reshaping of the lower face. *Aesthetic Surgery Journal*. 2008 May-Jun;**28**(3):251-257
- [10] Carruthers J, Carruthers A. Botulinum toxin: Procedures in cosmetic dermatology series (chapter 23, 4th ed). Elsevier; **2017**:153-159
- [11] Wu WTL. Botox facial slimming/facial sculpting: The role of botulinum toxin-a in the treatment of hypertrophic Masseteric muscle and parotid enlargement to narrow the lower facial width. *Facial Plastic Surgery Clinics of North America*. 2010;**18**(1):133-140
- [12] Xie Y, Zhou J, Li H, Cheng C, et al. Classification of masseter hypertrophy for tailored botulinum toxin type A treatment. *Plastic and Reconstructive Surgery*. 2014;**134**(2):209e-218e
- [13] Peng HP, Peng JH. Complications of botulinum toxin injection for masseter hypertrophy: Incidence rate from 2036 treatments and summary of causes and preventions. *Journal of Cosmetic Dermatology*. 2018;**17**(1):33-38

- [14] Baş B, Ozan B, Muğlali M, Celebi N. Treatment of masseteric hypertrophy with botulinum toxin: A report of two cases. *Medicina Oral, Patología Oral y Cirugía Bucal*. 2010;**15**(4): e649-e652
- [15] Hu KS, Kim ST, Hur MS, Park JH, et al. Topography of the master muscle in relation to treatment with botulinum toxin type A. *Oral Surgery, Oral Medicine, Oral Pathology, Oral Radiology, and Endodontics*. 2010;**110**(2):167-171
- [16] Won SY, Choi DY, Kwak HH, Kim ST, et al. Topography of the arteries supplying the masseter muscle: Using dissection and Sihler's method. *Clinical Anatomy*. 2012;**25**(3):308-313
- [17] Ahn KY, Kim ST. The change of maximum bite force after botulinum toxin type A injection for treating Masseteric hypertrophy. *Plastic and Reconstructive Surgery* 2007; **120**(6):1662-1666
- [18] Park HU, Kim BI, Kang SM, Kim ST, et al. Changes in masticatory function after injection of botulinum toxin type A to masticatory muscles. *Journal of Oral Rehabilitation*. 2013 Dec;**40**(12):916-922
- [19] Lee SJ, Kang JM, Kim YK, Park J, Kim DY. Paradoxical bulging of muscle after injection of botulinum neurotoxin type A into hypertrophied masseter muscle. *The Journal of Dermatology*. 2012;**39**(9):804-805
- [20] Lee HJ, Kang IW, Seo KK, Choi YJ, et al. The anatomical basis of paradoxical Masseteric bulging after botulinum neurotoxin type A injection. *Toxins (Basel)*. 2017;**9**(1):14
- [21] Bae JH, Choi DY, Lee JG. The Risorius muscle: Anatomic considerations with reference to botulinum neurotoxin injection for Masseteric hypertrophy. *Dermatologic Surgery*. 2014; **40**(12):1334-1339
- [22] Zhang XC, Zhang JJ. Analysis of causes on tempus depression caused by masseter injection of type A Botulinum toxin. *Chinese Journal of Aesthetic Medicine*. Jul 2017;**26**(7):71-72
- [23] Kowing D. Madarosis and facial alopecia presumed secondary to botulinum a toxin injections. *Optometry and Vision Science*. 2005;**82**(7):579-582
- [24] Kim JH, Shin JH, Kim ST, Kim CY. Effects of two different units of botulinum toxin type A evaluated by computed tomography and electromyographic measurements of human masseter muscle. *Plastic and Reconstructive Surgery*. 2007;**119**(2):711-717
- [25] Huang JL, Chen G, Chen XD, Zhou BR, et al. A comparative study of the efficacy and safety of radiofrequency ablation and botulinum toxin a in treating masseteric hypertrophy. *Experimental and Therapeutic Medicine*. 2014;**7**(5):1203-1208
- [26] Choi JH, Park SW, Chung HY, Choi KY, et al. Incidental aggravation of venous malformation after botulinum toxin type A injection for reducing benign Masseteric hypertrophy. *Dermatologic Surgery*. 2010;**36**(Suppl 4):2188-2192
- [27] Chun BY, Kim SY. Acute visual loss after botulinum toxin A injection in the masseter muscle. *International Ophthalmology*. 2017 May 23
- [28] Seo KK. Botulinum toxin for Asians (Chapter 3, 1st ed.). Springer; 2017:107-134

