

We are IntechOpen, the world's leading publisher of Open Access books Built by scientists, for scientists

6,900

Open access books available

185,000

International authors and editors

200M

Downloads

Our authors are among the

154

Countries delivered to

TOP 1%

most cited scientists

12.2%

Contributors from top 500 universities



WEB OF SCIENCE™

Selection of our books indexed in the Book Citation Index
in Web of Science™ Core Collection (BKCI)

Interested in publishing with us?
Contact book.department@intechopen.com

Numbers displayed above are based on latest data collected.
For more information visit www.intechopen.com



Laparoscopic Simple Prostatectomy

Yusuf Ilker Comez

Additional information is available at the end of the chapter

<http://dx.doi.org/10.5772/intechopen.79549>

Abstract

Benign prostatic hyperplasia (BPH) is the most common benign tumor and cause of urinary retention in middle-aged male patients. Transurethral resection of the prostate (TURP) is the gold standard surgical treatment for benign prostatic obstruction. Although widely performed, TURP is associated with significant morbidity. Open prostatectomy is performed in larger glands, which are more than 80 grams, with higher morbidity. Advances in technology, such as holmium laser enucleation of the prostate (HoLEP) and KTP laser vaporization, are other options that are widely used despite their limitations. Laparoscopic simple prostatectomy (LSP) is a minimally invasive treatment option with equivalent functional outcomes and is useful in larger prostatic adenomas, with low morbidity in experienced hands.

Keywords: prostatectomy, adenomectomy, prostatic adenoma, benign prostatic hyperplasia, laparoscopy, minimally invasive, simple prostatectomy

1. Introduction

Benign prostatic hyperplasia (BPH) is the most common benign pathology and cause of urinary retention in middle-aged male patients, and its incidence increases with age.

The International Prostate Symptom Score (IPSS) questionnaire is often used to assess patients of BPH [1]. The treatment depends on the severity of the disease. Conservative approach with watchful waiting and the use of systemic drugs that relaxes the smooth muscles of the prostate and bladder neck, resulting in the decrease in the prostate mass volume, may be preferred in the mild cases. When planning surgery, prostate volume and weight as well as the patients' expectations and associated comorbidities should be taken into account.

In patients with failure or inability to tolerate medical treatment, with urinary retention, renal failure secondary to BPH, urinary infections, bladder calculi, or hematuria, surgical intervention should be preferred [2–5].

Transurethral prostate resection (TURP), simple prostatectomy, and transurethral incision of the prostate (TUIP) have been the main surgical treatment options for benign prostate hyperplasia (BPH) for decades. Although TURP is accepted as the gold standard surgical treatment for benign prostatic obstruction and is widely used in all over the world, it has several limitations such as being insufficient in treating large prostates, risk of perioperative bleeding, postoperative transurethral resection (TUR) syndrome, urethral strictures, and at the same time the risk of reoperation requirement [6].

EAU and AUA guidelines recommend open prostatectomy (OP) for the surgical treatment of patients with prostate volumes larger than 80 ml [7, 8]. The advantages of this technique are lower reoperation rates and better clinical outcomes with more patient satisfaction [9]. However, it has also been associated with the need for perioperative transfusion, prolonged hospital stay, higher reoperation rate, urinary infections, and a large abdominal scar effecting the cosmesis [10–12]. Other rare adverse events as clot retention, contraction in the bladder neck, wound infection, and myocardial infarction may also be encountered [13]. Holmium laser enucleation of the prostate (HoLEP) is used in larger adenomas as an alternative to OP with the advantages such as shorter catheterization and hospital stay. However, the technique is not widely used because of the demanding learning curve, complications, and the need for special equipment [6].

The other laser treatment option as an alternative to OP is the GreenLight® KTP laser vaporization that promised better outcomes for large prostate adenomas with successful results [14]. By this technique surgeons achieved shorter catheterization time and hospital stay with perfect hemostasis [14]. However, the absence of definitive pathological result and lack of long-term results were the obstacles for the widespread use of the technique.

With advancements in the technology, minimal invasive methods such as enucleation of the prostate with holmium laser or laparoscopic simple prostatectomy (LSP) began to show off on stage.

LSP is recently accepted as an alternative to open surgery in patients with large prostate glands. However, it is accepted that learning curve of this technique is steep and time-consuming in order to reach to comparable results to OP [15].

In this chapter the benefits, conflicts, and surgical technique of laparoscopic simple prostatectomy are described with the review of the literature.

2. The surgical technique for simple laparoscopic prostatectomy

The surgical procedures may be performed either in an extraperitoneal or transperitoneal fashion [16–18].

Adenomectomy can be performed transvesically or by retropubic transcapsular (Millin) technique [19].

2.1. Port placement

The laparoscopic simple prostatectomy begins with placement of the trocars either transperitoneally or extraperitoneally [19, 20].

Intubation and nasogastric decompression are applied at supine position. The bladder emptying is performed after insertion of 22-F Foley catheter. Afterward, the spread of the legs to 30° at Trendelenburg position is performed. Both arms are fixed adjacent to the body (**Figure 1A**).

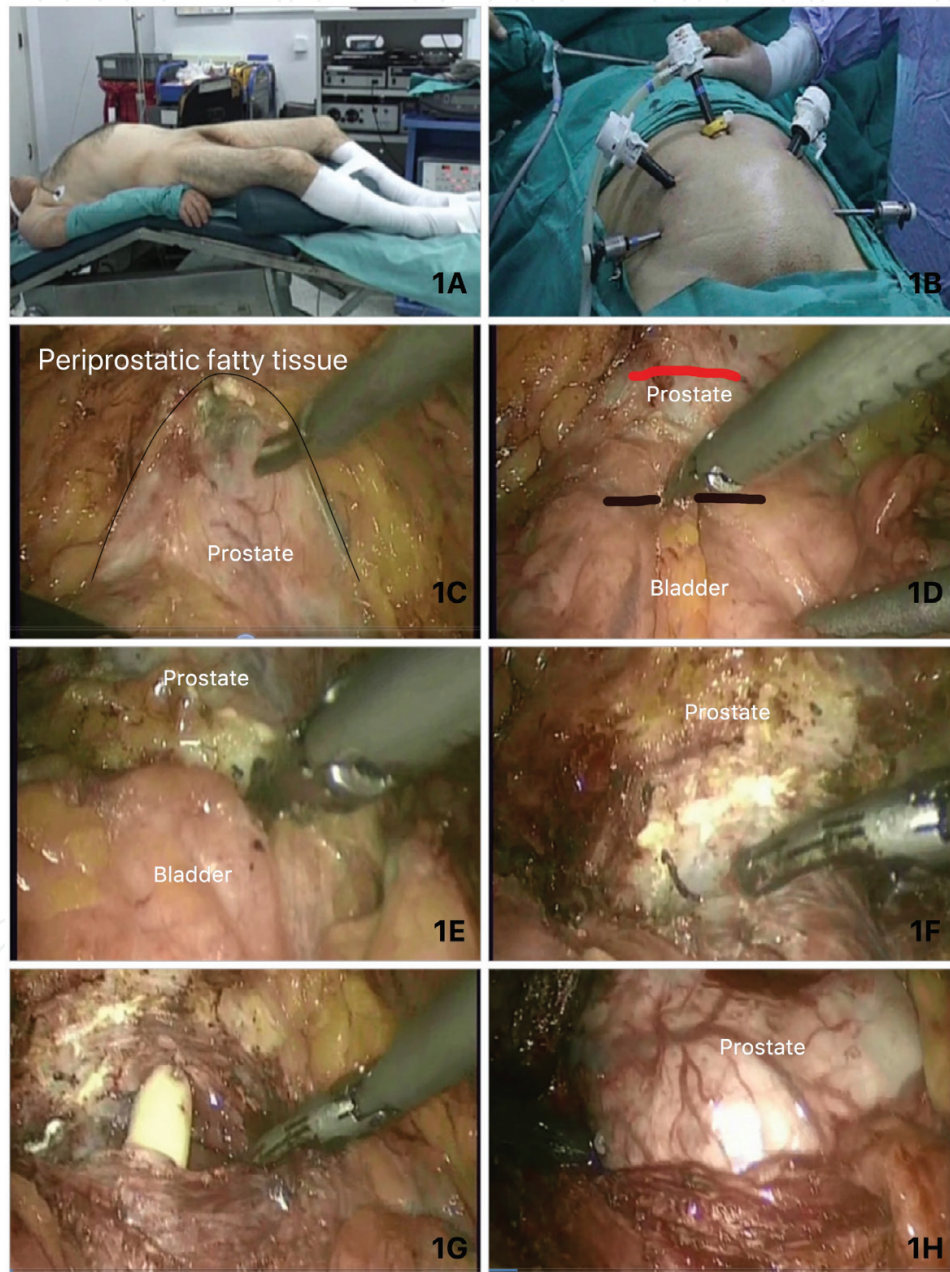


Figure 1. (A) The position of the patient for LSP; (B) the port placement for LSP; (C) the defatting the tissue over the prostate capsule; (D) black line shows the incision 1-cm proximal to the prostatovesical junction in transvesical approach; the red line depicts the ventral incision over prostate in retropubic transvesical Millin technique; (E) dissection of the detrusor with harmonic scissors; (F) widening the incision to see both orifices and prostate; (G) intravesical part of the Foley catheter is seen; and (H) the intravesical portion of the prostate can easily be pulled out of the fossa.

2.1.1. *The extraperitoneal approach*

The extraperitoneal approach involves making a 30-mm infraumbilical incision and dissecting down to the anterior rectus fascia. This fascia is incised 30 mm transversely, and after demonstrating the linea alba and rectus muscles, the bellies of the rectus are separated bluntly in the midline. Finger dissection is carried out between the rectus muscle and the peritoneum to form the preperitoneal space, taking care to avoid incidental peritonotomy by applying anterior pressure inferiorly when the posterior rectus fascia disappears below the arcuate line. Linea alba is incised adjacent to symphysis pubis inferiorly. A 12-mm balloon dissector with 10-mm visual optical channel is placed to the preperitoneal space superior to the bladder and the prostate. Anterior rectus fascia defect, near to the port, is closed. Subcutaneous and cutaneous sutures are performed with No.1 silk sutures to avoid gas leakage. The balloon is slowly inflated under direct visualization in the retroperitoneum. In the correct plane, the inferior epigastric vessels are visible ventrally helping to avoid incidental vascular damage. The balloon is deflated, the 10-mm trocar and a 0-degree optical lens are inserted, and the space is inflated with 10–15 mmHg of CO₂. Four additional trocars are inserted under direct visualization. Two 10-mm trocars are placed lateral to the rectus muscle over the line between anterior superior iliac spine and the umbilicus, and two 5-mm trocars are placed 2 cm medial to the anterior superior iliac spines (**Figure 1B**).

2.1.2. *The transperitoneal approach*

The transperitoneal approach is performed with the Trendelenburg position as described previously. A 2-mm incision below the umbilicus is performed. After reaching the rectus fascia, Veress needle is inserted in the peritoneum carefully. After forming pneumoperitoneum, a 10-mm port is replaced with 2-cm port inferior to the umbilicus in the midline between the rectus muscles. The other ports are replaced under direct visualization similar to the retroperitoneal approach. As we reach to the bladder, the peritoneum is incised ventrally to the bladder. By the caudal dissection via peritoneal incision, Retzius space is reached. The next steps of the surgery are similar either extraperitoneal or transperitoneal. As we reach the Retzius space, defatting the tissue over the prostate for better visualization of the prostate and bladder neck is provided (**Figure 1C**).

2.2. **The techniques of dissection**

2.2.1. *The transvesical dissection technique*

The bladder is filled with 200 cc saline. Therefore, careful manipulation of the bladder helps to identify prostatic lobes from the softer bladder wall. If transvesical approach is chosen, a transverse incision is done 2 cm proximally to the prostatovesical junction with harmonic scissors (**Figure 1D**). After transverse cystostomy, one may widen the incision laterally (**Figure 1F**), until the large adenoma can be seen clearly (**Figure 1H**). A grasper can also be used for anterior elevation of the median lobe to see the bladder lumen and orifices clearly (**Figure 2A**). Afterward, the Foley catheter is pulled out, and metal bugi is replaced to lift the prostate superiorly. Adequate vision allows the dissection of the adenoma through a transverse incision distal to the trigone (**Figure 2B and C**). The bladder neck is well perfused, and the use of harmonic scissors may be useful to prevent bleeding. Suction and posterior traction by the assistant are

mandatory. The subcapsular plane can be identified by leaving prostatic capsule posteriorly and elevating the adenoma out of the fossa. In the subcapsular plane, the aspirator is used for blunt dissection, while sharp dissections are made with harmonic scissor (**Figure 2D**). Prostatic tissue is liberated from 6-o'clock to 12-o'clock position in both sides (**Figure 2E and F**). In this stage of surgery, the use of suction and harmonic scissors may prevent vision difficulty due to bleeding (**Figure 2G and H**). Minor bleedings may be ignored. The pneumoperitoneum may

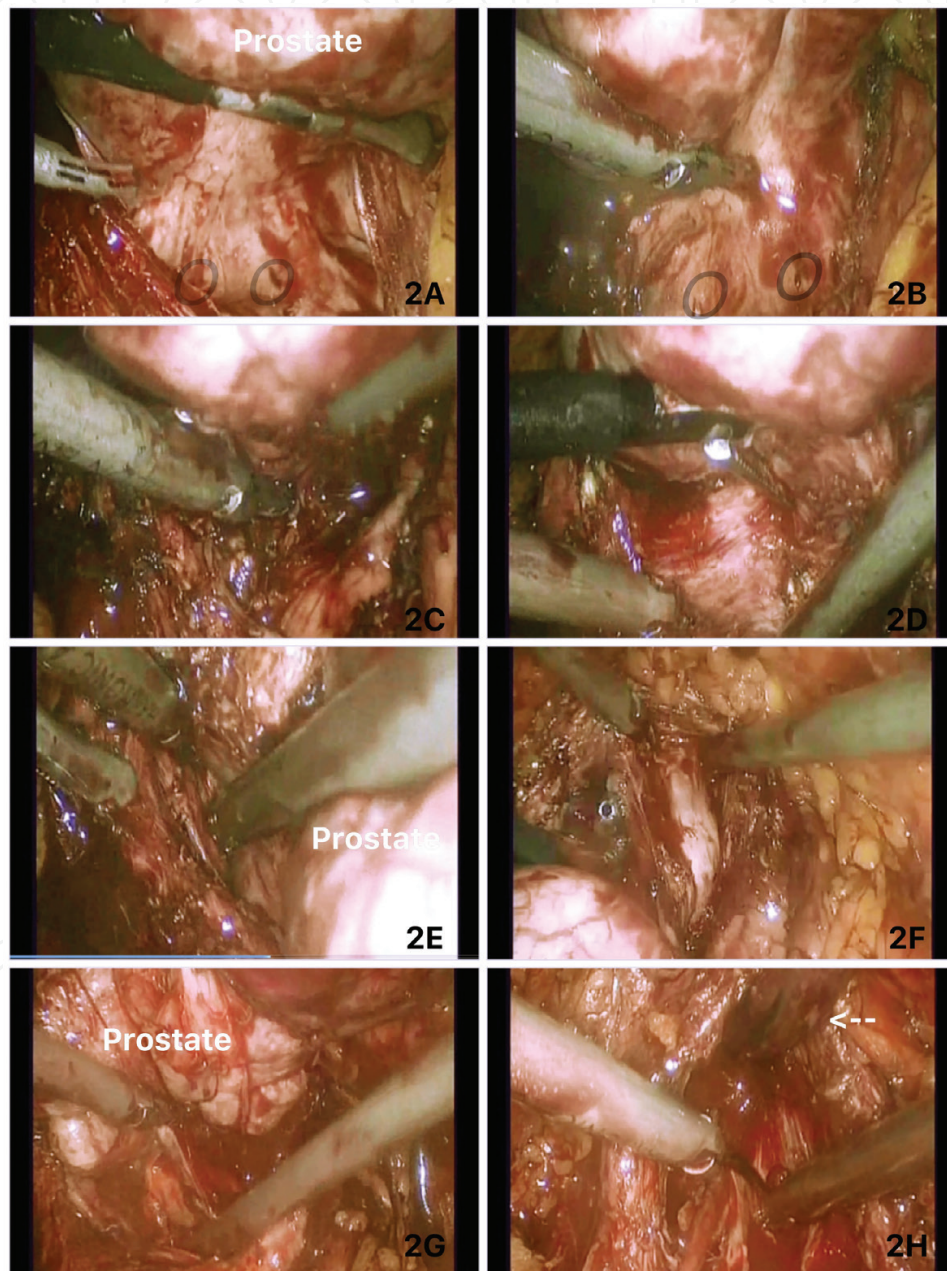


Figure 2. (A) a grasper can also be used for anterior elevation of the median lobe to see the bladder lumen and orifices clearly. Both orifices are shown in a black circle; (B) the harmonic dissection of the adenoma through a transverse incision distal to the trigone to enter the subcapsular space; (C) releasing the adenoma; (E) dissection to separate left side of the adenoma from the capsule. A grasper helps for traction while blunt and sharp dissections are held with harmonic scissors; (F) dissection of the anterior part of the right lobe; and (G and H) the releasing of the last posterior adhesions with the help of the superior adenoma lifting.

facilitate better vision (**Figure 3A**). In extremely large prostates, it may be required to resect the median lobe priorly. The anterior plane is then approached and followed caudally. The extent of the resection begins proximally from the bladder neck, distally to the verumontanum. Care must be given not to injure the urethra and the sphincter (**Figure 3B**). The adenoma is enucleated and placed into a specimen bag (**Figure 3C**). If the adenoma is extremely large, it may be cut into small pieces by endoscissors and put in the specimen bag to secure.

Once the adenoma is enucleated, the pneumoperitoneum provides better visualization of arterial capsular bleeders that can be controlled with harmonic scissors. If bladder neck bleedings originate from the intravesical pedicle, ligation with V-loc hemostatic sutures or placement of M-knots with a 3-0 Vicryl can be used. Trigonization is described as plication of the bladder neck over the posterior capsule and performed in an interrupted fashion with 2-0 monocryl sutures (**Figure 3D and E**). The aim of this technique is to ensure the passage of the Foley catheter from the urethra into the bladder. Urethrovesical anastomosis has been proposed to ensure apposition of the bladder neck to urethral mucosa while helping the hemostasis and allegedly decreasing bladder neck contracture rates [21].

At the end of the hemostasis and trigonization, 22-F Foley catheter is replaced to the bladder, and cystostomy is closed with 2-0 Vicryl with interrupted sutures (van Velthoven technique) (**Figure 3F and G**) [22]. After closing the cystectomy, the balloon is filled with 30-ml saline, and urinary leakage is controlled by filling the bladder (**Figure 3H**). A Jackson Pratt drain is replaced to the Retzius space. Specimen is taken out from the port below the umbilicus.

2.2.2. Laparoscopic transcapsular (Millin) technique

The retropubic approach can be done utilizing several incisions. Transverse anterior prostatic, longitudinal anterior prostatic incisions and longitudinal prostatovesical and transverse incision just proximal to the prostatovesical junction are some of the choices. Sotelo et al. described their technique as they use the transverse incision adjacent to the prostatovesical junction. This technique avoids bleeding of the venous plexus. The other recommendation of Sotelo et al. is resection of the adenoma as separate lobes for improved visualization [21]. The use of suprapubic hand port is another modified technique. The hand port usage improves the speed of resection and provides hemostatic control [22].

The superiority of the transvesical technique over transcapsular (Millin) technique is identifying the intravesical median lob and allowing the dissection without injuring the orifices.

Regardless of the type of dissection chosen, the bladder irrigation for 24 h and urethral catheterization for 3–4 days are adequate postoperatively.

2.3. Complications

A complete cardiovascular workup should be performed during patient selection and surgical planning. Major complications are incontinence, bleeding, and cardiac complications. They account for much of the morbidity and mortality.

Patients should be screened for prostate cancer before undergoing surgery. The incidental prostate cancer rates may increase up to 10% of specimens in larger series [16, 23–30].

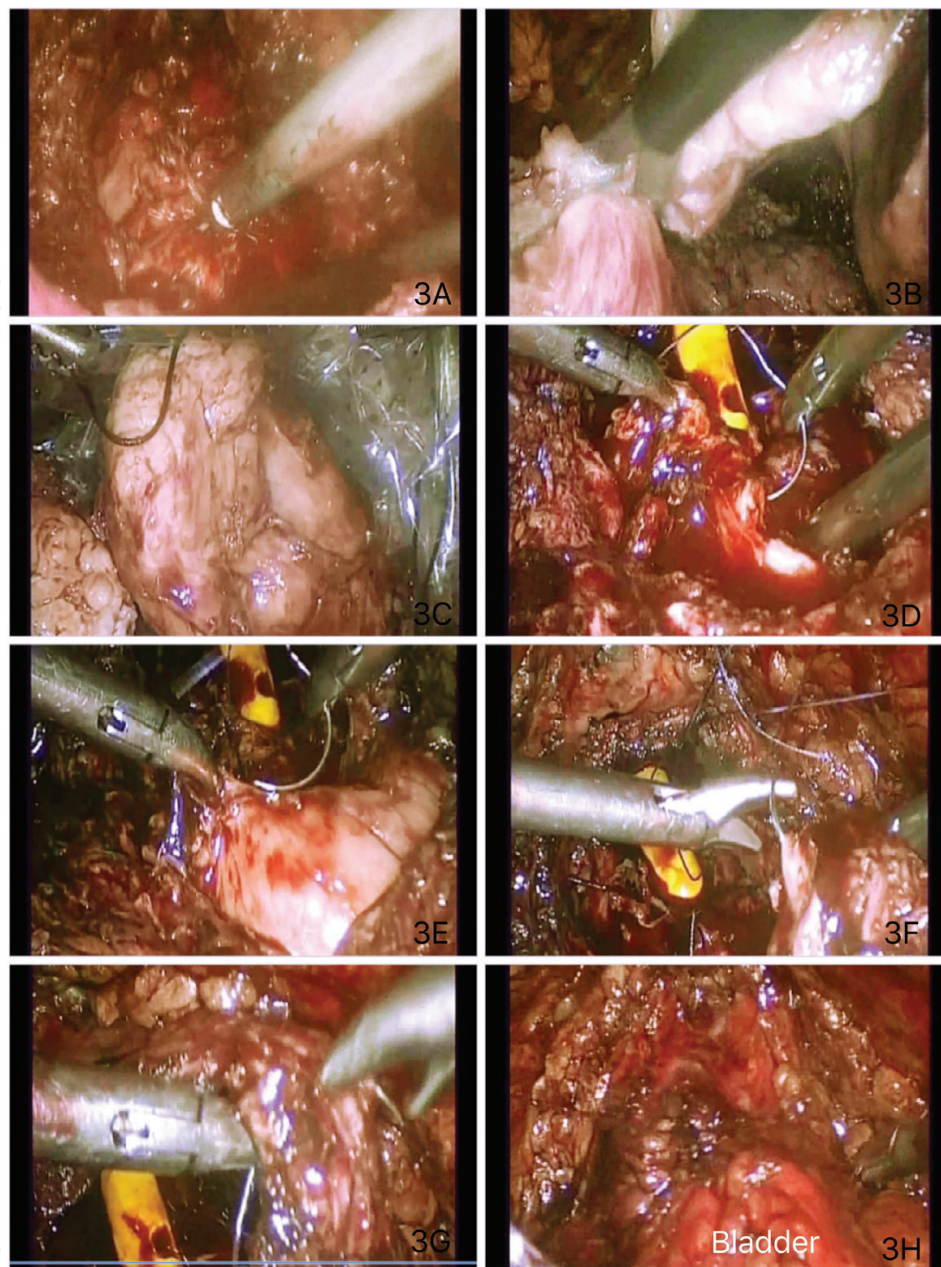


Figure 3. (A) The residual bleedings at the fossa are controlled by harmonic scissors; (B) the last adhesions are separated by endoscissors; (C) the adenoma is placed in the endobag; (D) the bleedings at the fossa are controlled with 3/0 Vicryl or V-loc hemostatic sutures; (E) trigonization is performed with plication of the bladder neck over the posterior capsule and facilitated in an interrupted fashion with 2-0 monocryl; (F and G) after 22-F Foley catheter is replaced to the bladder, cystostomy is closed with 2/0 Vicryl interrupted sutures; and (H) the bladder is finally filled with 200-ml saline in order to see if there is any leakage.

3. Discussion

Schuessler performed first laparoscopic radical prostatectomy in 1991 [31]. In 2002 Mariano et al. and in 2005 Sotelo et al. also performed laparoscopic simple prostatectomy for BPH [20, 21]. Mariano et al. reported first results of laparoscopic prostatectomy in 60 BPH patients with mean prostate weight of 144.50 ± 41.74 g. The mean operation time was 138.48 ± 23.38 min

with blood loss of 330.98 ± 149.52 mL and without any postoperative urinary incontinence [20]. Sotelo and van Velthoven et al., with minor modifications with the surgical technique, reported similar successful results without postoperative complications [21, 22].

Although initial results are encouraging, and its benefits including less blood loss and shorter hospital stay are better than the open surgery, there are very limited studies in the literature comparing the results of LSP with open prostatectomy [23, 32–34]. Most studies report the results of the small case series of LSP with different surgical approaches such as extraperitoneal, transperitoneal, transcapsular, or finger-assisted approaches [19–22, 31, 35–37]. In the literature, the results of extraperitoneal or transperitoneal techniques are reported to be similar without any superiority to the other [16–18].

Hoepffner et al., in their study with the biggest series published, reported 100 patients' results with mean prostate weight of 97.1 ± 18.5 g, mean operation time 66.3 ± 12.3 min with blood loss of 250 ± 86.8 ml without the need of blood transfusion with mean hospital stay of 4.2 ± 1.3 days and mean catheterization time of 3.2 ± 1 days [38]. Oktay et al. reported the results of 16 LSP patients with the biggest prostate weight, 147 g (between 80 and 200 g), mean operation time 133 min (75–210 min), mean blood loss 134 ml (50–300 ml) requiring one transfusion, hospital stay 3.9 days (2–7 days), and catheterization duration of 6.3 (6–7) days [39].

Chlosta et al., in their series of 66 patients, reported surgery time of 55 (45–85) minutes as the shortest surgery time and similar results for blood loss, hospital stay, and catheterization time [40].

There are four studies comparing the results of LSP with open prostatectomy. Three studies with small number of patients reported less blood loss [23, 32, 33], less hospitalization time [17, 18, 20], and less catheterization time [32–34]. One study with bigger number of patients, by McCullough et al., compared the results of 96 LSP patients with 184 open prostatectomy patients and found no statistically significant difference in blood loss (350 vs. 400 ml) and in prostate volume (111.3 vs. 117.2 g) between two techniques; however, statistically significant differences were found in terms of hospitalization time (6.3 vs. 7.7 days) ($p < 0.001$) and catheterization time (5.2 vs. 6.4 days) ($p < 0.001$) [34].

Porpiglia et al. reported statistically significant difference in blood loss between two techniques. Although the operation time, hospitalization, and catheterization time were longer in LSP than in the open prostatectomy, no significant differences are reported [23].

4. Conclusion

Simple prostatectomy although is still the treatment of choice in larger prostates and may be performed effectively via several techniques, newer technologies offer minimally invasive techniques for both patients and surgeons. If patients are able to reach or purchase, the outcomes may increasingly be better. It is obvious that LSP has as steep learning curve comparable to open prostatectomy but is a minimally invasive surgery and has satisfying results in larger prostates with low morbidity and hospital stay in the hand of experienced surgeons. Our goal is the final outcome of improved LUTS and decreasing residual volume while minimizing the cost and the complications.

Acknowledgements

I would like to express my special thanks to Prof. Dr. Hakan Vuruskan and Dr. Kadir Omur Gunseren for sharing their surgical photos.

Conflict of interest

No conflict of interest.

Author details

Yusuf Ilker Comez

Address all correspondence to: icomez@hotmail.com

Canakkale Government Hospital, Department of Urology, Canakkale, Turkey

References

- [1] Barry MJ, Fowler FJ Jr, O'Leary MP, et al. The American Urological Association symptom index for benign prostatic hyperplasia. The Measurement Committee of the American Urological Association. *Journal of Urology*. 1992;**148**:1549-1557
- [2] Sarma AV, Jacobson DJ, McGree ME, Roberts RO, Lieber MM, Jacobsen SJ. A population based study of incidence and treatment of benign prostatic hyperplasia among residents of Olmsted County, Minnesota: 1987 to 1997. *The Journal of Urology*. 2005;**173**:2048-2053
- [3] McVary KT, Roehrborn CG, Avins AL, Barry MJ, Bruskewitz RC, Donnell RF, Foster HE Jr, Gonzalez CM, Kaplan SA, Penson DF, Ulchaker JC, Wei JT. Update on AUA guideline on the management of benign prostatic hyperplasia. *The Journal of Urology*. 2011;**185**:1793-1803
- [4] de la Rosette JJ, Alivizatos G, Madersbacher S, Perachino M, Thomas D, Desgrandchamps F, de Wildt M, European Association of Urology. EAU guidelines on benign prostatic hyperplasia (BPH). *European Urology*. 2001;**40**:256-263. DOI: 10.1159/000049784
- [5] Parsons JK, Wilt TJ, Wang PY, Barrett-Connor E, Bauer DC, Marshall LM, Osteoporotic Fractures in Men Research Group. Progression of lower urinary tract symptoms in older men: A community based study. *The Journal of Urology*. 2010;**183**:1915-1920
- [6] Reich O, Gratzke C, Stief CG. Techniques and long-term results of surgical procedures for BPH. *European Urology*. 2006;**49**:970-978
- [7] http://www.uroweb.org/index.php?structure_id=140#EAU_guidelines_online

- [8] <http://www.auanet.org/guidelines/>
- [9] Asimakopoulos AD, Mugnier C, Hoepffner J, Lopez L, Re D, Gaston R, Piechaud T Laparoscopic treatment of benign prostatic hyperplasia (BPH): Overview of the current techniques. *BJU International*. 2011;**107**:1168-1182. DOI: 10.1111/j.1464-410X.2011.10157.x
- [10] Serretta V, Morgia G, Fondacaro L, Curto G, Lobianco A, Pirritano D, Melloni D, Orestano F, Motta M, Pavone-Macaluso M, Members of the Sicilian-Calabrian Society of Urology. Open prostatectomy for benign prostatic enlargement in southern Europe in the late 1990s: A contemporary series of 1800 interventions. *Urology*. 2002;**60**(4):623-627
- [11] Gratzke C, Schlenker B, Seitz M, Karl A, Hermanek P, Lack N, Stief CG, Reich O. Complications and early postoperative outcome after open prostatectomy in patients with benign prostatic enlargement: Results of a prospective multicenter study. *The Journal of Urology*. 2007;**177**(4):1419-1422
- [12] Suer E, Gokce I, Yaman O, Anafarta K, Göğüş O. Open prostatectomy is still a valid option for large prostates: A high-volume, single-center experience. *Urology*. 2008;**72**(1):90-94
- [13] Zargooshi J. Open prostatectomy for benign prostate hyperplasia: Short-term outcome in 3000 consecutive patients. *Prostate Cancer and Prostatic Diseases*. 2007;**10**:374-377
- [14] Tugcu V, Tasci AI, Sahin S, Ordekci Y, Karakas OF, Zorluoglu F. Outcomes of 80 W KTP laser vaporization of the large prostate. *Urologia Internationalis* 2007;**79**:316-320
- [15] Gunsren KO, Kordan Y, Vuruskan H. Laparoscopic simple prostatectomy. *Bulletin of Urooncology*. 2014;**13**:215-222. DOI: 10.4274/uob.174
- [16] Yuh B, Laungani R, Perlmutter A, Eun D, Peabody JO, Mohler JL, Stricker H, Guru KA. Robot-assisted Millin's retropubic prostatectomy: Case series. *The Canadian Journal of Urology*. 2008;**15**(3):4101-4105
- [17] Stolzenburg J, Kallidonis P, Qazi H, Ho Thi P, Dietel A, Liatsikos EN, Do M. Extraperitoneal approach for robotic-assisted simple prostatectomy. *Urology*. 2014;**84**:1099-1105
- [18] Patel M, Hemal A. Robot-assisted laparoscopic simple anatomic prostatectomy. *The Urologic Clinics of North America*. 2014;**41**:485-492
- [19] Rehman J, Khan SA, Sukkarieh T, Chughtai B, Waltzer WC. Extraperitoneal laparoscopic prostatectomy (adenomectomy) for obstructing benign prostatic hyperplasia: Transvesical and transcapsular (Millin) techniques. *Journal of Endourology*. 2005;**19**:491-496
- [20] Mariano MB, Graziottin TM, Tefilli MV. Laparoscopic prostatectomy with vascular control for benign prostatic hyperplasia. *The Journal of Urology*. 2002;**167**:2528-2529
- [21] Sotelo R, Spaliviero M, Garcia-Segui A, Hasan W, Novoa J, Desai MM, Kaouk JH, Gill IS. Laparoscopic retropubic simple prostatectomy. *The Journal of Urology*. 2005;**173**:757-760

- [22] van Velthoven R, Peltier A, Laguna MP, Piechaud T. Laparoscopic extraperitoneal adenomec-tomy (Millin): Pilot study on feasibility. *European Urology*. 2004;**45**:103-109 discussion 109
- [23] Porpiglia F, Terrone C, Renard J, Grande S, Musso F, Cossu M, Vacca F, Scarpa RM. Transcapsular adenomec-tomy (Millin): A comparative study, extraperitoneal laparos-copy versus open surgery. *European Urology*. 2006;**49**:120-126
- [24] Ellis WJ, Wright JL. Complications of simple prostatectomy. In: Taneja SS, editor. *Complications of Urologic Surgery: Prevention and Management*. 4th ed. Elsevier; 2010. p. 497-501. <https://doi.org/10.1016/B978-1-4160-4572-4.X0001-5>
- [25] Lucca I, Shariat SF, Hofbauer SL, Klatte T. Outcomes of minimally invasive simple prostatectomy for benign prostatic hyperplasia: A systematic review and meta-analysis. *World Journal of Urology*. 2015;**33**(4):563-570
- [26] Matei DV, Brescia A, Mazzoleni F, Spinelli M, Musi G, Melegari S, Galasso G, Detti S, de Cobelli O. Robot-assisted simple prostatectomy (RASP): Does it make sense? *BJU International*. 2012;**110**(11 Pt C):E972-E979
- [27] Ou R, You M, Tang P, Chen H, Deng X, Xie K. A randomized trial of transvesical pros-tatectomy versus transurethral resection of the prostate for prostate greater than 80 mL. *Urology*. 2010;**76**(4):958-961
- [28] Parsons JK, Rangarajan SS, Palazzi K, Chang D. A national, comparative analysis of peri-operative outcomes of open and minimally invasive simple prostatectomy. *Journal of Endourology*. 2015;**29**(8):919-924
- [29] Tubaro A, Carter S, Hind A, Vicentini C, Miano L. A prospective study of the safety and efficacy of suprapubic transvesical prostatectomy in patients with benign prostatic hyperplasia. *The Journal of Urology*. 2001;**166**(1):172-176
- [30] Varkarakis I, Kyriakakis Z, Delis A, Protogerou V, Deliveliotis C. Long-term results of open transvesical prostatectomy from a contemporary series of patients. *Urology*. 2004;**64**(2):306-310
- [31] Schuessler WW, Schulam PG, Clayman RV, Kavoussi LR. Laparoscopic radical prosta-tectomy: Initial short-term experience. *Urology*. 1997;**50**(6):854-857
- [32] Baumert H, Ballaro A, Dugardin F, Kaisary AV. Laparoscopic versus open simple prosta-tectomy: A comparative study. *The Journal of Urology*. 2006;**175**:1691-1694.24
- [33] García-Segui A, Gascón-Mir M. Comparative study between laparoscopic extraperito-neal and open adenomec-tomy. *Actas Urológicas Españolas*. 2012;**36**:110-116, 25
- [34] McCullough TC, Heldwein FL, Soon SJ, Galiano M, Barret E, Cathelineau X, Prapotnich D, Vallancien G, Rozet F. Laparoscopic versus open simple prostatectomy: An evaluation of morbidity. *Journal of Endourology*. 2009;**23**:129-133
- [35] Nadler RB, Blunt LW Jr, User HM, Vallancien G. Preperitoneal laparoscopic simple pros-tatectomy. *Urology*. 2004;**63**:778-779

- [36] Rey D, Ducarme G, Hoepffner JL, Staerman F. Laparoscopic adenectomy: A novel technique for managing benign prostatic hyperplasia. *BJU International*. 2005;**95**:676-678
- [37] Mariano MB, Tefilli MV, Graziottin TM, Morales CM, Goldraich IH. Laparoscopic prostatectomy for benign prostatic hyperplasia—A six-year experience. *European Urology*. 2006;**49**:127-131. discussion 131-2
- [38] Hoepffner JL, Gaston R, Piechaud T, Rey D. Finger assisted laparoscopic retropubic prostatectomy (Millin). *European Urology Supplements*. 2006;**5**:962-967
- [39] Oktay B, Vuruskan H, Koc G, Danisoglu ME, Kordan Y. Single-port extraperitoneal transvesical adenomectomy: Initial operative experience. *Urologia Internationalis*. 2010; **85**:131-134
- [40] Chlosto PL, Varkarakis IM, Drewa T, Dobruch J, Jaskulski J, Antoniewicz AA, Borówka A. Extraperitoneal laparoscopic Millin prostatectomy using finger enucleation. *The Journal of Urology*. 2011;**186**:873-876