

We are IntechOpen, the world's leading publisher of Open Access books Built by scientists, for scientists

6,900

Open access books available

185,000

International authors and editors

200M

Downloads

Our authors are among the

154

Countries delivered to

TOP 1%

most cited scientists

12.2%

Contributors from top 500 universities



WEB OF SCIENCE™

Selection of our books indexed in the Book Citation Index
in Web of Science™ Core Collection (BKCI)

Interested in publishing with us?
Contact book.department@intechopen.com

Numbers displayed above are based on latest data collected.
For more information visit www.intechopen.com



The Periodontal-Endodontic Relationship, What Do We Know?

Kai Ling Siew, Victor Goh, Chui Ling Goo,
Esmonde Francis Corbet and Wai Keung Leung

Additional information is available at the end of the chapter

<http://dx.doi.org/10.5772/intechopen.78664>

Abstract

Diagnosis and management of periodontal-endodontic lesions are often complicated by the close interrelationship between periodontal tissues and dental pulps. Communications between both biological entities may occur through the apical foramen, accessory canals or exposed dentinal tubules, allowing bi-directional spread of infection and/or inflammation. Endodontic and periodontal lesions may occur distinctly or in tandem. Infected pulps may provoke an inflammatory response in adjoining periodontal tissues, and induce tissue destruction, and likewise, periodontal infection may elicit progressive pulpal pathoses. Solely periodontal or solely endodontic lesions are often clinically recognizable as distinct pathologies. However reported pain from pulpal or periodontal tissues may be similar, especially in combined lesions in which both endodontic and periodontal infection co-exist. When combined lesions develop, signs and symptoms such as toothache, tooth mobility, increased probing pocket depths and localized swelling may develop concurrently. As such, appropriate diagnostic tests and detailed clinical examination are required to differentiate periodontal, endodontic and combined pathologies and to arrive at correct diagnoses. Successful treatment outcomes for any periodontal and/or endodontic lesion depend on correct diagnosis and timely implementation of appropriate therapies. In this chapter, available evidence on periodontal-endodontic lesions will be reviewed with classification, clinical presentations, prognoses and treatment modalities discussed collectively.

Keywords: diagnosis, oral disease, endodontics, periodontal diseases, periodontics

1. Introduction

The close inter-relationship between the periodontium and root canal systems has resulted in concomitant lesions from both entities, leading to periodontal-endodontic (perio-endo) infections that, to date, remain a challenge for the dental professional to both diagnose and manage. An in-depth understanding of the anatomy and disease pathogenesis is of utmost importance in assisting clinicians to establish a prognosis, derive a rational treatment plan and troubleshoot complicated cases grounded on sound biological and clinical bases. In this chapter, evidence-based and contemporary approaches to managing periodontal and/or endodontic lesions will be discussed collectively.

2. Relationship between the periodontium and root canal systems

2.1. Influence of pulpal pathologies on the periodontium

Periodontal disease is an inflammatory disease of the tooth supporting structures initiated by bacteria that form a biofilm on the tooth/root surfaces [1]. Root canal infections (i.e. apical periodontitis) are multi-microbial, biofilm-associated diseases [2, 3]. Apical ramifications, lateral canals, and isthmuses connecting main root canals may harbor biofilm-like microbial structures [2]. The communications between the pulp and the periodontium occur primarily through: exposed dentinal tubules, small portal of exits - e.g. accessory canals and lateral canals - and via the apical foramen [4, 5]. As such, it is unsurprising that pathogens infecting the periodontium and root canal systems are highly similar, indicative of an inseparable relationship between the root canal system and the periodontium [6].

In chronic apical abscesses caused by endodontic infections, a localized collection of pus with a draining sinus may track through the periodontium, forming a deep, narrow and isolated periodontal pocket, adjacent to, or alongside, the gingival sulcus. For molars or multi-rooted teeth, radiographic examination may reveal a radiolucent area at the furcation of an infected tooth, indicating presence of accessory canals which drain into the furcation area [4].

Jansson et al. [7] reported that teeth in periodontitis-prone patients lost more attachment when a continuous root canal infection was present compared to teeth with no periapical lesions. Such findings were also observed by Ehnevid et al. [8] who concluded that a root-canal infection, if left untreated, may impair periodontal healing following non-surgical periodontal therapy. When the pulp is the source of infection, considerations should be given towards treating the endodontic infections prior to periodontal treatment [5, 9]. Such an approach is aimed at eliminating the source of pulpal infection prior to periodontal therapy, as root instrumentation may remove the protective cementum layer [10] and communicate residual infection through exposed dentinal tubules or accessory canals [11, 12].

2.2. Influence of periodontal inflammation on the pulp

An inflamed periodontium resulting from a periodontal infection may affect the vitality of the pulp. Seltzer and Bender [13], reported that periodontal lesions could potentially infect

the pulp through numerous lateral and accessory canals in the furcation area. The authors found that 79% of periodontally involved teeth, without caries and restorations, exhibited histological evidence of pulpal pathology. In periodontal disease affected teeth, localized pulpal necrosis adjacent to accessory canals was found [13].

Langeland et al. [14] reported that the effect of periodontal disease on the pulp was degenerative in nature, resulting in pulpal inflammation, calcifications and resorption. Such insults from periodontal disease to the pulp were cumulative over time [14]. Similarly, Wan et al. [15] reported that the severity of periodontitis had substantial effect on pulpal health. They speculated that denuded root surfaces could induce more pathological changes within the pulp [15]. Root surfaces may be denuded of the protective cementum layer as a result of periodontal treatment [16], developmental defects [17] or even due to direct bacterial invasion [18]. Denuded surfaces are thought to allow passage of microorganisms between the pulp and periodontal tissues through patent dentinal tubules, lateral or accessory canals [18]. Furthermore, if the microvasculature of the apical foramen remains intact, the pulp may maintain its vitality [14].

2.3. Communications between the periodontium and dental pulp

The dental pulp and periodontium are closely related both anatomically and functionally, through three different channels of communication – as discussed below.

2.3.1. Apical foramen

The root canal system is a complicated system with the apical foramen as the principal route of communication between the pulp and the periodontium. A single apical foramen is the exception rather than the rule. Multiple foramina, fins, deltas, loops, and furcations are usually present at the apical end of the root canal [19]. Bacteria, bacterial toxins, inflammatory by-products and mediators pass readily through the apical foramen into the root canal eliciting inflammation of the pulp and subsequently pulpal necrosis [20].

If periodontal disease reaches the apical foramen, such inflammatory reactions may spread both ways leading to perio-endo pathologies. Similarly, infection from an infected pulp may exit the apical foramen, track through the periodontium, eliciting tissue destruction and formation of what registers clinically as a periodontal pocket.

2.3.2. Lateral and accessory canals

Accessory or lateral canals from the dental pulp may be formed during formation of the root sheath. A break develops in the continuity of the sheath, producing a small gap, which results in a small “accessory” canal between the dental sac and the pulp. Accessory and lateral canals can be seen anywhere along the root, creating a potential perio-endo pathway of communication [21]. Studies have reported that nerve fiber and blood vessels are commonly present in these lateral canals. They are found to traverse the periodontal ligament, course through the portal on cementum wall, root dentin and connect to the main root canal system [22]. Approximately 17% of teeth may present with multiple canal systems in the apical third of the root, about 9% in the middle third and fewer than 2% in the coronal third [23]. It has been

reported that debridement at molar furcation areas may increase the risk of bacterial contamination of the pulp by 39% through exposed dentin or furcation canals [24].

2.3.3. *Dentinal tubules*

As periodontitis gradually destroys the periodontal ligament between the cementum and bone, cementum becomes exposed to the oral environment via periodontal pockets and through gingiva recession. Destruction of Sharpey's fibers leaves a sieve-like surface on the cementum, full of canals which may be contaminated by bacteria and their toxins that may transverse the protective cemental layer into the patent dentinal tubules [10]. Furthermore, iatrogenic removal of cementum during periodontal treatment, various developmental fissures, grooves and incomplete calcifications on cementum may all permit penetration by bacteria into the underlying dentinal tubules [10].

Dentin is highly permeable with dentinal tubules as the major channels for diffusion of material across dentin. Bergenholtz and Lindhe [25] reported that the application of soluble material from bacterial plaque readily caused pulpal inflammation, suggesting there was a pathway of communication between the dentinal tubules, periodontium and the pulp. Such findings were again confirmed by Bergenholtz [26], who found that bacterial products applied to exposed dentin initiated inflammatory reactions in the dental pulp whilst occlusion of such exposed dentin had a protective effect with respect to the pulp.

2.4. The etiological agents

The source of perio-endo infection is no doubt from within the mouth yet there is no comprehensive report on the microbiota involved compare with periodontal or endodontic infection occurring independently. More than 460 bacterial, almost 10 fungal and 1 archaeal taxa [27] plus predominantly herpesviruses detectable at periradicular lesions [28] were reported associated with endodontic infection. Such observations were rather similar to microbiology of periodontitis [29]. Microbiology of failed endodontic treatment [30] and persisting periradicular endodontic infection (i.e. L-phase bacteria) [28], however exhibit unique microbiology. Taking that into consideration, the exact microbiological nature of perio-endo lesion remained to be elucidated.

3. Contributing factors to perio-endo lesions

3.1. Inadequate endodontic treatment

The primary aim of endodontic treatment is to disinfect the root canal system through chemo-mechanical debridement and cleaning so that the canal space can be freed of infected organic materials and obturated with an inert material [31]. Endodontic failures are caused by inadequate disinfection of the root canal system or reinfection of the root canal system due to failure to obtain a hermetic seal [32]. Endodontic infection may spread to the periodontium leading to perio-endo pathologies.

Endodontic failure may be caused by various biological and procedural factors e.g. (i) persistence intra- and extra-canal infection; (ii) inadequate or poorly condensed filling of the canal; (iii) overextensions of root filling materials; (iv) leakage due to inadequate coronal seal; (v) missed and thus undebrided canals; (vi) iatrogenic procedural errors such as poor access cavity design; and (vii) improper instrumentation (inadequate chemo-mechanical cleaning, ledges, perforations, or separated instruments). As it stands, proper access cavity design, thorough chemo-mechanical debridement and complete sealing of the root canal system to obliterate infection and prevent reinfection are key in prevention of endodontic failure.

3.2. Poor restorations

Poor restorations can be a major culprit for periodontal conditions and endodontic failure. Poor contours due to overhanging restorations, which impinge upon and thus violate the biological width, can contribute to localized periodontal defects [33, 34].

Poorly adapted restorations predispose to coronal leakage, allowing for recontamination of the root canal system and subsequent endodontic failure [35, 36]. Ray and Trope [36] reported that defective restorations with adequate root fillings had a higher failure rate in comparison to teeth with inadequate root fillings but with adequate restoration [36]. Similarly, a systematic review by Gillen et al. [35] reported that adequate root canal treatment (RCT) and good coronal seal increased the odds for healing of periapical lesions. In cases with adequate root filling-inadequate coronal restoration and inadequate root filling-adequate coronal restoration, poorer resolution of periapical infections are to be expected [35].

In short, sufficient disinfection and filling of the root canal system and a well-adapted coronal restoration which respects the biological width are paramount in ensuring long-term endodontic success and maintenance of a healthy periodontium around the treated tooth.

3.3. Perforations

Root perforation is a mechanical or pathological, communication between the root canal system and the external tooth surface [37]. Misalignment of instruments during endodontic access, negotiation and preparation of the root canals, and preparation of post space can cause iatrogenic perforations. Pathological root perforation, on the other hand, is caused by root resorption and/or caries.

In perforations, bacterial infections emanating from either the root canal or periodontal tissues, or both, could prevent healing and bring about inflammation. Down-growth of the gingival epithelium to the perforation site can follow, resulting in accelerated periodontal breakdown [38]. Ideally, any perforation should be repaired immediately. Treatment outcomes of endodontic perforations at the apical part of roots have been reported to be more successful than those located more coronally [39, 40]. Mineral trioxide aggregate (MTA) is often used for perforation repair [41] as it can stimulate hard tissue deposition [42], is biocompatible [43], provides excellent seal [44] and sets in the presence of moisture [45].

3.4. Developmental malformations

Developmental malformations both affect the periodontium and complicate conventional RCT. One of the most common dental malformations seen is the palatal-radicular groove, which has a reported prevalence of 4.6% appearing in maxillary incisors [46]. Its presence is a locus of plaque accumulation and provides potential pathway for microorganisms to penetrate into deeper parts of the periodontium, causing local inflammation and subsequent periodontal breakdown. Attachment loss may extend apically until it adversely affects the viability of the pulp, which is typical of the pathogenesis of a primary periodontal lesion with secondary endodontic involvement. RCT may be needed first if the patient complains of toothache. This may then be followed by periodontal surgical debridement or regenerative periodontal therapy when indicated [47].

Cemental tear is a rare periodontal condition characterized by partial or total separation of the cementum. The detachment normally happens at the cementum-dentin junction predisposing the tooth to plaque-induced periodontitis. Clinically, a cemental tear may present as a localized deep periodontal pocket, with or without other symptoms such as a sinus tract or pain. Probing at the affected site may detect root surface roughness or an obstruction, different to the expected typical tactile sense of calculus [48]. Treatment of cemental tear includes conventional periodontal therapy, combined periodontal and endodontic treatment when pulpal status of the affected tooth is compromised and/or surgery to remove the tear.

Cervical enamel projections and enamel pearls are development anomalies presenting as ectopic globules of enamel on the root surface. Enamel projections are small continuous or discontinuous extensions of enamel that occur in the molar furcations while enamel pearls are larger masses of enamel that have a predilection for molars [49]. It has been reported that 82.5% of molars with furcation attachment loss exhibited cervical enamel projections [50]. Enamel pearls are a rarity and occur mostly on permanent molars with an incidence rate of 1.1–9.7% [51]. Cervical enamel projections and enamel pearls predispose to periodontitis because Sharpey's fiber insertion is not developmentally possible, allowing only a hemidesmosomal attachment, which may be less resistant to periodontal breakdown. Both entities may also prevent effective oral hygiene procedures when exposed to the oral environment and may serve as a nidus for periodonto-pathogenic bacteria to grow and populate their surface [49]. In longstanding conditions, down-growth of epithelial attachment may cause a perio-endo lesion, especially if exposed accessory canals in the furcation area allow bacteria invasion into the pulp [24]. A combination of treatments may be warranted, such as RCT if pulpal symptoms are present, followed by periodontal surgery to recontour locally the affected root to allow for root debridement and to facilitate proper oral hygiene measures and periodontal maintenance measures.

3.5. Resorptions

Dental resorption is the loss of dental hard tissues as a result of resorptive activities by clastic cells (aptly known as odontoclasts) [52]. Root resorption may occur as a physiologic or pathologic phenomenon. Root resorption is classified into two types, external and internal.

3.5.1. *External inflammatory resorption*

External inflammatory resorption (EIR) is often a result of root avulsion injuries [53]. Traumatic dental injuries (e.g., intrusion, lateral luxation, and avulsion) and subsequent replantation often result in contusion injuries to the periodontal ligament (PDL). Damage to the pre-cementum, with a resultant breach in its integrity, is the precipitating factor in all types of external resorption [53]. In the wound healing process that follows, necrotic PDL tissues, damaged cementum and even root dentin may be actively removed by macrophages and osteoclasts, although the underlining mechanism is still unclear [52].

The diagnosis of EIR in clinical situations is often based on radiographic findings [54]. However, in two-dimensional radiographic imaging EIR may be obscured by overlapping images, or may not detectably show early signs of EIR, resulting in late diagnosis of EIR. Chronic inflammation seen in periodontal disease has been regarded as a cause for root resorption [55, 56], and such resorptive processes are associated with the severity of periodontitis [55]. The exact mechanism of periodontal disease-associated resorption is not known, but such a process may be a sequela of tooth mobility due to attachment loss [55]. When mobile teeth are subjected to occlusal forces, traumatic assault of the radicular surface may ensue, causing formation of cemental tears or lesions which may become colonized by odontoclastic cells or even periodontal pathogens that may resorb the root [55].

Treatment of EIR is based on effective removal of the cause, which is to institute a RCT with removal of the infected necrotic pulpal tissue [57]. Although the treatment of such lesions in periodontal disease is inconclusive, conventional mechanical debridement [56] may suppress inflammation and arrest the resorptive process. The earlier EIR is diagnosed and treated, the better the prognosis is for the affected tooth [58].

3.5.2. *External cervical resorption*

External cervical resorption (ECR) is a form of root resorption that originates on the external root surface but may invade root dentin in any direction and to varying degrees. ECR generally develops immediately apical to the epithelial attachment to the tooth. However, in teeth that have developed gingival recession and lost periodontal support and/or have developed a long junctional epithelium, the resorptive defect may arise at a more apical location [59]. The difference between EIR and ECR is that the pulp remains vital in ECR lesions unless the lesion is extensive and erodes into the pulpal space, while EIR always presents with necrotic pulp with or without any periapical lesion.

The exact etiology and pathogenesis of ECR have not been fully elucidated but may be regarded as the same for EIR. Infected or denuded cementum surfaces allow binding of multinucleated clastic cells which perpetuate the resorptive process [52]. Orthodontic treatment, dental trauma, oral surgery, periodontal therapy, bruxism, delayed eruption, and dental developmental defects were all identified as potential predisposing factors to ECR [60, 61]. In patients with periodontal disease, ECR may occur if the root-protective junctional epithelium (JE) did not develop. In such instances periodonto-pathogen initiated inflammation and dietary acid may extend into the root surfaces to cause ECR [56]. Although not fully understood, such a

situation may explain why resorption occurs only in the cervical region, where JE is absent and dietary acid easily gains access and may accumulate over a long period.

The clinical features of ECR may vary depending on etiology. However, the process is very often quiescent and asymptomatic initially. Its diagnosis is commonly made from a chance radiographic finding. A pink or red discoloration may later develop at the cervical region due to fibrovascular granulation tissue occupying the resorptive defect [59]. Inflammatory periodontal destruction may occur in the region of the resorption, resulting in a periodontal pocket that bleeds profusely on probing.

In recent years, CBCT has allowed three-dimensional assessment of the nature, position, and extent of resorptive defects, eliminating diagnostic confusion and providing essential information about the restorability and subsequent management of affected teeth [62–64]. A CBCT scan (at the smallest voxel size – 0.2 mm) provides a more site-focused and clearer radiographic image [65], thus reducing the need for exploratory treatment (usually surgical exploration), allowing timely intervention and reduced patient morbidity.

The fundamental treatment objectives in ECR are to access and excavate the resorptive defect (usually by raising a mucoperiosteal flap), halt the resorptive process (through application of 90% trichloroacetic acid), restore the hard tissue defect [66], and regular monitoring of the affected tooth for ECR recurrence, and the same for all other teeth which may be predisposed to the same resorptive event. This is especially true for ECRs related to periodontal diseases as multiple ECRs may occur in the same patient [56]. In cases where perforation of the root canal wall has occurred, RCT should be carried out as soon as possible to avoid pain. In periodontal disease-associated ECR, treatment was primarily aimed at suppressing periodontal pathogens through mechanical debridement, oral hygiene instruction and systemic antibiotics. This was supplemented with diet counseling and monitoring to lower the patients daily acid intake. High acidic intake may have contributed to the initiation of the resorptive process by retarding the proliferative capacity of the protective junctional epithelium [56].

3.6. Vertical root fractures

A vertical root fracture (VRF) is a longitudinally oriented complete or incomplete fracture initiated in the root at any level and is usually directed buccolingually [67]. The diagnosis of a VRF is somehow difficult in the early phase with patients complaining of dull pain, tooth sensitivity and discomfort while chewing. Early detection of VRF is unlikely radiographically due to various obstructions and overlapping structures, making proper diagnosis difficult. In of long-standing VRFs, a sinus tract may develop at a location more coronal than a sinus tract associated with chronic apical abscess [68]. This hints that the source of infection is not likely from an apical lesion [69, 70]. A deep, narrow, isolated periodontal pocket may be present, which is usually pathognomonic of a VRF. Radiographically, a typical J-shaped or halo radiolucency, with bone loss seen apically and extends alongside the involved root is highly indicative of VRF [71].

Over time, the pocket along the fracture line, which was initially tight and narrow, may become wider and easier to detect. When the fracture line propagates coronally, extending to the cervical root area, bacteria may penetrate and biofilm can attach along the fracture line,

triggering local host immune response which destroys the local periodontium. The fracture line allows the leakage of oral bacteria into the clean and previously sealed root canal system causing contamination. As reported by Tamse et al. [68], a typical VRF pocket could be observed in 67% of the cases. In periodontitis patients, vertical root fractures and cracks may serve to communicate the dental pulp with the periodontium. If the periodontium is infected or inflamed, pulp necrosis may ensue due to bacterial and bacterial product dissemination through such crevices [72].

Treatment for VRF differs greatly. VRF does not usually respond to non-surgical RCT or retreatment or to periodontal treatments instituted. In most cases, extraction of the tooth, especially for single-rooted teeth, is required. As for multi-rooted teeth, a root-resective approach may sometimes be considered.

3.7. Advanced periodontal disease

Untreated periodontal disease may progress and cause extensive damage to the tooth supporting structures. As the disease extends along the root surface, infection and/or inflammation can spread through the various communications between the pulp and the periodontium [28] until periodontal disease progression reaches the apical foramen leading to a primary periodontal lesion with secondary endodontic involvement [4]. Classification and management of such lesions will be discussed in the segments below.

4. Classification of periodontal and endodontic lesions

Many classifications for perio-endo lesions have been suggested [4, 72–74]. However, the proposed classification by Simon et al. [4] is still espoused by many, despite more rational later classifications, for many cases of perio-endo infections, and shall form the framework for the following discussion below.

4.1. Primary endodontic lesions

A necrotic pulp with its infected root canal system elicits inflammation of the adjacent periodontium through leaking of bacteria and bacterial by-products through the apical foramen and/or lateral canals causing tooth-supporting bone destruction [4, 72]. In multi-rooted teeth, infection from the apical foramen or the numerous accessory canals located in the molar bifurcation area, may track into the bifurcation area giving a radiographic and often clinical appearance of periodontal furcation involvement [21]. To consider solely endodontic lesions as having a component attributable to periodontitis is a diagnostic and conceptual error.

As such, when differentiating endodontic or periodontal lesions, one should be suspicious of a pulpally/endodontically induced lesion when the crestal bone levels on the mesial and distal aspects of the offending tooth appear relatively normal radiographically, despite a radiographically evident furcation radiolucency, and when clinical attachment loss is localized. Moreover, when the pulp is non-responsive to sensibility testing, it is likely that a necrotic

pulp may be the infectious source. Adequate RCT with adequate coronal restoration should usually resolve a primary endodontic lesion without any periodontal therapy, for such lesions are solely endodontic in origin. If solely affected by pulpal pathology, such teeth are only endodontically involved, and the so-called “primary endodontic lesion” is solely an endodontic lesion, and thus really should not be a component of any perio-endo classification. **Figure 1** illustrates a pure endodontic lesion managed by endodontic retreatment alone.

4.2. Primary endodontic lesions with secondary periodontal involvement

Over time, an untreated primary endodontic lesion may result in secondary consequential periodontal breakdown, which, if this reaches the gingival sulcus or a periodontal pocket, may become infected by periodonto-pathogens which subsequently trigger further periodontitis-associated periodontal tissue destruction, pocket formation, crestal bone loss and plaque (and calculus) contamination of root surfaces.

A tooth so affected requires both endodontic and periodontal treatments. In general, healing of tissues damaged by infection from the pulp can be anticipated after adequate RCT. The prognosis of the tooth will then largely depend on the outcome of periodontal therapy [4].

4.3. Primary periodontal lesions

Pure periodontal lesions are bacterial-induced inflammatory destructions of the tooth supporting apparatus due to periodonto-pathogens [75]. Diagnosis is based on periodontal examination such as probing pocket depths at 6 sites of each tooth, plaque accumulation and gingival bleeding scores [75, 76], on teeth having normal pulpal sensibility test outcomes. Teeth affected by solely periodontitis, which should respond to adequate periodontal therapy alone, are not endodontically involved.

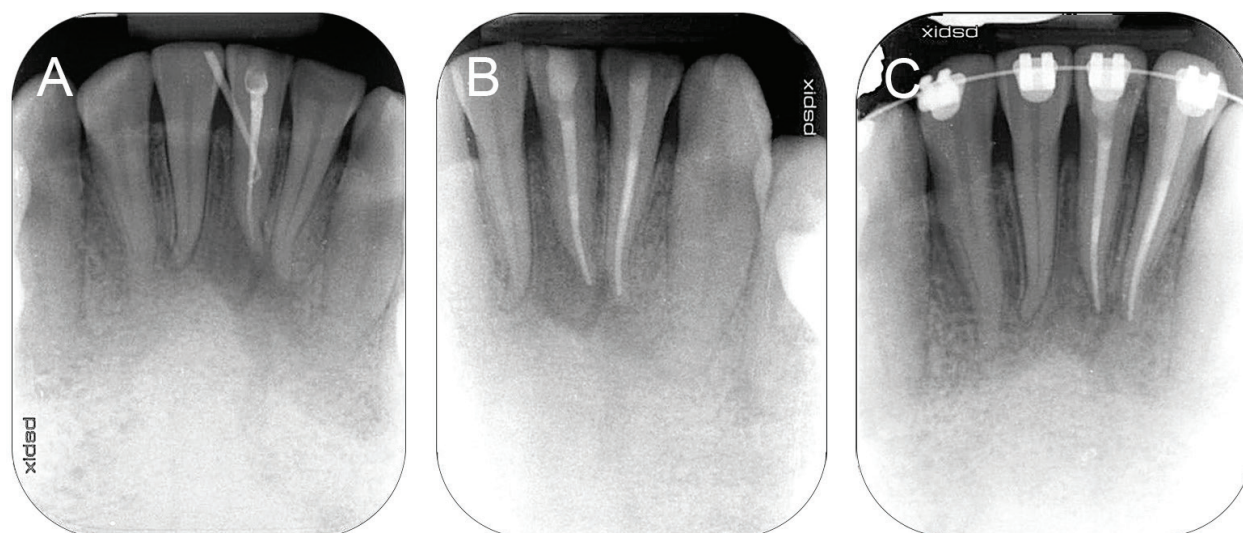


Figure 1. Endodontic lesion managed by endodontic retreatment. (A) Periapical radiograph of previously root treated tooth 31 exhibiting a large periapical lesion and infection draining through buccal gingival sulcus; (B) retreatment of 31 and RCT of a non-vital 32 completed; (C) radiograph of 31 and 32 showing bone fill 6 months post treatment.

In periodontitis, probing usually reveals plaque and calculus of varying quantity and quality along the root surface. In periodontitis many teeth are usually. The pulp typically responds positively to endodontic sensibility tests unless periodontitis has progressed towards the root apex. Prognosis of purely periodontally affected teeth depends largely upon the amount of bony destruction, the overall management of the patient, including non-surgical and surgical periodontal therapy, practice of adequate oral hygiene measures and adherence to supportive periodontal care [76, 77]. Once more, if a tooth is affected by only periodontitis which would respond to adequate periodontal treatment alone, then it is free from any endodontic involvement, and as such the so-called “primary periodontal lesion” should not form any part of a classification of perio-endo lesions.

4.4. Primary periodontal lesions with secondary endodontic involvement

If periodontitis progresses apically along the root surface, bacterial infiltrates from the periodontium may penetrate the pulp through exposed accessory and lateral canals, canaliculi of the furcation area, and eventually the apical foramen [72]. Pulpal necrosis can also result from periodontal procedures where the blood supply, through an accessory canal or the apex is severed during instrumentation. Lateral canals and dentinal tubules may be exposed to the oral environment during periodontal treatment allowing microorganism to pass freely to, or be pushed into, the pulpal tissue space [4].

Primary periodontal lesions with secondary endodontic involvement differ from primary endodontic lesion with secondary periodontal involvement only by the temporal sequence of the disease processes. Regardless of the primary cause of disease, RCT should precede periodontal therapy to prevent excessive removal of the protective root cementum and to alleviate any pulpal pain [5, 9, 22]. The tooth prognosis depends on adequate endodontic therapy, adequate coronal restoration and continuing periodontal care subsequent to endodontic therapy. The sequencing of treatment for both primary endodontic with secondary periodontal lesions and primary periodontal with secondary endodontic lesions is basically the same, so there is not a therapeutic distinction to be drawn from the differentiation between these two types of both periodontal and endodontic lesions affecting a tooth.

4.5. “True” combined lesions

True combined lesions occur where a primary endodontic lesion exists on a tooth that is also affected by periodontitis. These lesions are created when an infected periodontal pocket progresses apically to join with the endodontic lesion progressing coronally. Once the endodontic and periodontal lesions coalesce, they may be clinically and radiographically indistinguishable. The degree of attachment loss is usually quite substantial and the prognosis of such lesion is often very guarded [4].

In most cases, apical healing is often evident following successful endodontic treatment. The periodontal lesion, however, should respond well to adequate periodontal treatment and the prognosis may well depend on the severity of the periodontitis-induced periodontal attachment loss and the extent and pattern of alveolar bony destruction. The radiographic appearance of combined endodontic-periodontal disease may be similar to that of a VRF [4, 78].

4.6. Changes in the classification of perio-endo lesions

The primary endodontic lesion and the primary periodontal lesion are solely endodontic or periodontal in origin and should not be confused as perio-endo lesions where both entities are assumed to be associated with one another. To clarify such relationships, Abbott and Salgado [11] proposed a classification that limits the diagnosis of perio-endo lesions to teeth that have both endodontic and periodontal diseases occurring simultaneously. They proposed that such teeth should be classified into:

- i. *Concurrent endodontic and periodontal diseases without communication*: Implying that a tooth has an infection from the root canal system and concomitant alveolar bone loss due to periodontal disease but the periapical and periodontal lesions do not communicate with each other.
- ii. *Concurrent endodontic and periodontal diseases with communication*: Such a diagnosis applies to a tooth that has an infection from the root canal system and concomitant alveolar bone loss due to periodontal disease and the periapical and periodontal lesions communicate with each other. Radiographically, the periapical radiolucency and the marginal periodontal bone loss appear as one continuous radiolucent lesion.

Al-Fouzan [72] in their discussion on perio-endo lesions agreed largely with the classification by Simon et al. [4] but proposed a modification to the primary endodontic lesion. They classified an endodontic lesion with a deep narrow probing defect as “retrograde periodontal disease”, with two subdivisions:

- i. *Primary endodontic lesion with drainage through the periodontal ligament*: Which applies to an infected tooth with an apical lesion that drains coronally through a sinus tract that tracks along the periodontal ligament, mimicking a periodontal defect. There is usually a single deep and narrow periodontal pocket which heals upon endodontic treatment alone.
- ii. *Primary endodontic lesion with secondary periodontal involvement*: Such lesions exhibit extensive periodontal destruction as a result of drainage of infection from a necrotic root canal system. As the chronic communication persists, plaque and calculus accumulate within the periodontal pocket and contribute to the advancement of periodontal disease, necessitating periodontal treatment.

Al-Fouzan [72] also added an additional classification termed “iatrogenic periodontal lesions” which included: root perforation, coronal leakage, dental injuries or trauma, damage from chemicals used in dentistry and vertical root fractures. Although such lesions are not exactly periodontal lesions, such a classification allowed separate definition of perio-endo pathologies associated with trauma or iatrogenic injuries to the root surface itself. This was important as extensive damage to the root greatly diminishes a tooth’s long-term prognosis. This distinction may aid clinicians in identifying perio-endo lesions with direct and extensive damage to the root surface as opposed to lesions initiated by root canal infections and/or periodontal infections. Perio-endo lesions arising from root canal and/or periodontal infections are basically inflammatory lesions initiated by a wide array of microbiota such as bacteria, viruses or fungi.

These are usually presented clinically without detectable damage to the root itself. Such lesions are treated differently from those with significant root damage and will be discussed below.

Evidently, various opinions and controversies have emerged over the classification of perio-endo lesions. Future research or discussion may bring about a more comprehensive classification for such lesions that can clearly define the etiology of such pathologies and serve as a guide to adequately treat them.

5. Treatment modalities

Combined perio-endo lesions are a challenge to manage. RCT, or at least its initiation with mechanical and chemical cleaning of the pulp canal spaces, and effective intra-canal medication, is usually advocated as the first step in treatment of teeth with combined perio-endo lesions presenting with increased PPD and for teeth are unresponsive to pulp sensibility testing. Non-surgical periodontal therapy can proceed. Once RCT has been completed, adequate time for healing of the endodontic lesion should be given before further advanced periodontal therapy is considered [9]. Treatment modalities aimed at removal of bacterial irritants result in tooth prognosis which has been shown to improve over time [47]. This section summarized the treatment sequence for perio-endo lesions (**Figure 2**).

5.1. Non-surgical management

In the management of perio-endo lesions, it is important to recall that infected or necrotic pulps may lead to a narrow sinus tract undistinguishable clinically from a periodontal pocket. Because the primary cause of such lesions is pulpal in origin, the indicated treatment is solely RCT followed by adequate coronal seal, with long-term follow-up and monitoring to assess healing.

Similarly, if a vital tooth affected by solely periodontal disease develops mild pulpal symptoms, periodontal treatment should be the only intervention, followed by long-term follow-up. This will allow the mild and usually reversible inflammatory reaction of the pulp (which may transiently increase after periodontal therapy) to resolve as the vital pulp resists the spread of inflammation from the periodontal lesion [12].

With regards to concurrent perio-endo infections, although these separate entities may not be communicating, RCT should be carried out, or at least initiated, first to eliminate pulpal infection and relieve pain. This may then be followed by root surface debridement. Such a treatment sequence will allow removal of infectious source from the pulp and control of any possible communication between the infected root canal system and the adjacent periodontium. With this, even if the protective cementum layer is removed during root surface debridement, there should be no pulpal infection that can spread towards the periodontium through open dentinal tubules or accessory canals [11, 12]. Such a treatment philosophy is applied to true perio-endo lesions as well, to allow the affected tooth to undergo infection control in its entirety, sequentially and as effectively as possible [12].

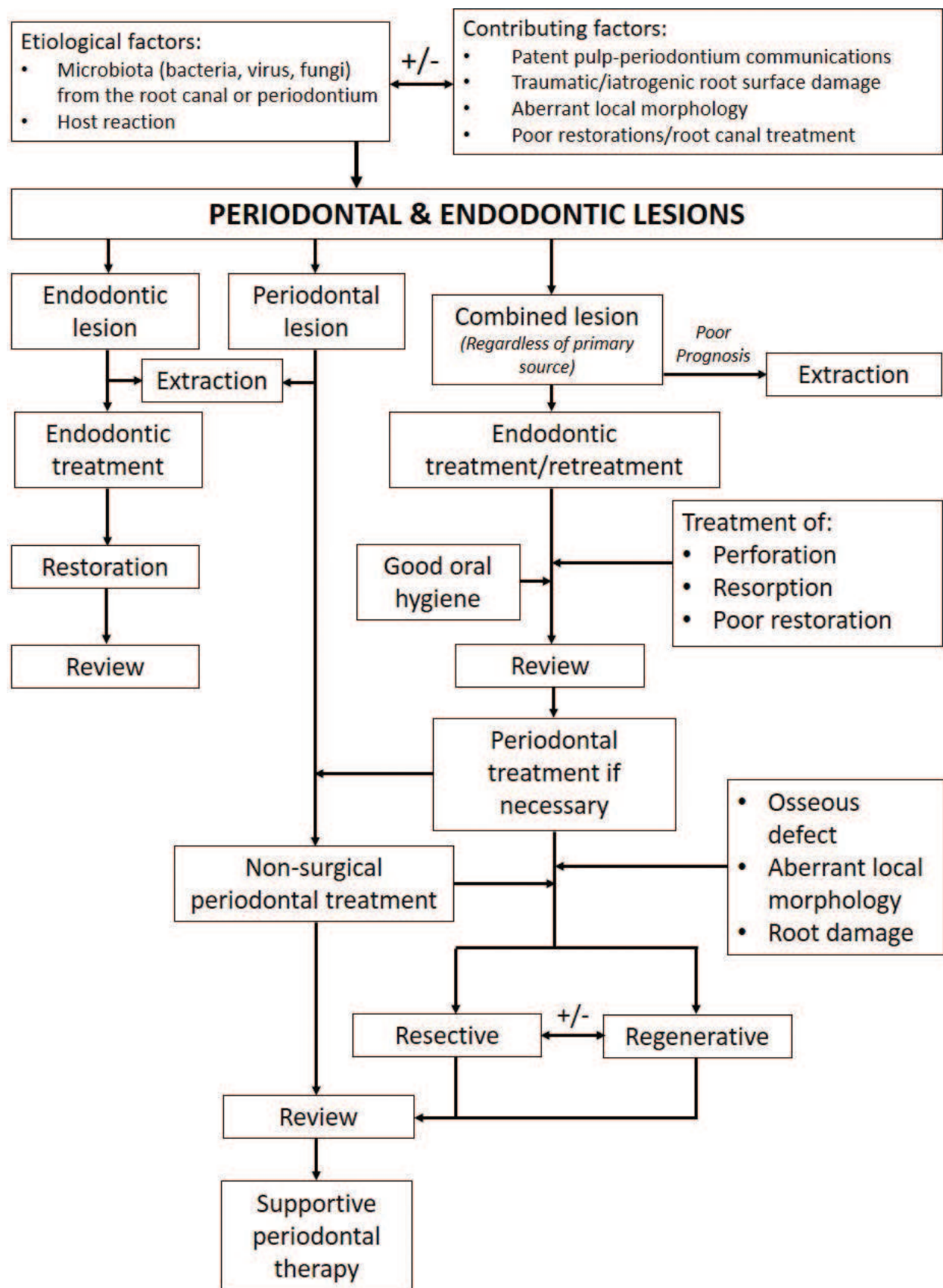


Figure 2. Flow chart summarizing treatment sequence for perio-endo lesions.

Indeed, in any patient with periodontal disease, management should include plaque control, non-surgical scaling and root debridement; periodontal surgery (with or with regenerative periodontal therapies) when indicated; and subsequent supportive periodontal care (SPC) [76, 79]. SPC should allow any teeth with pathologies, periodontal, endodontic or combined, to be well maintained within the oral cavity in the long term.

5.2. Surgical management

Conventional non-surgical periodontal and endodontic therapy may be predictably used to treat mild to moderate bony defects caused by perio-endo lesions. However, these non-surgical therapies alone might be inadequate for the treatment of lesions characterized by deep pockets, or wide circumferential apical defects caused by non-healing endodontic lesions, previous endodontic surgery [80], or those with substantial root surface damage such as root fracture of resorption. An endodontic lesion may be considered non-healing if the periapical lesion increases in size or remains unchanged after RCT. A decision to provide alternative treatment modalities will depend largely on the signs and symptoms experienced by the patient and judgment of the treating clinician, as periapical lesions can take up to four years [32] or longer [81] to heal. Surgical options for perio-endo lesions can be divided into surgical debridement, periodontal- or root- resective, or regenerative, approaches. The extent of periodontal tissue destruction or the failure of adequately delivered treatment to resolve the lesions, or any component thereof, may leave tooth extraction as the only practical treatment option.

5.2.1. Root-resective therapy

Root resection is the removal of a root (or roots, or root with coronal tooth structure) along with accompanying odontoplasty, before or preferably after endodontic treatment. Such tooth respective modalities are advocated to treat specific non-furcation and furcation defects that unlikely to be managed by non-surgical or surgical debridement alone [82]. The indications for root resection include root fracture, perforation, root caries, dehiscence, fenestration, external root resorption involving one root, incomplete endodontic treatment of a particular root, severe periodontitis affecting only one or two roots with at least one good sized root with proper/sufficient periodontal support to remain [83], or and severe grade II or grade III furcation involvement of multi-rooted teeth in the treatment of which clinicians attempt to create 'single rooted' situations to remove affect root(s) and to facilitate oral hygiene and SPC measures [84, 85].

Factors such as occlusal forces, tooth restorability, residual periodontal support and strategic value of the remaining root(s) should be taken into consideration during the planning stage before treatment. Proper reshaping of the occlusal table and appropriate restoration of the clinical crown are essential [83]. Additionally, the root surface at the site of the amputation must be recontoured after removal of the root stump to allow reestablishment of soft and hard tissue morphology favorable for oral hygiene measures by the patient and SPC measures by treating clinicians [86].

Hemisection is the surgical separation of a multirouted tooth. This is usually only a treatment option for mandibular molars with severe furcation involvement and periodontal attachment loss having affected one root more severely than the other (**Figure 3**). The tooth was sectioned

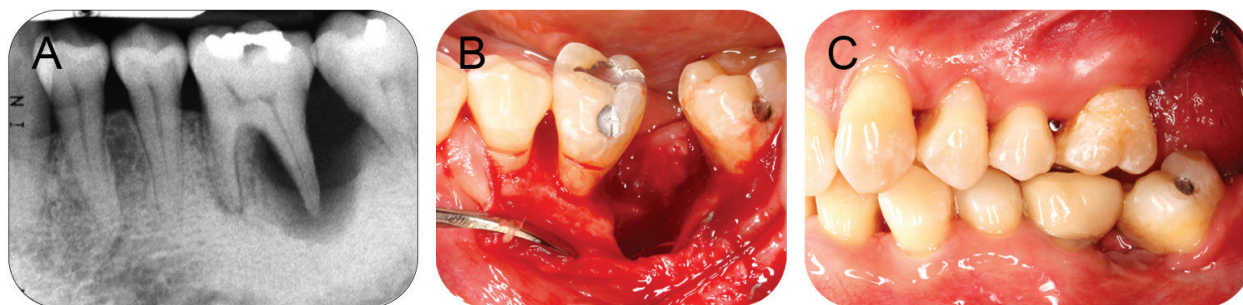


Figure 3. Management of a mandibular left first molar with severe furcation involvement and periodontal attachment loss. (A) Radiographic bone loss observable at distal root of a non-vital 36; (B) RCT was completed and 36 was hemisected distally; (C) 36 was subsequently crowned to coronally seal the treated root canal, re-establish occlusion and prevent further mesial drift of the second molar.

through the furcation, and the respective root and associated portion of the crown may be removed while another moiety is retained [87]. In most instances, an elective RCT should be performed before or as soon as possible after the hemisection to avoid any future pulpal complications. Hemisection allows retention of natural tooth structure, especially the root, which helps preserve surrounding alveolar bone, and may facilitate the placement of fixed prostheses [87].

The restorative aspects of the tooth to be so treated must be carefully assessed and integrated into the anticipated surgical procedure to ensure proper positioning of restorative margins relative to the osseous crest, and also to manage the anticipated changes in occlusal relationships and masticatory forces. In certain occasions, splinting of a resected tooth to neighboring teeth or the use of such teeth as abutments for fixed partial dentures may confer some reinforcement towards its long-term survival [83]. Although factors such as older age at time of resection, grade II mobility or above, and reduced pre-operative radiographic bone heights around roots seem to reduce the survival of resected teeth, the major cause of failure of resective procedures is often due to endodontic failure or vertical root fractures [88]. This is especially true if periodontal treatment had been properly carried out and the patient adheres to strict SPC [83, 88]. In most situations, the residual periodontal support of the treated tooth dictates the prognosis of the tooth. However, teeth with reduced periodontal support may still be maintained if proper SPC is provided [76, 89].

5.2.2. Regenerative therapy

Regenerative therapy has been shown to yield greater attachment gain and re-establish more favorable tissue morphology for oral hygiene measures compared to conventional periodontal therapy [90]. Pre-surgical assessment includes assessment of the pulp status and the severity of periodontal destruction. Once the therapeutic prognosis for the periodontal regenerative procedure is determined to be favorable, endodontic therapy is provided and the endodontic lesion is allowed to heal. Unsatisfactory healing after RCT might be further addressed with a surgical endodontic therapy approach (apicectomy) [78]. After a successful RCT, tooth mobility is reassessed to determine the necessity for splinting, as tooth mobility may reduce the success of regenerative therapy [91]. The intrasurgical assessment includes morphology of the

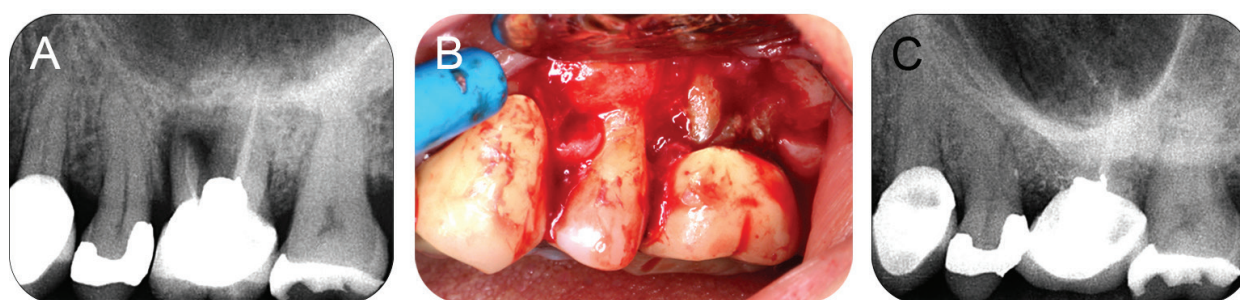

Figure 4. Periodontal surgical management of an upper left first molar with a root fracture. (A) Radiograph of root treated 26 with suspected mesio-buccal root fracture; (B) intra-operative view of 26 confirming initial diagnosis; (C) 26 MB root was resected and the defect regenerated with xenograft and a collagen barrier membrane. Radiograph taken at 6 months post treatment.

periodontal defect, material of choice to manage the defect, control of patient's oral hygiene, wound and tooth stabilization [78]. The defect, patient, and surgery-specific factors associated with favorable periodontal regeneration are [80]:

- i. Defect considerations: Deep (≥ 4 mm), narrow (< 45 degrees), vertical, two to three wall defects with no/minimal furcation involvement, adequate soft tissue thickness (> 1.1 mm) and keratinization (2 mm).
- ii. Patient considerations: Good oral hygiene, compliance towards periodontal care, abstinence from smoking/non-smoking and good systematic health/properly controlled systemic conditions.
- iii. Surgical considerations: Atraumatic incisions and flap elevation, primary closure, passive wound tension, uncontaminated wound during surgery (and post-surgical healing) and no occlusal trauma

In perio-endo lesions, regenerative periodontal therapies, such as use of biologically active products or guided tissue regeneration (GTR), may be used to promote periodontal regeneration and crestal intra-osseous defect bone-fill after endodontic treatment. In GTR, a barrier membrane is used to prevent contact of connective tissue with the osseous walls of an intra-osseous defect, to protect the underlying blood clot and to encourage growth of key tissues, while excluding unwanted cells such as epithelial cells [80]. When the intra-osseous defect is large, bone substitutes may be placed in the defect to support the overlying membrane and to maintain a space in which healing may occur [80]. Sometimes both root-resective and regenerative treatment may be carried out simultaneously to retain a tooth in function. **Figure 4** shows treatment of an upper first molar with a root fracture.

6. Summary

An in-depth understanding of the biology underlying perio-endo inter-relationships guides a clinician in diagnosing and subsequently deriving a sensible and timely treatment plan. Conventional endodontic and periodontal therapy have been shown to be successful in

managing such lesions [47] with endodontic therapy, or at least its initiation, being the first line of treatment in most cases [9]. The use of regenerative approaches to manage perio-endo lesions has advantages especially in terms of enhanced attachment gain and better long-term outcome of treated teeth. Various other treatment modalities for managing the periodontal component of perio-endo lesions, such as the application of enamel matrix derivatives [92] or platelet-rich fibrins [93] may offer good results. However, more research is warranted in this field with hope that retention of perio-endo involved teeth may become more predictable in the near future.

Acknowledgements

The work described in this chapter was substantially supported by the Young Researcher's Incentive Grants (GGPM-2016-062 and GGPM-2017-109), The National University of Malaysia, and the Research Grants Council of the Hong Kong Special Administrative Region, China (HKU 772110 M).

Conflict of interest

The authors declare no conflict of interest.

Author details

Kai Ling Siew¹, Victor Goh^{1,2}, Chui Ling Goo², Esmonde Francis Corbet¹ and Wai Keung Leung^{1*}

*Address all correspondence to: ewkleung@hku.hk

1 Faculty of Dentistry, The University of Hong Kong, Hong Kong SAR, China

2 Faculty of Dentistry, The National University of Malaysia, Malaysia

References

- [1] Offenbacher S, Barros SP, Singer RE, Moss K, Williams RC, Beck JD. Periodontal disease at the biofilm–gingival interface. *Journal of Periodontology*. 2007;**78**(10):1911-1925
- [2] Ricucci D, Siqueira Jr JF. Biofilms and apical periodontitis: Study of prevalence and association with clinical and histopathologic findings. *Journal of Endodontics*. 2010;**36**(8): 1277-1288
- [3] Ricucci D, Siqueira Jr JF. Fate of the tissue in lateral canals and apical ramifications in response to pathologic conditions and treatment procedures. *Journal of Endodontics*. 2010;**36**(1):1-15

- [4] Simon JH, Glick DH, Frank AL. The relationship of endodontic-periodontic lesions. *Journal of Periodontology*. 1972;**43**(4):202-208
- [5] Chen SY, Wang HL, Glickman GN. The influence of endodontic treatment upon periodontal wound healing. *Journal of Clinical Periodontology*. 1997;**24**(7):449-456
- [6] Parahitiyawa NB, Chu FC, Leung WK, Yam WC, Jin LJ, Samaranayake LP. Clonality of bacterial consortia in root canals and subjacent gingival crevices. *Journal of Investigative and Clinical Dentistry*. 2015;**6**(1):32-39
- [7] Jansson L, Ehnevid H, Lindskog S, Blomlof L. The influence of endodontic infection on progression of marginal bone loss in periodontitis. *Journal of Clinical Periodontology*. 1995;**22**(10):729-734
- [8] Ehnevid H, Jansson L, Lindskog S, Blomlof L. Periodontal healing in teeth with periapical lesions. A clinical retrospective study. *Journal of Clinical Periodontology*. 1993;**20**(4):254-258
- [9] Schmidt JC, Walter C, Amato M, Weiger R. Treatment of periodontal-endodontic lesions – A systematic review. *Journal of Clinical Periodontology*. 2014;**41**(8):779-790
- [10] Hiatt WH. Pulpal periodontal disease. *Journal of Periodontology*. 1977;**48**(9):598-609
- [11] Abbott PV, Salgado JC. Strategies for the endodontic management of concurrent endodontic and periodontal diseases. *Australian Dental Journal*. 2009;**54**(Suppl 1):S70-S85
- [12] Heasman PA. An endodontic conundrum: The association between pulpal infection and periodontal disease. *British Dental Journal*. 2014;**216**(6):275-279
- [13] Seltzer S, Bender IB, Ziontz M. The interrelationship of pulp and periodontal disease. *Oral Surgery, Oral Medicine, and Oral Pathology*. 1963;**16**:1474-1490
- [14] Langeland K, Rodrigues H, Dowden W. Periodontal disease, bacteria, and pulpal histopathology. *Oral Surgery, Oral Medicine, and Oral Pathology*. 1974;**37**(2):257-270
- [15] Wan L, Lu HB, Xuan DY, Yan YX, Zhang JC. Histological changes within dental pulps in teeth with moderate-to-severe chronic periodontitis. *International Endodontic Journal*. 2015;**48**(1):95-102
- [16] Goh V, Corbet EF, Leung WK. Impact of dentine hypersensitivity on oral health-related quality of life in individuals receiving supportive periodontal care. *Journal of Clinical Periodontology*. 2016;**43**(7):595-602
- [17] Jeffcoat MK, Jeffcoat RL, Jens SC, Captain K. A new periodontal probe with automated cemento-enamel junction detection. *Journal of Clinical Periodontology*. 1986;**13**(4):276-280
- [18] Adriaens PA, Edwards CA, De Boever JA, Loesche WJ. Ultrastructural observations on bacterial invasion in cementum and radicular dentin of periodontally diseased human teeth. *Journal of Periodontology*. 1988;**59**(8):493-503
- [19] Herbranson E. The anatomy of the root canal system as a challenge to effective disinfection. In: Cohenca N, editor. *Disinfection of Root Canal Systems*. John Wiley & Sons, Inc. Ames, IA, USA; 2014. pp. 15-28

- [20] Graunaite I, Lodiene G, Maciulskiene V. Pathogenesis of apical periodontitis: A literature review. *Journal of Oral and Maxillofacial Research*. 2012;**2**(4):e1
- [21] Gutmann JL. Prevalence, location, and patency of accessory canals in the furcation region of permanent molars. *Journal of Periodontology*. 1978;**49**(1):21-26
- [22] Dongari A, Lambrianidis T. Periodontally derived pulpal lesions. *Endodontics and Dental Traumatology*. 1988;**4**(2):49-54
- [23] De Deus QD. Frequency, location, and direction of the lateral, secondary, and accessory canals. *Journal of Endodontics*. 1975;**1**(11):361-366
- [24] Shambarger S, Johnson D, Versulius-Tantbirojin D, Bowles WR, McClanahan SB. The incidence of furcation region patency in molars before and after simulated periodontal therapy. *Northwest Dentistry*. 2015;**94**(2):27-32
- [25] Bergenholtz G, Lindhe J. Effect of soluble plaque factors on inflammatory reactions in the dental pulp. *Scandinavian Journal of Dental Research*. 1975;**83**(3):153-158
- [26] Bergenholtz G, Reit C. Reactions of the dental pulp to microbial provocation of calcium hydroxide treated dentin. *Scandinavian Journal of Dental Research*. 1980;**88**(3):187-192
- [27] Siqueira Jr JF, Rôças IN. Diversity of endodontic microbiota revisited. *Journal of Dental Research*. 2009;**88**(11):969-981
- [28] Rotstein I. Interaction between endodontics and periodontics. *Periodontology 2000*. 2017;**74**(1):11-39
- [29] Paster BJ, Olsen I, Aas JA, Dewhirst FE. The breadth of bacterial diversity in the human periodontal pocket and other oral sites. *Periodontology 2000*. 2006;**42**(1):80-87
- [30] Wade WG. The oral microbiome in health and disease. *Pharmacological Research*. 2013;**69**(1):137-143
- [31] Tabassum S, Khan FR. Failure of endodontic treatment: The usual suspects. *European Journal of Dentistry*. 2016;**10**(1):144-147
- [32] Quality guidelines for endodontic treatment. Consensus report of the european society of endodontology. *International Endodontic Journal*. 2006;**39**(12):921-930
- [33] Albandar JM, Buischi YA, Axelsson P. Caries lesions and dental restorations as predisposing factors in the progression of periodontal diseases in adolescents. A 3-year longitudinal study. *Journal of Periodontology*. 1995;**66**(4):249-254
- [34] Lang NP, Kiel RA, Anderhalden K. Clinical and microbiological effects of subgingival restorations with overhanging or clinically perfect margins. *Journal of Clinical Periodontology*. 1983;**10**(6):563-578
- [35] Gillen BM, Looney SW, Gu LS, Loushine BA, Weller RN, Loushine RJ, et al. Impact of the quality of coronal restoration versus the quality of root canal fillings on success of root canal treatment: A systematic review and meta-analysis. *Journal of Endodontics*. 2011;**37**(7):895-902

- [36] Ray HA, Trope M. Periapical status of endodontically treated teeth in relation to the technical quality of the root filling and the coronal restoration. *International Endodontic Journal*. 1995;**28**(1):12-18
- [37] American Association of Endodontists. Glossary of Endodontic Terms. 9th ed. Chicago: AAE; 2015
- [38] Tsesis I, Rosen E, Schwartz-Arad D, Fuss Z. Retrospective evaluation of surgical endodontic treatment: Traditional versus modern technique. *Journal of Endodontics*. 2006;**32**(5):412-416
- [39] Kvinnsland I, Oswald RJ, Halse A, Gronningsaeter AG. A clinical and roentgenological study of 55 cases of root perforation. *International Endodontic Journal*. 1989;**22**(2):75-84
- [40] Siew K, Lee AH, Cheung GS. Treatment outcome of repaired root perforation: A systematic review and meta-analysis. *Journal of Endodontics*. 2015;**41**(11):1795-1804
- [41] Torabinejad M, Parirokh M, Dummer PMH. Mineral trioxide aggregate and other bioactive endodontic cements: An updated overview – Part ii: Other clinical applications and complications. *International Endodontic Journal*. 2018;**51**(3):284-317
- [42] Economides N, Pantelidou O, Kokkas A, Tziafas D. Short-term periradicular tissue response to mineral trioxide aggregate (mta) as root-end filling material. *International Endodontic Journal*. 2003;**36**(1):44-48
- [43] Torabinejad M, Parirokh M. Mineral trioxide aggregate: A comprehensive literature review – Part ii: Leakage and biocompatibility investigations. *Journal of Endodontics*. 2010;**36**(2):190-202
- [44] Torabinejad M, Watson TF, Pitt Ford TR. Sealing ability of a mineral trioxide aggregate when used as a root end filling material. *Journal of Endodontics*. 1993;**19**(12):591-595
- [45] Parirokh M, Torabinejad M. Mineral trioxide aggregate: A comprehensive literature review – Part iii: Clinical applications, drawbacks, and mechanism of action. *Journal of Endodontics*. 2010;**36**(3):400-413
- [46] Kogon SL. The prevalence, location and conformation of palato-radicular grooves in maxillary incisors. *Journal of Periodontology*. 1986;**57**(4):231-234
- [47] Cho YD, Lee JE, Chung Y, Lee WC, Seol YJ, Lee YM, et al. Collaborative management of combined periodontal-endodontic lesions with a palatogingival groove: A case series. *Journal of Endodontics*. 2017;**43**(2):332-337
- [48] Xie C, Wang L, Yang P, Ge S. Cemental tears: A report of four cases and literature review. *Oral Health and Preventive Dentistry*. 2017;**15**(4):337-345
- [49] Matthews DC, Tabesh M. Detection of localized tooth-related factors that predispose to periodontal infections. *Periodontology 2000*. 2004;**34**:136-150
- [50] Hou GL, Tsai CC. Relationship between periodontal furcation involvement and molar cervical enamel projections. *Journal of Periodontology*. 1987;**58**(10):715-721

- [51] Moskow BS, Canut PM. Studies on root enamel (2). Enamel pearls. A review of their morphology, localization, nomenclature, occurrence, classification, histogenesis and incidence. *Journal of Clinical Periodontology*. 1990;**17**(5):275-281
- [52] Arana-Chavez VE, Bradaschia-Correa V. Clastic cells: Mineralized tissue resorption in health and disease. *The International Journal of Biochemistry and Cell Biology*. 2009;**41**(3):446-450
- [53] Andreasen FM, Pedersen BV. Prognosis of luxated permanent teeth – The development of pulp necrosis. *Endodontics and Dental Traumatology*. 1985;**1**(6):207-220
- [54] Andreasen FM, Sewerin I, Mandel U, Andreasen JO. Radiographic assessment of simulated root resorption cavities. *Endodontics and Dental Traumatology*. 1987;**3**(1):21-27
- [55] Mahajan AC, Kolte AP, Kolte RA, Agrawal AA. Dimensional evaluation of root resorption areas in differing severity of chronic periodontitis: A scanning electron microscopic study. *Contemporary Clinical Dentistry*. 2017;**8**(3):433-438
- [56] Beertsen W, Piscaer M, Van Winkelhoff AJ, Everts V. Generalized cervical root resorption associated with periodontal disease. *Journal of Clinical Periodontology*. 2001;**28**(11):1067-1073
- [57] Barnett F. The role of endodontics in the treatment of luxated permanent teeth. *Dental Traumatology*. 2002;**18**(2):47-56
- [58] Moule AJ, Moule CA. The endodontic management of traumatized permanent anterior teeth: A review. *Australian Dental Journal*. 2007;**52**:S122-S137
- [59] Heithersay GS. Clinical, radiologic, and histopathologic features of invasive cervical resorption. *Quintessence International*. 1999;**30**(1):27-37
- [60] Heithersay GS. Invasive cervical resorption: An analysis of potential predisposing factors. *Quintessence International*. 1999;**30**(2):83-95
- [61] Heithersay GS. Invasive cervical resorption following trauma. *Australian Endodontic Journal*. 1999;**25**(2):79-85
- [62] Vaz de Souza D, Schirru E, Mannocci F, Foschi F, Patel S. External cervical resorption: A comparison of the diagnostic efficacy using 2 different cone-beam computed tomographic units and periapical radiographs. *Journal of Endodontics*. 2017;**43**(1):121-125
- [63] Patel S, Dawood A. The use of cone beam computed tomography in the management of external cervical resorption lesions. *International Endodontic Journal*. 2007;**40**(9):730-737
- [64] Gunst V, Mavridou A, Huybrechts B, Van Gorp G, Bergmans L, Lambrechts P. External cervical resorption: An analysis using cone beam and microfocus computed tomography and scanning electron microscopy. *International Endodontic Journal*. 2013;**46**(9):877-887
- [65] Talwar S, Utneja S, Nawal RR, Kaushik A, Srivastava D, Oberoy SS. Role of cone-beam computed tomography in diagnosis of vertical root fractures: A systematic review and meta-analysis. *Journal of Endodontics*. 2016;**42**(1):12-24

- [66] Heithersay GS. Treatment of invasive cervical resorption: An analysis of results using topical application of trichloroacetic acid, curettage, and restoration. *Quintessence International*. 1999;**30**(2):96-110
- [67] Liao WC, Tsai YL, Wang CY, Chang MC, Huang WL, Lin HJ, et al. Clinical and radiographic characteristics of vertical root fractures in endodontically and nonendodontically treated teeth. *Journal of Endodontics*. 2017;**43**(5):687-693
- [68] Tamse A, Fuss Z, Lustig J, Kaplavi J. An evaluation of endodontically treated vertically fractured teeth. *Journal of Endodontics*. 1999;**25**(7):506-508
- [69] Meister Jr F, Lommel TJ, Gerstein H. Diagnosis and possible causes of vertical root fractures. *Oral Surgery, Oral Medicine, and Oral Pathology*. 1980;**49**(3):243-253
- [70] Testori T, Badino M, Castagnola M. Vertical root fractures in endodontically treated teeth: A clinical survey of 36 cases. *Journal of Endodontics*. 1993;**19**(2):87-91
- [71] Tamse A, Fuss Z, Lustig J, Ganor Y, Kaffe I. Radiographic features of vertically fractured, endodontically treated maxillary premolars. *Oral Surgery, Oral Medicine, Oral Pathology, Oral Radiology, and Endodontics*. 1999;**88**(3):348-352
- [72] Al-Fouzan KS. A new classification of endodontic-periodontal lesions. *International Journal of Dentistry*. 2014;**2014**:919173
- [73] Benenati FW, Roane JB, Waldrop TC. The perio-pulpal connection: An analysis of the periodontic-endodontic lesion. *General Dentistry*. 1981;**29**(6):515-520
- [74] Guldener PH. The relationship between periodontal and pulpal disease. *International Endodontic Journal*. 1985;**18**(1):41-54
- [75] Armitage GC. Periodontal diagnoses and classification of periodontal diseases. *Periodontology 2000*. 2004;**34**:9-21
- [76] Goh V, Hackmack PP, Corbet EF, Leung WK. Moderate- to long-term periodontal outcomes of subjects failing to complete a course of periodontal therapy. *Australian Dental Journal*. 2017;**62**(2):152-160
- [77] Leung WK, Ng DK, Jin L, Corbet EF. Tooth loss in treated periodontitis patients responsible for their supportive care arrangements. *Journal of Clinical Periodontology*. 2006;**33**(4):265-275
- [78] Oh SL, Fouad AF, Park SH. Treatment strategy for guided tissue regeneration in combined endodontic-periodontal lesions: Case report and review. *Journal of Endodontics*. 2009;**35**(10):1331-1336
- [79] Goh V, Nihalani D, Yeung KWS, Corbet EF, Leung WK. Moderate- to long-term therapeutic outcomes of treated aggressive periodontitis patients without regular supportive care. *Journal of Periodontal Research*. 2018;**53**(3):324-333
- [80] Bashutski JD, Wang HL. Periodontal and endodontic regeneration. *Journal of Endodontics*. 2009;**35**(3):321-328

- [81] Molven O, Halse A, Fristad I, MacDonald-Jankowski D. Periapical changes following root-canal treatment observed 20-27 years postoperatively. *International Endodontic Journal*. 2002;**35**(9):784-790
- [82] DeSanctis M, Murphy KG. The role of resective periodontal surgery in the treatment of furcation defects. *Periodontology 2000*. 2000;**22**:154-168
- [83] Lee KL, Corbet EF, Leung WK. Survival of molar teeth after resective periodontal therapy – A retrospective study. *Journal of Clinical Periodontology*. 2012;**39**(9):850-860
- [84] Svardstrom G, Wennstrom JL. Periodontal treatment decisions for molars: An analysis of influencing factors and long-term outcome. *Journal of Periodontology*. 2000;**71**(4):579-585
- [85] Walter C, Weiger R, Zitzmann NU. Periodontal surgery in furcation-involved maxillary molars revisited – An introduction of guidelines for comprehensive treatment. *Clinical Oral Investigations*. 2011;**15**(1):9-20
- [86] Carnevale G, Pontoriero R, di Febo G. Long-term effects of root-resective therapy in furcation-involved molars. A 10-year longitudinal study. *Journal of Clinical Periodontology*. 1998;**25**(3):209-214
- [87] Sharma S, Sharma R, Ahad A, Gupta ND, Mishra SK. Hemisection as a conservative management of grossly carious permanent mandibular first molar. *Journal of Natural Science, Biology, and Medicine*. 2018;**9**(1):97-99
- [88] Huynh-Ba G, Kuonen P, Hofer D, Schmid J, Lang NP, Salvi GE. The effect of periodontal therapy on the survival rate and incidence of complications of multirooted teeth with furcation involvement after an observation period of at least 5 years: A systematic review. *Journal of Clinical Periodontology*. 2009;**36**(2):164-176
- [89] Graetz C, Dorfer CE, Kahl M, Kocher T, Fawzy El-Sayed K, Wiebe JF, et al. Retention of questionable and hopeless teeth in compliant patients treated for aggressive periodontitis. *Journal of Clinical Periodontology*. 2011;**38**(8):707-714
- [90] Jepsen S, Eberhard J, Herrera D, Needleman I. A systematic review of guided tissue regeneration for periodontal furcation defects. What is the effect of guided tissue regeneration compared with surgical debridement in the treatment of furcation defects? *Journal of Clinical Periodontology*. 2002;**29**(Suppl 3):103-116 (discussion 60-2)
- [91] Cortellini P, Tonetti MS, Lang NP, Suvan JE, Zucchelli G, Vangsted T, et al. The simplified papilla preservation flap in the regenerative treatment of deep intrabony defects: Clinical outcomes and postoperative morbidity. *Journal of Periodontology*. 2001;**72**(12):1702-1712
- [92] Azaripour A, Willershausen I, Kammerer P, Willershausen B. Post-endodontic treatment periodontal surgery: A case report. *Quintessence International*. 2013;**44**(2):123-126
- [93] Karunakaran JV, Fenn SM, Jayaprakash N, Ragavendran N. Successful surgical management of palatogingival groove using platelet-rich fibrin and guided tissue regeneration: A novel approach. *Journal of Pharmacy and Bioallied Sciences*. 2017;**9**(Suppl 1):S268-S273