

We are IntechOpen, the world's leading publisher of Open Access books Built by scientists, for scientists

6,900

Open access books available

185,000

International authors and editors

200M

Downloads

Our authors are among the

154

Countries delivered to

TOP 1%

most cited scientists

12.2%

Contributors from top 500 universities



WEB OF SCIENCE™

Selection of our books indexed in the Book Citation Index
in Web of Science™ Core Collection (BKCI)

Interested in publishing with us?
Contact book.department@intechopen.com

Numbers displayed above are based on latest data collected.
For more information visit www.intechopen.com



Pleural Effusions in Lung Cancer: Detection and Treatment

Milic Medenica, Miras Medenica and Danilo Cosovic

Additional information is available at the end of the chapter

<http://dx.doi.org/10.5772/intechopen.78307>

Abstract

In all cell types of lung cancer, pleural effusion is a possible complication of disease. Paramalignant pleural effusions [PMPE] are not a consequence of malignant disease spreading to pleura. The probability that an effusion is paramalignant is higher if the effusion is a transudative or parapneumonic effusion. Differentiating between paramalignant and malignant effusions has both therapeutic and prognostic significance. MPEs are a sign of metastatic dissemination of neoplastic disease. In pleural fluid or tissue, there are malignant cells. In PMPE, lung cancer had been previously diagnosed. Bronchoobstruction, atelectasis, infection, pulmonary emboli, air therapy, and heliotherapy result in effusion development. PMPEs equally appear in all pathohistological types of lung cancer, as MPEs are the most common in lung adenocarcinoma. Also, there are biochemical properties of PMPE and MPE. Therapeutic procedures depend on the presence of respiratory distress, biochemical properties of pleural fluid, type of primary tumour, and expected response to the therapy.

Keywords: paramalignant, malignant, effusion, thoracocentesis, pleurodesis

1. Introduction

Over 175,000 MPE [1] are diagnosed yearly in USA and 50,000 [2] in the UK. In 75% of cases, MPE are a consequence of metastatic dissemination of lung or breast cancer [3]. Pleural effusion in lung cancer is a complication of terminal or preterminal stage of disease. Lung cancer disturbs one or more mechanisms of normal fluid flow, which is followed by inevitable accumulation of fluid in pleural space. Pleural effusion is not always a sign of cancer metastasis, but it is evident that in most cases it is related to the primary disease.

Pleural effusion is a possible complication of disease in all cell types of lung cancer [4, 5]. At the first presentation, around 15% of patients with lung cancer have a pleural effusion [5]. For the duration of disease, approximately 50% of patients develop a pleural effusion. Depending on the presence of malignant cells in pleural fluid, pleural effusions are divided into two groups: paramalignant pleural effusions [PMPE] and malignant pleural effusions [MPE] [3]. Distinguishing between PME and MPE can be challenging. Analytical limitations do not allow the use of a single method to pursue the diagnosis and also can expose the patients to invasive procedures. PMPE are not a consequence of malignant disease spreading to the pleura. The probability that an effusion is paramalignant is higher if the effusion is a transudative or parapneumonic effusion. Differentiation between PMPE and MPE is important, so that appropriate decisions about treatment modalities can be made, and also due to different prognosis of the two conditions.

2. Clinical features of pleural effusion

In patients with lung cancer and pleural effusion, there is a mild to medium symptomatology of respiratory distress. Clinical history usually points to the diagnosis of lung, breast, ovarian cancer or lymphoma. At the time of diagnosis of malignant pleural effusion, 23% of patients are asymptomatic [4]. Pleural effusion followed by pleural pain indicates the inflammation of the parietal pleura. Dull pain in the chest wall stirs suspicion of pleural malignancy [6]. Nevertheless, pleuritic or dull pain in the chest wall indicates a distortion of the parietal pleura and a high probability of an exudative effusion developing. As a rule, pain is a consequence of pleural disease. Localisation of pain is correlated to the area of pleura that is affected (parietal pleura is innervated by intercostal nerves). Occasionally, pleuritic pain spreads into upper parts of stomach [intercostal nerves innervate the abdomen as well]. Exception in pain localisation and spreading of the pain are noted when the central parts of diaphragmatic pleura are affected by the disease. These parts of the pleura are innervated by phrenic nerves and consequently the pain localises to the ipsilateral shoulder. In over 70% of patients with MPE intrathoracic pain is a symptom of the disease [7]. Non-productive cough can also be a symptom of a pleural effusion. Mechanism of genesis of the cough is not clear and is probably related to pleural inflammation. Alternatively, compression of lungs and bronchial wall by fluid might stimulate the cough reflex [8]. Cough is present in over 50% of patients. A common symptom of pleural effusion is dyspnoea. Dyspnoea is present in around 70% of patients with MPE [7]. The severity of dyspnoea is often not proportional to the size of pleural effusion [4]. Dyspnoea is usually present in diaphragmatic dysfunction. In an inverted diaphragm, dyspnoea is disproportional to the size of the effusion. Mulvey [9] classified hemi-diaphragmatic alterations seen on chest radiographs and fluoroscopy into three groups. The three groups are: normal function of the hemidiaphragm, fixed hemidiaphragm, and hemidiaphragm with paradoxical movement. Patients with normal functioning diaphragm are usually asymptomatic, even with a large pleural effusion. The second group of patients are the patients with a fixed hemidiaphragm. Immobile diaphragm disables sufficient ventilation of the lungs. In the third patient group, hemidiaphragm exhibits paradoxical movement which results in severe dyspnoea. Paradoxical movement of the right hemidiaphragm is rarely seen, probably due to proximity of the liver. The severity of respiratory

insufficiency depends on the size of the effusion and previous lung function. Pleural effusion reduces the thoracic space and lung volumes or in turn the thoracic cavity enlarges as the ipsilateral hemidiaphragm descends. Therefore, fluid in the pleural space causes restrictive ventilator defect. Small to moderate pleural effusions cause dislocation rather than lung compression and they have a little consequential effect on the lung function [6]. In massive pleural effusions, the most common symptoms are the ones that are a direct consequence of lung function compromise. Improvement of lung function after therapeutic thoracocentesis is less than expected [10]. Explanation of inadequate improvement of lung function probably lays in the fact that usually, besides pleural effusion, there are also changes in the lung parenchyma. In massive pleural effusions, the mechanism of dyspnoea is closely related to the reduction of chest wall compliance, counter lateral mediastinum movement, and loss of the ipsilateral lung volume with additional action of neurogenic factors of the pulmonary parenchyma [11].

In 26 patients, spirometry was performed before thoracocentesis and 24 hours after thoracocentesis. Average amount of evacuated fluid was 1740 ml [12]. After thoracocentesis, vital capacity increased for 410 ± 390 ml. Estenne et al. [13] examined respiratory mechanics in nine patients, before and 2 hours after evacuation of 600–2750 ml (average amount = 1818 ml) of pleural fluid. Before thoracocentesis, forced vital capacity (FVC) was between 22 and 51% of predicted values. After thoracocentesis, the average value of FVC has increased only by 300–460 ml. Estenne interprets reduction in dyspnoea by reduction in the size of the thoracic volume. Reduction of the thoracic cavum enables inspiratory muscles to function in much more favourable length-tension relationship. Before thoracocentesis, maximum inspiratory pressure at TLC (total lung capacity) was -16 cm H₂O, and after thoracocentesis, the pressure fell to -25 cm H₂O. Explanation of these phenomena probably lays in the fact that hemidiaphragm is released from the pressure of pleural fluid. In pleural effusion, PaO₂ is usually low, as alveolar-arterial gradient is increased.

Patients with pleural effusion complain of intolerance to exertion. Exertional intolerance was examined in 24 patients, before and after thoracocentesis. There were no significant changes in hypoxia and hypercapnia level. A number of patients had malignant effusions and it is possible that the given results are the consequence of primary disease rather than lung function being compromised by pleural effusion [14].

Systemic symptoms are a consequence of cancer development. The most common systemic symptoms are weight loss, general weakness, haemoptysis, fever, cyanosis, and dysphagia [4]. Over 40% of patients had systemic symptoms, general weakness, and loss of weight. Eighteen percent of patients had fevers, and 9% of patients had haemoptysis [13]. Similar data were found by Chernow, Sahn [4] and Baburao and assoc. [15]. The patients with MPE had chest pain in 32% cases, compared to 11% of patients with benign effusions, while the patients with benign effusions were more commonly found to have pleuritic pain [51 versus 24%]. Fever was more common in the patients with benign effusion (73 versus 37%) [8].

Massive pleural effusion can compromise cardiac function. It has been proven that massive pleural effusion can lead to the right ventricular diastolic collapse with consequential reduction of cardiac output. In artificial bilateral pleural effusions, right ventricular diastolic collapse appears at the pressure of about 4 mmHg [16]. This value of pleural pressure is also seen with the patients with massive pleural effusion [17]. Arterial-blood gases usually have clinically acceptable values.

On examining the patient, the absence of the pectoral fremitus, shortened and dull percussion sound, and weakened respiratory sounds are usually found. By auscultation above the fluid level, the change of breathing pattern (area of the compromised lung), that is, aegophony is heard. Conversing through auscultation of the affected side, increased resonance of voice can be heard. Experienced doctors think that dullness to percussion and aegophony are two most common findings that are present in over 90% of patients with pleural effusion. Above the area of dullness to percussion, humid sounds are heard auscultatorily [18]. Contralateral displacement of the trachea could be found in massive effusion.

3. Paramalignant pleural effusion

The main characteristic of PMPE is that the lung cancer had been previously diagnosed, and that malignant cells had not been identified in the effusion either cytologically or pathohistologically. These effusions are not a sign of malignant disease spreading to the pleura [3].

PMPEs are a direct consequence of local or systemic effect of tumour. Pulmonary infection distally from partial or complete obstruction of bronchi could be a cause of parapneumonic effusions. Obstruction of main or lobar bronchi by neoplasm leads to consequential atelectasis of the corresponding part of the lung. In order to compensate for the lost volume, the remainder of the lung must additionally expand or the hemithorax must be contracted. This sequence of events results in lower intrapleural pressure. Low intrapleural pressure is an additional factor of more intensive fluid accumulation.

Furthermore, the incidence of pulmonary emboli in malignant disease is not negligible, and pulmonary embolus can also be one of the causes for pleural effusion development. Additionally, certain chemotherapeutic protocols are a cause of increased retention of fluid in pleural space. Lymphatic obstruction is a common property of lung cancer and lymphoma and at the same time is a possible complication of radiotherapy which is a contributing factor of fluid accumulation in pleural space.

A considerable number of patients with malignant disease are malnurtured. Hypoproteinemia can in rare cases lead to transudative pleural effusion. In malignant disease, metastatic changes on the pericardium can be found. Pericardial effusion leads to the increase of hydrostatic pressure in systemic and pulmonary circulation which leads to transudative pleural effusion development [19].

In around 5% of patients with lung cancer, PMPEs are diagnosed. Frequency of PMPE in squamous cell carcinoma is 4.5%, in adenocarcinoma 6.2% and in SCLC 6.5%, so they are equally present in all pathohistological types of lung cancer [7, 21].

In 67% of patients, PMPEs are moderate or massive. They are mostly serous or cloudy (60%), and haemorrhagic effusions represent 21.3% of all PMPEs [7, 20].

3.1. Pleural fluid analysis

Compared to the MPE ratio of LDH—E/S (effusion/serum) is higher in PMPE, but not significantly higher. This can be interpreted with the help of the fact that in PMPE, parapneumonic

effusion (inflammation is followed by high values of LDH in effusion) is diagnosed in 18.3% of patients. Significant differences in other biochemical characteristics (glucose, proteins, and cholesterol) were not found either [7].

Compared to MPE, total number of cells, eosinophils, and PMN [polymorphonuclear cells] is higher in the group of patients with PMPE, but not significantly. Lymphocytes and PMN dominate in the differential picture in PMPE. Percentage of PMN is usually below 25%, but cases when they dominate are not rare, for example, in secondary pleural inflammation. In PMPE, eosinophils are found in 51% of patients diagnosed with PMPE. The percentage range of eosinophils in pleural fluid ranged from 1 to 24% [7].

3.2. Management of paramalignant pleural effusion

PMPEs are not an absolute contraindication for operative treatment. It is a therapeutic challenge to establish the optimal therapeutic protocol for the patients who are diagnosed with lung cancer and ipsilateral pleural effusion in which no malignant cells are found cytologically. Rodriguez-Panadero [21] performed thoracoscopy on 21 patients with lung cancer and paramalignant effusion. After thoracoscopy, thoracotomy was indicated in five patients. Invasion of mediastinal lymph nodes was found in all five patients. In another study, five patients out of 73 with PMPE have survived long term after surgery [22]. It can be concluded that in the patients with PMPE, thoracoscopy and CT of the thorax should be firstly done for the evaluation of mediastinal lymph nodes. In the case of enlarged lymph nodes, mediastinoscopy is indicated. In the patients with negative thoracoscopy, even if lymphatics are not enlarged, explorative thoracotomy is recommended. Before resection, lavage of pleural space with cytological analysis of the obtained material should be performed. One study that encompassed more than 1200 patients found that in patients with lung cancer without an effusion undergoing surgical resection with curative intent, 5.3% of patients had positive cytological findings of the pleural fluid lavage at the time of thoracotomy before surgical resection took place [23]. In PMPE, most commonly performed therapeutic procedures are thoracocentesis (51%) and pleurodesis (39%). Thoracotomy was done in two (6%) patients [7].

4. Malignant pleural effusion

Malignancy is the most common cause of massive pleural effusions opacifying the entire hemithorax and of large pleural effusions opacifying two thirds of a hemithorax. MPE is an end-stage sign of malignant disease. Sometimes MPE can be the first clinical sign of a tumour, given that often lung cancer are not detected in the beginning of disease development. In a retrospective series of 766 patients, carcinoma was the cause of 55% of massive and large pleural effusions [24]; other causes included tuberculosis effusion and pleural empyema.

In older age groups (>60 years old), malignant pleural effusions are the most common cause of exudative effusions and they are often the first clinical manifestation of disease (**Figure 1**) [3, 5]. Diagnosis of malignant effusion is established by the identification of malignant cells in effusion or pleural tissue. Pathohistological and/or cytological investigations are not of credible diagnostic significance until malignant cells are defined.

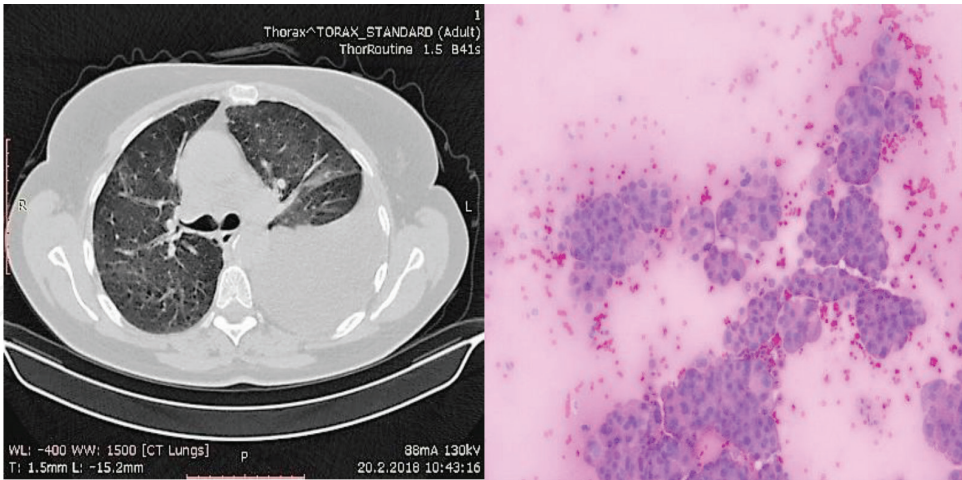


Figure 1. Pleural fluid sample containing cells of adenocarcinoma. N.B.—Origin of the primary tumour is unknown.

In over a half of MPE in men, the effusion is caused by lung cancer. MPEs appear in all cell types of lung cancer [3]. Incidence of MPE in lung adenocarcinoma is significantly higher in comparison to other pathohistological types of cancer. Thirty one percent of patients (out of 96) with lung adenocarcinoma developed a MPE, while 8.6% of patients (out of 404) with squamous cell carcinoma and between 7 and 10% with patients with small-cell carcinoma developed a MPE [7, 25–27].

The next most common causatives of malignant effusions are lymphoma and leukaemias (20%). Seven percent of MPE are a result of spread of gastrointestinal system cancer, 6% of genitourinary system and 11% of tumour are of unknown primary source [28]. Incidence of MPE in regards to primary tumour localisation is given in **Table 1**.

In women, around 40% of MPE is a direct consequence of spread of breast cancer. In about 50% of patients with breast cancer, pleural effusion is developed during evolution of disease [29]. Twenty percent of effusions are the consequence of genital tract tumour spread, 15% of lung malignoma, 8% of lymphoma or leukaemia, 3% of melanoma, and 9% of tumours of unknown primary source.

Primary tumour localisation	Incidence %
Breast	26–49
Lung	10–24
Lymphoma	Up to 24
Non-Hodgkin lymphoma	13–24
Ovary	6–17
Hodgkin’s disease	Up to 13

Table 1. Causes of malignant pleural effusions.

4.1. Pathophysiology of malignant pleural effusions

Malignant tumours can lead to pleural effusion development either by direct or indirect spread of the disease. In post-mortem studies, malignant disease of the pleura without an effusion was found in 40% [30] to 45% [6] of cases. Pleural effusions in malignancy most likely develop due to increased entry of fluid into pleural space and decreased evacuation of liquid from the pleural space. Increased transport of liquid into pleural space occurs due to increased permeability of the pleural vessels by direct invasion of the tumour cells, vasoactive and inflammatory cytokines. Increased permeability of pleural vessels can also be caused by injury, infection, pulmonary embolus, pulmonary infarction that causes movement of liquid from lung to pleural space by increased hydrostatic forces caused by venous obstruction [31].

Pleural liquid and protein are largely resorbed by the lymphatic system of the parietal pleura. The exit of fluid from pleural space could be decreased by several mechanisms that reduce lymphatic drainage. Lymphatic obstruction at any point, from the stomata of parietal pleura to mediastinal lymph nodes is a dominant cause of increased accumulation of pleural fluid [3, 20]. Insufficiency of lymphatic drainage appears for two reasons. The first one is that the transport of liquid from pleural space through stomata and lymphatic vessels of parietal pleura is disabled because of the presence of metastases and other reason, as the lymphatic vessels of parietal pleura are mostly drained by mediastinal lymph nodes. So, neoplastically changed mediastinal lymph nodes decrease the clearance of pleural cavum thus contributing to additional accumulation of fluid [32]. Obstruction of thoracic duct by malignant tumour can also be a cause of pleural effusion development. In these cases, a chylothorax develops. Chylothorax is the most common complication of mediastinal tumours, mostly lymphoma (in 50%). Furthermore, chylothorax is a complication of surgery (20%) and trauma to the thorax (<5%) [33].

In atelectasis pleural pressure is lower due to bronchial obstruction and therefore the exit of fluid from pleural space is reduced. In superior vena cava syndrome, pleural liquid drainage is reduced due to elevated central venous pressure.

Cellular and molecular mechanisms of localisation of pleural metastases are still mostly unclear. From visceral pleura malignant cells spread to parietal pleura, where they multiply [20]. Pleural metastases are also found on visceral and parietal pleura, while isolated metastases of parietal pleura have never been identified. From visceral pleura, malignant cells spread on parietal pleura [3]. In the process of pleural metastase development, several steps are necessary. First, malignant cells must leave the primary tumour. For this step, deregulation of cellular adhesion is necessary. Deregulation of cellular adhesion depends on the changes in the extracellular matrix and the change of expression degree of integrin with simultaneous increase of cell motility. By leaving the primary tumour, tumour cells via vascular or lymphatic structures (they can cause different haemodynamic and immunological changes in these structures) find their way towards distant organs or lymph nodes. With the help of video microscopy, it has been shown that a great number of circulating tumour cells (80%) stay alive even up to 3 days after their entry, both into circulation and/or extravascular space. Only small subgroups of cells (0.07%) can form metastases [34].

Control of extravascular cell growth is crucial in forming of metastases. Formation of pleural metastases is probably mediated by the interaction of mesothelial and neoplastic cells. Tumour activated mediators (VEGF, ligand for CC-sequence of chemokines CCL2 and TNF) stimulate the accumulation of inflammatory cells [35, 36]. IL-5 stimulates the development of MPE, accumulation of Eo as well as myeloid suppressor tumour-activating cells [37]. On the other hand, tumour cells activate proinflammatory and proangiogenic transcription programs controlled by nuclear transcription factor (NF)-kB [38] and signal transduction of transcription activator (STAT)3 [39]. Tumour necrosis factor (TNF), interleukin 6 (IL-6), and osteopontin (OPN) participate in positive reverse coupling (povratna sprega) regulating the activation of tumour NF-kB/STAT3. The end result of these events is the formation of MPE [35]. Furthermore, stimulated mesothelial cells secrete different factors, such as chemoattractants, chemokines, and platelet-derived growth factor (PDGF). These products facilitate the appearance of metastases. Simultaneously, the production of adhesion molecules is increased, such as intracellular adhesive molecules [ICAM-1] and vascular molecules of cell adhesion (VCAM-1) which, in vitro, in contact with cancer cells secrete metalloproteinase [40].

And finally, continuous growth of metastatic foci depends on angiogenesis. Vascular endothelial growth factor (VEGF) stimulates proliferation and migration of endothelial cells. At the same time, invasion of pleural space by malignant cells and VEGF expression from tumour cells is necessary for the formation of pleural liquid [41]. Angiogenesis is the primary process that disables the growth and progression of tumour [42]. Yano et al. [41] used human cells of pulmonary adenocarcinoma and squamous cell cancer, with different invasive properties and different levels of VEGF expression, and they have proven that invasion of pleural space by malignant cells and VEGF expression from tumour cells is necessary for the formation of pleural fluid. VEGF is one of the most powerful known chemokines that directly affect the increase of vascular permeability [42]. In comparison to tuberculosis effusions and transudative effusions, the concentration of VEGF is significantly higher in malignant effusion [42, 43]. The average value of VEGF in malignant pleural effusion is significantly higher than in pleural effusions that are a consequence of congestive cardiac failure [41].

Malignant effusion in comparison to benign incidence of CD4+ cells is significantly increased [44]. Accumulation of immunosuppression and protumour CD4+ lymphocytes contributes to weakening of the immune response and simultaneous growth of tumour cells [45].

On development of pleural metastases, tumour cells disseminate onto the mesothelial surface or malignant cells penetrate the subserosa. When the mesothelium is encompassed by the tumour, 'excess' of tumour cells appears in the pleural fluid. However, when only submesothelium is infiltrated by the tumour, there is a small number of malignant cells in pleural liquid. In these cases, malignant cells are rarely identified in pleural fluid, that is, thoracocentesis does not have any diagnostic significance [46, 47]. Infiltration of pleura by tumour results in reactive changes of mesothelium, that is, fibrosis. In advanced stage of disease, disposal of collagen into submesothelial pleural tissue is increased, which is at least a part of the cause of low values of pH and glucose in the effusion.

Another, and less likely mechanism of metastases development is by direct invasion of pleura by tumour, whether it is lung or breast cancer. In some cases, spread of tumour to the pleura is evident, and in spite of this, the effusion does not develop. For example, effusion rarely

appears when pleura is invaded by sarcoma. One of the properties of sarcoma is the absence of lymphogenic metastases [20].

Bilateral metastases in lung cancer are usually indirect evidence of the primary neoplasm spreading to the liver and of subsequent disease dissemination to the lungs. However, if the lungs are not the primary source of carcinoma, this implies that the changes on pleura are a tertiary consequence of metastasis spreading from the liver [4, 19].

4.2. Pleural fluid analysis

Pleural effusions in lung cancer are usually classified as exudates [4, 48]. In 5–10% of cases, the pleural effusion is a transudate [4, 54]. Transudative effusions are more likely when the lymphatic drainage is obstructed by the tumour and in atelectasis caused by bronchial obstruction or congestive cardiac failure [31]. Malignant cells can be found in transudative effusions as well. Macroscopic MPEs can be serous, serosanguinous, and haemorrhagic. Erythrocyte count in pleural fluid is often between 30,000 and 50,000/ μ l [48]. Erythrocyte count over 100,000/ μ l, in the absence of trauma, indicates a probable diagnosis of malignant disease. Direct invasion of blood vessels, occlusion of venules, increased permeability of capillaries due to vasoactive chemokines and cytokines, occlusion of venules usually result in a bloody, malignant pleural effusion.

In more than half of malignant effusions, lymphocytes are present in 50–70% range, but are typically present in lesser amount than they occur with tuberculosis pleurisy (usually $\geq 80\%$) [12, 49]. In TBCPE, the number of lymphocytes was $153,696 \times 10^4$ versus $95,414 \times 10^4$ /ml in MPE [7]. In order to differentiate between tuberculosis and malignant effusions, determining adenosine deaminase (ADA) presence in the effusion is of significance. The level of ADA greater than 70 U/l in effusion indicates to tuberculosis aetiology, while the ADA level below 40 U/l excludes the tuberculosis aetiology [50, 51]. Although the cause of lymphocytosis is unclear, the lymphocytes that are most prevalent are T lymphocytes that have a role in local defence systems against tumour invasion of the pleural cavity. In vitro, lymphocytes of malignant pleural effusions spontaneously secrete lymphokines [52]. Mesothelial cell percentage in malignant effusion varies ranging from few percent to a large percentage of total cells. Mesothelial cell abundance occurs early in the course of infiltration of the pleura, well before pleural fibrosis and marked tumour infiltration. Fewer mesothelial cells are seen in advanced stages of pleural metastases due to pleural fibrosis.

The percentage of PMN is usually below 25%, even though often PMN can dominate the percentage, as in secondary inflammation of pleura. Eosinophils are present in up to 36% of malignant effusions [7]. The percentage in which eosinophils are a significant finding in pleural liquid is considered to be higher than 10%. In MPE, eosinophil percentage ranges from 1 to 52% [7]. Eosinophilic pleural effusion is the most common in malignant disease (34, 8%) [24], which is then followed by infections (19, 2%), effusions of unknown aetiology (14, 1%), post-traumatic effusions (8, 9%), and effusions (23%) in other diseases.

Usually, eosinophilia is related to the presence of blood or air in pleural space. Eosinophilic effusions reappear even after repeated thoracentesis [53]. Good correlation was found between IL-5 levels and the number of eosinophils in pleural fluid [54]. In MPE, compared to

other cells, malignant cells are rarely found. Significant concentrations of proteins are found in pleural fluid. Nevertheless, the total amount of protein transported from pleural space is lesser than the amount of protein transported in tuberculosis effusions, effusions in pulmonary embolism, and congestive cardiac failure.

Chronic pleural effusions (CPE) are very rarely found to be transudates. Characteristic biochemical property of CPEs is that they have low pH and low glucose concentration, while they have a large protein concentration. The ratio of pleural protein to serum protein can be found to be low, and nevertheless, the effusion would still be classified as an exudate. If in exudative effusion only the LDH criterium is positive, this points to the diagnosis of malignancy [48, 55, 56].

In one third of MPE, pH is less than 7.30 (ranging from 6.95 to 7.29) [57]. Effusions with low pH value have a high concentration of glucose (<60 mg/dl) and pO_2 , and additionally a high concentration of lactate and pCO_2 . Glucose concentration can be rarely reduced to the value of 5 mg/dl and it usually ranges from 30 to 55 mg/dl [55]. Malignant effusions with low values of pH and glucose characteristically have a longer evolution of up to several months and they usually follow the fast tumour and pleural fibrosis [54]. Pathologically altered pleura reduce glucose entry into the pleural space and at the same time disable the transport of metabolic products. The end result of this disorder is local acidosis [56]. Low level of LDH in effusion indicates a higher possibility of negative pathohistological results. In effusions with high LDH level, the percentage of positive biopsies is higher [58].

Pleural fluid amylase concentration is found to be elevated in 10% of patients diagnosed with a MPE. However, the origin of amylase in pleural fluid is not pancreatic but is found to be salivary instead. In a series of consecutive effusions, a very high amylase level in malignant pleural fluid (>600 IU/L) was found to be a poor prognostic factor [59].

4.3. Tumour markers in pleural liquid

Biological markers of malignancy are yet to be identified, but may be identified in the future as the molecular biology of cancer is better understood. Pleural fluid biomarkers could potentially assist the cytological diagnosis. Unfortunately, biomarkers have been found to have indeterminate specificity and sensitivity which has led to overlap between malignant and benign conditions. An approach that has been used is to combine the tumour markers to improve the diagnostic yield. However, the diagnosis of malignancy can also be reached by using the clinical characteristics—duration of symptoms for more than a month, absence of fever, CT thorax findings of malignancy, and serosanguinous fluid [60].

4.3.1. Carcinoembryonic antigen

It has been concluded in several reports that determining the CEA level in pleural fluid is useful in establishing the diagnosis of malignant pleural effusion [61, 62]. CEA level below 10 ng/ml is usually found in lymphoma, sarcoma, and mesothelioma. CEA higher than 10 ng/ml could indicate a malignant disease; however, it does not have diagnostic significance, and routine measuring of CEA is not recommended.

4.3.2. Carbohydrate antigen

It is known that three different carbohydrate antigens (Ca 15-3, CA 19-9, and CA 72-4) are present in malignant disease. These antigens have been studied in order to differentiate malignant and benign effusions [63]. Comparing the levels of these three antigens in malignant and benign effusions, there is a significant overlap of the obtained results. Hence, this test is not sensitive enough and it is not used in routine diagnostics.

4.3.3. Sialyl stage-specific antigen-1

Sialyl stage-specific antigen-1 is a carbohydrate antigen present in malignant disease. Patients with positive cytological findings of pleural fluid to adenocarcinoma cells have higher values of this antigen in effusion in comparison to effusions of other aetiologies [64]. However, simultaneously, significant overlap of value levels of this marker was recorded, and therefore sialyl stage-specific antigen-1 in effusions of unclear aetiology does not bare a diagnostic significance.

4.3.4. Cytokeratin-19 fragments

Cytokeratin 19 (CYFRA 21-1) is the main component of cytoskeletal filaments of epithelial cells. It is significantly increased in malignant diseases. The level of CYFRA-21 higher than 100 ng/ml is present in around 60% of patients with carcinoma and mesothelioma [65]. A significant overlap has been found in CYFRE levels in both malignant and benign effusions, and therefore this test is not recommended in routine work.

4.3.5. Enolase

Enolase is a glycolytic enzyme present in extracts of neuroendocrine tumours. In pleural effusions in small cell lung cancer, higher levels of enolase are found when compared to pleural effusions in non-small cell lung cancer and benign effusions [66], but as there is a significant overlap in measured enolase values establishing its presence has no diagnostic significance.

4.3.6. Squamous cell carcinoma antigens

Squamous cell carcinoma antigen (SCC) has been used as a serum marker for squamous cell carcinoma. In the greatest number of patients with pleural effusion in malignant disease, a low level of this marker was found. This marker was positive in 7 out of 11 patients (64%) with squamous cell carcinoma. However, SCC values are very high in some benign effusions as well; thus, SCC is not used in squamous cell carcinoma diagnostics [66].

4.3.7. Oncogenes

Oncogenes are closely related to the development of malignancy, and one of the hypotheses has suggested that in the pleural fluid of patients with pleural malignancy cells containing oncogenes are present. In 11 (34%) of malignant effusions, protein p53 has been detected, and should be noted that it has not been found in any non-malignant effusion [67].

There is no significant difference in CMYC oncogene expression between malignant and benign effusions [68]. CHARAS oncogene has been detected in 21 out of 24 malignant effusions, but it has also been found in 6 out of 16 benign effusions (37%), and therefore its diagnostic utility is limited [69].

4.3.8. *Hyaluronic acid*

Pleural fluid of patients with mesothelioma is sometimes extremely viscous. Increased viscosity of liquid is a consequence of hyaluronate, that is, hyaluronic acid presence. Hyaluronic acid level higher than 1 mg/ml indicates mesothelioma diagnosis. In no other aetiology of pleural effusion, hyaluronate level higher than 0.8 mg/ml was found. Sensitivity of this test for malignant mesothelioma is 56% [70]. Average values of hyaluronic acid in mesothelioma are comparable to values of hyaluronic acid present in pleural effusions in adenocarcinoma [71].

4.3.9. *Lectins binding*

Lectins are a class of glycoproteins of non-immune origin which bind specifically to the carbohydrate group in different biological products. Lectin binds much easier to adenocarcinoma cells compared to reactive mesothelial cells or mesothelioma cells [72]. These authors could not find significant differences in lectin binding between mesothelioma cells and reactive mesothelial cells.

4.3.10. *Flow cytometry*

Flow cytometry is a method of quick measuring of nuclear DNA. It has been postulated that this method would enable differentiation of benign from malignant cells, taking into account that malignant cells have numerous chromosomal abnormalities (aneuploidy) and consequentially abnormal DNA content (DNA aneuploidy). However, aneuploidy is present in benign effusions as well [73]. Flow cytometry is used in the identification of superficial lymphocyte markers and it has found the use in diagnosis of lymphoma [68].

4.3.11. *Chromosomal analysis*

Malignant cells have a higher number of chromosomes with structural abnormalities, such as translocation, ascension, dissension, discention, inversion, and isochromosomy [70]. The place of chromosome analysis in routine examination of pleural effusions remains to be established.

4.3.12. *Association of mRNA expression in metastatic malignant effusions*

Alternative diagnostic methods are still needed to assist in the diagnosis of pleural effusions. The supernatant of samples of pleural effusion might contain useful information such as nucleic acids and proteins. MicroRNAs that are circulating and cell free have been identified as potential biomarkers of cancer. MicroRNAs are heavily involved in processes of development, cell survival, carcinogenesis, and apoptosis. Hence, it is likely that they play a considerable role in modulating sensitivity and resistance to anticancer medications [74].

However, potential applications and the existence of cell-free microRNA in pleural effusion samples are uncertain. MicroRNA (miRNA) is a group of short RNAs that regulate expression of proteins post-transcriptionally by binding to the 3'UTRs target mRNAs. As MicroRNAs are involved in cancer development, the expression of a specific miRNA profile may suggest the disease status, prognosis, and response to chemotherapy agents.

Wang et al. [75] have used real-time quantitative PCR to analyse related gene expression in 46 patients with malignant effusion. Data were prospectively collected from gastric cancer, non-small cell lung cancer, and gynaecological cancer patients. Cancer cells that are viable and obtained from malignant effusions are tested for sensitivity to docetaxel and cisplatin using ATP-TCA assay. The authors have concluded that BRCA1 (breast cancer susceptibility gene 1) and ERCC1 (excision repair cross-complementing group 1) miRNA expression levels are in correlation with in vitro chemosensitivity to docetaxel and/or cisplatin in malignant effusions of gastric cancer and non-small cell lung cancer patients. Additionally, combining ERCC1 and BRCA1 may produce better results predicting the sensitivity to cisplatin than when only a single agent is considered.

4.4. Prognosis of malignant pleural effusion

By diagnosing a malignant effusion, prognostic information is obtained simultaneously [57]. Mean survival time of patients with lung cancer and MPE is between 3 and 4 months [76]. Multivariable analysis has demonstrated that shorter survival time was found in patients with a high level of serum CRP, low values of albumins, serum proteins, distant metastases and those patients who did not have chemotherapy [77]. Disease progression and poor prognosis can be related to the immunosuppressant effect of tumour and functional damage of the immune system.

In non-small cell carcinoma, mean survival time in patients with stage IIIb, IIIb with pleural effusion and stage IV was 15.3, 7.7, and 5.5 months, respectively [78].

From the time malignant effusion is diagnosed, patients with lung, stomach, and ovarian cancer survive for only several months, while survival time in patients with breast cancer is longer—several months or years, depending on the response to chemotherapy [4, 55]. Survival time of the patients with lymphomatoid effusion is between the survival time of patients with breast cancer and cancers of different organs.

Prognosis of malignant effusion depends on the stage of the disease and contributing factors (Table 2) [55], which is of crucial importance for choosing the treatment modality. LDH criterion and pleural fluid pH in malignant effusions are important prognostic indicators. Poor prognosis is indicated by high LDH effusion/serum ratio, high level of LDH in effusion, and low pH of pleural fluid [55]. When pH and glucose levels are found to be low in a malignant pleural effusion (below 7.30 and 60 mg/dl, respectively), the survival time is found to be less for an average of 2 months when compared to those patients who have normal values of glucose and pH-average of 10-month survival time [76].

The only true predictive marker of mortality might be the performance status at the time of diagnosis. A Karnofsky score of more than 70 is associated with a median survival time of 13.2 months, while a Karnofsky score of less than 30 is associated with a median survival time of 1.1 months.

Tumour related	Non-tumour related
Extensive invasion of mediastinal lymph nodes	Tuberculosis or fungal infection
Parapneumonic effusion (obstructive pneumonia)	Immunological disorders: rheumatic, allergic, etc.
Pericardial effusion as a consequence of malignant disease	Pulmonary embolism
Previous mediastinal radiotherapy	Congestive cardiac failure
Malignant ascites	Parapneumonic effusion as a consequence of an unrelated pneumonia
Pulmonary embolus	Organ failure that is not a consequence of cancer or cancer treatment

Table 2. Factors contributing to the spread of pleural effusion.

4.5. Imaging

4.5.1. Chest radiographs

For documenting the presence of pleural fluid in pleural space, the most practical diagnostic test is conventional chest radiography [79]. Pathological changes of the pleura are commonly easily diagnosed by appropriate radiological modalities.

The distribution of fluid in pleural space is completely dependent on the laws of gravity. Fluid is firstly accumulated in basal parts of the hemithorax, that is, between the lower surface of the lung and diaphragm. When a large amount of fluid accumulates, the fluid starts spreading to anterior, posterior, and lateral costophrenic sinuses. The thickness of the fluid is greater laterally. The line of the border discretely fades on moving medially and ends in the mediastinum with a meniscus shaped line. On lateral radiographs, upper border of pleural fluid is semicircular, that is, the upper border is higher both anteriorly and posteriorly, while it gently descends in the middle part. A small amount of fluid seen on the chest radiograph is not indicative of a pleural effusion, as the diaphragmatic configuration is unchanged. During accumulation of a larger amount of pleural fluid, costophrenic angles are the first to be filled. Costophrenic angles are filled only after the quantity of fluid in sub-pulmonary space exceeds 175 ml s.

‘Middle lobe step sign’ can be often seen on a lateral view. The ‘middle lobe step sign’ is explained by the fact that the fluid firstly accumulates in the lower lobe, as it is the lowest of the pulmonary lobes. The middle lobe remains unchanged and its volume is preserved. Pleural fluid is most commonly evident in the posterior parts of the chest.

In massive pleural effusion, the sheer weight of the fluid can be a cause of inverted diaphragm, so much so that the normal convex appearance becomes concave. Inversion of the hemidiaphragm is more commonly seen on the left side. On diascopy of the inverted diaphragm, paradoxical movements are evident, that is, it rises on inspiration and descends on expiration [9].

It is common practice for the chest radiographs to be performed while the patient is standing. However, in critically ill patients, the chest radiographs can be only performed while the patient is lying down, and this could lead to the pleural effusion not being diagnosed. This is due to the fact that pleural fluid is being pulled by gravity and consequently localises in the posterior parts of the thoracic cavity.

Characteristic signs of a pleural effusion on chest radiograph when the patient is lying down are: blunting of the costophrenic angle, increased density of the part of the lung, loss of diaphragmatic silhouette, the presence of apical cap, elevation of a hemidiaphragm, difficulty in spotting vascular structures of the lower lobe, and accentuated small fissure [80]. These signs are not present in patients with a small or moderate pleural effusion.

Serial radiographs of the chest while the patient is lying down after moving the patient from one side to the other side can indicate a presence of mobile fluid and absence of loculations which in malignant pleural effusions enables the determination of a possible pleurodesis site [81].

Using the above mentioned radiological signs, it is possible to differentiate increased density of a pleural effusion from infiltrates for example. First, if the cause of increased density is a pleural effusion vascular structures of the lung will be visible on the radiograph. Any other intra-pulmonary process would cause an obliteration of vascular structures—‘the silhouette effect’. Second, if pleural effusion is the cause of increased density, the visible change will be entirely homogenous. Infiltrates caused by an intrapulmonary process are usually less homogenous. Third, air bronchogram is only present when the increased density is a consequence of parenchymal infiltration.

Typical localization of fluid in pleural space of healthy lungs depends on the reverse action of elastic forces. Compared to other parts of the lung, the parts of the lung that are below the effusion exhibit different characteristics of elastic forces. Part of the lung above which the fluid is accumulated has a higher intensity of action reverse elastic forces. Accordingly, atypical localisation of fluid in the pleural space indicates that the part of the pulmonary parenchyma below the effusion is altered. Encapsulated fluid usually produces an image of a bi-convex lens or adopts a lenticular shape. For instance, if lower lobe pathology increases the intensity of action of reverse elastic forces, the fluid will accumulate posteriomedially. Characteristically, the opacity is higher in the axillary line. In some cases, a pleural effusion can mimic middle or lower lobe atelectasis. On the lateral radiographs, the upper border of the density is parallel to the main fissure and is higher in the posterior segments of the thorax, and on moving anteriorly, it descends into the costophrenic sulcus. Lobar or segmental lung collapse can be a cause of pleural effusion development. In these cases, the effusion can mimic pleural adhesion [82].

When the whole hemithorax is opacified, the first priority should be to determine the position of the mediastinum, as the position of the mediastinum depends on the intrapleural pressure. Lower intrapleural pressure will shift the mediastinum to the ipsilateral side of the effusion, (**Figure 2**) while if the pressure is higher on the side of the effusion mediastinum will shift contralaterally, (**Figure 3**) assuming that the mediastinum is not infiltrated by a tumour or an infiltrative process, that is, that it is not fixed. When the mediastinum is fixed, there is no mediastinal

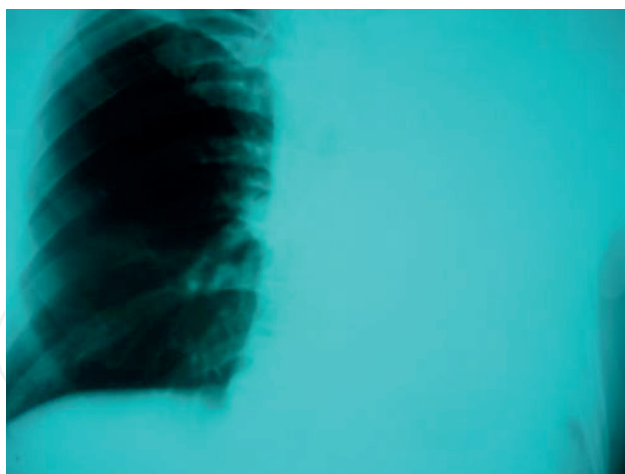

Figure 2. Atelectasis of the left lung with ipsilateral shifting of the mediastinum.

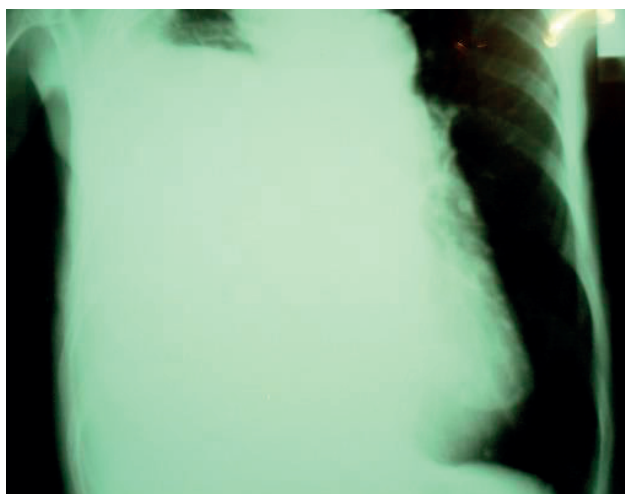

Figure 3. Massive pleural effusion with contralateral shifting of mediastinum.

shift seen. If the mediastinum shifts to the ipsilateral side of the effusion, it can be concluded that the underlying process is an expansive lung disease. Occasionally, in complete atelectasis contralateral lung is a cause of increased retrosternal light, which is clearly seen on a lateral radiograph. This radiological picture corresponds to complete obstruction of the ipsilateral bronchus by a neoplasm. In obstruction of a bronchus, thoracocentesis is not indicated as it is not necessary for diagnostic work up and as it carries a risk of additional increase of the negative intrapleural pressure. Possible complications include pneumothorax and re-expansive pulmonary oedema. In an obstructive lesion, evacuation of a large amount of fluid [more than 1000 ml] is only recommended if a simultaneous measuring of intrapleural pressure is possible [17].

4.5.2. Computed tomography [CT]

CT is efficient in diagnosing pathological alterations of the pulmonary parenchyma and changes that belong to pleural diseases (**Figure 4**). In comparison to standard radiography, pleural alterations are diagnosed much easier on the CT scan and are easily distinguished from the

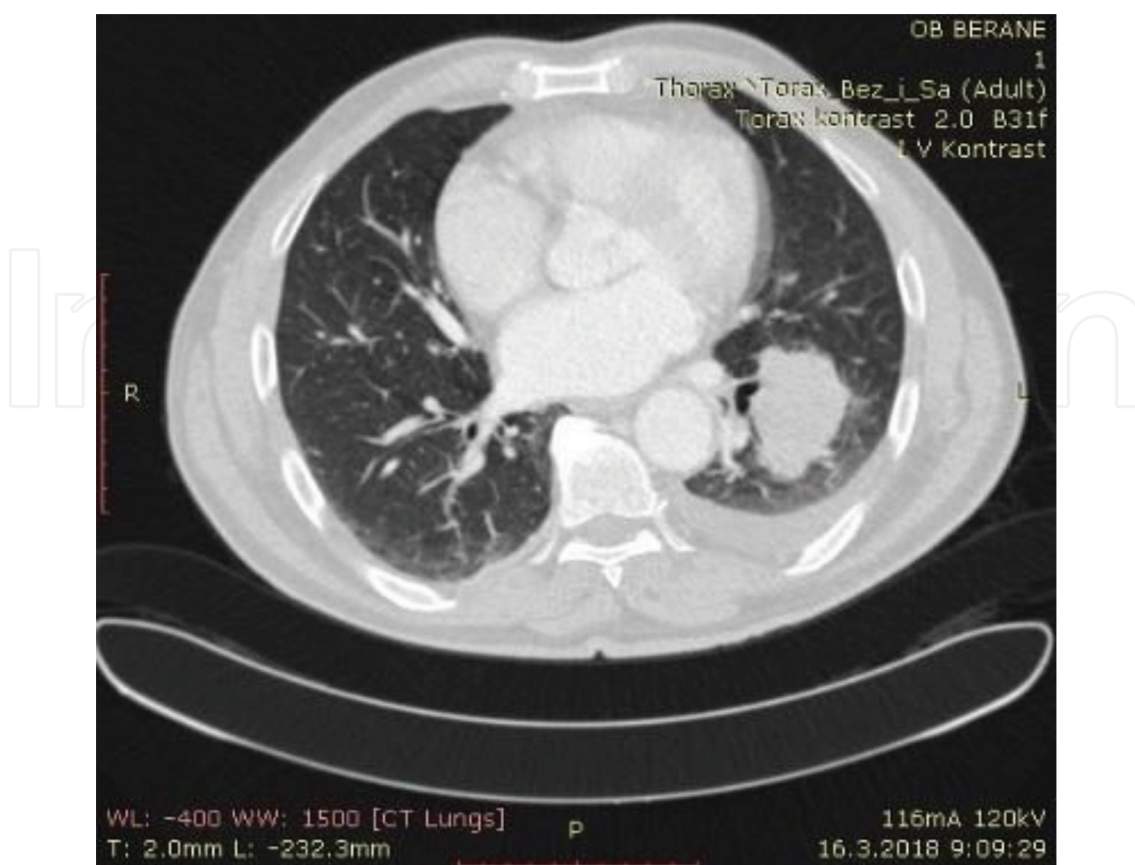


Figure 4. Lung cancer followed by an ipsilateral effusion.

pulmonary parenchyma and diseases that do not affect the pleura [83]. Collections of fluid or masses have a tendency to adjust to the pleural space. As in the radiograph, the angle between the lesion and thorax helps when trying to differentiate a pleural from a parenchymal change. If the angle between the lesion and thorax wall is sharp, then the change is likely to be a part of the lung parenchyma, while if the angle is blunt, then the lesion is more likely to be of pleural origin. Nevertheless, CT can also be inconclusive. The findings can be similar to the chest radiograph findings, especially when atelectasis or pneumonia are in question, or when a pleural collection forms a sharp angle with thorax wall. Free pleural fluid can form sickle-like opacities in the lowest and posterior parts of the thorax. Fluid collection that is loculated can be seen as a fixed, lenticular opacity. Thickening of the pleura almost invariably points to an exudative effusion [83]. Unreliable signs of pleural invasion are: absence of border area between pleura and primary lesion, blunt angle between the tumour and chest wall, and the presence of a pleural effusion. A probable sign of pleural invasion is if in addition to rib destruction simultaneously the distance between the surface of the tumour and wall of the thorax is less than 3 cm.

The typical features of malignant pleural disease are nodules, irregularity, and pleural thickening >1 cm. It was found that these pleural characteristics discriminated well between malignant and benign disease in a prospective chest radiograph study of 40 patients with suspected malignant effusions, with a sensitivity of 84% and specificity of 100% for malignancy [84]. However, pleural thickening alone was not found to be specific as it was found in malignancy as well as in empyema. Albeit, the presence of pleural nodules was found to be highly specific, it was found

to have only 17% sensitivity—17% of patients with malignant effusion had associated pleural nodules. It is interesting that the half of the patient with malignant effusion had no pleural abnormalities on CT in this study [85]. In patients with lung cancer, even minimal pleural effusions can represent malignant involvement [86]. CT density coefficient is not specific enough to differentiate parenchymal lesion from a solid pleural mass or a serous effusion from blood or pus [87]. In these cases, ultrasound is the investigation of choice and has an edge over CT.

4.5.3. *Magnetic resonance imaging [MRI]*

Pleural effusion can be identified on an MRI scan; however, MRI is not advised for routine evaluation of malignant effusions.

Collections of pleural fluid are visible as areas of low intensity signal on T1 images, while signal is intensified on T2 images. MRI can sometimes enable the classification of a pleural effusion to transudate, chylothorax, empyema, but in essence, the information gained by MRI is usually insufficient to be of diagnostic use. However, its ability to produce excellent soft-tissue contrast can be useful for detailed evaluation of tumour invasion [88]. MRI is superior to CT in identification of solitary foci on the chest wall, changes of the endothoracic fascia and identifying the invasion of diaphragmatic muscles. MRI can be especially useful in evaluating apices of both hemithoraces.

4.5.4. *Positron emission tomography with F-18-fluorodeoxyglucose [PET]*

PET-FDG imaging accurately detected malignant pleural involvement and the presence of malignant pleural effusion in 16 out of 18 patients and excluded pleural metastatic involvement or malignant effusion in 16 of 17 patients—sensitivity of 88.8%, specificity 94.1%, and accuracy of 91.4%. PET-FDG imaging is a highly reliable and accurate non-invasive test that can differentiate benign from malignant pleural effusions and/or pleural involvement in lung cancer patients and CT findings of suspected malignant pleural effusion [89]. Nonetheless, this form of imaging may not be able to differentiate pleural malignancy from benign inflammation of the pleura, for example, caused by talc pleurodesis [90].

4.5.5. *Ultrasound*

Thoracic ultrasound can be done with any modern ultrasound machine. Curved ultrasound probe 5–7.5 MHz enables the examination of deep structures of the chest wall. Intercostal spaces are utilised as an acoustic window [91]. When using high frequency probe of 7.5–10 MHz, parietal and visceral pleura are usually seen as echogenic lines, not thicker than 2 mm (**Figure 5**). Diaphragm is visualised as a bright curved line moving upwards or downwards, depending on the respiration phase. High frequency probes improve the resolution in the fields close to source of the echo, enabling differentiation of cystic lesions from solid masses. Ultrasound properties of pleural fluid are best evaluated by changing the form of the fluid during respiration [10]. Ultrasound discovers the presence of fluid in pleural space with an accuracy varying between 87 and 94% [92]. An amount of liquid present in pleural space can be quantified by ultrasonographic examination. Calculated amount of liquid is in better correlation with real amount of fluid present if it is defined by ultrasonographic examination. Amount of liquid

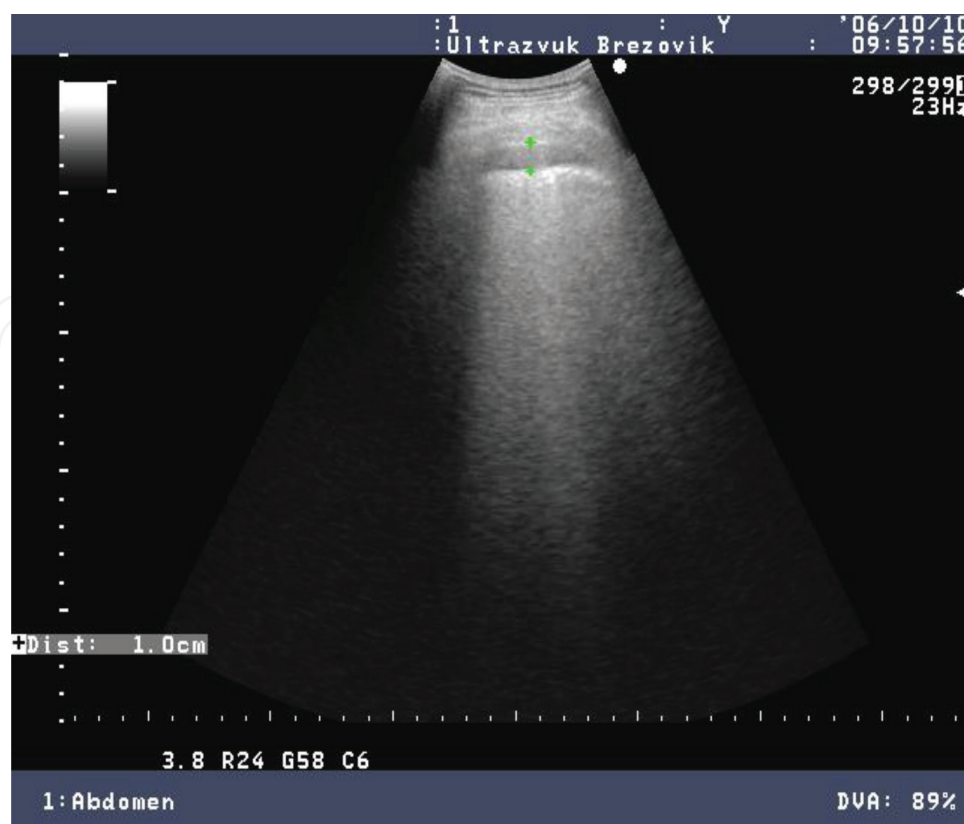

Figure 5. 'Comet tail' sign.

of 1000 ml on radiograms in lateral decubitus correlates to a 30-mm layer of liquid, while the same amount of fluid correlates to ultrasonographic thickness of 40 mm [93].

Ultrasound diagnostics is useful in determining a suitable spot for thoracocentesis, especially in loculated and small effusions [92, 94, 95]. Ultrasound is also helpful in therapeutic thoracocentesis for measuring effusion the depth of an effusion which makes this procedure safer. At thoracocentesis, the thickness of pleural liquid must not be less than 10 mm. Complications of ultrasound guided thoracocentesis are minimal [94].

Pleural thickenings are presented as constant regions of weak echogenicity. Differentiation of pleural thickening from effusion, tumour, and mesothelioma is uncertain. Respiratory dependent configuration change of identified lesion favours a pleural effusion, regular borders favour pleural thickening, and irregular borders favour a diagnosis of a tumour [96]. Plaques produce the image of focal zones of intensive reflection with dense posterior acoustic shadow and usually surrounding non-calcified pleural thickening.

Pleural masses are sonographically presented as masses of unclear limitation, weakly echogenic, nodal or linearly disseminated along the pleura. Malignant tumour of pleura can infiltrate the chest wall and it leads to poorly visible demarcation of pleural mass from the thoracic wall [97]. Pleural thickening over 1 cm brings forward justified suspicion of a malignant tumour. Accompanying pleural effusion is usually visible in a big field which spreads locally and is especially emphasised. The effusion is helpful in tumour identification and it enables differentiation of parietal from visceral pleura. Visceral pleural thickening is rarely

seen. In pleural mass, respiratory motions of lungs during the respiratory cycle are reduced. Very clear echogenic and irregular reflexes are visible on passing towards the ventilated area of lungs.

Metastases might appear as diffuse parietal pleural thickenings. These can be seen as weakly echogenic and moderately echogenic structures; they are oval and easily nodal.

4.6. Cytological and pathohistological examination of pleural fluid and pleural tissue

The percentage of positive cytological results has a wide range, which depends on the type and location of the primary neoplasm, the number of samples being examined, methods and way of sample processing. Results of cytological examination depend on pathohistological type of tumour, number of prepared samples, length of time sample is kept, and interest of cytopathologist.

Malignant cells have several characteristic properties which differentiate them from other cells. They can significantly vary in form and size. They are usually large. The diameter of the nucleus ranges up to 50 μm and their diameter is significantly bigger than, for example, the nucleus of mesothelial cells that are rarely bigger than 20 μm (**Figure 6**). For comparison, small lymphocytes have diameter up to 10 μm . Nucleoli of malignant cells are up to 5 μm in size. Nucleoli of non-malignant cells do not exceed 3 μm . Malignant cells have a high nucleocytoplasmic ratio. Morphological analysis itself is not sufficient for differentiation of adenocarcinoma cells from, for example, mesothelioma cells. Mesothelioma cells have a tendency to make papillary groups, and they are multinuclear, with atypia and cell to cell position. Adenocarcinoma cells have a greater tendency to form acini of similar structures. They can form big group of cells. Balloon-like cytoplasmic vacuolization is expressed [98].

Groups of 20 or more benign mesothelial cells can sometimes appear bizarre. Large, vacuolated cells of adenocarcinoma enable differentiation between these two entities. A small number of mitotic figures are often present in benign effusions and the presence of such picture does not point to malignant disease.

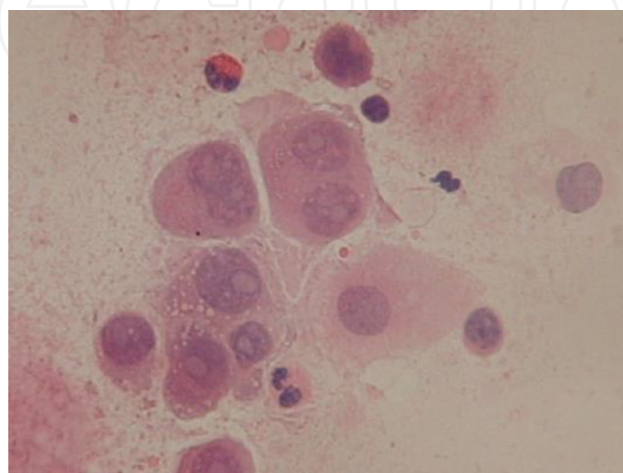


Figure 6. Atypical giant cells in pleural effusion.

Two most important histochemical tests commonly used are alcian blue staining and periodic acid-Schiff. Alcian blue staining enables the detection of acid mucins, which is a specific finding for mesothelioma. Alcian blue staining was positive in 14 out of 19 (73%) patients with mesothelioma, while it was negative in all the patients with adenocarcinoma [99]. Periodic acid-Schiff staining, after diastasis digestion (PAS-D), enables the detection of neutral mucins that have a diagnostic value for adenocarcinoma. PAS-D staining was positive in 27 out of 44 (61%) patients for adenocarcinoma, while it was negative in all patients with mesothelioma [100].

In differentiation of adenocarcinoma from mesothelioma, a whole palette of monoclonal antibodies is used. The same antibodies are found in the presence of benign mesothelial cells, adenocarcinoma, and malignant mesothelioma.

Immunohistochemical staining can be a useful diagnostic tool. Specific markers such as thyroid transcription factor 1 exhibit a high specificity for a primary lung carcinoma, whereas GATA3 has been advocated as a sensitive and specific immunostain for diagnosis breast cancer [101]. Cytological specimens are used for sequencing of mutations of epidermal growth factor receptor (EGFR), [102] and with the use of highly sensitive sequencing such as next-generation sequencing, these markers can be detected even when cytological examination affirms a low percentage of malignant cells or even no malignant cells [103].

Pathologist's challenge can be differentiating mesothelioma from both metastatic adenocarcinoma and non-malignant reactive mesothelium. Using a panel of immunohistochemical stains is now the standard for diagnosing mesothelioma, including using antibodies that stain positively for mesothelioma (WT1, cytokeratin 5/6, calretinin) and those that stain negatively (e.g. adenocarcinoma specific stains such as MOC-31, CEA, Ber-EP4, and B72.3) [104, 105]. However, it is of note that pleural liquid mesothelin levels can be elevated in a significant number of patients with malignant effusions other than mesothelioma, while mesothelin levels are not elevated in benign effusions. Hence, a high mesothelin level strongly suggests a presence of some form of malignancy [106]. The future of diagnosis might include genetic analysis—either for microarray characteristic of tumours or for characteristics of malignancy (microsatellite, aneuploidy, telomerase DNA methylation, and mutations) [107, 108]. As explained earlier, pleural cells genetic testing may lead to therapeutic choices; for example, establishing an EGFR mutation in malignant pleural cells can predict response to pertinent EGFR tyrosine kinase inhibitors, like gefitinib or erlotinib [102, 103, 109]. High throughput sequencing technology—a by-product of the Human Genome Project, enables rapid sequencing of either a small percentage of the genome that codes for expressed genes (the exome), or the whole genome. As all cancers are unique, the hope is that this could lead to patient-specific markers and subsequent therapies—for example, designing specific vaccines that 'drive' the immune system of the host to attack that patient's cancer [110].

In previously diagnosed neoplasms, pleural effusion cytology is positive in 50–90% of cases [112]. Falsely positive results range from 0 to 3% [111]. The absence of malignant cells in pleural effusion does not exclude malignancy and this infers the necessity of repeating the cytological investigations.

If repeated cytological analysis is negative, clinical observations and laboratory examinations do not point towards a probable aetiology of pleural effusion, and percutaneous blind biopsy is indicated (**Figure 7**).

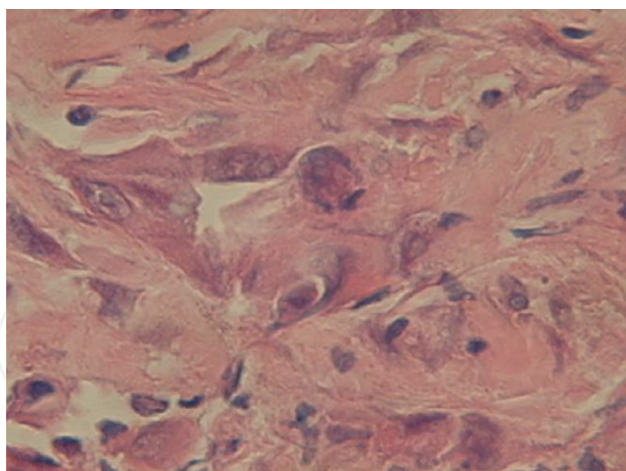


Figure 7. Adenocarcinoma invasivum pleurae HG2, NG3 (EMA $\times 400$).

In seven series of malignant pleural effusions published and analysed in the literature (over 500 recorded cases), cytological analysis of pleural fluid sample had a diagnostic significance ranging from 66 [47] to 76% [57]. Pleural biopsy had positive predictive value of 46% [8]. Combining of these two procedures, cytological and pathohistological analysis, disease was diagnosed in 73% of patients. These data indicate that cytology is the more specific method compared to pleural biopsy, while they also suggest that these tests are complementary and that small samples given by pleural biopsy can be falsely negative.

In a randomised study that compared CT-guided biopsy with closed pleural biopsy using an Abrams needle, CT-guided biopsy was notably more sensitive (87 versus 47%) with a superior negative predictive value (80 versus 44%) [113]. Thoracoscopy is a procedure that is well tolerated and at the same time allows excellent visualisation of the entire pleural surface.

Correct identification of metastatic disease of pleura in nearly 100% of cases is achieved by directed pleural biopsies [117]. This technique provides additional advantages, including the ability to provide the information about the tumour's gross appearance, to provide the information for staging, to drain the pleural space for talc pleurodesis, to lyse adhesions, and the ability to produce large biopsy specimens for genetic and immunohistochemical analysis for molecular markers (e.g. EGFR) if needed. In routine examination, pleural effusion analysis by electronic microscopy has a slight advantage over cytological examination [115].

5. Possible therapeutic modalities of malignant pleural effusions

Treatment of patients with malignant pleural effusion has to be in accordance with the disease prognosis. Asymptomatic patients do not warrant treatment; nevertheless, most patients will go on to develop progressive pleural effusions that will elicit symptoms and require treatment. However, some patients will reach a stable state of pleural fluid formation and removal and these patients not progress to a symptomatic stage.

According to therapeutic possibilities, the doctor's first step is to estimate the patient's performance status. In order to get a clear answer to the question of should the patient with malignant effusion be treated or not treated, the following questions must be answered. Do the current symptoms reduce the patient's quality of life? What was the response of primary tumour to radiotherapy or chemotherapy? What is the performance status? What is the expected survival time? What was the patient's response to initial thoracentesis? What is the liquid reaccumulation rate after evacuating thoracentesis? For how long was the patient asymptomatic after thoracentesis? Did lungs re-expand after drainage? Is the patient in a condition to tolerate intrapleural sclerotherapy?

If one is to follow this line of thought and principle, cooperation with oncologist, cardio-thoracic surgeon, radiotherapist, and everyone involved in the patient's treatment is necessary.

After diagnostic thoracentesis is performed, therapeutic thoracentesis follows (without intrapleural medication) which probably will not result in long-term control of pleural effusion [79, 116]. Possible complications of repeated thoracentesis are secondary infections, loss of proteins, artificial pneumothorax, effusion loculation, and trapped lung.

5.1. Significance of specific oncological treatment

One of the important principles of oncological treatment is primary implementation of radio and/or chemotherapy. In cancers which have a high probability of being highly sensitive to systemic chemotherapy, for example, lymphoma, chemotherapy is the treatment of choice [79]. Of course, thoracentesis is necessary in the initial phase of diagnostics and treatment, for both cytological examination and alleviating symptoms of respiratory distress.

Patients with an effusion and a tumour that is refractory to chemotherapy should have thoracentesis performed every 3-4 days for symptomatic relief. In NSCLS, colon and pancreatic cancer, favourable effects of primary systemic chemotherapy and/or radiotherapy are not expected. Intrapleural therapy will probably be indicated for these patients.

5.2. Treatment modalities—therapeutic approach

Moribund patients and patients in the preterminal phase of disease, with the symptoms of respiratory distress thoracentesis is an urgent therapeutic procedure for alleviating current symptomatology. Aggressive therapy is not recommended in such patients. In view of possible complications during repeated thoracentesis, a certain number of doctors reserve thoracentesis only for moribund patients as a type of a short-term symptomatic therapy.

Patients who have a good performance status and longer survival time is expected, chemotherapy and/or radiotherapy is administrated after thoracentesis. Generally, systemic chemotherapy produces disappointing results when it comes to control of malignant pleural effusion. Since the adverse effects from radiation pneumonitis outweigh the possible benefits of therapy, hemithorax radiation is contraindicated in malignant pleural effusion from lung cancer as a rule (**Figure 8**).

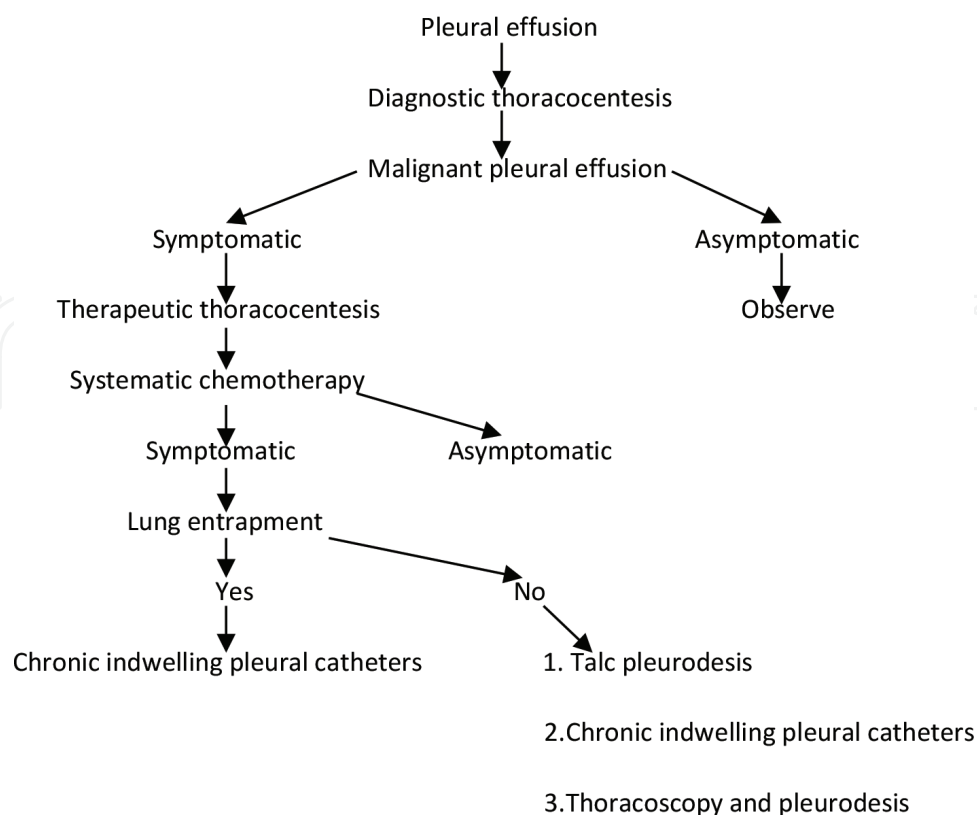


Figure 8. Diagnostic and therapeutic algorithm in malignant pleural effusions.

Drainage or intrapleural therapy is indicated if previous therapeutic protocols produce no results, that is, if they did not enable the control of pleural fluid production. Reaccumulation of larger amount of liquid leads to respiratory distress and/or worsening of clinical picture.

Pleurectomy, shunts, and other aggressive surgical interventions are reserved for patients refractive to intrapleural therapy. Pleurectomy and/or pleural abrasion are highly effective in obliteration of pleural space and in malignant pleural effusion control [117]. Therefore, this procedure is reserved for patients who have a reasonably long expected survival time and are in good general condition or who have failed a sclerosing agent therapeutic procedure. Pleuroperitoneal shunt has been demonstrated to be both safe and effective [118]. The shunt can be especially beneficial in refractory chylothorax where it allows recirculation of chyle [119]. Hyperthermic intrathoracic chemotherapy perfusion (HITHOC) combined with cytoreductive surgery can be performed in selected patients with acceptable mortality and morbidity rates [120].

5.3. Use of thoracic drain

Primary therapeutic task for treatment of patients with malignant effusion is alleviating dyspnoea. Reaccumulation of fluid sometimes can be controlled by intrapleural instillation of medication. In controlling the usual techniques of thoracocentesis, needle aspiration, and drainage are rarely efficient [79]. Treatment is basically palliative, disregarding the stage of disease and condition of the patient. Drainage postpones respiratory distress, but it does not prevent reaccumulation of liquid, dyspnoea, and pleural pain. Therefore, all patients with

notable symptomatology, except moribund and those patients in preterminal stage of disease, are recommended to have drainage of pleural space with instillation of therapeutic solution. Intrapleural therapy often produces satisfactory outcomes with in regard of long term palliation of respiratory symptoms by reducing or eliminating pleural liquid formation.

In loculated effusions, drainage is not successful. This is due to the fact that the lung never re-expands sufficiently so that visceral and parietal pleura are in contact. In this case, intrapleural therapy is not recommended.

Instillation of thoracic drain is a safe and successful surgical procedure enabling at the same time diagnostics and treatment of malignant pleural effusion. If it is performed correctly, the method is relatively painless.

After placing the drain, it is necessary to perform control radiographs in order to check the correct position of the drain, exclude pneumothorax, establish lung expansion, and amount of liquid that is possibly retained.

Lung expansion is necessary to achieve in order to close the space previously filled with liquid and to bring pleural surfaces into contact.

Failure of pleurodesis is associated with abnormal lung expansion that is detected with pleural manometry. A pleural space elastance greater than 19.0 cm H₂O/L during the evacuation of first 500 ml of pleural liquid was found to predict 100% pleurodesis failure at 1 month [121]. Lung expansion abnormalities detected during later stages are indicative of immediate or delayed pleurodesis outcomes.

Prerequisite for pleurodesis is that the effusion is not loculated, that patient has a good performance status and that expected survival time is longer than 4 weeks. After adequate evacuation of liquid, medicines are instilled into pleural space by bolus. Whether the procedure is done with or without active suction, fast decompression should be avoided. Consequences of fast decompression are severe pain, pulmonary shock, mediastinal shift, and pulmonary oedema of the re-expanded lung. If the effusion is massive, 1000–1500 ml can be evacuated. Drained should be intermittently clammed, especially in the early phase of suction. This way, hemodynamic stabilisation of patient is ensured. Drainage is continuous while daily amount of aspirated content is higher than 100 ml. By irritating pleura and lungs, every drain will produce around 50 ml of pleural liquid during 24 h. Drainage gives satisfactory results in less than 20% of patients [69, 116]. Nevertheless, pleurodesis in an outpatient setting using small-bore catheters can be successfully performed with decreased cost and morbidity.

The utilisation of indwelling catheters [Denver Biomaterials, Golden, PleurX, Colorado] has attained popularity due to it being an outpatient procedure, which allows the patient and family to manage the pleural effusion in a timely fashion at home. For symptomatic refractory or recurrent malignant pleural effusion, these catheters have grown to be the mainstay of treatment in most centres in the United States. This is due to their ability to successfully palliate the symptoms of dyspnoea regardless of the presence of lung entrapment. Spontaneous pleurodesis is developed by approximately 50% of patients by 2 months [122, 123].

5.4. Medicine choice for intrapleural therapy

It is presumed that medications such as tetracyclines, talc, and nitrogen mustard, etc. cause inflammation of pleural surfaces. Inflammation leads to obliteration of pleural space disabling reaccumulation of liquid [pleurodesis]. The mechanism of action of 5-fluorouracil effect is even less clear. Agents like cisplatin and cytosine arabinoside locally achieve high concentrations; thus, they are assumed to have a direct cytoreductive effect [116].

Choice of medication for pleurodesis partly depends on clinical, and partly on non-clinical parameters.

5.4.1. Nitrogen mustard

Nitrogen mustard (mechlorethamine) has been used in intrapleural therapy since 1949 and it is one of the first medications used in control of malignant pleural effusions [124]. Medicine efficiency is different and is accompanied by a large number of side effects such as chest pain, nausea, and vomiting [124, 125].

5.4.2. Talc

Talc is one of the oldest and most efficient medicines [79, 125]. Talc is instilled into the pleural space as a suspension or powder (**Figure 9**). Insufflation of talc powder has proven to be more efficient than instillation of the suspension [125]. Following talc poudrage and slurry, fever is a common occurrence, occurring 16–69% of the time. Complications that have also been reported with talc usage include arrhythmia, empyema, respiratory failure including pneumonitis, and adult respiratory distress syndrome (ARDS).

5.4.3. Quinacrine

Quinacrine is an antimalarial medication which has been recommended in therapy of malignant effusions for a period of time. Its use is completely abandoned now [79].

5.4.4. Biological agent—*corynebacterium parvum*

Biological agent—*corynebacterium parvum* in dose from 5 to 10 mg was promising at first; however, randomised study which compared its efficiency with efficiency of tetracycline did not show a statistically significant efficiency [126, 127].

5.4.5. Tetracycline

Tetracycline is a very popular medicine in intrapleural therapy because of its efficiency, affordability, and ease of use. Recommended dose for instillation is between 500 mg and 3 g of diluted tetracycline in 50–100 ml of normal saline [114, 127]. The most common side effects, in about 30–40% patients, are fever and moderate to severe chest pain which requires premedication [79]. Tetracycline is efficient in prevention of pleural effusion recurrence as well. Crucial factor for treatment success is fast and complete dispersion of tetracycline in pleural space [125].

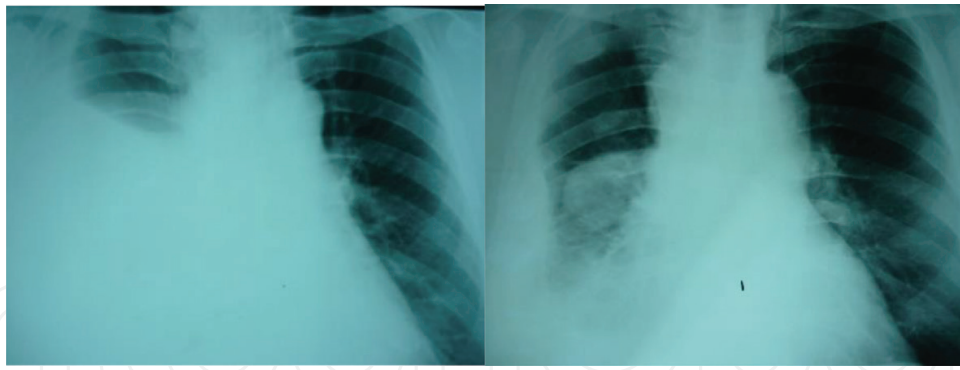


Figure 9. CXR before and after pleurodesis.

5.4.6. *Bleomycin*

Bleomycin is an antitumor, antibiotic producing significant results in prevention of pleural liquid reaccumulation [128]. Usual dose is 60 U in 100 ml D5W or normal saline [129, 130]. Systemic reabsorption is limited. About 40–45% of medicine is resorbed via pleura. This dose of medicine does not suppress the bone marrow; thus, bleomycin can be used simultaneously with chemotherapy and radiotherapy and it can be used in patients that suffer from myelosuppression [129].

In prevention of malignant pleural effusion, recurrence bleomycin is more efficient than tetracycline. Average time of effusion recurrence after tetracycline therapy (dose of 1 gram) was 32 days and 46 days for bleomycin (dose of 60 U) [129]. Series of three to four daily instillations of bleomycin is used in refractory effusions with a reduction in dosing from 60 to 30 U [131] is recommended.

5.4.7. *Other medicines*

Other medicines used for pleurodesis are thiotepa and 5-fluorouracyl, but they are less efficient than above mentioned medications. It is assumed that NaOH implementation achieves chemical pleuritis [132]. Doxorubicin has a similar effect to nitrogen mustard [121].

After pleurodesis, reaccumulation of liquid occurs in around 20–30% patients. If this is a small amount of fluid and is well tolerated by the patient, further treatment is usually not necessary.

The most efficacious methods in control of the effusion are pleural abrasion, chest tube drainage with sclerosing agent instillation, and pleurectomy. Mixed intravenous and intrapleural chemotherapy, with air therapy has produced response in 55% of patients, complete remission has resulted in 7%, partial remission in 48%, in 22% disease stabilisation has been achieved, and disease progression has been recorded in 22% of patients [133].

5.5. **Therapy associated pain**

After intrapleural administration of sclerotherapy, pain might occur. After drainage of 15–20 ml, 2% lidocaine is instilled via drain or catheter. The patient needs to breathe deeply and cough mildly for better distribution of anaesthetic over the surface of pleural space. Five to ten minutes before tetracycline is intravenously injected, 75–150 µg fentanyl is administered, and

5–10 mg of morphine is given after that. Fentanyl acts very quickly, as morphine takes over the extended analgesic effect. Fentanyl is slowly injected, over 5–7 minutes. If an unwanted reaction to fentanyl is expected, naloxone is given. Doctor must make sure that drain or flexible catheter is vertical and that intrapleural agent from the drain interflows into pleural space. In the analgesic therapy, results are achieved with less strong medications; therefore, premedication with morphine 10 mg or meperidine 75–100 mg intramuscularly or subcutaneously is recommended. Just before tetracycline solution instillation, 20 ml of 2% lidocaine is given intrapleurally. Morphine, fentanyl as well as other analgesics can have a depressive effect on respiratory centre and therefore, these principles of pain therapy cannot be applied in elderly patients, patients who are predisposed to respiratory depression and those with a bad general condition.

6. Conclusion

PMPE were equally present in all pathohistological types of lung cancer, while MPE were most common in lung adenocarcinoma. The diagnostic yield of pleural fluid cytology and closed pleural biopsy combined was more than 90%. Most commonly used therapeutic procedures were thoracocentesis and pleurodesis. PMPE were not a contraindication for explorative thoracotomy.

Author details

Milic Medenica^{1*}, Miras Medenica² and Danilo Cosovic¹

*Address all correspondence to: milic.medenica@gmail.com

1 Hospital for Lung Diseases – Brezovik, Niksic, Montenegro

2 Wrightington, Wigan and Leigh NHS Foundation Trust, UK

References

- [1] Taghizadeh N, Fortin M, Tremblay A. USA Hospitalizations for Malignant Pleural Effusions - Data from the National Inpatient Sample, 2012. *Chest*; Apr 2017;**151**(4):845-854
- [2] Rahman NM, Ali NJ, Brown G, et al. Local anaesthetic thorascopy: British thoracic society pleural disease guideline, 2010. *Thorax*. 2010;**65**(Suppl 2):ii54-ii60
- [3] Johnston WW. The malignant pleural effusion: A review of cytopathological diagnoses of 584 specimens from 472 consecutive patients. *Cancer*. 1985;**56**:905-909
- [4] Chernow B, Sahn SA. Carcinomatous involvement of the pleura of 96 patients. *The American Journal of Medicine*. 1977;**77**:507-513
- [5] Naito T, Satoh H, Ishikawa H, et al. Pleural effusion as a significant prognostic factor in non small cell lung cancer. *Anticancer Research*. 1997;**17**:4743-4746

- [6] Meyer PC. Metastatic carcinoma of the pleura. *Thorax*. 1966;**21**:437-443
- [7] Medenica M. Pleural Effusion. Podgorica: University of Montenegro; 2015. [25, 26, 30, 35, 82, 83, 207, 209, 211]. ISBN 978-86-7664-131-4
- [8] Marel M, Stastny B, Melinova L, et al. Diagnosis of pleral effusion: Experience with clinical studies, 1986-1990. *Chest*. 1995;**107**:1598-1603
- [9] Mulvey RB. The effect of pleural fluid on the diaphragm. *Radiology*. 1965;**84**:1080-1086
- [10] Marks WM, Filly RA, Callen PW. Real-time evaluation of pleural lesions: New observations regarding the probability of obtaining free fluid. *Radiology*. 1992;**142**:163-164
- [11] Brown NE, Zamel N, Aberman A. Changes in pulmonary mechanics and gas exchange following thoracentesis. *Chest*. 1978;**74**:540-542
- [12] Light RW, Stansbury DW, Brown SE. The relationship between pleural pressures and changes in pulmonary function after therapeutic thoracentesis. *The American Review of Respiratory Disease*. 1986;**133**:658-661
- [13] Estenne M, Yernault J-C, DeTroyer A. Mechanism of relief of dyspnea after thoracentesis in patients with large pleural effusions. *The American Journal of Medicine*. 1983;**74**:813-819
- [14] Shinto R, Stansbury DW, Brown SE, et al. The effect of thoracocentesis improve the exercise capacity of patients with pleural effusion? *The American Review of Respiratory Disease*. 1987;**135**:A244
- [15] Baburao A, Narayanswamy H. Clinico-pathological profile and haematological abnormalities associated with lung cancer in Bangalore, India. *Asian Pacific Journal of Cancer Prevention*. 2015;**16**(18):8235-8238
- [16] Vaska K, Wan LS, Sagar K, et al. Pleural effusion as a cause of right ventricular diastolic collapse. *Circulation*. 1992;**86**:609-617
- [17] Light RW, Jenkison SG, Minh V, et al. Obervation on pleural space pressures as fluid withdraw during thoracentesis. *The American Review of Respiratory Disease*. 1980;**121**:799-804
- [18] Gilbert VE. Shifting percussion dullness of the chest: A sign of pleural effusion. *Southern Medical Journal*. 1997;**90**:1255-1256
- [19] Wong FM, Grace WJ, Rottino A. Pleural effusions, ascites, pericardial effusions and edema in Hodgkin's disease. *The American Journal of the Medical Sciences*. 1963;**246**:678-682
- [20] Sahn SA. Pleural diseases related to metastatic malignancies. *The European Respiratory Journal*. 1997;**10**:1907-1913
- [21] Rodriguez-Panadero F. Lung cancer and ipsilateral pleural effusion. *Annals of Oncology*. 1995;**6**(suppl 3):S25-S27
- [22] Decker DA, Dines DE, Payne WS. The significance of a cytologically negative pleural effusion in bronchogenic carcinoma. *Chest*. 1978;**74**:640-642

- [23] Shintani Y, Ohta M, Iwasaki T, et al. Intraoperative pleural lavage cytology after lung resection as an independent prognostic factor for staging lung cancer. *The Journal of Thoracic and Cardiovascular Surgery*. 2009;**137**(4):835-839
- [24] Porcel JM, Vives M. Etiology and pleural fluid characteristics of large and massive effusions. *Chest*. 2003;**124**(3):978-983
- [25] Herrstedt J, Clementsen P, Hansen OP. Increased myelosuppression during cytostatic treatment and pleural effusion in patients with small cell lung cancer. *European Journal of Cancer*. 1992;**28A**:1070-1073
- [26] Livingston RB, JK MC, Trauth CJ. Isolated pleural effusions in small cell lung carcinoma: Favorable prognosis. *Chest*. 1982;**81**:208-211
- [27] Hsu C. Cytologic detection of malignancy in pleural effusion: A review of 5255 samples from 3811 patients. *Diagnostic Cytopathology*. 1987;**3**(1):8-12
- [28] Antunes G, Neville E, Duffy J, Ali N. BTS guidelines for the management of malignant pleural effusions. *Thorax*. 2003;**58**:ii29-ii38
- [29] Apffelstaedt JP, Van Zyl JA, Muller AG. Breast cancer complicated by pleural effusion: Patient characteristic and results of surgical management. *Journal of Surgical Oncology*. 1995;**58**:173-175
- [30] Rodriguez-Panadero F, Borderas Naranjo F, Lopez Mejias J. Pleural metastatic tumours and effusions. Frequency and pathogenic mechanisms in a post-mortem series. *The European Respiratory Journal*. 1989;**2**:366-369
- [31] Light RW, Hamm H. Malignant pleural effusion: Would the real cause please stand up? *The European Respiratory Journal*. 2007;**10**:1701-1702
- [32] Wang NS. The preformed stomas connecting the pleural cavity and the lymphatics in the parietal pleura. *The American Review of Respiratory Disease*. 1975;**111**:12-20
- [33] Staats BA, Ellefson RD, Badahn LL, Dines DE, Prakash UBS, Offord D. The lipoprotein profile of chylous and non-chylous pleural effusions. *Mayo Clinic Proceedings*. 1980;**55**:700-704
- [34] Sahn SA. Malignant pleural effusions. *Clinics in Chest Medicine*. 1985;**6**:113-125
- [35] Stathopoulos GT, Kollintza A, Moschos C, et al. Tumor necrosis factor-alpha promotes malignant pleural effusion. *Cancer Research*. 2007;**67**:9825-9834
- [36] Yano S, Shinohara H, Herbst RS, et al. Production of experimental malignant pleural effusions is dependent on invasion of the pleura and expression of vascular endothelial growth factor/vascular permeability factor by human lung cancer cells. *The American Journal of Pathology*. 2000;**157**:1893-1903
- [37] Stathopoulos GT, Sherrill TP, Karabela SP, et al. Host-derived interleukin-5 promotes adenocarcinoma-induced malignant pleural effusion. *American Journal of Respiratory and Critical Care Medicine*. 2010;**182**:1273-1281

- [38] Stathopoulos GT, Zhu Z, Everhart MB, et al. Nuclear factor-kappaB affects tumor progression in a mouse model of malignant pleural effusion. *American Journal of Respiratory Cell and Molecular Biology*. 2006;**34**:142-150
- [39] Yeh HH, Lai WW, Chen HH, et al. Autocrine IL-6-induced Stat3 activation contributes to the pathogenesis of lung adenocarcinoma and malignant pleural effusion. *Oncogene*. 2006;**25**:4300-4309
- [40] Cheng C-S, Rodriguez RM, Perket EA, et al. Vascular endothelial growth factor in pleural fluid. *Chest*. 1999;**115**:760-765
- [41] Yano S, Herbst SH, et al. Treatment for malignant pleural effusion of human lung adenocarcinoma by inhibition of vascular endothelial growth factor receptor tyrosine kinase phosphorylation. *Clinical Cancer Research*. 2000;**6**:957-965
- [42] Collins PO, Connolly DT, Williams TJ. Characterization of increase in vascular permeability induced by vascular permeability factor in vivo. *British Journal of Pharmacology*. 1993;**109**:195-199
- [43] Jankowska R, Porebska I, Dyla T. Evaluation of vascular endothelial growth factor [VEGF] in neoplastic and tuberculosis effusions - preliminary results. *Pneumonologia i Alergologia Polska*. 2002;**70**:258-264
- [44] J B, Ł S, M K, M F, J G-S, H B-G, J S. Regulatory T cells in malignant pleural effusions subsequent to lung carcinoma and their impact on the course of the disease. *Immunobiology*. 2016;**18**: 2985(16):30425-30429
- [45] Ye ZJ, Zhou Q, Yin W, et al. Interleukin 22-producing CD4⁺ T cells in malignant pleural effusion. *Cancer Letters*. 2012;**326**:23-32
- [46] Spriggs AI, Boddington MM. *The Cytology of Effusions*. 2nd ed. New York: Grune and Stratton; 1968
- [47] Black LF. The pleural space and pleural fluid. *Mayo Clinic Proceedings*. 1972;**47**:493-506
- [48] Light RW, MacGregor MI, Luchsinger PC, Ball WC. Pleural effusions: The diagnostic separation of transudates and exudates. *Annals of Internal Medicine*. 1972;**77**:507-513
- [49] Bousfield LR, Greenberg ML, Pacey F. Cytogenetic diagnosis of cancer from body fluids. *Acta Cytologica*. 1985;**29**:768-774
- [50] Ocana IM, Martinez-Vazquez JM, Seguna RM, et al. Adenosine deaminase in pleural fluids. *Chest*. 1983;**84**:51-53
- [51] Perez-Rodriguez E, Walton IJ, Hernandez JJ, et al. ADA 1/ADAp ratio in pleural tuberculosis: an excellent diagnostic parameter in pleural fluid. *Respiratory Medicine*. 1999;**93**:816-821
- [52] Yamagishi K, Tajima M, Suzuki A, Kimura K. Relation between cell composition of pleural effusions in patients with pulmonary carcinomas and their clinical courses. *Acta Cytologica*. 1976;**20**:537-541

- [53] Mohamed KH, Abdel-Hamid AL, Lee YCG, et al. Pleural fluid levels of IL-5 and eosinophils are closely correlated. *American Journal of Respiratory and Critical Care Medicine*. 2001
- [54] Schandene L, Namias B, Crusiaux A, et al. IL-5 in posttraumatic eosinophilic pleural effusion. *Clinical and Experimental Immunology*. 1993;**115**:115-119
- [55] Clarkson B. Relationship between cell type, glucose concentration, and response to treatment in neoplastic effusions. *Cancer*. 1964;**17**:914-928
- [56] Good JT Jr, Taryle DA, Sahn SA. The pathogenesis of low glucose, low pH malignant effusions. *The American Review of Respiratory Disease*. 1985;**131**:734-741
- [57] Sahn SA, Good JT Jr. Pleural fluid pH in malignant effusions. Diagnostic, prognostic and therapeutic implications. *Annals of Internal Medicine*. 1988;**108**:345-349
- [58] Nusair S, Breuer R, Amir G. Closed needle biopsy: Predicting diagnostic yield examining pleural fluid parameters. *Respiratory Medicine*. 2002;**96**:890-894
- [59] Villena V, Perez V, Pozo F. Amylase levels in pleural effusions: A consecutive unselected series of 841 patients. *Chest*. 2002;**121**:470-474
- [60] Ferrer J, Roldan J, Teixidor J, et al. Predictors of pleural malignancy in patients with pleural effusion undergoing thoracoscopy. *Chest*. 2005;**127**:1017-1022
- [61] McKenna JM, Chandrasekhar AJ, Henkin RE. Diagnostic value of carcinoembryonic antigen in exudative pleural effusions. *Chest*. 1980;**78**:587-590
- [62] Rittgers RA, Loewenstein MS, Feinerman AE, et al. Carcinoembryonic antigen levels in benign and malignant pleural effusions. *Annals of Internal Medicine*. 1978;**88**:631-634
- [63] Miedouge M, Rouzaud P, Salama G, et al. Evaluation of seven tumour markers in pleural fluid for the diagnosis of malignant effusion. *British Journal of Cancer*. 1999;**81**:1059-1065
- [64] Lee YC, Chern JH, Lai SL, et al. Sialyl stage-specific embryonic antigen-1 useful marker for differentiating the etiology of pleural effusion. *Chest*. 1998;**114**:1542-1545
- [65] Lee YC, Knox BS, Garrett JE. Use of cytokeratin fragments 19.1 and 19.21 [Cyfra 21-1] in the differentiation of malignant and benign pleural effusion. *Australian and New Zealand Journal of Medicine*. 1998;**29**:765-769
- [66] Tamura S, Nishigaki T, Moriwaki Y, et al. Tumor markers in pleural effusion diagnosis. *Cancer*. 1988;**61**:298-302
- [67] Lai CL, Tsai CM, Tsai TT. Presence of serum anti-p53 antibodies is associated with pleural effusion and poor prognosis in lung cancer patients. *Clinical Cancer Research*. 1998;**4**:3025-3030
- [68] Moriarty AT, Wiersema L, Snyder W, et al. Immunophenotyping of cytologic specimens by flow cytometry. *Diagnostic Cytopathology*. 1993;**9**:252-258. provjeriti
- [69] Dewald G, Dines DE, Weiland LH, et al. Usefulness of chromosome examination in the diagnosis of malignant pleural effusions. *The New England Journal of Medicine*. 1976;**295**:1494-1500

- [70] Nurminen M, Dejmek A, Martensson G, et al. Clinical utility of liquid-chromatographic analysis of effusions for hyaluronate content. *Clinical Chemistry*. 1994;**40**:777-780
- [71] Hillerdal G, Lindqvist U. Hyaluronan in pleural effusions and serum. *Cancer*. 1991;**67**: 2410-2414
- [72] Kawai T, Greenberg SD, Truong LD, et al. Differences in lectin binding of malignant pleural mesothelioma and adenocarcinoma of the lung. *The American Journal of Pathology*. 1988;**130**:401-410
- [73] Rodriguez de Castro MT, Acosta O, et al. Value of DNA analysis in addition to cytological testing in the diagnosis of malignant pleural effusions. *Thorax*. 1994;**49**:692-694
- [74] Xie L, Chen X, Wang L, et al. Cell-free miRNAs may indicate diagnosis and docetaxel sensitivity of tumor cells in malignant effusions. *BMC Cancer*. 2010;**10**:591
- [75] Wang L, Wei J, Qian X, et al. ERCC1 and BRCA1 mRNA expression levels in metastatic malignant effusions is associated with chemosensitivity to cisplatin and/or docetaxel. *BMC Cancer*. 2008;**8**:97
- [76] Heffner JE, Nietert PJ, Barbieri C. Pleural fluid pH as a predictor of survival for patients with malignant pleural effusions. *Chest*. 2000;**117**(1):79-86
- [77] Kasapoglu US, Arınç S, Gungor S, et al. Prognostic factors affecting survival in non-small cell lung carcinoma patients with malignant pleural effusions. *Immunobiology*. 2016;**16**:30425-30429
- [78] Sugiura S, Ando Y, Minami H, et al. Prognostic value of pleural effusion in patients with non-small cell lung cancer. *Clinical Cancer Research*. 1997;**3**:47-50
- [79] Hausheer FH, Yarbo JW. Diagnosis and treatment of malignant pleural effusion. *Cancer and Metastasis Reviews*. 1987;**6**:23-40
- [80] Ruskin JA, Gurney JW, Thorsen MK, et al. Detection of pleural effusions on supine chest radiographs. *AJR. American Journal of Roentgenology*. 1987;**148**:681-683
- [81] Dhillon DP, Spiro SG. Malignant pleural effusions. *British Journal of Hospital Medicine*. 1983;**29**:506-510
- [82] Rigby M, Zylak CJ, Wood LDH. The effect of lobar atelectasis on pleural fluid distribution in dogs. *Radiology*. 1980;**136**:603-607
- [83] Henschke CI, Yankelevitz DF, Davis SD. Pleural diseases: Multimodality imaging and clinical management. *Current Problems in Diagnostic Radiology*. 1991;**20**:155-181
- [84] Traill ZC, Davies RJ, Gleeson FV. Thoracic computed tomography in patients with suspected malignant pleural effusions. *Clinical Radiology*. 2000;**56**(3):193-196
- [85] Arenas-Jimenez J, Alonso-Charterina S, Sanchez-Paya J, et al. Evaluation of CT findings for diagnosis of pleural effusions. *European Radiology*. 2000;**10**(4):681-690
- [86] Ryu JS, Ryu HJ, Lee SN, et al. Prognostic impact of minimal pleural effusion in non-small-cell lung cancer. *Journal of Clinical Oncology*. 2014;**32**(9):960-967
- [87] Pugatch RD, Spirn PW. Radiology of the pleura. *Clinics in Chest Medicine*. 1985;**6**:17-32

- [88] Knisely BL, Broderick LS, Kuhlman JE. MR imaging of the pleura and chest wall. *Magnetic Resonance Imaging Clinics of North America*. 2000;**8**(1):125-141
- [89] Gupta NC, Rogers JS, Graeber GM. Clinical role of F-18 fluorodeoxyglucose positron emission tomography imaging in patients with lung cancer and suspected malignant pleural effusions. *Chest*. 2002;**122**:1918-1924
- [90] Weiss N, Solomon SB. Talc pleurodesis mimics pleural metastases: Differentiation with positron emission tomography/computed tomography. *Clinical Nuclear Medicine*. 2003;**28**(10):811-814
- [91] Wernecke K. Sonographic features of pleural disease. *AJR. American Journal of Roentgenology*. 1997;**168**:1061-1066
- [92] Kataoka H, Takada S. The role of thoracic ultrasonography for evaluation of patients with decompensated chronic heart failure. *Journal of the American College of Cardiology*. 2000;**35**:1638-1646
- [93] Blackmore CC, Black WC, Dallas RV, et al. Pleural fluid volume estimation: a chest radiograph prediction rule. *Academic Radiology*. 1996;**3**:103-109
- [94] Moyers JP, Starnes DL, Bienvenu GL, et al. Thoracentesis performed by radiologist using ultrasound guidance is safe regardless of the amount of fluid withdrawn. *Chest*. 1998;**114**:368S
- [95] McCloud TC, Flower CD. Imaging the pleura: Sonography, CT, and MR imaging. *AJR. American Journal of Roentgenology*. 1991;**156**:1145-1153
- [96] Lichtenstien DA, Menu Y. A bedside ultrasound sign ruling out pneumothorax in the critically ill. Lung sliding. *Chest*. 1995;**108**:1345-1348
- [97] Mathis G. Thoraxsonography - part I: Chest wall and pleura. *Ultrasound in Medicine & Biology*. 1997;**23**:1131-1139
- [98] Stevens MW, Leong AS, Fazzalari NL, et al. Cytopathology of malignant mesothelioma.: A stepwise logistic regression analysis. *Diagnostic Cytopathology*. 1992;**8**:333-342
- [99] Ordonez NG. The immunohistochemical diagnosis of epithelial mesothelioma. *Human Pathology*. 1999;**30**:313-323
- [100] Warnock ML, Stoloff A, Thor A. Differentiation of adenocarcinoma of the lung from mesothelioma. Periodic acid-Schiff, monoclonal antibodies B 72.3, and Leu M1. *The American Journal of Pathology*. 1988;**133**:30-38
- [101] Shield PW, Papadimos DJ, Walsh MD. GATA3: A promising marker for metastatic breast carcinoma in serous effusion specimens. *Cancer Cytopathology*. 2014;**122**(4):307-312
- [102] Smouse JH, Cibas ES, Janne PA, et al. EGFR mutations are detected comparably in cytologic and surgical pathology specimens of nonsmall cell lung cancer. *Cancer*. 2009;**117**(1):67-72
- [103] Buttitta F, Felicioni L, Del Grammastro M, et al. Effective assessment of *egfr* mutation status in bronchoalveolar lavage and pleural fluids by next-generation sequencing. *Clinical Cancer Research*. 2013;**19**(3):691-698

- [104] Beasley MB. Immunohistochemistry of pulmonary and pleural neoplasia. *Archives of Pathology & Laboratory Medicine*. 2008;**132**:1062-1072
- [105] Husain AN, Colby T, Ordonez N, et al. Guidelines for pathologic diagnosis of malignant mesothelioma: 2012 Update of the consensus statement from the international mesothelioma interest group. *Archives of Pathology & Laboratory Medicine*. 2013;**137**(5):647-667
- [106] Creaney J, Yeoman D, Naumoff LK, et al. Soluble mesothelin in effusions: A useful tool for the diagnosis of malignant mesothelioma. *Thorax*. 2007;**62**(7):569-576
- [107] Brock MV, Hooker CM, Yung R, et al. Can we improve the cytologic examination of malignant pleural effusions using molecular analysis? *The Annals of Thoracic Surgery*. 2005;**80**(4):1241-1247
- [108] Holloway AJ, Diyagama DS, Opeskin K, et al. A molecular diagnostic test for distinguishing lung adenocarcinoma from malignant mesothelioma using cells collected from pleural effusions. *Clinical Cancer Research*. 2006;**12**(17):5129-5135
- [109] Zhang X, Zhao Y, Wang M, et al. Detection and comparison of epidermal growth factor receptor mutations in cells and fluid of malignant pleural effusion in non-small cell lung cancer. *Lung Cancer*. 2007;**60**:175-182
- [110] Kroemer G, Zitvogel L. Can the exome and the immunome converge on the design of efficient cancer vaccines? *Oncoimmunology*. 2012;**1**(5):579-580
- [111] Grunze H. The comparative diagnostic accurancy, efficiency and specificity of cytologic techniques used in the diagnosis of malignant neoplasm in serous effusions of the pleural and pericardial cavities. *Acta Cytologica*. 1964;**8**:150-164
- [112] Boutin C, Viallat JR, Cargnino P, Farisse P. Thoracoscopy in malignant effusion. *The American Review of Respiratory Disease*. 1981;**124**:588-592
- [113] Maskell NA, Gleeson FV, Davies RJ. Standard pleural biopsy versus CT-guided cutting-needle biopsy for diagnosis of malignant disease in pleural effusions: A randomised controlled trial. *Lancet*. 2003;**366**:1326-1330
- [114] Cardillo G, Facciolo F, Carbone L, et al. Long-term follow-up of videoassisted talc pleurodesis in malignant recurrent pleural effusions. *European Journal of Cardio-Thoracic Surgery*. 2002;**21**(2):302-305. discussion 305-306
- [115] Gondos B, McIntosh KM, Renston RH, King EB. Application of electron microscopy in the definitive diagnosis of effusions. *Acta Cytologica*. 1978;**22**:297-304
- [116] Ruckdeschel JC. Management of malignant pleural effusions: An overview. *Seminars in Oncology*. 1988;**15**(suppl):24-28
- [117] Martini N, Bains MS, Beattie EJ Jr. Indications for pleurectomy in malignant effusion. *Cancer*. 1975;**35**:734-738
- [118] Petrou M, Kaplan D, Goldstraw P. Management of recurrent malignant pleural effusions. The complementary role of talc pleurodesis and pleuroperitoneal shunting. *Cancer*. 1995:801-805

- [119] Murphy MC, Newman BM, Rodgers BM. Pleuroperitoneal shunt in the management of persistent chylothorax. *The Annals of Thoracic Surgery*. 1989;**48**:195-200
- [120] Kerscher C, Ried M, Hofmann HS, Graf BM, Zausig YA. Anaesthetic management of cytoreductive surgery followed by hyperthermic intrathoracic chemotherapy perfusion. *Journal of Cardiothoracic Surgery*. 2014;**9**:125
- [121] Rs L, Lo SK, Chuang NL, Yang CT, et al. Elastance of the pleural space: A predictor for the outcome of pleurodesis in patients with malignant pleural effusion. *Annals of Internal Medicine*. 1997;**126**:768-774
- [122] Tremblay A, Michaud G. Single-center experience with 250 tunnelled pleural catheter insertions for malignant pleural effusion. *Chest*. 2006;**129**:362-368
- [123] Putnam JB Jr, Walsh GL, Swisher SG, et al. Outpatient management of malignant pleural effusion by a chronic indwelling pleural catheter. *The Annals of Thoracic Surgery*. 2000;**69**:369-375
- [124] Chahinian AP. Managment of pleural tumors and malignant pleural effusions. In: Chretien J, Bignon J, Hirsch A, editors. *The Pleura in Haelth and Disease*. New York, NY: Marcel Dekker Inc; 1985. pp. 571-584
- [125] Anderson CB, Philpott GW, Ferguson TB. The treatment of malignant pleural effusions. *Cancer*. 1974;**33**:916-922
- [126] Hausheer FH, Yarbo JW. Diagnosis and treatment of malignant pleural effusion. *Seminars in Oncology*. 1985;**12**:54-75
- [127] Leahy BC, Honeybourne D, Brear SG. Treatment of malignant pleural effusions with intrapleural *Corynebacterium parvum* or tetracycline. *European Journal of Respiratory Diseases*. 1985;**56**:50-54
- [128] Ostrowski MJ. Intracavitary therapy with bleomycin for the tretment of malignant pleural effusions. *Journal of Surgical Oncology*. 1989;(suppl):7-13
- [129] Ruckdeschel JC, Moores D, Lee JZ. Intrapleural therapy for malignant pleural effusions: A randomized comparison of bleomycin and tetracycline. *Chest*. 1991;**100**:1535
- [130] Rusch VW, Harper GR. Pleural effusions in patients with malinancy. In: Roth JA, Ruckdeschel JC, Weisseburger TH, editors. *Thoracic Oncology*. Philadelphia, PA: WB Co; 1989. pp. 594-605
- [131] Hamed H, Fentimen IS, Chaudarz MA. Comparison of intracavitary bleomycin and talc for control of pleural effusions secondary to carcinoma of the breast. *The British Journal of Surgery*. 1989;**1266**:1266-1267
- [132] Austin EH, Flye MW. The treatment of recurrent malignant pleural effusions. *The Annals of Thoracic Surgery*. 1979;**28**:190-203
- [133] Su WC, Lai WW, Chen HH. Combined intrapleural and intravenous chemotherapy, and pulmonary irradiation, for treatment of patients with lung cancer presenting with malignant pleural effusion. A pilot study. *Oncologia*. 2003;**64**:18-24