

# We are IntechOpen, the world's leading publisher of Open Access books Built by scientists, for scientists

6,900

Open access books available

185,000

International authors and editors

200M

Downloads

Our authors are among the

154

Countries delivered to

TOP 1%

most cited scientists

12.2%

Contributors from top 500 universities



WEB OF SCIENCE™

Selection of our books indexed in the Book Citation Index  
in Web of Science™ Core Collection (BKCI)

Interested in publishing with us?  
Contact [book.department@intechopen.com](mailto:book.department@intechopen.com)

Numbers displayed above are based on latest data collected.  
For more information visit [www.intechopen.com](http://www.intechopen.com)



---

# iOCT in PVR Surgical Management

---

Salvatore Di Lauro, Salvador Pastor Idoate and  
Jose Carlos Pastor

Additional information is available at the end of the chapter

<http://dx.doi.org/10.5772/intechopen.78774>

---

## Abstract

Recent advances in optical coherence tomography (OCT) technology have allowed the introduction of OCT into the operating room. Intraoperative OCT (iOCT) has been utilized to visualize the retinal architecture prior, during, and following several retinal surgical techniques. The identification of epiretinal, subretinal, and intraretinal changes is one of the crucial points in PVR management. The iOCT can identify intraretinal changes and/or subretinal PVR membranes which cannot be easily peeled as epiretinal membranes. Intraretinal forms are especially difficult to identify preoperatively but their presence may be crucial in surgical management because the attempt to remove the presumed membrane may result in severe retinal tissue damage and iatrogenic tears. Therefore, surgical technique and even tamponade choice may be seriously affected by OCT imaging results.

**Keywords:** OCT, intraoperative OCT, PVR, retinal detachment, vitreo-retinal surgery

---

## 1. Introduction

Optical coherence tomography (OCT) has dramatically changed the diagnosis, classification, and treatment of many vitreo-retinal diseases [1–3]. One of the most recent developments of this technology is the intraoperative OCT (iOCT). The iOCT allows a real-time tomographic visualization of the retina without the need to stop the surgery and without any external machines (microscope-integrated OCT). In this way, the surgeon can see OCT images during the surgery on an external display or directly through the microscope.

iOCT adds microscopic information and visualizes sub-surface structures in a non invasive way. This information can impact surgical decision-making as well as surgical maneuvers in selected cases. In this sense, the intraoperative visualization of the retina opens new surgical

and diagnostic possibilities. Vitreo-retinal interphase diseases may especially benefit from iOCT spreading but also retinal detachment (RD) surgery could be positively affected.

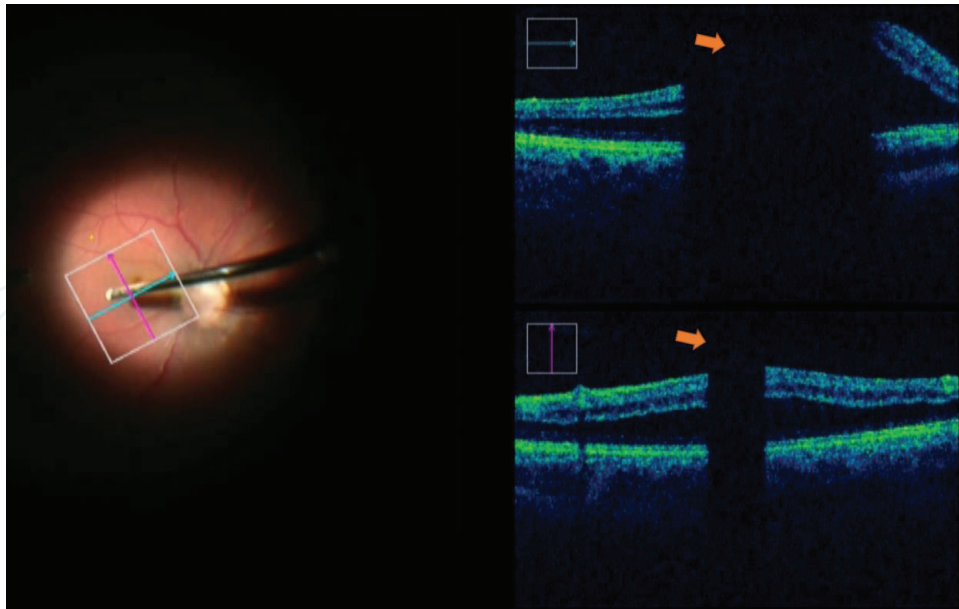
Proliferative vitreoretinopathy (PVR) is one of the most severe complications after RD, appearing in 5–10% of them [4]. Despite recent advances in vitreo-retinal surgery, PVR management is still an unsolved issue [4]. The introduction of the iOCT in surgical practice could be useful in improving the management of this important complication.

## 2. Intraoperative optical coherence tomography (iOCT)

The iOCT is a relatively new technology, and the first relevant study about iOCT applications in ophthalmology was the so named Prospective Intraoperative and Perioperative Ophthalmic Imaging with Optical Coherence Tomography (PIONEER) study [5]. The 2-year results published in 2014 demonstrated the potential advantages and applications of this technology [5]. Nevertheless, in this study, an external OCT system mounted on the operative microscope (Bioptigen SDOIS portable spectral-domain OCT [SD OCT] system; Bioptigen, Research Triangle Park, North Carolina, USA) was used. The most serious inconvenience of this system was the need to pause the surgery to obtain the required images.

Since this study, relevant advances in this technology have been reached to obtain a real microscope-integrated technology. Actually, there are several iOCTs available, including RESCAN 700 (Carl Zeiss Meditec, Inc., Oberkochen, Germany), the EnFocus (Bioptigen/Leica Microsystems, Wetzlar, Germany), and an integrated prototype internally developed at the Cole Eye Institute, Cleveland Clinic Foundation (Cleveland, Ohio) [6]. All these systems allow a real-time OCT imaging during the surgery and provide instantaneous feedback to the surgeon.

The PIONEER and the Determination of Feasibility of Intraoperative Spectral-Domain Microscope Combined/Integrated OCT Visualization during En Face Retinal and Ophthalmic Surgery (DISCOVER) studies have largely demonstrated the iOCT usefulness in the anterior and posterior segment surgery [5, 6]. Surgical procedures and pathologies positively affected by iOCT introduction in surgical practice include Descemet stripping automated endothelial keratoplasty (DSAEK), Descemet membrane endothelial keratoplasty (DMEK), pars plana vitrectomy for epiretinal membrane, proliferative diabetic retinopathy (PDR), rhegmatogenous retinal detachment, macular hole, optic pit maculopathy, chorioretinal biopsy, and Argus (Second Sight Medical Products, Inc., Sylmar, CA) prosthesis implant [5–13]. The DISCOVER study's 3-year results have been recently published [6]. A total of 837 eyes (244 anterior segment/593 posterior segment cases) were included and iOCT successful image acquisition was achieved in 820 eyes (98.0%; 95% confidence interval (CI), 96.8–98.8%). In 43.4% of the anterior segment cases (95% CI, 37.1–49.9%) and 29.2% (95% CI, 25.5–33.0%), the surgeons considered that the iOCT information impacted their surgical decision-making and altered the previous related procedure. Thus, iOCT could be considered a useful technology for ophthalmic surgery. Nevertheless, there are some limitations. The RESCAN 700, the commonest iOCT, is a SD-OCT system with scanning speed of 27,000 A-scans  $\mu$ m per second, with a wavelength of 840 nm, refresh rate from 5 to 50 Hz, axial resolution of 5.5  $\mu$ m in tissue, scan depth of 2 mm, and scan length of 6 mm (adjustable from 3 to 16 mm). This means that image quality is still far away from the OCT

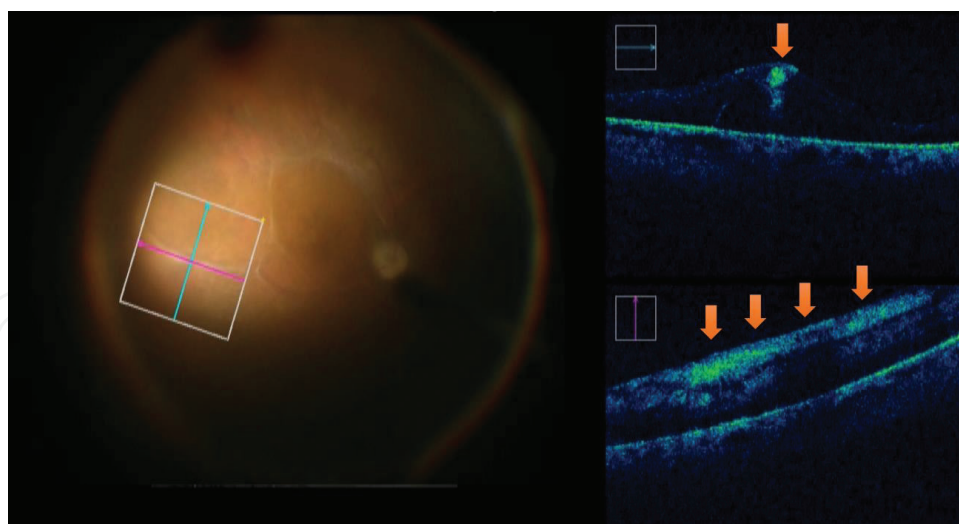


**Figure 1.** Instrument shadow during intraoperative OCT (iOCT) imaging. Note the shadow (arrow) below the vitreotome probe. Image obtained with the Zeiss Rescan® 700 iOCT (Carl Zeiss Meditec, Oberkochen, Germany).

currently used in clinical practice with axial resolutions of 1  $\mu\text{m}$  and scanning speed of 400,000 A-scans per second. Furthermore, the autofocus and tracking mechanism must be improved to be faster and more accurate. Other limitations include artifacts, instrument shadow during surgery, and function overload with the surgical microscope pedal [6]. Instrument shadow is an important problem limiting the possibility of viewing retinal tissues immediately below the surgical instrument and is related to OCT image caption properties and the materials currently used in vitreo-retinal surgery (**Figure 1**). Nevertheless, new non-metallic instruments made from “OCT-friendly” materials, such as silicone, polycarbonate, and PVC, may allow one to diminish this problem, especially important in vitreo-retinal interface procedures [14, 15]. A valid alternative could be the use of OCT-integrated surgical instruments [14].

### 3. Proliferative vitreoretinopathy (PVR)

PVR is a complex process involving several risk factors, most of them still unknown. During the last 25 years, and despite the enormous advantages in vitreo-retinal surgery techniques, such as small-gauge instrumentation and new imaging technology, PVR incidence is unchanged and functional and anatomical results are still very poor. PVR is a complex and multifactorial disease, and pharmacological strategies (including anti-inflammatory drugs, antiproliferative agents, antineoplastic, antigrowth factors, and antioxidants) have been considered ineffective and they have been basically abandoned in current practice. Its pathogenesis is divided into several steps: migration of cells, mostly retinal pigment epithelial (RPE) and glial cells; proliferation of these cells; membrane development; contraction of the fibrocellular membrane; extracellular collagen production; and creation of fixed folds in the retina [4]. Several cytokines, growth factors, and single-nucleotide polymorphisms in genes related with inflammation and apoptosis have shown to have a crucial role in PVR development [4, 16–24]. The histopathology of the disease is



**Figure 2.** Intraoperative OCT (iOCT) in PVR. iOCT allows intraretinal changes identification (arrows). These membranes cannot be surgically removed. Image obtained with the Zeiss Rescan® 700 iOCT (Carl Zeiss Meditec, Oberkochen, Germany).

characterized by various grades of fibrocellular membrane proliferation with prominent Muller cell activation. These phenomena result in complete retinal architecture alteration with a loss of normal retinal cell organization and function. These membranes may be epi-, intra- or sub-retinal. One of the crucial points is a correct and widely accepted classification which must include intraretinal status [4, 25]. In fact, PVR is characterized by epiretinal, subretinal but also intraretinal proliferation [4, 26, 27]. Intraretinal membranes are especially important because there is no way to remove them during surgery [4], and this increases the risk of surgical failure due to the retinal shortening. Intraretinal PVR must be considered the most severe form in which changes affecting retinal architecture lead to significant dysfunction. Epiretinal or subretinal membranes can be quite easily removed during surgery but intraretinal forms are an unsolved problem. In this sense, iOCT may be awfully valuable in surgical practice allowing the intraoperative assessment of retinal status. The iOCT may be useful to identify intraretinal changes and/or subretinal PVR membranes which cannot be removed with standard techniques (**Figure 2**). This means that it allows a better PVR classification and this can change our surgical attitude intraoperatively for better decision-making about a surgical technique. In fact, trying to remove the presumed membrane can have as consequences severe retinal injury and iatrogenic tears. Thus, surgical technique and even tamponade choice may be seriously affected by iOCT imaging.

## Author details

Salvatore Di Lauro<sup>1,2\*</sup>, Salvador Pastor Idoate<sup>1,2</sup> and Jose Carlos Pastor<sup>1,2</sup>

\*Address all correspondence to: sadilauro@live.it

1 Departamento de Oftalmología, Hospital Clínico Universitario de Valladolid, Valladolid, Spain

2 Instituto de Oftalmobiología Aplicada (IOBA), Retina Group, Universidad de Valladolid, Valladolid, Spain



## References

- [1] Phadikar P, Saxena S, Ruia S, Lai TY, Meyer CH, Elliott D. The potential of spectral domain optical coherence tomography imaging based retinal biomarkers. *International Journal of Retina and Vitreous*. 2017;**3**:1. PubMed PMID: 28078103. Pubmed Central PMCID: PMC5220620. Epub: 2017/01/13. eng
- [2] Lavinsky F, Lavinsky D. Novel perspectives on swept-source optical coherence tomography. *International Journal of Retina and Vitreous*. 2016;**2**:25. 11/0106/04/received 10/04/accepted. PubMed PMID: PMC5088466
- [3] Fujimoto J, Swanson E. The development, commercialization, and impact of optical coherence tomography. *Investigative Ophthalmology & Visual Science*. 1 July 2016;**57**(9): OCT1-OCT13. 07/13 05/20/received 06/16/accepted. PubMed PMID: PMC4968928
- [4] Pastor JC, Rojas J, Pastor-Idoate S, Di Lauro S, Gonzalez-Buendia L, Delgado-Tirado S. Proliferative vitreoretinopathy: A new concept of disease pathogenesis and practical consequences. *Progress in Retinal and Eye Research*. 2016 Mar;**51**:125-155. PubMed PMID: 26209346. Epub 2015/07/26. eng
- [5] Ehlers JP, Dupps WJ, Kaiser PK, Goshe J, Singh RP, Petkovsek D, et al. The Prospective Intraoperative and Perioperative Ophthalmic Imaging with Optical Coherence Tomography (PIONEER) Study: 2-year results. *American Journal of Ophthalmology*. 2014 Nov;**158**(5):999-1007. PubMed PMID: 25077834. Pubmed Central PMCID: PMC4250395. Epub: 2014/08/01. eng
- [6] Ehlers JP, Modi YS, Pecan PE, Goshe J, Dupps WJ, Rachitskaya A, et al. The DISCOVER Study 3-year results: Feasibility and usefulness of microscope-integrated intraoperative OCT during ophthalmic Surgery. *Ophthalmology*. 3 Feb 2018. pii: S0161-6420(17)32218-2. PubMed PMID: 29409662. Epub: 2018/02/08. eng
- [7] Ehlers JP, Uchida A, Srivastava SK. The integrative surgical theater: Combining intraoperative optical coherence tomography and 3D digital visualization for vitreoretinal surgery in the DISCOVER Study. *Retina (Philadelphia, PA)*. 2017 Dec 18. PubMed PMID: 29256988. Epub: 2017/12/20. eng. Publish Ahead of Print
- [8] Borrelli E, Palmieri M, Aharrh-Gnama A, Ciciarelli V, Mastropasqua R, Carpineto P. Intraoperative optical coherence tomography in the full-thickness macular hole surgery with internal limiting membrane inverted flap placement. *International Ophthalmology*. 2018 Mar 3. DOI: 10.1007/s10792-018-0880-8. [Epub ahead of print] PubMed PMID: 29502211. Epub: 2018/03/05. eng
- [9] Heinrich D, Bohnacker S, Nasser MA, Feucht N, Lohmann CP, Maier M. Intraoperative optical coherence tomography in explorative vitrectomy in patients with vitreous haemorrhage—A case series. *Der Ophthalmologe: Zeitschrift der Deutschen Ophthalmologischen Gesellschaft*. 2018 Feb 15. DOI: 10.1007/s00347-018-0665-5. [Epub ahead of print] PubMed PMID: 29450624. Epub: 2018/02/17. Intraoperative optische Kohärenztomographie bei explorativer Vitrektomie an Patienten mit Glaskörperblutung - eine Fallserie. ger

- [10] Lu CD, Waheed NK, Witkin A, Bauman CR, Liu JJ, Potsaid B, et al. Microscope-integrated intraoperative ultrahigh-speed swept-source optical coherence tomography for wide-field retinal and anterior segment imaging. *Ophthalmic Surgery, Lasers & Imaging Retina*. 2018 Feb 1;**49**(2):94-102. PubMed PMID: 29443358. Epub: 2018/02/15. eng
- [11] Toygar O, Riemann CD. Intraoperative optical coherence tomography in macula involving rhegmatogenous retinal detachment repair with pars plana vitrectomy and perfluoron. *Eye (London, England)*. 2016 Jan;**30**(1):23-30. PubMed PMID: 26656086. Pubmed Central PMCID: PMC4709554. Epub: 2015/12/15. eng
- [12] Junker B, Maier M, Agostini H, Hattenbach LO, Pielen A, Framme C. Intraoperative optical coherence tomography in retinal detachment. *Der Ophthalmologe: Zeitschrift der Deutschen Ophthalmologischen Gesellschaft*. 2016 Aug;**113**(8):663-667. PubMed PMID: 27378449. Epub: 2016/07/06. Intraoperative optische Kohärenztomographie bei Ablatio retinae. ger
- [13] Ehlers JP, Tao YK, Srivastava SK. The value of intraoperative optical coherence tomography imaging in vitreoretinal surgery. *Current Opinion in Ophthalmology*. 2014 May;**25**(3):221-227. PubMed PMID: 24614147. Pubmed Central PMCID: PMC4119822. Epub: 2014/03/13. eng
- [14] Carrasco-Zevallos OM, Viehland C, Keller B, Draelos M, Kuo AN, Toth CA, et al. Review of intraoperative optical coherence tomography: Technology and applications [Invited]. *Biomedical Optics Express*. 2017 Mar 1;**8**(3):1607-1637. PubMed PMID: 28663853. Pubmed Central PMCID: PMC5480568. Epub: 2017/07/01. eng
- [15] Ehlers JP, Srivastava SK, Feiler D, Noonan AI, Rollins AM, Tao YK. Integrative advances for OCT-guided ophthalmic surgery and intraoperative OCT: Microscope integration, surgical instrumentation, and heads-up display surgeon feedback. *PLoS One*. 2014;**9**(8):e105224. PubMed PMID: 25141340. Pubmed Central PMCID: PMC4139373. Epub: 2014/08/21. eng
- [16] Pastor-Idoate S, Rodriguez-Hernandez I, Rojas J, Gonzalez-Buendia L, Delgado-Tirado S, Lopez JC, et al. Functional characterization of rs2229094 (T>C) polymorphism in the tumor necrosis factor locus and lymphotoxin alpha expression in human retina: The retina 4 project. *Clinical Ophthalmology (Auckland, NZ)*. 2017;**11**:973-981. PubMed PMID: 28579748. Pubmed Central PMCID: PMC5449105. Epub: 2017/06/06. eng
- [17] Di Lauro S, Rodriguez-Crespo D, Gayoso MJ, Garcia-Gutierrez MT, Pastor JC, Srivastava GK, et al. A novel coculture model of porcine central neuroretina explants and retinal pigment epithelium cells. *Molecular Vision*. 2016;**22**:243-253. PubMed PMID: 27081295. Pubmed Central PMCID: PMC4812504. Epub: 2016/04/16. eng
- [18] Pastor-Idoate S, Rodriguez-Hernandez I, Rojas J, Fernandez I, Garcia-Gutierrez MT, Ruiz-Moreno JM, et al. BAX and BCL-2 polymorphisms, as predictors of proliferative vitreoretinopathy development in patients suffering retinal detachment: The Retina 4 project. *Acta Ophthalmologica*. 2015 Nov;**93**(7):e541-e549. PubMed PMID: 25991504. Epub: 2015/05/21. eng

- [19] Rojas J, Fernandez I, Pastor JC, MacLaren RE, Ramkissoon Y, Harsum S, et al. Predicting proliferative vitreoretinopathy: Temporal and external validation of models based on genetic and clinical variables. *The British Journal of Ophthalmology*. 2015 Jan;**99**(1):41-48. PubMed PMID: 25075124. Epub: 2014/07/31. eng
- [20] Pastor-Idoate S, Rodriguez-Hernandez I, Rojas J, Fernandez I, Garcia-Gutierrez MT, Ruiz-Moreno JM, et al. The p53 codon 72 polymorphism (rs1042522) is associated with proliferative vitreoretinopathy: The Retina 4 Project. *Ophthalmology*. 2013 Mar;**120**(3):623-628. PubMed PMID: 23207172. Epub: 2012/12/05. eng
- [21] Pastor-Idoate S, Rodriguez-Hernandez I, Rojas J, Fernandez I, Garcia-Gutierrez MT, Ruiz-Moreno JM, et al. The T309G MDM2 gene polymorphism is a novel risk factor for proliferative vitreoretinopathy. *PLoS One*. 2013;**8**(12):e82283. PubMed PMID: 24349246. Pubmed Central PMCID: PMC3857251. Epub: 2013/12/19. eng
- [22] Rojas J, Fernandez I, Pastor JC, Maclaren RE, Ramkissoon Y, Harsum S, et al. A genetic case-control study confirms the implication of SMAD7 and TNF locus in the development of proliferative vitreoretinopathy. *Investigative Ophthalmology & Visual Science*. 2013 Mar 05;**54**(3):1665-1678. PubMed PMID: 23258148. Epub: 2012/12/22. eng
- [23] Fernandez-Bueno I, Garcia-Gutierrez MT, Srivastava GK, Gayoso MJ, Gonzalo-Orden JM, Pastor JC. Adalimumab (tumor necrosis factor-blocker) reduces the expression of glial fibrillary acidic protein immunoreactivity increased by exogenous tumor necrosis factor alpha in an organotypic culture of porcine neuroretina. *Molecular Vision*. 2013;**19**:894-903. PubMed PMID: 23687426. Pubmed Central PMCID: 3654850
- [24] Rojas J, Fernandez I, Pastor JC, Garcia-Gutierrez MT, Sanabria MR, Brion M, et al. A strong genetic association between the tumor necrosis factor locus and proliferative vitreoretinopathy: The Retina 4 project. *Ophthalmology*. 2010 Dec;**117**(12):2417-2423. e1-2. PubMed PMID: 20663564. Epub: 2010/07/29. eng
- [25] Di Lauro S, Kadhim MR, Charteris DG, Pastor JC. Classifications for proliferative vitreoretinopathy (PVR): An analysis of their use in publications over the last 15 years. *Journal of Ophthalmology*. 2016;**2016**:7807596. PubMed PMID: 27429798. Pubmed Central PMCID: PMC4939352. Epub: 2016/07/19. eng
- [26] Pastor JC, Mendez MC, de la Fuente MA, Coco RM, Garcia-Arumi J, Rodriguez de la Rua E, et al. Intraretinal immunohistochemistry findings in proliferative vitreoretinopathy with retinal shortening. *Ophthalmic Research*. 2006;**38**(4):193-200. PubMed PMID: 16679807
- [27] Pastor JC, Rodriguez de la Rua E, Martin F, Mayo-Isar A, de la Fuente MA, Coco R, et al. Retinal shortening: The most severe form of proliferative vitreoretinopathy (PVR). *Archivos de la Sociedad Española de Oftalmología*. 2003 Dec;**78**(12):653-657. PubMed PMID: 14689321. Epub: 2003/12/23. Acortamiento retiniano: la forma mas grave de la vitreoretinopatía proliferante (VRP). spa



