

# We are IntechOpen, the world's leading publisher of Open Access books Built by scientists, for scientists

6,900

Open access books available

186,000

International authors and editors

200M

Downloads

Our authors are among the

154

Countries delivered to

TOP 1%

most cited scientists

12.2%

Contributors from top 500 universities



WEB OF SCIENCE™

Selection of our books indexed in the Book Citation Index  
in Web of Science™ Core Collection (BKCI)

Interested in publishing with us?  
Contact [book.department@intechopen.com](mailto:book.department@intechopen.com)

Numbers displayed above are based on latest data collected.  
For more information visit [www.intechopen.com](http://www.intechopen.com)



---

## Tension in Peripheral Nerve Suture

---

Jörg Bahm, Tobias Esser, Bernd Sellhaus,  
Wissam El-kazzi and Frederic Schuind

Additional information is available at the end of the chapter

<http://dx.doi.org/10.5772/intechopen.78722>

---

### Abstract

Avoiding suture tension in peripheral nerve coaptation seems to be a clinical dogma since 30 years, although experimental data are weak and clinical practice shows good functional outcome after peripheral nerve repair by direct coaptation under “reasonable” tension, defined by *local anatomic feasibility* and the use of *specific suture material*. In this article, we focus on the microsurgical technique of nerve stump coaptation and the *distribution of tension through epineural sutures* with various suture materials; we also analyze the impact on the different nerve tissue layers, the limit of this approach and its combination with other tissue releasing techniques like *paraneurolysis*, *adjacent joint flexion*, or *bone shortening*.

**Keywords:** nerve suture, coaptation, tension, brachial plexus injury, obstetrical, peripheral nerve, microsurgery

---

### 1. Introduction

The actual state-of-the-art in suture-coaptation bringing together two stumps of a severed peripheral nerve requires good histologic quality of both stumps, a gap that may overcome by acceptable tension, and a good microsurgical technique when performing epineural or epi-perineural mattress sutures, leading finally to a nearly invisible congruent “anastomosis”.

Few authors have dealt so far with aspects of technical improvement of nerve stump coaptation, but fascicular alignment seems to be a major factor to ensure proper regeneration [1].

Peripheral nerves contain elastic fibers and after nerve transection, even without any loss of substance, a gap between the two stumps becomes apparent. The local nerve tissue damage

---

and ingrowing fibrosis of both stumps may increase and/or fix the gap in an irreversible manner, than the further coaptation becomes hazardous.

Although “reasonable” tension may be applied to try to overcome the gap, it is generally recommended to perform nerve sutures in a tension-free environment using 9/0 and 10/0 microsurgical suture material. When these stitches break, a nerve graft is recommended.

Recently, we gained reasonable experience in the reconstruction of upper and extended upper obstetric brachial plexus lesions (OBPL) in general [2] and with direct sutures [3], showing very good clinical results of motor recovery after severe obstetric traction injury with complete trunk ruptures. Optimizing the functional result after surgical reconstruction in all types of OBPL is always the prevalent aim, especially to recover an adequate hand function [4].

The OBPL direct suture repair technique was introduced already over hundred years ago [5] and we know that several peripheral nerve surgeons are incline to perform a direct coaptation of two peripheral nerve stumps with a “reasonable” tension, to avoid short grafting with less dense nerve fiber interposition.

There is thus a striking controversy between a clinical axiom (tensionless nerve coaptation) and surgical experience, leading us to investigate this issue further and to discuss both the existing literature and possible research protocols.

## 2. Surgical technique

The nerve suture should bring together two stumps of good tissue quality, that is, free of fibrosis (i.e., infiltration of collagen fibers) or neuroma (predominance of misoriented peripheral minifascicles), with good fascicular appearance and a gap overcome by slight traction and finally hold by the sutures [6, 7]. de Medinaceli introduced a microsurgical technique focusing on good fascicular alignment in both stumps [1], mainly to avoid random fascicular ingrowth of the regeneration cones.

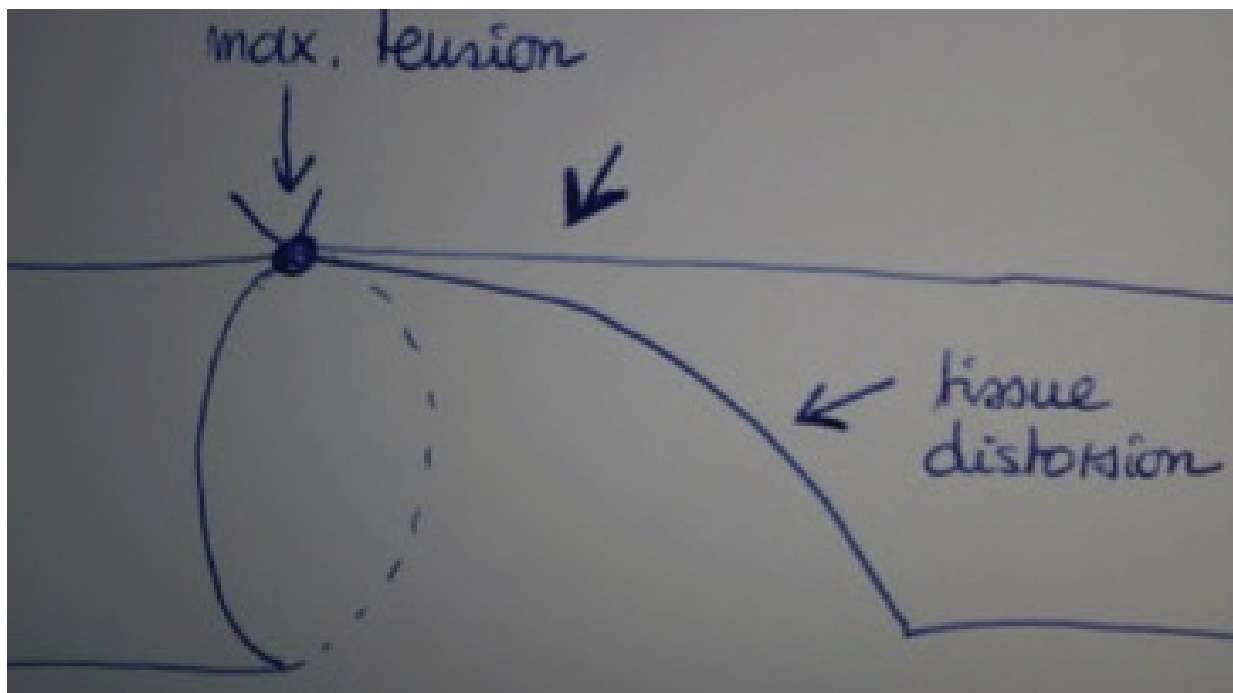
Every nerve microsurgeon knows that if there is tension, the first suture point is the most difficult to be achieved and at risk for filament rupture (**Figure 1**).

As there are more points added, the tension lowers (**Figure 2**) and at the end, the coaptation site shows a good appearance and mechanical resistance.

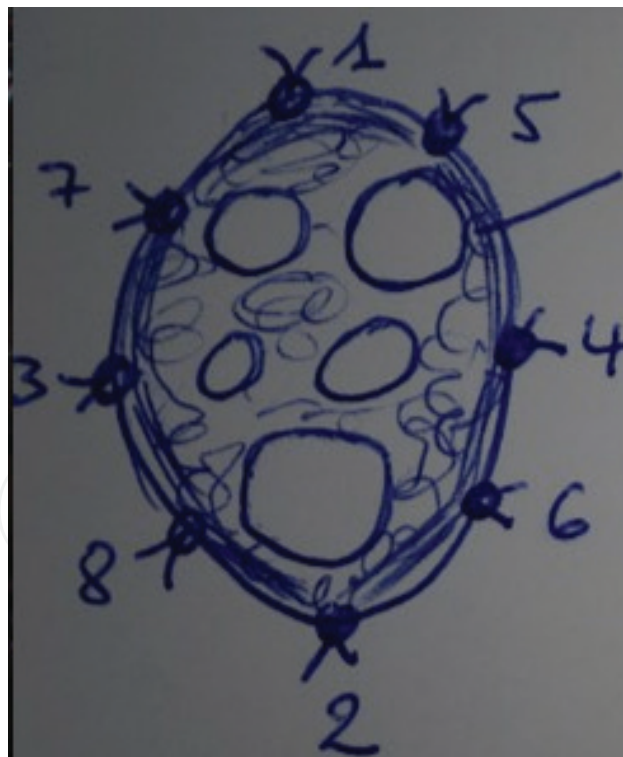
To prevent undue tension, either the proximal and/or the distal nerve stump may be mobilized, that is, freed from their paraneural tissue, thus giving additional length, gained at the price of decreased local blood supply (as the vasa nervorum might be interrupted by this circumferential paraneurolysis).

Also may one take advantage of the existence of “reserve capacity” of each peripheral nerve at the level of major joints, which are flexed to release more tissues.

In dramatic situations, like in war injuries or when considering very large nerve repairs (like the ischiatic nerve), bone shortening might be considered to reduce or overcome the gap.



**Figure 1.** Problem of the first epineurial suture knot under undue tension.

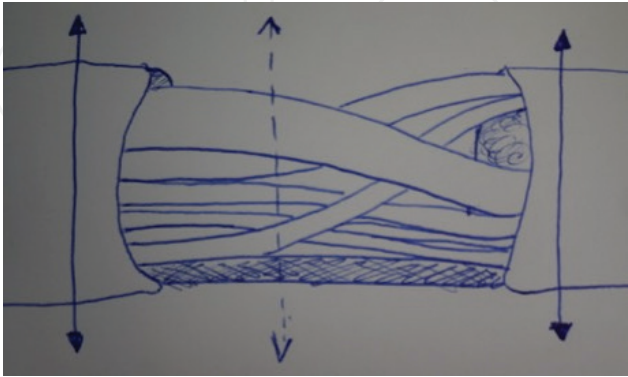


**Figure 2.** Tension decreases with more anchor points.

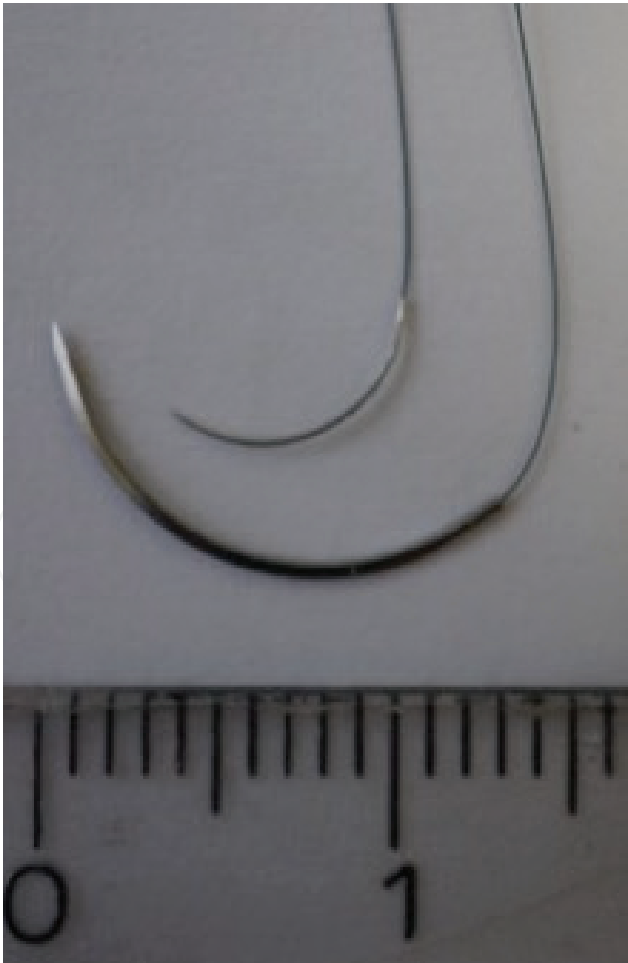
In very young children, like those suffering from OBPL, the structural elasticity of the longitudinally growing nerves is assumed to be enhanced, as is also the capacity of nerve regeneration and overall cortical plasticity. The young connective tissue is loose, nerve fibers

and myelin sheaths are thin and the peripheral nerve structure itself is continually under a longitudinal growth stretch.

Concerning nerve stump coaptation at every age, there is no way to overcome the fascicular malalignment due to the intrinsic plexual structure constitutional of most multifascicular peripheral nerves (**Figure 3**).



**Figure 3.** Intraneural plexiform fascicular structure.



**Figure 4.** Onalon 6/0 microsurgical filament: fine needle, 6/0 strand.

Moreover, we actually do not have an insight into the physiologic regeneration once the suture is completed and the wound is closed, as the diffusion tensor imaging (DTI) technology related to MRI images is actually not performed regularly after peripheral nerve surgery.

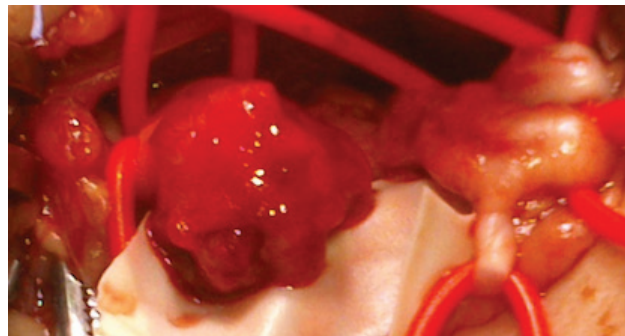
When it comes to the suture material, nerve microsurgeons routinely use 8–10 or 11/0 nylon (nonabsorbable monofilament) material with fine needles proportional to the filament diameter, that is, needles for 11/0 sutures are smaller and thinner than those for 8/0 sutures.

Recently, we developed in cooperation with Onatec (Pößneck Jestetten, Germany), a specific microsurgical suture material, made up of a 6/0 filament with a real microsurgical needle (**Figure 4**), allowing epineural nerve sutures of “bigger” nerves like the upper or middle trunk in OBPL repair or adult radial and median nerve coaptations.

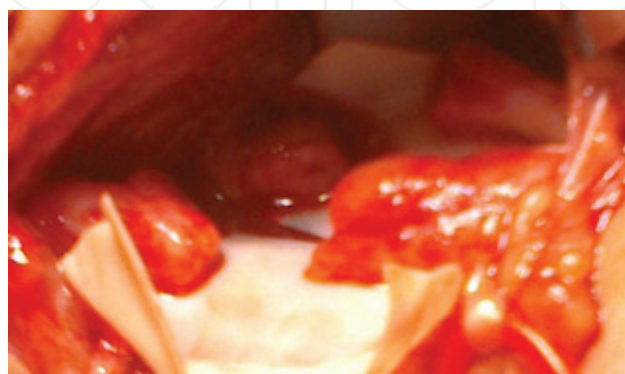
As the 6/0 filament is inserted strictly epineural and thus lays outside the fascicular structures, and as nylon is supposed to be biologically inert, we continued that practice on a prospective series of OBPL repairs we actually published with a follow up of 18 months and still very promising results of sensory and motor function recovery [3].

**Figures 5–7** show one clinical example of a typical upper and middle trunk neuroma repair with the identification of the rupture site (**Figure 5**), trimming of both proximal and distal stumps (**Figure 6**), and the direct suture (**Figure 7**).

The 6/0 strand together with a rather thick epineurium in larger nerves (like those mentioned above) gave us satisfactory coaptation stability already after two or three sutures, where

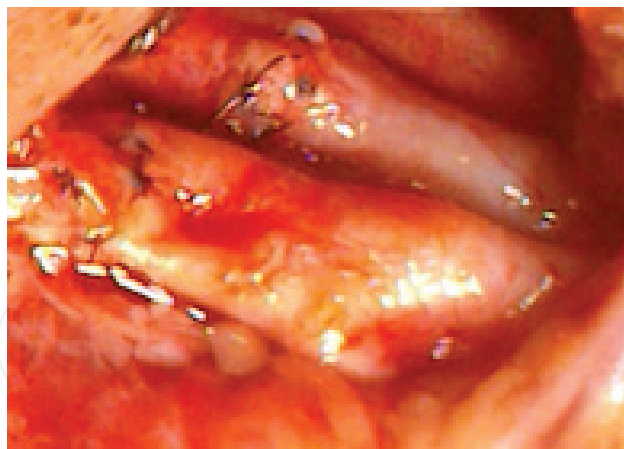


**Figure 5.** Clinical example of OBPL direct suture: upper and middle trunk rupture.



**Figure 6.** Clinical example of OBPL direct suture: after proximal and distal stump trimming.





**Figure 7.** Clinical example of OBPL direct suture: upper and middle trunk direct suture.

thinner suture filaments needed more sutures to stabilize the coaptation. Nevertheless, in our OBPL trunk coaptations, we regularly used a minimum of 6–8 6/0 epineural sutures (**Figure 2**) before surrounding the coaptation site with a sleeve of fibrin glue.

The only similar stabilizing technique using foreign material promoted polylacton (vicryl) strips applied outside the epineurium to decrease the tension onto the suture points [8].

### 3. Morphologic and mechanic analysis

Tension is a force applied onto a surface and might be reduced on a circumference while using more anchor points (remind **Figure 2**). Suture tension has so far not been quantified or measured, we probably could state that it is even unmeasurable in the *in vivo* situation of a surgical procedure.

The question is how much of the maintained tension into the nerve stump coaptation is transmitted to the periphery, that is, the stumps, and if this affects nerve regeneration and the physiologic function afterwards.

Some experiences support the concept of a negative influence of nerve stretching on the physiologic function [9]. But clinical results show the feasibility of this method without lowering the functional outcome, even providing unexpected good results.

Tension could harm by decreasing the blood flow in the vasa nervorum (a stretch on a circular blood vessel-tube would flatten it and diminish the cross section, thus theoretically lower the blood flow); but one could argue that through the initial nerve lesion and the surgical paraneurolysis, those freed segments are anyhow separated from the local blood supply.

Tension is also said to increase local fibrosis (the amount of collagen fibers), but we should further investigate if the tension in the epineural layer, holding the suture material, is equally transmitted to the deeper structures (the deep interfascicular epineurium and finally the perineurium and the fascicular sheets).

- 
- Very young patient
  - Acceptable nerve diameter (OBPL trunk or cord)
  - Limited scar and/or gap
  - Compliance for postoperative immobilization
- 

**Table 1.** Ideal conditions for a direct suture approach.

- 
- Good clinical result in OBPL direct sutures
  - Longitudinal growth in young patients
  - Tissue adaptation: elastic fibers, low collagen content, and postoperative immobilization
- 

**Table 2.** Strong arguments for a limited tension-suture model.

One could imagine that the tension is hold within the thicker epineural layer of a thicker peripheral nerve and that the aligned fascicles in the nerve depth are no longer experiencing distraction stress—thus the nerve regeneration happening on the highways of the deeper fascicules would not be disturbed (that’s what our clinical cases seem to show, like a “*tube-in-tube*” concept).

Tension is not measured easily, or even not at all, and once it comes to textbook descriptions like “reasonable tension” or “avoiding excessive tension” we should be convinced that the actually accepted dogma is weak.

On the other hand, there is the real danger of “promoting” bad microsurgical technique and overindication for direct coaptation, bringing together bad quality stumps under undue tension just to avoid a graft (donor site morbidity, longer procedure, two coaptation sites, but overall less fiber density).

**Table 1** summarizes ideal clinical conditions for a direct suture approach; **Table 2** summarizes strong arguments for a limited tension, suture approach.

#### 4. Literature research

Between 1975 and 2017, a PubMed MEDLINE research about “nerve suture” and “tension” only prompted eight valuable articles on nerve-suture related tension [8, 10–16]; presenting animal studies in rats, cats, dogs, and monkeys; using sciatic or upper limb nerves, and studying the outcome by histology and nerve conduction studies. There are so far no conclusive data about what is better and how much tension is tolerated.

#### 5. Further investigations and today’s conclusions

There is still enough controversy about tension tolerance in peripheral nerve surgery. Clinical outcomes oppose to the experimental background, which on deeper analysis is rather weak, as the literature on the subject is scarce.



Out of our actual clinical and scientific knowledge, we believe that further investigation could be conducted in several ways:

- biomechanical analysis of various suture filament strengths used in nerve coaptation
- nylon suture: long term interaction with the fascicular anatomy studied by late histologic examination
- a model of a tube, in tube, behavior of the peripheral nerve (epineural versus fascicular tubes)
- in vivo observation of coapted nerves in a regeneration chamber.

Meanwhile, we continue to use all available “tricks” and refinements to decrease the gap and the suture tension, to allow optimal nerve fiber regeneration, without any visual help to follow this biological process after reconstructive surgery.

Never should our analysis allow bad techniques with insufficiently cleared stumps, undue tension on the coaptation after three or four knots, the introduction of stronger filament material (3 or 4/0), not adapted to the local anatomy, extension of the proposed technique to smaller nerves with fine epineurium, and not supporting suture material thicker than 10 or 11/0.

But with further developments, we may define indications and good surgical background conditions with limited nerve damage, good mobilization capacity of stumps, good microsurgical coaptation, and rewarded after a good technique with a significant functional result.

## Author details

Jörg Bahm<sup>1,3\*</sup>, Tobias Esser<sup>1</sup>, Bernd Sellhaus<sup>2</sup>, Wissam El-kazzi<sup>3</sup> and Frederic Schuind<sup>3</sup>

\*Address all correspondence to: jorg.bahm@belgacom.net

1 Euregio Reconstructive Microsurgery Unit, Franziskus hospital Aachen, Germany

2 Institute for Neuropathology, RWTH University Hospital Aachen, Germany

3 Department for Orthopaedics and Traumatology, ULB Erasme University Hospital, Brussels, Belgium

## References

- [1] de Medinaceli L, Seaber AV. Experimental nerve reconnection: Importance of initial repair. *Microsurgery*. 1989;**10**:56-70
- [2] Bahm J, Ocampo-Pavez C, Noaman H. Microsurgical technique in obstetric brachial plexus repair: A personal experience in 200 cases over 10 years. *Journal of Brachial Plexus and Peripheral Nerve Injury*. 2007;**2**:1

- [3] Bahm J, Gkotsi A, Bouslama S, El-kazzi W, Schuind F. Direct nerve sutures in [extended] upper obstetric brachial plexus repair. *Journal of Brachial Plexus and Peripheral Nerve Injury*. 2017;**12**(1):e17-e20
- [4] Kirjavainen M, Remes V, Peltonen J, Rautakorpi S, Helenius I, Nietosvaara Y. The function of the hand after operations for obstetric injuries to the brachial plexus. *Journal of Bone and Joint Surgery (British)*. 2008;**90**(3):349-355
- [5] Kennedy R. Suture of the brachial plexus in birth paralysis of the upper extremity. *British Medical Journal*. 1903;**1**(2197):298-301
- [6] Millesi H. The nerve gap: Theory and clinical practice. *Hand Clinics*. 1986;**2**:651-663
- [7] Trumble T. Overcoming defects in peripheral nerves. In: Gelberman RH, editor. *Operative Nerve Repair and Reconstruction*. Philadelphia: Lippincott; 1991
- [8] Haas HG, Holste J. Spannungsentlastung bei Nähten peripherer Nerven. *Handchirurgie, Mikrochirurgie, Plastische Chirurgie*. 1990;**22**:156-162
- [9] Driscoll PJ, Glasby MA, Lawson GM. An in vivo study of peripheral nerves in continuity: Biomechanical and physiological responses to elongation. *Journal of Orthopaedic Research*. 2002;**20**:370-375
- [10] Hentz VR, Rosen JM, Xiao SJ, McGill KC, Abraham G. The nerve gap dilemma: A comparison of nerves repaired end to end under tension with nerve grafts in a primate model. *Journal of Hand Surgery*. 1993;**18**(3):417-425
- [11] Maeda T, Hori S, Sasaki S, Maruo S. Effects of tension at the site of coaptation on recovery of sciatic nerve function after neurorrhaphy: Evaluation by walking-track measurement, electrophysiology, histomorphometry, and electron probe X-ray microanalysis. *Microsurgery*. 1999;**19**:200-207
- [12] Miyamoto Y. Experimental study of results of nerve suture under tension vs. nerve grafting. *Plastic and Reconstructive Surgery*. 1979;**64**(4):540-549
- [13] Okamoto H, Oka Y. Experimental study on tension and stretching to peripheral nerve. *Nihon Seikeigeka Gakkai Zasshi*. 1990;**64**(5):472-484
- [14] Rodkey WG, Cabaud HE, McCarroll HR Jr. Neurorrhaphy after loss of a nerve segment: Comparison of epineurial suture under tension versus multiple nerve grafts. *Journal of Hand Surgery*. 1980;**5**(4):366-371
- [15] Scherman P, Kanje M, Dahlin LB. Bridging short nerve defects by direct repair under tension, nerve grafts or longitudinal sutures. *Restorative Neurology and Neuroscience*. 2004;**22**(2):65-72
- [16] Terzis J, Faibisoff B, Williams HB. The nerve gap: suture under tension vs. graft. *Plastic and Reconstructive Surgery*. 1975;**56**(2):166-170

