

We are IntechOpen, the world's leading publisher of Open Access books Built by scientists, for scientists

6,900

Open access books available

186,000

International authors and editors

200M

Downloads

Our authors are among the

154

Countries delivered to

TOP 1%

most cited scientists

12.2%

Contributors from top 500 universities



WEB OF SCIENCE™

Selection of our books indexed in the Book Citation Index
in Web of Science™ Core Collection (BKCI)

Interested in publishing with us?
Contact book.department@intechopen.com

Numbers displayed above are based on latest data collected.
For more information visit www.intechopen.com



Clinical Application of Enamel Matrix Derivative for Periodontal Regeneration and Treatment of Peri-Implantitis

Jun-Beom Park

Additional information is available at the end of the chapter

<http://dx.doi.org/10.5772/intechopen.78595>

Abstract

One of the goals of periodontal therapy is to regenerate lost supporting structures that have been destroyed by periodontal disease. Treatment procedures including various bone grafts, guided tissue regeneration, use of enamel matrix derivative, or combinations of the aforementioned have been suggested as regenerative periodontal therapies to achieve this goal. Enamel matrix derivative is composed of a number of proteins, 90% of which are amelogenins, and these proteins are thought to induce the formation of periodontal attachment during tooth formation. Previous reports have shown that enamel matrix derivative was able to improve clinical attachment level and reduce probing depth. The results of previous controlled clinical trials have shown that using enamel matrix derivative in combination with bovine porous bone mineral may enhance the regenerative outcome with regard to the clinical attachment level gain compared with using the enamel matrix derivative alone. In this chapter, an extensive review of the role of enamel matrix derivative will be performed using in vitro and in vivo studies. Clinical implications of the enamel matrix derivative will also be discussed.

Keywords: enamel matrix proteins, guided tissue regeneration, periodontics, regeneration

1. Introduction

One of the goals of periodontal therapy is to regenerate lost supporting structures that have been destroyed by periodontal disease [1]. Treatment procedures including various bone grafts, guided tissue regeneration, use of enamel matrix derivative, or combinations of the

aforementioned have been suggested as regenerative periodontal therapies to achieve this goal [2]. Enamel matrix derivative is composed of a number of proteins, 90% of which are amelogenins, and these proteins are thought to induce the formation of the periodontal attachment during tooth formation [3]. Previous reports have shown that enamel matrix derivative was able to improve clinical attachment level and reduce probing depth [4]. The results of previous controlled clinical trials have shown that using enamel matrix derivative in combination with bovine porous bone mineral may enhance the regenerative outcome with regard to the clinical attachment level gain compared with using enamel matrix derivative alone [5].

In this chapter, an extensive review of the role of the enamel matrix derivative will be performed using *in vitro* and *in vivo* studies. Clinical implications of the enamel matrix derivative will also be discussed.

2. Guided tissue regeneration

The concept of “guided tissue regeneration” has been in the clinic for very long time [6]. The barrier membrane allows space for the supporting tissue of the bone to be regenerated [7]. The membrane also prevents soft tissue invasion to the area to be regenerated [8]. Clinical results of guided tissue regeneration using bone graft and membrane are shown in **Figure 1**. Preoperative clinical and radiographic evaluations indicate the furcation involvement (**Figure 1A** and **B**). **Figure 1C** shows the buccal view after elevation of a full thickness flap showing involvement of the furcation at the mandibular right first molar. The defect area was filled with bone graft and resorbable membrane (**Figure 1D**). The clinical photograph of the mandibular right first molar and the radiograph of the mandibular right first molar with the regeneration of the furcation area are shown in **Figure 1E** and **F**, respectively.

Various membranes have been applied for this guided tissue regeneration application [9, 10]. The non-resorbable Gore-Tex membrane has been used [11]. However, there is a possibility of the exposure of membranes, which may produce a detrimental effect on the final outcome. It should also be noted that the non-resorbable membrane may be more suitable for vertical bone augmentation procedures [10]. Previous reports have shown that non-resorbable and bioabsorbable membranes in combination with graft material were both effective in enhancing the periodontal regeneration [11].

In a previous report, expanded polytetrafluoroethylene (e-PTFE) membranes were used to evaluate the healing pattern of bone regeneration in the membrane-applied area [12]. It was seen that significantly better healing was achieved with the application of the membrane when compared with the control group. Transmandibular defects of 5 mm in diameter were created in rats, and the test sites were covered with the barrier membrane [13]. The test sites showed complete healing at 6 weeks, but the control site without the membrane indicated little or no sign of healing.

The effects of early exposure of e-PTFE were tested by applying the membrane in fresh extraction sockets [14]. Non-exposure of the membrane for 6–8 months resulted in 99.6% of bone

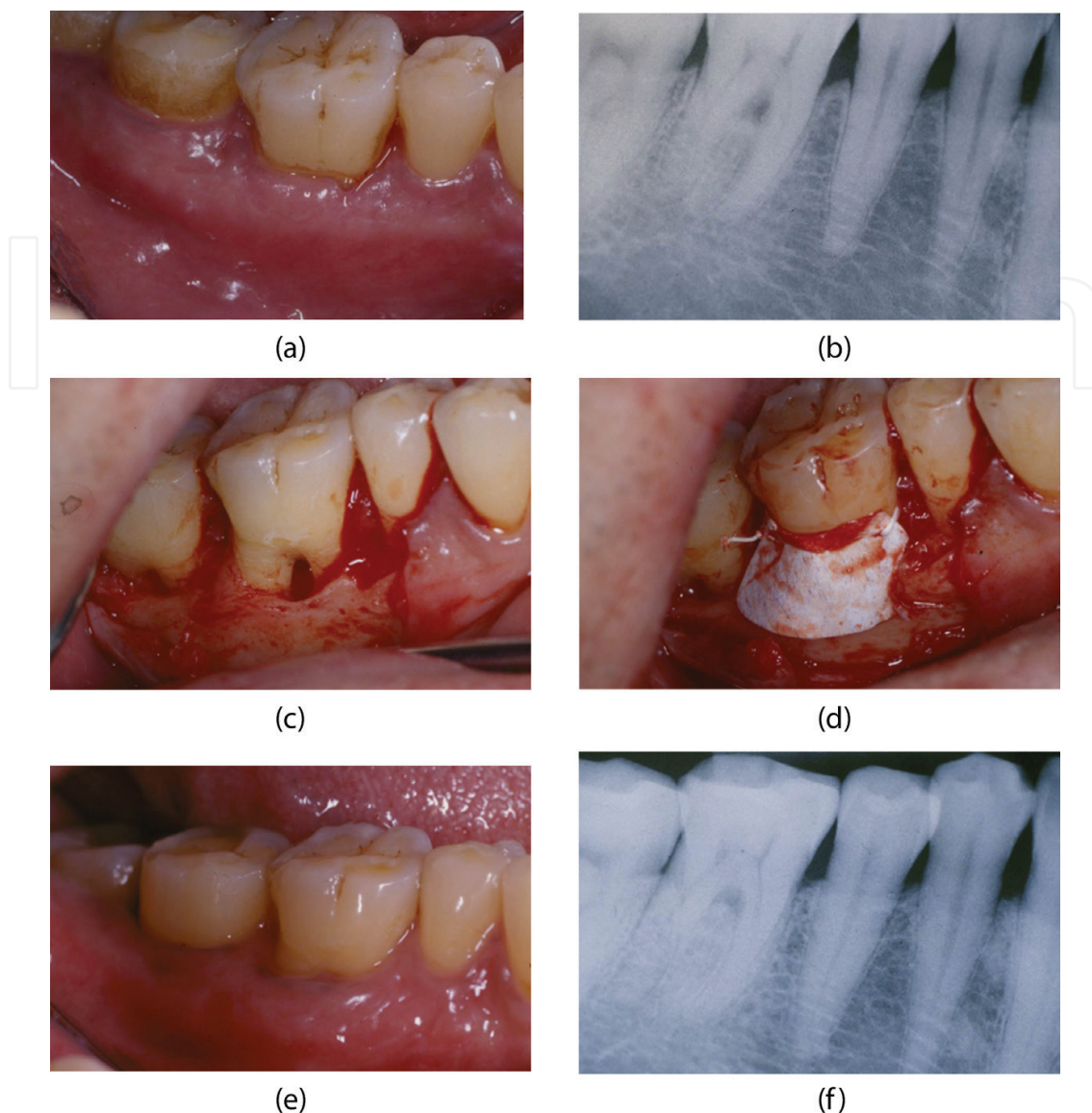


Figure 1. Clinical results of guided tissue regeneration using bone graft and membrane. (A) Preoperative view. (B) Preoperative periapical radiograph. (C) Buccal view after elevation of a full thickness flap showing involvement of the furcation at the mandibular right first molar. (D) The defect area was filled with bone graft and resorbable membrane. (E) The clinical photograph of the mandibular right first molar. (F) The radiograph of the mandibular right first molar with regeneration of the furcation area.

regeneration, but exposure of the membrane resulted in lower bone regeneration of 48.6%, suggesting that early exposure hinders bone regeneration around dental implants.

The mean average percentage of bone fill for bioresorbable collagen membrane was $92 \pm 19\%$, and the percentage was $78 \pm 50\%$ for the e-PTFE membrane [15]. Moreover, in e-PTFE cases, wound dehiscences were shown in 44%.

Previously, several principles were suggested for aiming at predictable results for bone regeneration [16]. Principle 1: Achievement of primary soft tissue healing to prevent membrane exposure. Principle 2: Creation and maintenance of a secluded space beneath the membrane. Principle 3: Stabilization and adaptation of the barrier membrane. Principle 4: Sufficient

healing period to achieve bone regeneration and maturation. Wang and Boyapati suggested several key factors, called PASS principles, for predictable guided bone regeneration, including primary wound closure, angiogenesis, space maintenance/creation, and the stability of wound and implant [17].

Vertical incision and periosteal-releasing incision can be applied for flap management [18]. In a more recent study, a flap advancement technique without vertical incision for guided bone regeneration was introduced using a sulcular incision extending to the adjacent two teeth with a wide periosteal-releasing incision and an additional releasing incision that selectively cut part of the facial expression muscles [19].

Maintaining space can be achieved by applying tenting screw technology, especially in deficient alveolar ridges and atrophic extraction sockets [20]. Titanium-reinforced membranes have been applied for the regeneration of recession defects, and it was concluded that this approach can be considered a predictable surgical procedure [21]. Alveolar ridge augmentation can also be performed with titanium mesh [22]. It was shown that a longer healing time may produce a large amount of bone fill [23].

3. Enamel matrix derivative

Enamel protein is secreted by ameloblasts [24], and enamel matrix derivative is a purified, lyophilized product extracted from porcine enamel matrix from crowns of developing premolars and molars [25]. A major component of enamel matrix derivative is amelogenin, and non-amelogenins consist of ameloblastin, enamelin, and amelotin [25].

The enamel matrix derivative with β -tricalcium phosphate was shown to be efficacious in the regeneration of intrabony defects [26]. Enamel matrix derivative is considered comparable to demineralized freeze-dried bone allograft and guided tissue regeneration and is considered better than open-flap debridement in the treatment of intrabony defects [26]. Meta-analysis showed that enamel matrix derivative produced additional clinical and radiographic benefits compared to open-flap debridement alone [27].

Figure 2 shows the regeneration of the defect area with enamel matrix only. The preoperative periapical radiograph of the mandibular left first molar shows the loss of the supporting bone in the distal area (**Figure 2A**). An elevation of a full thickness flap indicated the loss of alveolar bone in the distal root area (**Figure 2B**). A 10-month postoperative clinical view and radiograph showed uneventful healing (**Figure 2C and D**). The radiograph at 1 year and 11 months postoperative showed increased radiopacity in the distal root area (**Figure 2E**).

The viscosity of enamel matrix derivative decreases if the circumstance changes from acidic and cool to physiological conditions [28]. This application of enamel matrix derivative enhanced cell attachment and periodontal ligament extension [29]. Enamel matrix protein promoted the reformation of acellular cementum [30]. Enamel matrix derivative mimicked the role of enamel proteins in cementogenesis during the development of teeth [31]. The deposition of enamel matrix proteins and subsequent acellular cementum formation seems

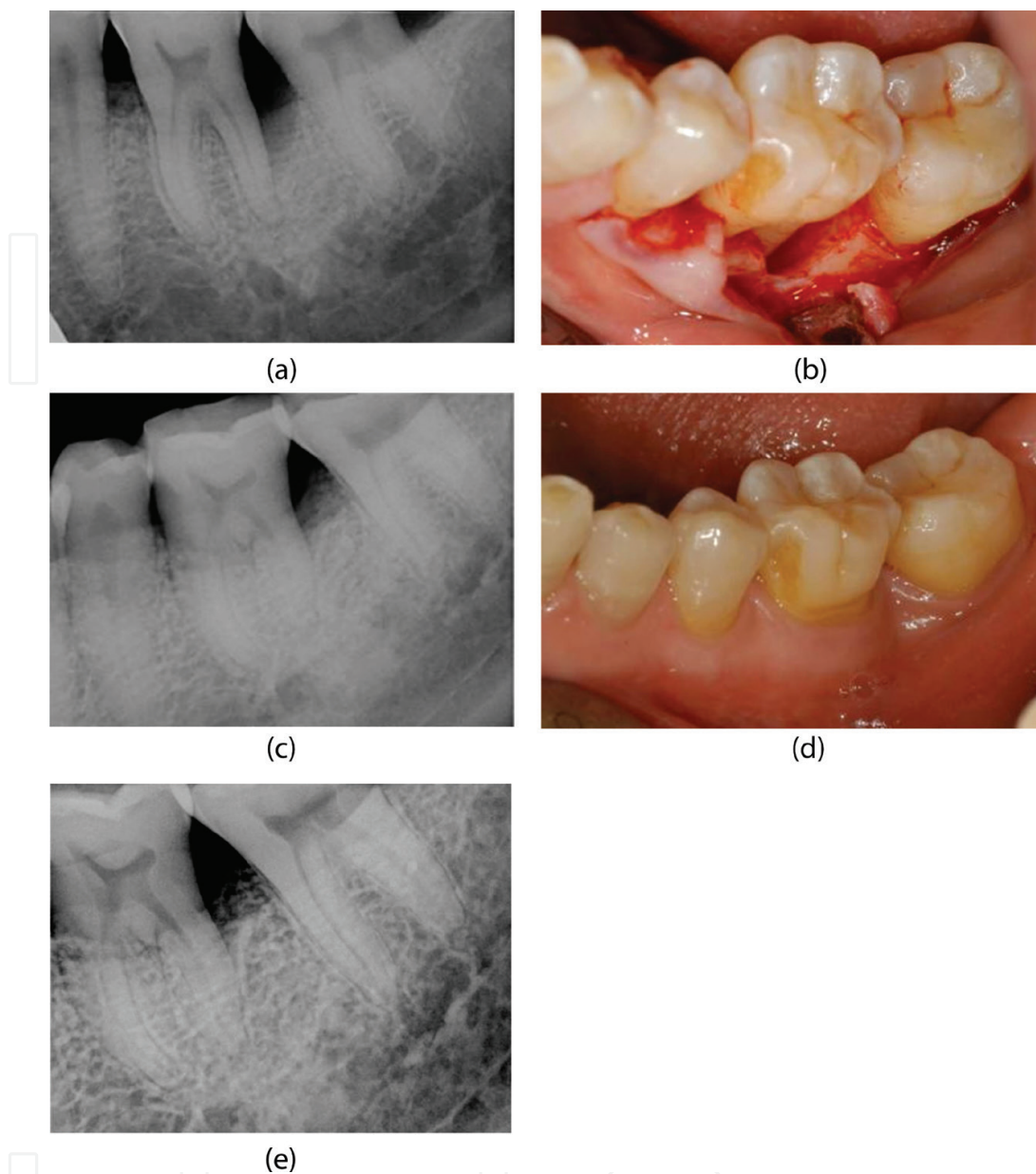


Figure 2. Regeneration of the defect area with enamel matrix only. (A) Preoperative periapical radiograph of the mandibular left first molar with loss of supporting bone in the distal area. (B) Buccal view after elevation of a full thickness flap, showing the loss of alveolar bone in the distal root area. (C) Ten-month postoperative clinical view indicating the uneventful healing. (D) Ten-month postoperative radiograph. (E) The radiograph at 1 year and 11 months postoperative, showing increased radiopacity in the distal root area.

important for the reformation of alveolar bone and periodontal ligament [32]. Earlier gains in soft-tissue density were noted after the application of enamel matrix derivative [4].

The application of enamel matrix derivative combined with coronally advanced flaps produced similar results when compared with the connective tissue grafts in conjunction with coronally advanced flaps [33]. However, another report on the use of enamel matrix derivative indicated that it does not seem to significantly improve the results of the coronally advanced flap procedure for root coverage in the treatment of multiple recessions [34].

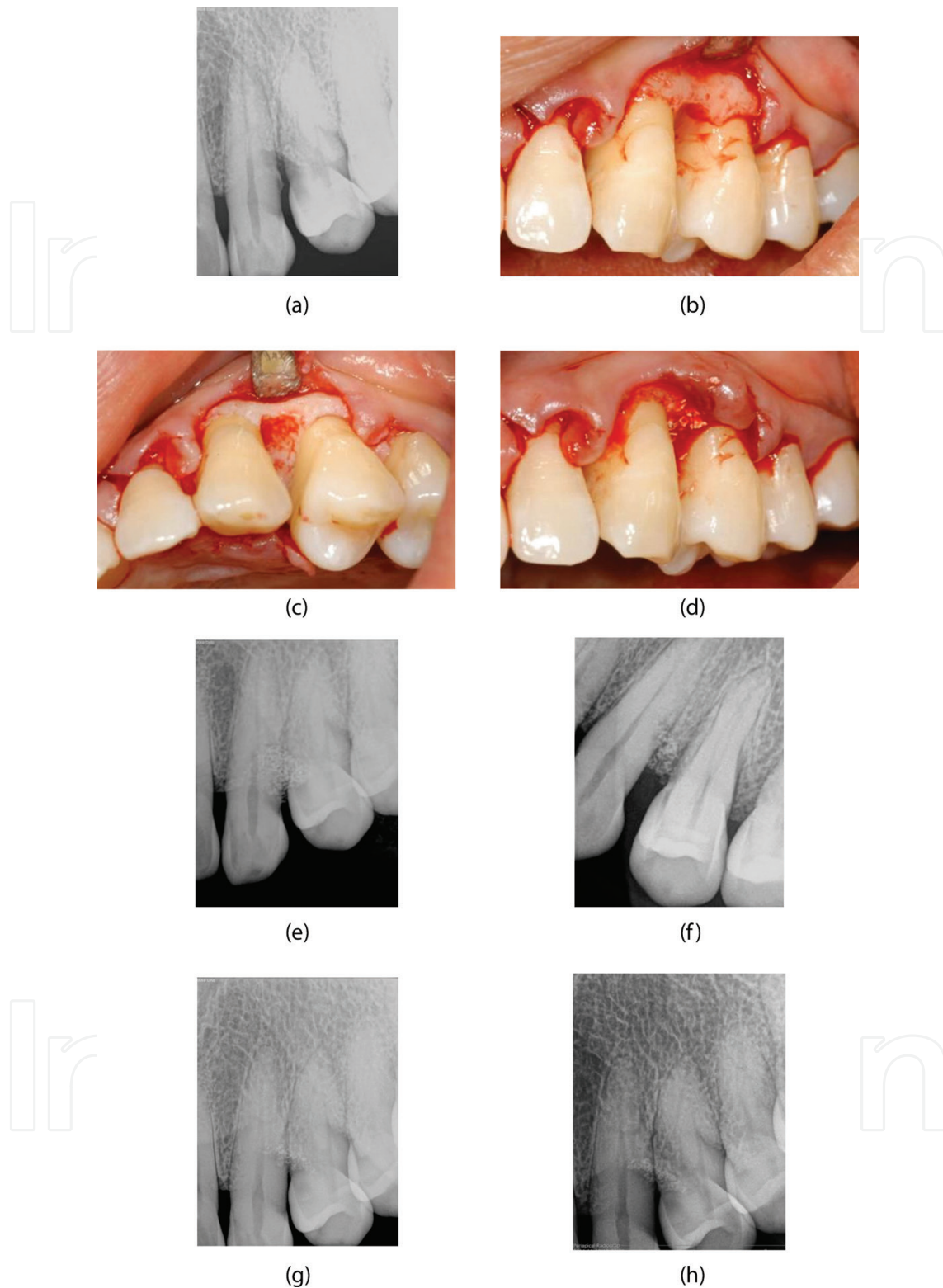


Figure 3. Regeneration of the defect area with enamel matrix and bone graft material. (A) Preoperative periapical radiograph showing the loss of supporting area between the maxillary left canine and first premolar. (B) Clinical buccal view after elevation of a full thickness flap, showing loss of supporting tissue between the maxillary left canine and first premolar. (C) Occlusal buccal view showing the defect. (D) The defect area was filled with graft material and enamel matrix derivative. (E) The periapical radiograph right after surgery. (F) The periapical radiograph taken at 6 weeks after surgery. The graft seems stabilized at the defect site. (G) Eight-month postoperative radiograph. (H) The radiograph taken at 1 year and 6 months after the regenerative surgery.

Enamel matrix derivative was applied for autotransplantation [35]. The procedure consists of the following: Clean the denuded root surface with manual and ultrasonic scalers and wash the surface with saline before extraction. Extract the tooth gently with forceps and prepare the recipient site. The administration of enamel matrix derivative should be done on the whole surface of the tooth. The donor tooth should be placed in the recipient. Suture the wound tightly, and the transplanted tooth should be left without occlusal contact.

The combination therapies of enamel matrix derivative and bone graft yielded better clinical outcomes regarding gain of defect fill and recovery of gingival recession in periodontal intrabony defects [36]. **Figure 3** shows the regeneration of the defect area with enamel matrix and bone graft material. A preoperative periapical radiograph showed the loss of supporting area between the maxillary left canine and first premolar (**Figure 3A**). Elevation of a full thickness flap showed the loss of supporting tissue between the maxillary left canine and first premolar (**Figure 3B**). The clinical view showed the defects around the tooth, and the defect area was filled with graft material and enamel matrix derivative (**Figure 3C and D**). **Figure 3E** shows the periapical radiograph right after surgery. **Figure 3F** shows the periapical radiograph taken at 6 weeks after surgery. The graft seems stabilized at the defect site. The 8-month postoperative radiograph and the radiograph taken at 1 year and 6 months after the regenerative surgery are shown in **Figure 3G and H**, respectively.

4. Application of enamel matrix derivative on the titanium surface

Enamel matrix derivative is shown to enhance the proliferation and osteogenic differentiation of human periodontal ligament stem cells on the titanium implant surface at concentrations of 5–60 µg/ml [37]. Enamel matrix derivative is shown to influence the proliferation and expression of angiogenic genes in endothelial cells on different titanium surfaces [38]. Enamel matrix derivative is shown to enhance the behavior of gingival fibroblasts on the titanium surface, proven by increased cell growth, spreading, and the synthesis of an extracellular matrix [39]. The surface topography did not influence this phenomenon.

A previous report showed that the application of enamel matrix derivative can be considered an adjunct to mechanical debridement in the non-surgical treatment of peri-implant mucositis [40]. The bone regenerative potential of enamel matrix protein was tested in the circumferential defect around a dental implant [41]. A randomized controlled trial of the surgical treatment of peri-implantitis using enamel matrix derivative proved that the adjunctive use of enamel matrix derivative improved implant survival [42].

In a previous report, adjunctive enamel matrix derivative to the surgical treatment of peri-implantitis was associated with the prevalence of Gram+/aerobic bacteria during the follow-up period and increased marginal bone level at the final evaluation [43].

Figure 4 shows the regeneration of peri-implantitis with enamel matrix derivative. A preoperative buccal view of the implant installed in the second premolar area is seen in **Figure 4A**. The periapical radiograph indicates the loss of the supporting bone (**Figure 4B**). Elevation of a full thickness flap showed the loss of alveolar bone around the dental implant (**Figure 4C**).

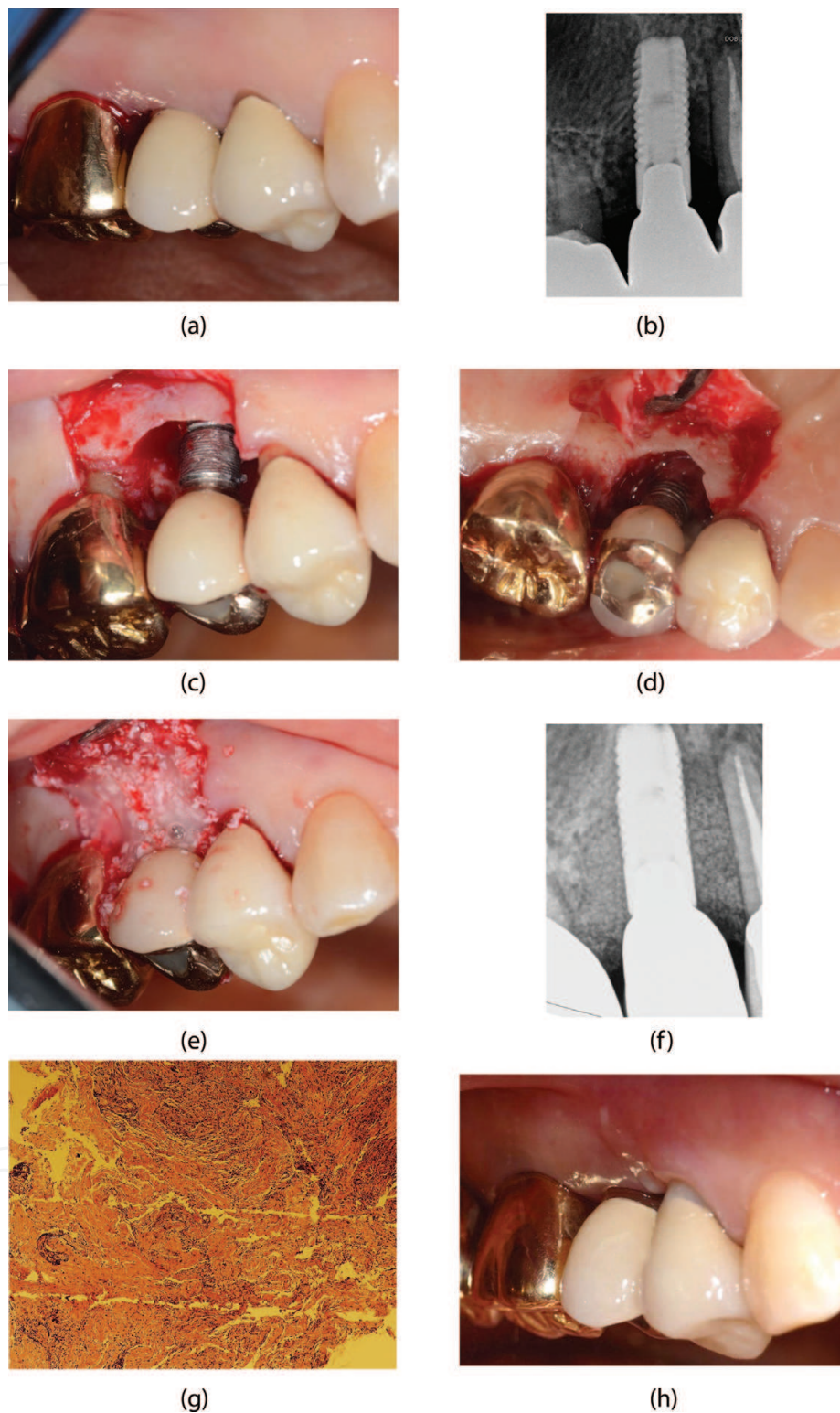


Figure 4. Regeneration of peri-implantitis with enamel matrix derivative. (A) Preoperative buccal view of implant installed in the second premolar area. (B) The periapical radiograph indicating the loss of the supporting bone. (C) Clinical buccal view after elevation of a full thickness flap, showing the loss of alveolar bone around the dental implant. (D) Occlusal buccal view showing the defect. (E) The defect area was filled with graft material and enamel matrix derivative. (F) The radiograph after surgery. (G) The tissue was removed during the surgery, and histological analysis was performed. the results showed that acute and chronic inflammation with fibrosis with collagen fibers intermingled with numerous lymphocytes and inflammatory infiltrate occupied a large area of the peri-implant soft tissue. (H) Ten-month postoperative clinical buccal view.

The occlusal buccal showed a defect in **Figure 4D**. The defect area was filled with graft material and enamel matrix derivative (**Figure 4E**), and the radiograph showed results after surgery (**Figure 4F**). The tissue was removed during the surgery, and histological analysis was performed. The results showed that acute and chronic inflammation with fibrosis with collagen fibers intermingled with numerous lymphocytes and inflammatory infiltrate occupied a large area of the peri-implant soft tissue (**Figure 4G**). A 10-month postoperative clinical buccal view is shown in **Figure 4H**.

5. Conclusions

This chapter showed the clinical implications of enamel matrix derivative. Previous reports have shown that enamel matrix derivative was able to improve clinical attachment level and reduce probing depth, and enamel matrix derivative in combination with bovine porous bone mineral may enhance the regenerative outcome with regard to the clinical attachment level gain compared with using enamel matrix derivative alone.

Acknowledgements

This study was supported by Basic Science Research Program through the National Research Foundation of Korea (NRF) funded by the Ministry of Science, Information and Communication Technology and Future Planning (NRF-2017R1A1A1A05001307).

Conflict of interest

The authors confirm that they have no competing interests.

Author details

Jun-Beom Park

Address all correspondence to: jbassoonis@yahoo.co.kr

Department of Periodontics, College of Medicine, The Catholic University of Korea, Seoul, Republic of Korea

References

- [1] Wang HL, Greenwell H, Fiorellini J, et al. Periodontal regeneration. *Journal of Periodontology*. 2005;76:1601-1622

- [2] Rathva VJ. Enamel matrix protein derivatives: Role in periodontal regeneration. *Clinical, Cosmetic and Investigational Dentistry*. 2011;**3**:79-92
- [3] Esposito M, Grusovin MG, Papanikolaou N, Coulthard P, Worthington HV. Enamel matrix derivative (Emdogain) for periodontal tissue regeneration in intrabony defects. A Cochrane systematic review. *European Journal of Oral Implantology*. 2009;**2**:247-266
- [4] Miron RJ, Sculean A, Cochran DL, et al. Twenty years of enamel matrix derivative: The past, the present and the future. *Journal of Clinical Periodontology*. 2016;**43**:668-683
- [5] Birang R, Abouei MS, Razavi SM, Zia P, Soolari A. The effect of an enamel matrix derivative (Emdogain) combined with bone ceramic on bone formation in mandibular defects: A histomorphometric and immunohistochemical study in the canine. *The Scientific World Journal*. 2012;**2012**:196791
- [6] Pretzl B, Kim TS, Holle R, Eickholz P. Long-term results of guided tissue regeneration therapy with non-resorbable and bioabsorbable barriers. IV. A case series of infrabony defects after 10 years. *Journal of Periodontology*. 2008;**79**:1491-1499
- [7] Sam G, Pillai BR. Evolution of barrier membranes in periodontal regeneration—“Are the third generation membranes really here?”. *Journal of Clinical and Diagnostic Research*. 2014;**8**:Ze14-Ze17
- [8] Pellegrini G, Pagni G, Rasperini G. Surgical approaches based on biological objectives: GTR versus GBR techniques. *International Journal of Dentistry*. 2013;**2013**:521547
- [9] Sheikh Z, Qureshi J, Alshahrani AM, et al. Collagen based barrier membranes for periodontal guided bone regeneration applications. *Odontology*. 2017;**105**:1-12
- [10] Soldatos NK, Stylianou P, Koidou VP, Angelov N, Yukna R, Romanos GE. Limitations and options using resorbable versus nonresorbable membranes for successful guided bone regeneration. *Quintessence International*. 2017;**48**:131-147
- [11] Wadhawan A, Gowda TM, Mehta DS. Gore-tex((R)) versus resolut adapt((R)) GTR membranes with perioglas((R)) in periodontal regeneration. *Contemporary Clinical Dentistry*. 2012;**3**:406-411
- [12] Schenk RK, Buser D, Hardwick WR, Dahlin C. Healing pattern of bone regeneration in membrane-protected defects: A histologic study in the canine mandible. *The International Journal of Oral & Maxillofacial Implants*. 1994;**9**:13-29
- [13] Dahlin C, Linde A, Gottlow J, Nyman S. Healing of bone defects by guided tissue regeneration. *Plastic and Reconstructive Surgery*. 1988;**81**:672-676
- [14] Simion M, Baldoni M, Rossi P, Zaffe D. A comparative study of the effectiveness of e-PTFE membranes with and without early exposure during the healing period. *The International Journal of Periodontics & Restorative Dentistry*. 1994;**14**:166-180
- [15] Zitzmann NU, Naef R, Scharer P. Resorbable versus nonresorbable membranes in combination with Bio-Oss for guided bone regeneration. *The International Journal of Oral & Maxillofacial Implants*. 1997;**12**:844-852

- [16] Buser D, Dula K, Belser U, Hirt HP, Berthold H. Localized ridge augmentation using guided bone regeneration. 1. Surgical procedure in the maxilla. *The International Journal of Periodontics & Restorative Dentistry*. 1993;**13**:29-45
- [17] Wang HL, Boyapati L. "PASS" principles for predictable bone regeneration. *Implant Dentistry*. 2006;**15**:8-17
- [18] Park JB. Implant installation with bone augmentation and transmucosal healing with demineralized human cortical bone in the maxillary anterior region: Report of 3 cases. *The Journal of Oral Implantology*. 2012;**38**:762-766
- [19] Kim Y, Kim TK, Leem DH. Clinical study of a flap advancement technique without vertical incision for guided bone regeneration. *The International Journal of Oral & Maxillofacial Implants*. 2015;**30**:1113-1118
- [20] Chasioti E, Chiang TF, Drew HJ. Maintaining space in localized ridge augmentation using guided bone regeneration with tenting screw technology. *Quintessence International*. 2013;**44**:763-771
- [21] Tinti C, Vincenzi GP. Expanded polytetrafluoroethylene titanium-reinforced membranes for regeneration of mucogingival recession defects. A 12-case report. *Journal of Periodontology*. 1994;**65**:1088-1094
- [22] Poli PP, Beretta M, Cicciu M, Maiorana C. Alveolar ridge augmentation with titanium mesh. A retrospective clinical study. *The Open Dentistry Journal*. 2014;**8**:148-158
- [23] Jovanovic SA, Spiekermann H, Richter EJ. Bone regeneration around titanium dental implants in dehiscence defect sites: A clinical study. *The International Journal of Oral & Maxillofacial Implants*. 1992;**7**:233-245
- [24] Deutsch D, Catalano-Sherman J, Dafni L, David S, Palmon A. Enamel matrix proteins and ameloblast biology. *Connective Tissue Research*. 1995;**32**:97-107
- [25] Lyngstadaas SP, Wohlfahrt JC, Brookes SJ, Paine ML, Snead ML, Reseland JE. Enamel matrix proteins; old molecules for new applications. *Orthodontics & Craniofacial Research*. 2009;**12**:243-253
- [26] DiGiovanni CW, Lin SS, Baumhauer JF, et al. Recombinant human platelet-derived growth factor-BB and beta-tricalcium phosphate (rhPDGF-BB/beta-TCP): An alternative to autogenous bone graft. *The Journal of Bone and Joint Surgery. American Volume*. 2013;**95**:1184-1192
- [27] Graziani F, Gennai S, Cei S, et al. Does enamel matrix derivative application provide additional clinical benefits in residual periodontal pockets associated with suprabony defects? A systematic review and meta-analysis of randomized clinical trials. *Journal of Clinical Periodontology*. 2014;**41**:377-386
- [28] Gestrelus S, Andersson C, Johansson AC, et al. Formulation of enamel matrix derivative for surface coating. Kinetics and cell colonization. *Journal of Clinical Periodontology*. 1997;**24**:678-684

- [29] Apicella A, Heunemann P, DeJace L, Marascio M, Plummer CJG, Fischer P. Scaffold requirements for periodontal regeneration with enamel matrix derivative proteins. *Colloids and Surfaces. B, Biointerfaces*. 2017;**156**:221-226
- [30] Hammarstrom L. The role of enamel matrix proteins in the development of cementum and periodontal tissues. *CIBA Foundation Symposium*. 1997;**205**:246-255. discussion 255-260
- [31] Harrison JW, Roda RS. Intermediate cementum. Development, structure, composition, and potential functions. *Oral Surgery, Oral Medicine, Oral Pathology, Oral Radiology, and Endodontics*. 1995;**79**:624-633
- [32] Gestrelus S, Andersson C, Lidstrom D, Hammarstrom L, Somerman M. In vitro studies on periodontal ligament cells and enamel matrix derivative. *Journal of Clinical Periodontology*. 1997;**24**:685-692
- [33] Alexiou A, Vouros I, Menexes G, Konstantinidis A. Comparison of enamel matrix derivative (Emdogain) and subepithelial connective tissue graft for root coverage in patients with multiple gingival recession defects: A randomized controlled clinical study. *Quintessence International*. 2017;**48**:381-389
- [34] Cordaro L, di Torresanto VM, Torsello F. Split-mouth comparison of a coronally advanced flap with or without enamel matrix derivative for coverage of multiple gingival recession defects: 6- and 24-month follow-up. *The International Journal of Periodontics & Restorative Dentistry*. 2012;**32**:e10-e20
- [35] Ninomiya M, Kamata N, Fujimoto R, et al. Application of enamel matrix derivative in autotransplantation of an impacted maxillary premolar: A case report. *Journal of Periodontology*. 2002;**73**:346-351
- [36] Li W, Xiao L, Hu J. The use of enamel matrix derivative alone versus in combination with bone grafts to treat patients with periodontal intrabony defects: A meta-analysis. *Journal of the American Dental Association (1939)*. 2012;**143**:e46-e56
- [37] Li G, Hu J, Chen H, et al. Enamel matrix derivative enhances the proliferation and osteogenic differentiation of human periodontal ligament stem cells on the titanium implant surface. *Organogenesis*. 2017;**13**:103-113
- [38] Shi B, Andrukhov O, Ozdemir B, Shokoohi Tabrizi HA, Dard M, Rausch-Fan X. Effect of enamel matrix derivative on the angiogenic behaviors of human umbilical vein endothelial cells on different titanium surfaces. *Dental Materials Journal*. 2017;**36**:381-386
- [39] Wang Y, Zhang Y, Jing D, Shuang Y, Miron RJ. Enamel matrix derivative improves gingival fibroblast cell behavior cultured on titanium surfaces. *Clinical Oral Investigations*. 2016;**20**:685-695
- [40] Kashfimehr A, Pourabbas R, Faramarzi M, et al. Effects of enamel matrix derivative on non-surgical management of peri-implant mucositis: A double-blind randomized clinical trial. *Clinical Oral Investigations*. 2017;**21**:2379-2388

- [41] Lim HC, Lee JS, Jung UW, Choi SH. Bone regenerative potential of enamel matrix protein in the circumferential defect around a dental implant. *Implant Dentistry*. 2016;**25**:179-185
- [42] Isehed C, Svenson B, Lundberg P, Holmlund A. Surgical treatment of peri-implantitis using enamel matrix derivative, an RCT: 3- and 5-year follow-up. *Journal of Clinical Periodontology*. 2018. [Epub ahead of print]
- [43] Isehed C, Holmlund A, Renvert S, Svenson B, Johansson I, Lundberg P. Effectiveness of enamel matrix derivative on the clinical and microbiological outcomes following surgical regenerative treatment of peri-implantitis. A randomized controlled trial. *Journal of Clinical Periodontology*. 2016;**43**:863-873

IntechOpen

