

We are IntechOpen, the world's leading publisher of Open Access books Built by scientists, for scientists

6,900

Open access books available

186,000

International authors and editors

200M

Downloads

Our authors are among the

154

Countries delivered to

TOP 1%

most cited scientists

12.2%

Contributors from top 500 universities



WEB OF SCIENCE™

Selection of our books indexed in the Book Citation Index
in Web of Science™ Core Collection (BKCI)

Interested in publishing with us?
Contact book.department@intechopen.com

Numbers displayed above are based on latest data collected.
For more information visit www.intechopen.com



Fissure-In-ANO

Muhammad Fahadullah and Colin Peirce

Additional information is available at the end of the chapter

<http://dx.doi.org/10.5772/intechopen.76887>

Abstract

This chapter provides a summary of the aetiology, diagnosis, investigation and management of anal fissure. It gives an overview of clinical anatomy and pathophysiology related to anal fissure. Focusing on anal sphincter hypertonia as the key factor for anal fissure progression, the chapter draws attention to perpetuating factors that contribute to a vicious cycle of fissure non-healing and addresses management options for these factors. This chapter also looks at the way how different treatment options for anal fissure emerged over time and uses evidence-based medicine to compare these options. “Fissure-in-ANO” concludes with summarising the treatment options and suggesting an algorithm for management of acute and chronic anal fissures.

Keywords: anal fissure, sphincter hypertonia, lateral internal sphincterotomy, glyceryl trinitrate, faecal incontinence

1. Introduction

Anal fissure, also known as fissure-in-ano, is a common cause of perianal pain. Patients often describe the pain they experience during a bowel movement as ‘passing shards of glass’, and the pain is often associated with rectal bleeding.

An anal fissure is an ulcer like longitudinal tear in the squamous epithelium of the anal canal, which extends from the anal verge cephalad sometimes up to the level of the dentate line. It usually causes pain both during and for 1–2 h after defecation [1]. This feature helps to distinguish anal fissure from other causes of anal pain such as perianal and ischiorectal abscesses, thrombosed haemorrhoids, viral ulcers, and others. As patients may be embarrassed about the anatomic location of their symptoms, they may present to care late in the course of their illness.

An annual incidence of 1.1 per 1000 person-years is reported, equivalent to an average life-time risk of 7.8%. There are approximately 342,000 new cases diagnosed in the United States of America annually, a figure similar to appendectomies performed, but study estimates vary widely. One retrospective population-based study found that anal fissures most commonly affected females aged 12–24 years and males 55–64 years of age [2]. Risk factors included chronic constipation, obesity, hypothyroidism, and solid tumours.

2. Anatomy

An acute anal fissure has the appearance of a clean longitudinal tear in the anoderm, sometimes with surrounding inflammation. A chronic fissure is usually deeper and generally has exposed internal anal sphincter (IAS) fibres at its base. It is frequently associated with a hypertrophic anal papilla at its proximal aspect and with an irritated skin tag or sentinel pile at its distal aspect.

The anal canal can be described in terms of the 'surgical' and 'anatomical' anal canal. The surgical anal canal is approximately 4 cm long extending from the anal verge (anocutaneous line) to the anorectal ring (muscular ring formed at the junction of the rectum and anal canal) proximally. The anatomical anal canal is approximately 2 cm in length and extends from the anal verge distally to the dentate line (junction of the ectoderm and endoderm in the anal canal) proximally.

The epithelium of the anal canal between the anal verge below and the pectinate line above is anal mucosa. This area has somatic sensation and is the reason why anal fissures are painful. The anal canal just above the pectinate line for about 1–2 cm is called the anal transitional zone (ATZ). Above the ATZ, the anal canal is lined with columnar epithelium.

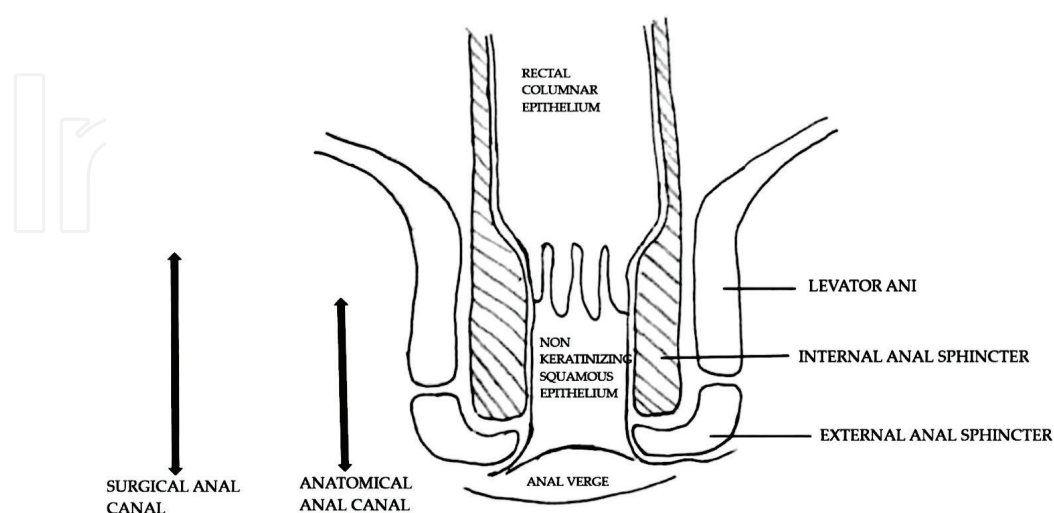


Figure 1. Schematic representation of anal canal anatomy.

The inner smooth muscle layer of the colon and rectum thickens in its lowermost part over a length of 2.5–4 cm of the rectum to form the IAS. The IAS is an involuntary muscle that is in a state of continuous contraction to prevent flatal and faecal incontinence. The external anal sphincter (EAS) forms a circular tube around the anal canal. It merges proximally with the puborectalis and the levator ani muscles to form a single complex. It is supplied by the inferior rectal nerves and by a perineal branch of the fourth sacral nerve. This muscle is predominantly under voluntary contraction.

An anal fissure involves only the epithelium and when chronic in nature it involves the full thickness of the anal mucosa rendering fibres of the IAS visible. Hypertonia and hypertrophy of the IAS are commonly observed (**Figures 1–3**).

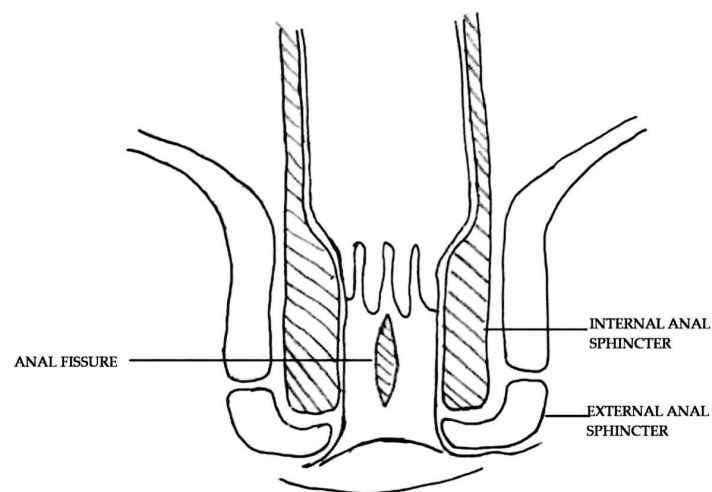


Figure 2. Schematic description of anal fissure.

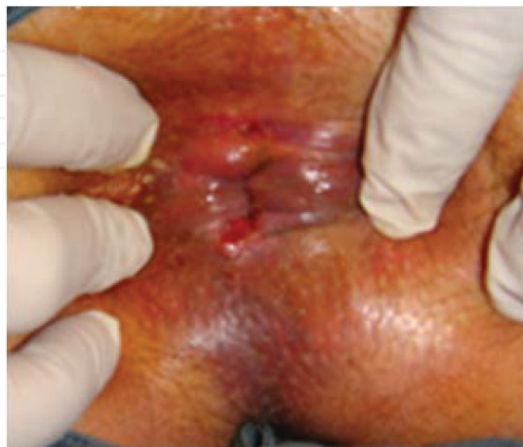

Figure 3. Posterior fissure-in-ano.

3. Pathophysiology

Different factors are involved in initiating and perpetuating the symptoms of an anal fissure. Stretching of the anal mucosa beyond its physiological limits initiates the cycle, which causes a breakdown in mucosal integrity in areas with poor muscular support i.e. an area of the relative paucity of support between the coccyx and the anorectal ring. This is followed by attempts at healing that are compromised by bowel movements that bring about repeated injury due to stretching of the whole muscular complex. The impaired healing and pain leads to persistent spasm of the IAS and an increased mean average resting luminal pressure. The persistent spasm prevents opposition of the tear leading to impaired wound healing, bacterial colonisation and progression from an acute to a chronic anal fissure in up to 40% of patients [3]. The high anal resting tone also reduces the blood supply to the posterior midline, an area of poor vascular supply of the anal canal. This explains why approximately 90% of anal fissures in both men and women are located posteriorly in the midline. Another contributing factor for posterior anal fissure is lack of clinical perineal descent in people with anal fissure which leads to repeated preferential over-stretching of the posterior anal sphincter complex and perineum. On the contrary, normally during defecation the anal sphincters and the puborectalis muscle relax, which allows the anorectal angle to widen and the perineum to descend avoiding overstretching of the posterior perineum [4].

Anterior fissures occur in 10% of patients, more commonly women and predominantly after vaginal delivery. Atypical fissures are very rare (less than 1%) and are usually found away from the midline or are multiple in number and should raise a suspicion of underlying conditions such as inflammatory bowel disease e.g. Crohn's disease, sexually transmitted diseases (human immunodeficiency disease, syphilis, or herpes), anal cancer or tuberculosis [5].

Studies have shown that people with anal fissures have increased tone [6] and hypertrophy of the IAS. The anal spasm can additionally cause ischemia of sensitive rectal tissue, which exacerbates the condition [7]. This concept is utilised in both the medical and surgical management of anal fissure.

Anal hypertonicity may aggravate perfusion to the anal canal. Studies using anorectal manometry have demonstrated hypertonia of the IAS and have shown fewer IAS relaxations in patients with chronic anal fissures [8]. Relative ischemia of the posterior anal canal has been demonstrated in chronic, non-healing anal fissures. Post-mortem studies have shown that the posterior midline of the anal canal is poorly perfused in 85% of patients. Increased IAS tone can compromise perfusion to the posterior commissure, as it increases pressure on vessels passing in a perpendicular direction through the sphincter where blood flow is already sparse [9]. Doppler laser flow studies have clearly shown lower anodermal blood flow at the fissure site compared with the posterior commissure of controls [8, 10]. Nitrous oxide synthase was also found to be intrinsically lower in individuals with fissures in one study [11].

4. Clinical findings

Patients can present with an acute or a chronic fissure-in-ano. In the acute setting, patients often complain of severe rectal pain, especially with bowel movements, described as intense

and sharp and “like passing shards of glass or razor blades.” The pain eases until the next bowel movement. The severity of the pain can be likened to that of urolithiasis or childbirth for some, while for others the symptoms are mild and patients need reassurance only. Patients with a chronic anal fissure complain of constant pain because of sphincter hypertrophy and spasm, with exacerbation of the pain during defecation. Passage of fresh bright red blood is less common as the initial presenting symptom. Patients are usually constipated and have a straining pattern of defecation. Painful defecation leads to avoidance of defecation and results in a vicious, self-perpetuating cycle. They tend to eat less to avoid the need for passing stool. Some patients report episodes of diarrhoea prior to the commencement of symptoms. Other patients complain of pruritus and also, albeit this is not a common presenting symptom for a fissure. On history taking, the patient may point towards the passing of a large or hard stool as the initiating event. Anal intercourse and penetration with foreign bodies must also be enquired about, as should a personal or family history of inflammatory bowel disease.

5. Investigations

Physical examination in the left lateral position by gently separating the buttocks, and evert-ing the anal verge usually exposes linear separation of the anoderm at the lower half of the anal canal. Severe pain can be induced with digital rectal or proctoscopic examination, so should not be attempted if a fissure is expected or demonstrable in the awake setting. If sus-pecting a secondary pathology and proctoscopy and digital examination are necessary, this should be done under local, regional or general anaesthesia.

If the diagnosis is unclear and the clinician is unable to see the fissure at the bedside, or a patient who is high risk for colorectal cancer and presents with significant fresh bleeding per rectum, examination under anaesthesia (EUA) with anoscopy, colonoscopy and tissue sampling may be warranted. Similarly, dependent on findings at EUA, further investigation with endoanal ultrasound, CT and MRI scanning may be required.

6. Differential diagnosis

Other conditions that can present with perianal pain and bleeding PR include thrombosed haemorrhoid, anal fistula, solitary rectal ulcer, Crohn’s disease, malignancy or tuberculosis. These can be excluded by history and careful clinical assessment.

7. Classification

Anal fissures are classified on the basis of chronicity and morphological appearance. Acute fis-sures are defined as those with duration of symptoms of 6 weeks or less. They usually involve only the superficial mucosal layer and the base of the fissure does not have visible IAS fibres. They tend to have sharply demarcated, fresh mucosal edges, often with granulation tissue at

the base [12] and often they will heal spontaneously. Lindsey et al. proposed a definition for chronic anal fissure as 'the presence of visible transverse IAS fibres at the base of an anal fissure of duration not less than 6 weeks' [13]. Over time, the IAS hypertrophies and becomes more effective in keeping the wound open and thus, prevents spontaneous wound healing. Chronic anal fissures have distinct anatomical features, such as the aforementioned visible sphincter fibres at the fissure base along with an anal papilla, sentinel pile and indurated margins.

8. Treatment options

Any treatment plan needs to address the following issues: (1) supportive measures, (2) atraumatic passage of stool, (3) pain management, (4) abnormal pattern of defecation, e.g. excessive straining, and (5) decreasing anal sphincter tone and local ischemia in patients with a hypertonic sphincter.

8.1. Supportive measures

The American Society of Colorectal Surgeons (ASCRS) recommends non-operative management as the initial treatment. ASCRS suggests that nearly 50% patients can achieve symptom resolution with the use of supportive measures such as sitz baths, bulking agents and topical anaesthetics and steroids [14–19]. A sitz bath comprises immersing the anus in lukewarm water for 10–15 min, two to three times a day. The treatment supplemented with a sitz bath regimen is associated with improved pain relief [15]. Maintenance therapy with fibre is associated with lower rates of fissure recurrence compared with placebo [18].

8.2. Atraumatic passage of stool

Constipation leads to straining and in turn usually worsening of the fissure symptoms. Laxatives, stool softeners and appropriate intake of dietary fibre are advised by ASCRS. The treatment of acute anal fissure with fibre supplementation has been associated with increased healing rates, improvement of symptoms, and prevention of recurrence [15, 18]. Fibre works by absorbing water, forming a viscous and bulky stool that promotes peristalsis and renders the stool easier to evacuate and in turn reduces the need for straining during defaecation. Stool softeners work by increasing the water content of stool and thus avoiding trauma to the anal canal lining during defecation. Mineral oil also aids to facilitate passage of stool without much stretching or abrasion of the anal mucosa, but it is not recommended for indefinite use.

8.3. Pain management

Topical anaesthetics in combination with sitz baths and the other above mentioned supporting strategies provide good pain control. Analgesics are often required for patient comfort. Non-steroidal anti-inflammatory drugs, paracetamol, and on occasion opioid analgesics are required, the latter requiring concurrent laxative use to avoid further constipation.

8.4. Abnormal pattern of defecation

Assessment of dyssynergic defaecation and anorectal feedback may be required in patients with excessive straining at defecation. A manual perineum support has been shown to help in patients with defecatory issues [20]. A novel posterior perineal device incorporated in the toilet seat has also shown improvement in pain, constipation and bleeding symptoms [21].

8.5. Decreasing sphincter tone and local ischaemia

Pharmacological and surgical options are available to manage increased IAS tone with associated local ischaemia. For chronic fissures, studies have suggested lateral internal sphincterotomy (LIS) has better results as compared to pharmacological agents [22]. ASCRS recommends LIS as the first line of treatment in the selected group of patients with no underlying faecal incontinence of any degree. The available options are discussed below.

8.5.1. Pharmacological management

Calcium channel blockers and nitrates are the most commonly used pharmacological agents. Both topical and oral forms are in use. Patients with an acute fissure can be treated with supportive measures only, but the NICE (National Institute for Health and Care Excellence) guidelines recommend using nitrates as an adjunct for 6–8 weeks followed by a re-evaluation and prescribing another course of medication if required. While for Diltiazem, NICE recommends usage only on specialist advised for those who cannot use GTN, as it's an unlicensed product. If symptoms persist then EUA and further investigation is needed.

Medical management has a much-reduced incidence of the dreaded complication of faecal incontinence but has a higher recurrence rate (around 50% for medical management as compared to 3–6% for LIS) [23–25]. This recurrence rate is similar for both calcium channel blockers and nitrates. However, patients who are already on these drugs for hypertension and ischemic heart disease may not be suitable candidates as the systemic therapy did not prevent the development of the fissure and thus may not aid in its healing.

Medical management does not provide a solution for skin tags, sentinel piles and fibrous polyps. These persist even after symptoms have resolved and can themselves cause bleeding or pain with trauma or can be a cause of faecal soilage.

8.5.1.1. Calcium channel blockers

Calcium channel blockers reduce anal tone and spontaneous activity of the sphincter by decreasing the intracellular availability of calcium. This is done by blocking the L-type calcium channels involved in the maintenance of IAS tone [26–28]. ASCRS recommends using calcium channel blockers as opposed to topical nitrates because of the superior side effect profile while having similar efficacy. In a recent systematic review and meta-analysis, topical calcium channel blockers were found to have better healing rates (21.3 vs. 38.4% unhealed fissures) as compared to oral, with fewer side effects [29].

8.5.1.1.1. *Nifedipine*

Studies have shown that nifedipine has a local anti-inflammatory effect [30] and produces modulating effects on the microcirculation [31]. In a trial comparing nifedipine and nitroglycerin as the treatment option, nifedipine proved to be better in healing (89 vs. 58%) and also had fewer side effects, while recurrence was frequent with both (42% with nifedipine vs. 31% with GTN) [32]. Direct comparison of oral and topical nifedipine found similar rates of healing and pain relief [27]. Given the higher incidence of systemic effects associated with oral calcium channel blockers, topical delivery is preferred.

8.5.1.1.2. *Diltiazem*

Recurrence is a problem for this class of drug. In one of the few long-term trials [33], more than 60% of patients experienced a recurrence within 2 years after cessation of therapy. One study reported that topical diltiazem has superior healing rates to oral diltiazem (65 vs. 38%) [34]. The main side effects include migraine and pruritus ani in 10% of patients [35, 36].

8.5.1.2. *Nitrates*

Myenteric nerves innervating the internal sphincter muscle of the anus produce and release nitric oxide, the chemical messenger that mediates relaxation of this muscle. Nitroglycerin, which is locally metabolised to nitric oxide, lowers the mean resting pressure of the anal sphincter when applied topically to the anus.

8.5.1.2.1. *Nitroglycerin*

Nitroglycerin promotes healing by decreasing pressure in the anal sphincter and concurrently increasing blood flow. For an acute fissure, NICE guidelines recommend 0.4% GTN as a second line treatment option if only supportive measures are not effective after 1 week of treatment, as a proportion of acute anal fissures heal spontaneously within 2 weeks. For chronic fissures, intra-anal application of GTN (also called glyceryl trinitrate, GTN) ointment directly to the IAS helps in fissure healing in approximately 50% [37]. Commonly used preparations come in either 0.2 or 0.4% strengths. Different doses ranging from 0.05 to 0.4% have been studied and the dose has not been shown to effect healing in three studies which compared different doses [38–40].

Headache is the main side effect occurring in at least 30% of treated patients [37]. Typically, these headaches last for no more than 30 min and occur 10–15 min after application. Hypotension is another side effect, brought about by vasodilation. It causes dizziness and thus, susceptible patients should lie down after application of the ointment to avoid dizziness. Topical GTN should be avoided within 24 h of taking erectile dysfunction medications such as Sildenafil.

A large Cochrane review compared the efficacy of 17 different therapies and concluded that topical GTN is better than placebo for anal fissures and is equivalent to botulinum toxin (BTA) injection and topical calcium channel blockers. GTN tends to cause more side effects, specifically headache [23].

8.5.1.3. Other medications and treatment options

Parasympathomimetic medications such as Bethanechol and Indoramin (alpha blocker), beta agonists like Salbutamol, natural products like Myoxinol ointment [41], egg yolks [42], and injection of sclerosing agents [43] have been tried with varying results.

Use of percutaneous posterior tibial nerve stimulation has also been suggested as a safe and effective alternative [44–46]. Studies have shown it to be some ways superior to GTN ointment for the treatment of chronic anal fissure. In a prospective randomised study of 40 patients who had persistent anal fissures despite 6 weeks of supportive measures, patients were randomised to either perianal application of GTN ointment (twice daily for 8 weeks) or percutaneous posterior tibial nerve stimulation (30-min session 2 days per week for 8 weeks). After 8 weeks of treatment, the healing rate in the percutaneous posterior tibial nerve stimulation group was 87.5 vs. 65.0% in the GTN ointment group. There were no side effects or treatment withdrawal in the nerve stimulation group as compared to 15% withdrawal in the GTN group due to headache [44].

8.5.1.4. Botulinum toxin A

The British Medical Journal (BMJ) best practice recommends using botulinum toxin (BTA) if topical agents are unsuccessful. BTA is used for performing a chemical sphincterotomy. The major effect of BTA on the IAS is blockade of sympathetic (noradrenaline mediated) neural output. This is probably a postganglionic action, involving a reduction in noradrenaline release at the neuromuscular junction causing short-term paralysis of the IAS, resulting in a reduction in anal tone [47, 48]. It can be used to treat acute and chronic anal fissures. The site of injection is still not clear and different sites have been tried (directly under the fissure or in both sides of the fissure or circumferential injections). There is no dosage or injection site with evidence of superiority. A meta-analysis shows there is no dose-dependent efficiency. The postoperative incontinence rate is not related to the dosage regardless of the type of formulation of BTA used. Also, there is no difference in healing rates with regard to the site and number of injections per session [49]. BTA has been shown to give comparable results with internal vs. external anal sphincter injection. One explanation of this is possible diffusion of the toxin from EAS to IAS [50, 51]. A second injection for an unsatisfactory response to the initial injection has shown good results where healing rates are around 60–95% after the second session of injections, with recurrence rates of 12.5% at 6 months and with no reports of anaphylaxis [23, 52, 53]. The effect is thought to last about 3 months until nerve endings regenerate allowing acute fissures (and sometimes chronic fissures) to heal and symptoms to resolve [54]. The incidence of postoperative incontinence (5–10%) [23, 49] (both faecal and flatal) needs to be considered and patients counselled regarding same.

In an updated systematic review and meta-analysis of randomised controlled trials, BTA was associated with fewer side effects than GTN but there was no difference in fissure healing or recurrence, although there was an increased incidence of transient anal incontinence [55]. Haematomas and subcutaneous infections are other commonly reported but infrequent side effects. A double-blind randomised controlled trial that compared topical diltiazem with BTA demonstrated that BTA has better healing rates in the short term but after 3 months diltiazem and BTA resulted in similar healing rates. Also, no significant difference in pain reduction was observed between the treatments [54]. ASCRS reports that BTA has similar results compared

with topical therapies as first-line therapy for chronic anal fissures, and modest improvement in healing rates as second-line therapy following treatment [56].

8.5.1.5. Summation of pharmacological management

The Association of Coloproctology of Great Britain and Ireland (ACPGBI) recommends supportive treatment for both acute and chronic anal fissures, in combination with a calcium channel blocker for 6–8 weeks. If resistant to treatment, they recommend the injection of 20–25 units of BTA [57]. ASCRS recommends non-operative treatment of acute anal fissures e.g., sitz baths, psyllium fibre and bulking agents as the first step in therapy. Almost half of all patients who have an acute anal fissure will experience symptom resolution with non-operative measures [14, 15]. If symptoms persist, then pharmacological and/or surgical options should be considered.

8.5.2. Surgical options

As per a recent systematic review and meta-analysis of 148 trials, surgical intervention is significantly more effective for chronic anal fissure than medical management [24] but carries the additional potential risk of incontinence. The main contraindication to surgery for an anal fissure is impaired faecal continence, a condition that might worsen with surgery. This contraindication mostly applies to patients with minor incontinence, or who are at risk of incontinence due to a weakened sphincter complex, e.g., multiparous women and older patients. Surgery is offered to patients in whom an acute fissure is not responding to medical treatment and to those patients with chronic fissures [58–61]. No specific preoperative preparation is needed, intravenous antibiotics are not recommended [62] and preoperative enemas can be very painful for the patient and thus should be avoided.

The following are the most commonly performed operations for anal fissures.

8.5.2.1. Sphincterotomy procedures

The aim of a sphincterotomy is to release tension in the IAS by dividing it and thus allowing healing [63]. In broad terms, there are two categorised subtypes: the posterior and lateral approaches. Posterior sphincterotomy is no longer recommended as it potentially leaves a keyhole defect [64]. Lateral internal sphincterotomy (LIS) is the gold standard surgical procedure [65]. LIS can be performed by either the open or closed technique with similar outcomes [66] and healing rates of approximately 95%. The open technique involves making an incision at the anoderm to expose the IAS and then a division of the IAS under direct vision. For the closed technique, a scalpel blade is inserted directly under the anoderm or into the intersphincteric groove and the sphincter is divided without widely incising the anal mucosa.

Common complications include recurrence in up to 6% and incontinence of flatus or stool (usually transient) in 3.4–4.4% of patients [24]. This procedure commonly involves division of the IAS from its distal end to the level of dentate line or just proximal to it. LIS has been shown to result in better quality of life than that following medical therapy. Importantly, LIS also negates any patient compliance issues associated with medical therapy. Due to

this, LIS can be offered as 1st line treatment for patients with chronic anal fissures and no underlying symptoms of or predisposition to incontinence.

A modified form called a tailored sphincterotomy or fissure apex sphincterotomy involves division of the IAS up to the level of the apex of the fissure and thus it preserves more sphincteric muscle fibres. Two randomised controlled trials have reported a clinically significant reduction in incontinence with fissure apex sphincterotomy as compared the aforementioned traditional LIS [67, 68]. Another described technique is that of the calibrated sphincterotomy. A predetermined anal canal diameter (3 cm) is achieved by transecting the sphincter muscles. Results from a randomised controlled trial show equivalent healing in calibrated LIS and fissure apex LIS, but the incidence of faecal incontinence was higher in the fissure apex LIS group [69].

A recent review using three-dimensional anal ultrasonography to determine the extent of IAS division during LIS in women reported that the safest method is to divide less than 25% of the sphincter, which in women corresponds to less than 1 cm. No incontinence was observed in these patients [70]. It is important to ensure the sphincter is actually divided during LIS. A study by Farouk et al. evaluated patients with persistent fissures post-sphincterotomy with ultrasound. Almost 70% had no demonstrable division of the IAS on imaging [71]. If LIS fails, endoanal ultrasound should be performed to assess the sphincter (**Figure 4**).

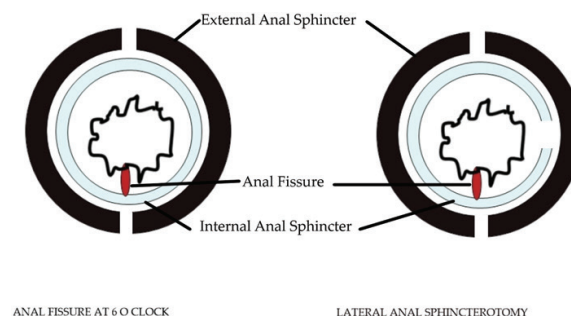


Figure 4. Diagrammatic presentation of Lateral internal shincterotomy.

8.5.2.2. Anal advancement flap

This is a sphincter-saving procedure that has a very low reported incidence of postoperative minor faecal incontinence (0–6%). An anocutaneous (dermal V-Y or house) flap can be used for chronic non-healing fissures in patients with an increased risk of developing faecal incontinence (e.g. older adults, multiparous women, patients with recurrent fissures). This procedure has been shown to have good healing rates (81–100%) [53, 72]. Anal advancement flaps have been utilised as a subsequent therapy to LIS or BTA injection resulting in less postoperative pain and improved healing [73, 74].

8.5.2.3. Anal dilatation

The concept of sphincter stretching was first described by Recamier in 1838 for the treatment of proctalgia fugax and anal fissure. In 1968, Lord introduced a technique involving

the insertion of four fingers of each hand into the anal canal and stretching over the course of 3–4 min. Nelson suggested abandoning the dilatation procedures by manual stretching [66]. This procedure is associated with higher rates of recurrence and incontinence [57].

A Cochrane review was performed of seven randomised controlled trials comparing anal stretch with internal sphincterotomy. The results significantly favoured sphincterotomy over anal stretch for efficacy (OR = 3.35; 95% CI = 1.55–7.26; here, OR: odds ratio, CI: confidence interval) and incontinence to flatus or faeces (OR = 4.03; 95% CI = 2.04–7.46) [23]. With the advent of endoanal ultrasound, sphincter defects after anal dilation are now readily detectable [75, 76]. In one study, IAS defects were visualised in 65% with 12.5% reporting incontinence. EAS defects were also found in 11/18 patients with incontinence [75].

Pneumatic balloon dilation (PBD) seems to be an effective, safe, easy procedure that decreases anal resting pressure without endosonographically detectable significant sphincter damage. A randomised controlled trial reported on PBD compared to LIS for the treatment of chronic anal fissure. Pneumatic dilation was performed with a 40 mm diameter, 60 mm in length anal balloon (Microvasive, Genova, Italy) with the balloon inflated to 20 psi for 6 min. Overall healing rates at 6 weeks were 83 and 92% for PBD and LIS, respectively. Based on preoperative and postoperative manometry, both techniques reduced anal pressures by ~30%. The PBD group did demonstrate mild transient faecal incontinence; however, at 24-month follow-up, the incidence of incontinence in the PBD group was 0%, but 16% in the LIS group ($p < 0.0001$) [77].

8.5.2.4. Fissurectomy

Fissurectomy entails excision of the scarred superficial skin around the anal fissure, chronic granulation tissue, hypertrophied papilla and the skin tag or sentinel pile. This then leaves a base of healthy tissue that will hopefully heal. The wound is either left open or closed primarily. In one clinical trial by Mousavi et al., fissurectomy was considered inferior to LIS. Another study by Barnes et al. reported on a combined modality of fissurectomy with BTA injection and had a 93% healing rate with only transient incontinence to flatus in 7% [78]. Fissurectomy has also been performed in conjunction with GTN or BTA injection to treat anal fissures with no recurrence and no sphincter damage on post operative endosonography [79, 80].

8.5.2.5. Surgical adjuncts

Persistence of hypertrophied papillae, skin tags and polyps often leads to patient dissatisfaction. Removal of hypertrophied anal papillae and fibrous anal polyps should be considered as a part of the surgical procedure. A randomised controlled trial found 84% of patients who had removal of the polyp, papilla or skin tag were satisfied at 2 years postoperatively as compared to only 58% of the control group [81]. A radiofrequency procedure can also be useful in the eradication of these concomitant pathologies [82].

8.5.2.6. Summation of surgical management

American and British surgical societies recommend against uncontrolled manual dilatation. ASCRS recommend that LIS may be offered as first-line therapy without prior medical

treatment to decrease IAS tone in a selected group of patients. The ACPGBI recommends LIS in cases of failed medical treatment, or of chronic anal fissures in association with a hypertonic anal sphincter. Modifications of the traditional sphincterotomy procedure have shown promising results. Anal advancement flaps can be an option for high-risk patients with IAS hypotonia.

8.5.3. Combination procedures

Primary wound healing can be achieved by combining anal advancement flap with LIS or BTA injection providing faster pain relief and potentially providing better functional results [83]. Theodoropoulos et al. found significantly less postoperative pain, faster healing, and fewer incontinence episodes in the tailored LIS plus flap group in comparison to the conventional LIS alone group [74]. Magdy et al. found tailored LIS with V-Y flap produced a superior healing rate, with relatively lesser complications and less rate of recurrence as compared to LIS or anal advancement flap alone [84]. In a randomised controlled trial of 99 patients, the combination of diltiazem and BTA injection was found to be as effective as LIS in patients with chronic anal fissure of the duration of 1 year or less [85].

9. Overview and comparison of side effects

Different side effects are associated with different therapies. The outcomes and side effects of the treatments for anal fissures reported in the literature are inconsistent. The recent systematic review and meta-analysis of 148 trials reported that nitrates are associated with headache in 20–30% of cases or even higher [24, 38, 86]. Higher doses do not seem to influence efficacy but do increase the side effect profile, especially headaches. Oral calcium channel blockers also have a reasonably high incidence of associated headache, but in their topical form, this is reduced to only 16%.

Variable incontinence rates have been described. LIS has been shown to have an incontinence incidence rate of 3.4–4.4%. BTA injection has a reported incontinence rate of 2.3%, GTN 1.1% and topical calcium channel blockers 1.4%. Other side effects include perianal itching and dermatitis [24]. Medical therapies have been shown to have recurrence rates as high as 50% [25].

Following chart compares different aspects of different treatment options (**Figure 5**).

	GTN	CCBs	BTA	LIS
HEALING	58% ⁽³⁷⁾	79% ⁽²⁹⁾	67.5%(1st injection) ⁽⁵⁵⁾	68-100% ^(24,25)
RECURRENCE	≈50% ⁽²⁴⁾	≈50% ⁽²⁴⁾	18.1 ⁽⁵⁵⁾	≈6%
INCONTINENCE	1.1% ⁽²⁴⁾	1.4% ⁽²⁴⁾	2-10% ^(24,55)	3.4-4.4%
HEAD ACHE	20-30%	16% for topical forms	4.8% ⁽⁵⁵⁾	-

Figure 5. Chart comparing different aspects of different treatment options.

10. Fissures with low anal pressures

The management of anal fissure is mainly based on relieving anal hypertonicity. Patients with anterior anal fissures have been shown to have significantly lower anal pressures, suggesting a different pathophysiology in the development of these fissures [87, 88]. Low-pressure anal fissures are most commonly seen in postpartum patients. These patients are at particularly high risk for incontinence with measures directed at reducing anal hypertonia. Thus, it is especially important to approach anterior and low-pressure fissures more cautiously. It may be beneficial to perform anorectal manometry before proceeding with a treatment algorithm.

Various small studies have shown success with advancement anoplasty, or fissurectomy with advancement anoplasty, in patients with low-pressure anal fissures with reported healing rates ranging from 87 to 100% [89–91]. Advancement flap surgery may be an acceptable first approach to low-pressure fissures.

11. Novel therapies

Autologous adipose tissue injection has been shown to result in healing in 75% of treated anal fissures and 80% resolution of anal stenosis in patients with chronic anal fissure who failed previous medical and surgical therapy. Surgical treatment consisted of transplant of purified autologous fat retrieved from the hypogastrium [92]. Another reported technique is laser electrocoagulation of the fissure and its margins, leaving the IAS virtually intact. This destroys the scarred tissue and gives the tissue a chance to heal gradually from the bottom to the top of the anal ulcer of the fissure. A study reporting on 200 patients found no recurrence and no complications on follow-up [93].

A randomised prospective study compared anal self-massage with manual anal dilators and found a better resolution of an acute anal fissure in a shorter time. The anal self-massage consisted of the introduction of the patients' own index finger into the anal canal (with lubricant cream) for 10 min twice a day for the first 2 days of treatment. Following this initial 2-day strategy, patients were then instructed to perform a circular motion with the finger for 10 min twice a day for a further 5 days [94].

12. Treatment algorithm

Comparing the potential risks and benefits of different medical and surgical options as per evidence based medicine, the following treatment algorithm is proposed (**Figure 6**).

The authors favour the above algorithm, as many patients will decline the definitive treatment of surgical sphincterotomy when they are made aware of the small, but potential, complication of incontinence. Thus, commencing with supportive measures is the first step and highly unlikely to cause any lasting side effects. BTA injection is not licenced for nor present

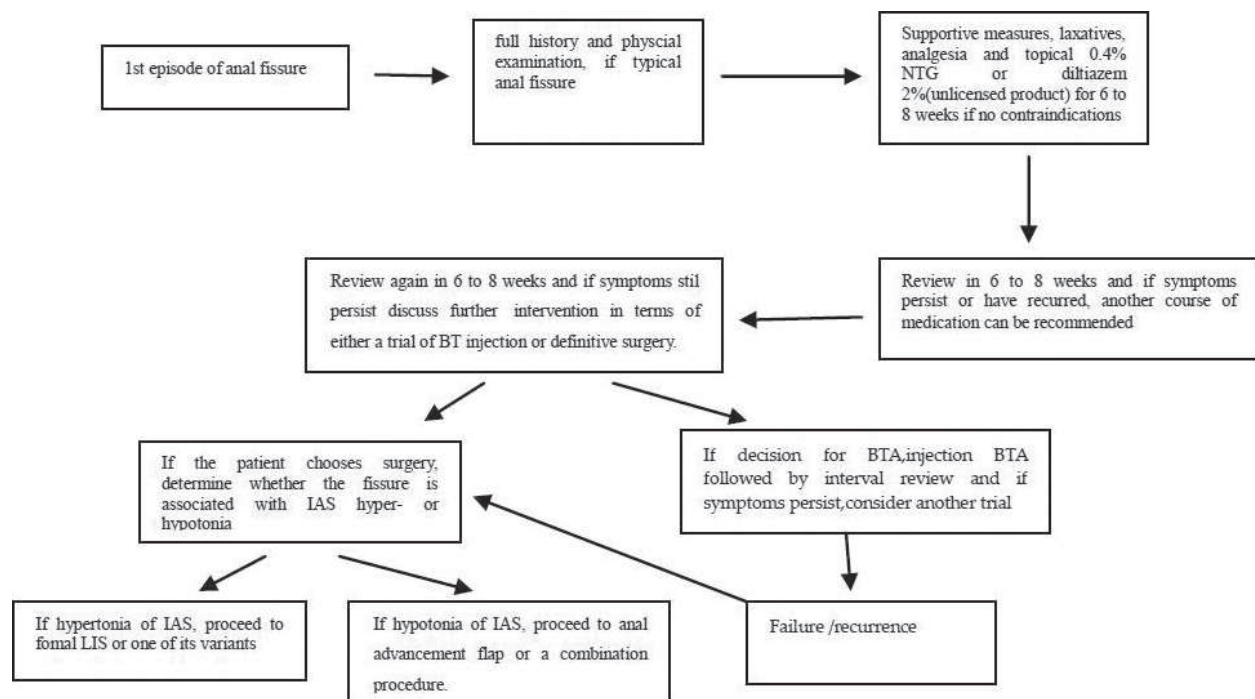


Figure 6. Algorithm for management of anal fissure.

in formal guidelines, but it is utilised by many surgeons as a bridging step between topical therapy and definitive surgery, with the added option of being able to repeat the injection if required. It often seems to be a more acceptable option to the patient also, in that it involves an injection as opposed to cutting a muscle, one sounding like a far more serious and complex operation than the other. In cases of failure of LIS, patients should be assessed with anorectal manometry and endoanal ultrasound. If the amount of sphincter divided was inadequate, repeat internal sphincterotomy can be done, or contralateral LIS can be performed [95]. Patients' wishes should be taken into consideration for further management.

13. Conclusion

An anal fissure is a painful ulceration predominantly associated with spasm of the IAS. Treatment is based on controlling pain, sphincter tone and regularisation of bowel movements. There is no consensus found among different guidelines from including Europe and America, regarding a definitive treatment algorithm with variation between health services and individual clinicians alike. While acute fissures usually heal with supportive measures and topical analgesic agents, some guidelines suggest early use of pharmacological agents even in the acute phase, while for chronic fissures medical and surgical treatments both have been recommended. Different pharmacological agents have advantages and side effects, but lateral internal sphincterotomy or its variants have been found to be best. Novel therapies have been tested but need more research. The authors like to take an aptly described 'bottom up' approach, commencing with supportive measures and topical therapies, followed by BTA

injection if the patient wishes and leaving definitive surgery in the form of a sphincterotomy or advancement flap as the final treatment option.

Nomenclature

AF	Anal fissure
ASCRS	American Society of Colorectal Surgeons
LIS	Lateral internal sphincterotomy
IAS	Internal anal sphincter
ACPGBI	Association of Coloproctology of Great Britain and Ireland
BTA	Botulin toxin A
GTN	Glyceryl trinitrate
CCBs	Calcium channel blockers
PR	Per rectal
NICE	National Institute for Health and Care Excellence
RCT	Randomised control trial
PBD	Pneumatic balloon dilatation
BMJ	British Medical Journal

Author details

Muhammad Fahadullah and Colin Peirce*

*Address all correspondence to: colinpeirce@rcsi.ie

Department of Colorectal Surgery, University Hospital Limerick, Limerick, Ireland

References

- [1] Goligher JC, Nixon HH, Duthie HL. Surgery of the Anus, Rectum and Colon. London: Baillière Tindall; 1980
- [2] Mapel DW, Schum M, Von Worley A. The epidemiology and treatment of anal fissures in a population-based cohort. BMC Gastroenterology. 2014;**14**(1):129

- [3] Madalinski MH. Identifying the best therapy for chronic anal fissure. *World Journal of Gastrointestinal Pharmacology and Therapeutics*. 2011;**2**(2):9-16
- [4] Poh A, Tan KY, Seow-Choen F. Innovations in chronic anal fissure treatment: A systematic review. *World Journal of Gastrointestinal Surgery*. 2010;**2**(7):231-241
- [5] Zaghiyan KN, Fleshner P. Anal fissure. *Clinics in Colon and Rectal Surgery*. 2011;**24**(1):22
- [6] Farid M, El Nakeeb A, Youssef M, Omar W, Fouda E, Youssef T, et al. Idiopathic hypertensive anal canal: A place of internal sphincterotomy. *Journal of Gastrointestinal Surgery*. 2009;**13**(9):1607-1613
- [7] Wray D, Ijaz S, Lidder S. Anal fissure: A review. *British Journal of Hospital Medicine (London, England)*. 2008;**69**(8):455-458
- [8] Schouten WR, Briel JW, Auwerda JJ. Relationship between anal pressure and anodermal blood flow. *Diseases of the Colon and Rectum*. 1994;**37**(7):664-669
- [9] Klosterhalfen B, Vogel P, Rixen H, Mittermayer C. Topography of the inferior rectal artery: A possible cause of chronic, primary anal fissure. *Diseases of the Colon and Rectum*. 1989;**32**(1):43-52
- [10] Schouten W, Briel J, Auwerda J, De Graaf E. Ischaemic nature of anal fissure. *The British Journal of Surgery*. 1996;**83**(1):63-65
- [11] Lund JN. Nitric oxide deficiency in the internal anal sphincter of patients with chronic anal fissure. *International Journal of Colorectal Disease*. 2006;**21**(7):673-675
- [12] Nelson RL. Anal fissure (chronic). *BMJ Clin Evid* 2014; 2014: 0407
- [13] Lindsey I, Jones OM, Cunningham C, Mortensen NJ. Chronic anal fissure. *The British Journal of Surgery*. 2004;**91**(3):270-279
- [14] Gough M, Lewis A. The conservative treatment of fissure-in-ano. *The British Journal of Surgery*. 1983;**70**(3):175-176
- [15] Jensen SL. Treatment of first episodes of acute anal fissure: Prospective randomised study of lignocaine ointment versus hydrocortisone ointment or warm sitz baths plus bran. *British Medical Journal (Clinical Research Ed.)*. 1986;**292**(6529):1167-1169
- [16] Shub HA, Salvati EP, Rubin RJ. Conservative treatment of anal fissure: An unselected, retrospective and continuous study. *Diseases of the Colon and Rectum*. 1978;**21**(8):582-583
- [17] Hananel N, Gordon PH. Re-examination of clinical manifestations and response to therapy of fissure-in-ano. *Diseases of the Colon and Rectum*. 1997;**40**(2):229-233
- [18] Jensen S. Maintenance therapy with unprocessed bran in the prevention of acute anal fissure recurrence. *Journal of the Royal Society of Medicine*. 1987;**80**(5):296
- [19] Gupta PJ. Randomized, controlled study comparing SITZ-bath and no-SITZ-bath treatments in patients with acute anal fissures. *ANZ Journal of Surgery*. 2006;**76**(8):718-721

- [20] D'Hoore A, Penninckx F. Obstructed defecation. *Colorectal Disease*. 2003;**5**(4):280-287
- [21] Tan K-Y, Seow-Choen F, Hai CH, Thye GK. Posterior perineal support as treatment for anal fissures—Preliminary results with a new toilet seat device. *Techniques in Coloproctology*. 2009;**13**(1):11-15
- [22] Brown CJ, Dubreuil D, Santoro L, Liu M, O'Connor BI, McLeod RS. Lateral internal sphincterotomy is superior to topical nitroglycerin for healing chronic anal fissure and does not compromise long-term fecal continence: Six-year follow-up of a multicenter, randomized, controlled trial. *Diseases of the Colon and Rectum*. 2007;**50**(4):442-448
- [23] Nelson RL, Thomas K, Morgan J, Jones A. Non surgical therapy for anal fissure. *Cochrane Database of Systematic Reviews*. 2012;**2**:CD003431
- [24] Nelson R, Manuel D, Gumieny C, Spencer B, Patel K, Schmitt K, et al. A systematic review and meta-analysis of the treatment of anal fissure. *Techniques in Coloproctology*. 2017;**21**(8):605-625
- [25] Ebinger SM, Hardt J, Warschkow R, Schmied BM, Herold A, Post S, et al. Operative and medical treatment of chronic anal fissures—A review and network meta-analysis of randomized controlled trials. *Journal of Gastroenterology*. 2017;**52**(6):663-676
- [26] Cook T, Brading A, Mortensen N. Differences in contractile properties of anorectal smooth muscle and the effects of calcium channel blockade. *The British Journal of Surgery*. 1999;**86**(1):70-75
- [27] Cook TA, Brading AF, Mortensen NJ. Effects of nifedipine on anorectal smooth muscle in vitro. *Diseases of the Colon and Rectum*. 1999;**42**(6):782-787
- [28] Jonard P, Essamri B. Diltiazem and internal anal sphincter. *The Lancet*. 1987;**329**(8535):754
- [29] Sahebally SM, Ahmed K, Cerneveciute R, Iqbal A, Walsh SR, Joyce MR. Oral versus topical calcium channel blockers for chronic anal fissure—A systematic review and meta-analysis of randomized controlled trials. *International Journal of Surgery*. 2017;**44**:87-93
- [30] Fleischmann JD, Huntley HN, Shingleton WB, Wentworth DB. Clinical and immunological response to nifedipine for the treatment of interstitial cystitis. *The Journal of Urology*. 1991;**146**(5):1235-1239
- [31] Oshiro H, Kobayashi I, Kim D, Takenaka H, Hobson RW, Durán WN. L-type calcium channel blockers modulate the microvascular hyperpermeability induced by platelet-activating factor in vivo. *Journal of Vascular Surgery*. 1995;**22**(6):732-741
- [32] Ezri T, Susmallian S. Topical nifedipine vs. topical glyceryl trinitrate for treatment of chronic anal fissure. *Diseases of the Colon and Rectum*. 2003;**46**(6):805-808
- [33] Nash GF, Kapoor K, Saeb-Parsy K, Kunanadam T, Dawson PM. The long-term results of diltiazem treatment for anal fissure. *International Journal of Clinical Practice*. 2006;**60**(11):1411-1413
- [34] Jonas M, Neal KR, Abercrombie JF, Scholefield JH. A randomized trial of oral vs. topical diltiazem for chronic anal fissures. *Diseases of the Colon and Rectum*. 2001;**44**(8):1074-1078

- [35] Bielecki K, Kolodziejczak M. A prospective randomized trial of diltiazem and glyceryltrinitrate ointment in the treatment of chronic anal fissure. *Colorectal Disease*. 2003;**5**(3):256-257
- [36] Jonas M, Speake W, Scholefield JH. Diltiazem heals glyceryl trinitrate-resistant chronic anal fissures: A prospective study. *Diseases of the Colon and Rectum*. 2002;**45**(8):1091-1095
- [37] Berry SM, Barish CF, Bhandari R, Clark G, Collins GV, Howell J, et al. Nitroglycerin 0.4% ointment vs placebo in the treatment of pain resulting from chronic anal fissure: A randomized, double-blind, placebo-controlled study. *BMC Gastroenterology*. 2013;**13**:106
- [38] Carapeti E, Kamm M, McDonald P, Chadwick S, Melville D, Phillips R. Randomised controlled trial shows that glyceryl trinitrate heals anal fissures, higher doses are not more effective, and there is a high recurrence rate. *Gut*. 1999;**44**(5):727-730
- [39] Bailey HR, Beck DE, Billingham RP, Binderow SR, Gottesman L, Hull TL, et al. A study to determine the nitroglycerin ointment dose and dosing interval that best promote the healing of chronic anal fissures. *Diseases of the Colon and Rectum*. 2002;**45**(9):1192-1199
- [40] Scholefield J, Bock J, Marla B, Richter H, Athanasiadis S, Pröls M, et al. A dose finding study with 0.1%, 0.2%, and 0.4% glyceryl trinitrate ointment in patients with chronic anal fissures. *Gut*. 2003;**52**(2):264-269
- [41] Martellucci J, Rossi G, Corsale I, Carrieri P, D'Elia M, Giani I. Myoxinol ointment for the treatment of acute fissure. *Updates in Surgery*. 2017;**69**(4):499-503
- [42] Salari M, Salari R, Dadgarmoghadam M, Khadem-Rezaian M, Hosseini M. Efficacy of egg yolk and nitroglycerin ointment as treatments for acute anal fissures: A randomized clinical trial study. *Electronic Physician*. 2016;**8**(10):3035
- [43] Dessily M, Charara F, Chelala E, Donfut AL, Alle JL. Injection of a sclerosing agent as first line treatment in anal fissure. *Acta Chirurgica Belgica*. 2014;**114**(4):261-265
- [44] Ruiz-Tovar J, Llaverro C. Percutaneous posterior tibial nerve stimulation vs perianal application of glyceryl trinitrate ointment in the treatment of chronic anal fissure: A randomized clinical trial. *Diseases of the Colon and Rectum*. 2017;**60**(1):81-86
- [45] Moya P, Arroyo A, Del Mar Aguilar M, Galindo I, Giner L, Bellon M, et al. Percutaneous posterior tibial nerve stimulation in the treatment of refractory anal fissure. *Techniques in Coloproctology*. 2016;**20**(3):197-198
- [46] Youssef T, Youssef M, Thabet W, Lotfy A, Shaat R, Abd-Elrazek E, et al. Randomized clinical trial of transcutaneous electrical posterior tibial nerve stimulation versus lateral internal sphincterotomy for treatment of chronic anal fissure. *International Journal of Surgery*. 2015;**22**:143-148
- [47] Jankovic J, Brin MF. Therapeutic uses of botulinum toxin. *The New England Journal of Medicine*. 1991;**324**(17):1186-1194
- [48] Jones O, Moore J, Brading A, Mortensen NMC. Botulinum toxin injection inhibits myogenic tone and sympathetic nerve function in the porcine internal anal sphincter. *Colorectal Disease*. 2003;**5**(6):552-557

- [49] Bobkiewicz A, Francuzik W, Krokowicz L, Studniarek A, Ledwosinski W, Paszkowski J, et al. Erratum to: Botulinum toxin injection for treatment of chronic anal fissure: Is there any dose-dependent efficiency? A meta-analysis. *World Journal of Surgery*. 2016; **40**(12):3063
- [50] Jost WH. Treatment of anal fissure with botulinum toxin A. In: Frühmorgen P, Bruch H-P, editors. *Non-Neoplastic Diseases of the Anorectum: An Interdisciplinary Approach*. Kluwer Academic Publishers; 2001
- [51] Jost S. Chronic anal fissures treated with botulinum toxin injections: A dose-finding study with Dysport((R)). *Colorectal Disease*. 1999;**1**(1):26-28
- [52] Wald A, Bharucha AE, Cosman BC, Whitehead WE. ACG clinical guideline: Management of benign anorectal disorders. *The American Journal of Gastroenterology*. 2014; **109**(8):1141-1157; (Quiz) 058
- [53] Glover PH, Tang SJ, Whatley JZ, Davis ED, Jex KT, Wu R, et al. High-dose circumferential chemodenervation of the internal anal sphincter: A new treatment modality for uncomplicated chronic anal fissure: A retrospective cohort study (with video). *International Journal of Surgery*. 2015;**23**(Pt A):1-4
- [54] Samim M, Twigt B, Stoker L, Pronk A. Topical diltiazem cream versus botulinum toxin a for the treatment of chronic anal fissure: A double-blind randomized clinical trial. *Annals of Surgery*. 2012;**255**(1):18-22
- [55] Sahebally SM, Meshkat B, Walsh SR, Beddy D. Botulinum toxin injection vs topical nitrates for chronic anal fissure: An updated systematic review and meta-analysis of randomized controlled trials. *Colorectal Disease*. 2018;**20**(1):6-15
- [56] Stewart DB Sr, Gaertner W, Glasgow S, Migaly J, Feingold D, Steele SR. Clinical practice guideline for the management of anal fissures. *Diseases of the Colon and Rectum*. 2017;**60**(1):7-14
- [57] Cross KL, Massey EJ, Fowler AL, Monson JR, Acpgbi. The management of anal fissure: ACPGBI position statement. *Colorectal Disease*. 2008;**10**(Suppl 3):1, 7
- [58] Evans J, Luck A, Hewett P. Glyceryl trinitrate vs. lateral sphincterotomy for chronic anal fissure. *Diseases of the Colon and Rectum*. 2001;**44**(1):93-97
- [59] Libertiny G, Knight JS, Farouk R. Randomised trial of topical 0.2% glyceryl trinitrate and lateral internal sphincterotomy for the treatment of patients with chronic anal fissure: Long-term follow-up. *The European Journal of Surgery*. 2002;**168**(7):418-421
- [60] Oettle G. Glyceryl trinitrate vs. sphincterotomy for treatment of chronic fissure-in-ano. *Diseases of the Colon and Rectum*. 1997;**40**(11):1318-1320
- [61] Menteş BB, Irkörüçü O, Akın M, Leventoğlu S, Tatlıcioğlu E. Comparison of botulinum toxin injection and lateral internal sphincterotomy for the treatment of chronic anal fissure. *Diseases of the Colon and Rectum*. 2003;**46**(2):232-237

- [62] Shaw D, Ternent CA. Perioperative management of the ambulatory anorectal surgery patient. *Clinics in Colon and Rectal Surgery*. 2016;**29**(1):7-13
- [63] Rather SA, Dar TI, Malik AA, Rather AA, Khan A, Parray FQ, et al. Subcutaneous internal lateral sphincterotomy (SILS) versus nitroglycerine ointment in anal fissure: A prospective study. *International Journal of Surgery*. 2010;**8**(3):248-251
- [64] Notaras M. *Lateral Subcutaneous Sphincterotomy for Anal Fissure—A New Technique*. SAGE Publications; 1969
- [65] Ram E, Vishne T, Lerner I, Dreznik Z. Anal dilatation versus left lateral sphincterotomy for chronic anal fissure: A prospective randomized study. *Techniques in coloproctology*. Dec 3 2007:1-3
- [66] Nelson RL, Chattopadhyay A, Brooks W, Platt I, Paavana T, Earl S. Operative procedures for fissure in ano. *Cochrane Database of Systematic Reviews*. 2011;**11**:CD002199
- [67] Elsebae MM. A study of fecal incontinence in patients with chronic anal fissure: Prospective, randomized, controlled trial of the extent of internal anal sphincter division during lateral sphincterotomy. *World Journal of Surgery*. 2007;**31**(10):2052-2057
- [68] Menteş BB, Ege B, Leventoglu S, Oguz M, Karadag A. Extent of lateral internal sphincterotomy: Up to the dentate line or up to the fissure apex? *Diseases of the Colon and Rectum*. 2005;**48**(2):365-370
- [69] Menteş BB, Güner MK, Leventoglu S, Akyürek N. Fine-tuning of the extent of lateral internal sphincterotomy: Spasm-controlled vs. up to the fissure apex. *Diseases of the Colon and Rectum*. 2008;**51**(1):128-133
- [70] Murad-Regadas SM, Fernandes GO, Regadas FS, Rodrigues LV, Pereira Jde J, Regadas Filho FS, et al. How much of the internal sphincter may be divided during lateral sphincterotomy for chronic anal fissure in women? Morphologic and functional evaluation after sphincterotomy. *Diseases of the Colon and Rectum*. 2013;**56**(5):645-651
- [71] Farouk R, Monson JR, Duthie GS. Technical failure of lateral sphincterotomy for the treatment of chronic anal fissure: A study using endoanal ultrasonography. *The British Journal of Surgery*. 1997;**84**(1):84-85
- [72] Kennedy M, Sowter S, Nguyen H, Lubowski D. Glyceryl trinitrate ointment for the treatment of chronic anal fissure. *Diseases of the Colon and Rectum*. 1999;**42**(8):1000-1006
- [73] Patti R, Guercio G, Territo V, Aiello P, Angelo GL, Di Vita G. Advancement flap in the management of chronic anal fissure: A prospective study. *Updates in Surgery*. 2012;**64**(2):101-106
- [74] Theodoropoulos GE, Spiropoulos V, Bramis K, Plastiras A, Zografos G. Dermal flap advancement combined with conservative sphincterotomy in the treatment of chronic anal fissure. *The American Surgeon*. 2015;**81**(2):133-142

- [75] Nielsen MB, Rasmussen OØ, Pedersen JF, Christiansen J. Risk of sphincter damage and anal incontinence after anal dilatation for fissure-in-ano. *Diseases of the Colon and Rectum*. 1993;**36**(7):677-680
- [76] Burnett S, Speakman C, Kamm MA, Bartram C. Confirmation of endosonographic detection of external anal sphincter defects by simultaneous electromyographic mapping. *BJS*. 1991;**78**(4):448-450
- [77] Renzi A, Izzo D, Di Sarno G, Talento P, Torelli F, Izzo G, et al. Clinical, manometric, and ultrasonographic results of pneumatic balloon dilatation vs. lateral internal sphincterotomy for chronic anal fissure: A prospective, randomized, controlled trial. *Diseases of the Colon and Rectum*. 2008;**51**(1):121-127
- [78] Barnes TG, Zafrani Z, Abdelrazeq AS. Fissurectomy combined with high-dose botulinum toxin is a safe and effective treatment for chronic anal fissure and a promising alternative to surgical sphincterotomy. *Diseases of the Colon and Rectum*. 2015;**58**(10):967-973
- [79] Engel A, Eijsbouts Q, Balk A. Fissurectomy and isosorbide dinitrate for chronic fissure in ano not responding to conservative treatment. *The British Journal of Surgery*. 2002;**89**(1):79-83
- [80] Scholz T, Hetzer F, Dindo D, Demartines N, Clavien P, Hahnloser D. Long-term follow-up after combined fissurectomy and Botox injection for chronic anal fissures. *International Journal of Colorectal Disease*. 2007;**22**(9):1077-1081
- [81] Gupta PJ, Kalaskar S. Removal of hypertrophied anal papillae and fibrous anal polyps increases patient satisfaction after anal fissure surgery. *Techniques in Coloproctology*. 2003;**7**(3):155-158
- [82] Filingeri V, Gravante G, Cassisa D. Clinical applications of radiofrequency in proctology: A review. *European Review for Medical and Pharmacological Sciences*. 2006;**10**(2):79-85
- [83] Halahakoon VC, Pitt JP. Anal advancement flap and botulinum toxin A (BT) for chronic anal fissure (CAF). *International Journal of Colorectal Disease*. 2014;**29**(9):1175-1177
- [84] Magdy A, El Nakeeb A, Fouda el Y, Youssef M, Farid M. Comparative study of conventional lateral internal sphincterotomy, V-Y anoplasty, and tailored lateral internal sphincterotomy with V-Y anoplasty in the treatment of chronic anal fissure. *Journal of Gastrointestinal Surgery*. 2012;**16**(10):1955-1962
- [85] Gandomkar H, Zeinoddini A, Heidari R, Amoli HA. Partial lateral internal sphincterotomy versus combined botulinum toxin A injection and topical diltiazem in the treatment of chronic anal fissure: A randomized clinical trial. *Diseases of the Colon and Rectum*. 2015;**58**(2):228-234
- [86] Perry WB, Dykes SL, Buie WD, Rafferty JF. Practice parameters for the management of anal fissures (3rd revision). *Diseases of the Colon and Rectum*. 2010;**53**(8):1110-1115
- [87] Bove A, Balzano A, Perrotti P, Antropoli C, Lombardi G, Pucciani F. Different anal pressure profiles in patients with anal fissure. *Techniques in Coloproctology*. 2004;**8**(3):151-157

- [88] Jenkins J, Urie A, Molloy R. Anterior anal fissures are associated with occult sphincter injury and abnormal sphincter function. *Colorectal Disease*. 2008;**10**(3):280-285
- [89] Kenefick N, Gee A, Durdey P. Treatment of resistant anal fissure with advancement anoplasty. *Colorectal Disease*. 2002;**4**(6):463-466
- [90] Patti R, Famà F, Barrera T, Migliore G, Di Vita G. Fissurectomy and anal advancement flap for anterior chronic anal fissure without hypertonia of the internal anal sphincter in females. *Colorectal Disease*. 2010;**12**(11):1127-1130
- [91] Patti R, Famà F, Tornambè A, Restivo M, Di Vita G. Early results of fissurectomy and advancement flap for resistant chronic anal fissure without hypertonia of the internal anal sphincter. *The American Surgeon*. 2010;**76**(2):206-210
- [92] Lolli P, Malleo G, Rigotti G. Treatment of chronic anal fissures and associated stenosis by autologous adipose tissue transplant: A pilot study. *Diseases of the Colon and Rectum*. 2010;**53**(4):460-466
- [93] Pappas AF, Christodoulou DK. A novel minimally invasive treatment for anal fissure. *Annals of Gastroenterology*. 2017;**30**(5):583
- [94] Gaj F, Biviano I, Candeloro L, Andreuccetti J. Anal self-massage in the treatment of acute anal fissure: A randomized prospective study. *Annals of Gastroenterology*. 2017;**30**(4):438-441
- [95] Liang J, Church JM. Lateral internal sphincterotomy for surgically recurrent chronic anal fissure. *The American Journal of Surgery*. 2015;**210**(4):715-719

