

We are IntechOpen, the world's leading publisher of Open Access books Built by scientists, for scientists

6,900

Open access books available

185,000

International authors and editors

200M

Downloads

Our authors are among the

154

Countries delivered to

TOP 1%

most cited scientists

12.2%

Contributors from top 500 universities



WEB OF SCIENCE™

Selection of our books indexed in the Book Citation Index
in Web of Science™ Core Collection (BKCI)

Interested in publishing with us?
Contact book.department@intechopen.com

Numbers displayed above are based on latest data collected.
For more information visit www.intechopen.com



Single-Bundle Anterior Cruciate Ligament Reconstruction

Kavin Khatri, Darsh Goyal and Deepak Bansal

Additional information is available at the end of the chapter

<http://dx.doi.org/10.5772/intechopen.77338>

Abstract

Anterior cruciate ligament (ACL) reconstruction is one of the most common procedures performed in orthopedics. The research has focused extensively on surgical technique factors like tunnel position, graft choices, fixation methods, and rehabilitation protocols following surgery. The advantages and disadvantages of each graft option shall help in deciding the correct graft in an individual case. A thorough understanding of anatomy and biomechanics of normal ACL has improved the understanding of complexities of knee joint stabilization over the preceding decades. The chapter shall discuss in detail about the anatomy, biomechanics, and surgical techniques along with postoperative rehabilitation protocol in current perspective.

Keywords: anterior cruciate ligament, injury, repair, ACL rehabilitation, preoperative rehabilitation, postoperative rehabilitation

1. Introduction

Anterior cruciate ligament (ACL) is the primary stabilizer for pivotal activities of the knee. In the early nineteenth century, Hay Groves and Ivor Palmer advocated repair of ACL [1]. However, the high rate of failure after repair shifted the focus to reconstruction of ACL. Macintosh advocated extra-articular reconstruction of ACL which was subsequently replaced by intra-articular approach popularized by Erikson [2, 3]. The choice of graft also shifted from patellar tendon to semitendinosus over the years [4, 5]. There has been marked improvement in surgical procedure with change from open to arthroscopic procedure. Similarly the pain management has improved significantly since then.

2. Anatomy

The major reason for the failure of ACL reconstruction is the improper placement of tunnel either femoral or tibial. So, it is imperative to know about the natural anatomy of the ACL insertion over the tibia and femur. It is an intra-articular but extrasynovial ligament of knee providing primary constraint to the anterior translation of the tibia and secondary stabilizer to varus and valgus stress to the knee. It comprises type I collagen peptide and viscoelastic properties similar to other ligaments in the body.

It comprises two bundles, i.e., anteromedial bundle and posterolateral bundle (**Figure 1**). The anteromedial bundle is tightened in 60 or more degrees of flexion, while posterolateral bundle is tight in extension. In extension both bundles are in parallel orientation along the sagittal plane, whereas in flexion of the knee, the insertion of posterolateral bundle moves anteriorly, and they appeared crossed [7, 8].

The names of the two ACL bundles are based upon the relationship between the two at the insertion point on the tibia. Both bundles originate from the posteromedial aspect of lateral femoral condyle and insert over the tibia just anterior to the intercondylar eminence. The diameter of both bundles varies from 7 to 17 mm, while the length of anteromedial bundle is slightly longer than posterolateral bundle measuring approximately between 28 and 38 mm [9, 10]. The cross section of the ACL bundle in midsubstance cross section varies from 36 to 44 mm².

The blood supply of ACL is primarily from middle geniculate artery which is a branch of popliteal artery. Inferomedial and inferolateral genicular arteries supply the ACL through anterior fat pad. ACL receives nerve fibers for proprioception through a branch of posterior tibial nerve [11].

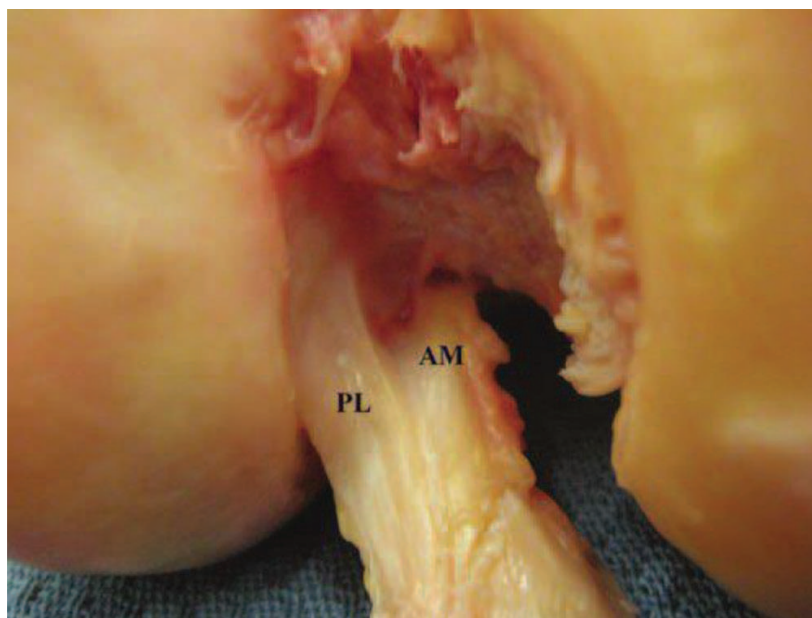


Figure 1. Distal femoral condyle showing the two bundles (anteromedial [AM] and posterolateral [PL] bundles) of the anterior cruciate ligament (reprinted with permission from Ref. [6]).

3. Biomechanics

The tensile strength of native ACL has been estimated to be within the range of 1725 ± 269 N [12]. ACL was initially thought to be subjected to isometric stresses throughout the range of motion; however, biomechanical studies demonstrated that the ACL is subjected to differential stresses in movement of the knee [13]. The anteromedial bundle experiences maximum stress in flexion, while posterolateral bundle experiences maximum stress in extension [14]. The posterolateral bundle bears the majority of the stress during knee motion. The single-bundle ACL reconstruction had stressed upon the restoration of anteromedial bundle leaving behind the posterolateral reconstruction [15]. Consequently, it was noticed that there were experiences of rotational instability and persistent pain in almost 31% cases. There has been now shift in focus from single-bundle to double-bundle ACL reconstruction improving the knee biomechanics.

4. Mechanism of injury

In majority of the cases, the flexed knee is subjected to rotational stress leading to ACL injury. The contraction of quadriceps leads to subluxation of the tibia anteriorly with failure of hamstrings to prevent the anterior subluxation.

In contact sports like football and hockey, the direct blow from the lateral aspect of the knee in a flexed and externally rotated position leads to tear in medial collateral ligament (MCL) and anterior cruciate ligament.

5. Diagnosis

5.1. History

The athlete gives a history of twisting injury to knee with popping sensation. There is associated swelling and pain. There is sensation giving away of the knee with respect to body. There are marked variations in the presenting symptoms ranging from mild pain and swelling to inability to bear weight. In the presence of associated injuries like fracture of the tibial shaft or femur, the injury to ACL is sometimes missed [16].

5.2. Physical examination

5.2.1. Swelling

There is swelling of the knee associated with the ACL injury due to hemarthrosis. The swelling might take some time before manifesting itself. The knee can be aspirated in selected cases of severe knee pain. If there are fat globules in the aspirate, then the intra-articular fracture is suspected.

5.2.2. Joint line tenderness

Both medial and lateral knee joint line should be palpated to assess the injury to medial and lateral meniscus. There is an associated meniscal injury in up to 50% of cases. The lateral meniscal tear is more common than medial meniscus tear. McMurray's test is difficult to perform in cases of acute knee injuries due to limitation in flexion.

5.2.3. Lachman test

It is the definitive test to detect the ACL injury. The knee is positioned in 20–30° of flexion. One hand is placed over the thigh to hold it firmly, and another hand is positioned such that the thumb is over the tibial tubercle and fingers across the calf region. The tibia is pulled forward with the lower hand placed over the tibia, and degree of anterior tibial translation is noted. The anterior displacement of the tibia by less than 5 mm is graded as 1+, between 5 and 10 mm as 2+, and more than 10 mm as 3+. Practically the firm end point indicates no injury, while soft end point indicates ACL injury.

5.2.4. Pivot shift test

It is a more consistent test to detect the ACL injury. The patient lies supine with legs extended. The examiner holds the heel of the involved leg and with opposite hand holding the leg just distal to the knee applies a valgus stress and an axial load while internally rotating the tibia when moving from full extension to flexion. A positive test is indicated by tibial subluxation with femoral rotation followed by reduction of the tibia at 30–40° of flexion.

5.2.5. Anterior drawer test

This test is usually carried out in chronic ACL injuries. The knee is bent at 90°, and both hands are kept over the proximal tibia giving an anteriorly directed pressure to look for anterior subluxation of the tibia. Positive test is indicated by soft end point with anterior subluxation of the tibia. Before performing the test, it is mandatory to rule out posterior cruciate ligament (PCL) injury by noting the anterior step off of the tibia with respect to femoral condyle.

5.2.6. Active quadriceps test

The anterior subluxation of the tibia on active contraction of quadriceps is indicative of ACL-deficit knee. The active quadriceps contraction is generally avoided in recently constructed ACL to prevent excessive pressure over the graft.

5.2.7. KT-1000 arthrometer

It is used to measure anterior and posterior translation of the tibia with respect to the femur. It is used to quantify the amount of anteroposterior translation of the tibia in ACL injury. The patient is placed in supine position with thighs supported with bolster keeping the knee in approximately 30° of flexion. The arthrometer has two sensing pads: one is positioned

over the patella, and the other is placed over the tibial tubercle. The arthrometer is secured to the leg with Velcro straps. The anteroposterior translation is measured by relative motion between sensory pads. When the examiner applies anterior force through handle, a tone is heard at 67, 89 and 133 N. The readings are recorded and evaluated. A side-to-side difference of less than 3 mm at 67 N and maximum force is considered normal. The side-to-side difference is more than 5 mm and is considered diagnostic of an ACL tear.

5.2.8. Range of motion

The movement of the knee is compared with the uninjured knee. The loss of extension is seen in cases with associated bucket handle tear of meniscus or torn fragments of ligament impinging anteriorly.

5.2.9. Assessment of collateral ligaments

The injured knee is given varus and valgus stress at 0 and 30° of flexion. The opening of medial or lateral joint space is graded from zero to three depending upon the amount of opening noticed on stress. Grade I injury is mild opening of less than 5 mm, grade II is opening between 5 and 10 mm, and grade III is opening of more than 15 mm.

5.2.10. Associated ligament injuries

It is important to document associated PCL and posterolateral corner injuries as the influence of the management of ACL injury.

5.2.11. Neurovascular assessment

It is imperative to document injuries to neurovascular injuries though they are rarely associated with isolated ligament injuries.

5.3. Imaging

5.3.1. Radiographs

Anteroposterior and lateral radiographs of the knee are carried out to detect the bony avulsions, osteochondral fractures, and tibial plateau fractures.

5.3.2. Computerized tomography

It is used to detect the suspected tibial plateau fracture that may be associated with ACL injury.

5.3.3. Magnetic resonance imaging

In acute setting the hemarthrosis may mask the ACL and meniscal injuries and sometimes even the minor injuries to ACL present as significant strains. It may detect the associated bone bruises and other ligament injuries. Generally the MRI examination should be delayed by

2–3 weeks for correct assessment of ACL injury. However, it is important to note that a good clinical examination is more informative and useful than an MRI to assess knee ligamentous injury (**Figure 2**).

5.3.4. Examination under anesthesia

The patient should be examined under anesthesia to reconfirm the findings of previous examinations. Sometimes due to spasm of muscles and pain, the laxity of the knee may be graded on a lower scale; hence, examination under anesthesia is important to assess the ligamentous injuries.

5.3.5. Diagnostic arthroscopy

Sometimes the findings of the MRI and clinical examination are equivocal, and diagnostic arthroscopy is carried out to look for pathology. In few cases the MRI findings may be falsely positive which can be ascertained on diagnostic arthroscopy [18].

5.4. Treatment decision

The treatment of ACL should be individualized to the patient. The two options in ACL tear are:

- a. Activity modification: the patient can opt for sports like cycling or swimming from contact sports. If there are no giving away episodes, then he can opt for conservative treatment.
- b. ACL reconstruction: in order to prevent early degenerative arthritis and return to previous activity level, the patient is advised to undergo ACL reconstruction.

Various factors should be considered before opting for operative or nonoperative treatment.

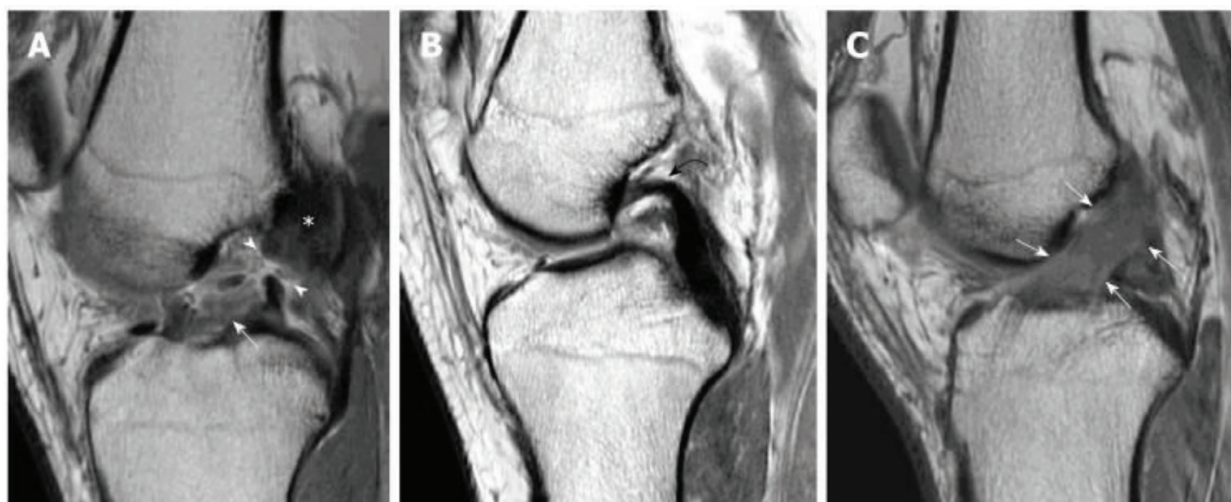


Figure 2. Signs of anterior cruciate ligament tear: (A) midsubstance discontinuity (white arrow heads), residual stump of ACL on tibial (white arrow), and femoral side (white asterisk); (B) complete resorption of ACL fibers and buckling of posterior cruciate ligament (PCL); (C) some fibers are shown in continuity (white arrows) suggestive of partial ACL tear (reprinted with permissions from Ref. [17]).

5.4.1. Age of patient

The older patients are given the option of nonoperative treatment with lifestyle modification. Young patients involved in sports activities are subjected to ACL reconstruction.

5.4.2. Activity level

The sportsperson shall require operative treatment in order to return back to sports activity of the same level.

5.4.3. Degree of instability

If side-to-side difference on KT-1000 arthrometer is more than 7 mm, then chances of successful surgical reconstruction are good.

5.5. Nonoperative management

- a. The use of extension splints and crutches for mobilization in early ACL injury as it allows the healing of associated meniscocapsulolabral tears
- b. Cryotherapy to reduce the swelling and pain
- c. Range-of-motion exercises to regain the movement of the knee
- d. Progressive strengthening exercises to regain tone of the quadriceps and hamstrings

5.6. Operative management

5.6.1. Timing of operative intervention

There is controversy over the timing of repair. Shelbourne had advised wait period of 3 weeks before reconstruction. He advocated that there are high chances of knee stiffness and loss of range of motion if operative procedure is carried out in acute phase [19]. However, Pinczewski reported good results with early reconstruction of ACL [20]. The general consensus is to wait till the swelling subsides, and good range of motion is achieved at the knee.

5.6.2. Graft selection

The various grafts available for ACL reconstruction are patellar tendon bone graft, hamstring graft, allograft, and synthetic tapes. The choice of graft depends upon the individual case, surgeon's experience, and preference.

In the 1970s, Erikson popularized the patellar tendon bone (PTB) as the graft for ACL reconstruction. It was the popular choice till the late 1990s. However, due to morbidity associated with the PTB, the focus was shifted to other grafts like hamstring graft, synthetic graft, allografts, etc. Fowler and Rosenberg popularized the use of hamstring graft. Initially there were apprehension about the strength of hamstring graft in comparison to PTB, but biomechanical testing and the use of newer fixation techniques like endobutton installed confidence

in minds of surgeons opting for it. The success of the reconstruction depends upon various factors like patient selection, surgical technique including correct tunnel placement, rehabilitation, and other associated ligamentous injuries.

5.6.2.1. Patellar tendon

It is considered as the gold strand in terms of graft for ACL reconstruction. There are advantages and disadvantages associated with this use of this graft.

5.6.2.1.1. Advantages

- a. Early bone-to-bone healing at 6 weeks
- b. Consistent size and shape of graft
- c. Ease of harvest

5.6.2.1.2. Disadvantages

- a. Harvest site morbidity: the common long-term problem is kneeling pain experienced with it. It was due to graft site morbidity that many surgeons had switched to hamstring tendons.
- b. Anterior knee pain: injury to infrapatellar branch of the saphenous nerve can produce anterior knee pain. It may also be due to patellofemoral syndrome.
- c. Late patellar tendon rupture.
- d. Loss of range of motion.
- e. Patella fracture: the cases of intraoperative patella fracture have been reported in patients when the graft was harvested with osteotome instead of saw. Sometimes the fractures are detected in late postoperative period due to overrun of saw. The stress risers that go beyond the limit of bone block should be avoided. The proximal saw cuts should preferably be boat shaped to avoid the stress riser formation.
- f. Late chondromalacia of patella.
- g. Patellar tendonitis: it leads to pain in some cases; however, it subsides by the end of the first year.
- h. Quadriceps weakness: inadequate participation in the rehabilitation program can result in quadriceps weakness.

5.6.2.1.3. Indications for the use of PTB graft for ACL reconstruction

The ideal patient for this graft is young athlete who would like to continue in contact sports for a longer time. The elder individuals can also be advised to undergo ACL reconstruction but with a caution that they had to undergo aggressive physiotherapy following reconstruction procedure.

5.6.2.1.4. Contraindications for the use of PTB graft

- a. Small patellar tendon: if the width of the patellar tendon is less than 25 mm, then harvesting the patellar tendon should be avoided, and another source is looked upon.
- b. Preexisting patellofemoral pain: it is advisable not to go for PTB if there is history of patellofemoral pain. There may be associated chondromalacia of patella which might aggravate the pain.
- c. Osgood-Schlatter disease.

5.6.2.2. Hamstring graft

5.6.2.2.1. Advantage

The principal advantage of hamstring graft is minimal donor site morbidity.

5.6.2.2.2. Disadvantages

- a. Weakness of internal rotation of the tibia is associated with hamstring retrieval; however, the weakness is to a minimal extent.
- b. Injury to the saphenous though rare but has been reported with it.
- c. Harvesting of graft can be difficult at times.
- d. Sometimes during harvesting of graft, there may occur premature amputation of the hamstrings.
- e. It takes longer to heal with hamstring graft, i.e., approximately 10–12 weeks.

5.6.2.3. Central quadriceps tendon

It can be harvested with minimal morbidity and used with interference screws.

5.6.2.4. Allograft

5.6.2.4.1. Advantages

As there is no need to harvest the graft, the surgical time is greatly reduced.

5.6.2.4.2. Disadvantages

- a. There is risk of disease transmission.
- b. It takes a much longer time than autograft to heal.
- c. The incidence of failure with allograft is higher than autograft.

5.6.2.5. *Synthetic graft*

5.6.2.5.1. *Advantages*

- a. There is no graft site morbidity.
- b. The graft is strong from the time of initial implantation itself.
- c. There is no risk of disease transmission.

5.6.2.5.2. *Disadvantages*

- a. There are high chances of failure with it.
- b. Sometimes there is synovitis seen with the use of synthetic graft.

5.6.3. *Surgical technique with harvesting of hamstring graft*

A 3-cm-long skin incision is given 1 cm medial to the tibial tubercle. Subcutaneous fat and fascia are incised along the line of skin incision. The superior border of pes anserinus is palpated, and the overlying fascia is incised. A curved artery is used to lift up the semitendinosus along with gracilis. The distal end of the tendon is stripped off from the tibia, and the free end of the tendons is held with Kocher. Each tendon is individually freed from the bands that attach it to the gastrocnemius. It is imperative to remove all the bands as passage of tendon stripper may inadvertently cut the tendon short. The length of the tendon usually obtained is approximately 28–30 cm. While harvesting tendon, it is advisable to keep the free end of the tendon in tension and move the tendon stripper with gentle push.

The harvested tendon is taken over to the back table, and graft is freed from the muscle attached. The free ends of the tendons are whipstitched with no. 2 ethibond. Both tendons, i.e., semitendinosus and gracilis, are quadrupled. The width and length of the tendons are measured. A stitch is applied at 3 cm from the free end of the graft as minimum desired length of the graft in the tunnels (femoral and tibial) is 3 cm.

The femoral notch area, tibial attachment, and femoral attachment of ACL are cleared of loose tissue with the help of shaver and cautery.

Next the focus is shifted to creation of tibial tunnel. Tibial zig is set at 55–60° and introduced from the anteromedial portal. The tip of the zig is positioned approximately 7 mm anterior to PCL insertion, in line with posterior border of lateral meniscus and 5 mm lateral to the medial tibial spine. Externally the tibial zig is positioned approximately 2 cm medial to the tibial tuberosity and 4 cm below the joint line. A guide wire is then introduced through tibial zig and passed across the proximal tibia till the tip of tibial zig. Sequential reaming is carried out for passage of graft.

The femoral tunnel placement is another important aspect of ACL reconstruction. The ACL foot print can be appreciated on the medial aspect of lateral femoral condyle. The femoral notch is assumed at 12 o'clock position; hence, the femoral tunnel approaching 10 o'clock

position in right knee (2 o'clock in left knee) mimics the anatomic center of posterolateral bundle of native ACL (**Figure 3**). The remnants of the torn ACL also help in placement of femoral tunnel. The mean distance between the centers of the two bundles was 6.2 mm. The distance from the center of the anteromedial bundle to the center of the femoral tunnel and the center of the posterolateral bundle to the center of the femoral tunnel was 4.2 and 4.1 mm, respectively. The placement of 7-mm offset reamer and creating a tunnel with the help of 10 mm reamer approximately reaches a midpoint between anteromedial bundle and anterolateral bundle.

The graft is then passed with the help of passer sutures through femoral and tibial tunnel. The various fixation methods used to fix femoral side of the graft are transfixation screws, endobutton, and tight rope. The tibial end of the graft can be fixed with the help of titanium or bioscrew or bone staples. Before fixing the graft, the knee should be flexed by approximately 20° in order to avoid fixation of a loose graft.

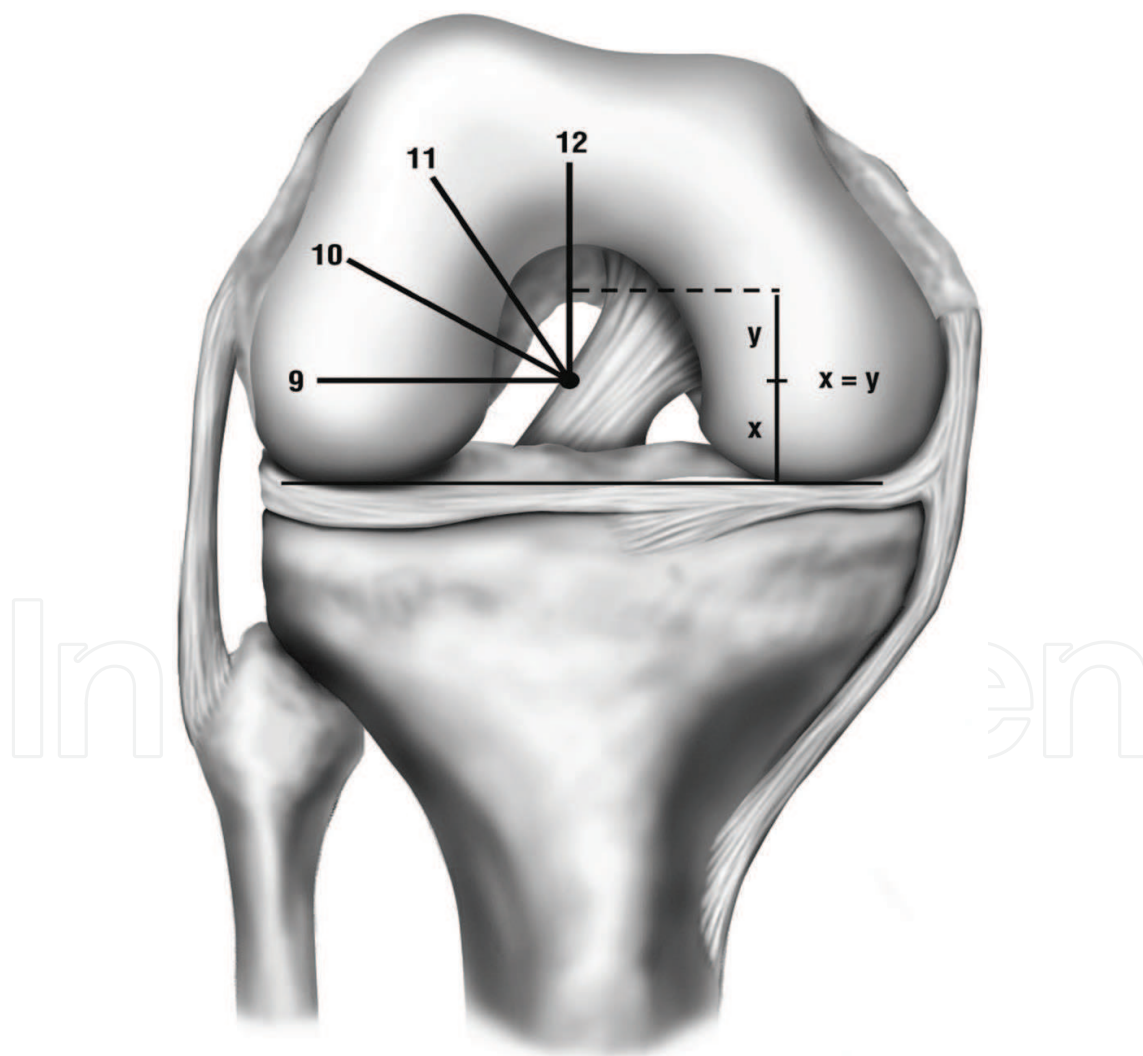


Figure 3. Diagram showing clock face superimposed on a coronal image of a right knee. It helps in coronal plane orientation in arthroscopy (reprinted with permission from Ref. [21]).

The stability of the graft should be checked with the help of probe and anterior drawer test. The wound is closed in layers, and a knee immobilizer is applied.

5.6.4. Postoperative rehabilitation protocol

The compressive stockings are applied over the limb to reduce the swelling, and cold fomentation at regular intervals is advised to the patient. Continuous passive motion (CPM) machine helps in regaining range of motion in the operated limb. The patient is allowed partial weight bearing with crutches and extension splint. The physiotherapy protocol including closed chain exercises is started immediately in the postoperative period.

The goal within 2 weeks is to achieve full extension, minimize swelling, and achieve 90° of flexion. Subsequently after 2 weeks, increase the knee flexion up to 135°, and increase the tone of the quadriceps along with hamstrings. At the end of 6 weeks, full movement of the knee is achieved along with full weight bearing with extension splint. At the end of 2 months, full weight bearing is allowed along with full functional activities like cycling, jogging, etc. At the end of 3 months, the goal is to achieve adequate hamstring and quadriceps strength along with proprioception with the help of balance board exercises. Light sports activities are allowed at the end of 4 months, and return to contact sports is permitted at the end of 6 months.

5.6.5. Complications

Every surgical procedure inherits the risk of complications so is the case with ACL reconstruction. Various factors have been implicated which lead to complications. Some of the factors are discussed below:

- a. Patient selection: there are high chances of failure in cases where the patient returns to sports activity too early without following proper rehabilitation protocols.
- b. Anterior knee pain: the patellar tendon bone graft should be avoided in cases with preoperative knee pain.
- c. Timing of operation: the operative procedure should be delayed by few days in cases of swelling or limited range of motion of the knee.
- d. Fracture of bone plug in the case of PTB graft: with careful harvesting of the graft, this complication can be avoided. It is advisable to harvest graft with the help of saw rather than osteotome. In the case of fracture of bony plug of the PTB graft, the ends of the tendon can be reversed, and the free end can be fixed with large bioscrew.
- e. Dropped graft: in case the graft falls on the floor while preparation or shifting from trolley, then the option is to harvest another graft or wash the dropped graft multiple times with chlorhexidine solution and normal saline. The graft should be prepared on a separate workstation in order to avoid falling of the graft.
- f. Tibial or femoral tunnel malposition: the earlier tunnel can be plugged with bone graft and new tunnel can be created. The complication can be avoided by looking for the tunnel positions with fluoroscopy.

- g. Posterior blowout of femoral tunnel: in case of posterior wall blow out, the method of femoral fixation should be changed to endobutton or cortical fixation techniques. The posterior wall blow out can be prevented with accurate positioning of the femoral zig before drilling the femoral tunnel. It is preferable to flex the knee beyond 90° to create a longer femoral tunnel and prevent posterior wall blow out.
- h. Loss of fixation: in case of tibial fixation, use a screw of the same or one size larger to achieve good purchase and avoid loss of fixation. This complication can be avoided with the appropriate measuring of the tunnel width and drilling it according to the graft width.
- i. Patellar fracture: it can occur intraoperatively and in late postoperative period.
- j. Arthrofibrosis: in cases where the patients do not follow the postoperative rehabilitation protocol, there are high chances of knee stiffness and loss of motion. Regular physiotherapy sessions can prevent this complication.
- k. Residual or recurrent instability: sometimes there could be failure of fixation or tunnel widening (femoral or tibial) leading to sense of instability. Thorough workup should be carried out to ascertain the cause of residual instability.

5.7. Outcome assessment

The functional outcome of the ACL reconstruction should be done with the help of measurement scales like international knee documentation committee form (IKDC), Oxford Knee Score (OKS), etc. [22]. However, the practice of outcome assessment is followed up in very few cases by authors. If the outcome assessment is carried out on these scales, then the interpretation of results can be done easily by others. Due to complexity of these forms, the authors generally avoid these methodologies. We should strive to form a universally acceptable and easily reproducible scoring system so that the results can be interpreted with ease.

5.8. Conclusion

Anterior cruciate ligament is now increasing being treated operatively with good functional results. The choice of graft has shifted from patellar tendon bone to hamstring graft over the years. There are several other graft choices; however, the preference depends upon the surgeon and patient. The more important issue in ACL reconstruction is the correct placement of tunnels. The modern zigs and fluoroscopy help in correct tunnel formations and hence graft placement. The assessment of the functional outcome should be done by both subjective and objective measurement scales.

Acknowledgements

I acknowledge the support from Dr. Darsh Goyal and Dr. Deepak Bansal for their support in preparation of the manuscript.

Conflict of interest

There is no conflict of interest in preparation of this chapter.

Author details

Kavin Khatri^{1*}, Darsh Goyal² and Deepak Bansal³

*Address all correspondence to: kavinkhatri84@gmail.com

1 Guru Gobind Medical College and Hospital, Faridkot, India

2 Sports Injury Centre, New Delhi, India

3 AIMC Bassi Hospital, Ludhiana, India

References

- [1] Groves EWH. Operation for repair of the crucial ligaments. *Clinical Orthopaedics and Related Research*. 1980;**147**:4-6
- [2] Bertolia JT, Urovitz EP, Richards RR, et al. Anterior cruciate reconstruction using the MacIntosh lateral-substitution over-the top repair. *The Journal of Bone and Joint Surgery. American Volume*. 1985;**67**:1183-1188
- [3] Erikson E. Reconstruction of the anterior cruciate ligament. *Orthopedic Clinics of North America*. 1976;**7**:167-179
- [4] Lipscomb AB, Jonhston RK, Synder RB, Warburton MJ, Gilbert PP. Evaluation of hamstring strength following use of semitendinosus and gracilis tendons to reconstruct the anterior cruciate ligament. *The American Journal of Sports Medicine*. 1982;**10**:340-342. DOI: 10.1177/036354658201000603
- [5] Martin SD, Martin TL, Brown CH. Anterior cruciate ligament fixation. *Orthopedic Clinics of North America*. 2002;**33**:685-696. DOI: 10.1016/S0030-5898(02)00023-8
- [6] Rue JP, Lewis PB, Parameswaran AD, Bach BR Jr. Single bundle anterior cruciate ligament reconstruction: Technique overview and comprehensive review of results. *The Journal of Bone and Joint Surgery. American Volume*. 2008;**90**(Suppl 4):67-74
- [7] Gabriel MT, Wong EK, Woo SL, Yogi M, Debski RE. Distribution of in situ forces in the anterior cruciate ligament in response to rotatory loads. *Journal of Orthopaedic Research*. 2004;**22**:85-89
- [8] Buoncristiani AM, Tjoumakaris FP, Starman JS, Ferretti M, Fu FH. Anatomic double-bundle anterior cruciate ligament reconstruction. *Arthroscopy*. 2006;**22**:1000-1006

- [9] Odensten M, Gillquist J. Functional anatomy of the anterior cruciate ligament and a rationale for reconstruction. *Journal of Bone and Joint Surgery. British Volume (London)*. 1985;**67**:257-262
- [10] Girgis FG, Marshall JL, Monajem A. The cruciate ligaments of the knee joint. Anatomical, functional and experimental analysis. *Clinical Orthopaedics and Related Research*. 1975;**106**:216-231
- [11] Georgoulis AD, Pappa L, Moebius U, et al. The presence of proprioceptive mechanoreceptors in the remnants of the ruptured ACL as a possible source of reinnervation of the ACL autograft. *Knee Surgery, Sports Traumatology, Arthroscopy*. 2001;**9**:364-368
- [12] Noyes FR, Butler DL, Grood ES, Aernicke RF, Hefzy MS. Biomechanical analysis of human ligament grafts used in knee ligament repairs and reconstructions. *Journal of Bone and Joint Surgery. British Volume (London)*. 1984;**66**:344-352
- [13] Hefzy MS, Grood ES. Sensitivity of insertion locations on length patterns of anterior cruciate ligament fibers. *Journal of Biomechanical Engineering*. 1986;**108**:73-82
- [14] Sakane M, Fox J, Woo SL, Livesay GA, Li G, Fu FH. In situ forces in the anterior cruciate ligament and its bundles in response to anterior tibial loads. *Journal of Orthopaedic Research*. 1997;**15**:285-293
- [15] Devgan A, Singh A, Gogna P, Singla R, Magu NK, Mukhopadhyay R. Arthroscopic anatomical double bundle anterior cruciate ligament reconstruction: A prospective longitudinal study. *Indian Journal of Orthopaedics*. 2015;**49**(2):136-142. DOI: 10.4103/0019-5413.152406
- [16] Stevens K, Dragoo J. Anterior cruciate ligament tears and associated injuries. *Topics in Magnetic Resonance Imaging*. 2006;**17**(5):347-362
- [17] Ng WHA, Griffith JF, Hung EHY, Paunipagar B, Law BKY, Yung PSH. Imaging of the anterior cruciate ligament. *World Journal of Orthopedics*. 2011;**2**(8):75-84. DOI: 10.5312/wjo.v2.i8.75
- [18] De Smet A, Nathan D, Graf B, Haaland B, Fine J. Clinical and MRI findings associated with false-positive knee MR diagnoses of medial meniscal tears. *American Journal of Roentgenology*. 2008;**191**(1):93-99
- [19] Shelbourne KD. JG. Patient selection for anterior cruciate ligament reconstruction. *Operative Techniques in Sports Medicine*. 1993;**1**(7):16-18
- [20] Pinczewski L, Lyman J, Salmon L, Russell V, Roe J, Linklater J. A 10-year comparison of anterior cruciate ligament reconstructions with hamstring tendon and patellar tendon autograft: A controlled, prospective trial. *Scandinavian Journal of Medicine & Science in Sports*. 2007;**17**(5):611-619
- [21] Rue JH, Busam ML, Bach Jr BR. Hybrid single-bundle anterior cruciate ligament reconstruction technique using a transtibial drilled femoral tunnel. *Techniques in Knee Surgery*. 2008;**7**:107-114
- [22] Dawson J, Fitzpatrick R, Carr A, Murray D. Questionnaire on the perceptions of patients about total hip replacement. *Journal of Bone and Joint Surgery. British Volume (London)*. 1998;**80**(1):63-69

