

We are IntechOpen, the world's leading publisher of Open Access books Built by scientists, for scientists

6,900

Open access books available

186,000

International authors and editors

200M

Downloads

Our authors are among the

154

Countries delivered to

TOP 1%

most cited scientists

12.2%

Contributors from top 500 universities



WEB OF SCIENCE™

Selection of our books indexed in the Book Citation Index
in Web of Science™ Core Collection (BKCI)

Interested in publishing with us?
Contact book.department@intechopen.com

Numbers displayed above are based on latest data collected.
For more information visit www.intechopen.com



Crush Injuries of the Hand Part I: History, Mechanism and Pathomechanics

Roohi Sharifah Ahmad and Pho Robert Wan Heng

Additional information is available at the end of the chapter

<http://dx.doi.org/10.5772/intechopen.76658>

Abstract

This chapter, the first of two; deals with the basics of crush injuries of the hand as opposed to crush syndrome. The definition is explained and the differences are outlined. A journey through the historical review of the causative mechanisms gives the reader an insight into the machines inflicting a spectrum of injuries and their sequelae. We see how the tools either remain the same or change with time, exacting similar types of injuries but in a different manner and timescale due to mechanisation. Thus it is vital to grasp the mechanics to get a basic understanding of the pathomechanics, enabling one to address the injury by reversing the inflicative force while maintaining respect for the machine. These are humbling injuries that require experience, expertise and enterprise by a dedicated and cohesive team always open to learning.

Keywords: crush, hand, injuries, mangled extremity, trauma

1. Introduction

Crush injuries of the hand pose a challenge to even the most accomplished of hand surgeons, whether it is a minor fingertip injury sustained by getting squashed in a closing door or a high pressure compression injury involving the palm or wrist.

A **crush injury** is defined as compression of the extremities causing muscular and neurological disturbance [1] and in the upper limb is sustained when the fingers, hand or wrist are caught between two surfaces (sharp, blunt, smooth or irregular) forcibly producing damage to the skin and its enclosed contents of soft tissues and bone. The degree of damage is proportional to the amount of force applied per square inch and the duration the compression is in place.

Thus a crushing element is present in almost all hand injuries be it distributed over a narrow segment as in a guillotine amputation of a finger or diffusely spread as in a roller injury.

Prolonged compression in heavy machinery in a more proximal part of the limb may induce **additional** systemic sequelae known as the **crush syndrome**. This was first described in the German language literature by Von Colmers, following the 1909 Messina earthquake and by Frankenthal during the 1916 World War I air raids as cited in Better [2]. The English Language literature, however, was only enlightened by Bywaters and Beall after the 1940 London ‘Blitzkrieg’ of World War II, where they outlined the pathogenesis of crush syndrome and its potential systemic effects of myoglobinuria leading to acute renal failure causing the patient’s demise hours or even days later [3]. He described alkalisation of urine as a method to prevent the acute renal failure and subsequent deterioration, which has stood the test of time. Michaelson defined continuous prolonged pressure on the limbs of at least 4 hours duration prior to extrication as causing crush syndrome [4]. Fortunately, crush injuries to the hand distal to the wrist have less systemic manifestations primarily due to a smaller muscle bulk. They are however otherwise no less dramatic and have evolved over the years associated with technological developments in human endeavours (**Table 1**).

Time and causative factor	Authors	Year
Agricultural age		
<i>Machines on the farm</i>		
Corn picker injury	Robinson and Hardin	1955
	Campbell DC et al.	1979
	Gorsche and Wood	1988
Grain auger injury	Grogono	1973
	Beatty et al.	1982
Farm machinery	Simpson	1984
Farm-related Injuries	Chun	1999
<i>Woodwork related mishaps</i>		
Woodworking tools	Heycock	1966
Chain saw injuries	Haynes et al.	1980
Wood splitter injuries	Jaxheimer et al.	1981
Industrial age		
<i>Industrial machines</i>		
Wool carder	Smith and Asturias	1968
Wringer injury	MacCollum et al.	1952
<i>Electrical machines</i>		
Escalators	Campbell Reid	1973

Time and causative factor	Authors	Year
Meat mincers	Al-Arabi and Sabet	1984
Sugarcane juice extracting machine	Rajput and Daver	1999
Dough sheeter	Carriquiry and Arganaraz	2005
Noodle-making machine	Ju et al.	2015
<i>Motors</i>		
Rotary lawn mowers and snowblowers	Barry and Linton	1977
Roll over injury	Harris and Wood	1978
Roll bar hand	Charters and Davis	1978
Overturning motor vehicle	Mehrotra and Crabb	1979
Forklift		1999
<i>Information age</i>		
Roping injury	Morgan	1984
Roping injury	Kirwan and Scott	1988
Pay phone receiver cord	Lesavoy	1984
<i>Sports related</i>		
Soccer	Curtin and Kay	1976
Karate	Nieman and Swann	1977

Table 1. Causes of crush injuries over the last 50 years.

2. Historical review

2.1. Mechanism of injury

2.1.1. The agricultural era

This period brought about some of the most devastating effects from the corn picker injury as first described by Robinson in 1955 and later by Campbell in 1979 and then Gorsche in 1988 [5–7], and later by the equally if not more devastating Grain Auger injury which cut swathes at multiple levels [8, 9]. In the mid 1960s to early 1970s when the oil embargo of the Arab states diverted energy sources away from fuel to firewood, a higher incidence of injuries with wood working tools was reported by Heycock in 1966 [10], the modern (and fatalistic) version of which is the chainsaw or circular saw injury (**Figure 1**) [11] and the motorised wood splitter injury [12]. The advent of industrialisation into the agricultural sector saw farm machinery and farm-related injuries coming into the scene in the 1980s and 1990s being a challenge due to the high contamination [13, 14].

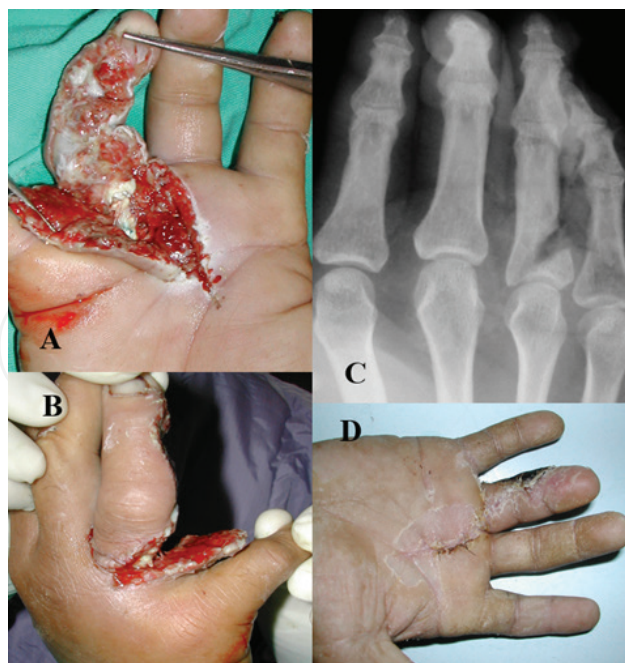

Figure 1. A, B: A circular chainsaw used to cut meat went through this gentleman's 3rd web space damaging flexor tendons, nerve and pulleys, plus C: Creating a gap in the proximal phalanx corresponding to the gauge of the saw. D: Although secondary infection complicated the healing, the flap survived and function was restored.

2.1.2. The industrial age

The advent of **the industrial age** saw its own share of mutilation with workers spinning wool on an electrical wool carder [15] sustaining a unique injury thereof with the fingers undergoing a crush and the spikes inflicting a horrific-looking but benign injury (**Figure 2**).

Children were the victims in 80% of "The Wringer Injury" as cited by MacCollum was first described in 1938 [17]. It wreaked havoc for 45 years till production was stopped in 1983 via legislation [18]. In the late 1960s and early 1970s, there was a flood of children getting their hands caught in escalators and meat mincers each presenting with their unique brand of mechanism and challenge [19, 20]. The former primarily caused a deep avulsion or a degloving (**Figure 3**), while the latter had two levels of injury: a multilevel cutting injury first like a miniature auger (**Figure 4**) and a mincing mechanism sustained later.

Peculiar but not exclusive to South and South East Asia is the sugarcane juice extraction machine which was described in 1999 [21] and has also evolved from manual to electric. This produced devastating injuries similar to the dough sheeter injury [22] with components of grinding, compression and avulsion, making it difficult to salvage digits [23]. In our experience, most end up with a metacarpal hand for the machine is very unforgiving and the infection due to bacterial contamination challenging to eradicate, requiring meticulous, repeated débridements in the primary setting (**Figure 5**). Another unique Asian injury is the noodle machine, which causes a degloving injury (**Figure 6**), of which in the English literature only one article mentions it in passing [24]. A more widespread but less reported one is the coconut grinding machine which causes a similar injury to the grain auger (and meat mincer) but of a smaller scale (**Figure 7**).

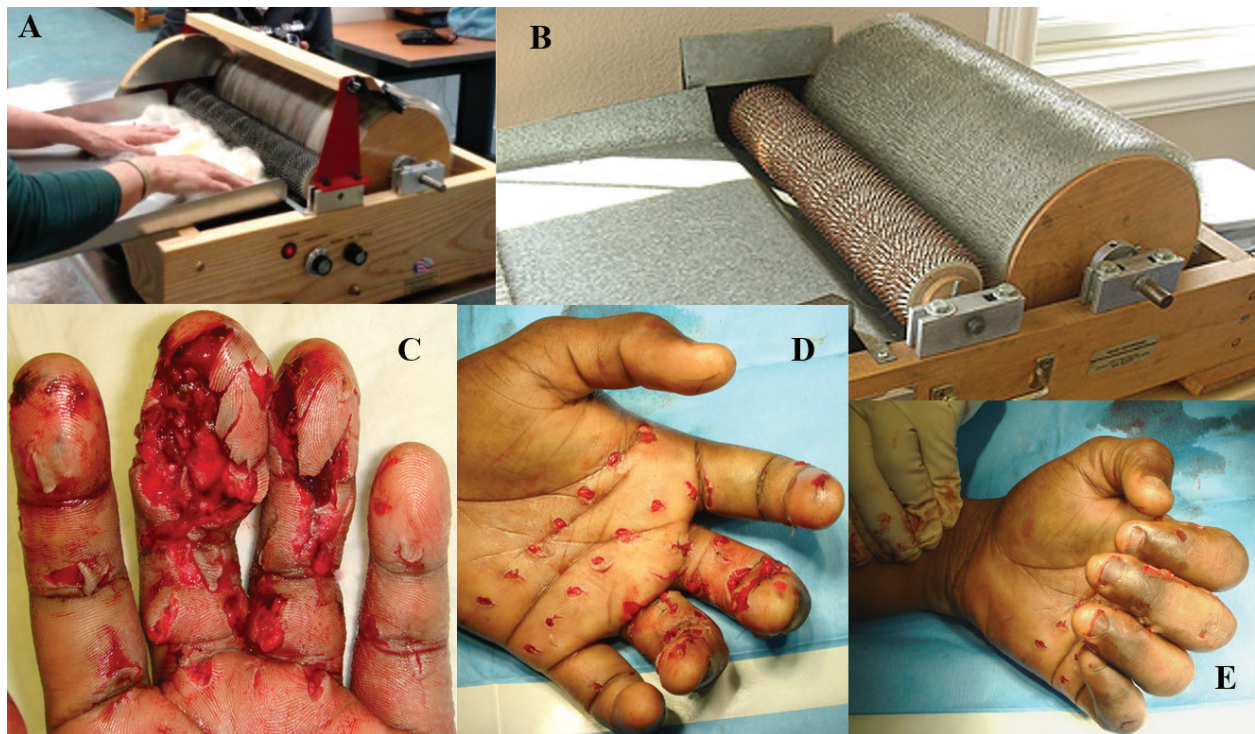


Figure 2. A, B: Images taken from Strauch filter blog [16] depicting how the wool is fed and what the machine looks like. C: The clinical picture where the digits (mostly middle and proximal phalanges) are crushed. D: Proximally the spikes, depending on their circumference and length inflict minimal harm. E: There was no neurological deficit in this gentleman and the flexors were fine as can be seen.

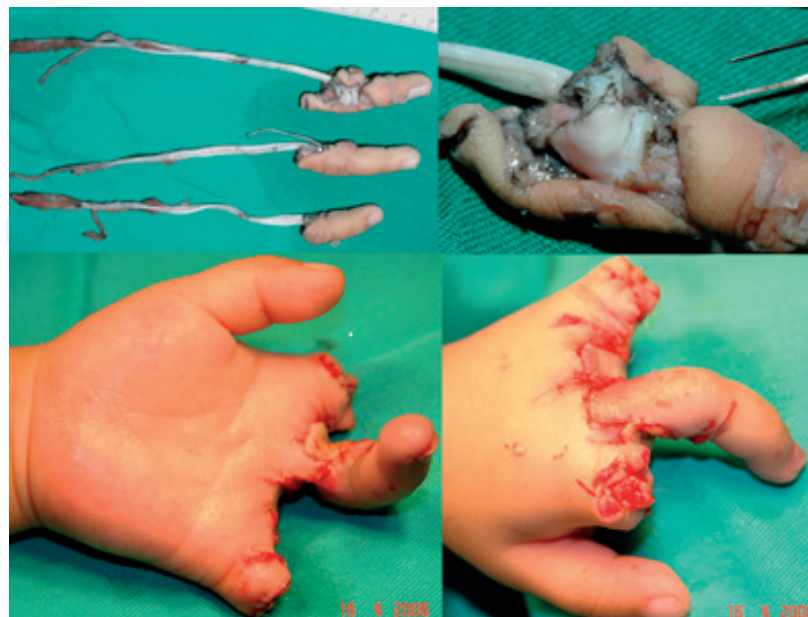


Figure 3. Anticlockwise from top left: A 3 year old girl caught her left hand in an escalator when she fell and had an avulsion of all her fingers. Only the middle pinked up after replantation. There was severe torsion and avulsion as shown.

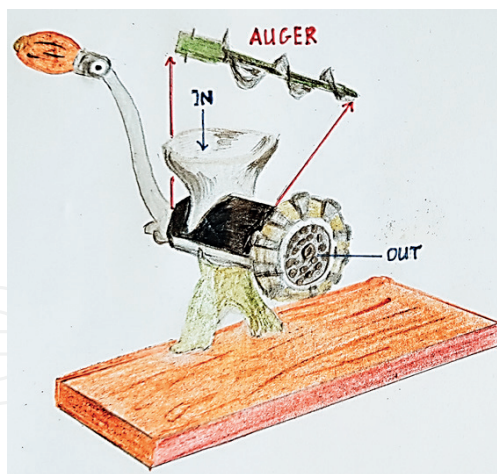


Figure 4. The manual meat mincer is not as damaging as the electrical one. The meat is placed into the funnel, pushed in and drawn into the mini auger mechanism (drawn outside of the black tube) which then forces it out through the small perforations (2–3 mm in diameter). If a hand is caught, it will be cut in swathes and squeezed out through the exiting mechanism; beyond repair or reconstruction. Usually the machine has to be brought to hospital and the patient placed under anaesthesia before extrication.

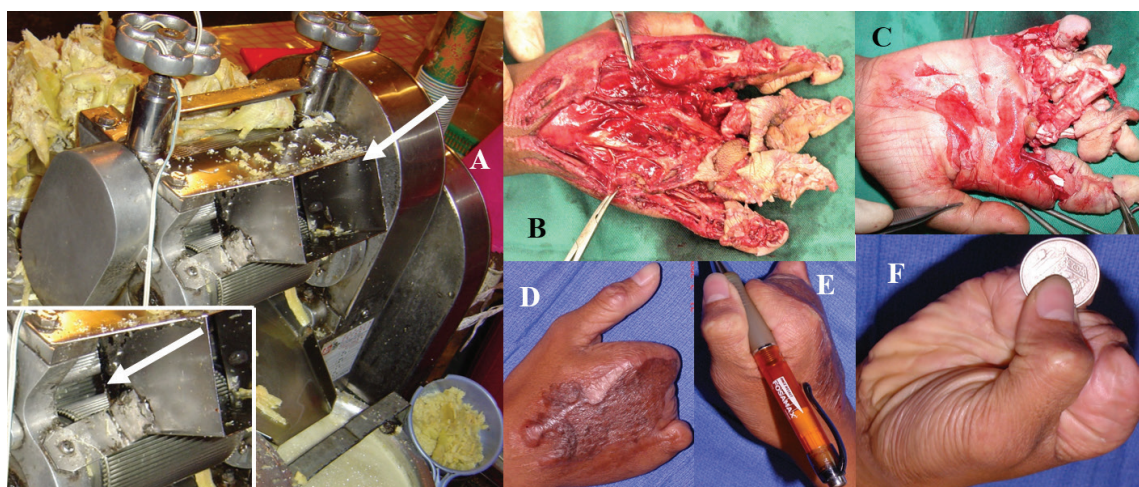


Figure 5. **A:** The sugarcane juice extraction machine feeding box (right white arrow) is where the cane is pushed into. It squeezes the cane between two rollers (left white arrow, inset) with an adjustable width in between (8–15 mm). **B, C:** Besides causing severe crushing (distal to proximal) and mangling the extremity, there is also extensive avulsion since the victim usually is trying to pull out the hand in the opposite direction to the rollers. **D–F:** This was the only patient in a series of six cases over a 2-year period [23] whose thumb was left intact. Usually only the metacarpals were spared and saving the remaining was an arduous if not impossible task.

In the **vehicle** category is the powered industrial vehicle (PIV) and although the literature describes how 70% of PIV injuries are attributable to forklifts [25], there are no specific articles on hand injuries caused by forklifts [26]. This is we feel a special entity which needs to be dealt with because it causes extensive damage to the skeleton as well as the soft tissues and needs rigid and rapid fixation best achieved with a simple form of mini external fixator (**Figure 8**). Spring and winter brought their own brand of injuries in rotary lawn mowers and snow blowers [28], while the motor vehicle left its own special mark, described as the roll

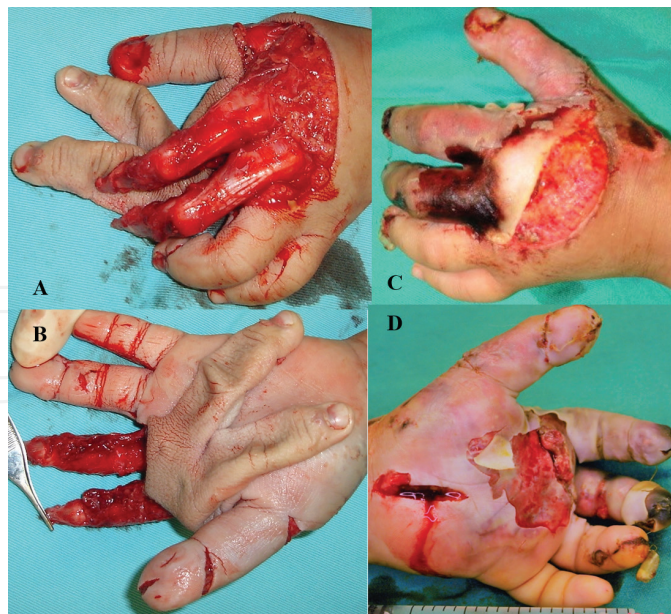


Figure 6. A, B: A 5 year old boy had his left hand caught in the escalator and the radial side was completely degloved. The veins were also thrombosed but we could anastomose one vessel on the thumb. **C, D:** As can be seen, the thumb and index finger were still pink a week later but part of the middle finger skin (only) had necrosed.

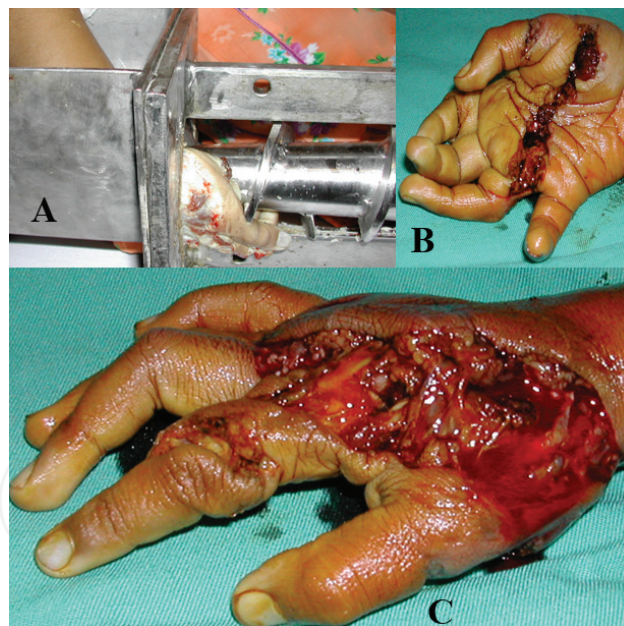


Figure 7. A: Coconut grating machine. A smaller version of the grain auger but just as devastating. Usually these devices need to be removed with the help of the fire department and sometimes under sedation or anaesthesia. **B, C:** Extensive crushing of the bone and soft tissues is seen at two levels.

over injury or roll bar hand in 1978 by Harris and Charters, respectively [29, 30] and subsequently by Mehrotra and Crabb as hand injuries sustained in the overturning motor vehicle [31]. Typically, the victim would have the hand outside the window during the accident or it is grazed along the gravel – what we call the “brake pad injury” (**Figure 9**).

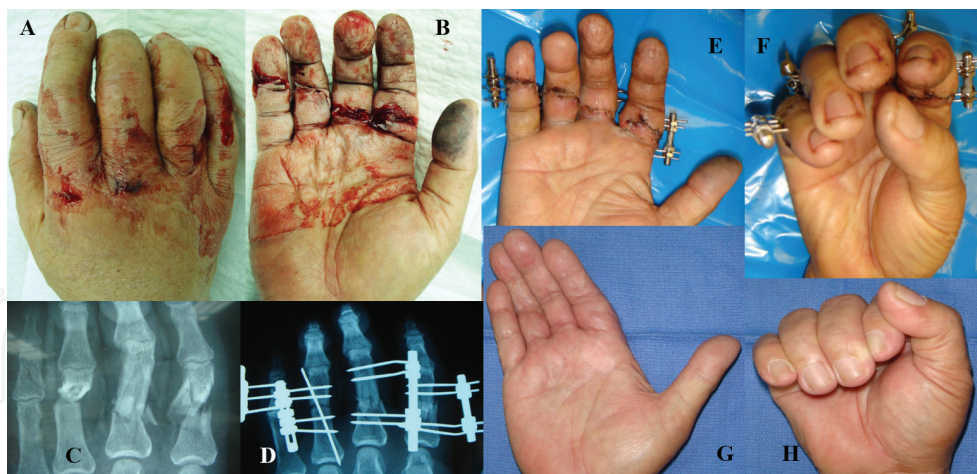


Figure 8. A, B: This gentleman was a supervisor who inadvertently got his right (dominant) hand caught between the ceiling beam and the forklift prongs. C: A clear line of injury (fractures) is seen across the proximal and middle phalanges. He had a heart condition and we were given 2 hours to fix all. D-F: Mini external fixators from Waldemaar Link® [27] made a rapid, rigid fixation possible and a mobile hand is seen within 5 days. G, H: 3 months post-operatively, he has a good range of motion and is able to make a grip.

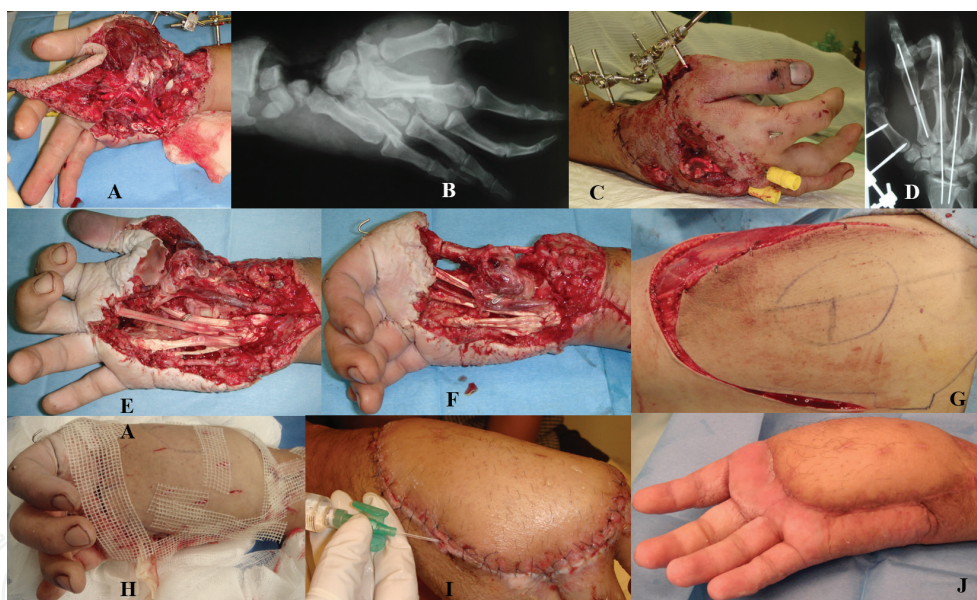


Figure 9. A, B: A 30 year old Army captain had a roll over injury in his car and hit a metal divider which all but severed his right hand at the radio-carpal level. He presented from another hospital 20 hours later. Salvage was attempted because it was his right hand. C, D: Revascularisation, debridement and tendon repair performed at 24 hours post-trauma and held with Kirschner wires and an external fixator. E: Infection destroyed the revascularisation and 3 days later the thenar muscles became necrotic. F: However, the thumb ray was only amputated after a delay in consent of 5 days. G, H: A free lateral thigh flap was performed to cover the defect and I: The battle with infection was finally won a year later. J: He felt “functional” although he had lost his thumb and did not want a pollicisation.

2.1.3. The information age

In this era, electrical equipment and wiring had peculiar stringing injuries as described by Morgan in 1984 [32] and as roping by Kirwan and Scott in 1988 [33]. Pay phone receiver cords [34] and power drill cords also cause similar injuries where the cord wraps around the hand or forearm like a vise cutting off blood supply and causing ischaemia to the limb (**Figure 10**).

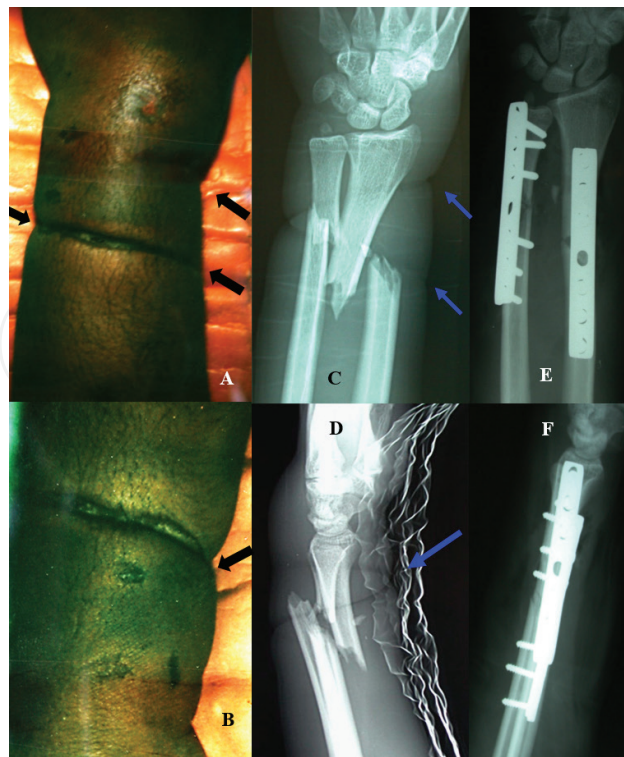


Figure 10. The deep indentation caused by the electrical cord (black arrows in **A & B**) can be seen with the corresponding marks on the radiographs (blue arrows in **C & D**), along with the bony injury. In this patient, prior to open reduction and internal fixation, the vessels were explored and found to be intact but in spasm. The vessel spasm was overcome by 10% Xylocard and warm saline, and subsequently bony fixation was carried out, (**E, F**).

2.1.4. Sport

A number of different types of hand injuries have been described while playing soccer but these are mostly fractures or associated ligamentous injuries with less of a crushing element to the tissues [35]. Karate is a sport, which may cause a crush injury to the hand or forearm since the hand is used as a weapon to demolish bricks and other hardware [36].

Thus we can see the spectrum of change in the pattern of crushing injuries to the hand but though the cause may be different, the mechanism and resultant effects still pose a challenge to the modern-day hand surgeon.

2.2. Pathomechanics

The pathomechanics of a crush injury will vary according to the manner in which the injury was sustained. The damage done is related to the **force** of the injury (**both in magnitude and direction**), the **velocity** of the impact and the **surface area** of the crushing. The damage sustained is also dependant on the **site** of injury, the surrounding skin and its contents.

Therefore, the **zone of injury** sustained is a function of the applied **force**, the **velocity** and the **width** of the offending object. These three main factors will determine the outcome and extent of the injury. The **duration** of compression as well as compounding factors such as **friction**, **heat**, **cold**, **chemicals** and **contamination** add further damage to the injured area.

2.2.1. Magnitude of force and velocity

The force may be a **low-energy** mechanism with resultant closed injury and fewer stigmata of damage. Typically, this may be due to a door or a drawer closing on the fingertip producing a subungual haematoma, a nailbed injury, a mallet deformity or a tuft fracture of the distal phalanx (**Figure 11**). The milder ones may not even present at the casualty department but may be seen later in the clinic. A more severe form seen especially in children called a Seymour Fracture occurs where the nail plate is avulsed proximally with an associated nailbed injury and a distal phalanx (P3) fracture (Salter Harris I) through the epiphysis (**Figure 12**). The middle finger being the longest is most commonly involved. Soft tissue interposition and instability dictate operative repair and fixation otherwise complications may include infection, nail disturbances, growth arrest and deformity [37].

A **high energy** force with a high velocity of impact would cause serious damage not only at site of impact but can cause degloving of the proximal part as well, from the dynamic force of the hand pulling away. These injuries are sustained in a road traffic accident or high pressure punch presses such as printing presses (**Figure 13**).

2.2.2. Direction of force

The crushing mechanism may be **uniplanar** as in a heavy object falling from a height onto the hand or **multiplanar** with either an associated *torsional* or a *tractional* force. Grain augers exert a *torsional* force and are used for raising grain and they cause characteristic multiple swathes equidistant to the spiral turns of the auger blade drawing the limb in with each turn (**Figure 14**). A similar mechanism is used in the meat mincer and the coconut grating machine (**Figures 4, 7**). An example of a *tractional* force can be seen in Roller belt injuries (**Figure 15**) as well as those due to the sugarcane juice extracting machine where severe avulsion or degloving of tissues can occur due to the pulling action, along with devastating superinfection due to microbial (*Pseudomonas Ae*) contamination [23].

2.2.3. Width of crushing force

The width of the instrument of injury determines the depth and extent of bone and soft tissue damage.

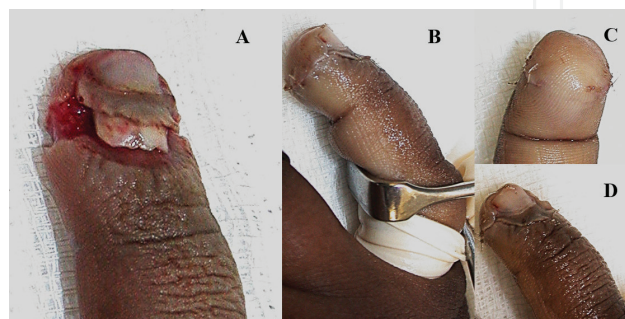


Figure 11. **A:** Typical fingertip injury in a child due to entrapment in a drawer or a door jamb. Note the proximal nail plate extrusion. **B:** Simple reduction of the nail plate under GA is required with **C, D:** Suturing of the pulp with a Vicryl® 7/0 spatulated needle.

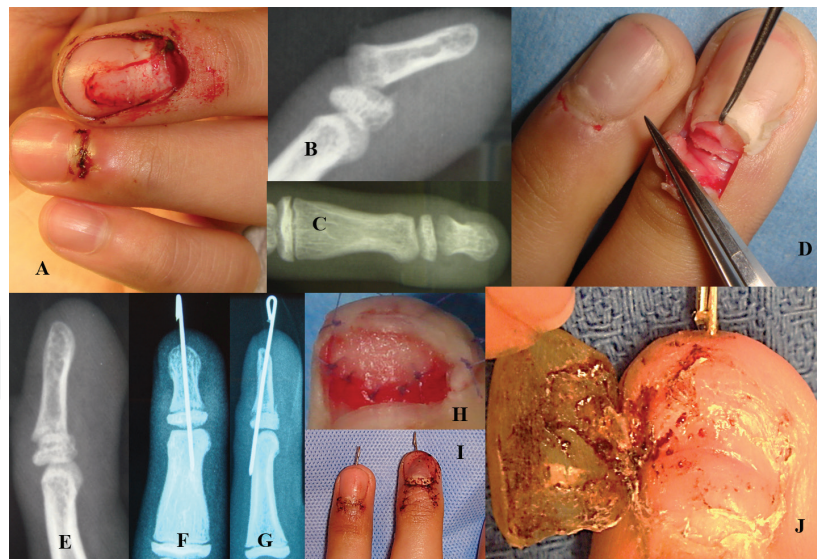

Figure 12. A: Typical Seymour fracture with haematoma and nail plate avulsion from base and flexion deformity of the middle finger. This deformity is due to the metaphyseal attachment of the flexor to the distal phalanx (P3), while the extensor attachment is more proximal at the epiphysis. B, C: X-ray shows a fracture through the epiphyseal plate but it may be missed in the AP view. D: The nail plate is elevated and two parallel skin incisions lifting the eponychium reveal the nailbed fracture in the germinal matrix. E: The fracture is reduced, then F, G: Pinned. H: We use spatulated 7/0 Vicryl® to suture the nail bed. I: The nail plate is reinserted under the eponychial fold after repair. J: After 2–3 weeks the nail plate can be removed to allow the new nail to grow out.

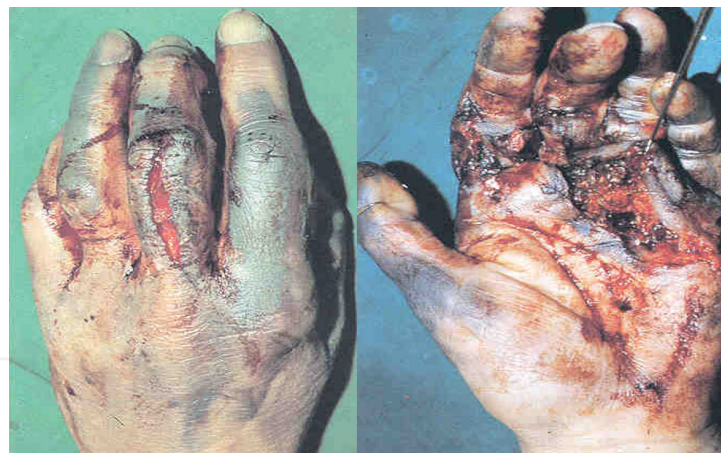

Figure 13. Left hand caught in a printing press. The ink marks can be seen staining the hand. To allow accurate assessment of circulation, these have to be scrubbed off. There is a longitudinal burst laceration seen over the dorsum of the middle finger over the proximal phalanx as well as a degloving injury in the palmar area (skin hook).

$$\text{Pressure} = \text{Force per unit area.}$$

Therefore, for the same force, the smaller the unit area, the higher the pressure concentrated over that minute area. Thus a sharp instrument with a lesser amount of force (sharp knife = amputation) might slice through tissue whereas a compression over a wider area (hammer = burst laceration) would cause more of a crushing injury.

The direction of the force is also important, whether it is along the tissue planes or perpendicular to it. Thus a vessel may be sliced in a transverse fashion – in case of a complete transection,

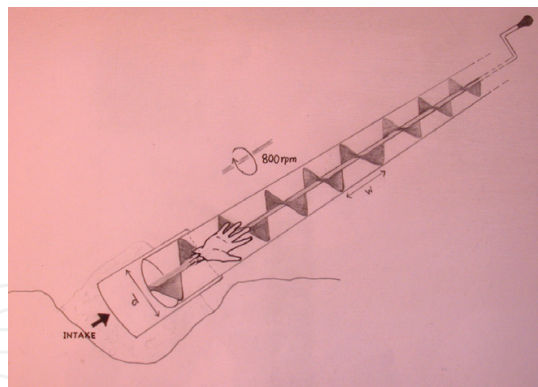


Figure 14. The grain auger mechanism uses the Archimedes principle to churn up water or grain against gravity. The spiral blades are approximately 6 inches apart (w) and the diameter (d) of the tube is also 6 inches. Thus the pitch is 1–1. It runs at 800–900 revolutions per minute and therefore moves grain up at a speed of 400 feet a minute or 7 feet a second!.

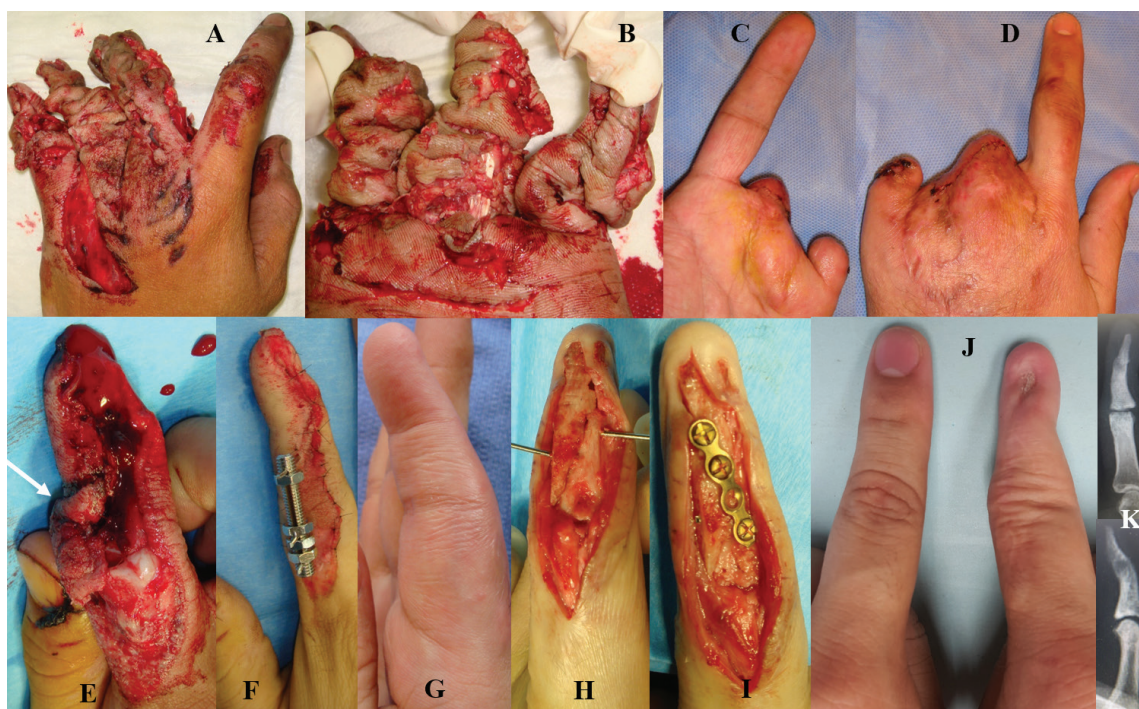


Figure 15. Top row: **A, B:** Shows the hand of an engineer that got caught in a running conveyor belt that was faulty. Note the 'rolled' skin folds and how the flexor tendons remain intact. **C, D:** All but his index and thumb were mangled which afforded him a pincer grip. Bottom row: **E:** A 32 year old mechanical engineer also got his finger caught in a roller belt which grazed the radial half of his ® dominant index finger, leaving only a sliver of rolled skin (white arrow) which **F:** Was used as a skin graft in the repair and skeletal stabilisation. **G:** He only had 20° of flexion after removal of the external fixator at 6 weeks. **H, I:** Reconstruction was performed using a bone graft and plating, 4 months post-trauma and physiotherapy. **J:** Size is smaller but he has full power and two-point discrimination of 4 mm. **K:** The radiographs show good fusion of the DIPJ and a clear PIPJ. Final ROM was 10–75°.

it will go into spasm and contract, but a partial one may be held open and still bleed – or scathed along its length (**Figure 16**). The latter will usually present with hypovolaemic shock due to profuse uncontrollable bleeding. Pressure dressing should be applied and exploration performed in the operating room.

2.2.4. Site of injury

The dorsum of the hand has minimal soft tissue padding and is relatively vulnerable to **bony injury**. A metacarpal fracture commonly occurs with a direct blow on the dorsum of the hand. Bony injury often results from the high energy impact of blunt objects related to the factors of force, velocity and width of the striking objects and may present in a spectrum of varying depths of involvement and comminution (**Figure 17**), from periosteal stripping, to unicortical fracture, to transverse, oblique, spiral or comminuted fracture, to segmental fracture and segmental bone loss.

Soft tissues over the palmar aspect are fairly well protected by the thick and highly sensitive glabrous skin. Neurovascular bundle and flexor tendon injuries are seldom seen in closed injuries. In open fracture of the phalanges, associated neurovascular and flexor tendon injuries must be looked for. The flexor tendons are very resistant to injury and usually are the last to be severed (**Figures 5 and 15B**). In the mid-palmar space, which is a relatively confined region holding soft tissues contained by a thick fascia, a sudden compression with high pressure may lead to bursting injuries, resulting in rupture and extrusion of muscles (**Figures 18, 19**).

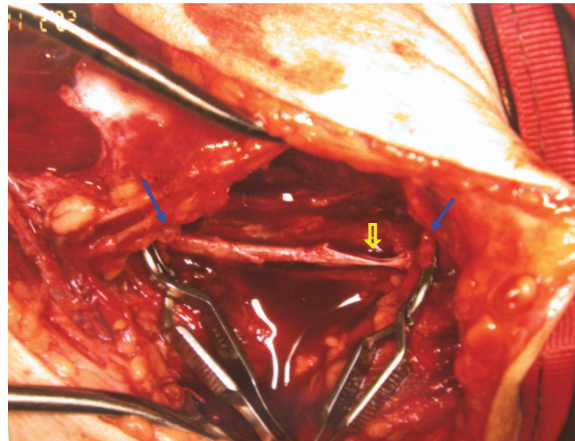


Figure 16. Stab injury to the right arm of a young gentleman who was hemodynamically unstable at presentation with a compromised circulation to his right upper limb. The brachial artery had been severed completely (held in bulldog clamps – solid arrows) and was in spasm but the vein was scalloped (hollow arrow) by the sharp instrument used in this assault and the culprit in the profuse bleeding. Picture courtesy of Professor Lim Beng Hai, Dept of HRM, NUH.

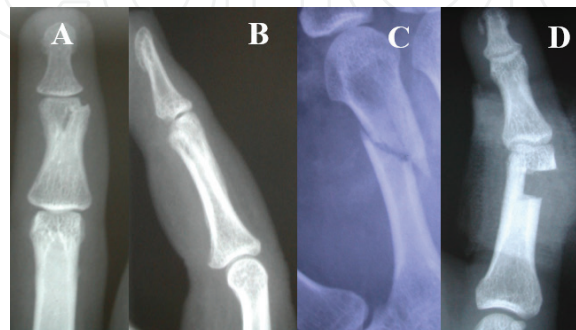

Figure 17. Varying depths of bony involvement: Radiological features **A, B**: Unicortical fracture which was initially missed in the A&E department, **C**: Short spiral fracture of 2nd metacarpal, and **D**: Segmental bone loss in the proximal phalanx the width of which corresponds to the thickness of the grinding axe.

2.2.5. Other factors

Thermal necrosis may be present due to friction, as in roller injuries or heat, chemical and electrical burns which cause either partial or full thickness skin loss or due to hot compression presses which result in full thickness loss even up to the deep muscle layer of the hand (**Figure 20**).

The roller injury is special in that it commonly results in distally based avulsion flaps and may be associated with friction burns [38]. The size of the gap between the rollers as well as

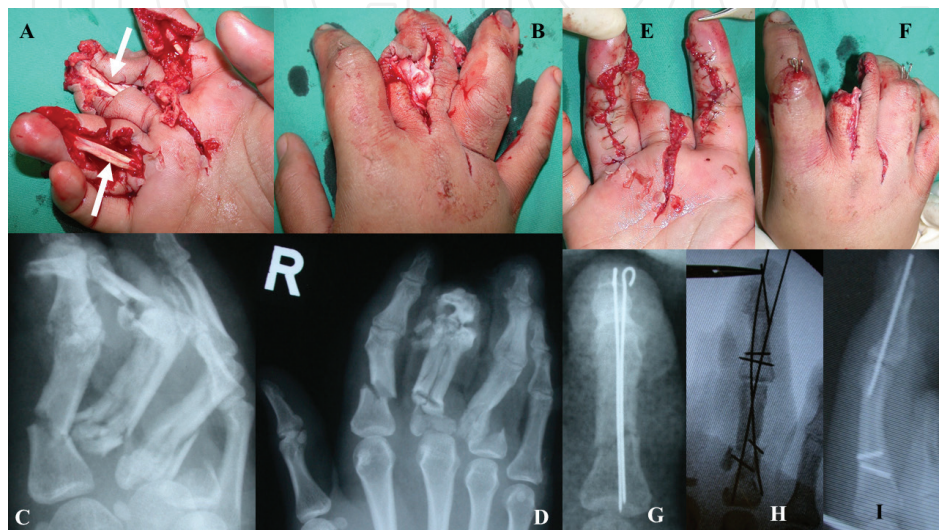

Figure 18. A, B: This lady's dominant right hand was caught in between two compressive surfaces and sustained burst lacerations to index, middle and ring fingers but the flexor tendons can be seen intact. The pulleys however, had to be reconstructed. C, D: The severity of comminution can be appreciated in the radiographs. E, F: The index finger had good refill and was fixed with cross k-wires. G: The middle finger could not be salvaged due to severe damage to both digital vessels. The periosteal sleeve of the proximal phalanx was shredded and also undertaking reconstruction would have retarded rehabilitation of the hand as a whole. H, I: The ring finger had multiple comminuted fractures and had to be revascularised. She went on to heal with some stiffness, but had pinch and grip functions.

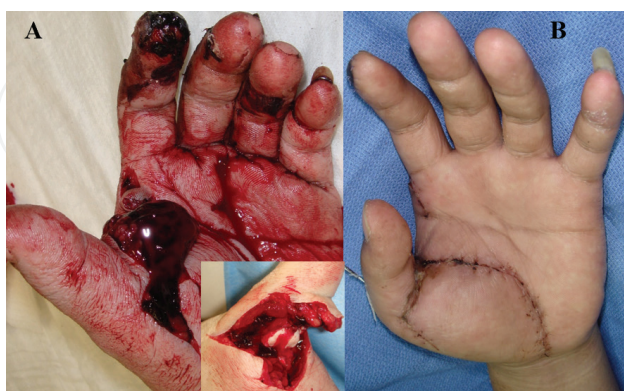

Figure 19. A: A 30 year old caught his left non dominant hand in a 200Kg compression machine while he himself was operating the lever. Debridement could only be done 6 hours later. **Inset:** After removal of the haematoma, it was noticed that the muscles were ischaemic, the pulleys ruptured and the MCP joint volarly dislocated. **B:** The joint was reduced and held with a K-wire. The thenar muscles that were necrotic had to be excised and carpal tunnel was released in anticipation of the oedema. He regained excellent motion but had reduced strength as expected.

the padding is important to determine the amount and force of crushing. If there is an automatic stop mechanism, there is some tendency to minimise damage. An examiner should not be foxed by superficial friction burns. A **degloving injury** of skin and deep tissues may not be apparent especially in a closed injury or incomplete avulsion. The resultant shearing off of blood vessels in the subcutaneous plane may lead to secondary thrombosis of the blood vessels resulting in fat necrosis and delayed necrosis of overlying skin [39]. A direct injury to the muscle or a compromised circulation of the forearm and hand may eventually lead to Volkmann's ischaemic contracture, an early symptom of which is pain on extension of the digits (**Figure 21**). A narrow gap in the rollers would inevitably involve severe crushing of muscles, nerves and the skeletal framework. For the novice, a simple guide to the extent of crushing may be evaluated by the degree of bony comminution in the X-ray (**Figure 22**).

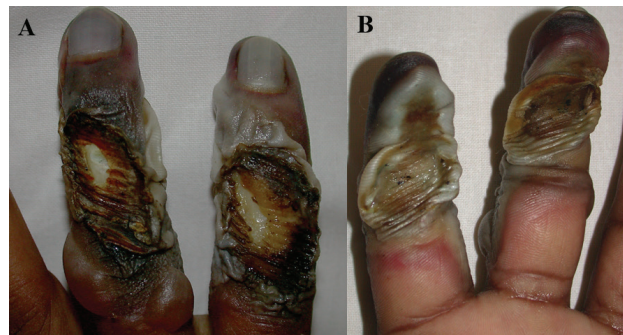


Figure 20. A, B: The ring and small fingers of this man's right hand were caught in a cardboard box-manufacturing machine of an ice-cream factory. He sustained full thickness burns of all structures down to bone. Revision amputation had to be carried out.

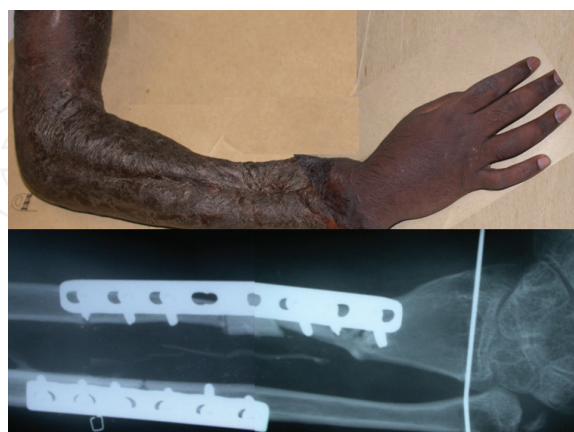

Figure 21. A 22 year old man sustained a roller crush injury of his left arm up to mid-humerus. He developed Volkmann's ischaemic contracture with atrophic non-union and shortening of his distal radius fracture, resulting in radial deviation. He also had patchy involvement of both median and ulnar nerves typical of ischaemic aetiology. **X-ray:** An ulnar shortening osteotomy and radial bone grafting was done to correct the deformity along with extensor adhesiolysis and median and ulnar nerve neurolysis.

2.3. Pathogenesis of crush syndrome

Compression of muscular segments of the limb is the basic mechanism underlying the pathogenesis of crush syndrome. The relative contribution of compression leading to ischaemia of the muscles and direct injury to the muscle leading to necrosis is difficult to separate. Mechanical compression alone with an adequate vascular supply (warm periphery with palpable pulses) has been shown to cause significant pathological changes in skeletal muscle by as early as 60 minutes as shown by Better and Stein and cited in Burzstein and Carlson [40]. This compares unfavourably to a warm ischaemic time of 6 hours – without compression [41], leading Burzstein and Carlson to conclude that *skeletal muscle is more sensitive to mechanical compression than ischaemia*. This may be due to the fact that in compression intramuscular pressures may reach as high as 240 mmHg [42] which is thought to compromise the microvasculature of skeletal muscle. This may cause alteration in myocyte function in terms of calcium flux across mitochondrial and plasma membranes.

In ischaemic injury however, reperfusion results in further damage to skeletal muscle resulting in the coinage of the term “reperfusion injury”. The offending substances are O_2 -derived free radicals such as super oxide, H_2O_2 and hydroxyl ions, which cause parenchymal and microvascular endothelial damage especially with reperfusion. Compounds such as super oxide dismutase (SOD) and catalase which when administered, inhibit or neutralise these radicals, have been shown to limit the reperfusion injury in the affected tissue and its microvasculature [43, 44].

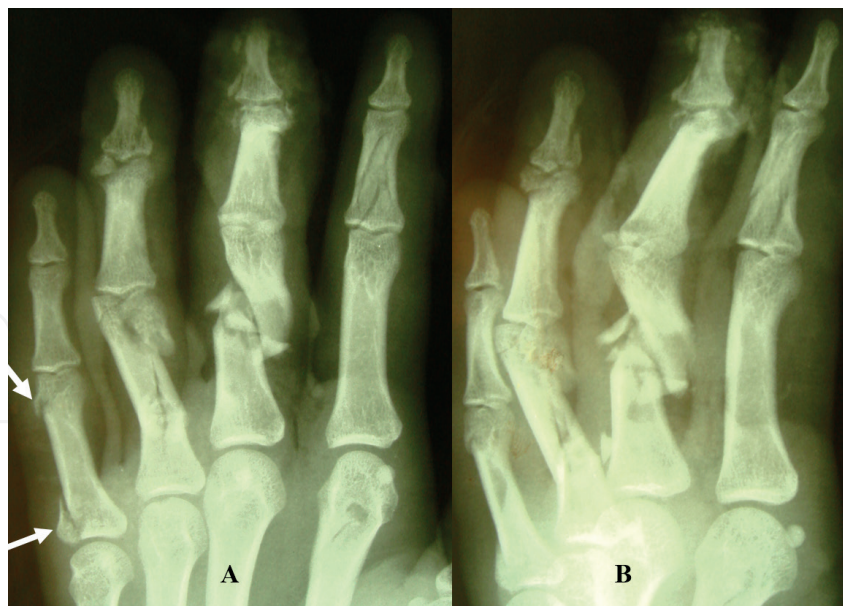


Figure 22. A, B: Compare these AP and lateral radiographs to the clinical picture of the patient in **Figure 2**. The degree of comminution (and displacement) is worst in the proximal phalanx of the middle finger followed by the ring and small. The former two would best be fixed internally with mini plates. The small finger may get away with a lag screw fixation – the abductor digiti minimi inserts at the base while the collateral ligament attaches at the neck. The middle phalanx of the index finger also has significant comminution, but no displacement and would do well with a mini external fixator. Note the punched hole in the 2nd metacarpal.

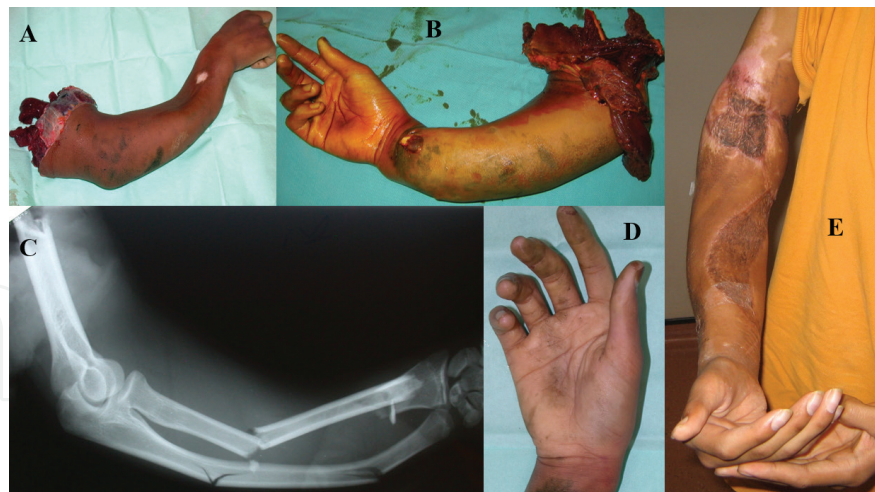

Figure 23. A 17 year old accidentally caught his right arm in a machine used to mix dyes at a carpet factory. **A, B:** He had an avulsion amputation at the mid-humerus level with **C:** segmental fractures of his radius and ulna. **D:** His hand was unharmed though. **E:** Reperfusion was achieved within 4 hours of injury and he attained a good function of his upper limb.

Krapohl et al. [45] showed that a crush injury to the arteries supplying the cremasteric muscle in rats resulted in a significant decrease in skeletal muscle perfusion even though the blood supply though the crushed vessel is maintained and that this may be due to thrombogenic results.

In another interesting animal study, thrombolysis followed thrombosis in rat arteries with induced crush injuries [46]. However, if the crushed arteries were divided and sutured with microvascular anastomosis almost all thrombosed (90%) unless they were irrigated with topical heparin solution which reduced the thrombosis rate but did not promote thrombolysis.

Both these studies show that localised crush injuries to the arteries deserve to be treated with respect and that all such tissue should be excised prior to microvascular anastomoses. It is also important to appreciate that the severity of the crushing may result in amputation of the digits and hand (**Figure 5**). In segmental crushing, however, the distal amputated part, for example, of the hand may be relatively uninjured (**Figure 23**).

3. Conclusion

A thorough understanding of the underlying mechanisms of injury will enable the primary surgeon to pay due diligence where required in detailed planning of the step by step management constantly deliberating carefully between damaged tissues to discard while treating with respect the tissues to be salvaged.

Acknowledgements

Roohi S.A. would like to thank Prof. Dr. Lim Beng Hai for his guidance as well as the use of some of his work in the Figures as acknowledged.

Conflict of interest

The authors declare no conflict of interest and have not received any remuneration or benefit from any entity for the writing or publication of this article.

Appendix and Nomenclature

ADM	abductor digiti minimi
DIPJ	distal interphalangeal joint
FDP	flexor digitorum profundus
FDS	flexor digitorum superficialis
K-wire	Kirschner wire
MCPJ	metacarpophalangeal joint
MVA	motor vehicle accident
P	phalanx 1: proximal, 2: middle, 3: distal
PIPJ	proximal interphalangeal joint
PT	post-trauma
ROM	range of motion
RTA	road traffic accident

Author details

Roohi Sharifah Ahmad^{1*} and Pho Robert Wan Heng²

*Address all correspondence to: roohihandsurgery@gmail.com

1 Universiti Putra Malaysia, Serdang, Selangor, Malaysia

2 National University of Singapore, Singapore

References

- [1] Fact Sheet Developed by the CDC. Available from: <http://www.emergency.cdc.gov/BlastInjuries>

- [2] Better OS. History of the crush syndrome. *American Journal of Nephrology*. 1997;**17**: 392-394
- [3] Bywaters EGL, Beall D. Crush injuries and renal function. *British Medical Journal*. 1941;**1**(4185):427-432
- [4] Michaelson M. Crush injury & crush syndrome. *Journal of Surgery*. 1992;**16**(5):899-903
- [5] Robinson DW, Hardin CA. Corn picker injuries. *American Journal of Surgery*. 1955; **89**:780-783
- [6] Campbell DC, Bryan RS, Cooney WP, Ilstrup D. Mechanical corn picker hand injuries. *The Journal of Trauma*. 1979;**19**(9):678-681
- [7] Gorsche TS, Wood MB. Mutilating corn-picker injuries of the hand. *The Journal of Hand Surgery (Am)*. 1988;**13**:423-427
- [8] Grogono BJS. Auger injuries. *Injury*. 1973;**4**(3):247-257
- [9] Beatty ME, Zook EG, Russell RC, Kinkead LR. Grain auger injuries: The replacement of the corn picker injury? *Plastic and Reconstructive Surgery*. Jan 1982;**69**(1):96-102
- [10] Heycock MH. On the management of hand injuries caused by woodworking tools. *British Journal of Plastic Surgery*. 1966;**19**:58-67
- [11] Haynes CD, Webb WA, Fenno CR. Chain saw injuries: Review of 330 cases. *The Journal of Trauma*. 1980;**20**(9):772-775
- [12] Jaxheimer EC, Morain WD, Brown FE. Wood splitter injuries of the hand. *Plastic and Reconstructive Surgery*. July 1981;**68**(1):83-88
- [13] Simpson SG. Farm machinery injuries. *Journal of Trauma, Injury and Infection*. Feb 1984; **24**(2):150-152
- [14] Chun S. Management of farm-related injuries to the upper extremity. *Hand Clinics*. 1999;**15**(2):201-220
- [15] Smith JR, Asturias J. Card injury of the hand. *Journal of Bone and Joint Surgery*. Sep 1968;**50-A**(6):1161-1170
- [16] Strauch blog. Available from: <http://www.strauchfiber.com/wordpress/?paged=4>; <http://www.twosheep.com/blog/?p=593>
- [17] MacCollum DW, Bernhard WF, Banner RL. The treatment of wringer-arm injuries. *New England Journal of Medicine*. 1952;**247**:750-754
- [18] Hemenway D. Home. In: Hemenway D, editor. *While We Were Sleeping: Success Stories in Injury and Violence Prevention*. Berkeley: University of California Press; 2009. pp. 34-35
- [19] Reid DAC. Escalator injuries of the hand. *Injury*. 1973;**5**(1):47-50

- [20] Al-Arabi KM, Sabet NA. Severe mincer injuries of the hand in children in Saudi Arabia. *Journal of Hand Surgery (British)*. 1984;**9**:249-250
- [21] Rajput RJ, Daver BM. Sugarcane crushing machine injuries – Mechanism of injury, classification & management. *Indian Journal of Plastic Surgery*. 1999;**32**:50-53
- [22] Carriquiry CE, Arganaraz D. Dough sheeter injuries to the upper limb: Severity grading and patterns of injury. *Journal of Trauma, Injury, Infection, and Critical Care*. 2005; **58**:318-322
- [23] Ahmad SR. Sugarcane extraction machine injuries of the hand. *BMC Proceedings*. 2015; **9**(Suppl 3):A104
- [24] Jihui J, Li J, Hou R. Microsurgery in 46 cases with total hand degloving injury. *Asian Journal of Surgery*. Oct 2015;**38**(4):205-209
- [25] Collins JW, Smith GS, Baker SP, Landsittel DP, Warner M. A case-control study of forklift and other powered industrial vehicle incidents. *American Journal of Industrial Medicine*. Nov 1999;**36**(5):522-531
- [26] Larsson TJ, Rechnitzer G. Forklift trucks— Analysis of severe and fatal occupational injuries, critical incidents and priorities for prevention. *Safety Science*. 1994;**17**(4):275-289
- [27] LINK® Ellis Mini-Fixator External. Available from: <https://www.linkorthopaedics.com/en/for-the-physician/products/lower-extremity/mini-fixator-external/>
- [28] Barry TP, Linton PC. Biophysics of rotary mower and snowblower injuries of the hand: High versus low velocity ‘missile’ injury. *The Journal of Trauma*. Mar 1977;**17**(3):214-221
- [29] Harris CN, Wood VE. Rollover injuries of the upper extremity. *The Journal of Trauma*. 1978;**18**(8):605-607
- [30] Charters AC, Davis IW. The roll-bar hand. *The Journal of Trauma*. 1978;**18**(8):601-604
- [31] Mehrotra ON, Crabb DJM. The pattern of hand injuries sustained in the overturning motor vehicle. *The Hand*. 1979;**11**(3):321-328
- [32] Morgan RF, Nichter LS, Friedman HI, McCue 3rd FC. Rodeo roping thumb injuries. *Journal of Hand Surgery (Am)*. 1984;**9**:178-180
- [33] Kirwan LA, Scott FA. Roping injuries in the hand: Mechanism of injury and functional results. *Plastic and Reconstructive Surgery*. 1988;**81**:54-61
- [34] Lesavoy MA, Meals RA. Pay phone receiver cord injuries to the hand. *Journal of Hand Surgery (Am)*. 1984;**9**:908-909
- [35] Curtis J, Kay NRM. Hand injury due to soccer. *The Hand*. 1976;**8**(1):93-95
- [36] Nieman EA, Swann PG. Karate injuries. *British Medical Journal*. 1977;**1**(742):223
- [37] Watts E. Seymour Fracture. Available from: <https://www.orthobullets.com/hand/6000/seymour-fracture>

- [38] Smith P. In: Smith P, editor. *Lister's the Hand, Diagnosis and Indications*. 4th ed. London: Churchill Livingstone; 2002
- [39] Strahan J, Crockett DJ. Wringer injury. *Injury*. Jul 1969;**1**(1):57-64
- [40] Burzstein S, Carlson G. In: Cooper GJ, editor. *Crush Injury in Scientific Foundations of Trauma*, Section 4, Chapter 22. Boston: Butterworth-Heinemann; 1997. pp. 285-299
- [41] Whitesides TE, Harada H, Morimoto K. The response of skeletal muscle to temporary ischaemia: An experimental study. *Journal of Bone and Joint Surgery*. 1971;**53A**:1027
- [42] Owen CA, Mubarak SJ, Hargens AR, et al. Intramuscular pressures with limb compression: Clarification of the pathogenesis of the drug-induced muscle compartment syndrome. *The New England Journal of Medicine*. 1979;**300**:1169-1172
- [43] Walker PM, Lindsay TF, Labbe R, et al. Salvage of skeletal muscle with free radical scavengers. *Journal of Vascular Surgery*. 1987;**5**:68-75
- [44] Collard CD, Gelman S. Pathophysiology, clinical manifestations, and prevention of ischaemia-reperfusion injury. *Anaesthesiology*. 2001;**94**:1133-1138
- [45] Krapohl BD, Mailander P, Siemionow M, Giunta R, Zins JE. Arterial crush injury causes decrease in tissue perfusion at the level of the microcirculation in skeletal muscle flaps. *Microsurgery*. 1999;**19**(8):364-368
- [46] Chen LE, Seaber AV, Jun UJR. Thrombosis and thrombolysis in crushed arteries with or without anastomosis: A new microvascular thrombosis model. *Journal of Reconstructive Microsurgery*. 1996;**12**(1):31-38

