

We are IntechOpen, the world's leading publisher of Open Access books Built by scientists, for scientists

6,900

Open access books available

186,000

International authors and editors

200M

Downloads

Our authors are among the

154

Countries delivered to

TOP 1%

most cited scientists

12.2%

Contributors from top 500 universities



WEB OF SCIENCE™

Selection of our books indexed in the Book Citation Index
in Web of Science™ Core Collection (BKCI)

Interested in publishing with us?
Contact book.department@intechopen.com

Numbers displayed above are based on latest data collected.
For more information visit www.intechopen.com



Laparoscopic Inguinal Hernia Repair: Technical Details, Pitfalls and Current Results

Fatih Altintoprak, Emrah Akin,
Kemal Gundogdu and Enis Dikicier

Additional information is available at the end of the chapter

<http://dx.doi.org/10.5772/intechopen.76942>

Abstract

Expanding view of minimal invasive surgery horizon reveals new practice areas for surgeons and patients. Laparoscopic inguinal hernia repair is an example in progress wondered by many patients and surgeons. Advantages in laparoscopic repair motivate surgeons to discover this popular field. In addition, patients search the most convenient surgical method for themselves today. Laparoscopic approaches to inguinal hernia surgery have become popular as a result of the development of experience about different laparoscopic interventions, and these techniques are increasingly used these days. As other laparoscopic surgical methods, experience is the most important point in order to obtain good results. This chapter aims to show technical details, pitfalls and the literature results about two methods that are commonly used in laparoscopic inguinal hernia repair.

Keywords: laparoscopy, inguinal hernia, TAPP, TEP

1. Introduction

For centuries, the inguinal hernias have played an important role in the surgical literature and continue to preserve this feature today. With many procedures, inguinal hernia interventions continue to be the most common general surgery operations worldwide and approximately 2 million people are operated for inguinal hernia every year. There are many techniques described on the surgical treatment of inguinal hernias. There is no other example of disease preoccupied in the surgical literature. Existence of the postoperative complications suggests that we have not found the ideal treatment option yet because a wide variety of techniques

have been described and most of the surgeons engaged in this procedure have completed learning curves a long time ago. In 1984, about hernia, Sir Astley Paston Cooper says: “No disease from the human body, belonging to the surgeon, demands in its treatment, a better mixture of precise, anatomical knowledge along with surgical skill, compared to hernia in most of its variations”. In this chapter, the details and results of two laparoscopic techniques, which have become common in inguinal hernia treatment today, are evaluated in detail.

2. Incidence and general information

The incidence of inguinal hernia varies according to age and sex. There is a bi-modal distribution in males and it increases in the first year of life and in older ages. The rate of 15% in the second decade increases with age and reaches 47% in the seventh decade. In females, this rate is 3% for life. There is a significant difference between the male/female ratio and is reported as 1:15. Although the majority of the inguinal hernia patients do not face great problems in resuscitating their lives, the incidence of general incidence and emergency case incidence (incarceration-strangulation) increases with age [1].

Inguinal hernias are classified as direct or indirect inguinal hernia according to their mechanism and anatomical characteristics. Indirect inguinal hernias are the most common subtype and the risk of strangulation is much higher compared to direct hernias. In the case of strangulation, it is also necessary to mention that the femoral hernias head to this issue. Femoral hernias, which are found in 70% of women and generally settled in the principle of “should be fixed when they are detected”, due to the risk of strangulation, have not been included in this section [2].

When the side is concerned, it is a fact that all inguinal hernias are seen more on the right side. One of the theories developed to explain this is that there is anatomically protective effect of the sigmoid colon present on the left side and delayed atrophy of the processus vaginalis due to the slower descent of the scrotum on the right side during embryological development.

3. History

The word “hernia” came from the Latin word “rupture” and was described as a disease in the first fifteenth century in papyrus. The idea of repairing surgery came out between fifteenth and seventeenth centuries although the inguinal region anatomy has been described in detail by Hesselbach, Cooper, Camper, Scarpa and Gimbernat during eighteenth and nineteenth centuries. In the twentieth century, “tension-free repairs” started to be proposed and in the last 25 years, parallel to technological developments, videoscopic repairs became widespread. As a result of this development, surgical procedures have now become the standard procedure for “strengthening the abdominal wall in the transverse fascia plan” and are accepted all over the world [3].

The idea of laparoscopic repair was first alleged by Ger in 1982 by the collapse of the internal loop. In 1990, Schultz used transperitoneal plugs and developed the intraperitoneal onlay mesh (IPOM) technique, which was performed in the same year by patching the Fitzgibbons

peritoneum. Transabdominal preperitoneal (TAPP) patch application was first performed by Leroy in 1990. Then in 1991 Dulucq and in 1992 McKernan introduced total extraperitoneal (TEP) intervention [4].

4. Anatomy

In the inguinal region, four different types of hernia—indirect, direct, femoral and obturator—can develop. One of the most important advantages of the posterior approach is the ability to reveal the entirety of hernia types. There are median, medial and lateral ligaments in the anterior wall of the abdomen after fetal period, followed by urachus obliteration, umbilical artery obliteration and inferior epigastric vessels, respectively. In addition, there are iliopubic tractus, pectineal ligament (Cooper) and lacunar ligament in pubic region, pubic tubercle, spina iliaca anterior superior (SIAS) and superior pubic ramus bones [5].

There are two potential gaps in the preperitoneum. The “Bogros gap” is located between the transverse fascia and the peritoneum. Preperitoneal fatty tissue and porous connective tissue fill this area. The medial part of the preperitoneal cavity on the bladder is known as the “Retzius cavity”. The posterior view angle allows examination of the myofeklineal orifice, which is a relatively weak part of the abdominal wall and is divided by the inguinal ligament [6].

The external iliac vessels are anastomosed with the inferior epigastric vessels and the superior epigastric vessels. They supply the abdominal wall and penetrate the rectus abdominus through the cranial route within the vagina musculature rectus. Posteriorly inspected anulus inguinalis profundus will reveal the deep location of inferior epigastric vessels. In addition, the aberrant obturator arteries formed by the anastomosis of the pubic ramus of the epigastric artery with the obturator artery, known as “Corona Mortis”, constitute the basis of the death triangle. The medial side of this triangle is vas deferens, the lateral side is the spermatic cord and the posterior border is the peritoneal margin.

The inferolateral border of the iliopubic tract, the superomedial border of the gonadal vessels and the lateral border of the peritoneal catheter is defined as the area of the pain triangle and the intermediate cutaneous branches of the lateral femoral cutaneous nerve, the femoral branch of the genitofemoral nerve and the anterior branch of the femoral nerve contain posterior anatomical approach.

5. Material and methods

We performed laparoscopic inguinal hernia surgery in 163 patients between January 2017 and 2018 in our clinic. Laparoscopic hernia repair was recommended to patients who are suitable for general anesthesia, had no previous abdominal surgery or incarceration or strangulated hernia or without acute mechanical intestinal obstruction. In terms of learning curve, TAPP was performed on first 50 cases and TEP on the following cases. A total of 155 (95%) patients were male and 8 (5%) were female. A total of 51 patients received TAPP (31.2%) and 112 patients (68.7%) received TEP. Eight patients who underwent TAPP (15.6%) were operated

for recurrence. Thirteen patients (25.4%) underwent bilateral repair while three (5.8%) patients underwent the same session umbilical hernia repair. The groups were evaluated in terms of operation time, pain scores, recurrence rates, duration of hospitalization and return to daily activity and complication rates. TAPP average operation time is 58 min while in bilateral cases this duration is 72 min. The duration of operation of recurrent cases was 59 min average and there was no significant difference between these patients and the primary cases. A total of 112 patients were treated with TEP technique. Nineteen patients (16.9%) were operated for recurrent hernia, and 14 patients (12.5%) underwent bilateral repair. In three patients (2.6%), the same session umbilical hernia repair was also performed. Average duration of TEP is 47 min while in bilateral cases this duration is observed as elongated, 56 min. The duration of operation in recurrent cases was 56 min and there was no significant difference between these patients and the primary cases. The hospital stay was measured as 1.2 days for TAPP and 1.1 days for TEP, and no significant difference was found between the groups. It was also found that the pain scores between the two groups were similar as 3.2 and 2.9 for TAPP and TEP, respectively. The time to return to the daily activity for TAPP was 5.6 days and for TEP was 5.3 days and no significant difference was found between the two groups. As a complication, seroma in four patients (2.4%), recurrent hernia in two patients (1.2%) and chronic persistent pain in six patients (3.6%) occurred. Patients with recurrence were reoperated. Five patients with chronic persistent pain were treated with medical therapy within 6 months, and one patient with osteitis pubis was detected and curettage was performed by orthopedics clinic. In our study, no significant difference in recurrence, return duration to work, pain score, duration of hospitalization and postoperative complication were detected between the groups.

6. Technical points

The use of laparoscopic methods for inguinal hernia surgery is advanced minimal invasive surgery with less tissue trauma, less postoperative pain, lower postoperative infection risk and faster postoperative recovery. It is possible to combine positive effects such as faster return to work and better cosmetic results. As with all surgical techniques, minimally invasive techniques also have advantages. Compared to open surgery, some disadvantages of inguinal hernia surgery are the initial operation time and the long learning curve. Also, the cost is relatively high. In addition, unlike open surgery, the lack of sense of depth in the image, that is, the operation with the 2D image requires the surgeon to dominate the inguinal region anatomy at a high level. Instead of cost problem, by time, the integration of the learning curve and the increase in the experience reduce most of the problems.

There are two main techniques when laparoscopic inguinal hernia repair is concerned. These are defined as transabdominal preperitoneal approach (TAPP) and total extraperitoneal approach (TEP). According to the International Endohernia Group's 2011 Guidelines, revised in 2015, TAPP and TEP have become the preferred repair techniques for the Lichtenstein technique, especially after hernia recurs by open pre-repair [7].

7. Laparoscopic transabdominal preperitoneal approach

It is stated that TAPP is the first method to be learned because it is applicable in all inguinal region hernia types. As an advantage of the intraabdominal approach, the posterior wall anatomy can be better dominated, so proper and adequate parietalization can be made more comfortable. Compared to TEP, the cost is lower and the learning curve is shorter. TAPP is a highly successful method for both incarcerated and scrotal hernias. Due to intraabdominal vision, providing a wide field of view study is one of its greatest advantages and is a method that can be used in laparoscopically repaired recurrent hernias.

8. Technical details

8.1. Operating room layout

The opposite side of the surgical field and both legs are in closed position. In bilateral hernia repair, both arms are in closed position. The videomonitor laparoscopy tower is placed on the patient's foot, on the side to be operated. The operator can be placed on the opposite side of the area to be operated and the camera assistant can be placed on the same side or opposite side of the surgeon depending on the experience and habits of the team. We prefer the camera assistant to sit on the same side of the surgeon (**Figure 1**).

8.2. Surgical instruments

- Standard laparoscopic equipment consisting of camera, monitor, light and bag
- 10 mm diameter and 30° angle camera
- One 10 mm and two 5 mm in diameter totally 3 trocars
- Veress needle
- Endoinstruments (Atraumatic pens, dissector, scissors, hook, acutenaculum, aspirator)
- 5 mm diameter vessel sealing device
- 15 × 15 cm polypropylene or polyester special shaped patch
- Fixing material for mesh detection and peritoneal closure (mechanical stapler, tissue adhesive or non-absorbable suture material) (**Figure 2**).

8.3. Preparation of the patient and treatment of trocars

A single dose of 1 g second-generation cephalosporin as prophylactic antibiotic is injected half an hour before the onset of operation. The patient should urinate before operation and pre-operative fluid resuscitation should be kept to a minimum. Before the operation, the patient

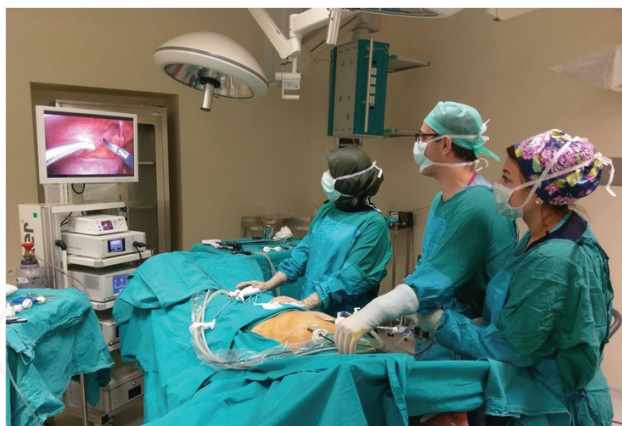

Figure 1. Operating room: The surgeon and camera assistant placed on the opposite side of the surgical area.

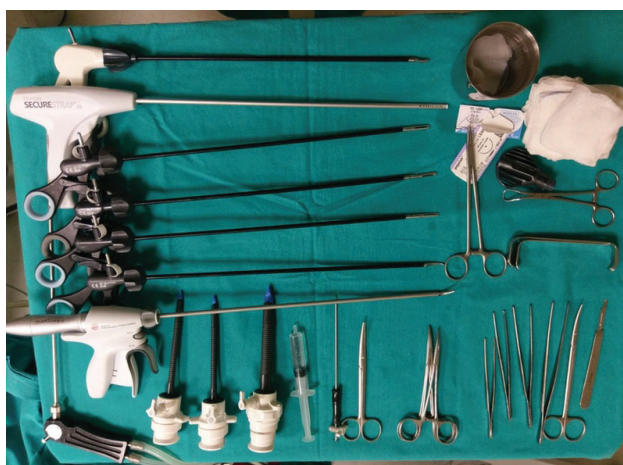

Figure 2. Surgical instruments for TAPP procedure.

is scrubbed and covered in the supine position for sterility. Under general anesthesia, by Hasson technique or with Veress needle which is placed in the infraumbilical region, produces caphno pneumoperitoneum. General intraabdominal exploration is completed with a 10 mm trocar inserted in the infraumbilical region. The operating table position is kept (30° Trendelenburg and 15° – 20° opposite to the operating area). Two operating ports (5 mm) are placed on the umbilical level transverse line, with the lateral sides of both rectus muscles localized and placed under direct vision. The trocars on the operative side are placed on infraumbilical transverse line, while the opposite trocar is placed 4–5 cm caudal side on this line (**Figure 3**). In bilateral hernias, it is suggested that both trocars to be placed on the transverse line at the same level.

8.4. Intraabdominal inguinal exploration

As the trocar placements are complete, the inguinal area is examined with care. The hernia type is detected and the content—if present—of the hernia is carefully reduced to origin with atraumatic clamp. If there are elements such as intestine or omentum in the hernia sac, the viability of intestine or omentum is checked after reduction.

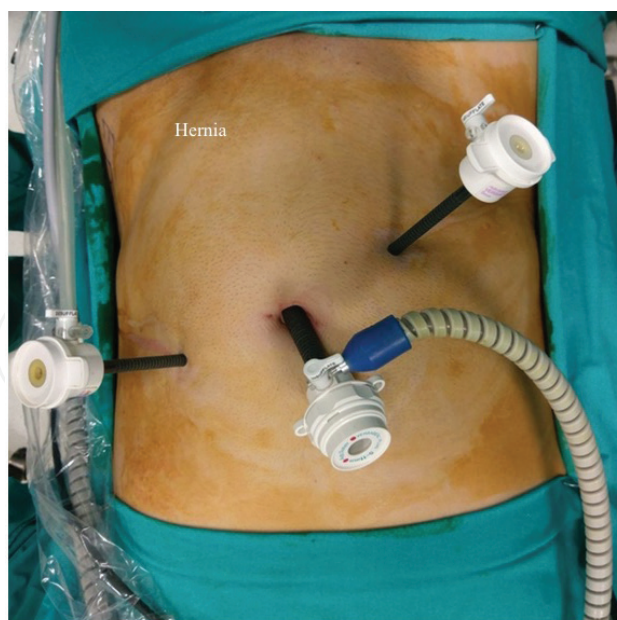


Figure 3. Trocar placement for TAPP procedure.

8.5. Peritoneal incision, dissection and preparation of preperitoneal area

The preparation of the peritoneal flap starts on approximately 5 cm above the hernia canal at the level of the anterior superior crista iliaca on the upper outer side of the annulus inguinalis. The incision is advanced to the medial side of the transverse plane through the upper 5 cm of the inguinal canal's inner ring and terminated at approximately 2 cm to median ligament.

The peritoneal incision can be done with endoscissors or hooks. Rest of the peritoneal flap on the inguinal canal inner ring can be easily disrupted with the help of intraabdominal CO₂ pressure, stretched with endograsper. Peritoneal dissection, below the inguinal canal inner ring, is a little more difficult. The lower peritoneal flap is liberated until lateral visualization of the iliopubic tract, and medial visualization of the Cooper ligament. The hernia sac is carefully dissected from the spermatic cord and elements that are attached through the lower peritoneal membrane (**Figure 4**). The peritoneal upper and lower flaps are dissected in each direction to provide large parietalization and vision of myopectineal orifice. Thus, enough space is available to lay a mesh on probable direct, indirect and femoral herniation defect sources. If bilateral hernias are present, the peritoneal incision can be extended from one side of the crista iliaca to the other side of the crista iliaca, but in the literature it is suggested that a single incision should be made and a peritoneal bridge could be released in the midline.

8.6. Preparation, placement and detection of the mesh patch

Special shaped polypropylene or polyester patches prepared in size appropriate to the anatomical characteristics of the hernia of the patient are used. The patch is rolled from the outside to the inside and from top to bottom in the form of a roll with limb or without limb (**Figure 5**). It is placed into the abdomen through a 10 mm trocar. With the help of two endograspers, placed in the working ports, the roll is unfolded in the opposite direction and is laid to cover

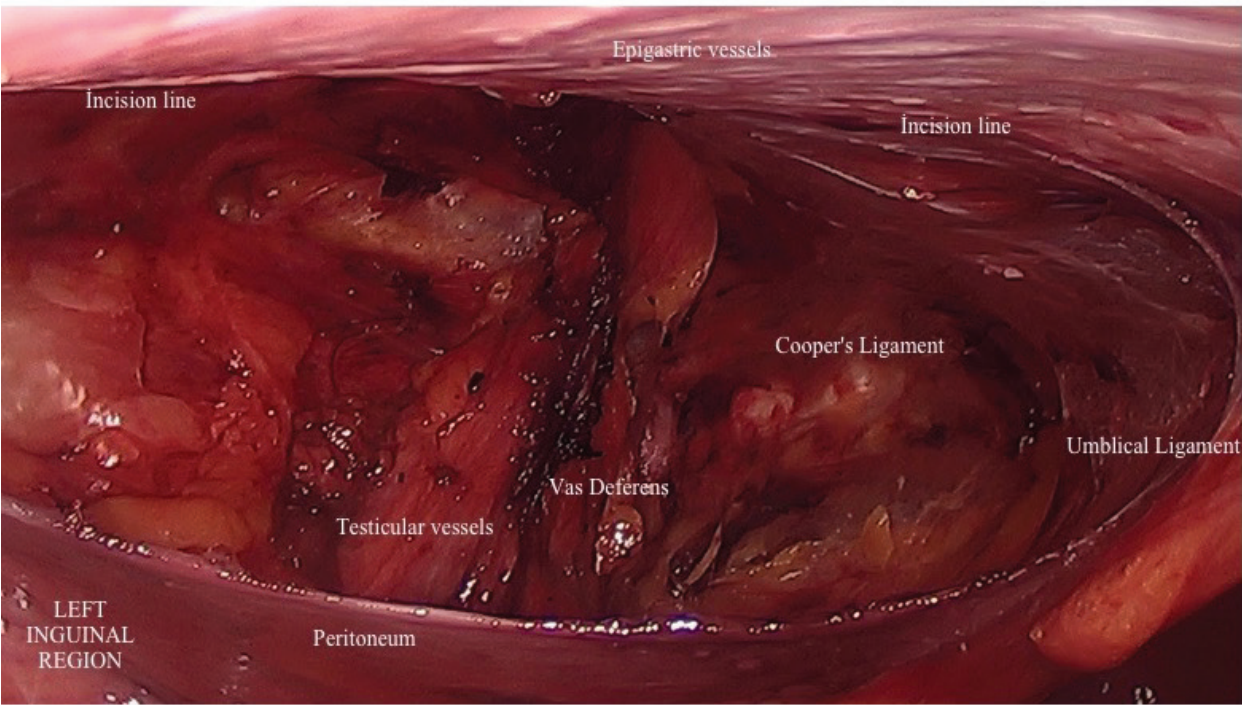


Figure 4. Anatomic details of left inguinal region after peritoneal flap preparation.




Figure 5. Mesh preparation.

the existing hernia defect and potential hernia sources. Also, it must be ensured that the patch is placed with a proper tension. When a limb patch is applied the lower limb is passed under the spermatic cord and it is wrapped in a tie and is joined laterally with the upper limb again. The location and number of staples is very important for the immobilization of the mesh patch. The basic rule—with different suggestions about this—is that the staples must be placed on the ileo-pubic tract. We prefer to fix it with two absorbable staples totally, one medially to the Cooper ligament and one to the back of the transverse fascia (**Figure 6**). Tissue adhesives or absorbable suture materials may also be used for detection.

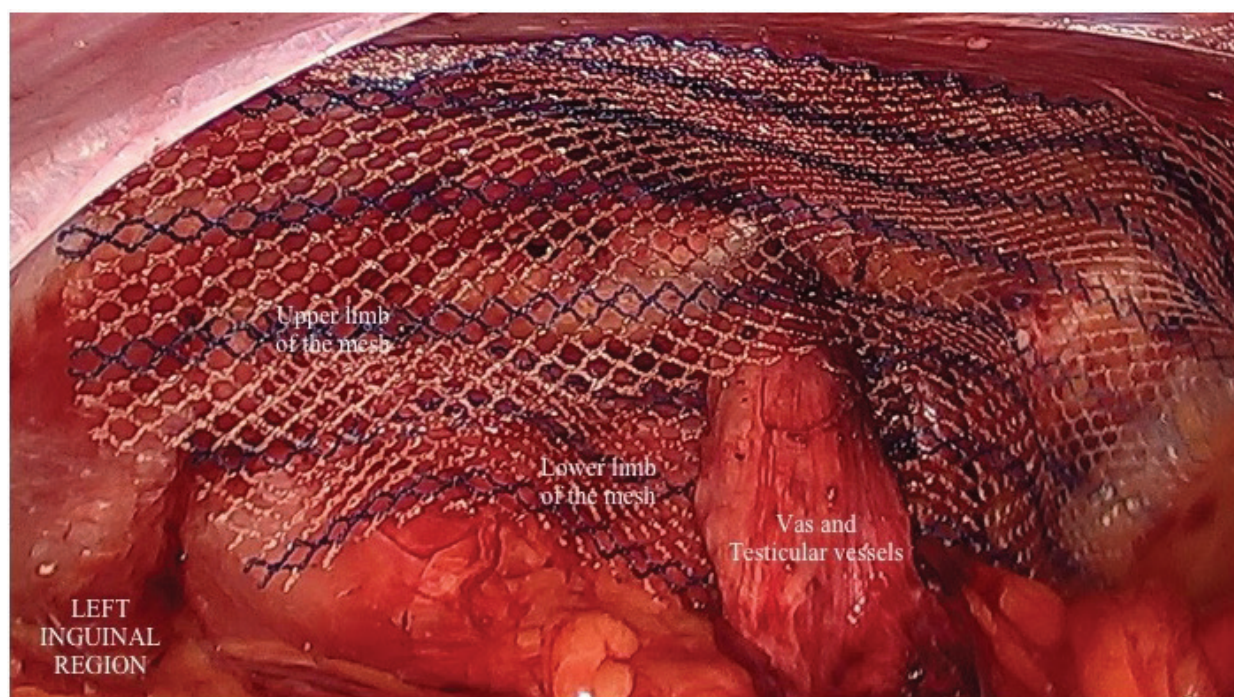


Figure 6. After mesh fixation in TAPP procedure.

8.7. Closure of peritoneum over mesh

After the integration of fixation, the upper and lower leaves of the peritoneum are covered on the patch and the opposite edges are closed with either continuous stitches or with clips. Closing the peritoneum with stitches is more convenient but requires more time and experience. The hernia sac, which is usually left in the lower peritoneal sheet and reduced into the peritoneum, can be left if it is small, also the larger sacs can be partially resected before closing the peritoneal leaves. According to experience and preference, a drain can be placed behind the peritoneal flap. After the peritoneum is closed, 5 mm ports are removed under direct vision and the operation is terminated.

8.8. Postoperative care

Oral intake can be started a few hours after surgery and the patient is mobilized the same evening. The following day the patient can be discharged by removal of the drain. There is no need to regulate postoperative medical treatment other than oral analgesics.

9. Laparoscopic total extraperitoneal approach

Despite discussions about the use of laparoscopy in the repair of primary unilateral groin hernias, the superiority of TEP in bilateral or recurrent hernias is accepted. The major advantages of this method are that it is extraperitoneal and there is no break in peritoneum. The

dominance of the anatomy of the posterior wall is not as good as TAPP, but sufficient parietalization is possible with TEP. Nowadays it becomes the first choice especially for athletes both men and women.

9.1. Operating room layout

The opposite side of the surgical field and both legs are in closed position. In bilateral hernia repair, both arms are in closed position. The videomonitor laparoscopy tower is placed on the patient's foot, on the side to be operated. The operator can be placed on the opposite side of the area to be operated and the camera assistant can be placed on the same side or opposite side of the surgeon depending on the experience and habits of the team. We prefer the camera assistant to sit on the same side of the surgeon.

9.2. Surgical supplies

Standard laparoscopic equipment consisting of a camera, a monitor, a light and an insufflator

- 10 mm diameter balloon trocar
- Laparoscope with a diameter of 10 mm and a 30° angle
- A 10 mm, two 5 mm diameter, totally 3 trocars
- Atraumatic clamps, endodissectors, endoscissors, endohooks, endoclamps, endoaspirators
- 5 mm diameter vessel sealing device
- 15 × 15 cm polypropylene or polyester special shaped patch
- Fixation material (mechanical staple or tissue adhesive)

9.3. Preparation of the patient, application of extraperitoneal trocars

A single dose of 1 g second-generation cephalosporin as prophylactic antibiotic is injected half an hour before the onset of operation. The patient should urinate before operation and pre-operative fluid resuscitation should be kept to a minimum. With general anesthesia, the operation starts in supine position. In method of TEP, the patient should be wider painted than the TAPP technique, from the nipple to the perineum. Infraumbilical, slightly lateralized incision is made on the hernia side and then the rectus sheath is opened by transverse incision. Rectus fibers are removed with Farabeuf retractor and blunt dissection is performed to reach the Bogros area. A tunnel is made between umbilicus to pubis. In front of this tunnel, there is a parietal peritoneum from the back of the rectus muscle and from the end of this fascia to the transverse course of the linea semilunaris. After blunt dissection and cannula is completely inserted from the preperitoneal tunnel to the pubis, it is removed from the trocar cannula and replaced with a telescope, and the cannula is inflated with a balloon attached to the mandrel. Air is discharged 20–25 times with pump after waiting for 30 s and this process is repeated three times. With some balloons, it is possible to view inside with scope as it inflates. It can also be monitored whether the definite surgical area is viewed during this observation. Upper view of rectus fibrils and lower view of parietal peritoneum indicates the

right position. A 10 mm trocar is placed in the infraumbilical incision to prevent gas leakage and the telescope is placed. The preperitoneal space is inflated with 10–12 mmHg CO₂. Two 5 mm ports are placed at a distance of 5 cm from the midline in direct view (**Figure 7**).

9.4. The dissection of extraperitoneal area and herniated sac

After the 30° camera is inserted, the inferior epigastric artery and vein are observed along the bottom of the rectus muscle. The parietal peritoneum is dissected in the medial and lateral directions to remain underneath. The Cooper ligament is visible in the inferomedial area and it is removed. The lateral aspect of the rectus is up to the border of the crista iliaca and the fascia transversalis is opened with blunt and sharp dissections posteriorly. The potential hernia areas are examined and the hernia type is determined (**Figure 8**). In the indirect inguinal hernia, the hernia sac is found adhered to the spermatic cord. The hernia sac should be dissected from the pubic tuberculum to the level of the external iliac vein. Large scrotal or indirect hernia may be released by Zig technique if it is confirmed that the hernia sac does not contain omentum or intestinal contents. The anatomic regions described as Femoral and Hasselbach triangles should be examined in terms of direct and femoral hernia that may be accompanied. The iliopectic tract must be detected not to injure the femoral and lateral femoral cutaneous nerves of the underlying genitofemoral nerve. The lateral dissection does not need to be as wide as the TAPP technique. The hernia sac should be gently released and reduced from the spermatic cord and cremaster fibers. If the peritoneum is wounded during the dissection procedure, the defect can be closed with a clip. If gas insufflation flows through the gap to the peritoneal defect, the enlarged abdomen will restrict the area of dissection. In order to prevent this, intraperitoneal air could be taken out from the upper left quadrant of the midclavicular line through the abdominal cavity (Palmer's point) with Veress needle. The valve is left open, the evacuation of the gas is provided and the operation can be continued.

9.5. Preparation, placement and detection of the mesh patch

Special shaped 15 × 15 cm polypropylene or polyester patch can be used according to the anatomy of the patient. The patch can be prepared with limb or without limb. It is rolled up

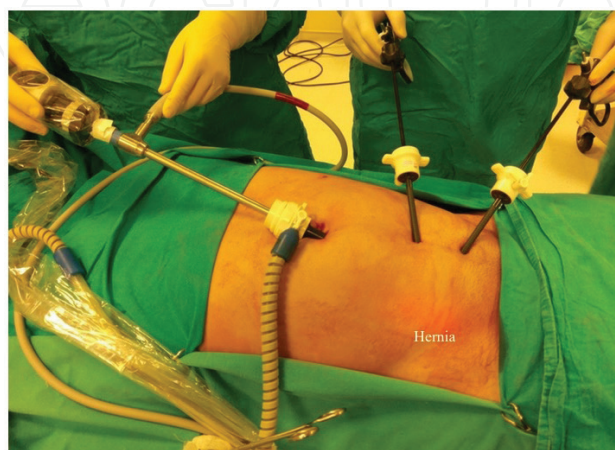


Figure 7. Trocar placement for TEP procedure.

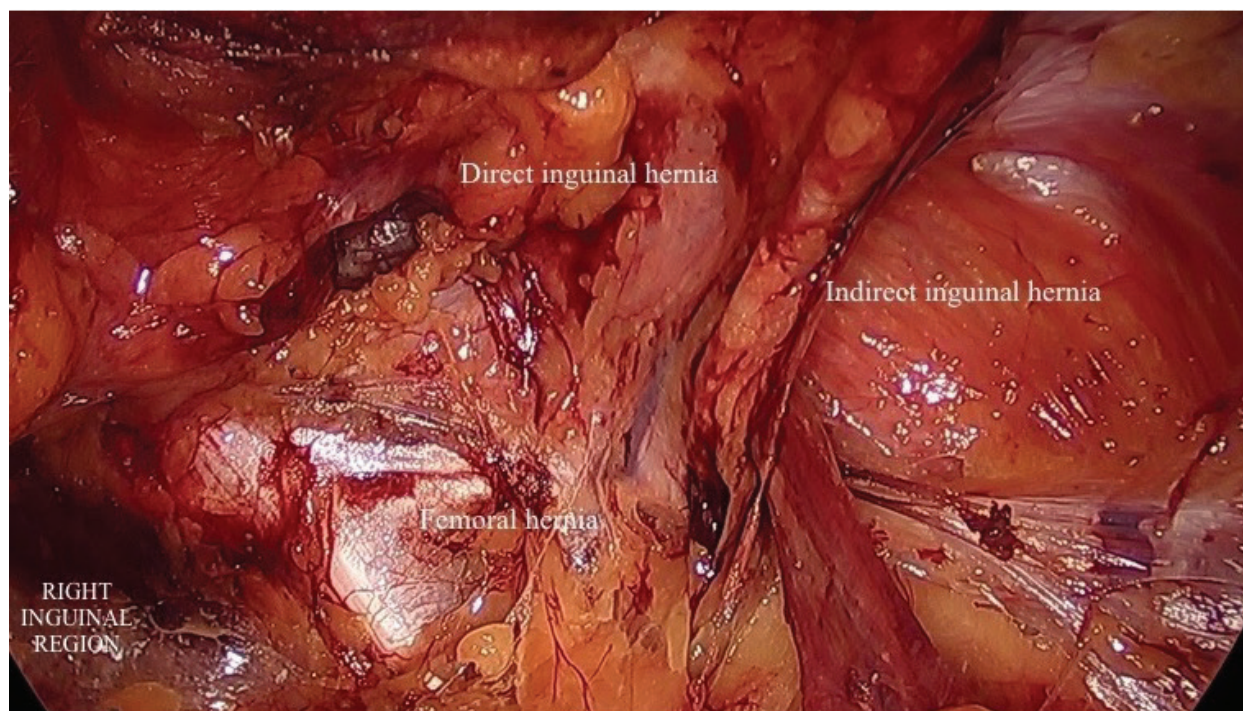


Figure 8. Potential hernia areas for TEP procedure.

from the top and laid to the extraperitoneal space by the 10 mm camera trocars. With the help of two endograspers placed in the working ports, the patch is unfolded in the opposite direction and is laid to cover the existing hernia defect and potential hernia areas. It should be ensured that the area where the patch is applied covers it with a proper tension. When a limb patch is applied, the lower limb is passed under the spermatic cord and it is wrapped in a tie and is laterally joined to the lower limb (**Figure 9**). The lower edge of the patch is placed so that it remains at least 2 cm above the released hernia sheath. The locations and numbers are very important if the absorbable staple is preferred for the detection of the mesh. The basic rule, with different suggestions about this, is that the mesh must be placed on the ileo-pubic tract. We prefer to fix it with a total of two absorptive staples, one medially to the Cooper ligament and one to the back of the transverse fascia laterally. On the lateral edge of the spermatic cord there are anatomical areas defined as the triangle of pain mentioned above and the death triangle at the medial border. Staples must be avoided in these areas. Tissue adhesives have also been used today as fixing material. The use of drains varies according to experience and habits. We routinely use aspirative drain after TEP.

9.6. Postoperative care

Oral intake can be started a few hours after surgery and the patient is mobilized the same evening. The following day the patient can be discharged by removal of the drain. There is no need to regulate postoperative medical treatment other than oral analgesics.

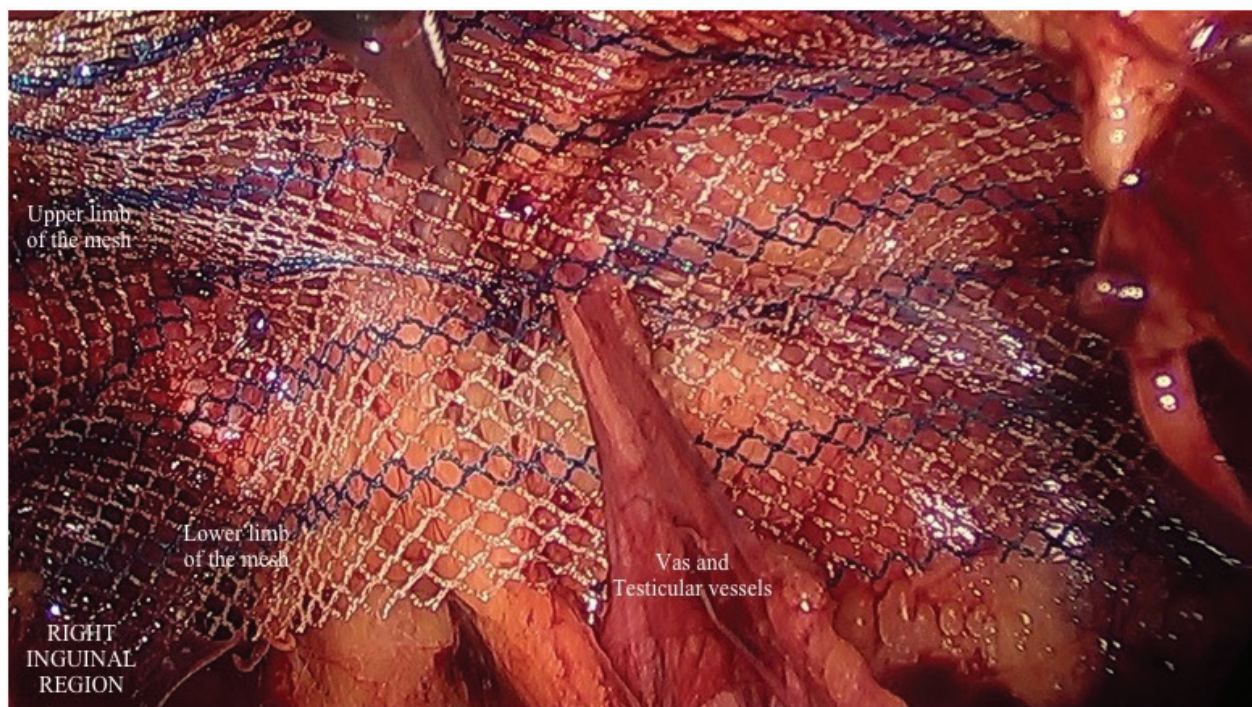


Figure 9. After mesh fixation.

10. Pitfalls

In this chapter, details take place as noted; details in current practice are given while applying the laparoscopic hernia repair. The points to be considered are evaluated for both techniques. In addition, the difficulties faced by the surgeon are itemized.

10.1. TAPP

- As all laparoscopic operations, the first point to note in laparoscopic hernia surgery is trocar entry sites. Correct positioning of the appropriate points will prevent intestinal injuries that may occur at the time of first entry and bleeding which may be caused by the injury of the abdominal wall, especially the epigastric vessels.
- A complete exploration should be done in terms of hernia type, size, presence of accompanying incarceration and other pathologies in intraabdominal exploration.
- Taking enough width for dissection during the preparation of the peritoneal flap will ensure that the exploration area is convenient. Working on a sufficient width of dissection will facilitate the spread of the patch, the adequate closure of the hernia defect and the operator's work during the detection of the patch.
- A very careful dissection should be performed in order to avoid damage to the spermatic cord structures, especially in the presence of indirect hernia, when the hernia incision is

dissected, as interference with the anatomical planes may result in attempts made for recurrent hernia.

- Should be very careful not to hold Vas Deferens by endo-devices so as to not disturb.
- The dissection should be performed at an adequate width of the myopectinale opening, but should be avoided from the extreme dissection in front of the psoas site in the lateral direction. There is an anatomic area defined as triangular pain in this region and it should be especially noted that the cutaneous femoral lateralis and femoral branches of genitofemoral nerves are not damaged. Postoperative chronic pain syndromes can be encountered in the event of a possible nerve injury.
- Death triangle is defined as the anastomotic area between the external iliac vein and the obturator vein and should be avoided from the extreme dissection. Because, in the event of a possible vascular injury in this region, catastrophic consequences may be encountered.
- The staples used for patch fixation due to the same reasons should never be used under the iliopubic tract.
- Should be sure to place the staples on the medial side, especially on the Cooper ligament, so that postoperative osteitis pubis is avoided.
- It is generally advised to use the least amount of other materials that can be used for stapling or patch fixation.
- Wide laying of the mesh will reduce the recurrence rate by covering the three hernia areas.
- Reducing the intraabdominal CO₂ pressure during the peritoneal flap closure and correcting the patient's position will facilitate closure because it will reduce tension. The effective closing of the flap is important to prevent postoperative intestinal adhesions.

10.2. TEP

- The infraumbilical incision should be made from slightly left or right lateral. What should be noted here is to be on the rectus front sheath. If the linea alba is opened by mistake, the gas will flow to the intraabdominal region and strengthen the technique at the start.
- It is important to notice the bright white color of the rectus posterior sheath, and it is important that the balloon is inflated by advancing the balloon trocar in this space. The balloon dissection between the fibers of the rectus will cause bleeding between the muscle fibers, disturbing the dissection plans and preventing the vision.
- If gas flows into the abdomen during possible peritoneal injuries in the TEP technique, as mentioned in the techniques section, the gas must be evacuated with the Veress needle, which will be entered from the Palmer point.
- Large peritoneal defects may cause postoperative patchy contact with the intestines and lead to postoperative intestinal adhesion development. For this reason, large peritoneal defects should be closed with endoclips.

11. Complications and management

In this section, complications related to laparoscopic inguinal hernia surgery, literature information about management of these complications and suggestions based on our own experience are included.

11.1. Local complications

The most common complications are serous fluid deposits (seroma) and bleeding (hematoma) which may develop during operation. Patients should be informed in the preoperative period about these complications. Postoperative seromas usually resorb spontaneously within 2 weeks and do not require treatment. Therapeutic drainage needs arise in the presence of seroma persistent for longer than 6–8 weeks or in the presence of seroma causing clinical symptoms. The use of peroperative aspirative drains in risky patients of who may be predicted seroma and hematoma development may prevent the development of these complications. Scrotal elevation is recommended in the postoperative period. If abdominal wall ecchymosis occur, mechanical compression, cold application and medical treatment can be tried. Subcutaneous emphysema is often untreated and spontaneous. In rare occasional hydrocele cases, it will be more appropriate to consult with a urologist.

11.2. Neurological complications

The treatment of chronic pain syndromes after laparoscopic hernia surgery is often long and difficult. Chronic postoperative pain has been reported in up to 63% of all groin repairs and significantly affects clinical outcomes. The pain following laparoscopic surgery is usually neuropathic pain. The cause is usually the damage or trapping of the lateral femoral cutaneous or femoral branch of the genitofemoral nerve. Clinically it occurs as acute burning and/or crushing pain in a particular dermatome. Mareljia parestetika is the name of a pain clinic that develops after a lateral femoral cutaneous nerve injury and persistent paresthesia lateral of the femoral area. It is recommended to apply corticosteroids or anesthetic injections which can be applied at rest, cold application, NSAIDs, physical therapy, locally. Osteitis pubis is; the name of the pain clinic that occurs due to pubic inflammation and arises especially on the middle of the groin or on the pubis, especially with femoral adduction. Diagnosis can be made by excluding recurrent hernia diagnosis radiographically and performing bone imaging. The treatment approach is the same as neuropathic pain. Often, 6 months are required to respond to treatment. However, if the cure is not available, the orthopedic consultation may be needed to consider possible bone resection or curettage options.

11.3. Cord and testicular injury

Ischemic orchitis should be considered in the complaints of hardened, enlarged and painful testicles that appear about 10 days after the repair of the inguinal hernia. It is often self-limiting. It is usually the result of a possible damage to the pampiniform plexus, not the testicular artery. Ultrasound can distinguish necrosis or ischemia. If testicular necrosis is detected,

urgent orchiectomy may be necessary. Treatment includes IV hydration and NSAIDs. If testicular artery is damaged, it can be caused testicular atrophy after long periods of operation. Vas deferens may not be manipulated during surgery and maximum effort to avoid disturbing their nutrition may help to avoid these complications.

11.4. Recurrents

Postoperative pain, swelling and the presence of a mass in the inguinal region should be considered. Diagnosis can be made by radiological examinations. Technical factors that play a role in the development of recurrence include inappropriate patch size, inadequate patch, stress or inaccurate detection, lack of experience, tissue ischemia and infections. Factors related to the patient include malnutrition, obesity, wound healing disorders and uncontrolled diabetes mellitus. Surgical intervention should be considered in the treatment.

Other complications include urinary retention, which can be prevented by the patient's urination before surgery or by preoperative urinary catheterization. Paralytic ileus, visceral injuries, vascular injuries, intestinal obstruction, hypercapnia, pneumothorax and gas embolism are also uncommon complications.

12. Literature review

The results of laparoscopic and open inguinal hernia surgeries are now being compared very much. Postoperative pain complications, recurrence rates, patient satisfaction, cost analysis are frequently discussed. Papachariston and colleagues in their postoperative evaluation of pain study [8], even though it was reported to require more analgesic in the first 6 h in the TAPP group, pain was reported in 2–11% of the open surgery group and reported as 1–4.2% in the laparoscopic group. In the same study, persistent pain lasting from seventh day to 1 year in the open surgical group was associated with postoperative fibrosis, while point pain in the laparoscopic group was associated with scar tissue rupture. In a meta-analysis evaluating persistent pain [9], patch repair has been shown to reduce persistent pain as opposed to pain relief, and it has also been found that chronic pain is less in the laparoscopic method.

In a study in which approximately 10,000 patient outcomes were assessed in the United States and patients were followed for 3 years [10], the recurrence rate of the laparoscopic method was found to be 0.4%, and it was emphasized that the most important difference between open and laparoscopic operations was the achievement of sufficient experimentation, the number of operations performed. According to this recommendation, a randomized controlled trial conducted by the Veterans Affairs Cooperative Study and reporting of 2-year follow-ups [11], recurrence rates were reported as 10% for laparoscopic repair and 5% for open repair, but after 250 laparoscopic cases techniques, results were improved. In a more recent study, Lal et al. [12] has shown that surgeons have reduced recurrence rates from 9 to 2.9% after 100 operations. In different studies, it has been reported that the laparoscopic techniques are spreading and the time to assess the competence of the surgeons is between 50 and

100 cases. A meta-analysis by Köckerling et al. [13] evaluating the relationship between patch fixation and recurrence, cases that patch fixation was performed and in cases not performed, there was no difference in the duration of operation, patch-related complications, recurrence and duration of hospital stay.

In a randomized controlled meta-analysis in which Wei and colleagues evaluated the outcomes of 1000 patients published in 2015, there was no difference between the two surgeries, pain score, operation time, return to daily activity, hospitalization time, complication and cost between the two surgeries. In conclusion, TEP was found to be more complicated than TAPP and advised to start laparoscopic surgery with TAPP to inexperienced surgeons [14]. In a study published by Köckerling et al. [15] there was no difference between two surgeries in terms of intraoperative complications and reoperation rates. However, after TAPP surgery, complication rates were found to be higher due to possible large complications, more scrotal hernia, elderly patient selection.

In a study conducted by Payne et al. [16] to measure postoperative quality of life, it has been shown that patients' compliance with straight leg exercises is better after laparoscopic surgery. Designed in the same way and studied by Lawrence et al. [17], this difference was more evident in bilateral hernia repair.

The problem of cost is still an important problem, with the fact that it has been removed from the big picture compared to the past. In the study conducted by Stylopoulos et al. [18] in 2003 and the results of 1.5 million patients evaluated, laparoscopic operations have been claimed to reduce costs compared to long-term open surgery when salary, health insurance costs, reduced job quality, delayed work shifts and the salary of the worker looking after the patient are taken into consideration. Farinas et al. [19] showed that 60% reduction in indirect costs could be achieved despite the 40% increase in the direct costs of using non-disposable devices and shortening of the operation time.

When TEP and TAPP were compared, there was no difference between the two techniques in terms of hospitalization time, recovery time and short term recurrence rates. The duration of the TEP technique is shorter than that of the TAPP technique [20]. However, according to the International Endohernia Association, it has been suggested that surgeons should apply the TEP technique after learning the TAPP technique and acquiring a certain experience in the learning curve [21].

In our study, we have found that there is only a minimal difference between TAPP and TEP techniques, in terms of operative time. There was no difference in both techniques when recurrence, return to work, pain score, duration of hospitalization and complications were evaluated. Particularly, we observed that bilateral and recurrent hernia had high patient satisfaction. Also we observed that TAPP surgery in the early stages of surgery, shortened the learning curve.

In conclusion, laparoscopic inguinal hernia surgery takes place in daily practice as an increasingly widespread up-to-date treatment method in which training and experience gained over time and patient satisfaction of clinical outcomes are very good.

Conflict of interest

The authors declare that they have no conflict of interest.

Author details

Fatih Altintoprak^{1*}, Emrah Akin², Kemal Gundogdu² and Enis Dikicier¹

*Address all correspondence to: fatihaltintoprak@yahoo.com

1 Istinye University Faculty of Medicine, Department of General Surgery, Istanbul, Turkey

2 Sakarya University Research and Educational Hospital, Department of General Surgery, Sakarya, Turkey

References

- [1] Wagner JP, Brunicaudi CF, Amid PK. Inguinal Hernias Schwartz's Principles of Surgery. 10th ed. In: Brunicaudi CF, editor. New York: In chief. McGraw Hill publishing; 2016. pp. 1510-1517
- [2] Mark A, Malangoni M and Michael J. Densen Hernias Sabiston Textbook of Surgery: The biological basis of modern surgical practice 19th ed. In: Townsend CM, Beauchamp RD, Evers BM, Mattox KL, editors. London: Saunders publishing; 2012. pp. 1114-1141
- [3] Van Hee R. History of inguinal hernia repair. *Turnalul de Chirurgie*. 2011;**73**:301-314
- [4] Sachs M, Damm M, Enche A. Historical evaluation of inguinal hernia repair. *World Journal of Surgery*. 1997;**21**(2):218-223
- [5] Bianutto SN, Repetto E, Aliendo MM, Borginho VW. Inguinal canal development: The muscular wall and the role of the gubernaculum. *Clinical Anatomy*. 2009;**22**(5):614-618. DOI: 10.1002/ca.20820
- [6] Rosenberger RT, Loewneck H, Meyer G. The cutaneous nerves encountered during laparoscopic repair of inguinal hernia: New anatomical findings for the surgeon. *Surgical Endoscopy*. 2000;**14**(8):731-735
- [7] Brittner R, Montgomery MA, Arregui, et al. Erratum to: Update of guidelines on laparoscopic(TAPP)and endoscopic(TEP) treatment of inguinal hernia (International Endohernia society). *Surgical Endoscopy*. 2015;**29**(6):1655-1656. DOI: 10.1007/s00464-015-4156-3
- [8] Papachariston EA, Mitselou MF, Finokaliotis ND. Surgical outcome and hospital cost analysis of laparoscopic and open tension free hernia repair hernia. 2002;**6**(2):68-72. PMID:12152642

- [9] EU Hernia trialists Colloboration. Repair of groin hernia with synthetic mesh: Meta analysis of randomized controlled trials. *Annals of Surgery*. 2002;**235**(3):322-332. PMID:118 82753
- [10] Felix EL, Harbestson N, Vartanian S. Laparoscopic hernioplasty; significant complications. *Surgical Endoscopy*. 1998 Apr;**13**(4):328-331. PMID:10094740
- [11] Neumayer L, Giobbie-Hurder A, Jonasson A, et al. Veterans cooperative studies program 456 investigators. Open mesh versus laparoscopic mesh repair of inguinal hernia. *The New England Journal of Medicine*. 2004;**350**(18):1819-1827. DOI: 10.1056/NEJMoa 040093
- [12] Lal P, Kajla RK, Chander J, et al. Laparoscopic total extraperitoneal (TEP) inguinal hernia repair: Overcoming the learning curve. *Surgical Endoscopy*. 2004;**18**(4):642-645. Epub 2004. DOI: 10.1007/s00464-002-8649-5
- [13] Köckerling F, Jacob DA, Chowbey P, et al. A meta-anlysis examining the use of tucker fixation versus no-fixation of mesh in laparoscopic inguinal hernia repair. *International Journal of Surgery*. 2012;**10**(6):325. DOI: 10.1016/J.ijssu. 2012.04.014
- [14] Fx W, Zhang YC, Han W, et al. Transabdominal preperitoneal (TAPP) versus totally extra-peritoneal (TEP) for laparoscopic hernia repair: A meta-analysis. *Surgical Laparoscopy, Endoscopy and Percutaneous Techniques*. 2015;**25**(5):375-383. DOI: 10.1097/SLE. 0000000000000123
- [15] Köckerling F, Bittner R, Jacob DA. TEP versus TAPP: Comparision of the perioperative outcome in 17.587 patients with a primary inguinal hernia. *Surgical Endoscopy*. 2015;**39**(12):3750-3760. DOI: 10.1007/s00464-015-4150-9
- [16] Payne JH, Grininger LM, Izawa WT, et al. Laparoscopic or open inguinal hernioraphy? A randomized prospective trial. *Archives of Surgery*. 1994;**129**(9):973-979. PMID:8080380
- [17] Lawrence K, Mc Whinnie D, Goodwin A, et al. Randomized controlled trial of laparoscopic versus open repair of inguinal hernia: Early results, *BMJ*. 1995;**311**(701):981-985. PMID:7583639
- [18] Stylopoulos N, Gazelle GS, Rattner DW, et al. A cost-utility analysis of treatment options for inguinal hernia in 1,513,008 adult patients, *Surgical Endoscopy*. 2003;**17**:180-189. DOI: 10.1007/900464-002-8849-z
- [19] Farinas LP, Griffin FD. Cost containment and totally extraperitoneal laparoscopic herni-orrhaphy. *Surgical Endoscopy*. 2000;**14**(1):37-40. PMID:10653233
- [20] Qiu K, Ma J. Comments on TAPP versus TEP for laparoscopic hernia repair: A meta-analysis. *Surgical Laparoscopy Endoscopy and Percutaneous Techniques*. 2016;**26**(2):171. DOI: 10.1097/SLE.0000000000000251
- [21] Bittner R, Köckerling F. Endorsement of the hernia surgical guidelines by the International Endohernia Society. *Hernia*. 2018;**22**(1):179. DOI: 10.1007/s10029-017-1674-z

