

We are IntechOpen, the world's leading publisher of Open Access books Built by scientists, for scientists

6,900

Open access books available

186,000

International authors and editors

200M

Downloads

Our authors are among the

154

Countries delivered to

TOP 1%

most cited scientists

12.2%

Contributors from top 500 universities



WEB OF SCIENCE™

Selection of our books indexed in the Book Citation Index
in Web of Science™ Core Collection (BKCI)

Interested in publishing with us?
Contact book.department@intechopen.com

Numbers displayed above are based on latest data collected.
For more information visit www.intechopen.com



Complications of Total Hip Replacement

Chang Park and Irfan Merchant

Additional information is available at the end of the chapter

<http://dx.doi.org/10.5772/intechopen.76574>

Abstract

Total hip replacement is a highly effective surgical procedure for patients suffering from end stage osteoarthritis and its success in improving symptoms of osteoarthritis has meant that its use has increased across many healthcare systems. Although in experienced hands the procedure provides very effective outcomes one must be aware of the potential complications of the procedure. These can be divided into general and procedure specific. General complications include infections, postoperative pulmonary issues and thromboembolic complications. Procedural specific complications include a surgical site infection, haemorrhage, nerve injury, dislocation, leg length discrepancy, periprosthetic fractures and heterotrophic ossification. This chapter explores and describes the complications a surgeon may face when performing a total hip replacement and how one may avoid and address these.

Keywords: complication, hip, arthroplasty

1. Introduction

Total hip replacement is a highly effective surgical procedure for patients suffering from end stage osteoarthritis [1]. Its success in improving pain, mobility and quality of life for patients has meant its use has increased since its introduction [2, 3].

As like any surgical procedure however, total hip replacements have associated surgical complications. Thanks to advances in technology, surgical awareness and anaesthetic techniques the overall rates of complications have been declining despite an increasing burden of comorbidities in the population [4]. The complications encountered can be divided into general and procedure specific. This chapter will explore both aspects of complications that the surgeon may encounter when performing total hip replacements.

2. General complications

2.1. Urinary tract infection

Urinary tract infections represent an approximately 13% of all healthcare-associated infection [5] and in the context of post total hip replacement is seen to be the most common minor postoperative complication [6]. The estimated rates of postoperative urinary tract infections are at 3.26 [7]. Risk factors for the development of a urinary tract infection include female sex, increased age, ASA 3 or higher and the use of a general anaesthetic [6]. Of these in a recent multicentre study by Alvarez et al., increased age followed by female sex was the strongest variable in developing a postoperative urinary tract infection. As with respiratory tract infections to be discussed in the next section, urinary tract infection in the postoperative setting following total hip replacements have been linked to more significant adverse effects such as peri-prosthetic infections, implant failure and revision procedures along with the immediate prolonged hospital stay [8].

2.2. Postoperative pulmonary complications

Postoperative pulmonary complications are common after major surgeries and are defined as a collective of respiratory failure, pneumonia, pleural effusion, atelectasis, pneumothorax and aspiration pneumonia [9]. Postoperative pulmonary complications are a common complication after total hip replacement with 45.9% patients having some form of postoperative pulmonary complications on postoperative CT screening [10]. The symptoms of any postoperative pulmonary complication can vary greatly with many atelectasis following general anaesthesia being asymptomatic but as like urinary tract infections can cause more serious complications along with increased length of stay. The rate of in-patient pneumonia following total hip replacement is estimated to be between 0.74 and 0.86% [7].

2.3. Thromboembolic complications

2.3.1. Deep vein thrombosis

Deep vein thrombosis is a common complication following total hip replacements due to the venous stasis and hypercoagulability experienced both during and subsequent to the procedure, adversely influencing Virchow's triad towards a state of thrombus formation [11]. The subsequent results of deep vein thrombosis can vary from asymptomatic, chronic venous insufficiency and proximal propagation. Without the use of any prophylaxis the overall radiological diagnosed rates of deep vein thrombosis has been as high as 70% in total hip replacement cases [12].

With the introduction of modern thromboprophylaxis the overall rates of deep vein thrombosis has reduced to approximately 44% and in those that are symptomatic as low as 1.3% [13, 14]. Thankfully with prophylactic treatment the rate of symptomatic proximal propagation to form a pulmonary embolus is lower still at less than 0.6% [15].

Although half of patient who develop a deep vein thrombosis post total hip replacement have no identifiable risk factor there are numerous well recorded risk factors that alter Virchow's triad towards a state of thrombus formation [16]. These include associated fracture, malignancy, previous history of thromboembolism, immobility, obesity, pro-thrombotic conditions such as anti-phospholipid syndrome and the use of oral contraceptive pills. Furthermore an ASA grade of greater than 3 is an independent risk factor [16].

The prophylaxis for deep vein thrombosis is aimed at returning the pro-thrombotic state into equilibrium by adjusting the parameters of Virchow's triad. This is done by treating the stasis of flow in the lower limbs both by mechanical thromboprophylaxis but also by the choice of anaesthetic used. A regional anaesthetic has been shown to reduce the risks of deep vein thrombosis over that of general anaesthetic by 50% alone due to the relative improvement in the flow of venous blood in the lower limbs [17]. Furthermore chemical thromboprophylaxis can be used to reverse the hypercoagulability. Various agents are used for chemical thromboprophylaxis but include low molecular weight heparin and more recently oral factor Xa inhibitors. Mechanical and chemical prophylaxis are utilised both intra and postoperatively to reduce the overall risk of deep vein thrombosis.

2.3.2. *Pulmonary embolism*

Deep vein thrombosis has a risk of propagating proximally through the right sided cardiac circulation into the pulmonary system. If the thrombus passes into the lungs they result in pulmonary embolisms. The results of these pulmonary embolisms can vary from being asymptomatic to caused catastrophic respiratory failure and can be fatal and pulmonary embolus being one of the leading causes of mortality post total hip replacements. The overall rates of postoperative total hip replacements are 3% in the absence of chemical prophylaxis [15], and 0.21% when chemical prophylaxis is used from a recent large review [18]. The prevention of pulmonary embolism lies primarily in the prevention of deep vein thrombosis discussed in the previous section. The treatment of established pulmonary embolisms are by the use of therapeutic agents to inhibit the pro-thrombotic cascade and profibrinolytic agents to dissolve away the embolus.

2.3.3. *Fat embolism*

In the same way that a deep vein thrombus can pass into the pulmonary circulation, at the time of implant insertion the rise of intramedullary pressure from the prosthesis and cement can cause the embolization of medullary fat and marrow contents into the venous system [19, 20]. If the fat or marrow then passes into the pulmonary circulation in can pass in the pulmonary arteries in the same way as a venous thrombus causing much the same issues. These bodies of fat can also pass into the left sided circulation and cause cerebral embolisms and infarction causing neurological deficits [21]. By the same pattern the fat bodies can cause infarcts in the systemic circulation in tissues causing a classic upper body petechiae. As such the classic symptomatic triad of fat embolism is respiratory distress, neurological symptoms and upper body petechiae. To avoid such complications the intra-medullary canal is lavage

cleaned prior to implant insertion to reduce the fat content. The treatment of fat embolism is supportive principally for the symptoms of respiratory compromise [22].

3. Procedure-specific complications

3.1. Surgical site infection

Surgical site infections can be classified as that of superficial and deep. Whereas superficial infections can be a nuisance and cause prolonged hospital stays and increased morbidity for patients and potential for wound dehiscence the sequelae of deep infection post total hip replacement can be catastrophic and challenging for the clinician to manage.

At the advent of its introduction the deep infection rates for total hip replacements were recorded to be as high as 9.4% [23]. However in modern practice with the widespread adoption of laminar flow operating theatres and prophylaxis antibiotics the current rates of deep infection are at between 0.3 and 1.5% [24, 25].

The prevention of deep infection is principally reducing the contamination of the surgical site from contaminants. These contaminants can arise from the patient's skin, the surgical personnel or the surgical instruments [26]. The use of laminar flow air circulation in theatres and the adaptation of rigorous sterile techniques and practices in the operating room is now standard practice to reduce the contamination of the surgical site. However despite these best practice the reality is that all surgical wounds are contaminated and even the most thorough of skin preparation will not decontaminate the micro-organisms in the deeper layers of the skin and the efficacy of laminar air flow can be easily influence by a variety of factors in the operating room [27–29].

As the contamination of the surgical site cannot be fully eliminated the use of prophylaxis antibiotics is standard practice with recognised benefits to reduce the risk of deep infection [30, 31]. The use of prophylaxis antibiotics in total hip replacements have been shown to reduce the absolute risk of infection by 81% [32]. Such use of prophylaxis antibiotics is not without its risks however and include both the direct side effects of its use but also the increasing concern of resistance. As such the choice of antibiotics is best directed by local protocols and guidelines and currently there is no clear consensus on the best regime [32].

Despite the effort to reduce the rates of deep infections however they do still occur and the diagnosis of a deep infection can be clinically challenging. The principal symptom is hip pain, but this along with more systemic symptoms such as fever, malaise and rigours are very variable. Further the clinical examination may show signs of local inflammatory changes along with reduced range of motion within the hip joint.

Biochemical marks such as CRP and ESR are widely used. However in the both markers are non-specific and can be elevated in the presence of any concurrent inflammatory process. In the absence of any concurrent conditions that may increase their levels the a CRP of greater than 10 mg/l has a sensitivity and specificity of 96 and 92% and an ESR of over 30 mm/h that of 82 and 85% [33].

Radiological investigations can aid the diagnosis with signs of osteopaenia and osteolysis however there is no clear way to distinguish these from aseptic loosening on plain radiographs alone. Radionuclide scanning can identify areas of increased bone turnover and inflammatory foci and are more sensitive and specific to deep infection. More specialist radiological investigations such as labelled white cell scans and immunoglobulin scans and modern PET scanning techniques are more sensitive and specific still, at 85.5 and 92.6% respectively for PET scans, but the availability remains challenging [34, 35].

Cytological and microbiological analysed sample can give both diagnostic information on the presence of infection but also the causative organism. Done radiologically under sterile conditions, a guided aspirate has been shown to have a sensitivity and specificity of 82 and 91% [36]. A surgically performed procedure allows the concurrent washout of the surgical site to furthermore reduce the organism load. Any such sample however should be taken with 2 weeks of antibiotic cleared time to avoid any false negative findings.

The treatment of deep infection in total hip replacement is based on the principles of eradication of infection and restoration of function [37]. If deep infection occurs in the acute period, in the first 2 weeks, then component retention may be possible with thorough debridement and antibiotic treatment. However such this only results in clearance of infection in 50–74% of patients [38]. More often the presence of deep infection requires a full revision of the total hip replacement. This can be performed as either a single or two stage procedure. A single stage procedure is the removal of the prosthesis with thorough clearance of the infection with the implantation of a new prosthesis and subsequent antibiotics therapy. This differs to that of a two stage procedure whereby the first stage is the removal of the infected prosthesis, soft tissue debridement and the insertion of an antibiotic loaded spacer. After an interval of approximately 6 weeks of antibiotic therapy and the patient undergoes a second stage procedure with the insertion of a new prosthesis [39, 40]. The benefits of a single stage procedure are that of reduced operative morbidity however the results of successful treatment of the infection is consistently better with a two stage procedure at 87–94% [41] (**Figure 1**).

3.2. Haemorrhage

Haemorrhage can be classified into intraoperative haemorrhage and postoperative. Arthroplasty surgery is associated with significant levels of haemorrhage and a relatively high demand of blood transfusion [42, 43]. Haemorrhage that is deemed to be clinically significant is difficult to determine and varies between clinician, centres and trials. One large multi-centred study defines important haemorrhage to be as *“bleeding that is recorded by the surgeon as being outside the range of ‘typical expected levels’ of bleeding following THA/TKA, or bleeding that is cited as the cause of prolonged hospital stay”* [44]. Rates of intraoperative haemorrhage vary from 2 to 3.6 unit [44–47]. Risk factors for increased intraoperative haemorrhage rates include increased operative time, with one study demonstrating a 1 min increase in operative time resulting in a 1.552 ml increase in intraoperative bleeding in total hip replacements [48]. Low and high BMI has been both associated with increased risk of haemorrhage [49, 50].

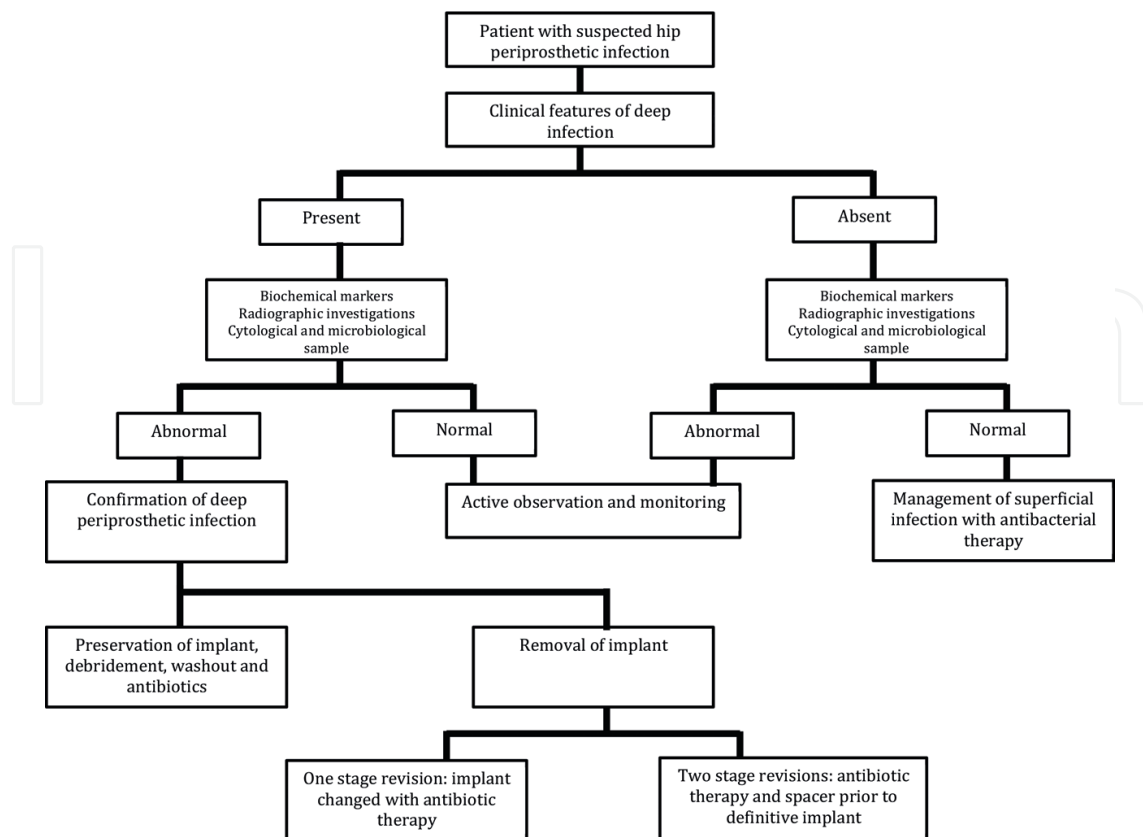


Figure 1. Management algorithm of peri-prosthetic infection.

Due to the high rates of intraoperative haemorrhage total hip replacement has a high rate of transfusion requirements. Median volume of allogenic transfusions in total hip replacements is 2 units [46, 47]. Autologous transfusion is also extensively used in total hip replacements with estimates at 20–80% of all total hip replacement patients requiring an allogenic transfusion [51–57]. When autologous transfusion is used the rates of requiring only autologous transfusions vary from 49 to 79% [47, 58–61]. Risk factors for intraoperative blood transfusion are low preoperative Hb, high age, female gender, large estimated volume of intraoperative blood loss and American Society of Anesthesiologists score of more than 2 [49, 62].

The risks of allogenic transfusions have been widely reported to include disease transmission, haemolytic reactions, fluid and haemodynamic overload, acute lung injury, coagulopathy, febrile non-haemolytic reactions as well as the a potential increased length of hospital stay and the financial cost [54, 63–65]. Various methods of blood management interventions are utilised to reduce the rates of autologous blood transfusions to include correcting any preoperative anaemia, ceasing antiplatelet and anticoagulant medications, intraoperative cell salvage and autologous transfusions and the use tranexamic acid [66–68].

Tranexamic acid in particular has been widely adopted as an agent to reduce intraoperative haemorrhage. As a synthetic lysine analogue tranexamic acid acts as an antifibrolytic agent by inhibiting plasminogen to plasmin and therefore delays the breakdown of fibrin containing blood clots. Studies have shown that the administration of tranexamic acid has reduced the proportion of patients requiring allogenic blood transfusions but not increasing the rates of complications including thromboembolic events and renal failure [68, 69].

3.3. Nerve injury

The incidence of nerve injury following a total hip replacement is approximately between 0.05 and 1.9% [70]. Damage to the sciatic and femoral nerve is most common, accounting for 79 and 13% respectively, with combined nerve palsy occurring in 5.8% cases. Obturator nerve palsies are more rare, occurring in 1.6% of cases [71].

Risk factors for nerve injury include revision surgery, female sex and developmental dysplasia of hip or acetabulum [72, 73]. The most common cause of nerve injury in total hip replacement is of unknown aetiology at 47%. Other recognised causes are iatrogenic with damage during the operative approach, though direct laceration is rare at 1%, or due to the mechanical effects of limb lengthening and offset mismatch [74]. If cement is used then the direct pressure effect or thermal injury can cause damage to the nerve. Haematoma formation can cause damage to the nerve and therefore meticulous haemostasis is important [72, 75].

There is no difference in the incidence of nerve palsy between the direct lateral or posterior approach [76]. When the sciatic nerve is affected it is usually the peroneal component, as it is more susceptible to traction and trauma [72]. Femoral nerve palsy is less common and is usually the result of direct compression intraoperatively by the retraction of soft tissues by surgical instruments.

Management of nerve injury can be challenging. The surgeon must ensure that the appropriate radiological imaging, usually an ultrasound to exclude a haematoma and possibly an MRI, is performed to exclude a reversible cause of injury and also other causes not related to the surgical intervention. Nerve conduction studies may be of benefit to assess the level and degree of injury. If the limb has been lengthened and there are no other causes of the injury identified, the leg length can be addressed to reduce the stretch of the sciatic nerve. If a haematoma is confirmed this may be an indication for surgery if symptoms do not resolve [72, 77–79]. However as most causes of nerve injuries are of unknown aetiology, generally in the absence of a clear cause, conservative management is advocated for a postoperative neuritis in a multi-disciplinary approach to ensure that all other causes of nerve injuries are excluded [80–82]. In this manner, one would ensure close observation and follow-up to ensure gradual improvement in function.

3.4. Dislocation

The rate of hip dislocations can range from 0.2 to 10% with 2% of patients dislocation within 1 year of their operation [83]. Of those who dislocate their total hip replacement, approximately one third will go on to have recurrent dislocations [84]. Risk factors are multifactorial and divided into patient, surgery and implant related.

3.4.1. Patient related factors

Cognitive disorders such as cerebral palsy, muscular dystrophy, dementia, advanced age and impaired compliance have showed increased chances of hip dislocations. Patients should avoid movements such as bending forward from a standing position or internal rotation of a flexed hip [76, 83]. Previous hip surgery have also shown to double the risk of dislocations [85].

3.4.2. *Surgical risk factors*

Surgical risk factors for dislocation of total hip replacements include the surgical approach, soft tissue tension, component design and orientation and surgeon experience. The majority dislocations occur posteriorly and therefore the posterior approach has the highest risk of dislocation. It has been documented in the literature a rate of 5.8% for the posterior approach in comparison to 2.3% for the anterolateral approach [85]. However recent research showing patients that have had a posterior capsular and external rotator repair have comparable rates to other approaches [76].

Implant alignment during hip replacement surgery is very important for stability of the joint. 'Safe zones' for acetabular cup position are defined as an abduction angle of 40 ± 10 degrees and anteversion of 15 ± 10 degrees, first defined by 6 in 1978 [86]. Recent studies have shown that although this range can be a useful guide to acetabular position, stability of a total hip replacement is multifactorial and should be assessed on an individual basis and therefore the 'Safe Zone' for a particular patient may lie outside this range [87].

3.4.3. *Implant related factors*

Component position and design can both influence the risk of dislocation. Head to neck ratio is very important for stability of the prosthesis and to allow a free range of movement without impingement. Larger femoral heads also allow a wide a mechanical range of motion when compare it to smaller head diameters [88]. In addition to this a larger femoral head has to move a greater distance away from the centre of the acetabular component before it can dislocate (jumping distance) therefore protecting against dislocation.

3.4.4. *Management*

Dislocations are initially managed by closed reduction in the majority of cases. In practice it is commonly seen that these patients are placed in an abduction brace though there is little evidence to support their use [76]. Patients who have recurrent or irreducible dislocations with correctly positioned components, can be managed with restrained liners. This has become a relatively more recent method of treatment that can be complicated with the increase risk of restricted range of movement due to impingement, osteolysis due to wear debris or early acetabular loosening. These should be used if a cause for instability has not been identified and can be used as a salvage procedure [89].

Recurrent dislocations can also be treated with a bipolar hemiarthroplasty due to the larger head size providing additional stability. This should be reserved for elderly low demand patients [89].

The use of dual mobility cups in unstable hips is becoming increasingly popular. Dual mobility cups have two points of articulation allowing increased stability with less restriction on range of movement [90].

Poor component position, soft tissue laxity and dislocations due to impingement may require surgical intervention to revise their total hip replacement.

3.5. Leg length discrepancy

Leg length discrepancy following a total hip arthroplasty is one of the most common reasons for patient dissatisfaction as it can cause nerve palsies, abnormal gait, lower back pain and reduced functional outcome. Inevitably this often leads to litigation against orthopaedic surgeons [91].

The incidence has been reported between 1 and 27% [92]. The measured leg length discrepancy have been reported to vary from 3 to 70 mm [93]. As previous covered, nerve palsies are one of the most serious complications of leg length discrepancy. Sciatic and peroneal nerve palsies have both been associated with limb lengthening [74].

Minor leg length discrepancy of less than 1 cm may be tolerated well by the patient but more than 2 cm may cause gait abnormalities as well as increase in physiological demand [91, 94]. It is important to assess the patient preoperatively and measuring true and apparent leg lengths can do this. True leg length is measured from the ipsilateral anterior superior iliac spine to medial malleolus whereas apparent leg length is measured from the umbilicus to medial malleolus. Apparent leg length discrepancies can be affected by pelvic abnormalities secondary to lumbar spine pathology or contractures around the hip. Leg length discrepancy that occurs secondary to chronic lumbar spine pathology can be very difficult to correct and may lead shortening or lengthening of the overall leg length.

Radiographs can be used for preoperative evaluation of leg length discrepancy and the use of a preoperative template to determine the level of the neck cut and position of acetabular component [95, 96]. However the reliance of preoperative templating alone has shown that its efficacy in avoiding any leg length discrepancy to be only 60% [96]. There are many intraoperative techniques using landmarks to ensure that the correct leg length is maintained. One review of the literature by Desai et al. has identified over 20 methods discussed in the literature [91]. These methods have in common the two constant reference points, one of the pelvis and the other on the femur intraoperatively to ensure the leg length is maintained and traditionally the greater trochanter is the reference point of the femur [97].

The achievement of absolute leg length equality is challenging to achieve [98]. There must be adequate time allowed for any contractures to resolve and any residual minor leg length discrepancies can be corrected with simple shoes raises. Although a simple intervention these are not always well received by patients [99]. In more significant discrepancies surgical intervention may be required to address the symptoms of pain and functional impairment then surgical correction may be required [100].

3.6. Peri-prosthetic fracture

With increasing life expectancy and an ageing population, resulting in more patients with poor bone quality and increase risk of falls, the number of total hip replacement is increasing. Thus the likelihood of patients who have had a total hip arthroplasty sustaining a peri-prosthetic fracture is on the rise. Furthermore with a broader indication for surgery, younger patients who are more active and therefore high energy trauma prone are increasingly undergoing such procedures, again increasing the risks of subsequent peri-prosthetic fractures [101].

Peri-prosthetic fractures can either occur in the intraoperative or postoperative period. Intraoperative and postoperative peri-prosthetic have been reported at 1 and 1.1% respectively. Cementless fixation are at higher risk for intraoperative peri-prosthetic fracture at 5.4% for primary total hip replacement and 21% for revision surgery [102]. For those sustaining a postoperative peri-prosthetic fracture the most significant risk factor is osteolysis with implant loosening [103]. The most common mechanism for peri-prosthetic fractures is a low energy movement accounting for over 75% of all peri-prosthetic fractures [104].

Peri-prosthetic fractures of the femur can be classified using the Vancouver classification (Table 1).

The management of peri-prosthetic fractures following total hip replacement is based not only on the fracture characteristics as defined by the Vancouver system but also patient factors including co-morbidities and bone quality. However the Vancouver classification does provide a well proven approach in considering the management of such injuries and we will briefly describe some of the approaches used in addressing such injuries.

Type A fractures are usually treated non-operatively unless a large part of the calcar is involved leading to instability of the prosthesis which would then require revision surgery. Type B fractures occur around or just distal to the stem and are most common representing 80% of all cases [101]. B1 fractures may be treated with open reduction internal fixation with a combination of plate and cerclage wire system. B2 type fractures have good bone stock and are commonly treated with revision total hip arthroplasty with a long stem, bypassing the fracture site in combination with plates and cerclage wires. B3 can be the most challenging to treat due to the poor bone stock. These may be treated with either revision hip arthroplasty with structural allografts, distally fixed long stem implants or custom proximal femoral replacements. Type C can be fixed using an open reduction internal fixation technique and there are numerous methods in use to include locking plates, screw and cable plates and intramedullary systems [101].

Various implants are available but treatment is very much dependent on the type of fracture, amount of bone stock along with taking into account patient factors. Dynamic compression plates (DCP) or locking compression plates (LCP) can be used in combination with cerclage wires and screws. Fixation of the plate can be done with either cerclage wires or unicortical screws. Proximal fixation with unicortical screws increases strength and therefore preferred

Type	Subtype	Description
A	A L	Lesser trochanter
	A G	Greater trochanter
B	B1	Well-fixed prosthesis
	B2	Loose prosthesis
	B3	Loose prosthesis with poor bone stock
C		Fracture well below the tip of prosthesis

Table 1. The Vancouver classification for periprosthetic fractures of total hip replacements [105].

over cerclage wires. Plates can also be biplanar to provide further stability. Various proximal femoral replacements are available and the choice depends on level of fracture, quality of bone and amount of bonestock remaining [106].

Acetabular peri-prosthetic fractures are uncommon but usually occur intraoperatively when inserting the acetabular component. The aim of treatment is to stabilise the fracture and prevent further propagation of the implant by plating the anterior or posterior columns, using bone grafts and, or using jumbo revision cups if there is significant bone loss [107].

3.7. Heterotopic ossification

Heterotopic ossification is the abnormal formation of lamellar bone in extra-skeletal soft tissue [108]. The reported rates of heterotopic ossification post total hip replacement varies greatly between 0.6 and 90% [108–112]. Risk factors include male gender, previous history of heterotopic ossification, pre-existing hip fusion, ankylosing spondylitis, Paget's disease, post traumatic osteoarthritis, osteonecrosis and rheumatoid arthritis [113]. Surgical factors may also play a role and include, extensive soft tissue dissection, haematoma formation, and excess bone debris [113].

Early changes of heterotopic ossification can be detected as early as 3 weeks on bone scan, 6 weeks on plain radiographs but can take up to 1 year for bone to fully mature [76]. Heterotopic ossification is usually asymptomatic and diagnosed on follow up radiographs. When symptomatic, patients most commonly present with pain and stiffness [108].

The abductor compartment is most commonly affected and is classified using the Brooker classification which is based on extent of heterotopic ossification seen on anteroposterior radiographs of the pelvis [114].

The management of heterotrophic ossification is divided into prevention and treatment once established. The prophylactic management was pioneered by Dhal with the administration of non-steroidal anti-inflammatory drugs [115]. Radiotherapy treatment in the form of 60Co gamma radiation or high energy X photons is also used to prevent the formation of heterotrophic ossification. The treatment of established heterotrophic ossification include physiotherapy during the maturation phase to prevent further propagation and no surgical intervention such as radiotherapy and extracorporeal shockwave therapy [116, 117]. Interventional procedures in the form of embolization of the nutrient arteries have been used to prevent the formation of further heterotopic ossification [118]. Surgical excision of the lesions may be considered to treat the symptoms of both pain and stiffness [119, 120].

3.8. Other complications

Osteolysis and subsequent aseptic loosening are complications that can occur as a late complication in total hip arthroplasty. Osteolysis is induced by several mechanisms to include; adaptive bone remodelling, fluid pressure and particulate debris [121]. The principle mechanism for osteolysis following total hip arthroplasty is particulate debris, particularly polyethylene [122]. These particulates are dissolved in the surrounding joint fluid that can lead to chronic inflammation at the implant bone interface. This leads to a build-up of cells such as macrophages,

fibroblasts, giant cells, neutrophils, lymphocytes and osteoclasts. The cellular response created by these cells lead to resorption of bone leading to aseptic loosening and failure of the arthroplasty [123]. This type of complication would be treated with a revision total hip replacement.

Trochanteric bursitis can be seen in 3–17% of patients following total hip arthroplasty. This can be a result of irritation due to over use, change in posture, leg length discrepancy or inappropriate offset. This is usually treated non operatively with simple analgesia, non-steroidal anti-inflammatory drugs or steroid injections [124].

Finally although more of an irritation rather than a complication with significant morbidity, some total hip arthroplasty can have issues with squeaking. Squeaking is an issue found on hard on hard bearings and rates have been reported between 0.3 and 24.6% in ceramic on ceramic arthroplasty [125]. The sound is thought to be produced from the friction created from hard on hard surfaces with insufficient fluid film lubrication. Although a nuisance, there is currently no clear consensus on the association of squeaking with ceramic failure, but patients should be counselled on the issue if hard on hard bearing surfaces are to be considered [126].

4. Conclusion

Complications following total hip replacement can be broadly divided into systemic and procedure specific complications. Overall, incidence of complications have improved over time as surgical and anaesthetic techniques have improved along with the diagnosis and management of such complications.

The most common systemic complication is a deep vein thrombosis. Infection is the most feared complication but the incidence have reduced with prophylactic antibiotics and improved theatre environment. Leg length is one of the most common causes of patient dissatisfaction and all complications can be challenging to manage for the hip surgeon. However despite these complications total hip replacements is one of the most successful orthopaedic procedures performed and continue to be widely performed across different healthcare systems with very positive patient satisfaction outcomes.

Conflict of interest

The authors have no conflicts of interest to declare.

Author details

Chang Park* and Irfan Merchant

*Address all correspondence to: changpark3@gmail.com

Royal Berkshire NHS Foundation Trust, Reading, UK

References

- [1] Jones CA, Voaklander DC, Johnston DW, Suarez-Almazor ME. Health related quality of life outcomes after total hip and knee arthroplasties in a community based population. *The Journal of Rheumatology*. 2000 Jul;**27**(7):1745-1752
- [2] Mancuso CA, Salvati EA, Johanson NA, Peterson MG, Charlson ME. Patients' expectations and satisfaction with total hip arthroplasty. *The Journal of Arthroplasty*. 1997 Jun;**12**(4):387-396
- [3] National Joint Registry. Summary of Annual Statistics (England and Wales). National Joint Registry. UK: Northgate Public Service; 2017
- [4] Liu SS, Gonzalez Della Valle A, Besculides MC, Gaber LK, Memtsoudis SG. Trends in mortality, complications, and demographics for primary hip arthroplasty in the United States. *International Orthopaedics*. 2009 Jun;**33**(3):643-651
- [5] Magill SS, Edwards JR, Bamberg W, Beldavs ZG, Dumyati G, Kainer MA, Lynfield R, Maloney M, McAllister-Hollod L, Nadle J, Ray SM. Multistate point-prevalence survey of health care-associated infections. *New England Journal of Medicine*. 2014 Mar 27;**370**(13):1198-1208
- [6] Alvarez AP, Demzik AL, Alvi HM, Hardt KD, Manning DW. Risk factors for postoperative urinary tract infections in patients undergoing total joint arthroplasty. *Advances in Orthopaedics*. 2016;**2016**:7268985
- [7] Rasouli MR, Maltenfort MG, Purtill JJ, Hozack WJ, Parvizi J. Has the rate of in-hospital infections after total joint arthroplasty decreased? *Clinical Orthopaedics and Related Research*®. 2013 Oct 1;**471**(10):3102-3111
- [8] Poss RO, Thornhill TS, Ewald FC, Thomas WH, Batte NJ, Sledge CB. Factors influencing the incidence and outcome of infection following total joint arthroplasty. *Clinical Orthopaedics and Related Research*. 1984 Jan 1;**(182)**:117-126
- [9] Sabaté S, Mazo V, Canet J. Predicting postoperative pulmonary complications: Implications for outcomes and costs. *Current Opinion in Anesthesiology*. 2014 Apr 1;**27**(2):201-209
- [10] Song K, Rong Z, Yang X, Yao Y, Shen Y, Shi D, Xu Z, et al. Early pulmonary complications following total knee arthroplasty under general anesthesia: A prospective cohort study using CT scan. *BioMed Research International*. 2016;**2016**:4062043
- [11] Jain V, Dhaon B, Jaiswal A, Nigam V, Singla J. Deep vein thrombosis after total hip and knee arthroplasty in Indian patients. *Postgraduate Medical Journal*. 2004;**80**(950):729-731. DOI: 10.1136/pgmj.2003.018127
- [12] Kim YH, Oh SH, Kim JS. Incidence and natural history of deep-vein thrombosis after total hip arthroplasty. A prospective and randomised clinical study. *Journal of Bone and Joint Surgery. British Volume (London)*. 2003 Jul;**85**(5):661-665

- [13] Samama CM, Ravaud P, Parent F, Barre J, Mertl P, Mismetti P. Epidemiology of venous thromboembolism after lower limb arthroplasty: The FOTO study. *Journal of Thrombosis and Haemostasis*. 2007 Dec;**5**(12):2360-2367
- [14] Mantilla CB, Horlocker TT, Schroeder DR, Berry DJ, Brown DL. Frequency of myocardial infarction, pulmonary embolism, deep venous thrombosis, and death following primary hip or knee arthroplasty. *Anesthesiology*. 2002 May;**96**(5):1140-1146
- [15] NICE. Venous Thromboembolism: Reducing the Risk of Venous Thromboembolism (Deep Vein Thrombosis and Pulmonary Embolism) in Inpatients Undergoing Surgery. National Collaborating Centre for Acute Care; 2007
- [16] Beksac B, Gonzalez Della Valle A, Salvati EA. Thromboembolic disease after total hip arthroplasty: Who is at risk? *Clinical Orthopaedics and Related Research*. 2006 Dec; **453**:211-224
- [17] Davis FM, Laurenson VG, Gillespie WJ, Wells JE, Foate J, Newman E. Deep vein thrombosis after total hip replacement. A comparison between spinal and general anaesthesia. *Journal of Bone and Joint Surgery. British Volume (London)*. 1989 Mar;**71**(2):181-185
- [18] Lieberman JR, Cheng V, Cote MP. Pulmonary embolism rates following total hip arthroplasty with prophylactic anticoagulation: Some pulmonary emboli cannot be avoided. *The Journal of Arthroplasty*. 2017;**32**(3):980-986
- [19] Kallos T, Enis JE, Gollan F, Davis JH. Intramedullary pressure and pulmonary embolism of femoral medullary contents in dogs during insertion of bone cement and a prosthesis. *The Journal of Bone and Joint Surgery. American Volume*. 1974 Oct;**56**(7):1363-1367
- [20] Tronzo RG, Kallos T, Wyche MQ. Elevation of intramedullary pressure when methylmethacrylate is inserted in total hip arthroplasty. *The Journal of Bone and Joint Surgery. American Volume*. 1974 Jun;**56**(4):714-718
- [21] Colonna DM, Kilgus D, Brown W, Challa V, Stump DA, Moody DM. Acute brain fat embolization occurring after total hip arthroplasty in the absence of a patent foramen ovale. *Anesthesiology*. 2002 Apr;**96**(4):1027-1029
- [22] Wenda K, Degreif J, Runkel M, Ritter G. Pathogenesis and prophylaxis of circulatory reactions during total hip replacement. *Archives of Orthopaedic and Trauma Surgery*. 1993;**112**(6):260-265
- [23] Charnley J. A clean-air operating enclosure. *The British Journal of Surgery*. 1964 Mar;**51**:202-205
- [24] Blom AW, Taylor AH, Pattison G, Whitehouse S, Bannister GC. Infection after total hip arthroplasty. The Avon experience. *Journal of Bone and Joint Surgery. British Volume (London)*. 2003 Sep;**85**(7):956-959
- [25] Bannister G. Prevention of infection in joint replacement. *Current Orthopaedics*. 2002; **16**(6):426-433
- [26] Hughes SP, Anderson FM. Infection in the operating room. *Journal of Bone and Joint Surgery. British Volume (London)*. 1999;**81**(5):754-755

- [27] Charnley J. Postoperative infection after total hip replacement with special reference to air contamination in the operating room. *Clinical Orthopaedics and Related Research*. 1972;**87**:167-187
- [28] Hooper GJ et al. Does the use of laminar flow and space suits reduce early deep infection after total hip and knee replacement?: The ten-year results of the New Zealand joint registry. *Journal of Bone and Joint Surgery. British Volume (London)*. 2011;**93**(1):85-90
- [29] Zheng H et al. Control strategies to prevent total hip replacement-related infections: A systematic review and mixed treatment comparison. *BMJ Open*. 2014;**4**(3):e003978
- [30] Classen DC et al. The timing of prophylactic administration of antibiotics and the risk of surgical-wound infection. *The New England Journal of Medicine*. 1992;**326**(5):281-286
- [31] Prokuski L et al. Prophylactic antibiotics in orthopaedic surgery. *Instructional Course Lectures*. 2011;**60**:545-555
- [32] AlBuhairan B, Hind D, Hutchinson A. Antibiotic prophylaxis for wound infections in total joint arthroplasty: A systematic review. *Journal of Bone and Joint Surgery. British Volume (London)*. 2008;**90**:915-919
- [33] Spangehl MJ, Masri BA, O'Connell JX, Duncan CP. Prospective analysis of preoperative and intraoperative investigations for the diagnosis of infection at the sites of two hundred and two revision total hip arthroplasties. *The Journal of Bone and Joint Surgery. American Volume*. 1999 May;**81**(5):672-683
- [34] Zhuang H, Yang H, Alavi A. Critical role of 18F-labeled fluorodeoxyglucose PET in the management of patients with arthroplasty. *Radiologic Clinics of North America*. 2007 Jul;**45**(4):711-718, vii
- [35] Love C, Marwin SE, Palestro CJ. Nuclear medicine and the infected joint replacement. *Seminars in Nuclear Medicine*. 2009 Jan;**39**(1):66-78
- [36] Ali F, Wilkinson JM, Cooper JR, Kerry RM, Hamer AJ, Norman P, et al. Accuracy of joint aspiration for the preoperative diagnosis of infection in total hip arthroplasty. *The Journal of Arthroplasty*. 2006;**21**:221-226
- [37] Tsukayama DT, Estrada R, Gustilo RB. Infection after total hip arthroplasty. A study of the treatment of one hundred and six infections. *The Journal of Bone and Joint Surgery. American Volume*. 1996 Apr;**78**(4):512-523
- [38] Crockarell JR, Hanssen AD, Osmon DR, Morrey BF. Treatment of infection with debridement and retention of the components following hip arthroplasty. *The Journal of Bone and Joint Surgery. American Volume*. 1998 Sep;**80**(9):1306-1313
- [39] Buchholz HW, Elson RA, Engelbrecht E, Lodenkamper H, Rottger J, Siegel A. Management of deep infection of total hip replacement. *Journal of Bone and Joint Surgery. British Volume (London)*. 1981;**63-B**(3):342-353
- [40] Younger AS, Duncan CP, Masri BA, McGraw RW. The outcome of two-stage arthroplasty using a custom-made interval spacer to treat the infected hip. *The Journal of Arthroplasty*. 1997 Sep;**12**(6):615-623

- [41] Stockley I, Mockford BJ, Hoad-Reddick A, Norman P. The use of two-stage exchange arthroplasty with depot antibiotics in the absence of long-term antibiotic therapy in infected total hip replacement. *Journal of Bone and Joint Surgery. British Volume (London)*. 2008 Feb;**90**(2):145-148
- [42] Rosencher N, Kerkkamp HE, Macheras G, Munuera LM, Menichella G, Barton DM, et al. Orthopedic surgery transfusion hemoglobin European overview (OSTHEO) study: Blood management in elective knee and hip arthroplasty in Europe. *Transfusion*. 2003;**43**:459-469
- [43] Vuille-Lessard É, Boudreault D, Girard F, Ruel M, Chagnon M, Hardy J-F. Red blood cell transfusion practice in elective orthopedic surgery: A multicenter cohort study. *Transfusion*. 2010;**50**:2117-2124
- [44] Cushner F, Agnelli G, Fitzgerald G, Warwick D. Complications and functional outcomes after total hip arthroplasty and total knee arthroplasty: Results from the Global Orthopaedic Registry (GLORY). *American Journal of Orthopedics (Belle Mead NJ)*. 2010 Sep;**39**(9 Suppl):22-28
- [45] Flordal PA, Neander G. Blood loss in total hip replacement. *Archives of Orthopaedic and Trauma Surgery*. 1991;**111**:34-38
- [46] Toy PTCY, Kaplan EB, McVay PA, Lee SJ, Strauss RG, Stehling LD. Blood loss and replacement in total hip arthroplasty: A multicenter study. *Transfusion*. 1992;**32**:63-67
- [47] Grosflam JM, Wright EA, Cleary PD, Katz JN. Predictors of blood loss during total hip replacement surgery. *Arthritis & Rheumatology*. 1995 Sep 1;**8**(3):167-173
- [48] Hrnack SA, Skeen N, Xu T, Rosenstein AD. Correlation of body mass index and blood loss during total knee and total hip arthroplasty. *The American Journal of Orthopedics*. 2012;**41**:467-471
- [49] Carling MS, Jeppsson A, Eriksson BI, Brisby H. Transfusions and blood loss in total hip and knee arthroplasty: A prospective observational study. *Journal of Orthopaedic Surgery and Research*. 2015 Mar 28;**10**(1):48
- [50] Bowditch MG, Villar RN. Do obese patients bleed more? A prospective study of blood loss at total hip replacement. *Annals of the Royal College of Surgeons of England*. 1999;**81**:198-200
- [51] Browne JA, Adib F, Brown TE, Novicoff WM. Transfusion rates are increasing following total hip arthroplasty: Risk factors and outcomes. *The Journal of Arthroplasty*. 2013;**28** (8 Suppl):34-37
- [52] Hasley PB, Lave JR, Hanusa BH, Arena VC, Ramsey G, Kapoor WN, Fine MJ. Variation in the use of red blood cell transfusions. A study of four common medical and surgical conditions. *Medical Care*. 1995;**33**:1145-1160
- [53] The Sanguis Study Group. Use of blood products for elective surgery in 43 European hospitals. *Transfusion Medicine*. 1994;**4**:251-268

- [54] Bierbaum BE, Hill C, Callaghan JJ, et al. An analysis of blood management in patients having a total hip or knee arthroplasty. *The Journal of Bone and Joint Surgery. American Volume*. 1999;**81**(1):2-10
- [55] Del Trujillo MM, Carrero A, Munoz M. The utility of the perioperative autologous transfusion system OrthoPAT in total hip replacement surgery: A prospective study. *Archives of Orthopaedic and Trauma Surgery*. 2008;**128**:1031-1038
- [56] Smith LK, Williams DH, Langkamer VG. Post-operative blood salvage with autologous retransfusion in primary total hip replacement. *Journal of Bone and Joint Surgery. British Volume (London)*. 2007;**89**:1092-1097
- [57] Moonen AF, Knoors NT, van Os JJ, et al. Retransfusion of filtered shed blood in primary total hip and knee arthroplasty: A prospective randomized clinical trial. *Transfusion*. 2007;**47**:379-384
- [58] MacFarlane BJ, Marx L, Anquist K, Pineo G, Cheng J, Cassol E. Analysis of a protocol for an autologous blood transfusion program for total joint replacement surgery. *Canadian Journal of Surgery*. 1988;**31**:126-129
- [59] Axelrod FB, Pepkowitz SH, Goldfinger D. Establishment of a schedule of optimal preoperative collection of autologous blood. *Transfusion*. 1989;**29**:677-680
- [60] Woolson ST, Marsh JS, Tanner JB. Transfusion of previously deposited autologous blood for patients undergoing hip replacement surgery. *Journal of Bone and Joint Surgery*. 1987;**69**:325-328
- [61] Eckardt JJ, Gossett TC, Amstutz HC. Autologous transfusion and total hip arthroplasty. *Clinical Orthopaedics and Related Research*. 1978;**(132)**:39-45
- [62] Hart A, Khalil JA, Carli A, Huk O, Zukor D, Antoniou J. Blood transfusion in primary total hip and knee arthroplasty. Incidence, risk factors, and thirty-day complication rates. *JBJS*. 2014;**96**(23):1945-1951
- [63] Goodnough LT, Shuck JM. Risks, options, and informed consent for blood transfusion in elective surgery. *American Journal of Surgery*. 1990;**159**(6):602
- [64] Keating EM, Meding JB. Perioperative blood management practices in elective orthopaedic surgery. *The Journal of the American Academy of Orthopaedic Surgeons*. 2002;**10**:393-400
- [65] Bower WF, Jin L, Underwood MJ, et al. Peri-operative blood transfusion increases length of hospital stay and number of post-operative complications in non-cardiac surgical patients. *Hong Kong Medical Journal*. 2010;**16**(2):116
- [66] Pierson JL, Hannon TJ, Earles DR. A blood-conservation algorithm to reduce blood transfusions after total hip and knee arthroplasty. *The Journal of Bone and Joint Surgery. American Volume*. 2004;**86**(7):1512-1518

- [67] Krebs V, Hozack WJ, Callaghan JJ, et al. Eliminating transfusion in primary joint arthroplasty—An achievable goal. *The Journal of Arthroplasty*. 2014;**29**(8):1511
- [68] Sukeik M, Alshryda S, Haddad FS, et al. Systematic review and meta-analysis of the use of tranexamic acid in total hip replacement. *Journal of Bone and Joint Surgery. British Volume (London)*. 2011;**93**(1):39-46
- [69] Poeran J, Rasul R, Suzuki S, Danninger T, et al. Tranexamic acid use and postoperative outcomes in patients undergoing total hip or knee arthroplasty in the United States: Retrospective analysis of effectiveness and safety. *BMJ*. 2014;**349**:g4829
- [70] Brown GD, Swanson FA, Nercessian OA. Neurologic injuries after total hip arthroplasty. *The American Journal of Orthopedics*. 2008;**37**(4):191-197
- [71] Schmalzried TP, Noordin S, Amstutz HC. Update on nerve palsy associated with total hip replacement. *Clinical Orthopaedics and Related Research*. 1997 Nov;**344**:188-206
- [72] Schmalzried TP, Amstutz HC, Dorey FJ. Nerve palsy associated with total hip replacement. Risk factors and prognosis. *The Journal of Bone and Joint Surgery. American Volume*. 1991;**73**:1074-1080
- [73] Edwards BN, Tullos HS, Noble PC. Contributory factors and etiology of sciatic nerve palsy in total hip arthroplasty. *Clinical Orthopaedics and Related Research*. 1987:136-141
- [74] Barrack RL. Neurovascular injury: Avoiding catastrophe. *The Journal of Arthroplasty*. 2004 Jun;**19**(4 Suppl 1):104-107
- [75] Klein GS, Sharkey PF, et al. Late sciatic nerve palsy caused by Haematoma after primary total hip arthroplasty. *The Journal of Arthroplasty*. 2004;**19**(6):760-792
- [76] Kinov P, editor. *Arthroplasty – Update*. The Shard, London: IntechOpen Limited; ISBN: 978-953-51-0995-2. 618 pp. [Chapters published February 20, 2013 under CC BY 3.0 license DOI: 10.5772/56149 Edited Volume]
- [77] Montgomery AS, Birch R, Malone A. Sciatic neurostalgia caused by total hip arthroplasty, cured by late neurolysis. *Journal of Bone and Joint Surgery*. 2005;**87**(3):410-411
- [78] Mounsasmy V, Cui Q, Brown TE, et al. Acute sciatic neuritis following total hip arthroplasty: A case report. *Archives of Orthopaedic and Trauma Surgery*. 2008;**128**(1):25-28
- [79] Milhako WM, Phillips MJ, Krackow KA. Acute sciatic and femoral neuritis following total hip arthroplasty. A case report. *Journal of Bone and Joint Surgery American*. 2001;**83**(4):589-592
- [80] Park C, Ikram A, Abdul-Jabar HB, Radford W. Sciatic nerve neuritis of no cause in primary total hip replacement. A case series. *Journal of Clinical Orthopaedics and Trauma*. DOI: 10.1016/j.jcot.2017.08.010 [Published online ahead of print]
- [81] May O, Girard J, Hurtevent JF, et al. Delayed transient sciatic nerve palsy after primary cementless hip arthroplasty: A report of two cases. *Journal of Bone and Joint Surgery*. 2008;**90**(5):674-676

- [82] Katsimihas M, Hutchinson J, Heath P. Et al, (2002) Delayed sciatic nerve palsy after total hip arthroplasty, *The Journal of Arthroplasty*, **17**(3):379-381
- [83] Dargel J et al. Dislocation following total hip replacement. *Deutsches Ärzteblatt International*. 2014;**111**(51-52):884-890. PMC
- [84] Sanchez-Sotelo J, Berry DJ. Epidemiology of instability after total hip replacement. *The Orthopedic Clinics of North America*. 2001 Oct;**32**(4):543-552, vii
- [85] Woo RY, Morrey BF. Dislocations after total hip arthroplasty. *The Journal of Bone and Joint Surgery. American Volume*. 1982 Dec;**64**(9):1295-1306
- [86] Lewinnek GE, Lewis JL, Tarr R, Compere CL, Zimmerman JR. Dislocations after total hip-replacement arthroplasties. *Journal of Bone and Joint Surgery*. 1978;**60**:217-220
- [87] Abdel MP, von Roth P, Jennings MT, Hanssen AD, Pagnano MW. What safe zone? The vast majority of dislocated THAs are within the Lewinnek safe zone for Acetabular component position. *Clinical Orthopaedics and Related Research*. 2016;**474**(2):386-391
- [88] Crowninshield RD, Maloney WJ, Wentz DH, Humphrey SM, Blanchard CR. Biomechanics of large femoral heads: What they do and don't do. *Clinical Orthopaedics and Related Research*. 2004;**429**:102-107
- [89] D'Angelo F, Murena L, Zatti G, Cherubino P. The unstable total hip replacement. *Indian Journal of Orthopaedics*. 2008;**42**(3):252-259
- [90] Ko LM, Hozack WJ. The dual mobility cup: What problems does it solve? *Bone Joint J*. 2016 Jan 1;**98**(1 Suppl. A):60-63
- [91] Desai AS, Dramis A, Board TN. Leg length discrepancy after total hip arthroplasty: A review of literature. *Current Reviews in Musculoskeletal Medicine*. 2013;**6**(4):336-341. PMC
- [92] Ranawat CS, Rodriguez JA. Functional leg-length inequality following total hip arthroplasty. *The Journal of Arthroplasty*. 1997;**12**:359-364. DOI: 10.1016/S0883-5403(97)90190-X
- [93] Sathappan SS, Ginat D, Patel V, Walsh M, Jaffe WL, Di Cesare PE. Effect of anaesthesia type on limb length discrepancy after total hip arthroplasty. *The Journal of Arthroplasty*. 2008;**23**:203-209. DOI: 10.1016/j.arth.2007.01.022
- [94] Jasty M, Webster W, Harris W. Management of limb length inequality during total hip replacement. *Clinical Orthopaedics and Related Research*. 1996 Dec 1;**333**:165-171
- [95] Woolson ST, James MH, Sawyer A. Results of leg length equalization for patients undergoing primary total hip replacement. *The Journal of Arthroplasty*. 1999;**14**:159-164
- [96] Knight JL, Atwater RD. Preoperative planning for total hip arthroplasty: Quantitating it's utility and precision. *The Journal of Arthroplasty*. 1992;**7**:403-409
- [97] Charnley J. *Low Friction Arthroplasty of the Hip: Theory and Practice*. New York: Springer; 1979

- [98] Rubash HE, Parvataneni HK. The pants too short, the leg too long: Leg length inequality after total hip arthroplasty. *Orthopaedics*. 2007;**30**:764-765
- [99] Maloney WJ, Keeney JA. Leg length discrepancy after total hip arthroplasty. *The Journal of Arthroplasty*. 2004;**19**:108-110
- [100] Parvizi J, Sharkey PF, Bissett BA, Rothman RH, Hozack WJ. Surgical treatment of limb length discrepancy following total hip arthroplasty. *The Journal of Bone and Joint Surgery. American Volume*. 2003;**85**:2310-2317
- [101] Schwarzkopf R, Oni JK, Marwin SE. Total hip arthroplasty periprosthetic femoral fractures: A review of classification and current treatment. *Bulletin/Hospital for Joint Diseases*. 2013;**71**:68-78
- [102] Berry DJ. Epidemiology: Hip and knee. *The Orthopedic Clinics of North America*. 1999 Apr;**30**(2):183-190
- [103] Sarvilinna R, Huhtala HS, Sovelius RT, et al. Factors predisposing to periprosthetic fracture after hip arthroplasty: A case (n = 31)-control study. *Acta Orthopaedica Scandinavica*. 2004 Feb;**75**(1):16-20
- [104] Lindahl H, Malchau H, Herberts P, Garellick G. Periprosthetic femoral fractures classification and demographics of 1049 periprosthetic femoral fractures from the Swedish National Hip Arthroplasty register. *The Journal of Arthroplasty*. 2005 Oct;**20**(7):857-865
- [105] Gaski GE, Scully SP. In brief: Classifications in brief: Vancouver classification of post-operative periprosthetic femur fractures. *Clinical Orthopaedics and Related Research*. 2011;**469**:1507
- [106] Yasen AT, Haddad FS. Periprosthetic fractures: Bespoke solutions. *The Bone & Joint Journal*. 2014 Nov 1;**96**(11 Suppl. A):48-55
- [107] Chitre A, Wynn Jones H, Shah N, Clayson A. Complications of total hip arthroplasty: Periprosthetic fractures of the acetabulum. *Current Reviews in Musculoskeletal Medicine*. 2013;**6**(4):357-363
- [108] Thomas BJ. Heterotopic bone formation after total hip arthroplasty. *The Orthopedic Clinics of North America*. 1992;**23**:347-358
- [109] Ahrengart L. Periarticular heterotopic ossification after total hip arthroplasty. Risk factors and consequences. *Clinical Orthopaedics and Related Research*. 1991;**263**(2):49-58
- [110] Naraghi FF, De Coster TA, Moneim MS, et al. Heterotopic ossification. *Orthopaedics*. 1996;**19**:145-151
- [111] Thomas BJ, Amstutz HC. Prevention of heterotopic bone formation: Clinical experience with diphosphonates. *The Hip*. 1987:59-69
- [112] Nilsson OS, Persson PE. Heterotopic bone formation after joint replacement. *Current Opinion in Rheumatology*. 1999;**11**(2):127-131

- [113] Board TN, Karva A, Board RE et al. The prophylaxis and treatment of heterotopic ossification following lower limb arthroplasty. *Journal of Bone and Joint Surgery. British Volume* (London) 2007 Apr;**89**(4):434-440
- [114] Jain R. Heterotopic ossification after acetabular fractures: Prevention and management. *Journal of Orthopaedic Complications*. 2016;**1**(1):20-22
- [115] Dahl HK. Klinske Observasjoner. In: Symposium on Arthrose. Blindern, Norway: MSD; 1975. pp. 37-46
- [116] Brissot R, Lassalle A, Vincendeau S, et al. Treatment of heterotopic ossification by extracorporeal shock wave: 26 patients. *Annales de Réadaptation et de Médecine Physique*. 2005;**48**(8):581-589
- [117] Healy WL, Lot TC, De Simone AA, et al. Single-dose irradiation for the prevention of heterotopic ossification after total hip arthroplasty. *Journal of Bone & Joint Surgery: American*. 1995;**77**:590-595
- [118] Vogl TJ, Wolff JD, Balzer J, et al. Preoperative arterial embolization in heterotopic ossification: A case report. *European Radiology*. 2001;**11**(6):962-964
- [119] Wick M, Muller EJ, Hahn MP, et al. Surgical excision of heterotopic bone after hip surgery followed by oral indomethacin application: Is there a clinical benefit for the patient? *Archives of Orthopaedic and Trauma Surgery*. 1999;**119**(3-4):151-155
- [120] Wahl B, Grasshoff H, Meinecke I, et al. Clinical and radiological results of surgical removal of periarticular ossifications after hip prosthesis implantation. *Unfallchirurg*. 2002;**105**(6):523-526
- [121] Dattani R. Femoral osteolysis following total hip replacement. *Postgraduate Medical Journal*. 2007;**83**(979):312-316
- [122] Rubash HE, Sinha RK, Shanbhag AS, et al. Pathogenesis of bone loss after total hip arthroplasty. *The Orthopedic Clinics of North America*. 1998;**29**:173-186
- [123] Abu-Amer Y, Darwech I, Clohisy JC. Aseptic loosening of total joint replacements: Mechanisms underlying osteolysis and potential therapies. *Arthritis Research & Therapy*. 2007 Jun;**9**(1):S6
- [124] Shemesh SS, Moucha CS, Keswani A, Maher NA, Chen D, Bronson MJ. Trochanteric bursitis following primary total hip arthroplasty: Incidence, predictors, and treatment. *The Journal of Arthroplasty*. 2018 Apr;**33**(4):1205-1209
- [125] Levy YD, Munir S, Donohoo S, Walter WL. Review on squeaking hips. *World Journal of Orthopedics*. 2015;**6**(10):812-820
- [126] Traina F, De Fine M, Bordini B, Toni A. Risk factors for ceramic liner fracture after total hip arthroplasty. *Hip International*. 2012;**22**:607-614

