

We are IntechOpen, the world's leading publisher of Open Access books Built by scientists, for scientists

6,900

Open access books available

185,000

International authors and editors

200M

Downloads

Our authors are among the

154

Countries delivered to

TOP 1%

most cited scientists

12.2%

Contributors from top 500 universities



WEB OF SCIENCE™

Selection of our books indexed in the Book Citation Index
in Web of Science™ Core Collection (BKCI)

Interested in publishing with us?
Contact book.department@intechopen.com

Numbers displayed above are based on latest data collected.
For more information visit www.intechopen.com



Office-Based Small Bore Needle Arthroscopy of the Knee

Kyle Williams, Kelly Scott, Donald Dulle III and
Anikar Chhabra

Additional information is available at the end of the chapter

<http://dx.doi.org/10.5772/intechopen.76757>

Abstract

Advanced imaging, such as MRI, can sometimes provide inconclusive results with knee pathology, leaving both patients and providers with a diagnostic challenge. In-office arthroscopy is a newer, low-risk, diagnostic procedure that allows the physician to use a small bore needle arthroscope to view the intra-articular anatomy of the joint. The patient and provider are provided with immediate results of the pathology found. This prevents having to undergo repeat imaging, which can be a costly, time-consuming, and inconclusive process. Ideal indications are patients who are claustrophobic, have previously undergone meniscal or chondral surgery, or whose MRI results are inconclusive. This chapter will review the background, indications, technique, and risks of this novel procedure.

Keywords: knee arthroscopy, in-office, magnetic resonance imaging

1. Introduction

Arthroscopy is currently the gold standard for diagnosing intra-articular knee pathology. While arthroscopy does allow surgeons to see within the finite pathologic area, magnetic resonance imaging (MRI) serves as a less invasive tool to diagnose injuries within the knee. MRI currently serves as the leading imaging tool to diagnose intra-articular injuries; however, studies have questioned its accuracy. Objective measures of test performance generally include, but are not limited to, sensitivity, specificity, accuracy and predictive values. To diagnose a complete anterior cruciate ligament (ACL) tear, studies show MRI to have sensitivity, specificity, accuracy and negative predictive value (NPV) of 90.9, 84.6, 88.6, and

84.6% respectively [1, 2]. Furthermore, the sensitivity, specificity, accuracy, and NPV of MRI to detect medial meniscus pathology was 100, 52.6, 64 and 100%, respectively, while detection of lateral meniscus pathology was 55.6, 83.3, 75.8 and 83.3%, respectively [1, 2]. MRI's objective measures of test performance are not perfect by any means, leading experts to question its overall reliability [3], while also seeking a superior method.

While arthroscopy is considered the gold standard for diagnosing and treating pathology of the knee, any type of surgical procedure, especially one that requires general anesthesia, presents risks that must be weighed alongside the benefits of the procedure. Arthroscopic procedures have been shown to have 30-day readmission rates of 0.92% for reasons including surgical site infections, deep venous thrombosis, pulmonary embolism, and postoperative ailments [4]. Although this percentage is low, complications do still exist. New technology geared toward obviating diagnostic arthroscopies may allow for similar diagnostic outcomes while also eliminating the surgical risk. New technology, namely mi-eye 2 (Trice Medical) has allowed physicians to perform in-office diagnostic arthroscopies.

2. Technique

The mi-eye 2™ received FDA 501(k) clearance in October 2016 for in-office diagnostic arthroscopy use (**Figure 1**). The device itself consists of a 14-gauge needle, through which the arthroscope is placed. The arthroscope is a 2.26 mm, 0° camera, which allows a 120° field of view and 5–35 mm depth of view with autofocus capability. The light source and the display monitor are also included in the packaging.

The patient should be placed in a comfortable position during the procedure; the knee should be in 90° of flexion, which can be done in a seated position or supine position with a bump under the patient's heel (**Figure 2**). Landmarks are then palpated and marked, including the medial, lateral, and inferior borders of the patella as well as the patellar tendon. The standard medial and lateral portals are marked 0.5 cm inferior to the inferior pole of the patella, just medial or lateral to the patellar tendon; a trans-patellar tendon portal, located 1 cm inferior to the inferior pole of



Figure 1. Device. The mi-eye 2 device from trice medical, which includes the tablet and disposable probe. The needle sheath is retracted by pushing back on button found on superior portion of device.

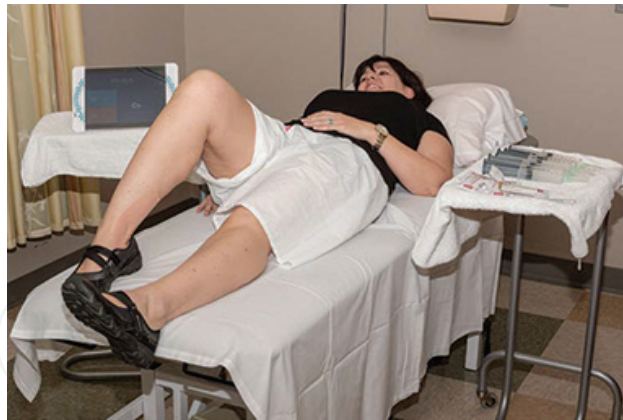

Figure 2. Patient set-up. The patient is set up with the knee at 90° in a comfortable position. This picture demonstrates the patient in a supine position. Alternatively, the patient can be positioned sitting with the knee bent to 90°.

the patella, can be marked and used as well (**Figure 3**). If further evaluation of the patellofemoral joint is necessary, standard supero-lateral or supero-medial portals can be used. Once the intended portal sites are marked, the skin is prepped in a sterile fashion and 2 cc of 0.2% lidocaine

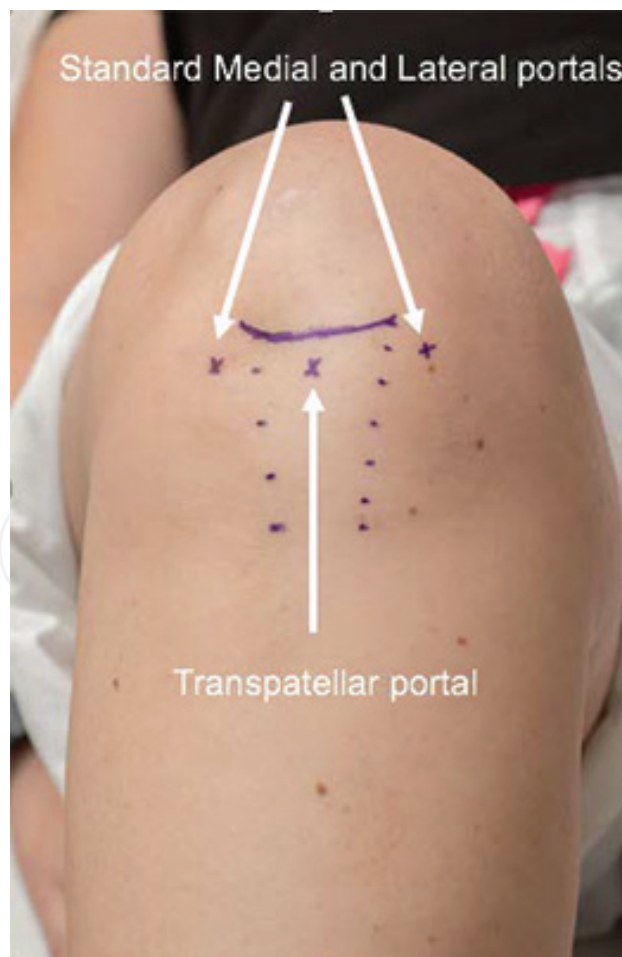


Figure 3. Portal sites. Anterolateral, anteromedial and transpatellar portal sites are marked, sterilized, and anesthetized. Additionally, superolateral and superomedial sites can be used for a more thorough visualization of the patellofemoral joint.

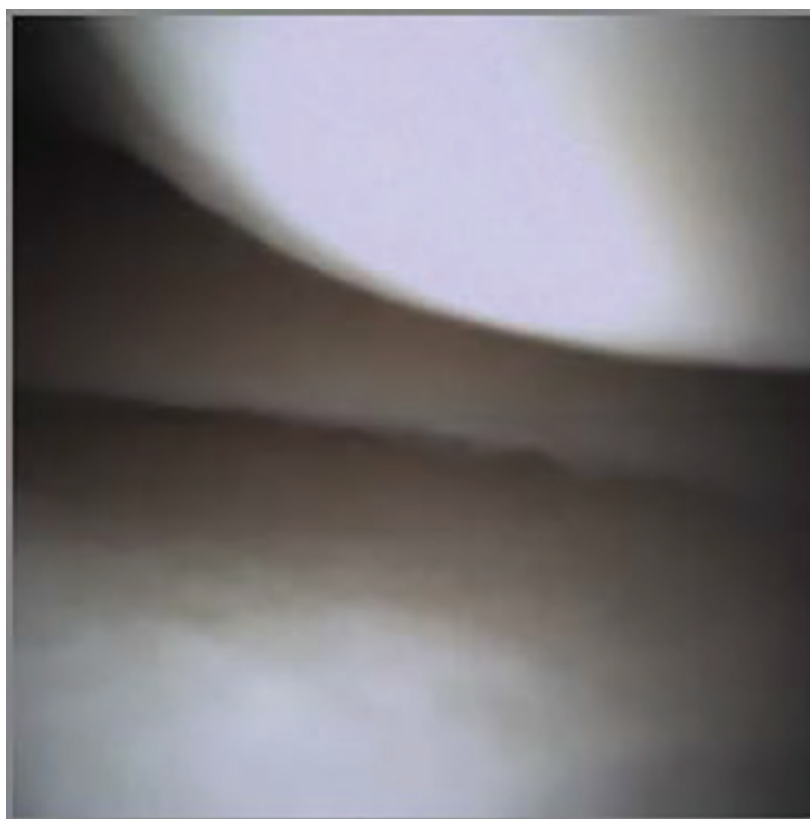
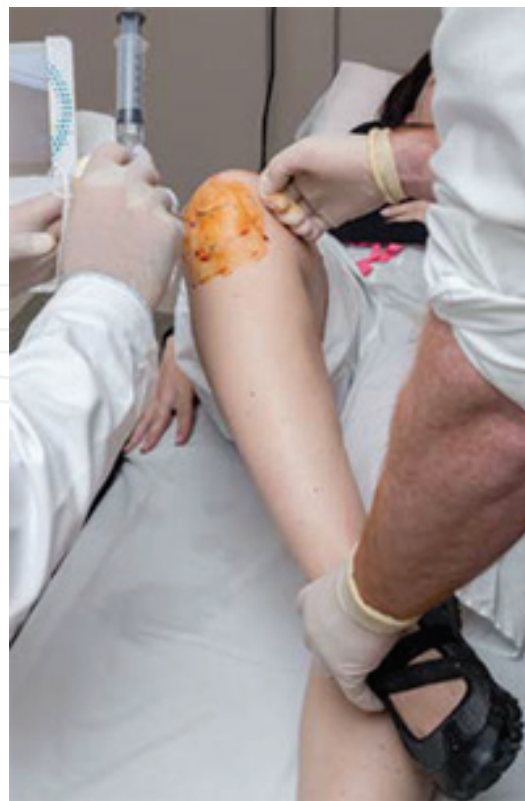


Figure 4. Medial knee compartment. Visualization of the medial meniscus and medial chondral surfaces using the in-office arthroscopy system.

without epinephrine is used to anesthetize the skin directly over each portal sites. An additional 20 cc of 0.2% lidocaine without epinephrine is injected intra-articularly. Allow approximately 10 minutes for the analgesia to take full effect. The skin is then sterily prepped a second time, prior to insertion of the mi-eye 2TM probe into the knee joint.

Multiple syringes of sterile saline are at hand and ready to inject into the knee joint through the mi-eye 2TM probe to obtain adequate distension for visualization; varying amounts of saline are needed but often times do not exceed 150 cc. The mi-eye 2TM is removed from its sterile packaging. The first syringe of saline (we recommend using 10 cc syringes to better control the probe) is attached to the stopcock and the probe connector is removed and handed to the assistant to be plugged into the tablet. The probe is then inserted into the medial or lateral portal sites, making sure to aim toward the notch to avoid damage to the cartilage or menisci. Once the capsule is entered, the retraction button is depressed and the needle is retracted; this will expose the probe optics. The stopcock should be opened a ¼ turn to allow for injection of saline. Slowly inject saline to distend the capsule and fill the joint to allow for adequate visualization. Bursts of fluid will be required to push away soft tissue and allow for visualization at various times during the procedure. A diagnostic arthroscopy is performed in a step-wise fashion, visualizing each compartment (medial, lateral and patellofemoral) (**Figures 4–6**), the notch (**Figure 7**), and the gutters. Certain maneuvers, including slight varus and valgus stresses, may be employed to visualize desired structures. Images and live video can be saved to the tablet device as needed.



(a)



(b)

Figure 5. a) Knee position in the Figure of Four Position to gain access to the Lateral Compartment of the Knee
b) Visualization of the Lateral Meniscus and the Lateral Chondral Surfaces using the in-office arthroscopy system.

After completion of the arthroscopy, the fluid in the joint can be aspirated through the same stop-cock using multiple 50 cc syringes. The probe is then removed from the joint, and a compressive dressing, such as an Ace Wrap, should be applied to the knee. The images and video saved to the portal can then be reviewed with the patient immediately following the procedure. Given the minimal procedure and early mobilization, no deep venous thrombosis prophylaxis is warranted.

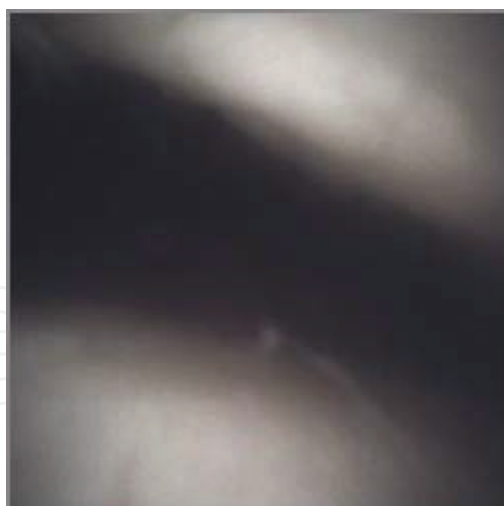


Figure 6. Patellofemoral knee compartment. Visualization of the patella and the trochlear chondral surfaces from the anterolateral portal using the in-office arthroscopy system.

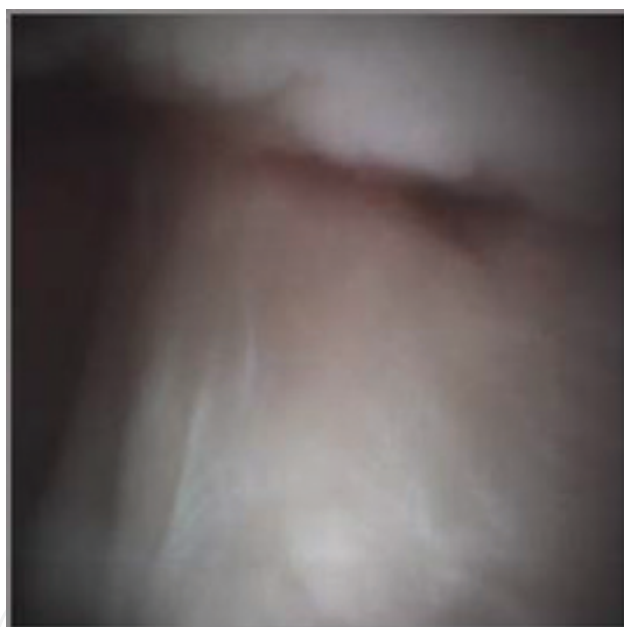


Figure 7. The notch. Visualization of the anterior Cruciate ligament in the notch using the in-office arthroscopy system.

3. Indications and contraindications

Indications for diagnostic in office arthroscopy include patients who cannot undergo an MRI for medical or personal reasons or patients who have undergone prior arthroscopic procedures and subsequently have an inconclusive MRI. In addition, patients who are potential candidates for a meniscal transplant, osteochondral allograft, or a unicompartmental knee arthroplasty (UKA) can undergo this in office procedure to better characterize current pathology as well as aid in the preparation of a definitive treatment plan. The main contraindication to the procedure are patients with acute hemarthrosis, due to the inability to adequately flush

the out the knee. Additionally, visualization can be difficult in patients who have had multiple surgical procedures resulting in significant synovial scarring.

4. Risks/limitations

While in office arthroscopy negates the anesthetic risk and greatly minimizes DVT and infection risks associated with intraoperative arthroscopy, there are limitations associated with its use. First, the surgeon must feel comfortable with the instruments, particularly the 0° scope, which may be unfamiliar. The 0° scope is used because the optics do not allow for the more commonly used 30° scope; however, the development of the 30° scope is in progress. Second, while direct visualization of intraarticular pathology is possible, the images are not as clear as an operative arthroscopy.

5. Discussion

In-office arthroscopy has been available since the early 1990s, yet, over the years, this technology has evolved, allowing for high quality intra-articular images to be obtained in an office setting [5, 6]. Historically, MRI has been used to diagnose a variety of intra-articular pathologies, due to its superiority to other imaging studies in identifying chondral, ligamentous and meniscal pathologies; reported accuracy rates hover around 90% [7, 8]. While imaging studies often play a substantial role in the decision to treat a patient conservatively or surgically, these studies are not perfect and can sometimes miss, under-diagnose, or over-diagnose intra-articular knee pathologies [8–10]. In-office arthroscopy allows the physician to directly visualize the knee through high-quality, real-time images. In an unpublished, current study, the accuracy of in-office arthroscopy in comparison to MRI is 91.5 versus 61.3% for all pathologies [11].

In addition to the accurate diagnostic potential, in-office arthroscopy provides further benefits to both the patient and the physician. The patient, who is seeking a medical opinion, can receive not only a more definitive and accurate answer regarding the nature of their pathology but this diagnosis can eliminate a possibly unnecessary diagnostic arthroscopy performed in the operating room under general anesthesia. The physician, who is providing a medical opinion, can be more definitive in their diagnosis of intra-articular pathology, leading to a more definitive and accurate treatment plan. In-office arthroscopy is a purely diagnostic tool; simple procedures, like loose body removal, are not yet possible.

The risk associated with in-office arthroscopy, as compared to diagnostic arthroscopy, is minimal. Diagnostic arthroscopy requires patients to undergo general anesthesia, adding both risk and cost to the patient, while in-office arthroscopy uses local anesthetic. Furthermore, both procedures allow patients to go home the same day, yet the time constraint of in-office arthroscopy is significantly decreased, since a diagnostic arthroscopy requires more time due to preoperative evaluation, anesthetic induction, the procedure itself, and time in the post-anesthesia care unit after surgery.

Advantages	Disadvantages
Minimal risk (compared to standard arthroscopy)	Surgeon unfamiliarity using 0° scope
No risk of anesthesia	Visualization not as clear (compared to standard arthroscopy)
Can be used when MRI contraindicated due to medical reasons, claustrophobia	Contraindicated with acute hemarthrosis (unable to flush out knee)
Improved accuracy (compared to MRI)	Scar tissue from prior surgeries limits excursion of small-bore needle
Allows visualization of prior repair	
Cost effective	
Cost savings	

Table 1. Advantages and disadvantages of in-office arthroscopy.

The potential cost savings associated with in-office arthroscopy is also worth noting. Studies have shown that in-office arthroscopy procedures are responsible for a net \$151 million per year in cost savings while being used over MRI [12]. Furthermore, the avoidance of unnecessary future surgical procedures has the potential for cost saving, yet this topic has not yet been critically analyzed. Although the procedure is novel, it appears that insurances are reimbursing for the diagnostic arthroscopy code. Advantages and disadvantages of in-office arthroscopy are listed in **Table 1**.

While in-office arthroscopy is not required in every patient presenting with symptoms of knee pain, its use in specific situations can greatly improve and expedite patient care, as well as save patients the cost and morbidity of an unnecessary procedure. In-office arthroscopy offers the surgeon another diagnostic tool that can be valuable in a multitude of clinical settings.

Conflict of interest

The authors have no conflict of interest or financial interest regarding this product.

Financial disclosures

Anikar Chhabra, MD MS: Arthrex Consultant.

Author details

Kyle Williams¹, Kelly Scott², Donald Dulle III² and Anikar Chhabra^{2*}

*Address all correspondence to: chhabra.anikar@mayo.edu

1 Arizona State University, United States

2 Department of Orthopedic Surgery, Mayo Clinic, Phoenix, Arizona, United States

References

- [1] Laoruengthana A, Jarusriwann A. Sensitivity and specificity of magnetic resonance imaging for knee injury and clinical application for the Naresuan University Hospital. *Journal of the Medical Association of Thailand*. 2012;**95**(Suppl 10):S151-S157
- [2] Panigrahi R, Priyadarshi A, Palo N, Marandi H, Agrawalla DK, Biswal MR. Correlation of clinical examination, MRI and arthroscopy findings in Menisco-Cruciate injuries of the knee: A prospective diagnostic study. *Archives of Trauma Research*. 2016;**6**(1):e30364
- [3] Hoyt M, Goodemote P, Morton J. How accurate is an MRI at diagnosing injured knee ligaments? *The Journal of Family Practice*. 2010;**59**(2):118-120
- [4] Westermann RW, Pugely AJ, Ries Z, Amendola A, Martin CT, Gao Y, Wolf BR. Causes and predictors of 30-day readmission after shoulder and knee arthroscopy: An analysis of 15,167 cases. *Arthroscopy*. 2015;**31**(6):1035-1040
- [5] Halbrecht JL, Jackson DW. Office arthroscopy: A diagnostic alternative. *Arthroscopy*. 1992;**8**(3):320-326
- [6] Yates JW. Diagnostic office arthroscopy. *Journal of the South Carolina Medical Association*. 1993;**89**(7):329-331
- [7] Phelan N, Rowland P, Galvin R, et al. A systematic review and meta-analysis of the diagnostic accuracy of MRI for suspected ACL and meniscal tears of the knee. *Knee Surgery, Sports Traumatology, Arthroscopy*. 2016;**24**:1525-1539
- [8] Quatman CE, Hettrich CM, Schmitt LC, et al. The clinical utility and diagnostic performance of magnetic resonance imaging for identification of early and advanced knee osteoarthritis: A systematic review. *The American Journal of Sports Medicine*. 2011;**39**:1557-1568
- [9] Gomoll AH, Yoshioka H, Watanabe A, et al. Preoperative management of cartilage defects by MRI underestimates lesion size. *Cartilage*. 2011;**2**(4):389-393
- [10] Figueroa D, Calvo R, Vaisman A, et al. Knee chondral lesions: Incidence and correlation between arthroscopic and magnetic resonance findings. *Arthroscopy*. 2007;**23**:312-315
- [11] Deirmengian CA, Dines JS, Vernace JV, Schwartz MS, Creighton A, Gladstone JN. Use of a small-bore needle arthroscope to diagnose intra-articular knee pathology: Comparison with magnetic resonance imaging. *American Journal of Orthopedics*. 2018 Feb;**47**(2). DOI: 10.12788/ajo.2018.0007
- [12] Voight JD, Mosier M, Huber B. In-office diagnostic arthroscopy for knee and shoulder intra-articular injuries its potential impact on cost savings in the United States. *BMC Health Services Research*. 2014;**14**:203

