

We are IntechOpen, the world's leading publisher of Open Access books Built by scientists, for scientists

6,900

Open access books available

186,000

International authors and editors

200M

Downloads

Our authors are among the

154

Countries delivered to

TOP 1%

most cited scientists

12.2%

Contributors from top 500 universities



WEB OF SCIENCE™

Selection of our books indexed in the Book Citation Index
in Web of Science™ Core Collection (BKCI)

Interested in publishing with us?
Contact book.department@intechopen.com

Numbers displayed above are based on latest data collected.
For more information visit www.intechopen.com



Preoperative Planning of Total Hip Arthroplasty

Aamir H. Shaikh

Additional information is available at the end of the chapter

<http://dx.doi.org/10.5772/intechopen.76368>

Abstract

Preoperative planning is a crucial step towards a successful hip replacement. It is approached in five easy steps that includes a comprehensive history and examination, ordering weight bearing standardized radiographs, assessment of patients for fitness in the pre-assessment clinic, choosing the best implants as per individual case basis along with choosing method of implantation and templating the radiographs before starting the procedure to replicate the patient joint anatomy for the best patient outcome and to restore hip joint biomechanics. This further allows anticipating difficulties and pitfalls prior to surgery and thereby reducing the risk of complications associated with the hip replacement surgery.

Keywords: preoperative, planning, hip arthroplasty, results, templating

1. Introduction

Total hip arthroplasty (THA) provides an excellent pain relief and improvement in functional capacity along with improvement in the objective performance scores in patients with established debilitating arthritis of the hip joint. The success of the above treatment is multifactorial including proper patient selection, preoperative procedure planning and surgeons ability to perform a satisfactory procedure that restores the biomechanics of the hip joint [1, 2]. The outcome is limited by the fact that no single prosthesis is suitable for all patients due to personal patient factors including variation in bone quality, bone anatomy, patient activity level and the postoperative expectations of the patient. However, with thorough preoperative planning, these goals are achievable while minimizing perioperative risks and complications.

A famous quote of an American polymath, a scientist Benjamin Franklin is, "By failing to prepare, you are preparing to fail." This is why preoperative planning is a vital step in the actual total hip arthroplasty.

2. Preoperative planning

Preoperative planning is presented here as a five step process that begins with the introduction of surgeon to the patient. These steps include:

- Obtaining meticulous history and examination.
- Ordering appropriate investigations including weight-bearing X-ray.
- Assessment of the patients for fitness in the pre assessment clinics.
- Selection of the most appropriate implants as per patient's need and anatomy along with the method of implantation of prosthesis.
- Templating procedure to help accurately size the implants before start of the procedure.

2.1. Obtaining meticulous history and examination

There is no substitute of a thorough history and examination, which will make a clinician to arrive at a working diagnosis of arthritis of the hip joint. Bear in mind radiculopathy pain can also present as pain surrounding gluteal region and thigh and has to be excluded by examination. It is a good practice to both subjectively and objectively determine patient's loss of function on Harris Hip score [3] and its impact on the quality of life using SF36 [4] or other acceptable scores of reporting system.

Patient past medical history should be obtained including significant comorbidities of other body systems as this will help clinician to obtain further assessment of patient body reserve prior to major surgery and in obtaining risk assessment which will help the clinician to optimize these risk beforehand and on occasion to book a special care bed post-surgery in a high dependency unit (HDU) to facilitate proper patient care.

Further, it is vital to obtain from patient history of medical comorbidities, which could have a serious bearing on response to healing after surgery like diabetes and immune deficiency states e.g. steroid use and liver or kidney disorders.

Medication history with any known allergies has to be documented and assessed carefully. This include allergy to any metal type or latex material. Antiplatelet medication like clopidogrel need to be assessed by cardiologist to consider holding it a week before planned surgery, as this would otherwise increase the risk for perioperative bleeding with increased incidence of transfusion. Likewise anticoagulant medication will all need to be assessed for their indication of use and consideration given for holding them if possible otherwise bridging them with a low molecular weight heparin.

Past surgical history with anesthesia given in the past helps to identify additional knowledge of patient's response to prior anesthetic medication and their tolerance. Further, any issues with spinal problems or previous spinal surgeries will require evaluating safety of the spinal anesthesia. Likewise any prior incisions at the operative area will require surgeon to carefully plan their surgical site incision, as this will create a flap with its healing problem if

not selected properly. Any past surgical procedure with its effect should be determined that could possibly increase the risk of prosthetic joint infection as colostomy, ileostomy or urinary conduit close to the operating site.

During robust clinical examination attention is paid to findings like fixed flexion deformity (FFD), leg length discrepancy (LLD), gait assessment including Trendelenburg or antalgic gait. Skin condition of the leg been operated is of paramount importance and any signs suggestive of severe eczema or infection should need to be addressed before the surgery itself. Likewise vascular status should be properly assessed and documented.

Patient's body mass index (BMI) is an important assessment parameter as obese population is at higher risk for prosthetic joint infection (PJI) and other wound problems post-surgery.

2.2. Ordering appropriate investigations including weight-bearing X-ray

It is prudent to obtain weight-bearing radiographs of the patient that accurately assess patient's anatomy with measurable dimensions of the bone. If there are concerns with alignment or limb length discrepancy then obtain long leg radiographs. Consider putting blocks under short leg, as this will correct pelvic obliquity from the effect of limb shortening.

In essence good quality radiographs that will show square pelvis with standardized magnification are essential for preoperative planning. The typical views include an anteroposterior (AP) pelvis along with AP views and Lowenstein lateral views of the affected hip. The AP views are obtained with legs internally rotated by 15–20° (**Figure 1**). This allows assessment of the neck shaft angle; the lateral hip offset and helps in comparison with the opposite unaffected hip.

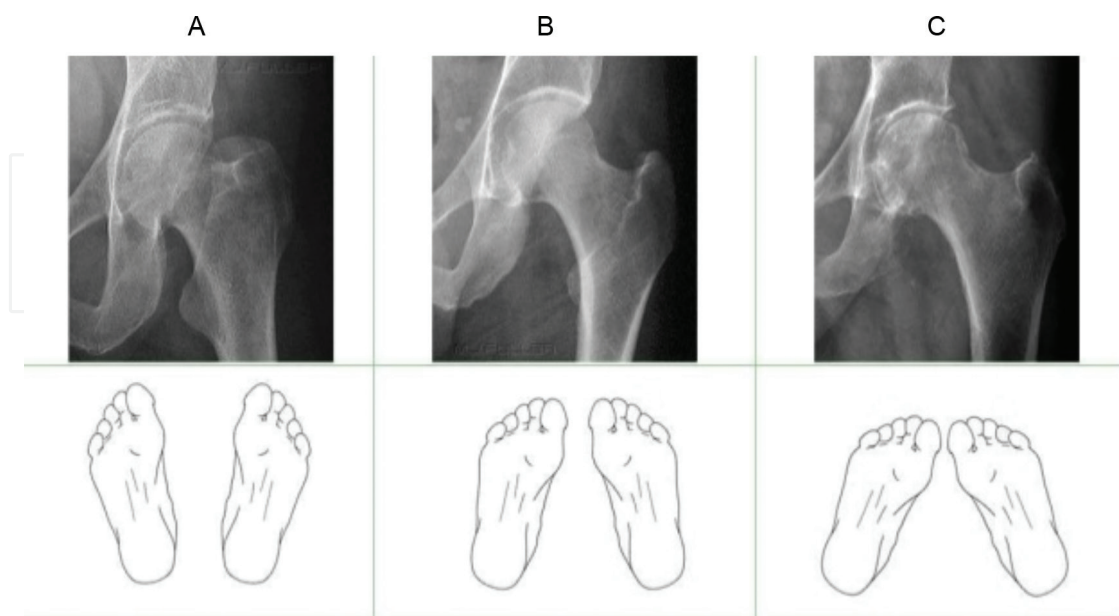


Figure 1. Hip X-ray taken with leg in (A) External rotation, (B) Internal rotation (C) extra internal rotation over 15–20°. (B) is considered optimum image.

2.3. Assessment of patients for fitness in the pre assessment clinics

The investigations obtained for determining anesthetic suitability starts with the blood work up. These include full blood count (FBC), renal function test (U&E), fasting blood glucose, coagulation profile, liver function test (LFT) if required. Other tests if needed in special circumstances will be ordered as per need like sickle cell test for certain African population, C-reactive protein (CRP) in infection cases. Blood group and hold is valid for few weeks and should be ordered if pre assessment of patient will lead to surgery promptly within acceptable time frame. Recently, there has been increased use of Tranexamic acid to prevent per operative bleeding and also the use of autologous blood transfusion by using cell saver preoperatively for long and complex primary and revision hip replacement cases.

Patient electro cardio graph (ECG) should be obtained with a recording of 12 lead ECG in this clinic appointment.

If patient is over 60 years of age and those under 60 years but smokers and those with respiratory conditions, obtain a base line chest X-ray. Consider repeating weight bearing joint X-ray if the earlier X-rays are over 12 months old for looking into any interim progress in the arthritic pattern.

2.4. Selection of the most appropriate implants as per patient's need and anatomy along with the method of implantation of prosthesis

Several factors are considered in selecting an appropriate implant. The patient's age and activity level are important. Other factors most important in consideration for choosing implants are national joint registry 10 years implant survival results published annually [5] and orthopedic data evaluation panel (ODEP) level rating [6], which depends on the revision rate in 10 years follow up.

Generally speaking the younger and more active patients are considered to have the highest physical demand; for them cement-less implants and some of the new bearing surface like ceramic head should be considered. On the contrary for older subjects with less activity profile or low demand patients treatment with hybrid THA along with the use of traditional bearing surface like metal on poly should be preferred.

The quality of bone is another factor that influences the method of implant fixation. Medullary canal configuration, as described by Noble et al. [7] by calculating the ratio of femoral canal width 20 mm proximal to the lesser trochanter in relation to the width of the canal at the femoral isthmus (**Figure 2**). This ratio is called canal flare index (CFI). If this ratio is less than 3.0, the canal has stovepipe configuration and the best implant fixation is by utilizing cementing technique. If this ratio is greater than 4.7, the femoral canal then has a champagne flute configuration and will require meticulous reaming to safeguard risk of periprosthetic fracture. Wider population has a ratio of 3.0–4.7, which is considered normal and may benefit from cement less implants if the cortex is simultaneously thick.

Next, the extent of arthritic involvement in the joint itself can influence the type of implant selection. Example, isolated femoral head wear with various stages of avascular necrosis (AVN) of the femur head, some surgeon will prefer a resurfacing hemiarthroplasty (**Figure 3**).

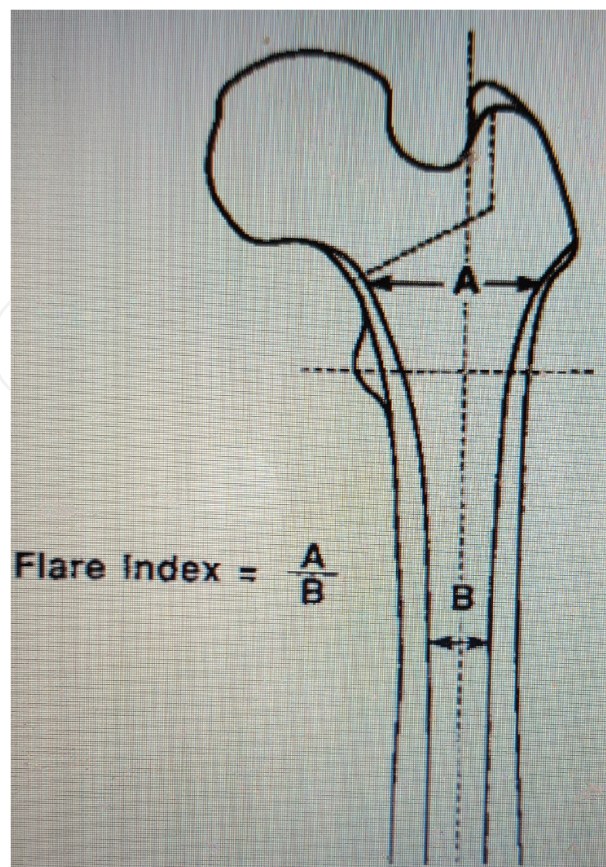


Figure 2. Canal flare index as described by Noble et al. [7].

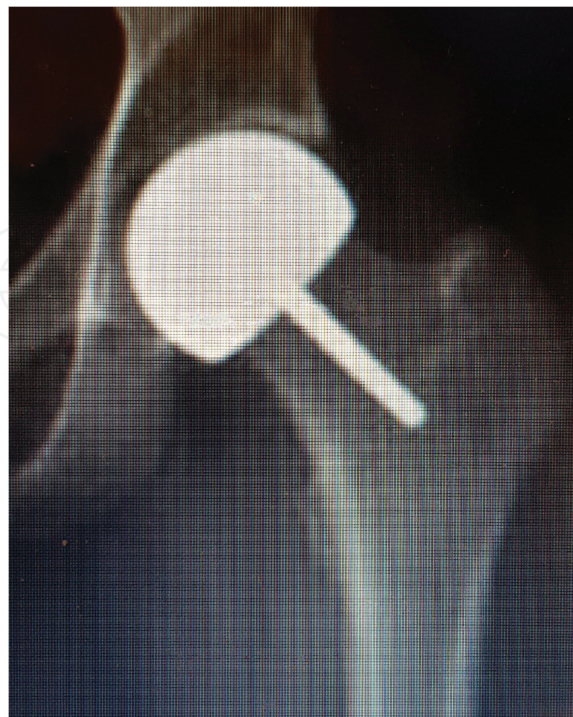

Figure 3. Resurfacing hemiarthroplasty for selected patients with isolated femoral head involvement from AVN.

In cases where proximal femur is excessively anteverted like development dysplasia of hip (DDH) population, the surgeon may prefer to use modular (**Figure 4**) or custom made prosthesis that will allow to adjust for extra anteversion when cement less implant system is used.

Further, on the acetabular side a protrusio configuration (**Figure 5**) can be accommodated with a deeper profile acetabular component. Acetabular protrusion is an anatomical finding encountered in cases of rheumatoid arthritis, ankylosing spondylitis, Paget's disease and in patients with severe osteoporosis with bone stock deficiency. Radiographic assessment of protrusio acetabulum is established by finding the extent of femoral head displacement medially relative to Kohler's line (ilioischial line) or can be defined by a center edge angle (CEA) of Wiberg exceeding 35° . This deformity is corrected by restoring the center of acetabular rotation to the correct anatomical position. During surgery any medial side reaming of the acetabular floor should be avoided. Acetabular component fixation is then achieved by good peripheral rim contact with the acetabular bone. Any associated medial wall defect can then be filled with autologous bone graft or by utilizing deeper profile acetabular cup that should be arranged preoperatively.

In nutshell it is prudent to define any anatomical distortion, whether on the femoral or acetabular side.

2.5. Templating procedure to help accurately size the implants before start of the procedure

Hip joint templating requires anticipating the size and position of the implants before the actual hip surgery is undertaken. Both Charnley [8] and Müller [9] emphasized the importance of preoperative templating utilizing radiographs in determining the type and size of prosthesis.

Preoperative planning for THA is performed by superposing acetate template drawings on the standardized AP radiographs of the hip using hard copies X-rays [10, 11], while other surgeons have favored using digital templating [12]. An old misconception, which some surgeons

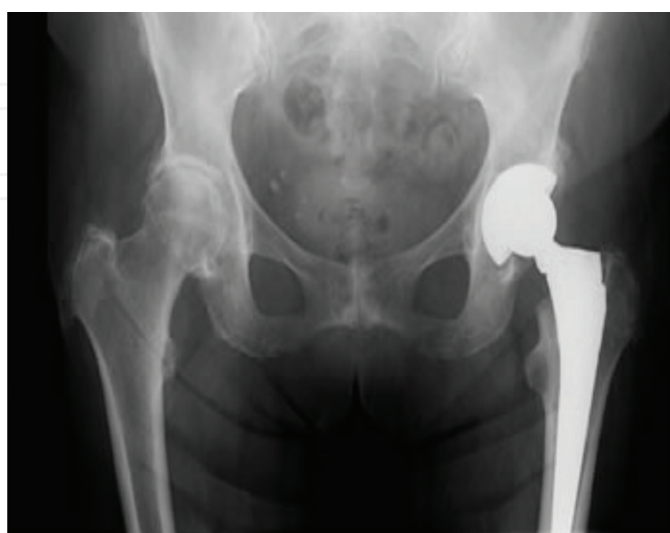

Figure 4. Modular THR for adjusting extra anteversion of the femur.

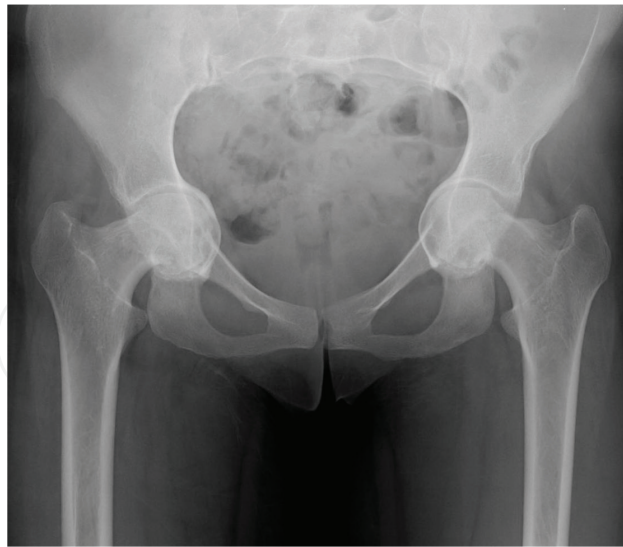

Figure 5. Protrusio acetabulum requiring marginal reaming with bone grafting on the floor of the acetabulum together with fitting a deeper profile cup.

hold about templating process, is that it only helps to guess about the size of the acetabular and femoral components. In reality this becomes difficult and inaccurate, as radiographs are a projection of three-dimensional structure. Many other factors like image magnification [13, 14] and distortion due from projection has also likely to play its role.

It is important to remember from literature that accurate prediction for a cup size is found in between 16 and 62% [11, 14, 15] while stem size accurate prediction is found in between 30 and 69% [11, 15] those accounting for cemented stem up to 78% [14] while cement less stem up to 42% [14]. More importantly, templating is more accurate in predicting within a range of \pm one size, for cup and stem size 52–98% [11, 15]. While its accuracy to predict hip offset is reasonably better in between 58 and 91% [11, 15].

Templating process does not only help to predict the implant size but its major benefit lies in helping an operating surgeon to estimate the position and insertion depth of both components to reproduce hip biomechanics. This also helps surgeon to anticipate any potential difficulties with the available implants.

To begin with this process, standardization of the magnification of hip and pelvis X-rays are of paramount importance. This can be achieved by calibration object of known magnification. Ideally a metal sphere of known dimension is placed at the level of the hip joint in the AP plane, in order to achieve same magnification. The best place is considered to be close to the pubis between the patient's legs and in the plane of greater trochanter [16].

A systematic five-step approach is recommended to proceed for smooth planning during templating process of the hip joints before surgery.

- A. Anatomical landmarks identification.
- B. Analyzing quality of the radiograph.

- C. Choosing mechanical references.
- D. Implant selection and positioning.
- E. The templating task.

2.5.1. Anatomical landmarks identification

To qualify as an anatomical landmark, it must be simple to identify them both on X-rays and simultaneously, while looking at the surgical specimen. At the acetabular side, the roof and the teardrop are adequate landmarks. Importantly acetabular roof is easy to identify at its supero-lateral corner during procedure. The teardrop is radiographic marker formed by superposition of the most medial part of acetabulum distally along with anterior and posterior horn of the acetabulum [17]. The main anatomical concept, which applies for the teardrop, is that it actually corresponds to the most distal and medial part of the acetabulum, that sits behind the transverse acetabular ligament (TAL) and at the superior border of the obturator foramen (OF) (**Figure 6**).

While on the femoral side, recognition of the anatomical reference landmarks include identifying greater trochanter (GT), Lesser trochanter (LT), the medullary canal (MC) and the sloppy saddle (SS) where distally the lower aspect of the neck meets greater trochanter (**Figure 6**).

2.5.2. Analyzing quality of the radiographs

Properly exposed, high quality standardized AP radiographs with set magnification are prerequisite for hip joint templating (**Figure 6**). Although this looks simple but it is a real challenging

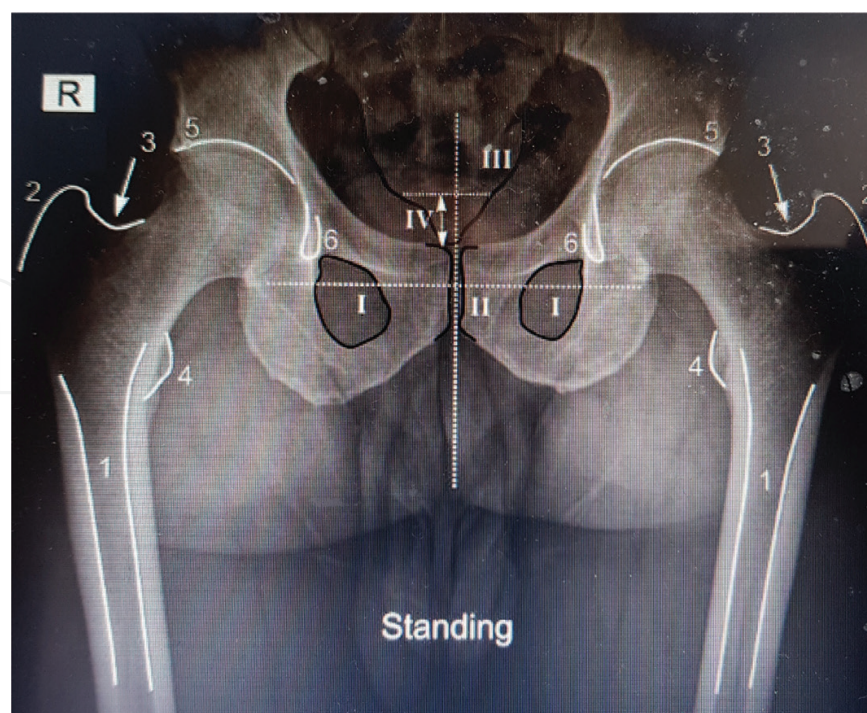


Figure 6. Standing AP hip X-rays suitable for templating. Anatomical Landmarks: (1) femoral medullary canal; (2) greater trochanter; (3) saddle; (4) lesser trochanter; (5) acetabular roof; (6) teardrop; (I) obturator foramina; (II) symphysis pubis; (III) sacrococcygeal joint; (IV) distance to measure for pelvic tilt observation.

task in our modern day practice for acquiring proper exposure. A low pelvis radiographs centered over pubis is preferred for hip templating. With this approach the entire proximal third of the femur is obtained. Pelvis should be kept square in an ideal radiograph. To gain insight into leg length discrepancy, pelvic tilt in both frontal and sagittal plane should be observed. To exclude this effect, keep the AP radiographs in standing position with iliac spines at the same distance bilaterally. This will be confirmed when the symphysis pubis is passing right through the middle of sacrum (**Figure 6**). To calculate sagittal tilt, distance between sacrococcygeal joint and the upper aspect of symphysis pubis is calculated. In neutral alignment it reflects a distance of 32 mm (range: 8–50 mm) in women and 47 mm (range: 15–72 mm) in men. This distance increases when pelvis is tilted forward and the reciprocal is true as well [18].

Another task is to determine femoral neck length (femur offset). To obtain real measurements both femurs should be kept about 15–20° of internal rotation (IR) corresponding to the femoral anteversion. This will highlight actual neck length and thus help in obtaining correct femoral offset (**Figure 7**) while radiographs obtained of femur with more or less IR will underestimate the true femoral neck length and thus femoral offset. Hananouchi et al. [19] highlighted that femoral rotation can be estimated by measuring lesser trochanter projection. By keeping femoral neck parallel to the film, the lesser trochanter is on the average 2.3 ± 3.1 mm broad. This means in most cases around 5 mm of lesser trochanter should be visible medially before attempting to calculate neck length and femoral offset.

2.5.3. Choosing mechanical references

Important mechanical references to determine include:

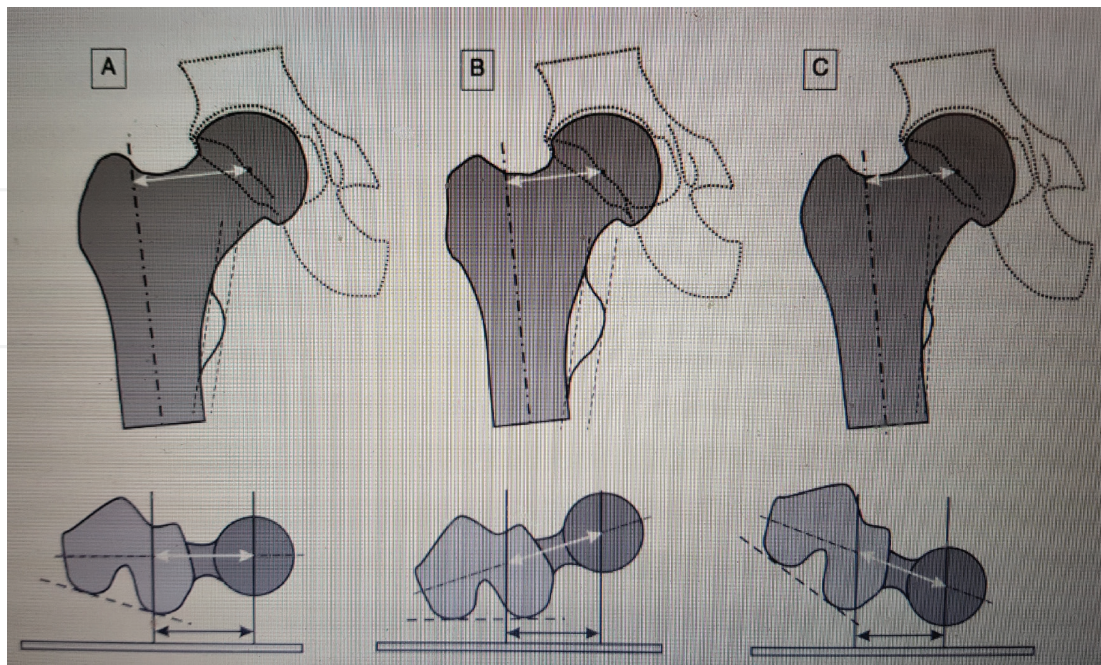


Figure 7. Femoral rotation influence on neck length. (A) IR corresponding to 15–20° with measuring neck length and femoral offset. (B) Femur kept in neutral position underestimating neck length and offset. (C) Femur kept in excessive IR also has same effect in underestimating neck length and femoral offset.

2.5.3.1. Hip, femoral and acetabular rotation Center

The hip joint rotation center is the central point around which all hip joint movement occurs. If the acetabulum and femoral head are concentric, then realistically their center of rotation projects on the hip joint center of rotation. As such, the hip rotation center can be easily found as the center of a circle fitted to the projection of the femoral head (**Figure 8**).

On the other hand, if the hip joint is deformed due from dysplastic cup or femoral head dysplasia then it makes very difficult to find hip joint center as its position may vary during hip joint movements. To make such situation easier we will define the “original rotation center” where the native femoral head and acetabulum rotates on the centers before the deformity occurs. This can be usually identified on the preserved inferior one-third of the femoral head and the preserved part of the acetabulum (generally the teardrop and the medial wall). Applying both rotation centers on each other, will likely give a good idea of the native hip joint center of rotation before appearance of the secondary changes.

2.5.3.2. Femoral, acetabular and combined offset

The femoral offset is defined as the least distance between the femoral head center of rotation and the longitudinal axis of the femur [20]. The longitudinal axis of femur is drawn as a line in the middle of projected femoral canal. In cases of dysplastic femoral head, the original

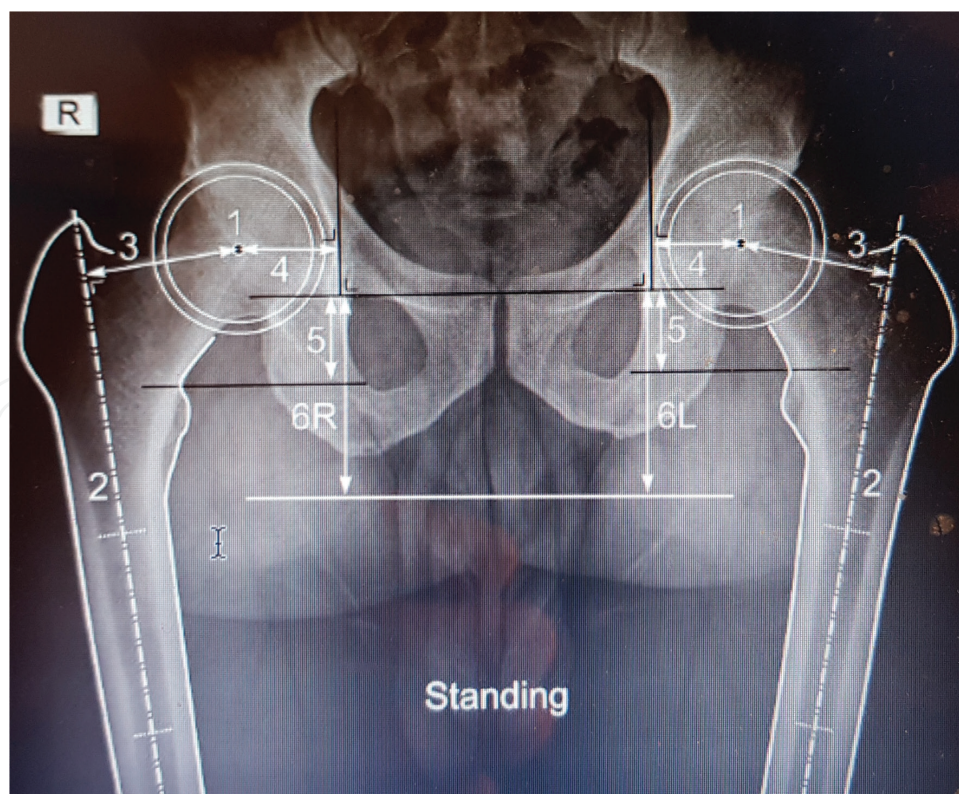


Figure 8. Mechanical landmarks: (1) hip rotation center; (2) longitudinal axis of proximal femur; (3) femoral offset; (4) acetabular offset; (5) hip length; (6) LLD is calculated as difference between distances 6R and 6L.

femoral offset can be estimated between original femoral center of rotation and the longitudinal axis of the proximal femur. Remember femoral offset calculation depends on leg rotation and inevitably it will under estimate femoral offset if the neck is not kept parallel to the radiographic film (**Figure 7**).

Acetabular offset is defined as the distance between acetabular center of rotation and a vertical line drawn through the teardrop. If acetabulum is dysplastic then the original acetabular offset can be found in the same way except replacing hip center of rotation with the original acetabular center of rotation by considering tear drop segment of acetabulum reflecting true acetabular landmark.

The combined hip offset is defined as the cumulative sum of the femoral and acetabular offset. This parameter is important as it bears the tension in hip abductor muscles along with the soft tissues as it controls relative position of greater trochanter with respect to the pelvis.

2.5.3.3. Leg length versus hip length

The “leg length” is defined by measuring distance between a fixed reference point on the pelvis, ideally teardrop inferior edge and the floor where heel lies on the ground. In real sense this measurement is not possible as the floor is not visible on any single radiographic image.

The “hip length” is defined by measuring distance between teardrop inferior edge and a horizontal line through a fixed point on the proximal femur like upper part of the lesser trochanter (**Figure 8**). Remember hip length is influenced by position of the hip in flexion/extension or abduction/adduction therefore, both hips should be kept in a similar position to determine hip lengths and simultaneously to help determine in “hip length discrepancy.”

2.5.4. Implant selection and positioning

After labeling of the anatomical landmarks on standardized radiograph and choosing the mechanical reference points, an ideal fitting implant size is chosen for both the acetabular and the femoral component. Our aim is to restore the original hip anatomy and biomechanics. However in certain cases it is not feasible and compromise has to be considered.

2.5.5. The templating task

If the pathological hip undergoing surgery for arthritis is anatomically acceptable then it is preferred to have templating performed on it otherwise it will be technically difficult and a substitute choice should be to template contralateral hip to determine the implant sizes for the operative hip.

2.5.5.1. Positioning: aim to restore the native hip anatomy and biomechanics

First, acetabular cup is selected to fit the acetabular cavity based on line to line reaming or press fit technique to restore the native acetabular center of rotation. Acetabular component should be templated with an abduction angle of 40–45° between longitudinal axis of the cup

and the teardrop [21], while template still kept in its position, cup insertion depth compared to the medial acetabular wall, the insertion height compared to the inferior border of the teardrop and the cup margins sitting on the superolateral border of the acetabular roof is noted. These anatomical reference marks are easily identifiable during surgery and will help in restoring original hip anatomy. In cases of protrusio acetabuli, planning is made for lateralizing the acetabular component while grafting the medial acetabular wall will help restoring the acetabular center of rotation thereby avoiding impingement [1]. In dysplastic hips, our goal again is to restore acetabular center of rotation. However, as the acetabulum is often secondarily deformed and shallow, obtaining superolateral roof coverage is a challenging task. This may require consideration for bone grafting or at times will require an additional use of shell and mesh to reconstruct the superolateral defect [1].

Secondly, a femoral implant is selected to fit the medullary canal based on the trial implant size. The longitudinal axis of the implant should be following the longitudinal axis of the femur, while approximate insertion depth is chosen to correctly restore the leg or the hip length. Three techniques are available to achieve the native femoral center of rotation and the femur offset.

- i. Lateralizing or medializing the femur by choosing standard versus high offset stem.
- ii. Modifying the size of the femoral head component.
- iii. Choosing a stem with different neck shaft angle.

Opting between a standard or high offset stem is an easy option as it has no effect on the leg and hip length while the other options does influences on the hip length. By opting to use a stem with less neck shaft angle, compromise is made on the hip length, which can be adjusted by the use of increase in head size or by keeping the stem proud. Using a large size femoral head component will increase both femur offset and hip length and thus will require a more distal stem insertion to control hip length.

More importantly, if a radiograph is obtained with leg in altered rotation. This will impact in determining adequate hip offset and should always be born in mind while decision is made on choosing right offset for the involved hip.

With templating, an appropriate neck cut and its orientation can be planned along with the insertion depth of the stem prosthesis.

2.5.5.2. Equating a balance when failure to restore the native hip anatomy

When it becomes impossible to restore adequate native hip anatomy in that scenario it becomes ideal to restore the combined femoro-acetabular offset and the hip length. When acetabular offset is decreased and hip rotation center is medialized then it becomes prudent to increase the femoral offset. Likewise, increasing the acetabular offset can compensate loss of the femoral offset. This will maintain the soft tissue tension between pelvis and the proximal femur and thus hip abductor function will be optimized.

Similarly, keeping stem more or less proud can compensate for a low or high set hip center of rotation.

Soft tissue balancing is of paramount importance when our goal is to increase or decrease in the leg length. When considering lengthening it is vital to consider for decreasing combined femoro-acetabular offset by medializing the cup or reducing femoral offset by using low offset stem. On the contrary, when planning shortening of the leg, it would be best to consider increasing combined hip offset to minimize the risk of dislocation and gluteal muscle weakness due from lack in the soft tissue tension.

2.5.5.3. *Challenges in tackling extreme varus and valgus hips*

In a varus hip, with its excessive femoral offset, surgeon can help restore the native anatomy by using high offset stem combined with a large head. To avoid with increase in the leg length with these choice of implants, surgeon may plan a distal neck osteotomy together with low stem insertion. Rarely, this may be benefited further if required with the use of large cup positioned laterally as possible or by using a lateral cup insert thereby helping in increasing acetabular offset. This will restore correct soft tissue tension. However, this increase in the acetabular center of rotation should be opted as the last resort as it increases the acetabular loading [20].

In a valgus hip, with its associated reduced combined hip offset should be respected as over stretching the soft tissues by increase the hip offset could lead to trochanteric bursa pain. This can be maintained by an attempt in medializing the cup. This further helps in reducing the mechanical load at the acetabular component and optimizing abductor function by improving femoral offset [20]. If femoral offset needs to be reduced further, a low offset stem combined with short head should be considered. However, this will require leaving the stem proud if it shortens the leg length.

3. Newer innovation in preoperative planning

Complex primary hip cases involving dysplasia at either side of the joint, trauma cases with fractures requiring arthroplasty, ankylosing spondylitis, protrusio cup and revision hip cases are a big challenge for arthroplasty surgeons. Rapid prototyping (RP) is a new concept adopted from industrial designing. This involves laying down series of additional layers of a material to regenerate a 3D model. Computer aided designing (CAD) program enables rapid production of a component with super accuracy [22]. This model is adopted in medical specialties including orthopedics to develop accurate replica of a body part in cross-section using CT scan as an input source. They are further printed using layered material to generate a 3D-printing model. This rapid prototype model provides a unique opportunity in preoperative planning, in terms of understanding deformity pattern, providing intraoperative referencing and surgical simulation. This further helps an arthroplasty surgeon for inventory planning as they can order necessary implants to make their availability on the day of surgery. This will save time during surgery and minimize on table bleeding, infection rate and thereby patient morbidity.

3.1. Customized instruments and implants

With advancement in the modern day technology, patient specific instruments can be obtained by using rapid prototyping [23]. This will aid in complex cases and will aid in improvement

in operative results. In future more customized implants will be developed to use for the individual case demand that will fit for the purpose and will have better survival outcome for our patients by improving joint kinematics.

4. Conclusion

Preoperative planning is an important step in the actual delivery of joint replacement as it allows the patient to go through a comprehensive assessment and preparation for undertaking joint replacement in a schematic fashion. This begins with a thorough clinical assessment by their operating surgeon and a series of investigations followed by actual planning of their hip joint replacement, utilizing template on their standardized radiographs. Templating process allows assessment of their anatomical landmarks to mark as reference points while implanting prosthesis with correct depth. This will allow the surgeons to restore hip biomechanics and thereby improving post-surgical outcomes. This will further allow anticipating difficulties and pitfalls prior to surgery.

Some surgeons do not like to proceed with this important step of templating prior to their joint replacement surgeries. However, unless it is done systematically, it might be difficult, even for the experience hip surgeons to identify those hips, which will definitely benefit from a proper anatomical and mechanical assessment. Moreover, these less planned cases without templating are at increase risk to suffer inadequate hip biomechanics and higher complication rates including trendelenburg gait, joint dislocation, significant leg length discrepancy, peri prosthetic fracture and trochanteric pain. It has been proven to have similar efficacy of preoperative templating by the junior surgeons in training as their senior counter parts [11]. Thus it makes it a legitimate cause for carrying out this vital process of templating of the hip joint prior to actual implantation of the prosthesis. In crux this will improve the long-term outcome and patient satisfaction in both subjective and objective manner [3, 4].

Author details

Aamir H. Shaikh

Address all correspondence to: draamir@mail.com

North Middlesex University Hospital, London, United Kingdom

References

- [1] Blackley HRL, Howell GED, Rorabeck CH. Planning and management of the difficult primary hip replacement: Preoperative planning and technical considerations. Instructional Course Lectures. 2000;49:3-11

- [2] Capello WN. Preoperative planning of total hip arthroplasty. *Instructional Course Lectures*. 1994;**43**:323-327
- [3] Harris WH. Traumatic arthritis of the hip after dislocation and acetabular fractures: Treatment by mold arthroplasty. An end-result study using a new method of result evaluation. *The Journal of Bone and Joint Surgery. American Volume*. 1969 Jun;**51**(4):737-755
- [4] 36-Item Short Form Survey from the RAND Medical Outcomes Study. RANDHealth. Available from: http://www.rand.org/health/surveys_tools/mos/mos_core_36item.html. [Accessed Nov 5, 2014]
- [5] Available from: <https://www.hqip.org.uk/media/NJR%2014th%20Annual%20Report%202017.pdf>
- [6] Available from: www.odep.org.uk/.../0/ODEPStatements/ODEP%20Benchmarks%202017_rev.6.pdf
- [7] Noble PC, Alexander JW, Lindahl LJ, et al. The anatomic basis of femoral component design. *Clinical Orthopaedics*. 1988;**235**:25-34
- [8] Charnley J. *Low friction arthroplasty of the hip*. Vol. 246. Berlin: Springer Verlag; 1979
- [9] Müller ME. Lessons of 30 years of total hip arthroplasty. *Clinical Orthopaedics*. 1992; **274**:12-21
- [10] Iorio R, Siegel J, Specht LM, et al. A comparison of acetate vs. digital templating for preoperative planning of total hip arthroplasty is digital templating accurate and safe? *The Journal of Arthroplasty*. 2009;**24**:180
- [11] Kearney R, Shaikh AH, O'Byrne JM. The accuracy and inter-observer reliability of acetate templating in total hip arthroplasty. *Irish Journal of Medical Science*. 2013 Sep;**182**(3):409-414
- [12] Gamble P, Beer JD, Petrucci D, et al. The accuracy of digital templating in uncemented total hip arthroplasty. *The Journal of Arthroplasty*. 2010;**25**:529-532
- [13] Conn KS, Clarke MT, Hallett JP. A simple guide to determine the magnification of radiographs and to improve the accuracy of preoperative templating. *Journal of Bone and Joint Surgery*. 2002;**84-B**:269-272
- [14] Knight JL, Atwater RD. Preoperative planning for total hip arthroplasty. Quantitating its utility and precision. *The Journal of Arthroplasty*. 1992;**7**:403-409
- [15] Della VAG, Comba F, Taveras N, et al. The utility and precision of analogue and digital preoperative planning for total hip arthroplasty. *International Orthopaedics*. 2008;**32**: 289-294
- [16] Wimsey S, Pickard R, Shaw G. Accurate scaling of digital radiographs of the pelvis. A prospective trial of two methods. *The Journal of Bone and Joint Surgery*. 2006;**88**:1508-1512
- [17] Bowerman JW, Sena JM, Chang R. The teardrop shadow of the pelvis; anatomy and clinical significance. *Radiology*. 1982;**143**:659-662

- [18] Siebenrock KA, Kalbermatten DF, Ganz R. Effect of pelvic tilt on acetabular retroversion: A study of pelvis from cadavers. *Clinical Orthopaedics and Related Research*. 2003; **407**:241-248
- [19] Hananouchi T, Sugano N, Nakamura N, et al. Preoperative templating of femoral components on plain X-rays. *Archives of Orthopaedic and Trauma Surgery*. 2007; **127**:381-385
- [20] Charles MN, Bourne RB, Davey JR, et al. Soft tissue balancing of the hip. The role of femoral offset restoration. *Journal of Bone and Joint Surgery*. 2004; **86-A**:1078-1088
- [21] Wan Z, Boutary M, Dorr LD. The influence of acetabular component position on wear in total hip arthroplasty. *The Journal of Arthroplasty*. 2008; **23**:51-56
- [22] Torabi K, Farjood E, Hamedani S. Rapid prototyping technologies and their applications in prosthodontics, a review of literature. *Journal of Dentistry*. 2015 Mar; **16**(1):1-9
- [23] Basalah A, Shanjani Y, Esmaeili S, Toyserkani E. Characterizations of additive manufactured porous titanium implants. *Journal of Biomedical Materials Research. Part B, Applied Biomaterials*. 2012 Oct; **100**(7):1970-1979