

We are IntechOpen, the world's leading publisher of Open Access books Built by scientists, for scientists

6,900

Open access books available

186,000

International authors and editors

200M

Downloads

Our authors are among the

154

Countries delivered to

TOP 1%

most cited scientists

12.2%

Contributors from top 500 universities



WEB OF SCIENCE™

Selection of our books indexed in the Book Citation Index
in Web of Science™ Core Collection (BKCI)

Interested in publishing with us?
Contact book.department@intechopen.com

Numbers displayed above are based on latest data collected.
For more information visit www.intechopen.com



Anatomic Single-Bundle ACL Reconstruction with Remnant Augmentation Technique

Adinun Apivatgaroon

Additional information is available at the end of the chapter

<http://dx.doi.org/10.5772/intechopen.76577>

Abstract

Anterior cruciate ligament (ACL) injury is the common ligamentous injury of the knees. An ACL reconstruction is the procedure that has been proven to improve knee stability and functional outcomes and may prevent the osteoarthritic changes and subsequent meniscal injuries. The ACL reconstruction techniques have been developed in various ways. Anatomical single-bundle ACL reconstruction with remnant augmentation technique is the optimal reconstruction procedure. It may improve the clinical outcomes of biological healing, preserve the proprioceptive function, and has shown less tibial tunnel widening postoperatively. This chapter presents the step-by-step technique of an anatomical single-bundle ACL reconstruction, indication and contraindication for surgery, the preferred graft choice, fixation methods, pearls and pitfalls of the procedure, and postoperative rehabilitation. The review of literatures about the remnant preserving ACL reconstruction is also discussed in this chapter.

Keywords: ACL reconstruction, remnant augmentation, anatomic single-bundle, preserving, the ACL remnant.

1. Introduction

Anterior cruciate ligament (ACL) injury is the common ligamentous injury of the knees, especially in active, healthy patients. An ACL reconstruction is the procedure that has been proven to improve knee stability and functional outcomes. Although there have been no clear benefits and prevention of osteoarthritic changes following ACL reconstruction [1, 2], some studies have proven that this operative procedure can prevent these changes and subsequent meniscal injuries [3, 4].

The ACL reconstruction techniques have been developed in various ways. These include single-bundle reconstruction, double-bundle reconstruction, selective bundle reconstruction, single-bundle reconstruction with remnant preservation, and double-bundle reconstruction with remnant preservation. With so many techniques, there has yet to be determined as to what is the best technique that provides the greatest stability and preserves knee functions (proprioceptive sensation, range of motion).

This chapter presents one optional ACL reconstruction technique that uses anatomic single-bundle anterior cruciate reconstruction with remnant augmentation. This technique is simple, has shown improved knee stability, may preserve the proprioceptive function, may accelerate cellular proliferation and revascularization of the grafted tendon, and has shown a lower incidence of tibial tunnel enlargement postoperatively.

2. The anatomic single-bundle anterior cruciate ligament reconstruction with remnant augmentation

The functional ACL bundles consist of two parts that include the anteromedial (AM) and the posterolateral (PL) bundles. The anatomical placement of the reconstructed ACL graft has similar forces as compared to the native ACL [5]. The different techniques for ACL reconstruction aim to perform as near a normal anatomic reconstruction as possible. The double-bundle reconstruction technique has become the more popular procedure. However, the double-bundle technique is more technically demanding and more costly and has limited evidence of superior results when compared with the single-bundle reconstruction technique [6]. The centrally placed anatomic single-bundle ACL reconstruction is the common operative procedure and has been proven to restore normal knee function [7, 8].

The ACL remnants are often found during arthroscopic ACL reconstruction of the knee (**Figure 1**). A previous study reported that the mechanoreceptors that are found in the ACL remnant may contribute to the proprioception of the knee [9] and provide some biomechanical stability of the knee [10]. An immunohistochemical study [11] on the morphology and the quantity of mechanoreceptors in 40 ACL reconstruction patients shows that the time from injury to surgery was negatively correlated with the number of total mechanoreceptors ($r = -0.52$, $p < 0.01$). This study emphasizes the role of the ACL stump or ACL remnant that has a role in the preservation of proprioceptive functions of the knee.

The ACL remnant is the tissue bridge between the tibia and either the posterior cruciate ligament (PCL) or the intercondylar notch. This remnant tissue maybe developed from the synovial scar, the remnant of the ACL, and the partial rupturing of the anteromedial (AM) or posterolateral ACL bundles. Although the injured knee has the remnant of the ACL, this remnant is often in an abnormal position and could not have the normal biomechanical functions identical to an intact ACL.

The remnant-preserving technique in ACL reconstruction was introduced in 1992 [12]. This procedure has theoretical advantages that include (1) possible promotion of the revascularization and the synovial coverage of the graft, (2) improvement of knee stability, (3) preservation

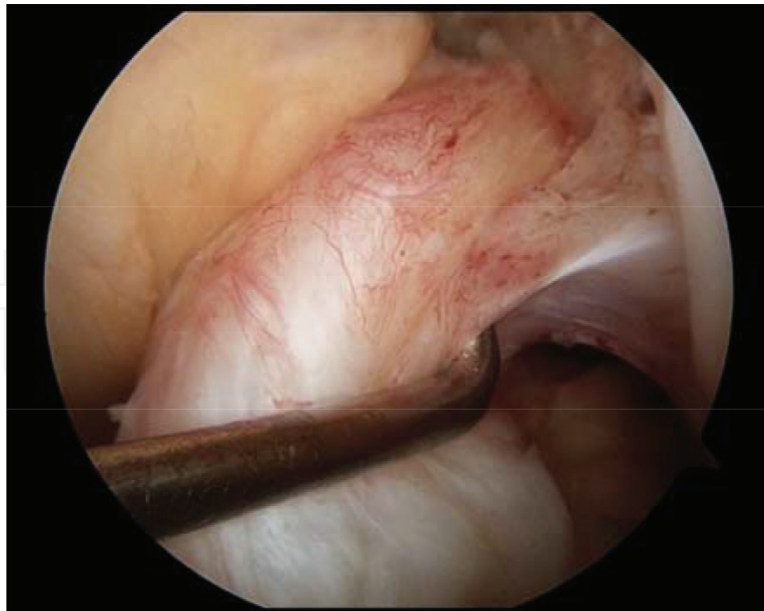


Figure 1. Arthroscopic view of the left knee from the anterolateral viewing portal. The ACL remnant was found and pulled with an arthroscopic probe during the arthroscopic ACL reconstruction surgery.

of the proprioceptive function of the knee, and (4) development of a lower incidence of tunnel widening postoperatively.

The ACL reconstruction with remnant augmentation has been developed in various ways. Some of these include:

1. Selective single-bundle reconstruction of the isolated ruptured bundle (AM or PL bundle): this technique is performed if the intact bundle remains attached at its anatomical origin.
2. Anatomic center, single-bundle reconstruction with remnant-preserving technique: this technique is indicated if both ACL bundles are completely torn but retain the ACL remnant in a nonanatomical position.
3. Anatomic double-bundle reconstruction with remnant-preserving technique: this technique might be indicated as in the anatomic center single-bundle reconstruction but has a near normal ACL and may provide more stability of the reconstructed knee.

A prospective, randomized controlled trial (RCTs) study [13] was evaluated in two groups. There were 45 patients with remnant-preserving ACL reconstruction, and these were compared with 45 patients who underwent a standard ACL reconstruction. Proprioception measurements were evaluated using a passive angle reproduction test with the Biodex detector (Shirley, New York) in 80 patients preoperatively and at the last follow-up appointment. There were no differences seen between both groups at the final follow-up (mean \pm SD, degree = 3.6 ± 1.8 in preservation group and 3.9 ± 2.2 in standard group, $p = 0.739$).

A systematic review of clinical outcomes of remnant-preserving augmentation ACL reconstruction [14] evaluated 13 studies including five RCTs, six case studies, and two retrospective cohort studies. The patients were 14–62 years of age and were treated with various

surgical techniques (the selective single-bundle reconstruction, remnant-tensioning technique, or remnant-sparing technique) using various types of grafts. The results showed that only two of the nine studies had exhibited a small significant side-to-side difference in the remnant-preserving groups. In the standard technique group, only 1 of 13 studies showed significant higher Lysholm scores in the remnant-preserving groups. Two of 13 studies showed significantly less tibial tunnel enlargement in the remnant-preserving groups. There were no significant reported complications in both groups (including the development of cyclops lesions).

The meta-analysis of the clinical outcomes of single-bundle ACL reconstruction with and without remnant preservation [15] in 6 RCTs, 378 patients (190 remnant-preserving patients, and 188 standard ACL reconstructions) had shown no significant differences in anterior stability, the pivot shift test, knee function scores, and the development of cyclops lesions. However, two RCTs from the remnant-preserving group had a lower percentage of tibial tunnel enlargement (obvious heterogeneity, $p = 0.067$, $I^2 = 70.3\%$). The percentage of tibial tunnel enlargement was $6.6 \pm 0.8\%$ vs. $2.4 \pm 0.3\%$ in one study and $34 \pm 8.9\%$ vs. $25.7 \pm 6.7\%$ in another study with significantly different results.

The study of the clinical outcomes with an arthroscopic reevaluation following ACL augmentation [16] in 216 patients with a mean age of 25 years (73 patients with single-bundle ACL augmentation, 82 of double-bundle reconstruction, and 61 of single-bundle reconstruction) had shown significantly better synovial coverage of the graft in the augmentation group (good 82%, fair 14%, poor 4%, $p = 0.039$). The side-to-side differences measured with the KT-2000 arthrometer were significantly better in the augmentation group than in the single-bundle reconstruction group (0.4 mm [-3.3 to 2.9] vs. 1.3 mm [-2.7 to 3.9], $p = 0.013$). Moreover, in the 62 patients who were with adequate synovial coverage had revealed significant improvement of the knee proprioception in three quarter motion measurements.

From previous studies, ACL reconstruction with remnant augmentation has shown comparable results with the standard ACL reconstruction. Although ACL reconstruction with remnant augmentation may not have proven to provide the benefits in terms of stability improvement, graft healing, proprioceptive functions, and clinical outcomes, this technique has significantly less tibial tunnel widening postoperatively and no greater incidence of complications. These complications include the occurrence of the cyclops lesions.

2.1. Surgical technique

This chapter shows the technique of anatomic center, single-bundle ACL reconstruction with remnant augmentation. Indications for this surgery are active patients with clinical instability from an ACL-deficient knee. The patients must have normal alignment of the lower extremity, have no advanced knee osteoarthritic changes, and should have good knee range of motion preoperatively (more than 90° arch of motion). Obvious knee stiffness, active infection, or the patients with skeletal immaturity are relative contraindications for this procedure. If the patients have a significant malalignment of the knee, corrective

osteotomy is indicated. The patients are evaluated for knee instability, with special attention to the anterior laxity using the anterior drawer, Lachman's test, and the pivot shift tests. The preoperative knee laxity was not an indicator of either the presence or lack of the presence of the ACL remnant. Associated knee pathologies such as ligamentous tears, meniscus lesions, or cartilage lesions are evaluated preoperatively. Magnetic resonance imaging (MRI) of the affected knee is obtained to evaluate the condition and associated pathologies of the ACL (**Figure 2**).

The patient is positioned supine with the operative knee flexed to approximately 90°. The procedure is done under spinal or general anesthesia depending on the patients' preference. The affected knee is draped and freely prepped from the proximal thigh to the foot. An arthroscopic examination is performed using standard anterolateral viewing and a standard anteromedial working portal (**Figure 3**). After cleaning the obstacles of fatty tissue and the ligamentum mucosum in the tibiofemoral compartment, the torn ACL and the ACL remnant are identified. Both menisci are then evaluated, and then the menisci are repaired or resected depending on the conditions found.

A quadruple semitendinosus autograft is harvested and prepared from the affected knee. The quadruple autograft length should be more than 6.5 cm, and the graft's diameter should be at least 7.5 mm. If the semitendinosus autograft is inadequate in size, an additional double or triple autogenous gracilis is also harvested. The EndoButton (Smith & Nephew, Andover, MA) is used for the graft's fixation point at the femoral side, and an interference screw (Smith & Nephew) is used for tibial fixation of the graft. Keeping in mind that the anatomic position of the tunnel is more important than the obstacle remnant of the ACL tissue, the femoral tunnel is created using a transportal technique from a standard anteromedial portal (**Figure 4**).

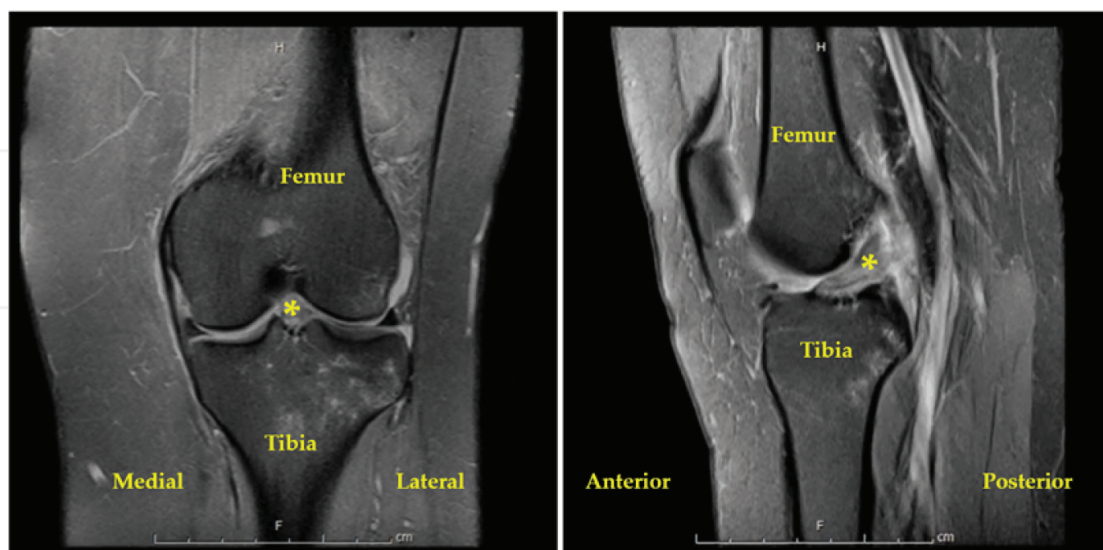


Figure 2. Preoperative MRI of the patient with ACL deficiency of the left knee reveals the increased signal intensity in the ACL fibers with the presence of a loose ACL remnant (yellow asterisk, *). The hypersignal of the lateral tibial plateau is represented by a valgus-impacted injury with bone bruise.

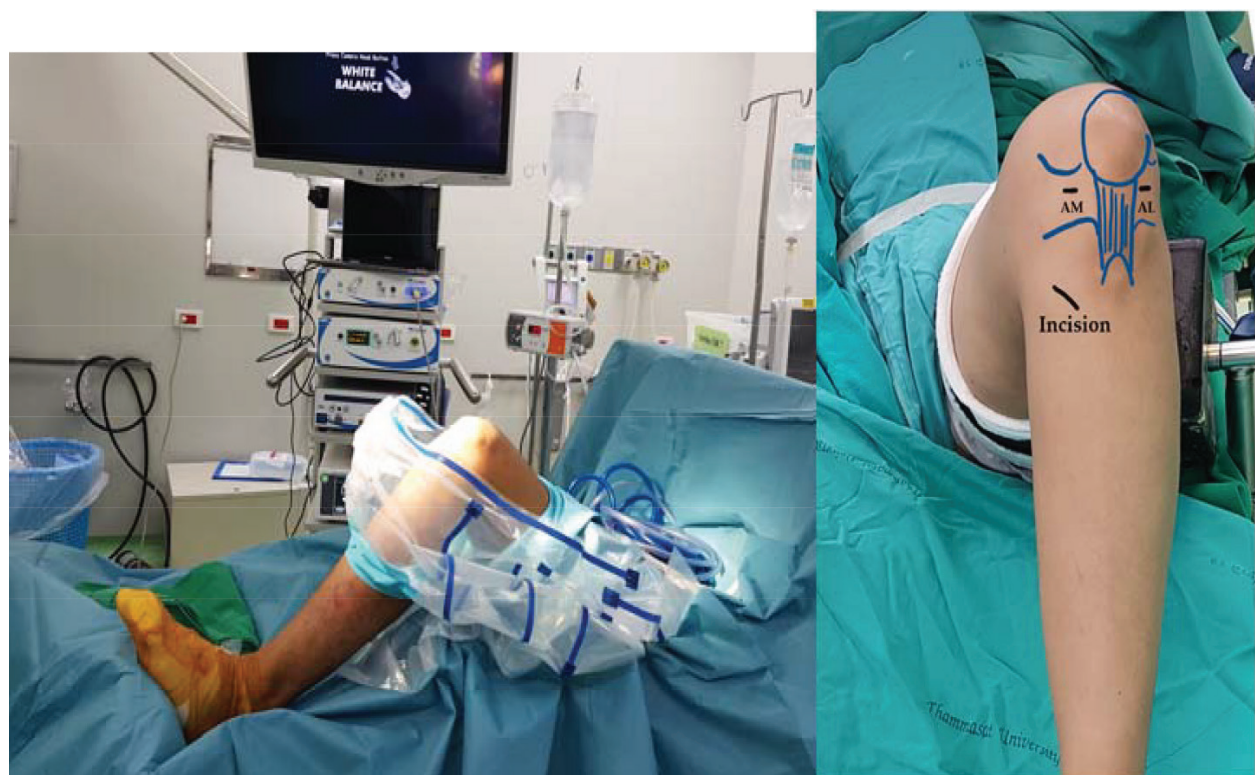

Figure 3. Patient positioning and placement of portals; the pictures show the positioning, preparation, and arthroscopic portals for arthroscopic ACL reconstruction of the left knee (AM, anteromedial portal; AL, anterolateral portal).

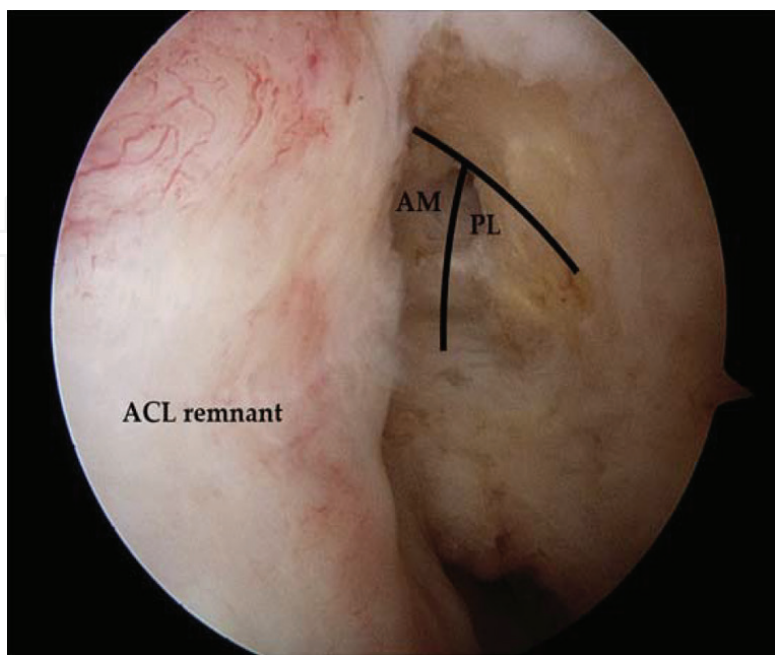


Figure 4. Arthroscopic view of the left knee from anterolateral viewing portal. After identifying the ACL femoral footprint, the femoral tunnel is created using the transportal technique from a standard anteromedial portal.

The medial femoral condyle is carefully protected during the creation of the femoral tunnel to avoid an iatrogenic cartilage injury [17]. The graft should be inserted within the femoral tunnel, and it should be at least 15 mm in length. Next, the tibial footprint of the ACL is identified. In this step, the ACL remnant at the tibial footprint often needs to be partially removed until obtaining the appropriated tibial footprint. The tibial tunnel is then created using a transtibial ACL guide pin (Acufex Director Drill Guide, Smith & Nephew) that is then inserted from a standard anteromedial working portal (**Figure 5**). If the position of the guide pin is not positioned through the center of the tibial footprint, an increment reamer is used to adjust the position of the guide pin [18].

After creating the femoral and tibial tunnels, the prepared autograft is passed from the anteromedial tibial cavity through the tibia and into the lateral intercondylar notch of the femur. The EndoButton is tested for possible dislodgement of the femoral cortex. Pretensioning of the ACL graft is performed, and the knee's motion is checked to evaluate of the graft position and the presence of an impingement (**Figure 6**). The ACL graft is then fixated at the tibia with an appropriately sized interference screw positioned eccentrically under adequate ACL graft tension in a position of nearly full extension of the operative knee (**Figure 7**). Postoperative radiographs are taken to evaluate the positioning of the implants and the femoral and the tibial tunnel positions (**Figure 8**). **Figure 9** represents the step-by-step process of a remnant-preserving ACL reconstruction of a 26-year-old woman with injury to her left knee.

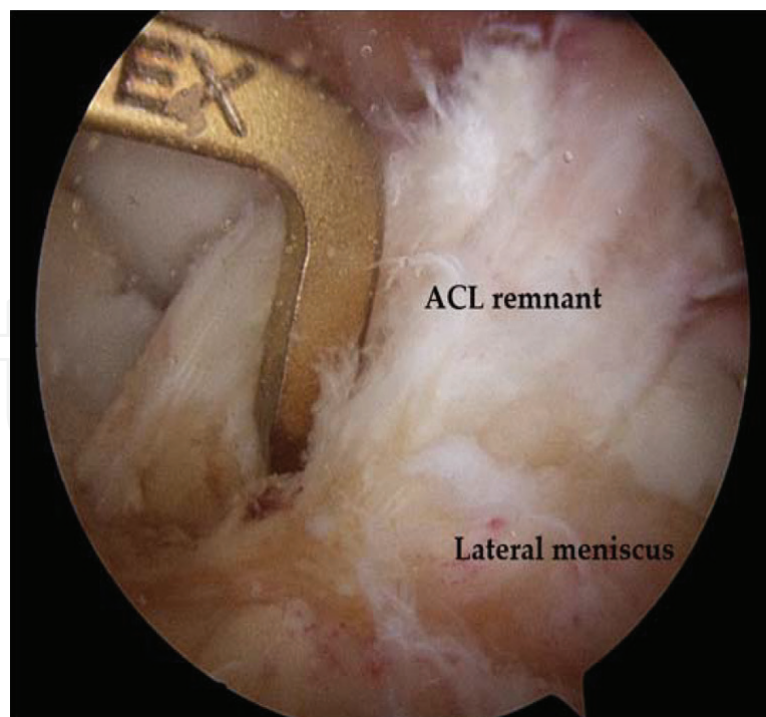


Figure 5. Arthroscopic view of the left knee from the anterolateral viewing portal. After identifying the ACL tibial footprint, a tibial tunnel is created with the use of a transtibial, ACL guide pin (Acufex Director Drill Guide, Smith & Nephew) inserted from the anteromedial portal.

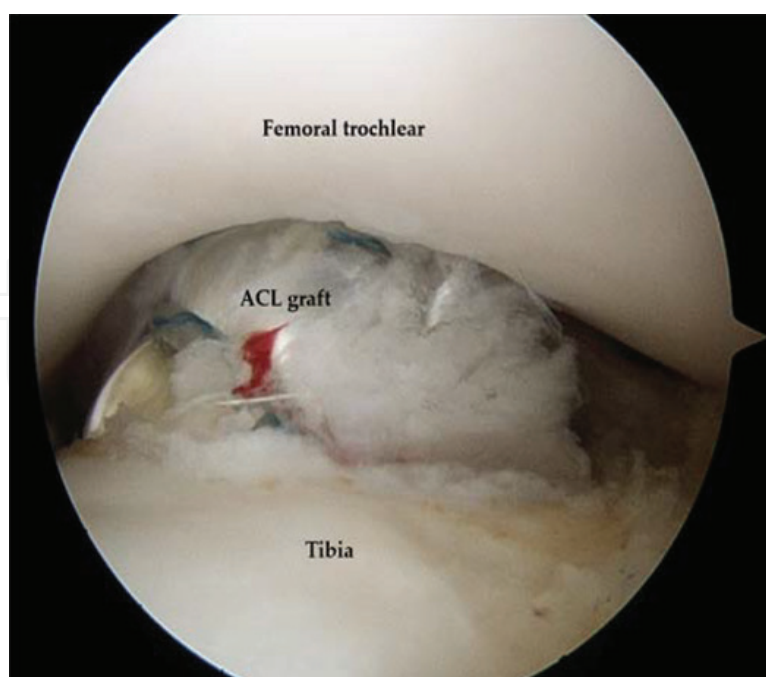


Figure 6. Arthroscopic view of the left knee from anterolateral viewing portal. The reconstructed ACL graft and positioning and impingement in full knee extension are checked.

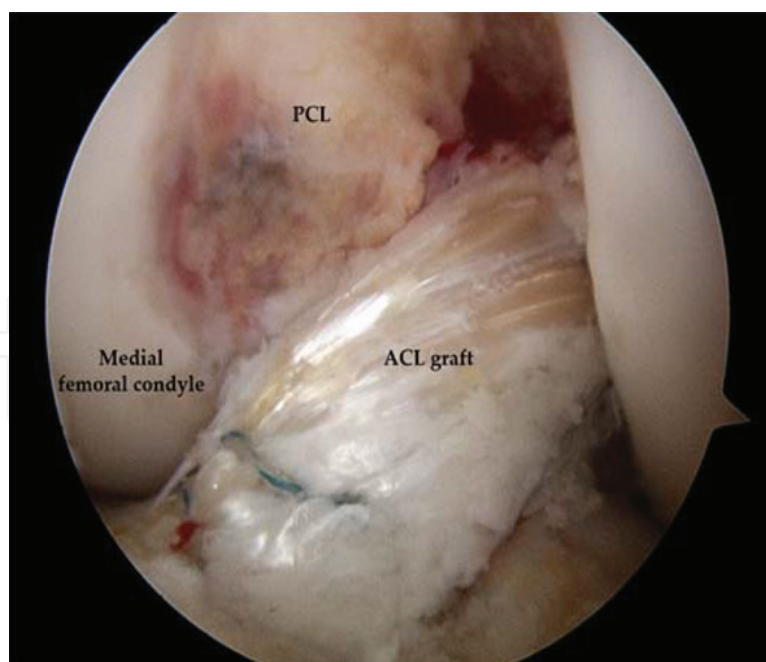


Figure 7. Arthroscopic view of the left knee from anterolateral viewing portal. Following fixation of the ACL graft, the graft, and the remnant appears to be a stable ACL reconstruct.

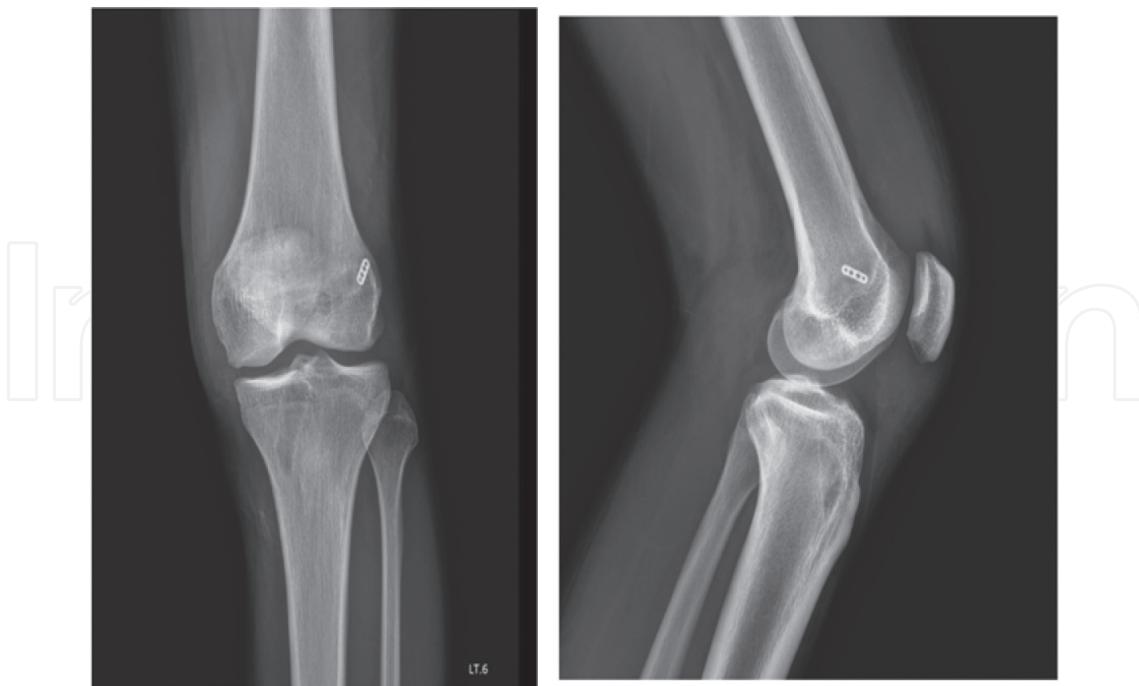


Figure 8. Postoperative radiographs of the left knee in anteroposterior and lateral views reveal the position of the EndoButton and the bony tunnels.

2.2. Postoperative rehabilitation

A small tubular drain is placed in the intra-articular area for 24 h postoperatively. An early range of motion exercises of the affected knee are encouraged as soon as possible with no limitations in knee flexion postoperatively. No knee braces or immobilization prosthetics are used. The patients can ambulate with crutches, and they are able to bear weight on the affected limb at approximately 10% of normal in the cases that had cartilage procedures done (microfracture or mosaicplasty). Approximately 50% of normal weight-bearing in the cases with meniscal repair and full weight-bearing as tolerated in cases with only ACL reconstructive surgery.

The stitches are removed 10–14 days postoperatively. Active quadriceps contraction exercises are allowed at the earliest possible time frame. Light sports activities such as jogging, swimming, and bicycling will be allowed 4 months postoperatively. Return to contact sports activities are allowed 10–12 months following the surgery.

2.3. Pearls and pitfalls

This technique is simple and processes in the same steps of a standard anatomic single-bundle ACL reconstruction. The difference is only of the preservation of the ACL remnant to get more advantages as have been discussed previously.

The pearls and pitfalls of this procedure are shown in **Table 1**.

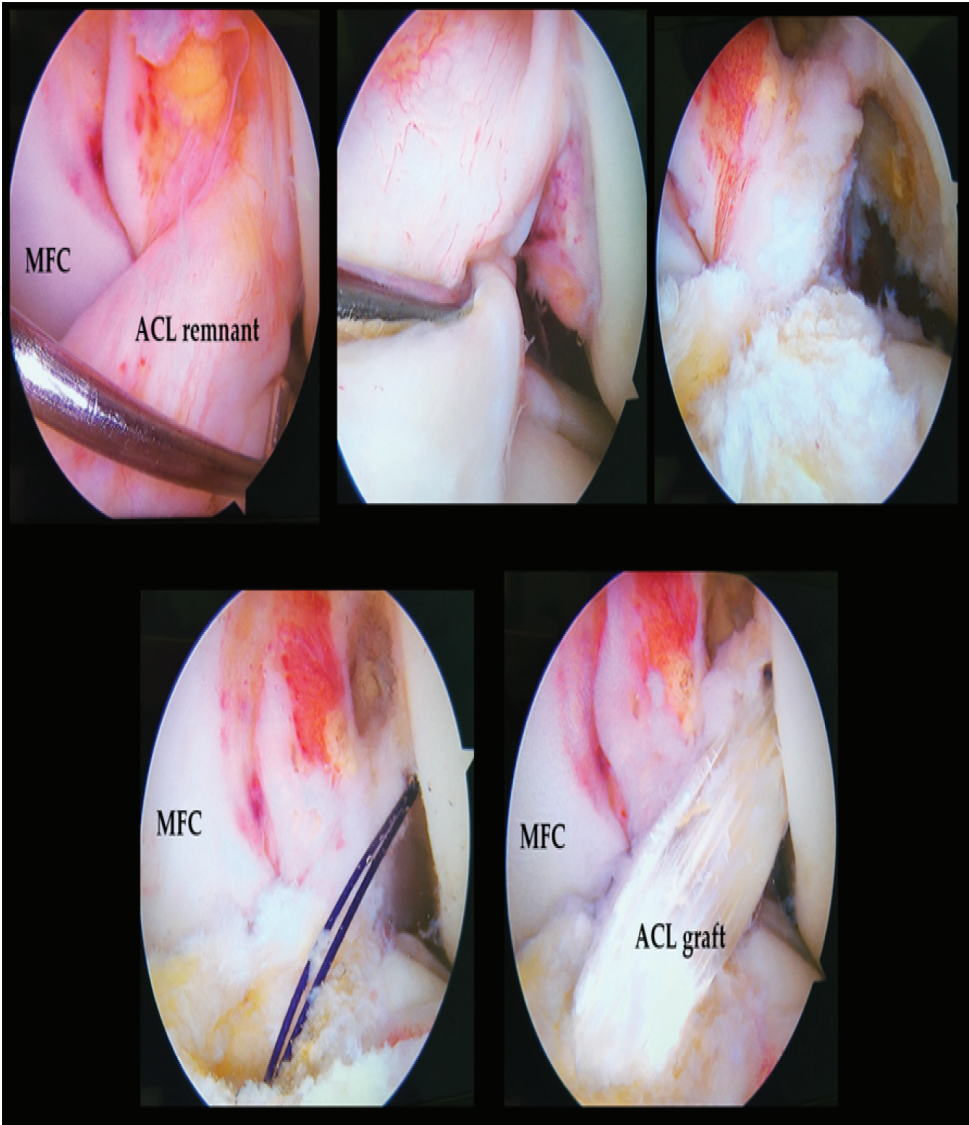


Figure 9. Arthroscopic images of a 26-year-old woman with left knee injury. The ACL remnant is observed arthroscopically. The step-by-step technique of a remnant-preserving ACL reconstruction is shown.

Pearls	Pitfalls
Simple, needs minimal technical demand as compared with the standard anatomic single-bundle ACL reconstruction	Clear identification of the center of both, the femoral and tibial footprints using bony ridges as reference
Some studies have reported achievement of greater knee stability and better proprioceptive functions	The appropriate graft position should be of greater concern than remnant preservation without anatomical graft placement
The RCTs show that the remnant-preserving ACL reconstruction has less tibial tunnel widening postoperatively	Most of the anterior tibial footprint stump of the ACL remnant should be removed to prevent anterior impingement of the graft or tissue (cyclops lesion) during full knee extension
Strict postoperative care is the key to obtaining good results	

Table 1. The pearls and pitfalls of the anatomic single-bundle ACL reconstruction with remnant augmentation technique.

3. Conclusion(s)

The anatomical single-bundle ACL reconstruction with remnant augmentation or preservation is the optional reconstruction technique that has shown comparable results with standard ACL reconstruction. This technique has theoretical advantages in the improvement of the stability of the knee, promotion of graft healing, preservation of the proprioceptive functions, and resulting good to excellent clinical outcomes. Although the studies have shown no significant benefits, this technique has a significantly lower incidence of tibial tunnel widening postoperatively and has exhibited no additional complications, including the occurrence of cyclops lesions.

Acknowledgements

There is no support funding for the publication.

Conflict of interest

The author declares that no conflicts of interest exist.

Author details

Adinun Apivatgaroon

Address all correspondence to: adino_ball@yahoo.com

Department of Orthopaedics, Thammasat University, Pathum Thani, Thailand

References

- [1] Tsoukas D, Fotopoulos V, Basdekis G, Makridis KG. No difference in osteoarthritis after surgical and non-surgical treatment of ACL-injured knees after 10 years. *Knee Surgery, SportsTraumatology, Arthroscopy*. 2016;**24**(9):2953-2959. DOI:10.1007/s00167-015-3593-9. Epub April 9, 2015
- [2] Monk AP, Davies LJ, Hopewell S, Harris K, Beard DJ, Price AJ. Surgical versus conservative interventions for treating anterior cruciate ligament injuries. *Cochrane Database of Systematic Reviews*. 2016;**4**:CD011166. DOI: 10.1002/14651858.CD011166.pub2
- [3] Sanders TL, Kremers HM, Bryan AJ, Fruth KM, Larson DR, Pareek A, Levy BA, Stuart MJ, Dahm DL, Krych AJ. Is anterior cruciate ligament reconstruction effective in preventing secondary meniscal tears and osteoarthritis? *The American Journal of Sports Medicine*. 2016;**44**(7):1699-1707. DOI: 10.1177/0363546516634325. Epub 2016 Mar 8

- [4] Mihelic R, Jurdana H, Jotanovic Z, Madjarevic T, Tudor A. Long-term results of anterior cruciate ligament reconstruction: A comparison with non-operative treatment with a follow-up of 17-20 years. *International Orthopaedics*. 2011;**35**:1093-1097
- [5] Kato Y, Ingham SJ, Kramer S, et al. Effect of tunnel position for anatomic single bundle ACL reconstruction on knee biomechanics in a porcine model. *Knee Surgery, Sports Traumatology, Arthroscopy*. 2010;**18**:2-10
- [6] Tiamklang T, Sumanont S, Foocharoen T, Laopaiboon M. Double-bundle versus single-bundle reconstruction for anterior cruciate ligament rupture in adults. *Cochrane Database of Systematic Reviews*. 2012;**11**:CD008413. DOI: 10.1002/14651858.CD008413.pub2
- [7] Ho JY, Gardiner A, Shah V, et al. Equal kinematics between central anatomic single-bundle and double-bundle anterior cruciate ligament reconstructions. *Arthroscopy*. 2009;**25**:464-472
- [8] Kanaya A, Ochi M, Deie M, et al. Intraoperative evaluation of anteroposterior and rotational stabilities in anterior cruciate ligament reconstruction: Lower femoral tunnel placed single-bundle versus double-bundle reconstruction. *Knee Surgery, Sports Traumatology, Arthroscopy*. 2009;**17**:907-913
- [9] Adachi N, Ochi M, Uchino Y, Iwasa J, Ryoke K, Kuriwaka M. Contribution of mechanoreceptors in the anterior cruciate ligament to the joint position sense knee. *Acta Orthopaedica Scandinavica*. 2002;**73**:330-334
- [10] Nakamae A, Ochi M, Deie M, Adachi N, Kanaya A, Nishimori M, Nakasa T. Biomechanical function of anterior cruciate ligament remnants: How long do they contribute to knee stability after injury in patients with complete tears? *Arthroscopy*. 2010;**26**:1577-1585
- [11] Gao F, Zhou J, He C, Ding J, Lou Z, Xie Q, Li H, Li F, Li G. A morphologic and quantitative study of mechanoreceptors in the remnant stump of the human anterior cruciate ligament. *Arthroscopy*. 2016;**32**(2):273-280. DOI: 10.1016/j.arthro.2015.07.010. Epub October 1, 2015
- [12] Kazusa H, Nakamae A, Ochi M. Augmentation technique for anterior cruciate ligament injury. *Clinics in Sports Medicine*. 2013;**32**(1):127-140. DOI: 10.1016/j.csm.2012.08.012. Epub September 23, 2012. Review
- [13] Hong L, Li X, Zhang H, Liu X, Zhang J, Shen JW, Feng H. Anterior cruciate ligament reconstruction with remnant preservation: A prospective, randomized controlled study. *The American Journal of Sports Medicine*. 2012;**40**(12):2747-2755. DOI: 10.1177/0363546512461481. Epub October 17, 2012
- [14] Hu J, Qu J, Xu D, Zhang T, Zhou J, Lu H. Clinical outcomes of remnant preserving augmentation in anterior cruciate ligament reconstruction: A systematic review. *Knee Surgery, Sports Traumatology, Arthroscopy*. 2014;**22**(9):1976-1985. DOI: 10.1007/s00167-013-2749-8. Epub November 2, 2013. Review

- [15] Tie K, Chen L, Hu D, Wang H. The difference in clinical outcome of single-bundle anterior cruciate ligament reconstructions with and without remnant preservation: A meta-analysis. *The Knee*. 2016;**23**(4):566-574. DOI: 10.1016/j.knee.2015.07.010. Epub May 17, 2016. Review
- [16] Nakamae A, Ochi M, Deie M, Adachi N, Shibuya H, Ohkawa S, Hirata K. Clinical outcomes of second-look arthroscopic evaluation after anterior cruciate ligament augmentation: Comparison with single- and double-bundle reconstruction. *Bone and Joint Journal*. 2014;**96-B**(10):1325-1332
- [17] Chuaychoosakoon C, Duangnumsawang Y, Apivatgaroon A. Prevention of medial femoral condyle injury by using a slotted cannula in anterior cruciate ligament reconstruction. *Arthroscopy Techniques*. 2017;**6**(5):e1639-e1643
- [18] Apivatgaroon A, Chernchujit B. A surgical trick for adjusting an inaccurate guide pin to the center of the tibial footprint in anatomic single-bundle anterior cruciate ligament reconstruction. *Arthroscopy Techniques*. 2014;**3**(2):e275-e277

