

We are IntechOpen, the world's leading publisher of Open Access books Built by scientists, for scientists

6,900

Open access books available

185,000

International authors and editors

200M

Downloads

Our authors are among the

154

Countries delivered to

TOP 1%

most cited scientists

12.2%

Contributors from top 500 universities



WEB OF SCIENCE™

Selection of our books indexed in the Book Citation Index
in Web of Science™ Core Collection (BKCI)

Interested in publishing with us?
Contact book.department@intechopen.com

Numbers displayed above are based on latest data collected.
For more information visit www.intechopen.com



Recurrent Pelvic Organ Prolapse

Nidhi Sharma and Sudakshina Chakrabarti

Additional information is available at the end of the chapter

<http://dx.doi.org/10.5772/intechopen.76669>

Abstract

The treatment of recurrent pelvic organ prolapse is challenging. The pelvic floor symptom needs to be treated, a high quality of life has to be ensured and complications have to be minimized. There is a wide range of surgical options that may be used. The surgeon should be able to discuss and offer native tissue procedures for prolapse. In addition, for the clinically challenging situations of recurrent prolapse, mesh augmented procedures may need to be discussed with the patient. A thorough knowledge of mesh and graft options, as well as knowledge of prolapse recurrence and adverse events rate, can help guide clinicians in counseling their patients effectively. Ultimately, this will allow surgeons to choose a personalized treatment option that best align with a woman's lifestyle and treatment goals. In this chapter the anatomical concepts of supports of vagina are elaborated. The pelvic diaphragm, lateral attachment of vagina to arcus tendineus fascia pelvis, intrinsic and extrinsic sphincter control mechanisms are elaborated. The surgical techniques of suspending the vaginal vault with autologous tissue and synthetic mesh are discussed. Finally, the role of minimally invasive surgery of pelvic floor is discussed as an integral part of management of recurrent vaginal prolapse.

Keywords: recurrent POP, pelvic floor, perineum, prolapse, vaginal vault prolapse, sacrospinous fixation

1. Introduction

Vaginal prolapse can be studied in defects at three levels of Prof John Delancey (**Figure 1**).

Usually vault prolapse is associated with anterior and/or posterior wall prolapse. The anterior compartment, the central compartment and the posterior compartment defect. Anterior compartment consists of the bladder and urethra. The central compartment consists of the vaginal vault/uterus. The rectum and perineal body form the posterior compartment. The lateral

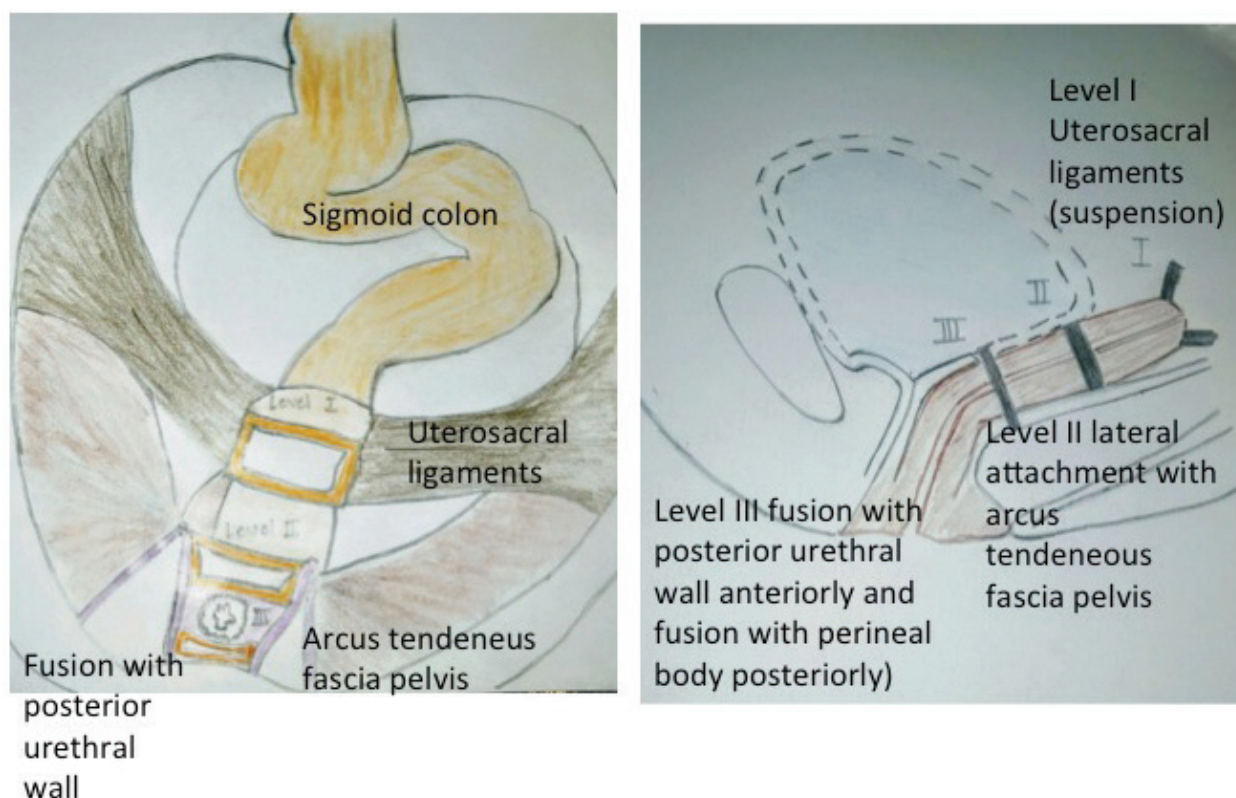


Figure 1. Professor John De Lancey's support of vaginal vault after hysterectomy as viewed from above and laterally.

compartment defect is the detachment from the arcus tendineus fascia pelvis. The enterocele and posterior compartment dysfunction is the commonest form of post hysterectomy vaginal vault prolapse (**Figure 2**).

Vault prolapse can occur following hysterectomy done for non-prolapse indications if the surgeon at the time of vaginal vault closure does not perform the vault suspension procedure. At the time of abdominal hysterectomy done for benign gynecological diseases like fibroid, adenomyosis, dysfunctional uterine bleeding, the uterosacral ligaments are clamped cut and ligated. The vaginal vault is sutured. This sutured vaginal vault needs to be suspended to the stumps of uterosacral ligaments to support the vagina following hysterectomy. This vital step is the most important point to be remembered by general gynecology practitioners to prevent the occurrence of vault prolapse following hysterectomy.

Recurrent pelvic organ prolapse can be defined as

"The recurrent complaint of something coming down pervaginum, following hysterectomy done for pelvic organ prolapse or other benign gynecological indications". Unfortunately this definition does not take into account the wide variation in this symptom and the underlying etiology. Some women may be asymptomatic while others may have severe symptoms.

Severity and quantity of symptoms that should be considered in history are:

1. Duration of complaint and whether the problem has been worsening

2. Presence of triggering factors or events (e.g. Coughing, sneezing, lifting, bending, feeling of urgency)
3. Constant or intermittent urine loss and provocation by minimal increase in intraabdominal pressure. Such as movement, changes in position, and incontinence with an empty bladder
4. Associated frequency, urgency, dysuria, pain with a full bladder, and a history of urinary tract infections
5. Concomitant symptoms of fecal incontinence or rectal prolapse
6. Indication of previous Hysterectomy and coexisting complicating or exacerbating medical problems like diabetes
7. Obstetrical history, including difficult deliveries, episiotomy, grand multiparity, forceps use, obstetrical lacerations, and large babies
8. Type of previous pelvic surgeries, especially the incontinence procedures, hysterectomy, or pelvic floor reconstructive procedures
9. History of spinal and central nervous system surgeries
10. Lifestyle issues like smoking, alcohol or caffeine abuse, and occupational and recreational factors causing severe or repetitive increase in intraabdominal pressure
11. Patients with coexisting pelvic organ prolapse may report dyspareunia, vaginal pain on ambulation, and a bulging sensation in vagina

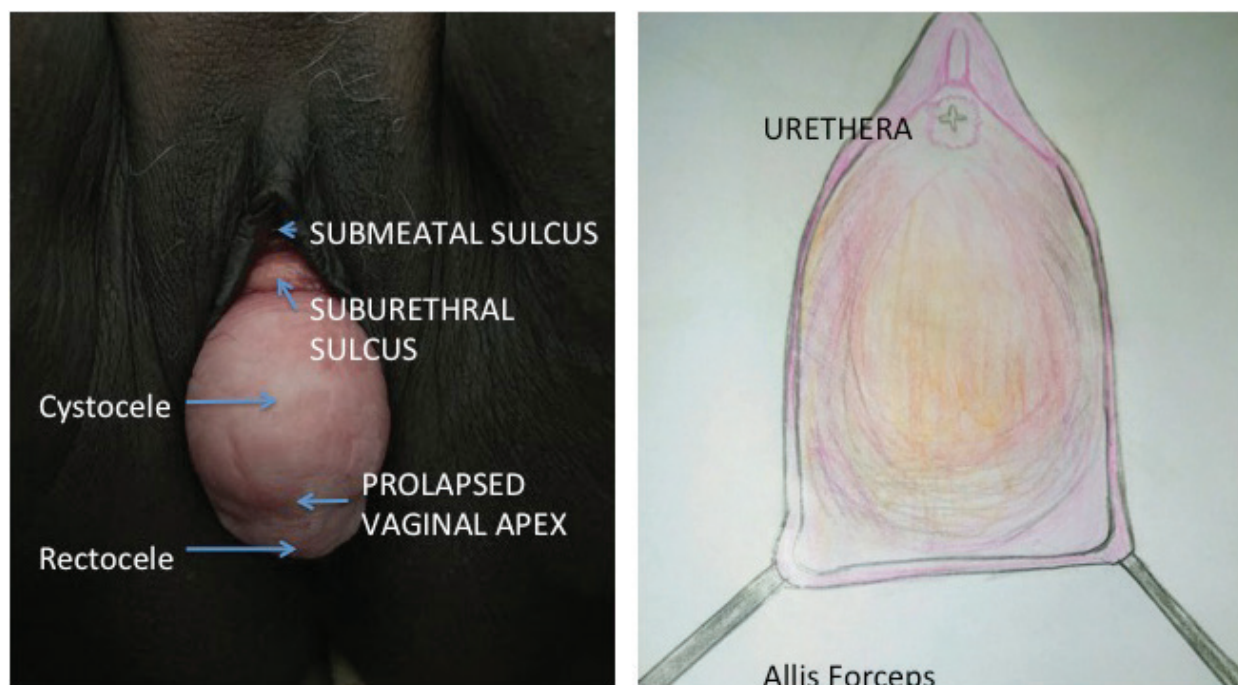


Figure 2. Vaginal vault prolapse with cystocele and enterocoele (Submeatal sulcus and suburethral sulcus is maintained). The leading point of the prolapse is the prolapsed vaginal apex hence also called as apical vaginal prolapse. Diagrammatic representation of the vaginal vault prolapse: the edges of the vaginal apex are held by Allis tissue holding forceps.

2. Anatomical considerations

In 1555 Andreas Vesalius referred to the pelvic floor muscles as “*Musculus sedem attollens*”. Von Behr later referred this as levator ani. The term pelvic diaphragm includes ischiococcygeus, ileococcygeus and pubococcygeus which all forms the levator ani. Puborectalis or “*Sphincter Recti*” is described as the fibers of pubococcygeus which loop around the rectum and this muscle is now included in the levator ani group. As the muscles of the pelvic diaphragm are intimately related to the urethra, vagina, rectum and anal canal, the term pubovisceralis for the muscles of pelvic floor was first coined by Lawson and was later supported by Delancey [1–3].

The muscles in pelvis can be classified into two groups. The lateral wall muscles and the pelvic floor muscles. The lateral wall muscles include the obturator internus and piriformis and the pelvic floor muscles include the levator ani. The pelvic floor muscles form the pelvic diaphragm [4, 5]. The levator ani is a broad thin sheet of muscle arising from the inner aspect of the pelvic walls unites with its fellow from the opposite side to form the floor of pelvic cavity. It supports the pelvic viscera and some of its fibers get attached to the wall of the visceral structures passing through it. The levator ani has an extensive origin starting from the posterior surface of the superior ramus of pubic bone, obturator fascia to the inner aspect of the ischial spine. The fibers pass downward and backwards thus creating a shallow saucer like structure on which the pelvic viscera rests. The posterior most fibers from either side get attached to the sides of the terminal two pieces of coccyx. Fibers immediately anterior to this unite with the fellow fibers of opposite side to form a median anococcygeal raphe extending between the coccyx and the posterior margin of anus.

The term pubovisceralis is extensively used in gynecological texts but it is not commonly mentioned in anatomical texts. The portions of pubovisceralis that are inserted into the urethra, vagina, perineal body and anal canal were given names as pubourethralis, pubovaginalis and puboperinalis respectively by Lawson [4–6]. The action of these muscles is to provide support to the visceral organs. The ileococcygeous muscle provides support to the posterior compartment and fuses anterior to the coccyx with fibers of opposite side to form the anococcygeal raphe or the levator plate in the median plane. This thin muscular plate supports the viscera of the pelvis especially when there is rise in intraabdominal pressure. Sagging of levator plate is an important defect leading to loss of support of the pelvic organs [7, 8].

The perineal body, which lies posterior to the posterior vaginal wall and anterior to the wall of anal canal, is an important support of pelvic floor. The attachments and components of perineal body are still debated. Recent studies using 3D endovaginal ultrasonography have assessed the structure of the perineal body showed that it has mixed echogenicity and situated between rectum, anal canal and posterior wall of vagina [2, 5]. Perineal body is divided into two levels, i.e. a superficial level which is continuous with external anal sphincter, bulbospongiosus and the superficial transverse perineal muscles and a deeper part, which is in continuity with the pubovisceralis muscle of the pelvic floor [6, 7].

The endopelvic connective tissue in this area attaches to the perineal membrane and laterally it stretches over the levator ani and condenses to form the arcus tendineus fascia pelvis, which stretches from pubic bone till the ischial spine. This arcus tendineus fascia pelvis lies at the

junction of the fascia of the obturator internus and levator ani muscle. This tissue provides support to vagina vault laterally [2, 8, 9].

3. Initial evaluation

The initial evaluation of patients with vaginal vault prolapse requires a systematic approach to consider the probable causes.

3.1. History

Physicians treating the recurrent prolapse patient should empathically ask them how the prolapse specially affects their life and to what degree the prolapse bothers them.

3.2. Physical examination

The physical examination of the patient with recurrent prolapse should focus on both the general medical conditions that may affect the pelvic organs as well as the problems related to prolapse [10, 11]. Such conditions include cardiovascular insufficiency, pulmonary disease, occult neurologic processes, (e.g. Multiple sclerosis, stroke, Parkinson's disease, and anomalies of the spine and lower back), abdominal masses and general activity of the patient [12, 13].

3.3. Pelvic examination

This should be performed by POP-Q system [12–14]. A special note should be made regarding pelvic organ prolapse and atrophy. Levator ani muscle symmetry should be noted during the ability to squeeze test. Anal sphincter function, presence of fissures and symmetry during squeezing should also be noted.

Recurrent prolapse assessment should include urodynamic studies to reach a correct diagnosis of the type of incontinence associated with recurrent prolapse. The indications of urodynamic studies are:

1. The diagnosis is uncertain (major discrepancies between the history, voiding diary and symptom scale).
2. Elevated post void residual urine volume.
3. Associated neurological conditions like multiple sclerosis leading to recurrent prolapse.
4. Previous surgery for incontinence correction.
5. Coexisting rectal prolapse.

3.4. Systemic examination

Gait assessment should be done and mobility status should be noted. A detailed neurological examination should incorporate measures of mental status, perineal sensation, perineal

reflexes and patellar reflexes. Cardiovascular examination should be done to rule out lower extremities edema and feature of congestive heart failure [15–17].

3.5. Simple primary care tests

Simple primary care clinical tests are an integral part of initial evaluation. Pelvic Floor Distress Inventory-Short Form 20 (PFDI-20), the Pelvic Floor Impact Questionnaire-7 (PFIQ-7) and the ICIQ-VS score can be used to evaluate the quality of life and severity of symptoms. The most common questionnaire used is the PFDI-20 questionnaire [18–20].

4. Management options

The management options of recurrent pelvic organ prolapse is almost always surgical. It is to be realized that surgical options are the first choice as they provide a long-term relief. Surgical measures should always be accompanied by pelvic muscle strengthening exercises in the postoperative period for best outcome.

The surgical procedure must be case based. If the initial repair was vaginal hysterectomy with pelvic floor repair the subsequent repair can be sacrospinous colpopexy or sacrospinous fixation. If the initial repair was sacrohysteropexy the recurrent prolapse can be managed by vaginal hysterectomy, anterior colporrhaphy and posterior colpoperineorrhaphy along with McCall’s culdoplasty.

Corrective Surgeries for vaginal Vault Prolapse	
Vaginal Approach	
McCall’s Culdoplasty	Approximation of uterosacral ligaments and attachment of vaginal vault to uterosacral ligaments
Sacrospinous Colpopexy	Vaginal Vault to sacrospinous ligament
Ileococcygeus colpopexy	Vaginal Vault to ileococcygeous muscle
Uterosacral ligament Suspension	Vaginal Vault to uterosacral ligaments
Abdominal Approach	
Abdominal Sacrocolpopexy	Vaginal Vault to presacral periosteum
Abdominal uterosacral suspension	Vaginal Vault to uterosacral ligaments
Laparoscopic Approach	
Laparoscopic Sacrocolpopexy	Vaginal vault to presacral periosteum
Robotic Approach	
Robotic Sacrocolpopexy	Vaginal vault to presacral periosteum

Table 1. Corrective surgery for vaginal vault prolapse.

The reconstructive surgical procedures for the anterior and posterior vaginal vault prolapse are listed in **Table 1**. The anterior vaginal Wall repairs include anterior colporrhaphy and site-specific repair. The posterior vaginal wall repair procedures include posterior colporrhaphy, site-specific repair, perineorrhaphy, McCall's culdoplasty and Moskowitz procedure. The procedures for vault prolapse following hysterectomy include sacrospinous colpopexy, uterosacral ligament (USLS) suspension via abdominal or vaginal route, ileococcygeal fascia suspension and abdominal sacrocolpopexy [21].

5. Sacrospinous colpopexy

Access to sacrospinous ligament is obtained through the Para rectal space in posterior approach and through the paravesical space in the anterior approach. The right ischial spine is localized digitally and after retractor positioning the ligament is made visible through blunt dissection. Two permanent sutures (Prolene 1.0, Ethicon, Somerville, NJ, USA) are placed through the right sacrospinous ligament at least 2 cm from the ischial spine. Pulley sutures are used to anchor the undersurface of the anterior vaginal cuff (anterior sacrospinous suspension) or posterior cuff (posterior sacrospinous suspension) along the sacrospinous ligament medially and laterally. During both techniques, the medial and lateral fixation sutures are placed at least 2 cm apart along the ligament. Hereafter an additional anterior and/or posterior colporrhaphy or incontinence surgery can be performed. The procedure is acceptable with few complications [22]. Sacrospinous Fixation can be done using Miya hook or Capiro (**Figure 3**).

There are two ways to access the sacrospinous ligament: the anterior approach and the posterior approach. In the anterior approach the sacrospinous ligament is accessed after dissecting the paravaginal and paravesical spaces and the anterior vaginal cuff is anchored to the sacrospinous ligament. In the posterior approach the pararectal fossa is opened after dissected the posterior vaginal wall from the rectovaginal fascia. And the posterior cuff of vagina is anchored to the sacrospinous ligament.

In the posterior approach the vaginal mucosa is incised transversely at the posterior fourchette and the posterior vaginal mucosal flap is raised above from rectovaginal fascia. The assistant deflects the rectum medially while the surgeon palpates the ischial spine and identifies the sacrospinous ligament. A Miya hook passed through the sacrospinous ligament. The Miya hook is threaded with the suture and the sutures are carried and anchored to the vaginal vault. The permanent sutures are placed through the posterior side of the vagina in the posterior approach. The lower two thirds of posterior vaginal wall is closed with absorbable sutures (Vicryl 2, Eticon Somerville, NJ, USA). The permanent sutures are now tightened and the remaining one third of the vaginal wall is also closed (**Figures 3(a)–(c)**). The same principal is applied for sacrospinous hysteropexy in an intact uterus. The posterior sacrospinous approach is less invasive but the vaginal axis is slightly downwards as compared to the physiological axis of vagina. This predisposes to anterior compartment defects as the raised intraabdominal pressures are now directly transmitted to the anterior vaginal wall.

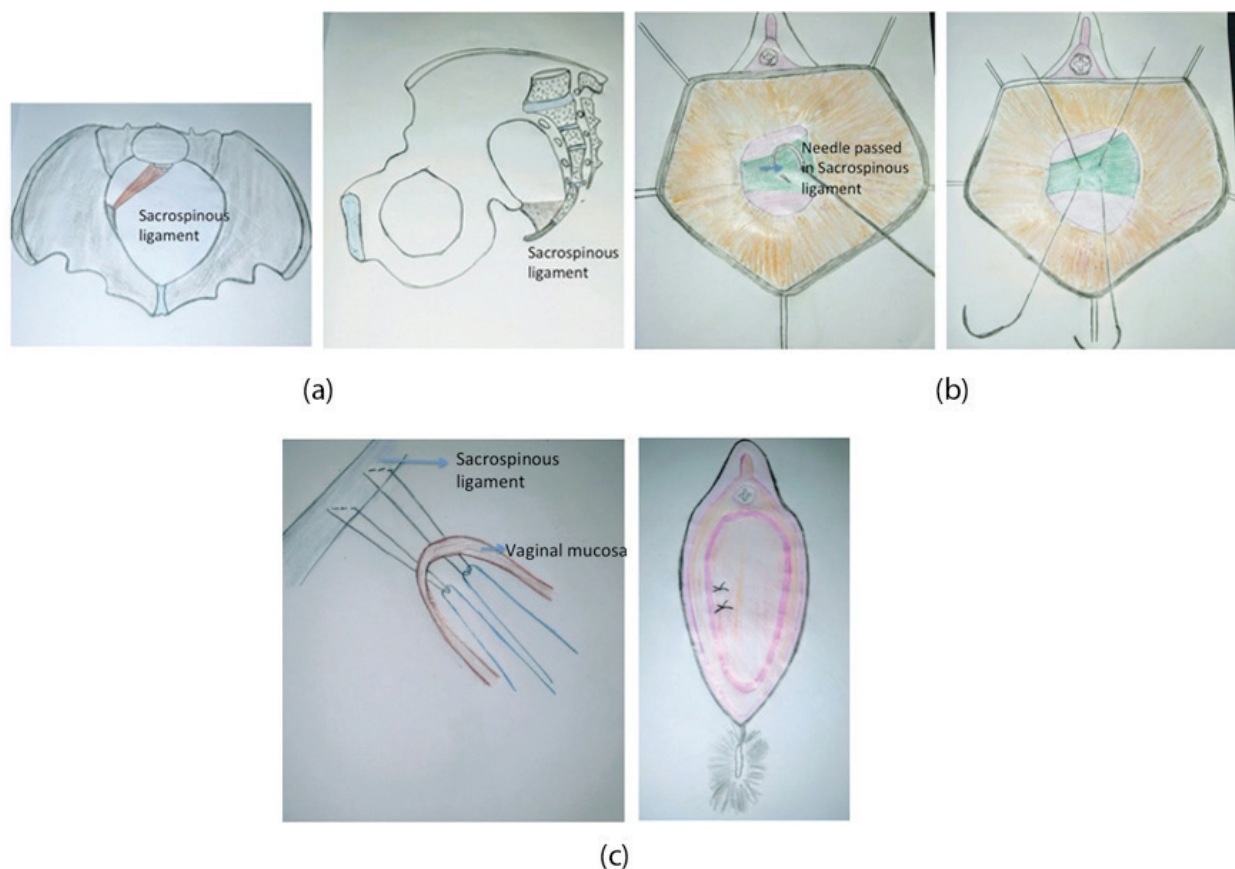


Figure 3. (a) The anatomical identification of sacrospinous ligaments as viewed from above and laterally. (b) The vaginal vault is anchored to the sacrospinous ligaments with delayed absorbable or nonabsorbable sutures. (c) The vaginal mucosa is anchored and closed.

The anterior approach was developed subsequently to overcome the shortcomings of posterior approach. In the anterior approach a vertical anterior vaginal incision is made for retro pubic entry and paravaginal and paravesical space is dissected. The sacrospinous ligament is identified and the anterior cuff of vagina is anchored with two polytetrafluoroethylene (00) sutures. The two sutures are placed 2 cm apart on sacrospinous ligament. The same procedure is performed on the contralateral sacrospinous ligament.

The anterior suspension technique positions the vaginal vault in a more capacious anatomic space, in comparison to the relatively narrow pararectal area occupied by the upper vagina after posterior sacrospinous vault suspension (**Figure 4(a)** and **(b)**). After anterior sacrospinous vaginal vault suspension, vaginal length and apical suspension are slightly increased. The axis of the suspended vagina appears more physiological. There are less chances of recurrent anterior compartment prolapse as compared with the posterior sacrospinous vaginal vault suspension procedure. The upper vaginal lumen caliber and sexual function are adequately preserved in both techniques [23]. The posterior vaginal wall laxity, on the contrary, is more common after anterior sacrospinous vault suspension.

However, these differences are likely to be influenced by differences in levator muscle tone and degree of perineal support. So a posterior colporrhaphy may be concurrently performed

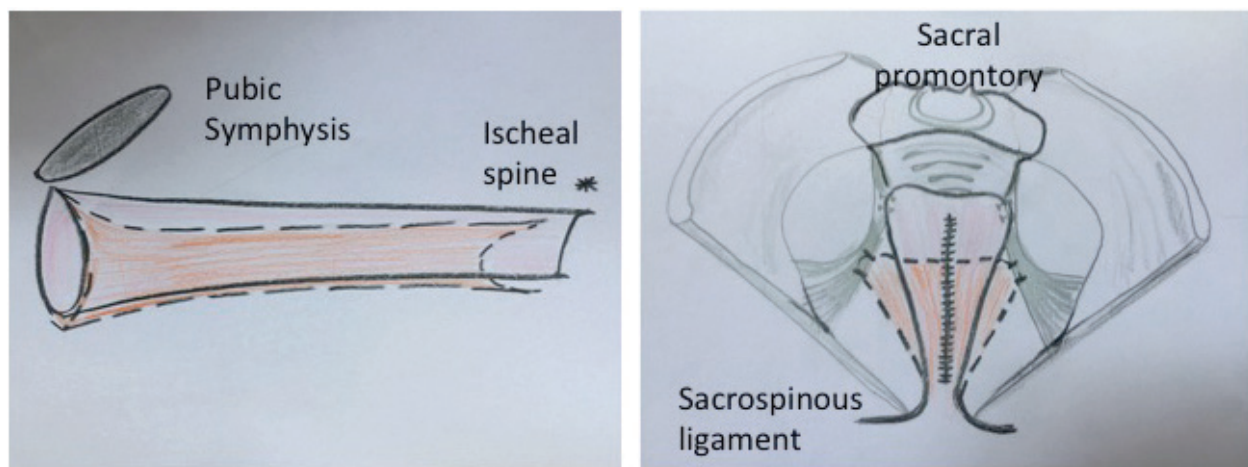


Figure 4. Anterior v/s posterior sacrospinous vault fixation: Postoperative comparison based on pelvic organ prolapse . Solid line: Anterior sacrospinous vault fixation, dashed line: Posterior sacrospinous fixation. (a): Lateral view of Vaginal axis after anterior and posterior bilateral sacrospinous fixation. (b): Anterior posterior view of vaginal axis after anterior and posterior bilateral sacrospinous fixation.

with anterior sacrospinous fixation to achieve the best outcome. Postoperative strengthening of perineal muscles by structured pelvic exercises is effective.

6. Uterosacral vaginal vault suspension

In vault prolapse the endopelvic fascia surrounding the vagina is broken at specific points. A site-specific repair and anchoring to the stumps of uterosacral ligaments will restore the suspension. Three principles are identification of the fascia defect, reducing the enterocele sac and closure of the fascia defect. Finally the vagina is anchored to the Level 1 support of uterosacral ligament making the procedure most anatomically close to physiologically correct vaginal axis.

Vaginal apex is grabbed with two Allis clamps. The vaginal mucosa over the enterocele is incised. The enterocele sac is identified and dissected till the base or neck of the sac. The enterocele sac is opened carefully and contents are reduced taking care of adhesions. The excessive peritoneum is excised. A Deaver retractor is placed anteriorly and used to pack the abdominal contents anteriorly.

The uterosacral ligament stumps are identified; remnants are usually believed to be present at 5 O'clock and 7 O'clock position. The ureter position is confirmed by palpating the pelvic sidewall. The ureter is usually placed 2–3 cm lateral and ventral to the ischial spine. A non-absorbable Prolene 1/0 suture is placed on the uterosacral remnant on left side passing the needle from lateral to medial side to avoid injuring the ureter. The rectum is then deflected away by the non-dominant hand. A second suture is placed further high and medially on the left uterosacral ligament for better anchoring. The peritoneum is included in the stitch and now the stitch is passed in the opposite uterosacral ligament taking the needle from lateral to medial side. Now these sutures are tied and this obliterates the cul-de-sac (**Figure 5**). Anterior colporrhaphy or sling procedures if required are performed at this stage now.

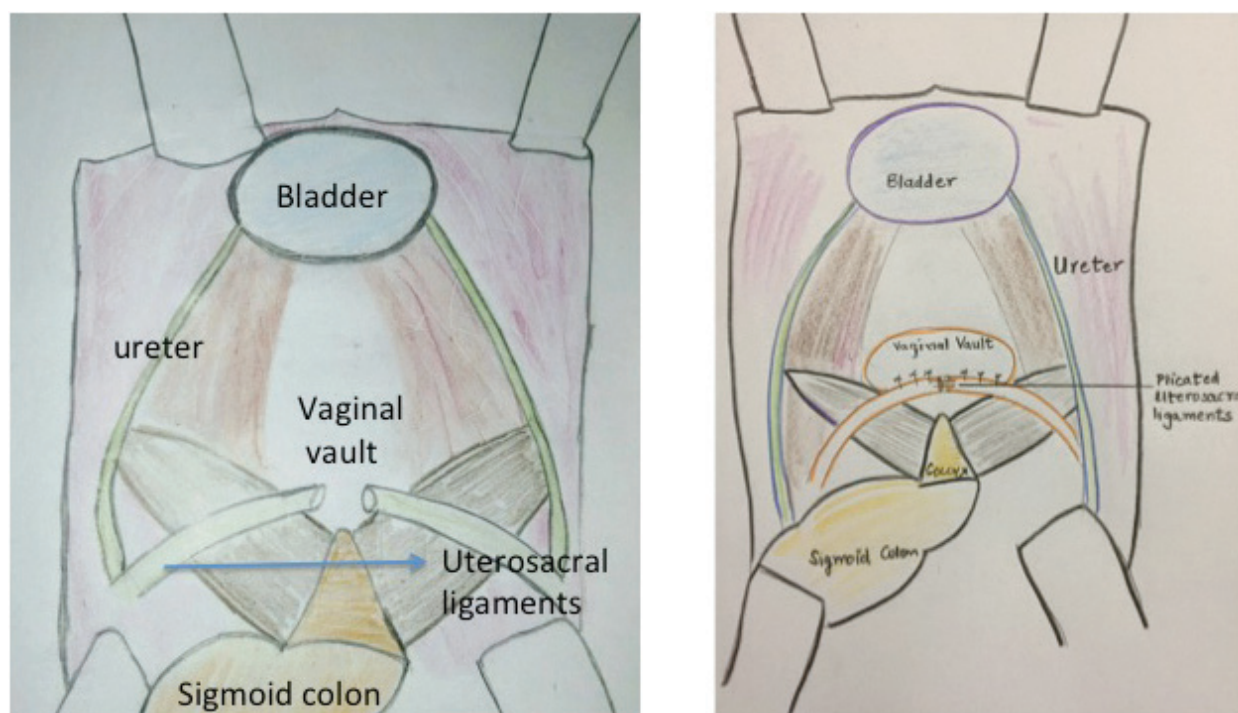


Figure 5. The abdominal uterosacral ligament suspension.

The nonabsorbable suture ends from the uterosacral ligaments are now attached to the vaginal apex. One suture end is taken through the lateral aspect of the posterior vaginal wall and the other is attached to the lateral aspect of the anterior vaginal wall. The same is repeated on the other side.

Tying these sutures suspends the vagina in the hollow of the sacrum and restores the continuity of the endopelvic fascia of the anterior and posterior vaginal walls [24].

The single most careful point in this procedure is prevention of ureteric injury or kinking. It is important to perform an intraoperative cystoscopy to ensure ureteral patency. If the urine spurt is not seen in cystoscopy then the suspension sutures on that side should be removed and ureters reevaluated. Often the anchoring can be achieved by taking a more medial suture through the uterosacral ligament.

7. Ileococcygeous fascia suspension

In 1963, Inmon used ileococcygeal fascia in three women for bilateral fixation of vaginal vault in patients with inadequate uterosacral ligaments. In 1993, Schull and colleagues had performed this technique in 42 women. The principle is to identify all fascial defects prior to surgery. Posterior perineal incision is made. The vaginal epithelium is then freed from the rectum and rectovaginalis fascia. The dissection is carried further laterally to the levators and cephalad to the vaginal cuff. The ileococcygeal muscle is identified lateral to the rectum and anterior to the ischial spine. The non-dominant hand is used to depress the rectum away from the ischial spine.

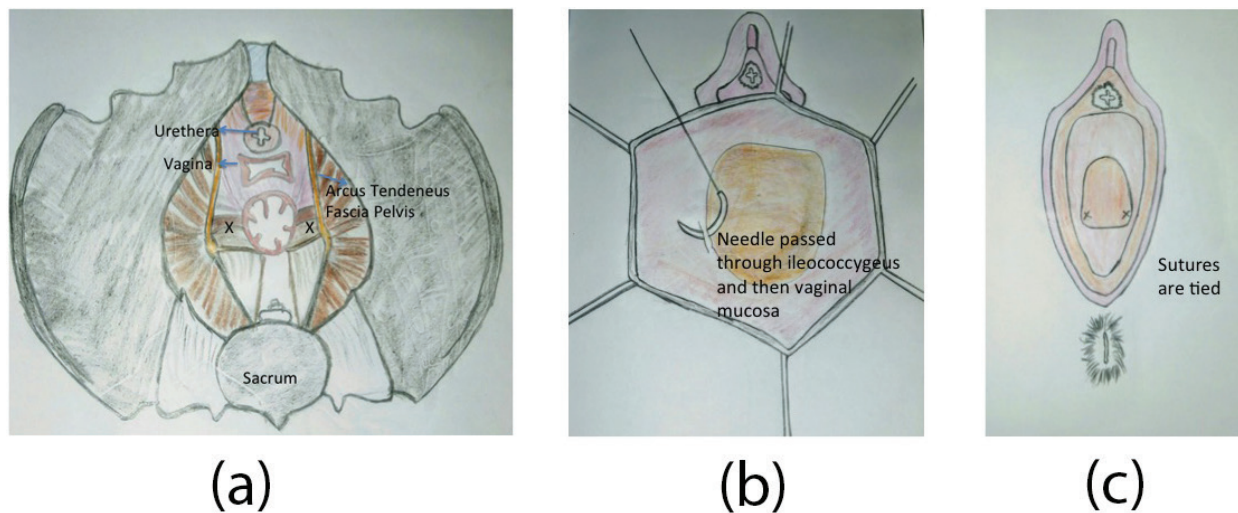


Figure 6. (a) The ileococcygeus muscle anatomical identification. (b) The ileococcygeus fixation of vaginal mucosa and closure of vagina after bilateral ileococcygeus fixation.

A suture is placed just anterior to the ischial spine in the fascia covering the ileococcygeous muscle. Both ends of the loop are now passed through the ipsilateral vaginal apex. A similar suture is placed on the contralateral ileococcygeus muscle and vaginal apex is sutured to the opposite ileococcygeus (**Figure 6(a)-(c)**). A delayed absorbable suture like Vicryl 1,0, Ethicon, Somerville, NJ, USA should pass through the entire vaginal thickness.

A specific complication is anterior vaginal wall relaxation due to non-physiological axis of the reconstructed vaginal support, which makes the vagina tilt anteriorly [25].

8. Abdominal sacrocolpopexy

Post Hysterectomy Vaginal Vault Prolapse always requires a surgical correction. The suspension of vagina in the hollow of sacrum to the anterior longitudinal ligament of first sacral vertebra has been shown to be an effective treatment of vault prolapse.

Peritoneum over vaginal apex is opened to identify the endopelvic fascia. A continuous covering of endopelvic fascia is created around the vaginal epithelium. Nonabsorbable sutures are used to suspend the vagina along with endopelvic fascia to the sacral periosteum [26].

Sacrocolpopexy is an abdominal operation that connects the top of the vagina with a strip of permanent synthetic mesh to the sacrum bone. This operation is sturdy, with many studies showing success rates of over 90%. Cutting and tying the mesh design an “inverted Y” shaped mesh.

The patient is placed in low lithotomy position to allow vaginal manipulation during the surgery. The vagina is packed with a sponge stick or an E sizer, End-to-end anastomosis **sizer** (Auto Suture EEA reusable **sizer**; United States Surgical, Tyco Healthcare Group LP, Norwalk, CT, USA).

The lower limbs of inverted Y are anchored to the full thickness of vagina by multiple interrupted sutures. The mesh is placed around half way down the anterior wall, thereby correcting the undiagnosed, unidentified cystocele.

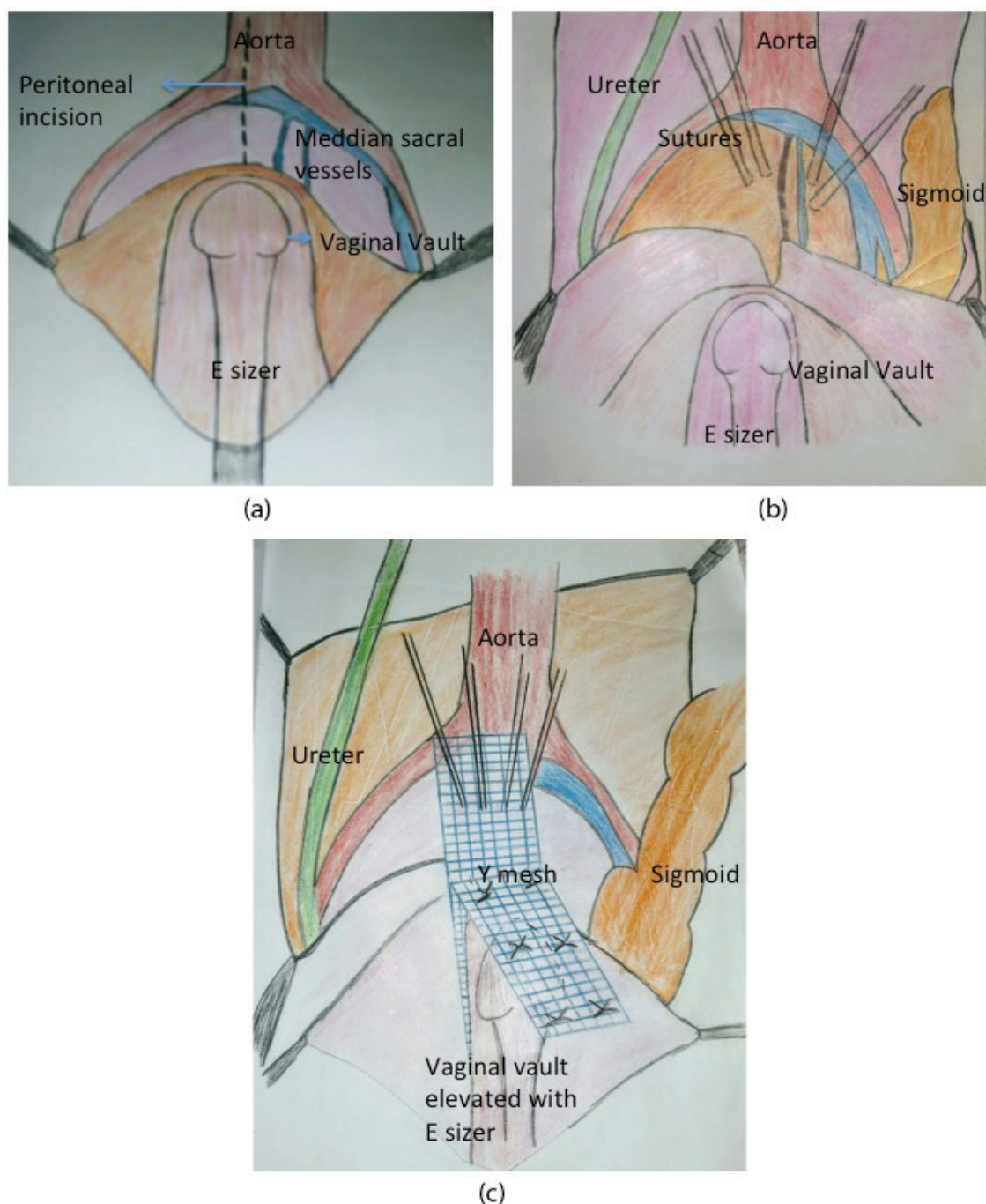


Figure 7. (a) The posterior peritoneum is incised over the sacral promontory and the median sacral artery and vein are identified. (b) Non-absorbable sutures are passed through the presacral fascia. The vaginal vault is elevated with an E-sizer and the bladder is dissected anteriorly and the rectum is dissected posteriorly. (c) The inverted oblique limbs of Y shaped mesh are anchored to the anterior and posterior vaginal wall. The vertical limb is anchored to the presacral fascia.

The vertical limb of inverted Y is now anchored to the periosteum with 2–4 nonabsorbable 0 suture. The peritoneum over the sacrum is sutured carefully taking care to prevent ureteric injury (**Figure 7(a)–(c)**). A paravaginal repair to anchor the lateral vaginal wall with arcus tendineus fascia pelvis is done. The abdomen is closed in layers. After this a posterior colporrhaphy procedure is done to correct the laxity of the perineal body.

9. Corrections of pelvic organ prolapse with mesh systems

Over the last decade, mesh augmented surgical repair is being increasingly used in pelvic organ prolapse. In 2008, the FDA issued a warning against the use of mesh for prolapse and incontinence repair. The warning was repeated in 2011, although narrowing it to vaginal mesh used for correction of pelvic organ prolapse (not for anti-incontinence procedures or when used abdominally). These warnings arose from concerns over mesh erosion through vagina, pain, infection, bleeding, dyspareunia, organ perforation and urinary problems. While many of these complications are common to all pelvic floor repairs, mesh erosion and some type of organ perforation are surely unique to mesh and trocars used for its placement [27, 28].

10. Role of minimally invasive surgery in vaginal vault prolapse

Though the operating times are still longer than vaginal surgery, multiple studies of minimally invasive surgery, including the laparoscopic colpopexy, robotic sacrocolpopexy, show shorter hospital stays and less blood loss compared to the open abdominal approach, they are therefore presumably associated with quicker recovery and less pain.

Randomized trials of Laparoscopic sacrocolpopexy versus robotic sacrocolpopexy showed no difference in anatomical prolapse or bulge symptoms 1 year after surgery, demonstrating that long-term outcomes after these two minimally invasive approaches may be similar [29].

However, robotic assisted laparoscopy is significantly more expensive, mainly because of a longer duration of surgery (265 min for robotic sacrocolpopexy versus 199 for laparoscopic sacrocolpopexy).

11. Recurrent prolapse and stress urinary incontinence

Vault prolapse and incontinence can develop simultaneously after hysterectomy. Women with prolapse who are continent have an increased risk of developing de novo stress urinary incontinence after surgical prolapse repair. Therefore addressing stress urinary incontinence at the time of surgical intervention for prolapse is an important consideration for improving the quality of life. Performing an anti-incontinence procedure at the time of prolapse repair is effective in reducing the risks of occult stress urinary incontinence postoperatively.

12. Operations for complete eversion of vagina

The management is always surgical because the prolapse has a tendency to enlarge gradually due to increased intraabdominal pressure. The vaginal prolapse also carries a rare risk of vaginal evisceration if not treated on time.

Rarely in elderly women who are not sexually active and have comorbidities the surgical removal of vagina (colpectomy) and closing of the vaginal space (colpocleisis) can be performed. These surgeries are rarely performed due to advances in anesthesia, as safe drugs for anesthesia in elderly are now available. The surgeon should also be sensitive towards the future coital activity and the underlying issues of patient self-image [30].

13. Conclusion

The assessment of recurrent pelvic floor dysfunction can be done clinically aided with imaging. The patient records of previous surgery are important. Vaginal apical prolapse surgery should always be combined with meticulous culdoplasty to correct the enterocele that is associated with vaginal prolapse.

When the previous surgery is sacrospinous ligament suspension, recurrent anterior vaginal prolapse is common as the vaginal axis gets deflected in sacrospinous fixation and the lines of force by increased intraabdominal pressure are directed across the vagina.

Each case should be individualized; keeping in mind the etiology of recurrent prolapse and surgical correction directed towards the cause. It is unclear whether the best route of surgical reconstruction for post hysterectomy vaginal apical prolapse is abdominal or vaginal. The most proper reconstructive surgery should be site specific, individualized and based on operating surgeon's expertise and experience.

Author details

Nidhi Sharma* and Sudakshina Chakrabarti

*Address all correspondence to: drbonuramkumar@yahoo.co.in

Saveetha University, Chennai, India

References

- [1] Delancey JO. Anatomic aspects of vaginal eversion after hysterectomy. *American Journal of Obstetrics and Gynecology*. 1992;**166**:1717-1724
- [2] Ren S, Xie B, Wang J, QiguoRong. Three-dimensional modeling of the pelvic floor support systems of subjects with or without pelvic organ prolapse. *BioMed Research International*. 2015;**2015**:845985. <http://dx.doi.org/10.11>
- [3] De Groat WC. Neuroanatomy and neurophysiology: Innervation of the lower urinary tract. Female urology. In: Raz S, Rodriguez L, editors. 3rd ed. Vol. 3. Philadelphia, PA: WB Saunders Company; 2008. pp. 26-46

- [4] Raizada V, Mittal RK. Pelvic floor anatomy and applied physiology. *Gastroenterology Clinics of North America*. 2008;**37**(3):493
- [5] Loubeyre P, Copercini M, Patrick Petignat and Jean Bernard Dubuisson. Levator Ani muscle complex anatomic findings in nulliparous patients at thin section MR imaging with double opacification. *Radiology*. 2012;**262**(2):538-543
- [6] Mouchel T, Mouchel F. Basic anatomic features in Pelviperrineology. *Pelviperineology*. Dec. 2008;**27**(4):156-159
- [7] Kindra A, Larson, Yousuf A, Delancey JOL. Perineal body anatomy in living women: 3D analysis using thin slice magnetic resonance imaging. *American Journal of Obstetrics and Gynecology*. 2010;**203**(5):494
- [8] Richard S. Snell *Clinical Anatomy*. 9th ed. Philadelphia: Wolters Kluwer, Lippincott Williams & Wilkins; 2012
- [9] Gill BC, Rackley RR. Urinary Incontinence Relevant Anatomy. <http://emedicine.medscape.com/article/1988009-overview>
- [10] Gormley EA, Lightner DJ, Burgio KL, Chai TC, Clemens JQ, CulkinDJ, Das AK, Foster HE Jr, Scarpero HM, Tessier CD, Vasavada SP, et al. Diagnosis and treatment of overactive bladder (nonneurogenic) in adults: AUA/SUFU guideline. *The Journal of Urology*. 2012;**188**(6 Suppl):2455-2463. DOI: 10.1016/j.juro.2012.09.079
- [11] Lucas MG, Bedretidnova D, Bosch JLHR, Burkhard F, Cruz F, Nambiar AK, Nilsson CG, De Ridder DJMK, Tubaro A, Pickard RS. EAU Guidelines on Urinary Incontinence. European Association of Urology. 2014. Available from: http://www.uroweb.org/gls/pdf/20%20Urinary%20Incontinence_LR.pdf
- [12] Swift S. Validation of a simplified technique for using POPQ pelvic organ prolapse quantification system. *International Urogynecology Journal*. 2006;**17**:615-620
- [13] Bland DR, Earle BB. Use of the pelvic organ prolapse staging system of the International Continence Society, Society of Gynecological Surgeons in Perimenopausal Women. *American Journal of Obstetrics and Gynecology*. 1999;**181**:1324-1328
- [14] Goldman HB, Wyndaele JJ, Kaplan SA, Wang JT, Ntanios F. Defining response and non-response to treatment in-patients with overactive bladder: A systematic review. *Current Medical Research and Opinion*. 2014;**30**(3):509-526. DOI: 10.1185/03007995.2013.860021
- [15] Barber MD, Walters MD, Bump RC. Short forms of two condition-specific quality-of-life questionnaires for women with pelvic floor disorders (PFDI-20 and PFIQ-7). *American Journal of Obstetrics and Gynecology*. 2005;**193**:103-113
- [16] Goba GK, Legesse AY, Zelelow YB, Gebreselassie MA, Rogers RG, Kenton KS, Mueller MG. Reliability and validity of the tigrigna version of the pelvic floor distress inventory-short form 20 (PFDI-20) and pelvic floor impact questionnaire-7 (PFIQ-7). *International Urogynecology Journal*. 2018. DOI: 10.1007/s00192-018-3583-9. [Epub ahead of print] PMID: 29536138

- [17] Price N, Jackson SR, Avery K, Brookes ST, Abrams P. Development and psychometric evaluation of the ICIQ vaginal symptoms questionnaire: The ICIQ-VS. *BJOG : An International Journal of Obstetrics and Gynaecology*. 2006;**113**(6):700-712. PMID: 16709214
- [18] Homma Y, Kakizaki H, Yamaguchi O, et al. Assessment of overactive bladder symptoms: Comparison of 3-day bladder diary and the overactive bladder symptom score. *Urology*. 2011;**77**:60-64
- [19] Apostolidis A, Kirana PS, Chiu G, Link C, Tsiouprou M, Hatzichristou D. Gender and age differences in the perception of bother and health care seeking for lower urinary tract symptoms: Results from the hospitalised and outpatients' profile and expectations study. *European Urology*. 2009;**56**:937-947
- [20] Irwin DE, Milsom I, Hunskaar S, et al. Population-based survey of urinary incontinence, overactive bladder, and other lower urinary tract symptoms in five countries: Results of the EPIC study. *European Urology*. 2006;**50**:1306-1315
- [21] RCOG and BSUG Joint Guideline 2015. Green Top Guideline No 46—Post Hysterectomy Vaginal Vault Prolapse. Available from: <https://www.rcog.org.uk/globalassets/documents/guidelines/gtg-46.pdf> [Published: July 24, 2015]
- [22] Argirović R, Likić-Ladević I, Vrzić-Petronijević S, Petronijević M, Ladević N. Application of transvaginal sacrospinous colpopexy in the treatment of pelvic organs prolapse. *Vojnosanitetski Pregled*. 2005;**62**(9):637-643. Serbian. PMID: 16229205
- [23] Goldberg RP, Tomezsko JE, Winkler HA, Koduri S, Culligan PJ, Sand PK. Anterior or posterior sacrospinous vaginal vault suspension: Long-term anatomic and functional evaluation. *Obstetrics & Gynecology*. 2001;**98**(2):199-204
- [24] Vaccaro C, Karram M. High uterosacral vaginal vault suspension to repair enterocele and apical prolapse. *OBG Management*. 2011;**23**(6):35-43
- [25] Serati M, Braga A, Bogani G, Maggiore ULR, Sorice P, Ghezzi F, Salvatore S. Iliococcygeus fixation for the treatment of apical vaginal prolapse: Efficacy and safety at 5 years of follow-up. *International Urogynecology Journal*. 2015;**26**(7):1007-1012. DOI: 10.1007/s00192-015-2629-5
- [26] NICE. Sacrocolpopexy Using Mesh for Vaginal Vault Prolapse Repair—NICE Interventional Procedure Guideline IPG283. January 2009. <https://www.nice.org.uk/guidance/ipg283/chapter/1-Guidance>
- [27] Alan JW. FDA safety communication: UPDATE on serious complications associated with transvaginal placement of surgical mesh for pelvic organ prolapse. *The Journal of Urology*. 2011;**186**(6):2328-2330
- [28] Jakus SM, Shapiro A, Hall CD. Biologic and synthetic graft use in pelvic surgery: A review. *Obstetrical & Gynecological Survey*. 2008;**63**(4):253-266
- [29] Farnam RW. Robotic uterosacral vaginal vault suspension. *Journal of Minimally Invasive Gynecology*. 2014;**21**(6):S20-S21
- [30] De Lancey JO, Morley JW. Total colpocleisis for vaginal eversion. *American Journal of Obstetrics and Gynecology*. 1997;**176**:1228-1235