

We are IntechOpen, the world's leading publisher of Open Access books Built by scientists, for scientists

6,900

Open access books available

185,000

International authors and editors

200M

Downloads

Our authors are among the

154

Countries delivered to

TOP 1%

most cited scientists

12.2%

Contributors from top 500 universities



WEB OF SCIENCE™

Selection of our books indexed in the Book Citation Index
in Web of Science™ Core Collection (BKCI)

Interested in publishing with us?
Contact book.department@intechopen.com

Numbers displayed above are based on latest data collected.
For more information visit www.intechopen.com



Pathophysiology of Pelvic Organ Prolapse

Lubna Razzak

Additional information is available at the end of the chapter

<http://dx.doi.org/10.5772/intechopen.76629>

Abstract

Pelvic organ support is provided by interaction between the pelvic floor muscle, ligaments and its connective tissues. Failure of anatomical support may result in pelvic organ prolapse. Therefore in managing anterior, posterior, or apical compartments prolapse, conceptual understanding of pelvic floor anatomy is essential for the surgeons. To appropriately treat these entities, comprehension of the various theories of the pathophysiology of pelvic organ prolapse is of paramount importance. DeLancey has described vaginal connective tissue support of the pelvis at three levels that has helped us to understand various clinical manifestations of pelvic organ support dysfunction. Pelvic floor disorder is frequently associated with etiological risk factors which include aging, parity, obesity, connective tissue disorder, increased intra-abdominal pressure and hysterectomy. A better understanding of pathophysiology of muscular, collagen, and neuronal components of the pelvic organs and their support would provide an insight of site specific defects and its prevention.

Keywords: prolapse, anatomy, pelvic floor muscles, compartments, collagen, risk factors

1. Introduction

Approximately one-third of adult women affected with pelvic organ prolapse, have significant impact on their quality of life and emotional well-being. Epidemiologic survey of the United States showed that pelvic organs prolapse (POP) becomes more prevalent as the population age advances [1]. Women have 11.1% lifetime risk of undergoing surgery for prolapse by age 80 [2] and a 30% risk of reoperation over a period of 4 years [3].

Pelvic organ prolapse is defined as the descent of the anterior, posterior, and/or apical vaginal compartment(s) with protrusion of one or more pelvic organs (e.g. bladder, uterus,

post-hysterectomy vaginal cuff, small bowel, or rectum) into the vagina [4]. These pathological changes are due to loss of structural support to pelvic organs resulting in an impact on women's quality of life. They arise because of injury and deterioration of the muscles, nerves, and connective tissue that support the pelvic floor and its contents.

Despite the high prevalence of POP, current treatment options remain suboptimal and do not address the underlying mechanisms of disease. Therefore, without improving our understanding of the pathophysiology of POP, treatment options and prevention of recurrence of POP would be limited. It is important to understand the pelvic floor support and the risk factors leading to POP. This chapter would include a review of pelvic floor support and the pathophysiology of POP.

2. Functional anatomy

Pelvic floor support includes:

1. Bony pelvis.
2. Subperitoneal connective tissue retinaculum and the broad ligament, including smooth muscle component and round ligament.
3. Cardinal and uterosacral ligaments complex.
4. Para vaginal attachments of the vaginal sulci to the arcus tendineus.
5. Urogenital diaphragm, including the pubourethrovaginal ligaments.
6. Pelvic diaphragm.
7. Fascia of denonvilliers.
8. Perineal body.

2.1. Bony pelvis

The support mechanism of Pelvic floor is provided by the complex and dynamic interactions of the muscles and connective tissues attachments within the bony pelvis. The bony pelvis provides fixed attachment to pelvic soft tissues and it consists of the two hip bones which made up of ilium, ischium and pubis, anteriorly fused with each other at pubic symphysis and the sacrum posteriorly. The pelvis has divided into the false (or greater) pelvis and the true (or lesser) pelvis by the iliopectineal line, coursing along the superior edge of the superior pubic ramus, and circumferentially forms the pelvic brim. Within the true pelvis are the sacrotuberous and sacrospinous ligaments, contribute significant stability of the pelvis. The lesser pelvis is the narrower continuation of the greater pelvis inferiorly and its inferior pelvic outlet is closed by the pelvic floor.

2.2. Muscular support

2.2.1. *Levator ani*

Levator ani muscles form the pelvic diaphragm, which provide the firm tissue support of the pelvic floor. These muscles are attached to the inner surface of the true pelvis form the muscular floor of the pelvis. Three components of the levator ani muscles recognized are pubococcygeus, iliococcygeus and puborectalis [5]. The **pubococcygeus**, also known as pubovisceralis muscle, arises from the anterior portion of the arcus tendineus and the back of the body of the pubis and is inserted with other parts of levator ani as anococcygeal raphe which forms a hiatus or levator plate. Pubovisceralis is further divided into pubovaginalis, puboanalis, and puboperinealis muscles [6]. The fibers attached to the perineal body are puboperinealis and draw this structure toward the pubic symphysis. The fibers attached to the anus at the intersphincteric groove between the internal and external anal sphincter are puboanalis. It elevates the anus and along with the rest of the pubococcygeus and puborectalis fibers keep the urogenital hiatus closed. Pubovaginalis refers to the medial fibers of pubococcygeus that attach to the lateral walls of the vagina.

The iliococcygeus arises from the arcus tendineus of the levator ani to the ischial spine and inserted into anococcygeal raphe. The puborectalis fibers of the levator ani (LA) muscle arises on lowest portion of pubic symphysis. It passes downward and backward on either side of vagina and fuses behind the rectum and form U-shaped muscular sling encircling the junction between the rectum and anus.

2.2.2. *Coccygeus muscle*

It forms the most posterior division of levator ani, arises from ischial spine and inserted into coccyx and lower sacrum. The piriformis and obturator internus form the posterolateral pelvic walls. The piriformis arises from the anterior and lateral surface of the sacrum and leaves the pelvis through the greater sciatic foramen, inserted to the greater trochanter of the femur. The obturator internus muscle arises from the ilium and ischium pelvic surfaces. It leaves the pelvis through the lesser sciatic foramen and inserted to the greater trochanter of the femur. The piriformis and obturator internus function as an external hip rotator.

2.3. Facial support

Endopelvic is composed of loose arrangements of collagen, elastin, and adipose tissue and condenses to form cardinal and uterosacral ligaments.

2.3.1. *The ATLA*

Arcus tendineus levator ani, dense connective tissue structure courses along the medial surface of the obturator internus muscle, serves as the point of origin for parts of the levator ani muscles (iliococcygeus). ATLA extends anteriorly from pubic tubercle to ischial spines posteriorly. The arcus tendineus fascia pelvis (ATFP), a thickening of fascia covering the medial

aspect of the iliococcygeus muscles, extends from the inner surface of the superior pubic rami to the ischial spines. It provides lateral attachment point for the proximal rectovaginal septum and pubocervical fascia [7].

2.3.2. Urogenital diaphragm

The urogenital diaphragm, a dense fibromuscular sheet is like sandwich and composed of superior and inferior fascial layers separated from one another by (compressor urethra and urethrovaginal sphincter muscles), the deep transverse perineal muscles. It attaches laterally to the ishiopubic rami and medially to the distal third of the vagina and to the perineal body. In standing position, urogenital diaphragm is almost horizontal and its fixation to perineal body contributes to the support of urethra and vesicourethral junction [5].

2.3.3. Perineal body

The perineal body is a pyramidal fibromuscular elastic structure found between the distal third of the posterior vaginal wall and the anus on a line between the ischial tuberosity. The perineal body apex is continuous with the rectovaginal septum (the fascia of Denonvilliers) and it extends 2–3 cm above the hymeneal ring.

2.3.4. Cardinal and uterosacral ligaments complex

The parametria attaches lateral to the uterus is known as the cardinal and uterosacral ligament complex. They form three dimensional complex attaching the lower uterine segment, cervix and upper vagina with sacrum and pelvic side walls. This complex maintains vaginal length and keeps the vaginal axis horizontal. The uterosacral ligament also provides suspension and assist in maintaining the position of the uterus and upper vagina over the levator plate.

Using 3D stress magnetic resonance imaging (MRI) in vivo, dynamic of the cardinal and uterosacral ligament for apical support with and without Valsalva have been explored. [8]. These imaging techniques continue to enhance our knowledge of the strain and lengthening of these structures, which in turn, may help in determining the nature and direction of apical support loss.

3. Subdivision of pelvic floor

Anterior compartment is bordered by pubic symphysis ventrally, levator Ani laterally and perineal membrane caudally.

Posterior compartment has sacrum and coccyx dorsally, levator ani muscles laterally and caudally. Rectovaginal fascia constitutes an incomplete layer ventrocranially. Ventrocaudal border is composed by the perineal body.

Middle compartment has no distinct borders described ventrally. Laterally there are components of levator ani muscles and the perineal body caudally. Rectovaginal fascia constitutes the dorsal border [9].

4. Pathogenesis

4.1. Risk factors of POP

4.1.1. Age

Age has been recognized as an intrinsic factor in the development of pelvic floor dysfunction and most consensus is in favor that it has a role in the etiology of female pelvic organ prolapse (POP) [10]. With advancing age, incidence and prevalence of POP increases. The relative prevalence of POP increased by about 40% with every decade of life, as demonstrated by a cross-sectional study of 1004 women (age 18–83 years) who attended their yearly examination [11].

Age and POP relation is hypothesized to be secondary to numerous factors including physiologic changes of the pelvic floor components and decline in estrogen during the postmenopausal period with advance age. This hypothesis is supported by Swift et al. study showing an increase in the odds ratio for pelvic prolapse from 1.04 to 1.46 for a change in 10 years of age [11].

4.1.2. Pregnancy and childbirth

There are hormonal induced physiological changes that occur in pelvic floor musculature and connective tissue during pregnancy. These alterations are vital for preparing the body to adjust the pelvic floor for vaginal birth. High level progesterone affects the pelvic floor by causing smooth muscle-relaxation and antagonizes estrogen effects.

Changes in biomechanical properties of the vaginal wall have been studied in fibulin-5 knockout mice (*Fbln5^{-/-}*) with and without prolapse [12]. He demonstrated that pregnant vaginal wall has increased distensibility, and decreased stiffness as compare to nonpregnant. The causative links between childbirth and prolapse have shown by various epidemiological and observational cohort studies [13, 14]. The pelvic structures affected by traumatic events are levator ani muscle complex, the pelvic nerves, the pelvic fascial structures and the anal sphincter.

Pregestational body mass index (BMI), BMI at term, duration of the first and second stages of labor, operative delivery, perineal lacerations, weight of the newborn and epidural analgesia are reported pregnancy related risk factors [14]. There is increased prevalence of true rectocele after vaginal childbirth as proven by many studies. Rectocele may be due to damage of the rectovaginal septum and Denonvillier's fascia in the posterior compartment [15]. Obstructed defaecation and pelvic organ prolapse are strongly associated with posterior compartment defects [16].

4.1.3. Raised intra-abdominal pressure

Chronically raised intra-abdominal pressure such as chronic constipation, higher body mass index (BMI), chronic cough, and repetitive heavy weight lifting seems to play a role in POP pathogenesis.

Morbid obesity was associated with 40% increase in the occurrence of uterine prolapse, 75% with rectocele and 57% with cystocele [17]. Five year follow up data [18] showed an increase in the risk for both anatomical and functional recurrence after vaginal surgery for POP in women with high body weight (>65 kg). Kuldish et al. studied the relationship between risk of prolapse progression in overweight and obese women compared with women with a normal BMI and found an increased by 32 and 48% for cystocele, by 37 and 58% for rectocele and by 43 and 69% for uterine prolapse [19]. Therefore it has been suggested that weight loss might help to prevent further progression and worsening of symptoms of prolapse and in reducing the post-surgical morbidity associated with obesity and prolapse surgery.

4.1.4. Previous pelvic organ surgery

Risk of subsequent pelvic organ prolapse is increased by hysterectomy however it takes years for development of symptomatic prolapse [20]. The mean interval between hysterectomy and surgery for pelvic organ prolapse in those who developed the prolapse was 19.3 years [21]. This occurs due to disruption of endopelvic fascia, uterosacral-cardinal ligament support and local nerve supply.

4.2. Pelvic floor defects

DeLancey [22] has described vaginal connective tissue support of the pelvis into three levels (Figure 1) that help to understand various clinical manifestations of pelvic organ support dysfunction. Level I, II and III representing apical, midvaginal and distal support respectively. Level I support is provided by cardinal and uterosacral ligament complex that suspends the vagina by attaching it to the pelvic side wall and is the most cephalad supporting structures.

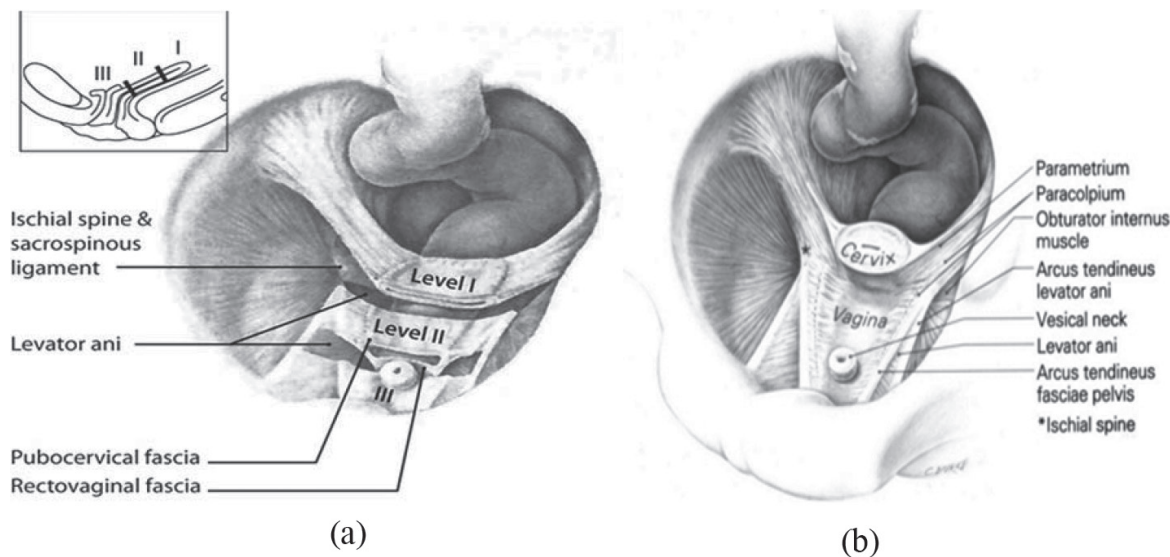


Figure 1. (A) In level I, paracolpium suspends vagina from the lateral pelvic walls. In level II, the vagina is attached to arcus tendineus of pelvic fascia and superior fascia of levator ani muscles. (B) Vagina and supportive structures drawn from dissection of a 56-year-old cadaver after hysterectomy: The bladder has been removed above the vesical neck. Paracolpium extends along the lateral wall of vagina. Reprinted, with permission, from DeLancey [22].

In the middle vaginal portion, the vagina attaches laterally to the arcus tendineus and fascia of the levator ani muscles which stretches it transversely between the bladder and the rectum. The bladder support is provided by pubocervical fascia and its attachment through the endopelvic fascia to the pelvic side wall. Similarly, rectovaginal fascia forms the support of rectum and prevents it from protruding forward. The lower third of vagina fuses with the perineal membrane, levator ani muscles and perineal body and provided level III support.

4.2.1. *Compartments defects*

4.2.2. *Middle compartment defect*

According to the Integral Theory [23], the support to the upper vagina is provided by pericervical ring, form by pubocervical fascia (anteriorly), cardinal ligaments (laterally), uterosacral ligaments (posterolateral), and the rectovaginal fascia (posteriorly). The pelvic organs are suspended by three suspensory ligaments pubourethral (PUL), cardinal/uterosacral, and arcus tendineus fascia pelvis from the pelvic brim. Three directional muscle forces tension the organs to give them position, shape, and strength. The pelvic organs are opened or closed by neurologically coordinated forward and backward muscle forces contracting against these ligaments. Laxity or damage of these ligaments may nullify the muscle forces causing POP, urinary and bowel dysfunctions. Apical or middle compartment prolapse occurs, when support at bladder base is lost contributing to stress and urgency urinary symptoms, as support is provided by cervical ring [24].

On physical examination, detachment of this support may be recognized by assessing mobility and descent of the cervix and bulging of the anterior or posterior fornices. According to International Federation of Gynecology and Obstetrics (FIGO) [25] working group the reasons for apical descent are (1) the loss of apical support for the cardinal/uterosacral ligament complex, and (2) birth-related levator ani muscle injury.

Pelvic organ prolapse is believed to be associated with some degree of cervical elongation, possibly due to the increasing pressures causing downward displacement and hypertrophy of the cervix. Cervical lengths in women with and without Prolapse has been compared by Berger and Associates using pelvic MRI [26], and found that the amount of cervical elongation appeared to increase with greater degrees of uterine descent. Women with prolapse have 36.4% longer cervixes than women without prolapse. However, it is difficult to assess clinically the cervical elongation and its significance is undetermined. The pelvic organ prolapse quantification (POP-Q) [27] examination allows in relation to fixed anatomic landmarks to evaluate the stages of prolapse in distinct compartments. Hypertrophic cervical elongation was defined as the difference between point C and point D of POP-Q as greater than 8 cm [28].

4.2.3. *Anterior compartment defect*

In maintaining bladder position, anterior vaginal wall support has a major role. The main structures involved are the anterior vaginal wall, pubocervical fascia, arcus tendineus fasciae pelvis (ATFP), arcus tendineus levator ani (ATLA), endopelvic fascia, and levator ani muscle.

The anterior compartment receives level I support at the pericervical ring whereas level II support is provided at the mid portion of anterior vagina which is attached laterally to the arcus tendineus fascia of the pelvic sidewall. The ATFPs act as suspension cables on either side of the vagina and bladder, harbor them to the pelvic wall and its detachment induces pelvic imbalance that may lead to lateral cystocele.

Petros described that bladder is supported anteriorly by the pubovesical ligaments and posteriorly by the cervical ring and laterally by the endopelvic fascia and ATFP [29]. The Pubocervical fascia is the main ventral support structure of the bladder, according to Petros. And disruption in pubocervical fascia results in cystocele. Level III (fusion) support at the distal third of the anterior compartment constitutes by fusion of the pubocervical fascia to the perineal membrane, perineal body, and levator ani muscles [30]. Although, controversy over the existence of a separate layer of fascia between the bladder and vagina. However, histologic studies of the anterior vaginal wall have failed to validate a separate layer of fascia between the vagina and the bladder [31]. Numerous cadaveric studies have demonstrated that the vesicovaginal space consists of fibroadipose tissue containing nerves and vascular channels [32] hence it has been recommended to use term “vaginal muscularis” or “fibromuscular wall” instead of using the term pubocervical or pubovesical fascia when describing the anterior vaginal wall tissue and support [33].

For the understanding of anterior compartment prolapse, different theories evolved with time. Richardson described areas of “breaks” in the “fascia” of the anterior vaginal wall, in the form of lateral paravaginal defects, transverse defect due to separation of the pubocervical fascia from the pericervical ring and, anteroposterior separation of fascia between bladder and vagina result in midline defect [34].

Petros' and DeLancey's anatomic/functional theories of bladder support structures discriminated three types of cystocele include apical, medial, and lateral or paravaginal [22, 29]. Apical cystocele is due to anatomic defect in the upper third of the vagina which include endopelvic fascia and DeLancey's level 1 ligament complex. Medial cystocele relates to the cervical ring defect. DeLancey found association between cervical-ring defect and high-grade cystocele by assessing anatomical lesions on MRI. Defects in Uterosacral ligaments and the Pubocervical fascia result in 75% of high-grade cystoceles. Lateral cystocele relate to both ligamentous and pelviperineal muscular defect which involves pubocervical fascia, the ATLA and the ATFP. Detachment of any of these bladder support result into lateral cystocele. Other factors such as obstructed voiding symptoms may be indicators of prolapse severity or absence of vaginal rugae also may suggest the location of certain anterior wall support defects [35].

Using biomechanical model, Chen and associates [36] analyzed the magnitude of anterior vaginal wall prolapse. They postulated that anterior vaginal prolapse dependent on the degree of impairment sustained by the pubovisceral muscle and the cardinal/uterosacral ligament complex under raised intra-abdominal pressure. They demonstrated the loss of support of the levator ani muscles leads to downward rotation of the levator plate (trap door opens), and widening of the urogenital hiatus, and worsening anterior vaginal wall prolapse, trap door theory effect.

4.2.4. Posterior compartment

Level III support of posterior vaginal wall is via fusion of the “rectovaginal fascia” to the perineal membrane, perineal body, and levator ani muscles and prevents rectum downward descent in this region. The middle third of the vaginal (Level II) support is through lateral endopelvic fascial attachments. Level I support shared with that of the anterior compartment (cardinal and uterosacral ligaments), where anterior and posterior vaginal walls abut.

The concepts on the mechanical support in the posterior compartment have been introduced by DeLancey [37]. According to that the pelvic floor closure by the puborectalis muscle contraction draws the posterior vaginal wall against the anterior vaginal wall, allowing for balanced pressures on either wall upon Valsalva. With the levator ani muscles injury, that created an unbalanced downward force on the posterior compartment, result in tension on the structures associated with level II support.

The posterior paravaginal defects due to loss of lateral attachments to the rectovaginal fascia whereas detachments of the distal “rectovaginal fascia” to the perineal body, which may evident as a perineal bulge or “low” posterior wall prolapse. In contrast high posterior wall defects are associated to loss of level I support to the pericervical ring and cardinal uterosacral complex.

4.2.5. Alteration of collagen and smooth muscles of the vagina

Comprehensively, it has been reviewed that abnormal synthesis or degradation of collagen and elastin fibers of the vaginal wall contributes to the pathophysiology of prolapse [38].

The pelvic organs are invested by connective tissues that provide the anatomic support of the pelvis and its contents. Histologically the normal vaginal wall comprises of four layers: a superficial non-keratinised stratified squamous epithelium; a subepithelial dense connective tissue layer composed primarily of collagen and elastin; muscularis; a layer of smooth muscle and adventitia, composed of loose connective tissue. The subepithelium and muscularis together give the tensile strength to the vaginal wall. The connective tissues of the vagina and supportive tissues comprise predominantly of fibrillar component (collagen and elastin) embedded in a non-fibrillar component (noncollagenous glycoproteins, hyaluronan, and proteoglycans), with the exception of the arcus tendineus, contain a significant amount of smooth muscle [39].

Collagen types I, III are the main structural constituents of vaginal epithelium and endopelvic fascia. Type I collagen confers strength to tissues associated with ligamentous tissue while type III contributes to elasticity found in loose areolar tissue, which makes up the vaginal wall adventitia and surrounds the pelvic organs. The ratio of collagen I to III is an indicator of tensile strength: the higher the amount of collagen type I, the higher is the mechanical strength. Balance is precisely maintained between quality and quantity of collagen through synthesis, posttranslational modification, and degradation and its deficiencies has been associated with the development of pelvic organ prolapses.

The matrix metalloproteinases (MMPs) is proteolytic enzyme involved in both physiological and pathological tissue remodeling in women with and without prolapse. Women predispose to prolapse with an excessive tendency toward connective tissue degradation. The proteolytic

activity in turn is regulated by inhibitors, TIMPs who bind with MMPs and inhibit its activity. In comparing women without prolapse, prolapse showed higher expression of MMP-2 mRNA with a concurrent decrease in the inhibitor TIMP-2 [40].

On comparing pre and postmenopausal women with and without prolapse, Takano [41] found decreased in amount of collagen with prolapse irrespective of menopausal status. Moalli et al. [42] demonstrated an increased in collagen III in vaginal subepithelium and muscularis in women with prolapse independent of age and parity. There is also Increase in collagen III content in the uterosacral and cardinal ligaments in women with prolapse [43]. The Moalli's group [44] analyzed a reduced in the ratio of collagen I/(III + V) is associated with menopause and with used of hormonal therapy restoration of this ratio to menarche level. This suggested the biomechanical properties of the supportive tissues of the vagina may improve with used of sex steroid hormones. Thus the increased stretchability and distensibility and decline in tensile strength associated with a higher content of collagen III are likely to contribute to the progression of POP.

5. Conclusion

Better understanding of pelvic functional anatomy, helps in understanding the pathophysiology of POP. The major support is by the levator ani muscles, pelvic connective tissue, vaginal walls and defects in these structures results in the genesis of pelvic floor dysfunction. Although the etiology of POP is multifactorial, but vaginal delivery is recognized as the strongest risk factor by many epidemiologic studies. However more research in these areas will, in turn lead to development of preventative strategies and better treatment modalities in women at high risk for the development of POP.

Author details

Lubna Razzak

Address all correspondence to: lubna.razzak@aku.edu

Aga Khan University, Karachi, Pakistan

References

- [1] National Center for Health Statistics (US). Health, United States: With Special Feature on Medical Technology; 2009
- [2] Olsen AL, Smith VJ, Bergstrom JO, Colling JC, Clark AL. Epidemiology of surgically managed pelvic organ prolapse and urinary incontinence. *Obstetrics & Gynecology*. Apr 1, 1997;89(4):501-506

- [3] Boyles SH, Weber AM, Meyn L. Procedures for pelvic organ prolapse in the United States, 1979-1997. *American Journal of Obstetrics and Gynecology*. Jan 31, 2003;**188**(1):108-115
- [4] DeLancey JO. The hidden epidemic of pelvic floor dysfunction: Achievable goals for improved prevention and treatment. *American Journal of Obstetrics and Gynecology*. May 31, 2005;**192**(5):1488-1495
- [5] Corton MM. Aspects of gynecologic surgery. Chapter 38. Anatomy. In: Hoffman BL, Schorge JO, Schaffer JI, et al, editors. *Williams Gynecology*. 2nd ed. New York: McGraw-Hill Medical; 2012. pp. 917-947
- [6] Kearney R, Sawhney R, DeLancey JO. Levator ani muscle anatomy evaluated by origin-insertion pairs. *Obstetrics and Gynecology*. Jul 2004;**104**(1):168
- [7] Albright TS, Gehrich AP, Davis GD, et al. Arcus tendineus fascia pelvis: A further understanding. *American Journal of Obstetrics and Gynecology*. Sep 30, 2005;**193**(3):677-681
- [8] Luo J, Betschart C, Chen L, et al. Using stress MRI to analyze the 3D changes in apical ligament geometry from rest to maximal Valsalva: A pilot study. *International Urogynecology Journal*. Feb 1, 2014;**25**(2):197-203
- [9] Santoro GA, Sultan AH. Pelvic floor anatomy and imaging. In: *Seminars in Colon and Rectal Surgery*. Vol. 27, No. 1. Elsevier; Mar 1, 2016. pp. 5-14
- [10] Jelovsek JE, Maher C, Barber MD. Pelvic organ prolapse. *The Lancet*. Mar 30, 2007;**369**(9566):1027-1038
- [11] Swift S et al. Pelvic organ support study (POSST): The distribution, clinical definition, and epidemiologic condition of pelvic organ support defects. *American Journal of Obstetrics and Gynecology*. Mar 31, 2005;**192**(3):795-806
- [12] Rahn DD et al. Biomechanical properties of the vaginal wall: Effect of pregnancy, elastic fiber deficiency, and pelvic organ prolapse. *American Journal of Obstetrics and Gynecology*. May 31, 2008;**198**(5):590-e1
- [13] O'Boyle AL et al. Pelvic organ support in nulliparous pregnant and nonpregnant women: A case control study. *American Journal of Obstetrics and Gynecology*. Jul 31, 2002;**187**(1):99-102
- [14] Bertozzi S et al. Impact of episiotomy on pelvic floor disorders and their influence on women's wellness after the sixth month postpartum: A retrospective study. *BMC Women's Health*. Apr 18, 2011;**11**(1):12
- [15] Dietz H, Steensma AB. The role of childbirth in the aetiology of rectocele. *BJOG: An International Journal of Obstetrics & Gynaecology*. Mar 1, 2006;**113**(3):264-267
- [16] Dietz HP, Korda A. Which bowel symptoms are most strongly associated with as rectocele? *Australian and New Zealand Journal of Obstetrics and Gynaecology*. Dec 1, 2005;**45**(6):505-508

- [17] Hendrix SL, Clark A, Nygaard I, et al. Pelvic organ prolapse in the Women's Health Initiative: Gravity and gravidity. *American Journal of Obstetrics and Gynecology*. Jun 30, 2002;**186**(6):1160-1166
- [18] Diez-Itza I, Aizpitarte I, Becerro A. Risk factors for the recurrence of pelvic organ prolapse after vaginal surgery: A review at 5 years after surgery. *International Urogynecology Journal*. Nov 1, 2007;**18**(11):1317
- [19] Kudish BI et al. Effect of weight change on natural history of pelvic organ prolapse. *Obstetrics and Gynecology*.. Jan 2009;**113**(1):81
- [20] Moalli PA, Ivy SJ, Meyn LA, Zyczynski HM. Risk factors associated with pelvic floor disorders in women undergoing surgical repair. *Obstetrics & Gynecology*. May 31, 2003;**101**(5):869-874
- [21] Clark AL, Gregory T, Smith VJ, Edwards R. Epidemiologic evaluation of reoperation for surgically treated pelvic organ prolapse and urinary incontinence. *American Journal of Obstetrics and Gynecology*. Nov 30, 2003;**189**(5):1261-1267
- [22] DeLancey JO. Anatomie aspects of vaginal eversion after hysterectomy. *American Journal of Obstetrics and Gynecology*. Jun 1, 1992;**166**(6):1717-1728
- [23] Liedl B et al. Update of the integral theory and system for management of pelvic floor dysfunction in females. *European Urology Supplements*. Apr 1, 2018;**17**(3):100-8
- [24] Petros PE, Ulmsten UI. An integral theory of female urinary incontinence. *Acta Obstetricia et Gynecologica Scandinavica*. Jan 1, 1990;**69**(S153):7-31
- [25] Betschart C et al. Management of apical compartment prolapse (uterine and vault prolapse): A FIGO Working Group report. *Neurourology and Urodynamics*. Feb 1, 2017;**36**(2):507-513
- [26] Berger MB, Ramanah R, Guire KE, et al. Is cervical elongation associated with pelvic organ prolapse? *International Urogynecology Journal*. Aug 1, 2012;**23**(8):1095-1103
- [27] Bump RC, Mattiasson A, Bo K, et al. The standardization of terminology of female pelvic organ prolapse and pelvic floor dysfunction. *American Journal of Obstetrics and Gynecology*. Jul 31, 1996;**175**(1):10-17
- [28] Ibeanu OA, Chesson RR, Sandquist D, et al. Hypertrophic cervical elongation: Clinical and histological correlations. *International Urogynecology Journal*. Aug 1, 2010;**21**(8):995-1000
- [29] Papa Petros PE, Ulmsten UI. An integral theory of female urinary incontinence: Experimental and clinical considerations. *Acta obstetricia et gynecologica Scandinavica*. Supplement. 1990;**153**:7-31
- [30] Ricci JV, Thom CH. The myth of a surgically useful fascia in vaginal plastic reconstructions. *Quarterly Review of Surgery*. Dec 1954;**11**(4):253

- [31] Tamilselvi A. Current concepts in pelvic anatomy. In: Principles and Practice of Urogynaecology. India: Springer; 2015. pp. 3-15
- [32] Weber AM, Walters MD. Anterior vaginal prolapse: review of anatomy and techniques of surgical repair. *Obstetrics & Gynecology*. Feb 1, 1997;**89**(2):311-318
- [33] Corton MM. Anatomy of pelvic floor dysfunction. *Obstetrics and Gynecology Clinics of North America*. Sep 30, 2009;**36**(3):401-419
- [34] Maldonado PA, Wai CY. Pelvic organ prolapse: New concepts in pelvic floor anatomy. *Obstetrics and Gynecology Clinics*. Mar 1, 2016;**43**(1):15-26
- [35] Whiteside JL, Barber MD, Paraiso MF, Walters MD. Vaginal rugae: Measurement and significance. *Climacteric*. Mar 1, 2005;**8**(1):71-75
- [36] Chen L, Ashton-Miller JA, Hsu Y, DeLancey JO. Interaction between apical supports and levator ani in anterior vaginal support: Theoretical analysis. *Obstetrics and Gynecology*. Aug 2006;**108**(2):324
- [37] DeLancey JO. Structural anatomy of the posterior pelvic compartment as it relates to rectocele. *American Journal of Obstetrics and Gynecology*. Apr 30, 1999;**180**(4):815-823
- [38] Kerkhof MH, Hendriks L, Brölmann HA. Changes in connective tissue in patients with pelvic organ prolapse—A review of the current literature. *International Urogynecology Journal*. Apr 1, 2009;**20**(4):461
- [39] Alperin M, Moalli PA. Remodeling of vaginal connective tissue in patients with prolapse. *Current Opinion in Obstetrics and Gynecology*. Oct 1, 2006;**18**(5):544-550
- [40] Liang CC et al. Expression of matrix metalloproteinase-2 and tissue inhibitors of metalloproteinase-1 (TIMP-1, TIMP-2 and TIMP-3) in women with uterine prolapse but without urinary incontinence. *European Journal of Obstetrics & Gynecology and Reproductive Biology*. Nov 30, 2010;**153**(1):94-98
- [41] Takano CC et al. Analysis of collagen in parametrium and vaginal apex of women with and without uterine prolapse. *International Urogynecology Journal*. Nov 1, 2002;**13**(6): 342-345
- [42] Moalli PA et al. Remodeling of vaginal connective tissue in patients with prolapse. *Obstetrics & Gynecology*. Nov 1, 2005;**106**(5, Part 1):953-963
- [43] Gabriel B et al. Uterosacral ligament in postmenopausal women with or without pelvic organ prolapse. *International Urogynecology Journal*. Dec 1, 2005;**16**(6):475-479
- [44] Moalli PA et al. Regulation of matrix metalloproteinase expression by estrogen in fibroblasts that are derived from the pelvic floor. *American Journal of Obstetrics and Gynecology*. Jul 31, 2002;**187**(1):72-79

