

We are IntechOpen, the world's leading publisher of Open Access books Built by scientists, for scientists

6,900

Open access books available

186,000

International authors and editors

200M

Downloads

Our authors are among the

154

Countries delivered to

TOP 1%

most cited scientists

12.2%

Contributors from top 500 universities



WEB OF SCIENCE™

Selection of our books indexed in the Book Citation Index
in Web of Science™ Core Collection (BKCI)

Interested in publishing with us?
Contact book.department@intechopen.com

Numbers displayed above are based on latest data collected.
For more information visit www.intechopen.com



Portal Vein Thrombosis in Liver Cirrhosis

Shuai Xue, Peisong Wang, Hui Han and
Guang Chen

Additional information is available at the end of the chapter

<http://dx.doi.org/10.5772/intechopen.76295>

Abstract

In liver cirrhosis, portal vein thrombosis (PVT), which is defined as thrombosis that occurs within the main portal vein and intrahepatic portal branches, is one of the most common complications. High incidence of PVT in the setting of liver cirrhosis is mainly due to hypercoagulable state and altered dynamic of blood flow in the portal vein. The clinical manifestations of PVT are variable among different patients, so the diagnosis of PVT is mainly dependent on the imaging examinations, like ultrasound, computed tomography and magnetic resonance imaging. The overall goal of treatment for PVT can be summarized as reducing risk factors of PVT, thus to prevent further expansion of thrombus and maintain portal patency and prevent and treat the symptoms of PVT by anticoagulants, local thrombolysis, transjugular intrahepatic portosystemic shunt and/or surgery. In future, due to the progress in vascular imaging and innovation in clinical anti-thrombotic drug, PVT could be prevented and cured effectively.

Keywords: portal vein thrombosis, cirrhosis, management, anticoagulant

1. Introduction

Portal vein thrombosis (PVT) is diagnosed when a venous thrombosis occurs within the main portal vein and intrahepatic portal branches [1, 2]. In liver cirrhosis, especially in advanced stages, PVT is one of the most common complications [3–5]. High incidence of PVT in the setting of liver cirrhosis is mainly due to hypercoagulable state and altered dynamics of blood flow in the portal vein [6–8]. Moreover, PVT will deteriorate liver cirrhosis by increasing portal vein pressure and decreasing blood flow into liver. Under severe circumstances, it will worsen symptoms of cirrhosis such as ascites, upper gastrointestinal bleeding, intestinal avascular necrosis and so on [3, 4, 9–11]. However, 30–50% patients with PVT will spontaneously

alleviate or recover without any treatment [4, 10, 12, 13]. This highlights the over-diagnosis of PVT in cirrhosis and questions whether PVT treatment will benefit cirrhotic patients, especially when they are diagnosed incidentally on imaging. Right now, there is no guideline or expert consensus on how to manage cirrhotic patients with PVT. A meta-analysis which includes 3735 cirrhotic patients demonstrated that PVT negatively influenced both mortality and hepatic decompensation, despite its limitation of including heterogeneous populations [14]. However, another prospective multicenter study which includes 863 Child-Pugh class A and 380 class B cirrhotic patients found PVT was not a prognostic factor for either mortality or hepatic decompensation [15]. A study that only investigated 42 cirrhotic patients with extra-hepatic nonmalignant partial PVT reported that no association was found between progression or regression of partial PVT and clinical outcomes. The model for end-stage liver disease (MELD) score, rather than PVT, was the predictor of worse prognosis in cirrhotic patients [16]. So, at present, the issue of whether PVT does or does not have influence on the natural history of cirrhosis is still controversial [17–19].

2. Prevalence

The prevalence and incidence of PVT in cirrhosis often varies from 1 to 28% among different studies depending on heterogeneity in diagnosis methods, different populations and variable follow-up time [16–22]. In a retrospective study of 150 patients with viral cirrhosis, the cumulative overall incidences of PVT were 12.8% at 1 year, 18.6% at 3 years, 20% at 5 years and 38.7% at 8–10 years, respectively [23]. In another study, which includes 701 cirrhosis patients without hepatocellular carcinoma, the incidence of PVT was 11.2% since they used ultrasound for diagnosis routinely [24]. PVT is more common in advanced cirrhosis and the incidence is positively related with the stage of cirrhosis, which is only 1% in compensated patients but 8.4% in severe cirrhosis waiting for liver transplantation [21, 25–28]. However, there are some limitations in these studies which weaken the magnitude and reliability of these conclusions like different subgroup patients and follow-up times as we previously mentioned. Violi et al. reported a study aimed at evaluating the prevalence of PVT in a broad spectrum of patients with cirrhosis and found 17% of 753 cirrhotic patients had PVT [29]. A multicenter randomized trial that includes 898 well-compensated cirrhosis patients reported that the 5-year cumulative incidence of PVT was 11.9% [30].

3. Pathophysiology

3.1. Hypercoagulable state of blood flow

After liver transplantation, the number of platelets will increase temporarily for a short time, which contributes to the hypercoagulable state of blood [31, 32]. That would be one of the significant reasons for PVT formation in liver transplantation patients. The study showed that surgery not only increased blood platelets but also activated their surface glycoprotein CD62P, reflecting the degree of platelet activation and causing a hypercoagulable state [33, 34]. Postoperative-elevated CD62P is closely related with PVT, which can be used as a sensitive

diagnostic biomarker of PVT [9, 35, 36]. Toshiki Matsui also reported that soluble form of glycoprotein VI, as a platelet activation marker, was associated with PVT formation after hepatectomy and splenectomy in patients with liver cirrhosis [37]. Another study from Poland found platelet aggregability was decreased in PVT patients [31]. In another logistic regression model, incidence of PVT was highly related with D-dimer and bilirubin [38, 39]. Additionally, increased whole blood viscosity due to increased number of erythrocytes and ability of aggregation as well as decreased deformability may be reasons for increased PVT formation [34, 40]. Both procoagulant and anticoagulant proteins decreased in liver cirrhosis patients at the same time, owing to decreased synthesis function of the liver, which often largely maintained in a dynamic balance [7, 8, 34, 41]. Therefore, the body is neither to bleed nor to form thrombosis. However, after liver transplantation surgery, venous injury would reduce the flow rate of portal vein; thus, anticoagulant-associated protein S and C decreased as well as anti-thrombin III [21]. Meanwhile, surgery consumes numerous coagulation factors. Factor VIII, VII factor-related antigens and anti-cardiolipin antibody increased, which both resulted in PVT formation. Factor VIII concentration and the ratio of the most powerful procoagulant (factor VIII) and anticoagulant (protein C) were considered as markers to indicate hypercoagulability [25, 38, 42–44]. Studies showed factor VIII was related to PVT in cirrhotic patients independently. Patients with factor VIII level above 129 IU/dl had six times the probability to PVT [45]. Some researchers reported in the literature that procoagulant gene mutations, including coagulation factor V Leiden G1691A, methylenetetrahydrofolate reductase C677T and prothrombin G20210A, may be associated with PVT [46, 47]. Recent studies showed that increased hemagglutinin activated fibrinolysin inhibition gene mutation and blood coagulation factor VII, which were closely related to the occurrence of PVT [1, 2].

3.2. Hemodynamic changes in the portal vein

PVT formation is associated with intrahepatic resistance and poor portal blood flow. Moreover, portal blood flow decreases more if cirrhosis progresses. That's why the incidence of PVT is much higher in advanced-stage cirrhotic patients compared with well-compensated ones [48]. Cirrhotic patients with PVT had low portal flow volumes and high collateral vessel flow velocity. Intraoperative clamp and squeeze will cause vein intimal injury, collagen exposure and activation of the coagulation system. After liver transplantation, blood flow in portal vein is relatively slow, which is easy to form turbulence and thrombosis [9, 25, 49, 50]. Portal vein blood flow velocity and PVT have an important relationship. Studies demonstrated that patients with portal vein blood flow <15 cm/s had higher incidence of PVT [17, 27, 50–52]. So, some researchers often regarded portal vein diameter as an independent risk factor for the formation of PVT. In short, because there are various changes in portal hemodynamics, the incidence of PVT is quite high after liver transplantation.

3.3. Endotoxemia

Cirrhosis is more likely to damage intestinal mucosal barrier which facilitates bacterial translocation and endotoxemia [53]. Endotoxemia not only can increase portal vein pressure but also can activate coagulation cascade. That explains why it can increase the PVT incidence in the portal system [54].

4. Diagnosis

4.1. Clinical manifestations

A study which includes 79 cirrhotic patients has shown that 57% of PVT were symptomatic and among them 39% had gastrointestinal bleeding and 70% had intestinal infarction [24]. Abdominal pain is generally the earliest clinical symptom after the acute formation of PVT. Usually, abdominal pain is limited within a specific region while few are diffuse pain and intermittent colic pain with longer durations. Nausea and vomiting occur in 50% of PVT patients [3, 4, 51, 55–57]. A few patients will have diarrhea or bloody stool. If complete intestinal obstruction occurs suddenly, abdominal pain is paroxysmal accompanied by significant nausea, vomiting without fart and defecation. Under this circumstance, there are no obvious physical examination signs, that the degree of pain is not consistent with the signs of the abdomen [19, 58, 59]. Increased anterior hepatic obstructive factors will cause decreased portal vein blood flow which aggravates liver damage, increases portal pressure, causes repeated upper gastrointestinal bleeding and refractory ascites and so on. In some severe cases, clinical manifestations of intestinal necrosis such as persistent abdominal pain, bloating, hemafecia, hematemesis, shock and peritoneal irritation will occur [18, 24, 26]. Abdominal puncture can be bloody ascites. In the event of intestinal necrosis, disease mortality rate can rise to 20–60%. Patients often suffer from persistent abdominal pain, hemafecia, abdominal cramps, ascites, multiple organ failure and so on. For chronic PVT, patients will have refractory bloating, diarrhea, upper abdominal pain and ascites due to gastrointestinal congestion and insufficient perfusion of liver portal vein [24]. The clinical manifestations of PVT are variable among different patients, so the clinical diagnosis of PVT is mainly dependent on the imaging examination.

4.2. Imaging

Ultrasound, the most common imaging way, is simple and easy to accurately evaluate PVT [60]. Thus, it is the preferred imaging method for diagnosis. Ultrasound diagnosis of PVT is characterized by abnormal echo in the portal vein, unclear boundary with the wall, CDFI: no blood flow signal, portal venous cavernous hemangioma; portal vein expansion before thrombosis site; and no display of portal vein if PVT is formed within a wide range [11, 17, 18, 60, 61]. The sensitivity and specificity of ultrasonography to diagnose PVT are up to 60 and 100% [60, 62]. Ultrasound can clearly demonstrate the blood flow, vascular diameter and the changes and the presence of thrombi. Ultrasound can also determine the formation of collateral circulation simultaneously through CDFI. But the ultrasound cannot reflect directly the situation of the portal vein and its branches, and the experience of the operator affects the accuracy of the diagnosis. Ultrasound angiography or ultrasound endoscopy can diagnose PVT more accurately that even raises the diagnostic sensitivity to 81% [24]. Some authors recommended contrasting enhanced ultrasound as the first-line imaging and “gold standard method” for the diagnosis of PVT [63, 64]. But ultrasound angiography and endoscopy also have some limitations. Firstly, they cannot evaluate the portal vein within the part of the liver and superior mesenteric vein end accurately. Moreover, they cannot assess the surrounding organs which may be affected by PVT [50, 63, 64].

Enhanced computer tomography (CT) or enhanced magnetic resonance imaging (MRI) examination by intravenous injection contrast can effectively solve the above deficiencies. By comparison with contrast, we can discover intraluminal filling defects and perfusion conditions for nearby organs at different times of the imaging process. CT angiography (CTA) and magnetic resonance angiography (MRA) greatly increase the accuracy of diagnosis. Some studies have showed that the sensitivity and the specificity for CTA were 86 and 95%. For MRA, the sensitivity was 100% and specificity was 98% [60, 65–67]. Typical CT signs of PVT are very intuitive: no-enhanced low-density intraluminal stripe or massive lesions within portal static. Occasionally, CT can also find an enhanced ring around thrombus due to nourishing small blood vessels. Moreover, CT can also help to diagnose primary liver cancer, cirrhosis and evaluate intestinal ischemia and necrosis. CTA has several advantages including short scan time, fast imaging speed and reduced motion artifact [67]. However, its main drawbacks can be related to some complications like contrast agent allergy, contrast agent nephropathy and other adverse reactions. The safety of MRA contract is significantly better than that of CTA. But MRA has the same disadvantages like motion artifacts, long-signal acquisition time and limited imaging range [66]. Therefore, patients with suspicious PVT should be enrolled in contract CT or MRI imaging, which can be more accurate for clinical diagnosis.

Angiography is the traditional method for diagnosis of PVT. It is not the routine examination of PVT because of its invasive feature. Angiography includes two categories: indirect and direct. Indirect angiography is through splenic artery and superior mesenteric artery to image [2, 65]. In this way, we can see the portal vein filling defect as well as the collateral circulation. The most important thing is we can put the catheter into the superior mesenteric artery and/or splenic artery branch to infuse thrombolytic drugs after indirect angiography. It means we can finish diagnosis and follow treatment after invasive process at one time. Direct angiography is divided into: percutaneous transhepatic portal angiography, which can display directly portal vein system and evaluate portal hemodynamics, and umbilical portal vein angiography, which is indicated for splenic vein thrombosis, spleen resection and failure of arterial portal angiography [50].

4.3. Laboratory tests

Usually, prothrombin time (PT) and activated partial thromboplastin time (APTT) were used as predictors for the coagulation state with cirrhosis, and even the predictive ability was poor [7, 34, 68]. Because they could not explain and represent natural anticoagulants such as anti-thrombin and protein C in vivo, the thrombin generation test, which used tissue factor as trigger and phospholipids as platelet substitutes, was considered more appropriate for evaluating thrombin generation. The test was regarded as representation of the balance between the pro- and anticoagulant proteins in plasma [33, 44]. Another test named thromboelastography (TEG) can monitor all kinds of hemostatic functions (coagulation, anticoagulation, fibrinolysis) continuously to predict thrombosis formation and dissolution dynamically. This test also emphasized the dynamic assessment of balanced status in blood coagulation and anticoagulation process [17, 18]. This is a new laboratory test to evaluate whether the blood is hypercoagulable, whether there is the formation of thrombus and whether the thrombus is stable. The effectiveness of clinical application needs to be further studied. Additionally, we

can exclude PVT patients with a 90% negative predictive value when the D-dimer level is less than 1.82 mg/l [38, 39, 69, 70]. Systemic evaluation of coagulation tests, including PT, international standardization ratio, partial thromboplastin time, and so on, could not fully assess the patient's coagulation abnormalities. Dynamic monitoring of vitamin K-related coagulation factors, fibrinogen, platelet function, fibrinolysis status as well as other coagulation factors simultaneously is essential.

5. Classification

According to PVT imaging findings preoperatively, Yerdel found a classification system as the following: grade I, <50% portal vein obstruction with or without micro-thrombus of the superior mesenteric vein; grade II, >50% portal vein obstruction with or without micro-thrombus of the superior mesenteric vein; grade III, complete portal vein and proximal superior mesenteric vein obstruction; and grade IV, complete portal vein and entire superior mesenteric vein obstruction [71].

6. PVT treatment

The overall goal of treatment for PVT can be summarized as reducing risk factors of PVT, thus to prevent further expansion of thrombus and maintain portal patency, prevent and treat the symptoms of PVT. For acute PVT, the aim is to prevent thrombus extension and intestinal infarction, whereas for chronic PVT, it is to prevent recurrent thrombosis, gastrointestinal bleeding and portal cholangiopathy [20, 35, 51].

6.1. Non-surgical treatment

The incidence of PVT is high in cirrhotic patients, but clinical studies found that 30–50% of patients with PVT could alleviate without any treatment. Longest diameter of portal vein and blood flow of the largest collateral circulation vein were closely related with the incidence of spontaneous alleviation in PVT patients [1, 21]. But another study demonstrated that untreated PVT was associated with increased mortality, especially in patients with low Child-Pugh scores. And there were strong correlations between anticoagulation therapy and lower thrombus progress rate as well as higher recanalization rate [11, 72, 73]. Furthermore, PVT has been reported as an independent risk factor for recurrent and refractory acute variceal bleeding [23, 74]. There is inconsistent guidance on the anticoagulant management of PVT. However, once the PVT is diagnosed, the optimal time of prevention and treatment often has been missed. Serious complications would increase mortality greatly for PVT patients. So, it is recommended for cirrhotic patients that routine color Doppler ultrasound assessment should be performed. Early diagnosis, early anticoagulant and thrombolytic therapy can effectively improve the prognosis of patients. A meta-analysis from Italy, which includes 8 studies comprising 353 patients with cirrhosis and PVT, demonstrated anticoagulant therapy (low-weight heparin or warfarin) could increase recanalization and reduce progression of thrombosis

effectively [75]. Meanwhile, these anticoagulants will not increase the incidence of any kinds of bleedings [75]. Another study from Italy found the benefits patients got outweighed the potential minor bleeding risk [76]. And they also concluded that portal hypertension, rather than anticoagulants, would be the real reason for the risk of major bleeding among cirrhotic patients with PVT. A prospective study from China which focused on patients with cirrhosis undergoing elective transjugular intrahepatic portosystemic shunt (TIPS) found that warfarin treatment within 12 months achieved a much higher rate of complete recanalization [77]. The commonly used drugs include warfarin, low molecular weight heparin and urokinase [78–81]. Most patients with acute PVT were recommended early anticoagulant therapy at least for 6 months. A systematic review and meta-analysis that summarized different regimens of anticoagulation has been reported [82]. In this study, the overall rate of portal vein recanalization was 37–93% and the anti-coagulation related bleeding was 0–18% [82]. In this way, we can not only reduce the incidence of PVT greatly but also increase PVT recanalization rate up to 39.3–100.0%.

In recent years, inhibitors of activated factor Xa (e.g., rivaroxaban) have been used in the prevention of clinical PVT. The advantages are convenient oral administration, no effect on the international standardization ratio and no need to monitor blood coagulation indicators. Hyeyoung Yang et al. reported a 63-year-old female who experienced complete resolution of recurrent acute PVT in liver cirrhosis after rivaroxaban treatment [83]. The disadvantage is there is no effective antagonist. When bleeding happens during anticoagulant therapy, the consequence is serious. However, some new oral anticoagulants' antidotes have been under investigation like andexanet alfa, P-glycoprotein substrates and drugs inducing CYP3A4. They all could inhibit the concentration or absorption of new oral anticoagulants and attenuate their effects remarkably [83, 84].

In short, clinical non-surgical methods are still mainly treatments of PVT in cirrhotic patients.

6.2. Local thrombolytic treatment

Local thrombolysis is divided into indirect way (femoral artery-superior mesenteric artery indwelling catheter thrombolysis) and direct way (percutaneous transhepatic portal vein thrombolysis) [13, 17, 18, 27, 35, 56, 85].

The advantages of the femoral artery-superior mesenteric artery catheter thrombolysis are simple and relative small trauma. It is just suitable for mild PVT without vascular occlusion. Because when PVT is found by this method, portal vein branches are usually in the stenosis or occlusion state by obstruction of thrombosis. Most of the drugs we injected for thrombolysis cannot reach the site of thrombus effectively. So, indications of this method are limited.

The advantages of the percutaneous transhepatic portal vein thrombolysis method are simple and show high success rates. However, we must stop this treatment when the patient has: (1) APTT significantly longer; (2) the international standardization ratio > 2; and (3) obvious abdominal pain, bloating, vomiting, hemafecia, increased puncture-point bleeding, more subcutaneous ecchymosis, hemoglobin continuing to decrease, faster heart rate, lower blood pressure and other signs of active bleeding.

6.3. TIPS

When severe PVT happened, thrombus blocked more than 50% lumen or completely blocked, anticoagulant therapy was unlikely to recanalization. Under this condition, we can choose TIPS. This method has the advantages as the following: the risk of thrombolysis is relatively small, and punctures can often reach directly to the thrombus site; at the same time intravascular technology (balloon plasty, stent replacement, thrombectomy and thrombolytic therapy surgery) can be applied to achieve the goal of treatment of PVT. A study from China which compared transcatheter selective superior mesenteric artery urokinase infusion and TIPS has found they were safe and effective for acute symptomatic PVT in cirrhosis [86]. But the operation was a relative difficult and lethal event as well as severe complications were still possible, so it is particularly important to assess the risk-benefit ratio of TIPS preoperatively. At present, the TIPS therapy methods for PVT are the following [87–89]:

- A. TIPS placement → portosystemic shunt → portal vein recanalization;
- B. TIPS placement through percutaneous ways portal vein recanalization;
- C. TIPS placement between hepatic vein and collateral vessel → no portal vein recanalization

For cirrhotic patients with refractory variceal bleeding and ascites, TIPS was considered as one of the major treatment strategies if the patient did not have PVT. PVT has changed natural history of liver cirrhosis and affected outcomes. So, in this circumstance, TIPS should be recommended with caution. No convincing evidence has been published to verify the superiority of TIPS over traditional anticoagulants. TIPS should only be recommended for severe PVT patients although technical difficulty rose sharply when severe PVT was diagnosed [89]. That means reliable predictors for PVT progression should be further investigated in future.

6.4. Surgical treatment of PVT

Surgery is relatively high risk. The commonly used methods are (1) PVT excision; (2) portal vein stent implantation, mainly aimed to relieve portal vein obstruction; (3) liver transplantation. During treatment, if the patient has the sustained abdominal pain, abdominal distension and other signs of peritonitis, laparotomy exploration should be performed early to prevent the occurrence of intestinal necrosis. When intestinal necrosis is diagnosed, intestinal and mesangial resections should be performed. At the same time, the intestinal end-to-end anastomosis should be done. Anticoagulation was continued after surgery to prevent thrombus reformation.

7. PVT prevention

Kawanaka et al. have shown that anti-thrombin III (AT III) activity and splenic vein diameter were the risk factors of PVT after surgery. Moreover, they used those risk factors to formulate risk stratification system [90]. According to the risk stratification, doctors can decide whether to give prevention or not: low risk: AT III activity $\geq 70\%$ and splenic vein straight diameter < 10 mm, no preventive treatment; intermediate risk: AT III activity $< 70\%$ or splenic

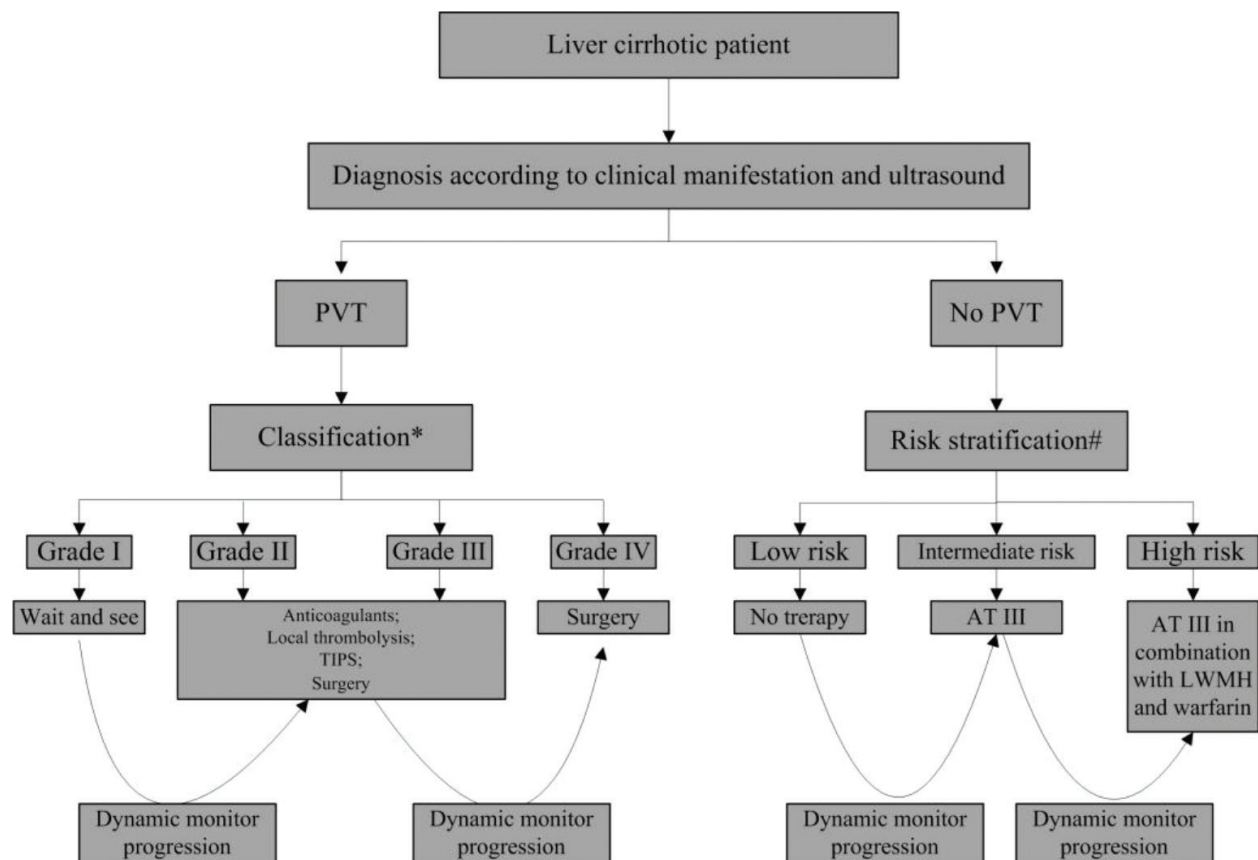


Figure 1. Algorithm for the treatment of portal vein thrombosis in liver cirrhosis. *Abbreviations:* PVT, portal vein thrombosis; TIPS, transjugular intrahepatic portosystemic shunt; AT III, anti-thrombin III therapy; LWMH, low-weight molecular heparin; *according to Yerdel's study [68]; # according to Kawanaka's study [90].

vein diameter ≥ 10 mm, simple AT III prevention treatment; and high risk: splenic vein diameter ≥ 15 mm or from the liver collateral circulation vein diameter ≥ 10 mm, AT III, low molecular weight heparin in conjunction with warfarin [90].

Enoxaparin was found to prevent PVT in advanced cirrhotic patients. Daily subcutaneous enoxaparin (4000 IU/day) could significantly reduce incidence of PVT in the short and long term [91, 92]. And enoxaparin can also decrease the liver decompensation rate and improve survival of patients who received liver transplantation [52, 91, 92].

Surgery on the portal vein system should be gentle and accurate. We should prevent unnecessary damage to the vascular endothelium and avoid ligation of chunk tissue. If there is no obvious bleeding tendency, surgeons should not use hemostatic after surgery which may result in thrombosis (Figure 1).

8. Conclusion

PVT was a clinical rare deep venous thrombosis but highly occurred in liver cirrhotic patients. Local or systemic factors alone or in combination make contribution to the formation of PVT. In clinical, PVT should be given enough attention due to its severe threat to the patient's

life and health. The overall treatment principles are early diagnosis, early treatment and prevention combined with treatment. In the future, due to the progress in vascular imaging and innovation in clinical anti-thrombotic drug, PVT could be prevented and cured effectively.

Author details

Shuai Xue, Peisong Wang, Hui Han and Guang Chen*

*Address all correspondence to: cg9293@sina.com

The General Surgery Center, The First Hospital of Jilin University, Changchun, Jilin, China

References

- [1] Chawla YK, Bodh V. Portal vein thrombosis. *Journal of Clinical and Experimental Hepatology*. 2015;**5**(1):22-40
- [2] Basit SA, Stone CD, Gish R. Portal vein thrombosis. *Clinics in Liver Disease*. 2015;**19**(1):199-221
- [3] Yang ZNJ, Costa KA, Novelli EM, Smith RE. Venous thromboembolism in cirrhosis. *Clinical and Applied Thrombosis-Hemostasis*. 2014;**20**(2):169-178
- [4] Handa P, Crowther M, Douketis JD. Portal vein thrombosis: A clinician-oriented and practical review. *Clinical and Applied Thrombosis-Hemostasis*. 2014;**20**(5):498-506
- [5] Tsochatzis EA, Bosch J, Burroughs AK. Liver cirrhosis. *Lancet*. 2014;**383**(9930):1749-1761
- [6] Cai CC, Liu SY. A meta-analysis of portal vein thrombosis in patients with liver cirrhosis. *Journal of Gastroenterology and Hepatology*. 2013;**28**:847
- [7] Schaden E, Saner FH, Goerlinger K. Coagulation pattern in critical liver dysfunction. *Current Opinion in Critical Care*. 2013;**19**(2):142-148
- [8] Mucino-Bermejo J, Carrillo-Esper R, Uribe M, Mendez-Sanchez N. Coagulation abnormalities in the cirrhotic patient. *Annals of Hepatology*. 2013;**12**(5):713-724
- [9] Ghabril M, Agarwal S, Lacerda M, Chalasani N, Kwo P, Tector AJ. Portal vein thrombosis is a risk factor for poor early outcomes after liver transplantation: Analysis of risk factors and outcomes for portal vein thrombosis in waitlisted patients. *Transplantation*. 2016;**100**(1):126-133
- [10] Girleanu I, Stanciu C, Cojocariu C, Boiculese L, Singeap AM, Trifan A. Natural course of nonmalignant partial portal vein thrombosis in cirrhotic patients. *Saudi Journal of Gastroenterology*. 2014;**20**(5):288-292

- [11] Borjas-Almaguer OD, Cortez-Hernandez CA, Gonzalez-Moreno EI, Bosques-Padilla FJ, Gonzalez-Gonzalez JA, Garza AA, et al. Portal vein thrombosis in patients with cirrhosis: Just a common finding or a predictor of poor outcome? *Annals of Hepatology*. 2016;**15**(6):902-906
- [12] Berry K, Taylor J, Liou IW, Ioannou GN. Portal vein thrombosis is not associated with increased mortality among patients with cirrhosis. *Clinical Gastroenterology and Hepatology*. 2015;**13**(3):585-593
- [13] Qi XS, Han GH, Fan DM. Management of portal vein thrombosis in liver cirrhosis. *Nature Reviews Gastroenterology & Hepatology*. 2014;**11**(7):435-446
- [14] Stine JG, Shah PM, Cornella SL, Rudnick SR, Stukenborg GR, Northup P. Portal vein thrombosis, mortality and hepatic decompensation in patients with cirrhosis: A meta-analysis. *Hepatology*. 2015;**62**:943A-A
- [15] Nery F, Chevret S, Condat B, de Raucourt E, Boudaoud L, Rautou PE, et al. Causes and consequences of portal vein thrombosis in 1,243 patients with cirrhosis: Results of a longitudinal study. *Hepatology*. 2015;**61**(2):660-667
- [16] Luca A, Caruso S, Milazzo M, Marrone G, Mamone G, Crino F, et al. Natural course of extrahepatic nonmalignant partial portal vein thrombosis in patients with cirrhosis. *Radiology*. 2012;**265**(1):124-132
- [17] von Kockritz L, De Gottardi A, Trebicka J, Praktiknjo M. Portal vein thrombosis in patients with cirrhosis. *Gastroenterology Report*. 2017;**5**(2):148-156
- [18] Fujiyama S, Saitoh S, Kawamura Y, Sezaki H, Hosaka T, Akuta N, et al. Portal vein thrombosis in liver cirrhosis: Incidence, management, and outcome. *BMC Gastroenterology*. 2017;**17**(1):112
- [19] Loudin M, Ahn J. Portal vein thrombosis in cirrhosis. *Journal of Clinical Gastroenterology*. 2017;**51**(7):579-585
- [20] Haris M, Thachil J. The problem with incidental and chronic portal vein thrombosis. *European Journal of Internal Medicine*. 2017;**39**:E29-E30
- [21] Chen H, Turon F, Hernandez-Gea V, Fuster J, Garcia-Criado A, Barrufet M, et al. Nontumoral portal vein thrombosis in patients awaiting liver transplantation. *Liver Transplantation*. 2016;**22**(3):352-365
- [22] Cruz-Ramon V, Chinchilla-Lopez P, Ramirez-Perez O, Mendez-Sanchez N. Effects of portal vein thrombosis on the outcomes of liver cirrhosis: A Mexican perspective. *Journal of Translational Internal Medicine*. 2017;**5**(4):189-191
- [23] Maruyama H, Okugawa H, Takahashi M, Yokosuka O. De novo portal vein thrombosis in virus-related cirrhosis: Predictive factors and long-term outcomes. *American Journal of Gastroenterology*. 2013;**108**(4):568-574

- [24] Amitrano L, Guardascione MA, Brancaccio V, Margaglione M, Manguso F, Iannaccone L, et al. Risk factors and clinical presentation of portal vein thrombosis in patients with liver cirrhosis. *Journal of Hepatology*. 2004;**40**(5):736-741
- [25] Lankarani KB, Homayon K, Motevalli D, Heidari ST, Alavian SM, Malek-Hosseini SA. Risk factors for portal vein thrombosis in patients with cirrhosis awaiting liver transplantation in shiraz, Iran. *Hepatitis Monthly*. 2015;**15**(12):e26407
- [26] Eshraghian A, Nikeghbalian S, Kazemi K, Shamsaeefar A, SAM H. Prevalence and risk factors of portal vein thrombosis in patients with liver cirrhosis and its impact on outcomes after liver transplantation. *Transplant International*. 2017;**30**:146
- [27] Qi XS, Li HY, Liu X, Yao H, Han GH, Hu FR, et al. Novel insights into the development of portal vein thrombosis in cirrhosis patients. *Expert Review of Gastroenterology & Hepatology*. 2015;**9**(11):1421-1432
- [28] Francoz C, Belghiti J, Vilgrain V, Sommacale D, Paradis V, Condat B, et al. Splanchnic vein thrombosis in candidates for liver transplantation: Usefulness of screening and anticoagulation. *Gut*. 2005;**54**(5):691-697
- [29] Violi F, Corazza RG, Caldwell SH, Perticone F, Gatta A, Angelico M, et al. Portal vein thrombosis relevance on liver cirrhosis: Italian venous thrombotic events registry. *Internal and Emergency Medicine*. 2016;**11**(8):1059-1066
- [30] Nery FG, Chaffaut C, Condat B, de Raucourt E, Boudaoud L, Rautou PE, et al. Portal vein thrombosis (PVT) in compensated cirrhosis: A prospective cohort study on 898 patients. *Hepatology*. 2013;**58**:271A-272A
- [31] Wosiewicz P, Zorniak M, Hartleb M, Baranski K, Onyszczuk M, Pilch-Kowalczyk J, et al. Portal vein thrombosis in cirrhosis is not associated with intestinal barrier disruption or increased platelet aggregability. *Clinics and Research in Hepatology and Gastroenterology*. 2016;**40**(6):722-729
- [32] Colli A, Gana JC, Yap J, Adams-Webber T, Rashkovan N, Ling SC, et al. Platelet count, spleen length, and platelet count-to-spleen length ratio for the diagnosis of oesophageal varices in people with chronic liver disease or portal vein thrombosis. *Cochrane Database of Systematic Reviews*. 2017;**4**:CD008759
- [33] Khoury T, Ayman A, Cohen J, Daher S, Shmuel C, Mizrahi M. The complex role of anti-coagulation in cirrhosis: An updated review of where we are and where we are going. *Digestion*. 2016;**93**(2):149-159
- [34] Tripodi A, Primignani M, Braham S, Chantarangkul V, Clerici M, Moia M, et al. Coagulation parameters in patients with cirrhosis and portal vein thrombosis treated sequentially with low molecular weight heparin and vitamin K antagonists. *Digestive and Liver Disease*. 2016;**48**(10):1208-1213
- [35] Sharma AM, Zhu D, Henry Z. Portal vein thrombosis: When to treat and how? *Vascular Medicine*. 2016;**21**(1):61-69

- [36] Dell'Era A, Seijo S. Portal vein thrombosis in cirrhotic and non cirrhotic patients: From diagnosis to treatment. *Expert Opinion on Orphan Drugs*. 2016;**4**(9):927-940
- [37] Matsui T, Usui M, Wada H, Iizawa Y, Kato H, Tanemura A, et al. Platelet activation assessed by glycoprotein VI/platelet ratio is associated with portal vein thrombosis after hepatectomy and splenectomy in patients with liver cirrhosis. *Clinical and Applied Thrombosis/Hemostasis*. 2017;**24**(2):254-262. DOI: 10.1177/1076029617725600
- [38] Zhang DL, Hao JY, Yang N. Value of D-dimer and protein S for diagnosis of portal vein thrombosis in patients with liver cirrhosis. *Journal of International Medical Research*. 2013;**41**(3):664-672
- [39] Dai JN, Qi XS, Li HY, Guo XZ. Role of D-dimer in the development of portal vein thrombosis in liver cirrhosis: A meta-analysis. *Saudi Journal of Gastroenterology*. 2015;**21**(3):165-174
- [40] Wu XM, Yao ZP, Zhao L, Zhang Y, Cao MH, Li T, et al. Phosphatidylserine on blood cells and endothelial cells contributes to the hypercoagulable state in cirrhosis. *Liver International*. 2016;**36**(12):1800-1810
- [41] Cui SB, Fu ZM, Feng YM, Xie XY, Ma XW, Liu TT, et al. The disseminated intravascular coagulation score is a novel predictor for portal vein thrombosis in cirrhotic patients with hepatitis B. *Thrombosis Research*. 2018;**161**:7-11
- [42] Singhal A, Karachristos A, Bromberg M, Daly E, Maloo M, Jain AK. Hypercoagulability in end-stage liver disease: Prevalence and its correlation with severity of liver disease and portal vein thrombosis. *Clinical and Applied Thrombosis-Hemostasis*. 2012;**18**(6):594-598
- [43] Girolami A, Cosi E, Ferrari S, Girolami B. Heparin, coumarin, protein C, antithrombin, fibrinolysis and other clotting related resistances: Old and new concepts in blood coagulation. *Journal of Thrombosis and Thrombolysis*. 2018;**45**(1):135-141
- [44] Qi XS, Chen H, Han GH. Effect of antithrombin, protein C and protein S on portal vein thrombosis in liver cirrhosis: A meta-analysis. *American Journal of the Medical Sciences*. 2013;**346**(1):38-44
- [45] Martinelli I, Primignani M, Aghemo A, Reati R, Bucciarelli P, Fabris F, et al. High levels of factor VIII and risk of extra-hepatic portal vein obstruction. *Journal of Hepatology*. 2009;**50**(5):916-922
- [46] Pasta L, Pasta F, D'Amico M. PAI-1 4G-4G, MTHFR 677TT, V Leiden 506Q, and Prothrombin 20210A in splanchnic vein thrombosis: Analysis of individual patient data from three prospective studies. *Journal of Clinical and Experimental Hepatology*. 2016;**6**(1):10-14
- [47] Ventura P, Venturelli G, Marcacci M, Fiorini M, Marchini S, Cuoghi C, et al. Hyperhomocysteinemia and MTHFR C677T polymorphism in patients with portal vein thrombosis complicating liver cirrhosis. *Thrombosis Research*. 2016;**141**:189-195

- [48] Werner KT, Sando S, Carey EJ, Vargas HE, Byrne TJ, Douglas DD, et al. Portal vein thrombosis in patients with end stage liver disease awaiting liver transplantation: Outcome of anticoagulation. *Digestive Diseases and Sciences*. 2013;**58**(6):1776-1780
- [49] Nazzal M, Sun YF, Okoye O, Diggs L, Evans N, Osborn T, et al. Reno-portal shunt for liver transplant, an alternative inflow for recipients with grade III-IV portal vein thrombosis: Tips for a better outcome. *International Journal of Surgery Case Reports*. 2017;**41**:251-254
- [50] Seijo S, Garcia-Criado A, Darnell A, Garcia-Pagan JC. Diagnosis and treatment of portal thrombosis in liver cirrhosis. *Gastroenterologia Y Hepatologia*. 2012;**35**(9):660-666
- [51] Manzano-Robleda MD, Barranco-Fragoso B, Uribe M, Mendez-Sanchez N. Portal vein thrombosis: What is new? *Annals of Hepatology*. 2015;**14**(1):20-27
- [52] Mancuso A. Management of portal vein thrombosis in cirrhosis: An update. *European Journal of Gastroenterology & Hepatology*. 2016;**28**(7):739-743
- [53] Lin RS, Lee FY, Lee SD, Tsai YT, Lin HC, Lu RH, et al. Endotoxemia in patients with chronic liver-diseases—Relationship to severity of liver-diseases, presence of esophageal-varices, and hyperdynamic circulation. *Journal of Hepatology*. 1995;**22**(2):165-172
- [54] Rosenqvist K, Eriksson LG, Rorsman F, Sangfelt P, Nyman R. Endovascular treatment of acute and chronic portal vein thrombosis in patients with cirrhotic and non-cirrhotic liver. *Acta Radiologica*. 2016;**57**(5):572-579
- [55] Buresi M, Hull R, Coffin CS. Venous thromboembolism in cirrhosis: A review of the literature. *Canadian Journal of Gastroenterology*. 2012;**26**(12):905-908
- [56] Llop E, Seijo S. Treatment of non-cirrhotic, non-tumoural portal vein thrombosis. *Gastroenterologia Y Hepatologia*. 2016;**39**(6):403-410
- [57] Ambrosino P, Tarantino L, Di Minno G, Paternoster M, Graziano V, Petitto M, et al. The risk of venous thromboembolism in patients with cirrhosis a systematic review and meta-analysis. *Thrombosis and Haemostasis*. 2017;**117**(1):139-148
- [58] Harding DJ, Perera M, Chen F, Olliff S, Tripathi D. Portal vein thrombosis in cirrhosis: Controversies and latest developments. *World Journal of Gastroenterology*. 2015;**21**(22):6769-6784
- [59] Cagin YF, Atayan Y, Erdogan MA, Dagtekin F, Colak C. Incidence and clinical presentation of portal vein thrombosis in cirrhotic patients. *Hepatobiliary & Pancreatic Diseases International*. 2016;**15**(5):499-503
- [60] Margini C, Berzigotti A. Portal vein thrombosis: The role of imaging in the clinical setting. *Digestive and Liver Disease*. 2017;**49**(2):113-120
- [61] Stine JG, Wang J, Shah PM, Argo CK, Intagliata N, Uflacker A, et al. Decreased portal vein velocity is predictive of the development of portal vein thrombosis: A matched case-control study. *Liver International*. 2018;**38**(1):94-101

- [62] Alam S, Pervez R. Validity of colour doppler sonography for evaluation of portal venous system in hepatocellular carcinoma. *Journal of the Pakistan Medical Association*. 2013;**63**(3):365-368
- [63] Danila M, Sporea I, Popescu A, Sirli R. Portal vein thrombosis in liver cirrhosis—The added value of contrast enhanced ultrasonography. *Medical Ultrasonography*. 2016;**18**(2):218-223
- [64] Tarantino L, Ambrosino P, Di Minno MND. Contrast-enhanced ultrasound in differentiating malignant from benign portal vein thrombosis in hepatocellular carcinoma. *World Journal of Gastroenterology*. 2015;**21**(32):9457-9460
- [65] Berzigotti A, Garcia-Criado A, Darnell A, Garcia-Pagan JC. Imaging in clinical decision-making for portal vein thrombosis. *Nature Reviews Gastroenterology & Hepatology*. 2014;**11**(5):308-316
- [66] Ahn JH, Yu JS, Cho ES, Chung JJ, Kim JH, Kim KW. Diffusion-weighted MRI of malignant versus benign portal vein thrombosis. *Korean Journal of Radiology*. 2016;**17**(4):533-540
- [67] Qi XS, Han GH, He CY, Yin ZX, Guo WG, Niu J, et al. CT features of non-malignant portal vein thrombosis: A pictorial review. *Clinics and Research in Hepatology and Gastroenterology*. 2012;**36**(6):561-568
- [68] Qi XS, Su CP, Ren WR, Yang M, Jia J, Dai JN, et al. Association between portal vein thrombosis and risk of bleeding in liver cirrhosis: A systematic review of the literature. *Clinics and Research in Hepatology and Gastroenterology*. 2015;**39**(6):683-691
- [69] Zhang DL, Hao JY. Evaluation of D-dimer and protein S in cirrhotic patients with portal vein thrombosis. *Journal of Gastroenterology and Hepatology*. 2013;**28**:909-910
- [70] Dai JN, Qi XS, Peng Y, Hou Y, Chen J, Li HY, et al. Association between D-dimer level and portal venous system thrombosis in liver cirrhosis: A retrospective observational study. *International Journal of Clinical and Experimental Medicine*. 2015;**8**(9):15296-15301
- [71] Yerdel MA, Gunson B, Mirza D, Karayalcin K, Olliff S, Buckels J, et al. Portal vein thrombosis in adults undergoing liver transplantation—Risk factors, screening, management, and outcome. *Transplantation*. 2000;**69**(9):1873-1881
- [72] Giannini EG, Stravitz RT, Caldwell SH. Portal vein thrombosis and chronic liver disease progression: The closer you look the more you see. *Hepatology*. 2016;**63**(1):342-343
- [73] Wang Z, Jiang MS, Zhang HL, Weng NN, Luo XF, Li X, et al. Is post-TIPS anticoagulation therapy necessary in patients with cirrhosis and portal vein thrombosis? A randomized controlled trial. *Radiology*. 2016;**279**(3):943-951
- [74] Abdel-Razik A, Mousa N, Elhelaly R, Tawfik A. De-novo portal vein thrombosis in liver cirrhosis: Risk factors and correlation with the model for end-stage liver disease scoring system. *European Journal of Gastroenterology & Hepatology*. 2015;**27**(5):585-592

- [75] Loffredo L, Pastori D, Farcomeni A, Violi F. Effects of anticoagulants in patients with cirrhosis and portal vein thrombosis: A systematic review and meta-analysis. *Gastroenterology*. 2017;**153**(2):480
- [76] Naeshiro N, Aikata H, Hyogo H, Kan H, Fujino H, Kobayashi T, et al. Efficacy and safety of the anticoagulant drug, danaparoid sodium, in the treatment of portal vein thrombosis in patients with liver cirrhosis. *Hepatology Research*. 2015;**45**(6):656-662
- [77] Qi XS, He CY, Guo WG, Yin ZX, Wang JH, Wang ZY, et al. Transjugular intrahepatic portosystemic shunt for portal vein thrombosis with variceal bleeding in liver cirrhosis: Outcomes and predictors in a prospective cohort study. *Liver International*. 2016;**36**(5):667-676
- [78] De Gottardi A, Trebicka J, Klinger C, Plessier A, Seijo S, Terziroli B, et al. Antithrombotic treatment with direct-acting oral anticoagulants in patients with splanchnic vein thrombosis and cirrhosis. *Liver International*. 2017;**37**(5):694-699
- [79] Jairath V, Burroughs AK. Anticoagulation in patients with liver cirrhosis: Complication or therapeutic opportunity? *Gut*. 2013;**62**(4):479-482
- [80] Leonardi F, De Maria N, Villa E. Anticoagulation in cirrhosis: A new paradigm? *Clinical and Molecular Hepatology*. 2017;**23**(1):13-21
- [81] Dhar A, Mullish BH, Thursz MR. Anticoagulation in chronic liver disease. *Journal of Hepatology*. 2017;**66**(6):1313-1326
- [82] Qi XS, De Stefano V, Li HY, Dai J, Guo XX, Fan DM. Anticoagulation for the treatment of portal vein thrombosis in liver cirrhosis: A systematic review and meta-analysis of observational studies. *European Journal of Internal Medicine*. 2015;**26**(1):23-29
- [83] Lenz K, Dieplinger B, Buder R, Piringer P, Rauch M, Voglmayr M. Successful treatment of partial portal vein thrombosis (PVT) with low dose rivaroxaban. *Zeitschrift Fur Gastroenterologie*. 2014;**52**(10):1175-1177
- [84] Yang H, Kim SR, Song MJ. Recurrent acute portal vein thrombosis in liver cirrhosis treated by rivaroxaban. *Clinical and Molecular Hepatology*. 2016;**22**(4):499-502
- [85] Qi XS, Wang J, Chen H, Han GH, Fan DM. Nonmalignant partial portal vein thrombosis in liver cirrhosis: To treat or not to treat? *Radiology*. 2013;**266**(3):994-995
- [86] Jiang TT, Luo XP, Sun JM, Gao J. Clinical outcomes of transcatheter selective superior mesenteric artery urokinase infusion therapy vs transjugular intrahepatic portosystemic shunt in patients with cirrhosis and acute portal vein thrombosis. *World Journal of Gastroenterology*. 2017;**23**(41):7470-7477
- [87] Zhao MF, Yue ZD, Zhao HW, Wang L, Fan ZH, He FL, et al. Techniques of TIPS in the treatment of liver cirrhosis combined with incompletely occlusive main portal vein thrombosis. *Scientific Reports*. 2016;**6**:33069
- [88] Wang L, He FL, Yue ZD, Zhao HW, Fan ZH, Zhao MF, et al. Techniques and long-term effects of transjugular intrahepatic portosystemic shunt on liver cirrhosis-related thrombotic total occlusion of main portal vein. *Scientific Reports*. 2017;**7**(1):10868

- [89] Fagiuoli S, Bruno R, Venon WD, Schepis F, Vizzutti F, Toniutto P, et al. Consensus conference on TIPS management: Techniques, indications, contraindications. *Digestive and Liver Disease*. 2017;**49**(2):121-137
- [90] Kawanaka H, Akahoshi T, Itoh S, Iguchi T, Harimoto N, Uchiyama H, et al. Optimizing risk stratification in portal vein thrombosis after splenectomy and its primary prophylaxis with antithrombin III concentrates and danaparoid sodium in liver cirrhosis with portal hypertension. *Journal of the American College of Surgeons*. 2014;**219**(5):865-874
- [91] Villa E, Camma C, Marietta M, Luongo M, Critelli R, Colopi S, et al. Enoxaparin prevents portal vein thrombosis and liver decompensation in patients with advanced cirrhosis. *Gastroenterology*. 2012;**143**(5):1253
- [92] Fortea JI, Zipprich A, Fernandez-Mena C, Puerto M, Bosoi CR, Almagro J, et al. Enoxaparin does not ameliorate liver fibrosis or portal hypertension in rats with advanced cirrhosis. *Liver International*. 2018;**38**(1):102-112

