

# We are IntechOpen, the world's leading publisher of Open Access books Built by scientists, for scientists

6,900

Open access books available

186,000

International authors and editors

200M

Downloads

Our authors are among the

154

Countries delivered to

TOP 1%

most cited scientists

12.2%

Contributors from top 500 universities



WEB OF SCIENCE™

Selection of our books indexed in the Book Citation Index  
in Web of Science™ Core Collection (BKCI)

Interested in publishing with us?  
Contact [book.department@intechopen.com](mailto:book.department@intechopen.com)

Numbers displayed above are based on latest data collected.  
For more information visit [www.intechopen.com](http://www.intechopen.com)



---

# Endoscopic Ultrasound in Pancreatic Cancer

---

Cameron John McLaren, Daphne Day,  
Daniel Croagh, Andrew Strickland and Eva Segelov

Additional information is available at the end of the chapter

<http://dx.doi.org/10.5772/intechopen.75211>

---

## Abstract

Endoscopic ultrasound (EUS) has been developed over the course of the last 50 years. This technique has been shown to improve diagnosis, provide more accurate local information with regards to staging and enhance prediction of surgical resectability. Further to this, minimally-invasive local techniques have been developed, and continue to be developed, to provide both active and palliative management within the treatment schema for pancreatic cancer (PC).

**Keywords:** diagnosis, staging, therapeutics, gastroenterology

---

## 1. Introduction

Endoscopic ultrasonography (EUS) refers to the use of an ultrasound probe on a flexible endoscope to provide ultrasound images from within the GI tract and has applications for use in transoesophageal echocardiography (TOE), endobronchial ultrasound (EBUS), transrectal ultrasound-guided (TRUS) prostate biopsies, and evaluation of suspicious lesions in the upper GI tract, including the stomach and pancreas, as well as local lymph nodes. This chapter focuses on the utility of EUS in the assessment of pancreatic lesions. EUS is performed by experienced endoscopists and provides information regarding the sonographic characteristics of lesions of interest, as well as provides opportunity, through instrument channels in the endoscope, to take biopsies and perform minimally-invasive procedures for therapeutic or palliative benefit.

EUS has a vital role in the diagnosis, staging, and provision of local therapeutics in the management of PC. Emerging applications and future directions of EUS in PC are also discussed.

---

## 2. History

Endoscopy in its modern form began in 1806 with the invention of the Lichleiter, or 'light conductor', by Philipp Bozzini. This device consisted of two parts: the light container and viewing device, and the mechanical part (various speculae) that facilitated access to the subject's body. The fibre-optic endoscope was originally invented by the then medical student, Heinrich Lamm in 1930 [1]. Poor image quality limited the utility of this endoscope until scientific advances made by Harold Hopkins and Narinder Singh Kapany in 1954 [2] were adapted by Dr. Basil Hirschowitz to create the flexible fiberscope [3].

Ultrasound as an investigational modality was also being developed at this time, with Neurologist Dr. Karl Dussik publishing the first use of diagnostic ultrasound in 1941 [4]. The addition of radial ultrasound technology to endoscopy is credited to Dr. DiMagno in 1980, who felt that by internalising the ultrasound probe, problems with interfering gas patterns and nearby organs could be avoided, and the accuracy of ultrasound would be improved [4]. Although the intent at the time was to use this technique to image the pancreas, the coupling of endoscopy and ultrasonography also led to the development of transoesophageal echocardiography, endoscopic bronchial ultrasound, and trans-rectal ultrasound.

In 1991, Dr. Peter Vilmann and Søren Hancke utilised the curved linear array endoscope to facilitate minimally-invasive diagnostic and therapeutic interventions during endoscopic ultrasound [5]. The use of the linear array ultrasound probe enabled the use of instrument channels. These channels have facilitated the current utility of endoscopic ultrasound to perform fine needle aspirations (EUS-FNA) for diagnostic purposes, and for minimally-invasive therapeutic alternatives to radiologically-guided, or surgical drainage of collections, for biliary drainage (EUS-BD), and to perform celiac plexus neurolysis (EUS-CPN) [6, 7].

## 3. Diagnosis

Early PC is often detected incidentally, with identification of a non-specific pancreatic lesion. The gold-standard treatment of early PC is with pancreaticoduodenectomy ('Whipple's' procedure); a major surgical undertaking with significant morbidity. Ensuring an accurate diagnosis of malignancy is crucial to preventing unnecessary surgeries and the complications thereof.

Diagnosing early PC noninvasively has been historically a difficult undertaking. Clinical suspicion of PC is often based on either non-specific clinical features (asthenia, weight loss, abdominal pain, anorexia, etc.), or features that are associated with advanced disease (jaundice, hepatomegaly, abdominal distension, signs of pancreatic insufficiency, etc.), but specific to pancreatic malignancy. Contributory evidence of malignancy has historically involved clinical history, including presence of risk factors for PC (discussed previously), serum level of cancer antigen 19-9 (CA19-9), and radiographical appearance on transabdominal ultrasound (US), computed tomography (CT), or magnetic resonance imaging (MRI). The advent of EUS and EUS-FNA has allowed for more accurate radiographical assessment of pancreatic lesions, as well as direct sampling to allow histological assessment of the lesion.

### 3.1. Tumour markers

CA19-9 is a useful biomarker for monitoring response to treatment, or disease progression or recurrence in patients with an established histological diagnosis of PC [8]. However, the specificity of CA19-9 (68–92%) and positive-predictive value (0.9% for serum concentrations >37 units/mL) negates the utility of CA19-9 in the diagnosis of PC [9].

### 3.2. Imaging

#### 3.2.1. Transabdominal ultrasound (US)

US can be used to assess pancreatic masses  $\geq 3$  cm in size with up to 95% sensitivity [10]. Specificity of US is reported between 94 and 98%, however sensitivity decreases substantially when assessing smaller lesions, and is highly operator-dependent [11]. In order to improve detection of PCs at a size where curative resection is achievable, more sensitive investigations are necessary.

#### 3.2.2. Computed tomography (CT)

Abdominal CT scan (multidetector CT, MDCT) has a sensitivity nearing 100% for pancreatic lesions >2 cm, which reduces to 77% for tumours  $\leq 2$  cm [12]. Its utility in assessing local extension is demonstrated by an accuracy for predicting surgical resectability of 80–90% [13], however is limited by its ability to detect liver metastases and early lymph node metastases [11].

### 3.3. Percutaneous biopsy

Percutaneous, image-guided pancreatic mass biopsies using ultrasound or CT, are safe and effective at obtaining the diagnosis of PC. Due to the direct sampling nature of the procedure, specificity is close to 100%, with varying sensitivity between 80 and 90% [14]. Theoretic concerns with regards to percutaneous biopsies include the risk of tumour seeding along the biopsy tract, or the increased risk of peritoneal carcinomatosis in patients having undergone percutaneous biopsy, and is contraindicated in potentially-resectable cases [15].

### 3.4. EUS-guided biopsy

EUS-guided fine-needle aspiration (EUS-FNA) uses the instrument channel of the endoscopy to pass a biopsy needle in front of the linear-array ultrasound probe to obtain tissue from lesions under direct ultrasound visualisation. The angle of the needle can be modified to target more cellular-appearing aspects of the target lesion. Two to 10 passes are made into the lesion with the needle and the use of an on-site cytopathologist, or specialist nurse trained in assessment of samples for cellularity is recommended. EUS-FNA allows for tissue acquisition for diagnostic purposes with a low rate of morbidity and mortality, and allows for early genetic and molecular analysis for research and therapeutic decisions [16].

Eloubeidi et al. conducted a review of 100 patients who underwent EUS-FNA, and found 95% sensitivity, 95% specificity, 100% positive predictive value, and 85.2% negative predictive value [17]. These results have been replicated and shown to hold in multiple studies, including

a meta-analysis and systematic review by Puli et al. , who identified 41 studies of EUS-FNA and found a pooled sensitivity of determining the correct nature of pancreatic masses of 86.8% (95% CI 85.5–87.9), a specificity of 95.8% (95% CI 94.6–96.7), a positive likelihood ratio of 15.2 (95% CI 8.5–27.3), and a negative likelihood ratio of 0.17 (95% CI 0.13–0.21) [18].

Chen et al. conducted a systematic review to determine the accuracy of EUS-FNA. They identified 15 studies, totalling 1860 patients and found 92% sensitivity (95% CI 91–93%,  $p < 0.001$ ,  $I^2 = 69.6\%$ ), 96% specificity (95% CI 93–98%,  $p = 0.006$ ,  $I^2 = 54.9\%$ ) [19]. From a practical point of view, the additional benefit of EUS in the assessment of pancreatic lesions is that radiological characterisation of the lesion, local extension and nodal involvement, and histological sampling can all occur in the one procedure, as opposed to US assessment followed by a separate imaging-guided biopsy.

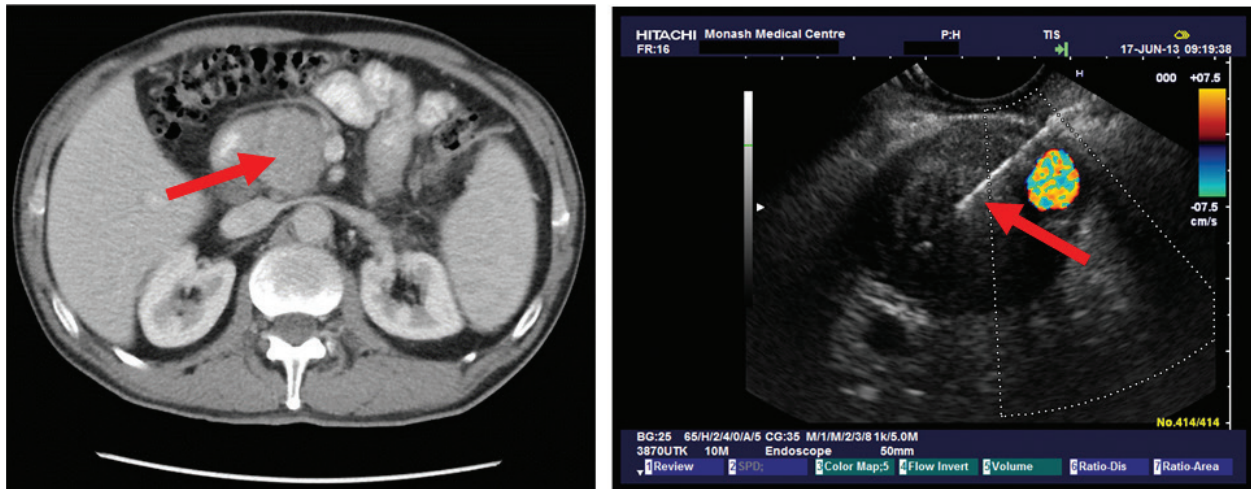
However, a more recent Cochrane review highlighted the lack of quality studies in the area of comparative diagnostics with regards to PC; conclusions were unable to be drawn from the data as only three articles were identified that met the pre-defined quality parameters [20]. There is a paucity of good-quality head-to-head prospective, randomised controlled trials that compare the investigative modalities and heterogeneity in the inclusion criteria of many of the current studies within the literature. Coupled with variability in access and quality of EUS-FNA, interpreting the comparative efficacy and developing a standardised pathway for the investigation of pancreatic lesions remains open to debate.

Horwhat et al. reported an interesting randomised crossover trial comparing EUS-FNA with percutaneous biopsy. Patients with non-diagnostic first-line investigations were allowed to cross over to be investigated with the alternate modality. Fewer patients who received upfront EUS-FNA went on to have percutaneous biopsy (8/36 (22%) versus 16/36 (44%)). The comparative sensitivity of percutaneous biopsy and EUS-FNA was 62% (95% CI 0.41–0.80) and 84% (95% CI 0.64–0.95), respectively ( $p = 0.1164$ ) [21]. In such a lethal disease, in a population where clinical deterioration often happens suddenly, accuracy in diagnosis is vital to facilitating early treatment. This study lends support to EUS-FNA over percutaneous biopsy for obtaining an early and accurate diagnosis.

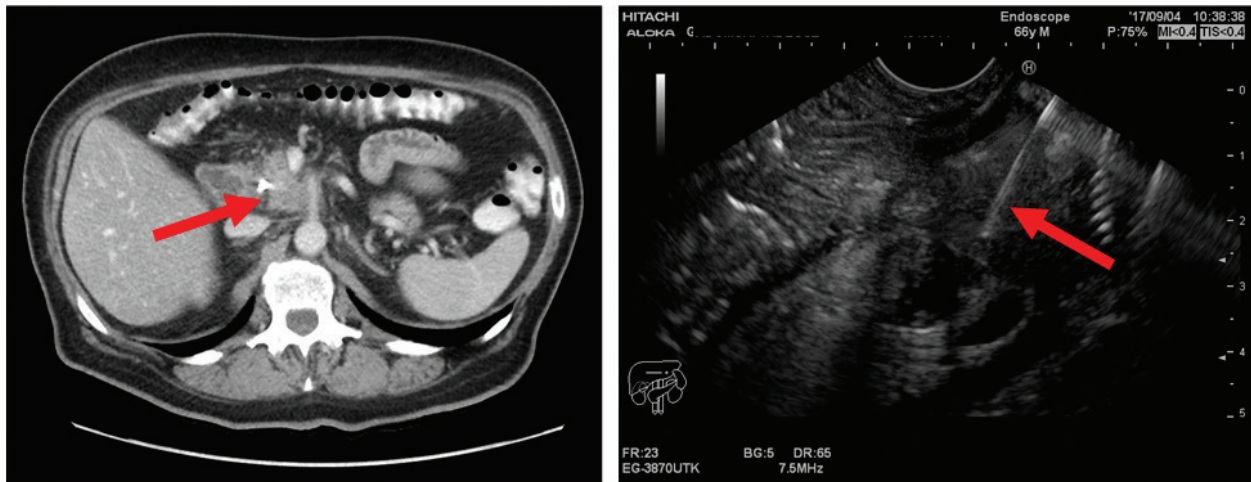
Okasha et al. conducted a multicentre, prospective, controlled trial in a non-randomised population of EUS-FNA versus ultrasound-guided percutaneous biopsy (US-FNA) in the investigation of pancreatic head tumours. The investigative modality was dictated by accessibility and feasibility. One hundred and ninety seven patients underwent investigation and comparable accuracy (88.9% for EUS-FNA; 87.2% for US-FNA), sensitivity (84% EUS-FNA; 85.5% US-FNA), specificity (100% EUS-FNA; 90.4% US-FNA), positive predictive value (100% EUS-FNA; 94.7% US-FNA), and negative predictive value (73.3% EUS-FNA; 76% US-FNA) were found. Complications occurred in 1/72 patients (1.38%) in the EUS-FNA group (abdominal pain secondary to pancreatitis), compared with 7/125 (5.6%) in the US-FNA group (three cases of severe post-procedure epigastric pain, three cases of peritoneal seeding, and one case of pancreatic abscess requiring surgical debridement and drainage) [22].

It is important to recognise that peritoneal seeding after EUS-FNA has been reported [23], and is therefore not a delineating factor between choosing between percutaneous and EUS-guided biopsy. Of the 15 cases of needle tract seeding reported in this review of case studies of needle-tract seeding after EUS biopsy, 11 occurred during evaluation of pancreatic adenocarcinoma,





**Figure 1.** CT and corresponding EUS image of a pancreatic mass that proved to be autoimmune pancreatitis.



**Figure 2.** CT and corresponding EUS image of a pancreatic mass that proved to be pancreatic cancer.

with 1 case each of intraductal papillary mucinous neoplasia (IPMN), gastric cancer, malignant melanoma, and squamous cell cancer of unknown origin. All cases of needle tract seeding with relation to investigation of PC occurred with a transgastric approach and did not appear to be related to needle size (mostly 22G) or number of passes (range 1–5).

EUS-FNA of solid masses is generally a safe procedure, with a reported overall complication rate of 0.5–2.54% [24, 25]. Complications include infection, bleeding, and acute pancreatitis. The mortality rate of the procedure has been quoted at 0.04% [25]. Several studies have not found significant benefit in diagnostic yield or complication rate relative to needle size used [26–28]. The use of core (trucut) biopsy (EUS-TCB) instead of, or in combination with FNA has not been investigated to an extent to definitively support its use [29]. EUS-TCB has the potential to provide information about tissue architecture, as well as allow for retrieval of a larger volume of tissue, which in an era of expanding availability of histological and molecular analyses, may become a more desirable methodology, however more information regarding the comparative efficacy and safety is required.

**Figures 1** and **2** below show the abdominal CT scan and EUS images of two patients referred to our institution for investigation of painless jaundice and a pancreatic mass. The red arrows in the CT images indicate the pancreatic lesion; the red arrows in the ultrasound image indicated the EUS-FNA needle within the pancreatic mass. In the first case (**Figure 1**), the CT scan and US findings were suspicious for autoimmune pancreatitis. The patient was commenced on high-dose steroids and the lesion resolved and liver function tests returned to normal. In the second case (**Figure 2**) the EUS FNA confirmed the clinical and radiological suspicion of pancreatic cancer.

#### 4. Staging

Surgery is currently the only possibility for cure in PC. 15–20% of PC cases at time of diagnosis are eligible for resection. For those who undergo a successful surgical resection, the morbidity of the procedure is significant, and the 5-year survival rate (5YSR) remains low at 10–25% [30]. Surgery is indicated in the treatment of localised, or minimally-locally-advanced (Stages I-II) PC. Better cure rates are found with node-negative disease (5YSR ~30%); approximately 10% of patients who undergo complete (R0) resection with limited nodal disease progress to long-term survival [31].

The role of preoperative staging is to accurately assess the above features to guide the surgeon as to the likelihood of obtaining an R0 resection. This can be thought of in terms of assessing the extent of local invasion, as well as the presence of distal disease. Standard abdominal CT scanning is the investigation of-choice for assessing distant disease, but has a low sensitivity for assessing local invasion and peritoneal spread. In one study, 61% of cases deemed resectable by CT assessment were found to be unresectable at laparotomy [32]. This modality should not be used alone in assessing appropriateness for surgical intervention.

Standard abdominal CT scans are performed around 60–120 s after injection of intravenous contrast. The optimal timing for imaging of contrast within the pancreas is around 35 s. By using a pancreatic protocol CT, where images are captured at this time point, and then during the washout phase, both local configuration of pancreatic lesions and evidence of local hepatic metastases are elucidated. Pancreatic-protocol CTs are considered the standard imaging investigation for local staging of pancreatic cancer.

The accurate appraisal of the extent of local spread is crucial not only for identifying unresectable disease, but for avoiding false hope and subjecting a patient to an ‘open-and-close’ laparotomy for no therapeutic benefit.

Local surgical expertise often determines the definition of resectable disease on a pragmatic level, however the National Comprehensive Cancer Network (NCCN) guidelines [33] refer to the following factors when determining resectability:

- Relation to the superior mesenteric artery (SMA), celiac axis, superior mesenteric vein (SMV), and inferior vena cava (IVC)
- Unreconstructable SMV or portal vein

- Aortic involvement
- Distant metastases
- Presence of disease in lymph nodes beyond the field of resection

EUS provides high-resolution images of the primary mass, its relationship to local structures, and the appearance of regional lymph nodes. Conversely to CT, although EUS can detect some liver metastases, it provides insufficient information on distant disease. There have been few studies directly comparing the two modalities, however the combination of both modalities for their relative strengths seems to be the way forward. One study has shown an equivalent PPV of surgical resectability with regards to T-staging of either modality (63%), with a significant increase to 86% when used in combination [34]. While most studies have shown equivalence of EUS and CT with regards to N-staging, EUS has shown greater accuracy in assessing mesenteric vessel involvement, which often has a significant impact on determining surgical resectability [35].

EUS has previously been thought to be superior to CT scanning for the detection and assessment of smaller pancreatic lesions, however comment has been made that the technological advances in radiology continually improving the resolution of CT images that contemporary CT scans may show more accurate results. EUS has however, been shown to lead to less over-staging than multidetector CT (MDCT) and MRI [35]. This is crucial so that resectable cases are not appreciated as unresectable.

## 5. Screening

The use of EUS in screening patients at increased risk (high-risk individuals [HRIs]) has been suggested due to the lethality of the disease, and the often late-onset of clinical features leading to a very low rate of patients diagnosed at a sufficiently-early stage to undergo curative-intent treatment (15–20%) [30]. In line with the Wilson and Jungner criteria for screening, PC is an important health problem with an acceptable treatment, with a 'latent' phase wherein curative treatment can be undertaken. EUS is a suitable test for early-stage disease that would be likely acceptable to an at-risk population. The questions remain as to whether EUS is yet an accessible test from a resource-availability perspective, and accurately defining HRIs to whom screening could be offered. Subsequent to this, EUS screening of HRIs is yet to be proven to be efficacious, let alone cost-effective to offer as a screening tool.

Identifying HRIs should be based on risk factors for PC. Risk factors such as family history, presence of germline mutations (BRCA1, ATM, PALB2, CDKN2A, and MLH1), Peutz-Jeghers syndrome (PJS), cystic fibrosis, race, ABO blood group, chronic pancreatitis, diabetes mellitus, smoking history, and obesity, are all factors that could be combined to develop a pancreatic risk score. Wang et al. have developed PancPRO, a predictive model for PC using Bayesian modelling to provide risk stratification for developing PC based on family history. It was validated prospectively using the National Familial Pancreas Tumour Registry with an observed to predicted PC ratio of 0.83 (95% CI 0.52–1.20) [36]. The combination of risk stratification algorithms



that may include presence of germline mutations may prove to be a more accurate way of identifying HRIs – more research is needed in this area to more-accurately define an at-risk population in which a screening population can be shown to be efficacious and cost effective.

The use of EUS in HRIs has been explored in a review by Bhutani et al. [37]. They identified 10 studies utilising screening EUS in families with identified familial PC, PJS, familial atypical multiple mole melanoma syndrome, and several other mutations incurring increased risk. A total of 512 screening EUSs were performed across the 10 studies. The rate of abnormal EUS results (pancreatic duct dilatation or ectasia, observable solid or cystic masses, or parenchymal changes) in this study population was 212/512 (41%). Clinical outcome measures (rate of curative resection for detected cases, overall survival (OS), etc.) were not reported overall. Several studies have demonstrated the ability of EUS in HRI to identify pancreatic dysplasia and IPMN, with no reported false-positives when these cases with abnormal EUS progressed to surgical resection [38, 39].

The largest of these studies was performed in 216 individuals with one of the following risk factors:

- Relatives with known familial PC and two affected first-degree relatives (n = 195)
- Individuals with PJS (n = 2), or
- Known familial breast-ovarian cancer patients with at least one first-degree relative affected by PC (n = 19).

Screening was performed on all of these cases with MRI, CT, and EUS. Ninety-two (42%) of participants had an abnormal EUS (at least one pancreatic mass [cystic n = 84, solid n = 3], or pancreatic duct dilatation [n = 5]). Eighty-two of the abnormal EUS cases were IPMNs, and three were neuroendocrine tumours. Five participants went on to have surgical resection, returning three cases of pancreatic dysplasia in <3 cm IPMNs, multiple intraepithelial neoplasms. No cases were identified by CT or MRI that were undetected by EUS. This study lends support to the potential for pancreatic screening in HRIs and supports the choice of EUS as the screening modality over CT and EUS. Further investigation to properly define the characteristics of the at-risk sub-population is needed. The optimal timing and frequency of screening also requires further exploration. The potential merits of screening will need to be balanced against the resource-cost, access, and scalability considerations before routine EUS screening can be supported.

## 6. Therapeutics

### 6.1. Celiac plexus neurolysis

The first reported use of EUS-guided celiac plexus neurolysis (EUS-CPN) was published by Wiersema in 1996. EUS-CPN was performed on 30 patients with celiac plexus neuropathy; 25 with PC, and 5 with other intraabdominal malignancies. This single-arm study demonstrated efficacy in a mild to moderate reduction in pain scores at 2, 4, 8, and 12 weeks post-procedure (1–10 pain scale 6.1  $\pm$  3.1 versus 4.8  $\pm$  2.0, p = 0.004) [40]. Complications were minor and transient (diarrhoea in four patients).

Although no randomised clinical trial has been performed to compare the relative efficacy and safety of CPN via percutaneous versus endoscopic approach, a Cochrane Review of 102 studies concluded that CPN by any modality was associated with reduced pain at 4 weeks (mean difference in visual analogue scale (VAS)  $-0.42$ , 95% CI  $-0.70$  to  $-0.13$ ,  $p = 0.004$ ). This less than one point improvement of VAS score begs the question of whether this is clinically-significant; coupling this data with quality of life would perhaps be more informative. This improvement was maintained at 8 weeks overall, the review noted significant heterogeneity of results at 8 weeks at this time point. Collective data on opioid consumption in these studies also showed a significant benefit in the CPN group [41]. A retrospective cohort study by Kambhampati et al. compared outcomes of patients who underwent either percutaneous or EUS-CPN between 2008 and 2015 at Johns Hopkins University School of Medicine. This study suggested a non-statistically significant reduction in procedural complications for EUS-CPN (7% EUS vs. 11% percutaneous,  $p = 0.51$ ), as well as a non-significant higher immediate response rate in percutaneous CPN (87% versus 72% in EUS-CPN,  $p = 0.08$ ). Response was defined as a decrease in numeric pain score by  $\geq 3$  points. There was no significant difference in quality of life measures, opiate usage, or pain response at 1 month between groups [42].

An interesting study of note by Wyse et al. looked at early EUS-CPN at the time of diagnosis by EUS of unresectable disease [43]. Patients with pain and suspected PC underwent a diagnostic and staging EUS. If diagnosis of unresectable adenocarcinoma was made, patients were randomised to either early EUS-CPN or conventional pain management. The early EUS-CPN group was found to have non-significant improvements in pain response (measured by the Likert scale) and morphine consumption at 3 months compared to standard analgesia (pain response  $-28.9$  [95% CI  $-67.0$  to  $2.8$ ],  $p = 0.09$ , morphine consumption  $-49.5$  [95% CI  $-127.5$  to  $7.0$ ],  $p = 0.10$ ). Although not statistically significant, these data do suggest that early EUS-CPN at the time of diagnosis could be considered to assist with the often difficult-to-manage analgesic requirements in late-stage PC.

## 6.2. Biliary duct drainage

EUS-guided biliary duct drainage (EUS-BD) can be performed via several methods, but all involve the direct visualisation via EUS of the pre-obstructed biliary tract and puncture of the pre-obstructive system and confirmation with cholangiography. A guidewire is then inserted and the tract is dilated to create a fistula. These techniques rely on accurate EUS images to target the pancreatic duct, common bile duct, or intrahepatic bile ducts (IHBDs) to create a pancreaticogastrostomy, choledocoduodenostomy, or hepaticogastrostomy, respectively.

EUS-BD can be performed using several techniques:

- Transluminally, where the bile duct or common bile duct is accessed via the stomach or duodenum, respectively.
- Rendezvous, where the ampulla is accessed and the biliary duct is targeted with EUS to fistulise a guidewire to facilitate secondary endoscopic retrograde cholangiopancreatography (ERCP) and stenting over the guidewire
- Antegrade, where an IHBD is accessed from the upper intestine to bypass the anatomic biliary system altogether.

Method	Success rate, % (n)	Complication Rate
EUS-CDS	94.0 (282/300)	18.9 (53/280)
EUS-HGS	86.7 (137/158)	26.8 (41/153)
EUS-RV	80.5 (215/267)	11.1 (24/217)
Overall	87.4 (634/725)	18.2 (118/650)

EUS-CDS, EUS-choledochoduodenostomy; EUS-HGS, EUS-hepaticogastrostomy; EUS-RV, EUS-rendezvous.

**Table 1.** Summary of EUS-BD approaches reported in Iwashita et al. [44].

These techniques allow for bypass drainage of bile around the level of obstruction and have been shown to be efficacious with a low rate of serious complications. Iwashita et al. [44] conducted a literature review of EUS-BD and stenting. Results are summarised in **Table 1**.

Complications of EUS-BD were generally limited to peritonitis, pneumoperitoneum, abdominal pain, and perforation. No deaths or need for surgery were reported to have been required for complications arising from EUS-CDS or EUS-HGS. Two deaths were recorded in the 217 cases of EUS-RV; one of these was due to cirrhosis, the other was related to sepsis [44]. No comment on prophylactic antibiotic use was made in this review.

A more recent systematic review by Wang et al. of 1192 patients across 42 studies showed similar success rates, with an overall complication rate of 23.3%. The complications encountered were bleeding (4.0%), bile leakage (4.0%), pneumoperitoneum (3.0%), stent migration (2.7%), cholangitis (2.4%), abdominal pain (1.5%), and peritonitis (1.3%), with no differences in complication rate between transduodenal and transgastric approaches [45]. Grade of complications was not reported. It is important to recognise that EUS-BD has historically been utilised in the setting of failed ERCP for biliary drainage and that this may introduce some selection bias towards more difficult cases, or those who have had recent ERCP, which may be attributable to some of the complications documented in the follow-up period of the studies included in these reviews. A randomised controlled multicentre trial (BILPAL) is currently recruiting to compare EUS-BD with standard ERCP in the first-line setting for palliation of malignant obstructive jaundice [46].

## 7. The future

### 7.1. Local administration of anticancer therapies

The use of EUS as a delivery system for anticancer therapies is an attractive prospect. The poor vascularity and desmoplastic stroma displayed within a malignant pancreatic tumour is likely a significant factor contributing to the relatively poor efficacy of haematogenously-administered systemic therapies. EUS may circumvent this limitation by offering locally administered anticancer therapies directly into the tumour.

#### 7.1.1. Intratumoural injections

EUS-fine needle injection (EUS-FNI) has the potential to improve the delivery of active cytotoxic agents such as chemotherapy or viral therapy to the target cancer more effectively, whilst

reducing systemic exposure and toxicity. Encouraging early phase data of several investigative approaches are emerging, although larger and randomised studies are lacking.

The use of EUS-FNI of ethanol was investigated in 19 patients with unresectable PC by Yang et al. (2009). At follow-up (between 2 and 7 months), a > 70% reduction in size of pancreatic lesions was identified in 12/19 patients (63%), and a 50–70% reduction in size was found in a further 6/19 patients (32%). Seven patients survived beyond 24 months. No major complications were encountered [47].

Levy et al. (2017) performed a prospective study on first-line EUS-FNI with gemcitabine in 36 patients with stage II-IV PCs. Conventional therapies were allowed in all cases at the discretion of the treating Oncologist, but not described in the results. 95 mg (2.5 mL of 38 mg/mL) of gemcitabine was administered via EUS-FNI. OS at 6- and 12-months was 78 and 44%, respectively. Four (20%) patients with stage III disease who underwent EUS-FNI were down-staged and were able to undergo R0 resection [48].

Immunogenic approaches have included EUS-FNI of allogenic mixed lymphocytic culture, immature dendritic cells, tumour necrosis factor alpha (TNF- $\alpha$ ), and gene-deleted replication-selective viruses such as ONYX-015. These agents are still under investigation and have been shown to be feasible and safe, however early clinical data has not been overwhelmingly positive [49].

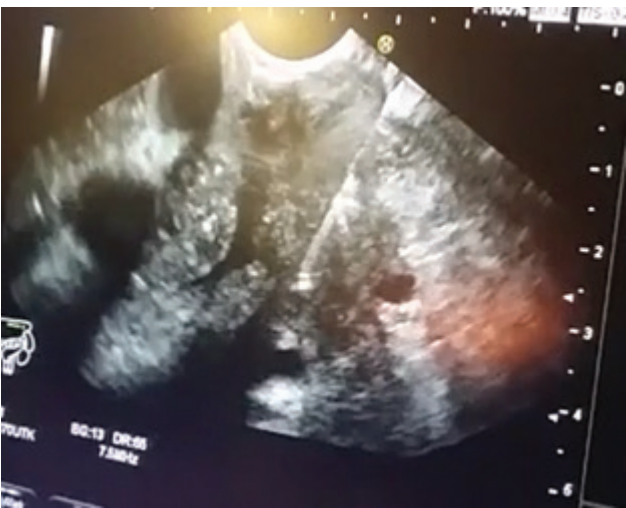### 7.1.2. Brachytherapy

Brachytherapy induces cell death through the delivery of short-wave beta radiation-emitting particles being placed within the tumour. The local delivery allows for a larger total dose to be delivered to the tumour when compared to external beam radiotherapy (EBRT), with relative sparing of surrounding tissue. Endoscopic brachytherapy (EUS-BT) is being investigated in the management of PC, particularly in locally-advanced unresectable PC, currently treated with either combined chemoradiotherapy with EBRT or palliative chemotherapy alone. Although, the efficacy of EUS-BT has not yet been established, trials in this area including at our institution are ongoing. **Figure 3** below shows the placement of brachytherapy seeds under direction visualisation into an unresectable pancreatic cancer through EUS. **Figure 4** shows a Bremm study taken 1 week after implantation of brachytherapy seeds showing the radiation field created by the implanted seed. **Figures 5** and **6** taken from the same patient shows the radiological response achieved by this technique in this case. More investigation is required to optimise patient selection and delivery techniques.

Sun et al. utilised EUS-BT in 15 patients with stage III (n = 8), and stage IV (n = 7) pancreatic adenocarcinoma [50]. 27% of cases experienced a partial response, with a mean duration of response of 4.5 months. Rate of disease control was notable at 80% (partial 27%, mild 20%, stable 33%), and 30% of patients showed a clinical benefit (defined by an improvement in Karnofsky Performance Score and pain response to treatment), particularly with regards to pain reduction. Local complications occurred in three patients (pancreatitis and pseudocyst formation), and grade III haematologic toxicity was encountered in three patients without clinical impact [50].

Brachytherapy with several radiation-emitting sources has been trialled (Ra<sup>226</sup>, Rn<sup>222</sup>, Au<sup>198</sup>, Ir<sup>192</sup>) with significant complications and post-treatment mortality. More recently, I<sup>125</sup> has been

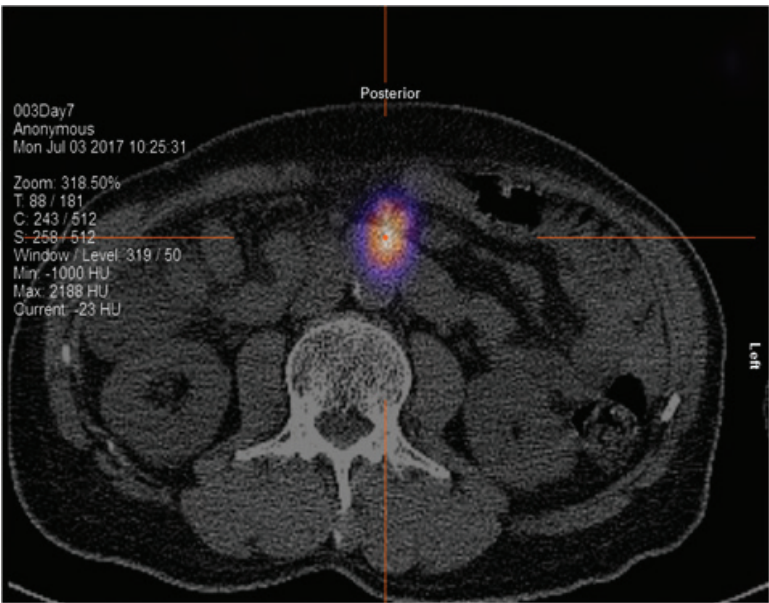




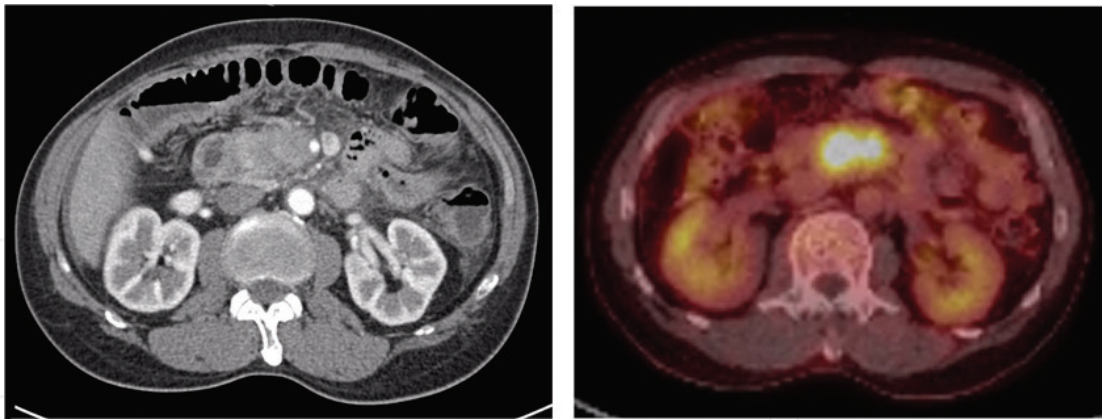
**Figure 3.** Brachytherapy seed implantation under direct EUS visualisation.

investigated, with much improved mortality rates, but showed no benefit to cancer-related mortality [51]. Current phase III studies are under way with P<sup>32</sup>; phase II safety studies have shown a moderate increase rate of serious adverse events per patient when used with 5-fluorouracil (5FU) chemotherapy followed by gemcitabine, compared to EBRT with 5FU chemotherapy, followed by gemcitabine [52]. The varying complication rates reported across studies may also be due to interoperator variability or the low numbers of cases treated. More studies with larger numbers are needed and are currently underway.

There are also some efforts to improve the planning and delivery of brachytherapy to the intended area. Sun et al. (2017) developed a computer-based treatment planning system that was studied in 42 patients with unresectable PC. In this study, EUS-BT using this software



**Figure 4.** Bremm study one week after brachytherapy.



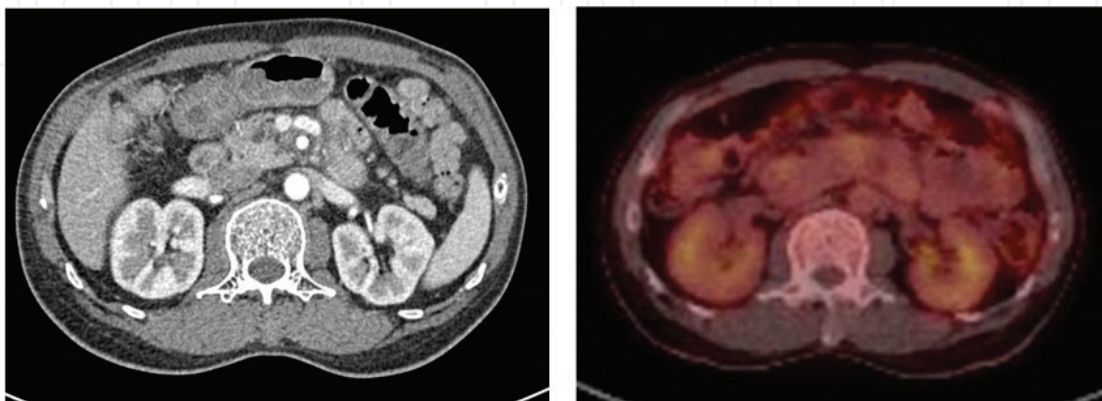
**Figure 5.** CT and PET scan of pancreatic cancer pre-brachytherapy implantation.

was performed and showed an OS for stage III patients of >12 months with an overall median survival time of 9.0 months (95% CI 7.6–10.4 months) [53]. Interestingly, the use of this treatment planning system resulted in no serious adverse events in the study population, which has been a significant criticism of this treatment modality previously.

#### *7.1.3. Radiofrequency ablation*

Radiofrequency ablation (RFA) induces coagulative necrosis through the application of heat induced by a medium-frequency alternating current [54]. RFA as an anticancer technique is currently utilised in the management of several other malignancies (hepatocellular, renal, etc.), but is also employed in the disruption of aberrant electrical pathways in the heart, as well as in pain medicine, for the ablation of nerve in certain conditions. Until EUS, the utility of external application of RFA has been limited by the sensitivity of pancreatic tissue and nearby gastrointestinal tissues to RFA, leading to significant complications.

EUS-radiofrequency ablation (EUS-RFA) has been studied in several small case series. There have been two recent systematic reviews published on EUS-RFA in pancreatic malignancies [55, 56]. Rustagi and Chhoda (2017) reported on four clinical studies performed in locally-advanced,



**Figure 6.** CT and PET scan of pancreatic cancer post-brachytherapy.

unresectable adenocarcinoma, pNETs, and pancreatic cystic neoplasms (PCNs). The endpoint of most of the reported studies was complication rate, rather than efficacy or survival. The follow-up period for the articles addressing better-prognosis pancreatic lesions (PCNs / pNETs) was also likely too short to draw conclusions from. Of the 37 cases included across the four studies, adverse events included mild abdominal pain in seven cases, minor duodenal bleeding in one case, jaundice in two cases, duodenal structuring in one case, and cystic fluid collection in one case. The authors concluded that EUS-RFA is feasible and safe in the management of pancreatic lesions, and that more studies are needed with larger sample sizes and longer follow-up periods to investigate EUS-RFA as a treatment modality for PC [56].

#### *7.1.4. High-intensity focused ultrasound*

A high-intensity focused ultrasound (HIFU) transducer has been developed for use with endoscopy. HIFU induces cell death by thermogenic coagulative necrosis, similar to RFA, but by emitting ultrasound waves, rather than radiofrequency waves. Tong et al. (2015) have successfully used this probe to induce lesions in normal porcine pancreatic models in vivo [57] to show proof of concept in inducing targeted areas of cell necrosis in pancreatic tissue. HIFU's use in inducing cell death in malignant pancreatic lesions has yet to be elucidated.

## **7.2. Artificial intelligence**

EUS images can be digitised for analysis by artificial neural networks (ANNs) to quantitatively analyse EUS images as to their likelihood of there being a malignant lesion within them. The use of ANN analysis in pancreatic EUS image analysis was reported by Norton (2016). In a study of 21 patients with PC and 14 patients with focal pancreatitis, ANN analysis was able to differentiate between PC and focal pancreatitis with an accuracy of 89%. This was similar to the endosonographer's impression at time of EUS (accuracy 85%) [58].

Saftoiu et al. performed a similar study among 68 patients; 22 with a normal pancreas, 11 with chronic pancreatitis, 32 with pancreatic adenocarcinoma, and 3 with pancreatic neuroendocrine tumours (pNETs). Reported sensitivity, specificity and accuracy were 91.4, 87.9, and 89.7% respectively and the study concluded that larger, prospective randomised controlled trials were needed to further investigate the use of this adjunct diagnostic tool [59].

With constant improvements in image quality, and further development of ANN models, this may prove a useful adjunct to EUS-based diagnosis, particularly if used by inexperienced endosonographers, and may help to broaden the accessibility of this imaging modality.

## **7.3. Elastography**

The act of vibrating tissues and measuring the elasticity of their resultant movement is being used in analysis of pancreatic lesions. In general, firmer lesions tend to be malignant; soft lesions are more likely benign. By qualitatively or quantitatively assessing their rebound potential, inferences can be made on the composition of pancreatic lesions.

Due to the differing relative consistency of benign and malignant lesions, quantitative strain elastography results can assist in differentiating subtypes of pancreatic mass. The use of EUS-Elastography has been assessed to have excellent sensitivity (95–99%) for differentiating benign



from malignant lesions, however due to the fibrotic nature of many of the benign pancreatic lesions (tumour-forming pancreatitis, and benign pancreatitis with fibrosis), specificity is inadequate (67–76%) to replace direct tissue sampling by way of EUS-FNA [60]. Moreover, there are currently several guidelines on the strain ratio cut-off value for differentiation between tissue subtypes, thus harmonisation and standardisation are required between techniques.

Elastography can be measured by either strain elastography by measuring propagated external pressure in the axis of the direction of the applied force, or by shear wave elastography [61]. The latter utilises acoustic radiation force impulses to generate perpendicular 'shear' waves, the velocity of which can be measured in the field of the ultrasound, and are not affected by structures posterior to the target organ in question. Currently, only strain elastography is available via endoscopic approach. Due to the pulsations of the nearby aorta, the future use of shear wave elastography may be advantageous over current strain elastography.

#### **7.4. Contrast-enhanced harmonic ultrasound**

Contrast-enhanced harmonic endoscopic ultrasound (CEH-EUS) uses intravenously administered hyperechoic microparticles at the time of ultrasound to provide further information regarding the vascularity of the lesion in-question. In the presence of contrast, PC generally appears hypoenhanced and heterogenous, pancreatitis appears isoenhanced, and pNETs cancers appear hyperenhanced [62]. Sensitivity has been reported to be above 90% in multiple studies [63, 64]. However, as some PCs have been reported as being isoenhanced, the specificity of this modality (68%) is also insufficient for replacing EUS-FNA.

CEH-EUS has been combined with EUS-FNA to improve the accuracy of diagnosis of EUS-FNA. Due to the highly desmoplastic stroma in and around PCs, targeting hypoechoic or isoechoic appearance on CEH-EUS for FNA has been shown to improve diagnostic yield when compared to EUS-FNA alone. Sugimoto et al. (2015) have also shown that CEH-EUS-FNA has the potential to reduce the number of needle passes required for diagnosis [65]. In their conclusion, the authors make the valid point that in all reported cases of needle-tract seeding in EUS-FNA, multiple needle passes were performed. Although in need of validation, CEH-EUS-FNA has the potential to reduce the risk of needle-tract seeding by reducing the required needle passes.

### **8. Confocal laser endomicroscopy**

Confocal laser endomicroscopy (CLE) allows for in vivo histological analysis of tissues in real time. The technique is being developed for the assessment of early pancreatic masses and the surveillance of precancerous lesions. A laser is used to illuminate the target tissue, which is then reflected back through a pinhole to the user. Local or systemic use of fluorescence agents, such as fluorescein can also be used to enhance the image. In endoscopy, CLE can either be done through an integrated endoscope tip, which has been useful for assessing and targeting biopsies of the luminal wall (e.g. oesophagus or stomach), or through needle-based CLE (nCLE), which uses a microfiber that can pass through a 19-gauge needle to assess tissue at the site of the needle tip.



nCLE has been studied mostly in investigation of pancreatic cystic lesions and shown to have an accuracy of 46–95% for diagnosing PC, with a low sensitivity 46–59%. Overall complication rate ranges from 0 to 2.5%; complications include bleeding, infection, pancreatitis and perforation [66]. Nakai et al. used a combination of EUS-guided cystoscopy (direct visualisation of the internal wall of a cystic lesion) and nCLE in the assessment of 30 patients with cystic pancreatic lesions. The sensitivity of cystoscopy was 90% for determining PCN vs. BPC, nCLE was 80% sensitive, and the combination of the two modalities was 100% sensitive [67].

Kongkam et al. conducted a study to validate the CLE diagnostic criteria and found a 90.9% accuracy of EUS-nCLE among 22 patients [68]. They found malignant lesions displayed dark clumping with or without dilated vessels ( $<40\ \mu\text{m}$ ), while benign lesions were more likely to display white fibrous bands and normal acini. They also found good inter-observer agreement between the three blinded endoscopists ( $\kappa = 0.82$ ) [68]. These results contrast that of Karstensen JG et al. (2018), who conducted a prospective, dual-centre study on 28 patients with pancreatic masses referred for EUS-FNA and found limited benefit above EUS-FNA alone by using the current proposed nCLE criteria. This study also found significant interobserver and intraobserver analysis of the proposed CLE criteria, suggesting the reproducibility of the procedure is currently suboptimal. They concluded that further development of the technology is needed to permit better delineation between benign and malignant disease [69]. More studies are required in this area before EUS-CLE can be recommended as an adjunct to EUS-FNA for routine analysis of solid pancreatic lesions.

The use of EUS-nCLE to enable direct visualisation of molecular expression with pancreatic cancers has also been explored. Nakai et al. have shown proof-of-concept in the ability to directly image EGFR and survivin expression in porcine models *in vivo*. This study utilised the direct injection of fluorescein isothiocyanate-labelled antibodies against EGFR and survivin into the pancreas 30 min before EUS-nCLE to highlight the expression of EGFR and survivin, and showed good correlation between the EUS-nCLE images and histological analysis of the porcine pancreas *ex vivo* [70]. The use of similarly labelled antibodies to KRAS could assist in the stratification of precancerous lesions and direct early-stage treatment.

What about a section on molecular diagnosis personalised therapy. You cannot tell me that this will not be important in the future. I know self-citation is frowned upon but we have published 3 articles in this space recently?

## 9. Conclusion

EUS now has an integral and indeed indispensable role in the diagnosis, staging, and treatment of pancreatic cancer and its complications. It is likely that this technique will become increasingly important in the management of patients with this condition.

## Author details

Cameron John McLaren<sup>1\*</sup>, Daphne Day<sup>1,2</sup>, Daniel Croagh<sup>1,2</sup>, Andrew Strickland<sup>1,2</sup> and Eva Segelov<sup>1,2</sup>

\*Address all correspondence to: [cam.mclaren@gmail.com](mailto:cam.mclaren@gmail.com)

1 Monash Health, Melbourne, Australia

2 Monash University, Melbourne, Australia

## References

- [1] Hirschowitz B. Development and application of endoscopy. *Gastroenterology*. 1993; **104**(2):337-342
- [2] Bhatt J, Jones A, Foley S, Shah Z, Malone P, Fawcett D, et al. Harold Horace Hopkins: A short biography. *BJU International*. 2010; **106**(10):1425-1428
- [3] Modli I. A Brief History of Endoscopy Milan. Italy: Nexthealth; 1999
- [4] DiMagno E, DiMagno MJ. Endoscopic ultrasonography: From the origins to routine EUS. *Digestive Diseases and Sciences*. 2016; **61**:342-353
- [5] Vilmann P, Jacobsen G, Henriksen F, Hancke S. Endoscopic ultrasound with fuided fine needle aspiration biopsy in pancreatic disease. *Gastrointestinal*. 1992; **38**(2):172-173
- [6] Oh S, Irani S, Kozarek R. What are the current and potential future roles for endoscopic ultrasound in the treatment of pancreatic cancer? *World Journal of Gastrointest Endoscopy*. 2016; **8**(7):319-329
- [7] Thomas L. Educational Dimensions [Online]. 2007. Available from: <https://www.educationaldimensions.com/eLearn/endoscope/anatomy.php> [cited 10 Dec 2017]
- [8] Locker G, Hamilton S, Harris J, Jessup J, Kemeny N, Macdonald J, et al. ASCO 2006 update of recommendations for the use of tumor markers in gastrointestinal cancer. *Journal of Clinical Oncology*. 2006; **24**(33):5313
- [9] Molina V, Visa L, Conill C, Navarro S, Escudero J, Auge J, et al. CA 19-9 in pancreatic cancer: Retrospective evaluation of patients with suspicion of pancreatic cancer. *Tumour Biology*. 2012; **33**(3):799-807
- [10] Karlson B, Ekbom A, Lindgren P, Kallskog V, Rastad J. Abdominal US for diagnosis of pancreatic tumor: Prospective cohort analysis. *Radiology*. 1999; **213**(1):107
- [11] Tummala P, Junaidi O, Agarwal B. Imaging of pancreatic cancer: An overview. *Journal of Gastrointestinal Oncology*. 2011; **2**(3):168-174

- [12] Bronstein Y, Loyer E, Kaur H, Choi H, David C, DuBrow R, et al. Detection of small pancreatic tumors with multiphase helical CT. *American Journal of Roentgenology*. 2004; **182**(3):619-623
- [13] Karmazanovsky G, Fedorov V, Kubyshkin V, Kotchatkov A. Pancreatic head cancer: Accuracy of CT in determination of resectability. *Abdominal Imaging*. 2005; **30**(4):488-500
- [14] DelMaschio A, Vanzulli A, Sironi S, Castrucci M, Mellone R, Staudacher C, et al. Pancreatic cancer versus chronic pancreatitis: Diagnosis with CA 19-9 assessment, US, CT, and CT-guided fine-needle biopsy. *Radiology*. 1991; **178**(1):95
- [15] Ducreux M, Cuhna A, Caramella C, Hollebecque A, Burtin P, Goere D, et al. Cancer of the pancreas: ESMO clinical practice guidelines for diagnosis, treatment and follow-up. *Annals of Oncology*. 2015; **26**(Suppl 5):v56-v68
- [16] Berry W, Lundy J, Croagh D, Jenkins B. Reviewing the utility of EUS FNA to advance precision medicine in pancreatic Cancer. *Cancers*. 2018; **10**(2):35
- [17] Eloubeidi M, Jhala D, Chhieng D, Chen V, Eltoum I, Vickers S, et al. Yield of endoscopic ultrasound-guided fine-needle aspiration biopsy in patients with suspected pancreatic carcinoma. *Cancer*. 2003; **99**(5):285-292
- [18] Puli S, Bechtold M, Buxbaum J, Eloubedi M. How good is endoscopic ultrasound-guided fine-needle aspiration in diagnosing the correct etiology for a solid pancreatic mass? A meta-analysis and systematic review. *Pancreas*. 2013; **42**(1):20-26
- [19] Chen J, Yang R, Lu Y, Xia Y, Zhou H. Diagnostic accuracy of endoscopic ultrasound-guided fine-needle aspiration for solid pancreatic lesion: A systematic review. *Journal of Cancer Research and Clinical Oncology*. 2012; **138**(9):1433-1441
- [20] Best L, Rawji V, Pereira S, Davidson B, Gurusamy KS. Imaging modalities for characterising focal pancreatic lesions. *Cochrane Database of Systematic Reviews* 2017; **17**(4):1-299
- [21] Horwhat J, Paulson E, McGrath K, Branch M, Baillie J, Tyler D, et al. A randomized comparison of EUS-guided FNA versus CT or US-guided FNA for the evaluation of pancreatic mass lesions. *Gastrointestinal Endoscopy*. 2006; **63**(7):966-975
- [22] Okasha H, Naga M, Esmat S, Naguib M, Hassanein M, Hassani M, et al. Endoscopic ultrasound-guided fine needle aspiration versus percutaneous ultrasound-guided fine needle aspiration in diagnosis of focal pancreatic masses. *Endoscopic Ultrasound*. 2013; **2**(4):190-193
- [23] Minaga K, Takenaka M, Katanuma A, Kitano M, Yamashita Y, Kamata K, et al. Needle tract seeding: An overlooked rare complication of endoscopic ultrasound-guided fine-needle aspiration. *Oncology*. 2017; **93**(Suppl 1):107-112
- [24] Eloubedi M, Tamhane A, Varadarajulu S, CM W. Frequency of major complications after EUS-guided FNA of solid pancreatic masses: A prospective evaluation. *Gastrointestinal Endoscopy*. 2006; **63**(4):622-629
- [25] Polkowski M, Larghi A, Weynand B, Boustiere C, Giovannini M, Pujol B, et al. Learning, techniques, and complications of endoscopic ultrasound (EUS)-guided sampling in gastroenterology: European Society of Gastrointestinal Endoscopy (ESGE) technical guideline. *Endoscopy*. 2012; **44**(2):190-206

- [26] Gerke H, Rizk M, Vanderheyden A, Jensen C. Randomized study comparing endoscopic ultrasound-guided trucut biopsy and fine-needle aspiration with high suction. *Cytopathology*. 2010;**21**(1):44-51
- [27] Siddiqui U, Rossi F, Rosenthal L, Padda M, Murali-Dharan V, Aslanian H. EUS-guided FNA of solid pancreatic masses: A prospective, randomized trial comparing 22-gauge and 25-gauge needles. *Gastrointestinal Endoscopy*. 2009;**70**(6):1093-1097
- [28] Song T, Kim J, Lee S, Eum J, Moon S, Park D, et al. The prospective randomized, controlled trial of endoscopic ultrasound-guided fine-needle aspiration using 22G and 19G aspiration needles for solid pancreatic or peripancreatic masses. *The American Journal of Gastroenterology*. 2010;**105**(8):1739-1745
- [29] Levy M. Endoscopic ultrasound-guided trucut biopsy of the pancreas: Prospects and problems. *Pancreatology*. 2007;**7**(2-3):163-166
- [30] Castillo C, RE J. UpToDate. [Online]. 2017. Available from: [https://www.uptodate.com/contents/overview-of-surgery-in-the-treatment-of-exocrine-pancreatic-cancer-and-prognosis?search=pancreatic%20cancer&source=search\\_result&selectedTitle=2~150&usage\\_type=default&display\\_rank=2#H18](https://www.uptodate.com/contents/overview-of-surgery-in-the-treatment-of-exocrine-pancreatic-cancer-and-prognosis?search=pancreatic%20cancer&source=search_result&selectedTitle=2~150&usage_type=default&display_rank=2#H18) [cited Jan 12 2018]
- [31] Allen P, Kuk D, Castillo C, Basturk O, Wolfgang C, Cameron J, et al. Multi-institutional validation study of the American joint commission on cancer (8th edition) changes for T and N staging in patients with pancreatic adenocarcinoma. *Annals of Surgery*. 2017;**265**(1):185-191
- [32] Tamburrino D, Riviere D, Yaghoobi M, Davidson B, Gurusamy K. Diagnostic accuracy of different imaging modalities following computed tomography (CT) scanning for assessing the resectability with curative intent in pancreatic and periampullary cancer. *Cochrane Database of Systematic Reviews*. 2016;**15**(9):1-52
- [33] National Comprehensive Cancer Network. Pancreatic Adenocarcinoma. NCCN Clinical Practice Guidelines in Oncology. August 2, 2016
- [34] Arabul M, Karakus F, Alper E, Kandemir A, Celik M, Karakus V, et al. Comparison of multidetector CT and endoscopic ultrasonography in malignant pancreatic mass lesions. *Hepato-Gastroenterology*. 2012;**59**(117):1599-1603
- [35] Gonzalo-Marin J, Vila J, Perez-Miranda M. Role of endoscopic ultrasound in the diagnosis of pancreatic cancer. *World Journal of Gastrointestinal Oncology*. 2014;**6**(9):360-368
- [36] Wang W, Chen S, Brune K, Hruban R, Parmigiani G, Klein A. PancPRO: Risk assessment for individuals with a family history of pancreatic Cancer. *Journal of Clinical Oncology*. 2007;**25**(11):1417-1422
- [37] Bhutani MS, Koduru P, Joshi V, Saxena P, Suzuki R, Irisawa A, Yamao K. The role of endoscopic ultrasound in pancreatic cancer screening. *Endoscopic ultrasound*. 2016;**5**(1): 8-16
- [38] Rulyak S, Brentnall T. Inherited pancreatic cancer: Surveillance and treatment strategies for affected families. *Pancreatology*. 2001;**1**(5):477-485



- [39] Canto M, Goggins M, Yeo C, Griffin C, Axilbund J, Brune K, et al. Screening for pancreatic neoplasia in high-risk individuals: An EUS-based approach. *Clinical Gastroenterology and Hepatology*. 2004;**2**(7):606-621
- [40] Wiersema M, Wiersema L. Endosonography-guided celiac plexus neurolysis. *Gastrointestinal Endoscopy*. 1996;**44**(6):656-662
- [41] Arcidiacono P, Calori G, Carrara S, McNicol E, PA T. Celiac plexus block for pancreatic cancer pain in adults. *Cochrane Database of Systematic Reviews*. 2011;**3**(CD007519):1-26
- [42] Kambhampati S, Sugar E, Herman J, Erdek M, Shin E, Laheru D. A comparison of percutaneous and endoscopic-guided celiac plexus block/neurolysis in pancreatic cancer patients. *Journal of Clinical Oncology*. 2017;**35**(15\_suppl):e15767-e15767
- [43] Wyse J, Carone M, Paquin S, Usatii M, Sahai A. Randomized, double-blind, controlled trial of early endoscopic ultrasound-guided celiac plexus neurolysis to prevent pain progression in patients with newly diagnosed, painful, inoperable pancreatic cancer. *Journal of Clinical Oncology*. 2011;**29**(26):3541-3546
- [44] Iwashita T, Doi S, Yasuda I. Endoscopic ultrasound-guided biliary drainage: A review. *Clinical Journal of Gastroenterology*. 2014;**7**(2):94-102
- [45] Wang K, Zhu J, Xing L, Wang Y, Jin Z, Li Z. Assessment of efficacy and safety of EUS-guided biliary drainage: A systematic review. *Gastrointestinal Endoscopy*. 2016;**83**(6):1218-1227
- [46] Kahaleh M. U.S. National Library of Medicine, Clinical Trials [Online]. 2017. Available from: <https://clinicaltrials.gov/ct2/show/NCT03063554> [cited Jan 14 2018]
- [47] Yang X, Ren D, Liu S, Xie W, Shen J, Cai H, et al. EUS-guided ethanol injection for treatment of pancreatic cancer. *Gastrointestinal Endoscopy*. 2009;**69**(2 (suppl)):S263
- [48] Levy M, Alberts S, Bamlet W, Burch P, Farnell M, Gleeson F, et al. EUS-guided fine-needle injection of gemcitabine for locally advanced and metastatic pancreatic cancer. *Gastrointestinal Endoscopy*. 2017;**86**(1):161-169
- [49] Kaplan J, Khalid A, Cosgrove N, Soomro A, Mazhar S, Siddiqui A. Endoscopic ultrasound-fine needle injection for oncological therapy. *World Journal of Gastrointestinal Oncology*. 2015;**7**(12):466-472
- [50] Sun S, Xu H, Xin J, Liu J, Guo Q, Li S. Endoscopic ultrasound-guided interstitial brachytherapy of unresectable pancreatic cancer: Results of a pilot trial. *Endoscopy*. 2006;**38**(4):399-403
- [51] Hilaris B, Rousis K. In: H B, editor. *Cancer of the Pancreas*. Acton: Publishing Sciences Group; 1975
- [52] Rosemurgy A, Luzardo G, Cooper J, Bowers C, Zervos E, Bloomston M, et al. 32P as an adjunct to standard therapy for locally advanced unresectable pancreatic cancer: A randomized trial. *Journal of Gastrointestinal Surgery*. 2008;**12**(4):682-688
- [53] Sun X, Lu Z, Wu Y, Min M, Bi Y, Shen W, et al. An endoscopic ultrasonography-guided interstitial brachytherapy based special treatment-planning system for unresectable pancreatic cancer. *Oncotarget*. 2017;**8**(45):79099-79110

- [54] Pai M, Habib N, Senturk H, Lakhtakia S, Reddy N, Cicinnati V, et al. Endoscopic ultrasound guided radiofrequency ablation, for pancreatic cystic neoplasms and neuroendocrine tumors. *World Journal of Gastrointestinal Surgery*. 2015;**7**(4):52-59
- [55] Rustagi T, Chhoda A. Endoscopic radiofrequency ablation of the pancreas. *Digestive Diseases and Sciences*. 2017;**62**(4):843-850
- [56] Changela K, Patil R, Duddempudi S, Gaduputi V. Endoscopic ultrasound-guided radiofrequency ablation of the pancreatic tumors: A promising tool in management of pancreatic tumors. *Canadian Journal of Gastroenterology and Hepatology*. 2016;**2016**:1-5
- [57] Hwang J, Farr N, Morrison K, Wang YN, Khokhlova T, Ko BM, et al. Development of an EUS-guided high-intensity focused ultrasound endoscope. *Gastrointestinal Endoscopy*. 2011;**73**(4 (suppl)):AB155
- [58] Norton I, Zheng Y, Wiersema M, Greenleaf J, Clain J, Dimagno E. Neural network analysis of EUS images to differentiate between pancreatic malignancy and pancreatitis. *Gastrointestinal Endoscopy*. 2001;**54**(5):625-629
- [59] Saftoiu A, Vilmann P, Gorunescu F, Gheonea D, Gorunescu M, Ciurea T, et al. Neural network analysis of dynamic sequences of EUS elastography used for the differential diagnosis of chronic pancreatitis and pancreatic cancer. *Gastrointestinal Endoscopy*. 2008;**68**(6):1086-1094
- [60] Kawada N, Tanaka S. Elastography for the pancreas: Current status and future perspective. *World Journal of Gastroenterology*. 2016;**22**(14):3712-3724
- [61] Sarvazyan A, Rudenko O, Swanson S, Fowlkes J, Emelianov S. Shear wave elasticity imaging: A new ultrasonic technology of medical diagnostics. *Ultrasound in Medicine & Biology*. 1998;**24**(9):1419-1435
- [62] Sugimoto M, Takagi T, Suzuki R, Konno N, Asama H, Watanabe K, et al. Contrast-enhanced harmonic endoscopic ultrasonography in gallbladder cancer and pancreatic cancer. *Fukushima Journal of Medical Science*. 2017;**63**(2):39-45
- [63] Kitano M, Kudo M, Yamao K, Takagi T, Sakamoto H, Komaki T, et al. Characterization of small solid tumors in the pancreas: The value of contrast-enhanced harmonic endoscopic ultrasonography. *The American Journal of Gastroenterology*. 2012;**107**(2):303-310
- [64] Park J, Kim H, Bang B, Kim S, Jeong S, Lee D. Effectiveness of contrast-enhanced harmonic endoscopic ultrasound for the evaluation of solid pancreatic masses. *World Journal of Gastroenterology*. 2014;**20**(2):518-524
- [65] Sugimoto M, Takagi T, Hikichi T, Suzuki R, Watanabe K, Nakamura J, et al. Conventional versus contrast-enhanced harmonic endoscopic ultrasonography-guided fine-needle aspiration for diagnosis of solid pancreatic lesions: A prospective randomized trial. *Pancreatology*. 2015;**15**(5):538-541
- [66] Guo J, Bhutani M, Giovannini M, Li Z, Jin Z, Yang A, et al. Can endoscopic ultrasound-guided needle-based confocal laser endomicroscopy replace fine-needle aspiration for pancreatic and mediastinal diseases? *Endoscopic Ultrasound*. 2017;**6**(6):376-381

- [67] Nakai Y, Iwashita T, Park D, Samarasena J, Lee J, Chang K. Diagnosis of pancreatic cysts: EUS-guided, through-the-needle confocal laser-induced endomicroscopy and cystoscopy trial: DETECT study. *Gastrointestinal Endoscopy*. 2015;**81**(5):1204-1214
- [68] Kongkam P, Pittayanon R, Sampatanukul P, Angsuwatcharakon P, Aniwat S, Prueksapanich R, et al. Endoscopic ultrasound-guided needle-based confocal laser endomicroscopy for diagnosis of solid pancreatic lesions (ENES): A pilot study. *Endoscopy International Open*. 2016;**4**(1):E17-E23
- [69] Karstenden J, Cartana T, Constantinescu C, Dumatriscu S, Kovacevic B, Klausen P, et al. Endoscopic ultrasound guided needle-based confocal laser endomicroscopy in solid pancreatic masses – A prospective validation study. *Endoscopy International Open*. 2018;**6**(1): E78-E85
- [70] Nakai Y, Shinoura S, Ahluwalia A, Tarnawski A, Chang K. In vivo visualization of epidermal growth factor receptor and survivin expression in porcine pancreas using endoscopic ultrasound guided fine needle imaging with confocal laser-induced endomicroscopy. *Journal of Physiology and Pharmacology*. 2012;**63**(6):577-580