Chapter 4

Epsilon Waves: The Gate to Understand Arrhythmogenic Right Ventricular Dysplasia

Guo Liang Li, Ardan M. Saguner and
Guy Hugues Fontaine

Additional information is available at the end of the chapter

http://dx.doi.org/10.5772/intechopen.75871

Abstract

Arrhythmogenic right ventricular dysplasia (ARVD), first recognized in 1977, is an inherited cardiomyopathy mostly due to mutations in both desmosomal and non-desmosomal genes. ARVD is considered as a leading cause of sudden cardiac death in the young and the athlete. It is characterized by an abnormality in the development of the right ventricular (RV) musculature. The final diagnosis of ARVD was pathologically based on the findings characterized by fibro-fatty infiltration and cardiomyocyte loss predominantly affecting the RV. Epsilon waves are a feature of ARVD reflecting postexcitation of the myocytes in the RV that are interspersed between fibrous and fatty tissue. Epsilon waves are considered to be one of the major diagnostic criteria of ARVD and appear to correlate with the extent of ARVD and arrhythmic risk. In this review, we will briefly review the discovery of ARVD and Epsilon waves, discuss the electrogenesis and various methods for recording Epsilon waves, provide evidence to assist in understanding the pathological and functional changes of the heart in ARVD, thus promoting the management of this disease in patients and family members.

Keywords: sudden cardiac death, mutation, ECG, Arrhythmogenic right ventricular dysplasia, epsilon waves

1. Introduction

Arrhythmogenic right ventricular dysplasia (ARVD) was recognized in 1977 during antiarrhythmic surgery to map and treat ventricular tachycardia in Paris [1]. This work demonstrated some male patients presenting with ventricular tachycardia (VT) originating in the right ventricle (RV)

(**Figure 1**) [2]. However, all of them had preserved left ventricular function [1, 3–5]. The term "dysplasia" was chosen because it was observed at this critical point that the remaining myocardium was thinner than normal and covered by a large amount of fat (**Figure 2**A). This pattern constantly observed on the first four cases led to conclude that this structural abnormality was the result of a "developmental deficiency". The same reasoning has been made 25 years before by Dr. Henry Uhl, a pathologist of the Johns Hopkins Hospital, who observed the eponym disease on a single pediatric heart without myocardium, mostly seen on the RV free wall [6, 7]. Based on the previous evidence, the dysplastic phenomenon preferentially involved the areas of the anterior RV infundibulum, the RV apex and the inferior or diaphragmatic aspect of the RV, which constitute the original "triangle of dysplasia" (**Figure 2**B).

The term "arrhythmogenic right ventricular cardiomyopathy (ARVC)" was introduced before the First International Symposium organized in Paris in 1996 to incorporate other diseases already known under a different name such as right ventricular outflow tract (RVOT) VT or Brugada syndrome (BrS), and has foreseen completely new subgroups based on clinics and/or genetics. Naxos disease and desmoplakin related RV diseases are examples demonstrating that this prediction was correct. Therefore, the term ARVCs (plural) looks appropriate to incorporate all the clinical forms of cardiomyopathies of the right ventricle, in which ARVD as described by Marcus and Fontaine in 1982 [3], remains the most frequent form of presentation. In addition, the notion of "dysplasia (trouble of development)" was strongly confirmed by the heart of an arrhythmic fetus (**Figure 3**) and by recent advances of reproducing the disease in-the-dish [8–11].

The final diagnosis of ARVD was pathologically based on the previous findings of the typical evidence, namely myocardium embedded in or bordered by fatty tissue or fibrosis (**Figure 4**)

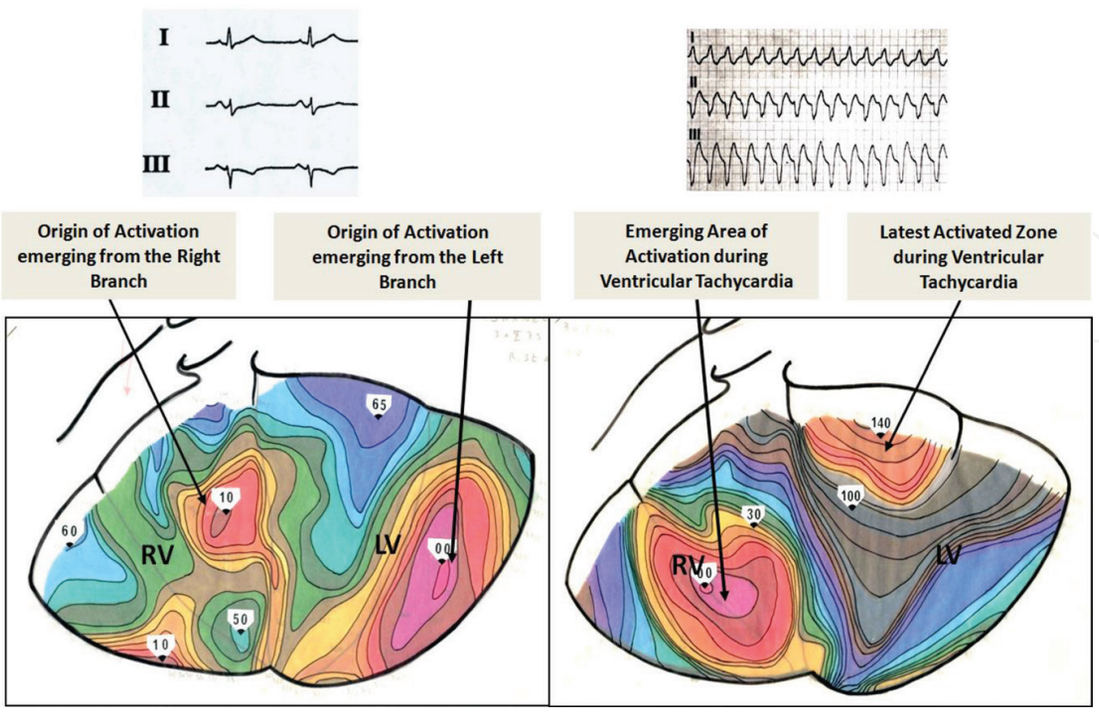

Figure 1. First ARVD patient, in whom the epicardial mapping during atrial overdrive pacing of sinus rhythm was performed. Note that the RV is activated 10 ms after the left ventricle (left); mapping after VT induction by burst stimulation (right). (With permission from Dr. Guy Hugues Fontaine) [2].

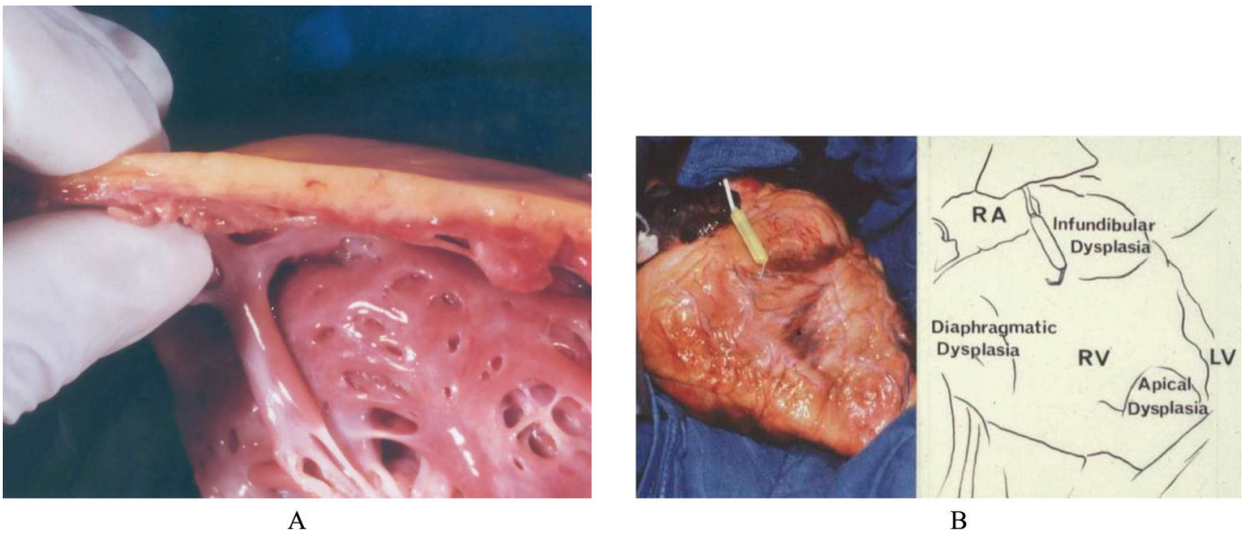

Figure 2. (A) Macroscopic findings in a patient with ARVD show a thinned endocardial layer of myocardium covered by a thicker than normal layer of fatty tissue. (Courtesy of Prof. Piccolo Venice). (B) The heart of a 50-year-old female ARVD patient during surgery. The most prominent areas of dysplasia are illustrated on the drawing. (With permission from Dr. Guy Fontaine) [3].

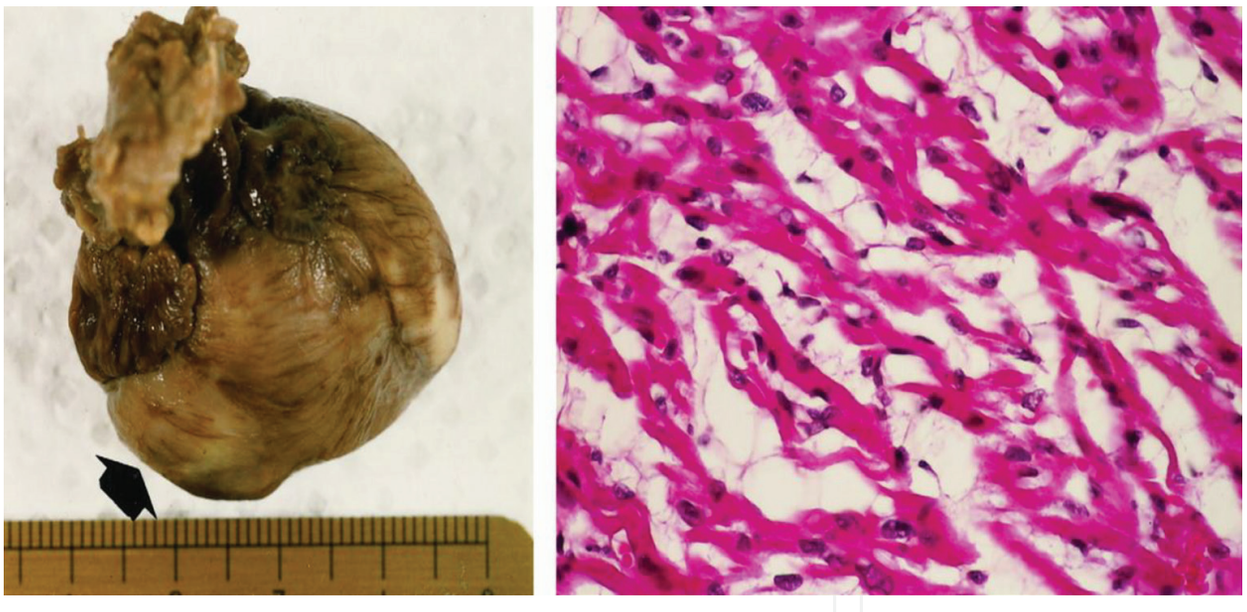

Figure 3. Evidence of a right lateral aneurysm of a 27-week-old fetal heart, arrhythmogenic in utero. Histology shows evidence of adipocytes interspersed with myocardial fibers. Minor fibrosis but no signs of inflammation were observed. Hematoxylin-phloxine-saffron stain; magnification ×400. (With permission from Dr. Guy Fontaine [10]).

[1, 4]. At the same time, the potential of apoptosis was also appreciated in remodeling myocardium in ARVD (**Figure 5**) [4]. In addition, further evidence indicates that the RV progressively enlarges over long-term follow-up. Left ventricular involvement is very frequently observed at later stages. This progression is likely to result in congestive heart failure leading to death [3, 12, 13]. The notion of ARVD as a genetic disease was strengthened by the evidence of its genetical susceptibility to myocarditis, (**Figure 6**) [14–17]. This, in turn, indicates that environmental factors can trigger rapid progression of ARVD.

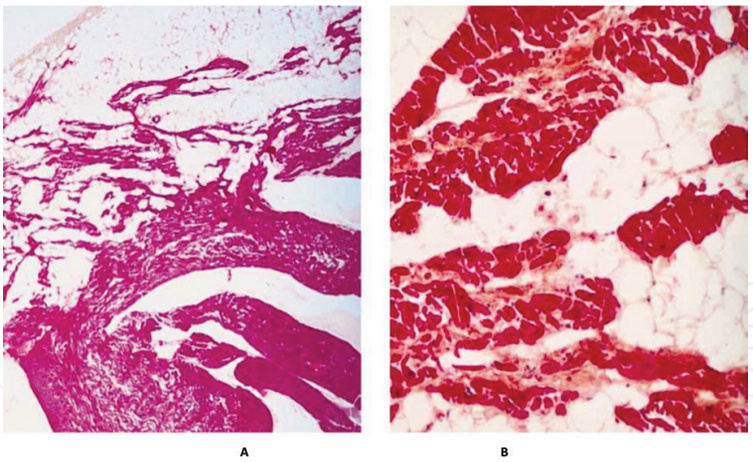

Figure 4. Free wall of the RV of a patient with ARVD. In panel a, there is a large amount of adipose tissue occupying the mediomural and subepicardial layers (hematoxylin-phloxine-saffron staining, ×10). In panel b, high magnification reveals surviving strands of myocardium bordered by or embedded in fibrous tissue. The presence of fibrous tissue is necessary for the diagnosis of ARVD. (With permission from Dr. Guy Fontaine [4]).

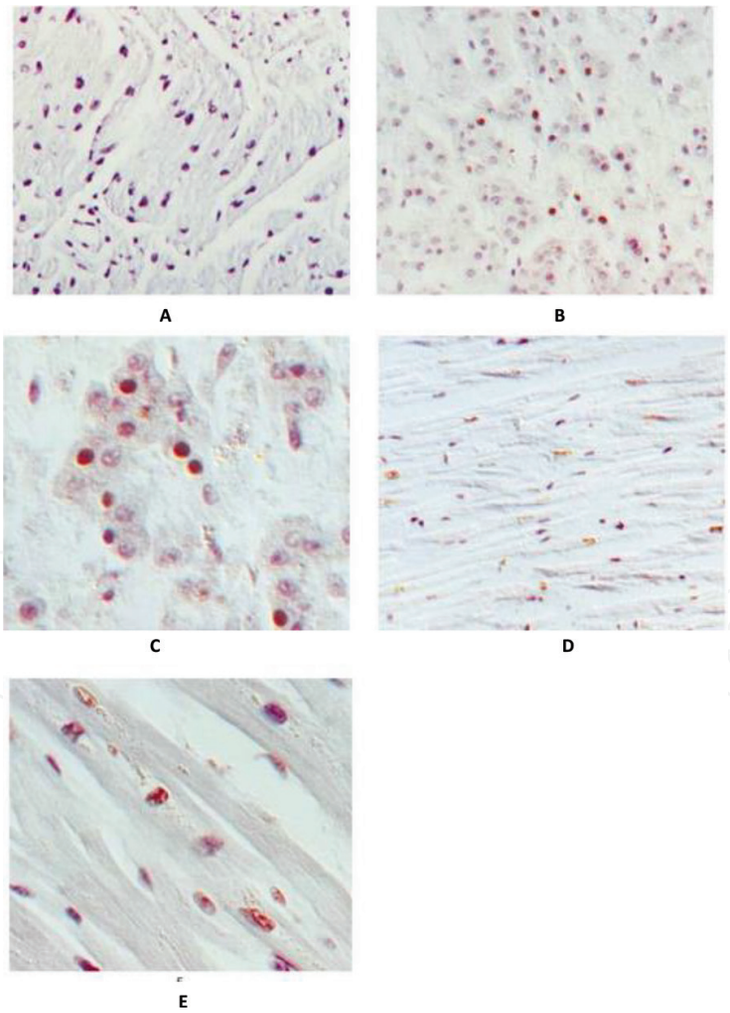

Figure 5. In situ end-labeling of fragmented DNA with TdT and biotinylated dUTP. Cells with fragmented DNA stained brown, whereas cells with normal nuclei stained blue (immunoperoxidase staining with hematoxylin counterstaining). In Panel A, a section from a normal human RV shows no apoptotic nuclei (×100). Transverse sections (Panels B and C) and longitudinal sections (Panels D and E) of RV myocardium from patients with lethal ARVD shows numerous myocardial nuclei with apoptosis. (Panels B and D, ×100; Panels C and E, ×400.) (With permission from Dr. Guy Fontaine [4]).

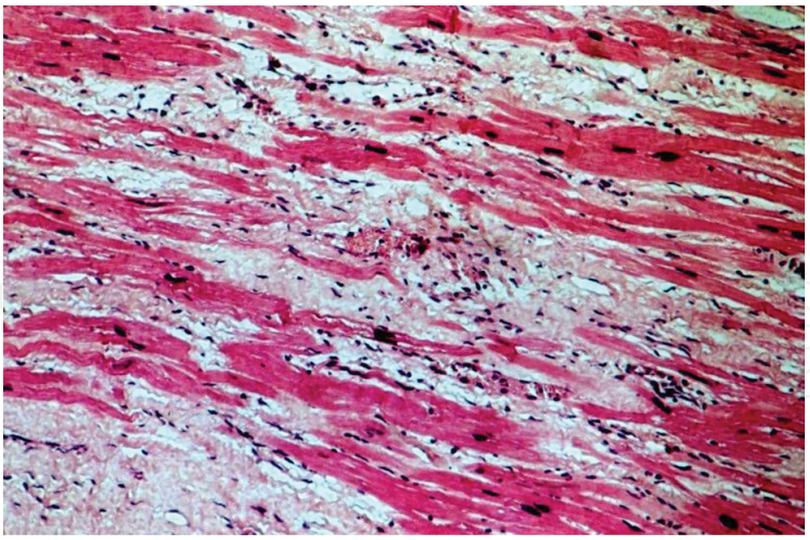

Figure 6. A 28-year-old male patient in whom the clinical course was illustrated by release of troponin and progressive decrease in left ventricular ejection fraction (LVEF), and finally heart transplant confirming the diagnosis of ARVD, but also showing a typical involvement of both ventricles by histological signs of lymphocytic myocarditis. A zone of chronic-active myocarditis in the LV in the same case indicated major loss of cardiac function leading to progressive deterioration of heart function and transplantation. (With permission Dr. Guy Fontaine [17]).

Major criteria
Epsilon waves or T wave inversions in leads V1-V3 and beyond in the absence of complete right bundle branch block
Minor criteria
Late potentials (signal-averaged ECG)
Inverted T waves in precordial leads (V1 and V2 or V4, V5 or V6) in absence of right bundle branch block
Terminal activation duration >=55ms in V1, V2 or V3

Table 1. ECG-based task force criteria for diagnosing ARV/D.

According to the 2010 Task Force criteria on ARVD [18], the fundamentals of ECG applications in the diagnosis of ARVD still remain unshakable. As an important noninvasive test, ECG provides useful information about disease evolution and the risk of VT/VF and SCD. ECG parameters for the diagnosis of ARVD were reviewed by several groups [3, 12, 19–24] and finally by the Task Force Criteria (**Table 1**) [18, 25]. The clinician needs to be aware of the ECG abnormalities reflecting the pathophysiology of ARVD to ascertain the likelihood of patients having this disease. This review focuses on the Epsilon wave, discusses the electrogenesis and various methods of assessing Epsilon waves. Importantly, it provides evidence to help better understand the pathological changes underlying ARVD, thus promoting the management of these patients.

2. Discovery of Epsilon waves

Epsilon waves (**Figure 7**), a reliable diagnostic ECG criterion of ARVD in the Task Force Criteria, were also reported in 1977 during surgery aforementioned [1]. We found that

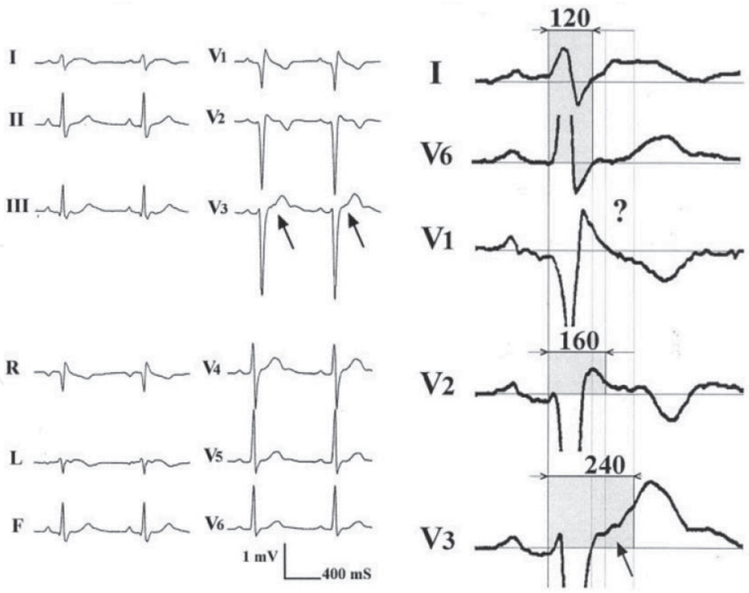

Figure 7. Typical ECG from a young man with ARVD with enlargement of some leads to stress the Epsilon wave in right precordials as opposed to the left. Also note fragmentation of the PR segment, which is in agreement with the possible risk of atrial arrhythmias. The '?' sign stresses the limit of Epsilon wave recognition on a single lead. (With permission from Dr. Guy Fontaine [28]).

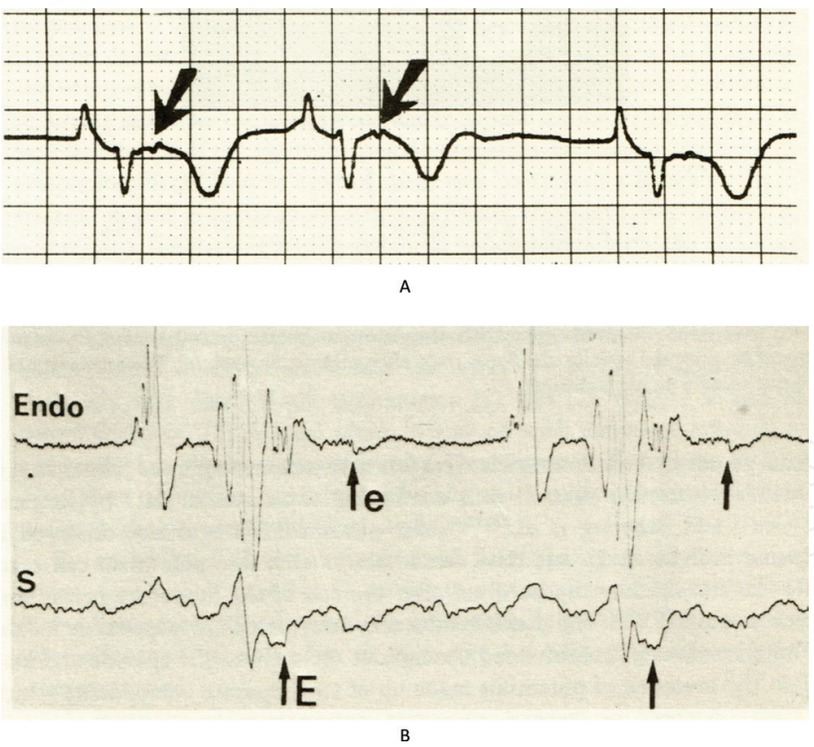

Figure 8. (A) Epsilon wave recorded from the body by two precordial electrodes positioned on both sides of xyphoid extremity. The Epsilon wave is indicated by an arrow. (B) on a bipolar thoracic lead (S), late potentials (indicated by an arrow) are seen in spite of considerable muscular activity. An intracavitary bipolar lead (electrodes located 6 cm apart) shows post-excitation waves, which occur much later than on the surface lead. (With permission from Dr. Guy Fontaine [1]).

the origination of VT was in the RV rather than the usual left ventricular scar areas. Low-amplitude signals on the epicardium during mapping consistently following each QRS complex (QRS) on the surface ECG were observed (**Figure 8**) [1]. At the end of right precordial QRS of the surface ECG, tiny signals as a slurring were also detected. Both signals were named Epsilon waves. The name "Epsilon wave" was given because (1) it is small in amplitude, (2) it is a "postexcitation" phenomenon that mirrors the "pre-excitation" delta wave of the Wolff–Parkinson–White syndrome at the beginning of each QRS complex, (3) it is the next Greek letter after delta, and (4) it represents delayed activation of right ventricular myofibers [9, 26].

3. Electrogenesis of Epsilon waves

This ECG feature of ARVD can be explained by its underlying pathogenesis. Epsilon waves are typically detected in ARVD patients during sinus rhythm. Observations from gross pathology of ARVD hearts during surgery and later from histology of tissue samples taken at surgery proved that electrogenesis of Epsilon waves was because of a structural anomaly. Strands of myocardium embedded in fatty tissue or fibrosis could account for zones of slow conduction leading to abnormal depolarization as a sign of postponed activation and the electrogenesis of Epsilon waves [1, 3, 4]. Conclusive clinical abnormalities contributing to Epsilon waves were only obtained after we studied 24 ARVD patients with resistant VT [3].

Epsilon waves typically appear in sinus-rhythm ECGs in ARVD patients as tiny potentials or notches following or buried at the end of the QRS, respectively, in the right precordial leads rather than the left counterparts (difference of QRS duration often ≥25 ms) (**Figure 7**). Epsilon waves were rarely observed during VT because most of the tachycardias in arrhythmogenic RV dysplasia exit from the triangle of dysplasia with early activation occurring in the RV myocardium. However, under some rare situation, Epsilon-like waves may also be detected during VT probably indicating extremely slow activation in the RV free wall of extensive ARVD [27].

4. Methods of assessing Epsilon waves

Three types of Epsilon waves (**Figure 9**) in ARVD patients can be recorded by various methods, including the common recording method of standard 12-lead ECG (S-ECG), the Fontaine Lead System (FLS), signal-averaged ECG (SAECG), and sometimes right-sided precordial lead electrocardiography (R-ECG) [3, 5, 26]. Recently, we also demonstrated the potential of an insertable loop recorder (ILR) [28] and a 16-lead High-Definition ECG recorder to detect Epsilon waves [29].

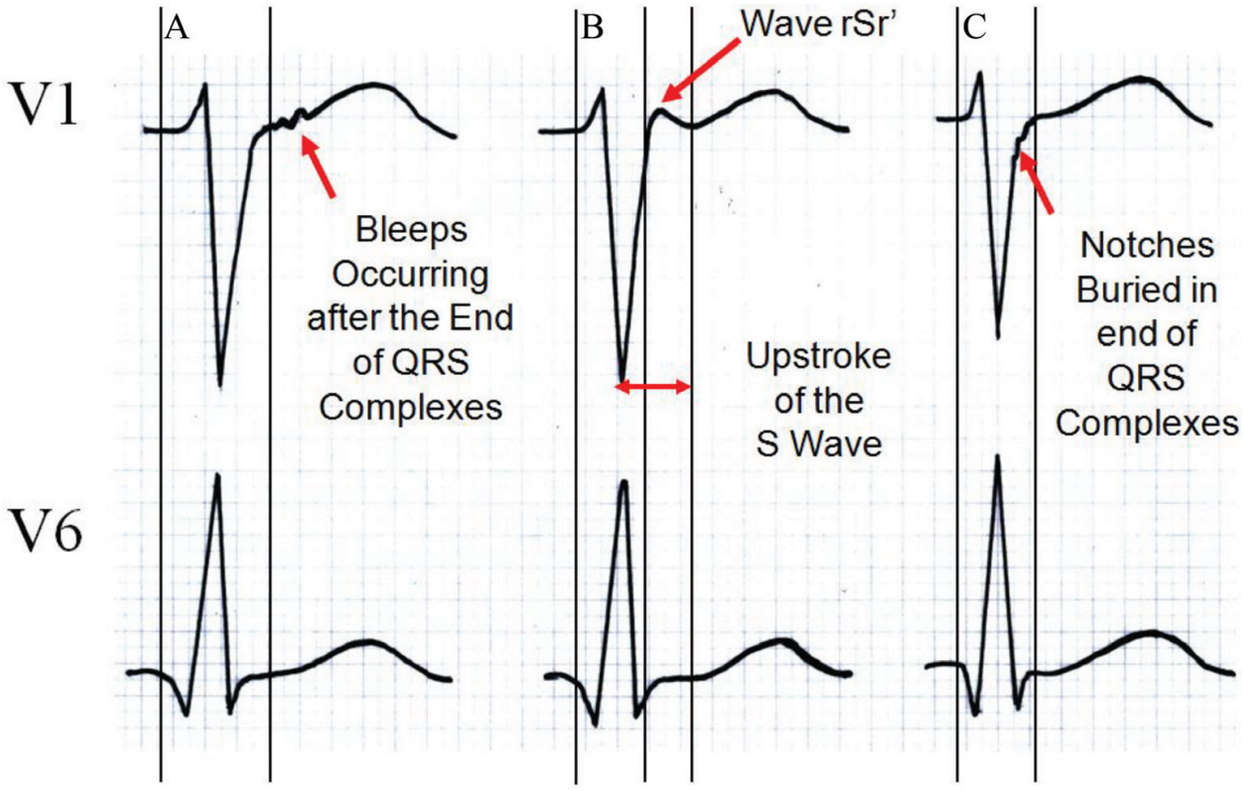

Figure 9. Patterns of Epsilon waves. Please note that our definition of Epsilon waves differs from the revised 2010 Task Force Criteria. The red arrows indicate the 3 patterns of Epsilon waves: (A) wiggle waves, (B) smooth potential waves with QRS duration in V_1 exceeding the duration in V_6 by 25 msec. (C) Small spike waves (With permission from Dr. Guy Fontaine). Please note that in the revised 2010 Task Force criteria these small spike waves within the upstroke of the S wave in leads V1-V3 are considered a minor depolarization criterion if the terminal activation duration is >=55ms (With permission from Dr. Guo-Liang Li) [29].

5. Standard 12-lead ECG

The detection rate of Epsilon waves was found to be up to 30% in S-ECG of ARVD patients evident in precordial leads V1 through V3 [5], and small spiked waves are the most common type observed [1, 5, 30]. When postponed activation of surviving strands of myocardium are present, an atypical prolonged R' wave of Epsilon waves can be detected in the right precordial leads. Therefore, the duration of any delayed signal in leads V1, V2 or V3 longer than the duration of the QRS in lead V6 by at least 25 ms can be regarded as Epsilon waves, indicating postponed activation of some RV myocardial fibers. Interestingly, the dynamic change of Epsilon waves was also addressed in the same individual [30]. Epsilon waves were seen in leads in V1 through V2 after the class 1C anti-arrhythmic drug propafenone to be administered intravenously for VT, but they disappeared after propafenone withdrawal. This dynamic change of Epsilon waves is not easy to explain; however, we can speculate that this is probably due to the effect of a rather large dose of propafenone I.V. The Epsilon wave is produced by a relative increase in conduction slowing in some, possibly more vulnerable, strands of RV myocardium. Also note that there is a "Presilon" wave, which disappears during propafenone administration due to a complete block of other strands of fibers.

6. Fontaine lead system

The FLS is a bipolar-lead system ECG performed specifically to detect RV signals from the infundibulum to the region of the diaphragm. FLS is able to detect larger amplitudes and a longer duration of Epsilon waves than S-ECG, on which this phenomenon of conduction slowing in the epicardial layers of the inferior RV and LV is too weak to produce significant Epsilon waves (**Figure 10**). In FLS, Epsilon waves were detected by putting an electrode close to the right arm connection (negative) on the manubrium sternal and the left arm connection (positive) on the xyphoid [5]. This placement is performed to detect more specifically the signals caused by the postponed RV fibers, covering the involved areas of the RV (**Figure 10**). The potential to detect Epsilon waves may also be increased by enhancing the sensitivity of detection [3, 5, 26, 21–33]. The detection rate of Epsilon waves was increased to more than 70% by FLS [26]. Previous work indicated that the FLS is capable of detecting Epsilon waves in FI, FII, and FIII to help meet a definitive diagnosis of ARVD according to the Task Force Criteria (**Table 1**) [32, 34].

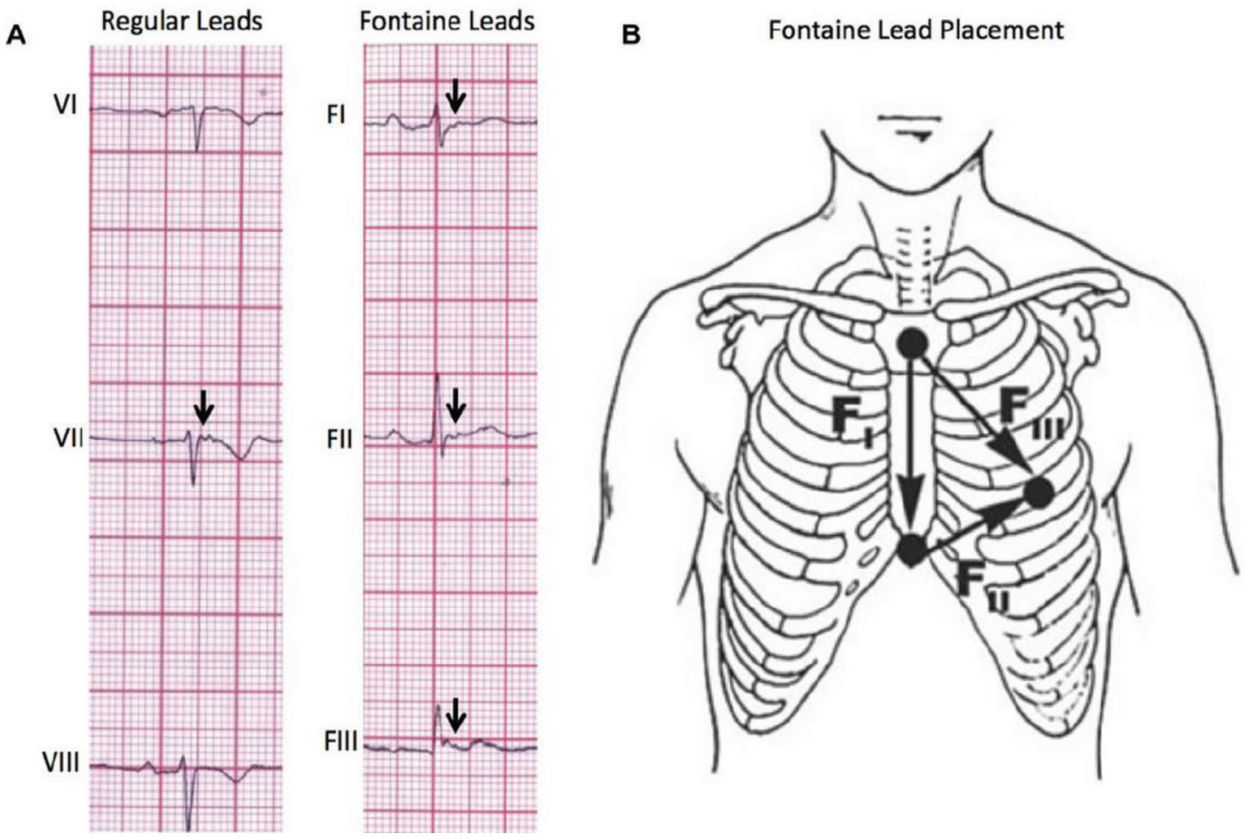

Figure 10. (A) Comparison of regular lead placement versus Fontaine Lead System in the ability to detect Epsilon waves (arrows). Using the Fontaine Lead System increases the sensitivity of detecting Epsilon waves so that they are detected in three leads (FI, FII, FIII) rather than one lead in the regular placement. (B), Fontaine bipolar precordial lead placement. In this modified technique, the ECG should be recorded at double speed (50 mm/s) and double amplification (20 mm/s) to improve the sensitivity for detection of Epsilon waves. (With permission from Dr. Guy Fontaine [32]).

Major
Regional RV akinesia or dyskinesia or dyssynchronous RV contraction and one of the following:
RV EDV/BSA ≥110 mL/m^2 (male) or ≥100 mL/m^2 (female)
RV ejection fraction ≤40%
Minor
Regional RV akinesia or dyskinesia or dyssynchronous RV contraction and 1 of the following:
RV EDV/BSA ≥100 to 110 mL/m^2 (male)or ≥90 to <100 mL/m^2 (female)
RV ejection fraction >40 to ≤45%

Table 2. CMR-based task force criteria for diagnosing ARVC/D.

7. Signal-averaged ECG

SAECG was performed to record late potentials (LPs). LPs provide a substrate for reentry presumably to initiate VT, especially after myocardial infarction. This is why LPs were frequently detected in individuals who are at risk of sustained VT or those affected by coronary artery disease and cardiomyopathy. The detection rate of LP in these patients ranges from 60 to 90%. The potentials detected by SAECG in ARVD have been better defined and systematically reviewed [3, 12, 23]. The prevalence of late potentials varied among ARVD patients ranging from 21 to 100%. SAECG has been performed to record low-amplitude and high-frequency signals in the terminal QRS of ARVD with high sensitivity, showing better correlation between the presence of LPs and the risk of VT as well as the extent of ARVD [3, 20, 35].

There is a direct relationship between SAECG variables and diffuse morphologic abnormalities as well as the regions of fibrous or fatty substitution of RV myocardium, further supporting the predictive value of SAECG for the extent of anatomical damage in individuals affected by ARVD [36, 37]. In addition, several studies were conducted to better define the potential of SAECG to evaluate progression of ARVD by recording LPs [12, 35, 37, 38]. Adults showed a higher prevalence of LPs on SAECG than the young, reflecting the gradually progressive course of ARVD [12, 36, 28]. During 8 years of follow-up conducted by Folino et al., [35] all parameters of SAECG showed a progression consistent with the evolution of LPs, particularly filtered QRS and high-frequency low-amplitude (HFLA) and root-mean-square (RMS).

8. Insertable loop recorder

ILR may constitute a sensitive method to detect Epsilon waves. The recording of Epsilon waves from ILR indicates a higher detection rate in ARVD due to the closer anatomic placement of ILR in relation to the RV than other methods. Recently, two cases of Epsilon waves detected by ILR were presented [28, 39]. In a case of a PKP2-mutation-positive carrier, we demonstrated for the first time the potential of an ILR to record Epsilon waves, absent on S-ECG. ILR displayed recurrent episodes of VT. In addition, fragmented potentials were detected before and after VT, indicating Epsilon waves undetectable by S-ECG (**Figure 11A**, **B**). The detectability of Epsilon waves

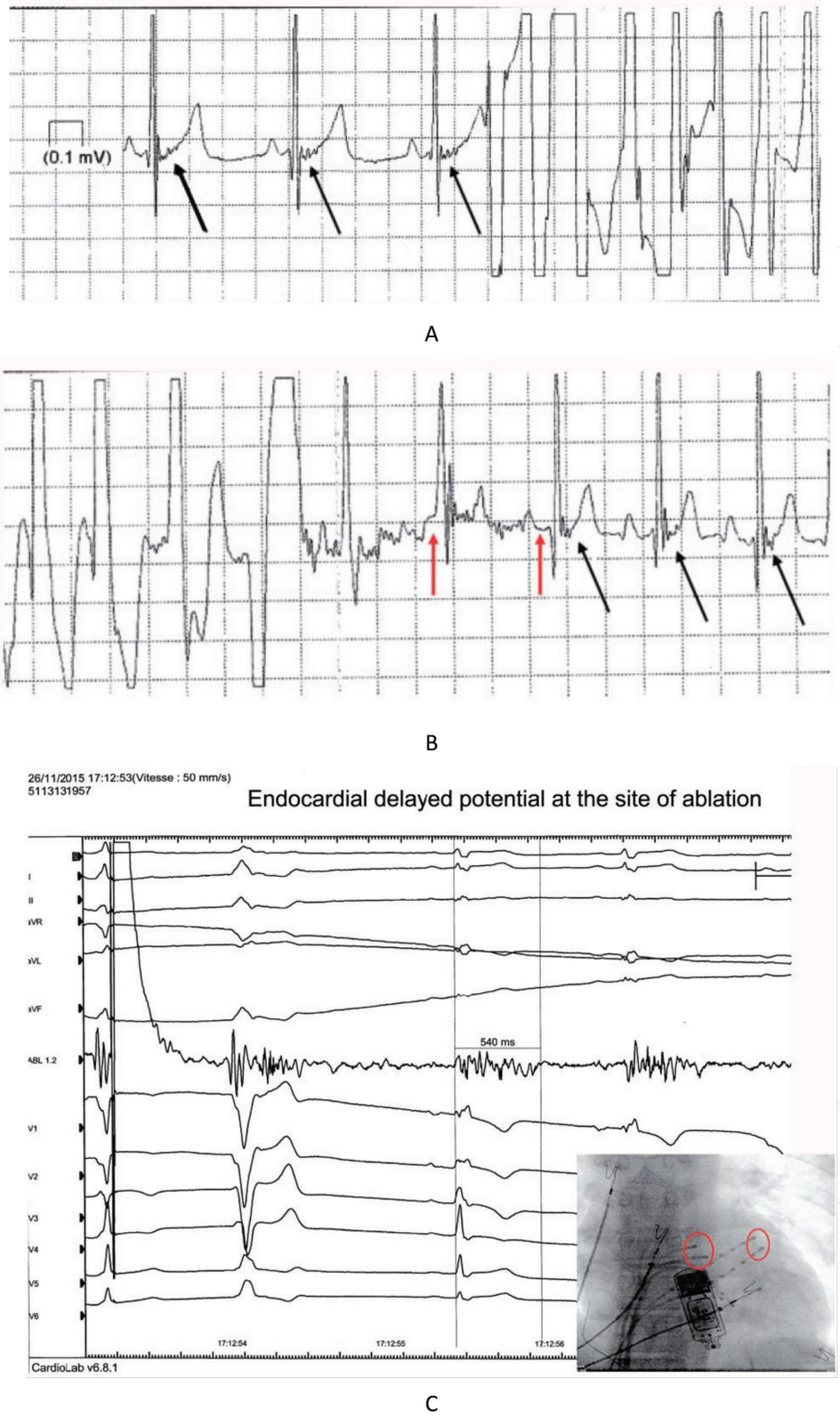

Figure 11. (A) Presence of Epsilon wave in the EGM of the ILR before the onset of VT (B) presence of Epsilon waves after EGM after spontaneous stop of VT (black arrows). Epsilon waves immediately after the VT interruption are able to occupy 80% of the basic cycle. Note that the two PR intervals show no fragmentation (red arrows). (C) Longest endocardial fragmented potentials in the infundibulum and X-ray image recorded during the ablation procedure (double catheter images is X-ray artifact). Position of the inserted loop recorder is close and almost parallel to the sternum. (With permission from Dr. Guy Fontaine [28]).

detected by ILR can be explained by its proximity to the RV free wall (if ILR are implanted in a classical position), where a 540 ms delay in conduction existed (**Figure 11C**). In addition, a host of myocardium encompassed by ILR systems may be another reason. Epsilon waves recorded by this system can help in the diagnosis of ARVD in individuals receiving ILR or similar devices. Recently, we also reported another case of ARVD in which the Epsilon wave is present on the surface ECG, but is also observed on the ILR confirming the previous description [28, 39]. However, a comparison of the potential of ILR to record Epsilon waves and other methods among ARVD individuals is lacking.

9. Combination of various methods

Multiple electrocardiographic recording methods are recommended to improve the potential to record Epsilon waves. Evidence from our and other groups confirmed the variability in distribution of involved regions from patient to patient and even within the same individual during the different stages of ARVD [30, 40]. Therefore, combined electrocardiographic recording methods are able to reinforce one another in the detection of Epsilon waves, especially after catheter ablation was introduced to treat ARVD related VT. The local-contact map in scar regions can clearly record delayed potentials, while Epsilon waves are not always visible upon surface ECG recordings [27, 41–43].

10. Cardiac magnetic resonance

Cardiac magnetic resonance (CMR) plays an important role in the detection of ARVD (**Table 2**). CMR can provide comprehensive information on cardiac morphology, function, and tissue characterization in a single investigation and help the physician toward the correct diagnosis, especially in distinguishing ARVD from other cardiomyopathies. [44, 45] As previously systematically reviewed [44–46], common findings of ARVD by CMR include global reduction in RV function and enlargement of the RV. In the revised TFC, the terms "akinesia," "dyskinesia" and "dyssynchronous" contraction are used to describe CMR findings.

However, evaluation of cardiac structure and function using CMR is probably not necessary in the absence of baseline electrical abnormalities [47]. In one of the largest clinical studies, the value of CMR was evaluated in a prospective cohort of 69 ARVD mutation carriers without prior sustained ventricular arrhythmias [47]. Te Riele et al. have shown that electrical abnormalities based on their ECG and Holter monitors were more prevalent (61%) than structural changes on CMR (48%). Of note, only 1 (4%) patient without electrical abnormalities at initial evaluation had structural changes on CMR, further suggesting that electrical abnormalities may have occurred long before the development of obvious signals detected by clinical and cardiac imaging tools such as CMR. This lead the authors to conclude that evaluation of cardiac structure and function using CMR is probably not necessary in the absence of baseline electrical abnormalities. Therefore, the optimal strategy is to perform CMR in individuals with baseline electrical abnormalities, especially in those with a history of arrhythmic events,

but deferred use of CMR is recommended in patients with normal ECG and/or 24-h Holter monitoring and transthoracic echocardiography at initial evaluation.

11. Significance and conclusion

ARVD development is a concealed process at the early stage. Most patients during this period present with ECG abnormalities, and there are no validated signals detected by clinical and cardiac imaging tools, indicating that ECG changes may have occurred long before the development of gross wall motion abnormalities. Therefore, it may be important to focus on electrical abnormalities to diagnosis suspected ARVD rather than on structural changes alone. For those with known ARVD, electrical indexes may help evaluating the progressive extent of this disease. In addition, understanding the manifestations on the ECG and the extent of this disease would help assisting in clinical decision-making, namely antiarrhythmic drugs, ICD insertion, and endocardial/epicardial ablation. Over the past four decades of progress since 1977, the contribution of Epsilon waves is increasingly recognized and is always on the list of available ECG markers used as a criterion of ARVD diagnosis. There is emerging evidence that there is a good correlation of Epsilon waves with the extent of ARVD and the risk of arrhythmias. However, the definition of Epsilon waves remains difficult and its value is sometimes controversial though emerging technological methods are introduced to increase the detection rates of Epsilon waves. Therefore, more accurate methods are needed to improve the sensitivity and specificity of Epsilon wave detection. Moreover, prospective, multicenter and collaborative studies are needed to broaden or define the potential of Epsilon waves in the diagnosis and risk stratification of patients with ARVD, particularly in family members, since up to one-third of ARVD first-degree relatives will develop manifest ARVD [48]. Finally, the detection of Epsilon waves with new techniques such as the 16HD-lead ECG system and some other noninvasive markers similar to or better than new CMR sequences (high-resolution T1 mapping or feature tracking) to perform a non-invasive morphological and functional evaluation, as well as to evaluate the risk of arrhythmias and the extent of progression in ARVD are imperative, especially when predominant left ventricular involvement is increasingly recognized. This is a challenge we all face in the present era.

Acknowledgements

We extend our gratitude to colleagues from all over the world who contributed to the ARVD work over the past four decades.

We dedicate this work to our great mentor and teacher Guy H. Fontaine who is deeply missed.

Conflict of interests

Authors declare no conflict of interests.

Author details

Guo-Liang Li[1,2*†], Ardan M. Saguner[3†] and Guy Hugues Fontaine[1]

*Address all correspondence to: liguoliang_med@163.com

1 Institute de Cardiologie, Unité de Rythmologie, Hôpital Universitaire La Pitié-Salpêtrière, Paris, France

2 Department of Cardiovascular Medicine, First Affiliated Hospital of Xi'an Jiaotong University, Xi'an, China

3 Department of Cardiology, University Heart Center Zurich, Zurich, Switzerland

† GL. Li and AM Saguner equally contributed to this article and are shared first authors.

References

[1] Fontaine G, Guiraudon G, Frank R, Vedel J, Grosgogeat Y, Cabrol C, Facquet J. Stimulation studies and epicardial mapping in ventricular tachycardia: Study of mechanisms and selection for surgery. In: Kulbertus HE, editor. Lancaster: MTP Pub; 1977. p. 334-350

[2] Fontaine G, Frank R, Hebert J-L, Hidden-Lucet F, Komajda M. Discovery of right ventricular cardiomyopathies. In: Brunckhorst C, Duru F, editors. Currents in Arrhythmogenic Right Ventricular Cardiomyopathy/Dysplasia. Minneapolis, Minnesota: Cardiotext Publishing; 2014. p. 1-13

[3] Marcus FI, Fontaine GH, Guiraudon G, Frank R, Laurenceau JL, Malergue C, Grosgogeat Y. Right ventricular dysplasia: A report of 24 adult cases. Circulation. 1982;**65**:384-398

[4] Mallat Z, Tedgui A, Fontaliran F, Frank R, Durigon M, Fontaine G. Evidence of apoptosis in arrhythmogenic right ventricular dysplasia. The New England Journal of Medicine. 1996;**335**:1190-1196

[5] Fontaine G, Fontaliran F, Hebert JL, Chemla D, Zenati O, Lecarpentier Y, Frank R. Arrhythmogenic right ventricular dysplasia. Annual Review of Medicine. 1999;**50**:17-35

[6] Uhl HS. A previously undescribed congenital malformation of the heart: Almost total absence of the myocardium of the right ventricle. Bulletin of the Johns Hopkins Hospital. 1952;**91**:197-209

[7] Perez Diaz L, Quero Jimenez M, Moreno Granados F, Perez Martinez V, Merino Batres G. Congenital absence of myocardium of right ventricle: Uhl's anomaly. British Heart Journal. 1973;**35**:570-572

[8] Te Riele AS, Agullo-Pascual E, James CA, Leo-Macias A, Cerrone M, Zhang M, Lin X, Lin B, Sobreira NL, Amat-Alarcon N, et al. Multilevel analyses of SCN5A mutations in arrhythmogenic right ventricular dysplasia/cardiomyopathy suggest non-canonical mechanisms for disease pathogenesis. Cardiovascular research. 2017;**113**:102-111

[9] Fontaine G, Chen HS. Arrhythmogenic right ventricular dysplasia back in force. The American Journal of Cardiology. 2014;**113**:1735-1739

[10] Fontaine GH. The multiple facets of right ventricular cardiomyopathies. European Heart Journal. 2011;**32**:1049-1051

[11] Kim C, Wong J, Wen J, Wang S, Wang C, Spiering S, Kan NG, Forcales S, Puri PL, Leone TC, et al. Studying arrhythmogenic right ventricular dysplasia with patient-specific iPSCs. Nature. 2013;**494**:105-110

[12] Nasir K, Rutberg J, Tandri H, Berger R, Tomaselli G, Calkins H. Utility of SAECG in arrhythmogenic right ventricle dysplasia. Annals of Noninvasive Electrocardiology 2003;**8**:112-120

[13] Hulot JS, Jouven X, Empana JP, Frank R, Fontaine G. Natural history and risk stratification of arrhythmogenic right ventricular dysplasia/cardiomyopathy. Circulation. 2004;**110**:1879-1884

[14] Lopez-Ayala JM, Pastor-Quirante F, Gonzalez-Carrillo J, Lopez-Cuenca D, Sanchez-Munoz JJ, Oliva-Sandoval MJ, Gimeno JR. Genetics of myocarditis in arrhythmogenic right ventricular dysplasia. Heart Rhythm. 2015;**12**:766-773

[15] Chang XD, Gu YJ, Dai S, Chen XR, Zhang CL, Zhao HS, Song QH. Ponsiglione A, Puglia M, Morisco C, Barbuto L, Rapacciuolo A, Santoro M, Spinelli L, Trimarco B, Cuocolo A, Imbriaco M. A unique association of arrhythmogenic right ventricular dysplasia and acute myocarditis, as assessed by cardiac MRI: A case report. BMC cardiovascular disorders. 2016;**16**:230

[16] Bowles NE, Ni J, Marcus F, Towbin JA. The detection of cardiotropic viruses in the myocardium of patients with arrhythmogenic right ventricular dysplasia/cardiomyopathy. Journal of the American College of Cardiology. 2002;**39**:892-895

[17] Saguner AM, Roland F, Li GL, Fontaine GH. Superimposed myocarditis leading to heart transplantation in a young patient with arrhythmogenic right ventricular dysplasia European heart journal. 2017;**38**:1424-1424

[18] Marcus FI, McKenna WJ, Sherrill D, Basso C, Bauce B, Bluemke DA, Calkins H, Corrado D, Cox MG, Daubert JP, et al. Diagnosis of arrhythmogenic right ventricular cardiomyopathy/dysplasia: Proposed modification of the task force criteria. Circulation. 2010;**121**:1533-1541

[19] Zhang L, Liu L, Kowey PR, Fontaine GH. The electrocardiographic manifestations of arrhythmogenic right ventricular dysplasia. Current Cardiology Reviews. 2014;**10**: 237-245

[20] Nava A, Folino AF, Bauce B, Turrini P, Buja GF, Daliento L, Thiene G. Signal-averaged electrocardiogram in patients with arrhythmogenic right ventricular cardiomyopathy and ventricular arrhythmias. European Heart Journal. 2000;**21**:58-65

[21] Kamath GS, Zareba W, Delaney J, Koneru JN, McKenna W, Gear K, Polonsky S, Sherrill D, Bluemke D, Marcus F, et al. Value of the signal-averaged electrocardiogram in arrhythmogenic right ventricular cardiomyopathy/dysplasia. Heart Rhythm. 2011;**8**:256-262

[22] Marcus FI, Zareba W. The electrocardiogram in right ventricular cardiomyopathy/dysplasia. How can the electrocardiogram assist in understanding the pathologic and functional changes of the heart in this disease? Journal of Electrocardiology. 2009;**42**:136 e131-135

[23] Neto JNdA, Baranchuk A, Bayés-Genís A, Luna ABd. Arrhythmogenic right ventricular dysplasia/cardiomyopathy: An electrocardiogram-based review. Europace, eux202, doi.org/10.1093/europace/eux202

[24] Peters S, Trummel M, Koehler B. QRS fragmentation in standard ECG as a diagnostic marker of arrhythmogenic right ventricular dysplasia-cardiomyopathy. Heart Rhythm. 2008;**5**:1417-1421

[25] McKenna WJ, Thiene G, Nava A, Fontaliran F, Blomstrom-Lundqvist C, Fontaine G, Camerini F. Diagnosis of arrhythmogenic right ventricular dysplasia/cardiomyopathy. Task Force of the Working Group Myocardial and Pericardial Disease of the European Society of Cardiology and of the Scientific Council on Cardiomyopathies of the International Society and Federation of Cardiology. British Heart Journal. 1994;**71**:215-218

[26] Hurst JW. Naming of the waves in the ECG, with a brief account of their genesis. Circulation. 1998;**98**:1937-1942

[27] Menon SM, Healey JS, Morillo CA. Epsilon waves during ventricular tachycardia in a case of arrhythmogenic right ventricular dysplasia. Circulation. 2010;**122**:1752-1755

[28] Fontaine GH, Duthoit G, Li GL, Andreoletti L, Gandjbakhch E, Frank R. Epsilon wave on an electronic loop in a case of arrhythmogenic right ventricular dysplasia with myocarditis: an updated definition of the Epsilon wave. Europace. 2017;**19**:1084-1090

[29] Li GL, Saguner AM, Akdis D, Fontaine GH. Value of a novel 16-Lead High Definition ECG machine to detect conduction abnormalities in structural heart disease. Pacing and Clinical Electrophysiology: PACE. 2018. DOI: 10.1111/pace.13338

[30] Wang J, Yang B, Chen H, Ju W, Chen K, Zhang F, Cao K, Chen M. Epsilon waves detected by various electrocardiographic recording methods: in patients with arrhythmogenic right ventricular cardiomyopathy. Texas Heart Institute journal. 2010;**37**:405-411

[31] Chiladakis J, Zagli F, Karantalis V, Alexopoulos D. New diagnosis of arrhythmogenic right ventricular cardiomyopathy in an octogenarian with the help of Fontaine electrocardiographic leads. Europace. 2010;**12**:1197-1198

[32] Gottschalk B, Gysel M, Barbosa-Barros R, De Sousa Rocha RP, Perez-Riera AR, Zhang L, Fontaine G, Baranchuk A. The use of fontaine leads in the diagnosis of arrhythmogenic right ventricular dysplasia. Annals of Noninvasive Electrocardiology. 2014;**19**:279-284

[33] Moreira D, Delgado A, Marmelo B, Correia E, Gama P, Pipa J, Nunes L, Santos O. Arrhythmogenic right ventricular cardiomyopathy: Contribution of different electrocardiographic techniques. Revista portuguesa de cardiologia. 2014;**33**:243 e241-247

[34] Kukla P, Jastrzebski M, Kurdzielewicz W. [Higher right precordial leads and Fontaine leads: The better detection of QRS fragmentation and epsilon wave in arrhythmogenic right ventricular dysplasia-cardiomyopathy]. Kardiologia Polska. 2012;**70**:958-959

[35] Folino AF, Bauce B, Frigo G, Nava A. Long-term follow-up of the signal-averaged ECG in arrhythmogenic right ventricular cardiomyopathy: Correlation with arrhythmic events and echocardiographic findings. Europace. 2006;**8**:423-429

[36] Daliento L, Turrini P, Nava A, Rizzoli G, Angelini A, Buja G, Scognamiglio R, Thiene G. Arrhythmogenic Right-Ventricular Cardiomyopathy in Young Versus Adult Patients-Similarities and Differences. Journal of the American College of Cardiology. 1995;**25**: 655-664

[37] Turrini P, Angelini A, Thiene G, Buja G, Daliento L, Rizzoli G, Nava A. Late potentials and ventricular arrhythmias in arrhythmogenic right ventricular cardiomyopathy. The American Journal of Cardiology. 1999;**83**:1214-1219

[38] Oselladore L, Nava A, Buja G, Turrini P, Daliento L, Livolsi B, Thiene G. Signal-averaged electrocardiography in familial form of arrhythmogenic right ventricular cardiomyopathy. The American Journal of Cardiology. 1995;**75**:1038-1041

[39] Fontaine G, Waintraub X, Li G, Gandjbahch E. A New Case of Epsilon Wave on Loop Recorder. Annals of Clinical and Laboratory Research. 2016;**4**:94-95

[40] Corrado D, Basso C, Leoni L, Tokajuk B, Bauce B, Frigo G, Tarantini G, Napodano M, Turrini P, Ramondo A, et al. Three-dimensional electroanatomic voltage mapping increases accuracy of diagnosing arrhythmogenic right ventricular cardiomyopathy/dysplasia. Circulation. 2005;**111**:3042-3050

[41] Ellison KE, Friedman PL, Ganz LI, Stevenson WG. Entrainment mapping and radiofrequency catheter ablation of ventricular tachycardia in right ventricular dysplasia. Journal of the American College of Cardiology. 1998;**32**:724-728

[42] Garcia FC, Bazan V, Zado ES, Ren JF, Marchlinski FE. Epicardial substrate and outcome with epicardial ablation of ventricular tachycardia in arrhythmogenic right ventricular cardiomyopathy/dysplasia. Circulation. 2009;**120**:366-375

[43] Reithmann C, Hahnefeld A, Remp T, Dorwarth U, Dugas M, Steinbeck G, Hoffmann E. Electroanatomic mapping of endocardial right ventricular activation as a guide for catheter ablation in patients with arrhythmogenic right ventricular dysplasia. Pacing and Clinical Electrophysiology: PACE. 2003;**26**:1308-1316

[44] van Rijsingen IA, van der Zwaag PA, Groeneweg JA, Nannenberg EA, Jongbloed JD, Zwinderman AH, Pinto YM, Dit Deprez RH, Post JG, Tan HL, et al. Outcome in phospholamban R14del carriers: Results of a large multicentre cohort study. Circulation Cardiovascular genetics. 2014;**7**:455-465

[45] Paul M, Rahbar K, Gerss J, Kies P, Schober O, Schäfers K, Breithardt G, Schulze-Bahr E, Wichter T, Schäfers M. Microvascular dysfunction in nonfailing arrhythmogenic right ventricular cardiomyopathy. European Journal of Nuclear Medicine and Molecular Imaging. 2012;**39**:416-420

[46] Udink ten Cate FE, Sreeram N, Brockmeier K. The pathophysiologic aspects and clinical implications of electrocardiographic parameters of ventricular conduction delay in repaired tetralogy of Fallot. Journal of Electrocardiology. 2014;**47**:618-624

[47] Philips B, Madhavan S, James CA, te Riele AS, Murray B, Tichnell C, Bhonsale A, Nazarian S, Judge DP, Calkins H, et al. Arrhythmogenic right ventricular dysplasia/cardiomyopathy and cardiac sarcoidosis: Distinguishing features when the diagnosis is unclear. Circulation Arrhythmia and Electrophysiology. 2014;**7**:230-236

[48] Te Riele AS, James CA, Groeneweg JA, Sawant AC, Kammers K, Murray B, Tichnell C, van der Heijden JF, Judge DP, Dooijes D, et al. Approach to family screening in arrhythmogenic right ventricular dysplasia/cardiomyopathy. European Heart Journal. 2016;**37**:755-763