

# We are IntechOpen, the world's leading publisher of Open Access books Built by scientists, for scientists

6,900

Open access books available

185,000

International authors and editors

200M

Downloads

Our authors are among the

154

Countries delivered to

TOP 1%

most cited scientists

12.2%

Contributors from top 500 universities



WEB OF SCIENCE™

Selection of our books indexed in the Book Citation Index  
in Web of Science™ Core Collection (BKCI)

Interested in publishing with us?  
Contact [book.department@intechopen.com](mailto:book.department@intechopen.com)

Numbers displayed above are based on latest data collected.  
For more information visit [www.intechopen.com](http://www.intechopen.com)



---

# Endoscopic Third Ventriculostomy

---

Tugrul Cem Unal and Aydin Aydoseli

Additional information is available at the end of the chapter

<http://dx.doi.org/10.5772/intechopen.75394>

---

## Abstract

Endoscopic third ventriculostomy (ETV) is a minimally invasive procedure commonly used to treat obstructive hydrocephalus. The objectives of the procedure are to fenestrate the floor of the third ventricle using a neuroendoscopic approach and to provide a cerebrospinal fluid (CSF) diversion. With high success rates published over the years, ETV became a routine modality for the obstructive hydrocephalus treatment. Furthermore, indications for ETV are expanding day by day and are no longer limited to obstructive hydrocephalus. Endoscopic third ventriculostomy has lower complication rate and has significant advantages compared to other CSF diversion techniques. Efficiency and safety of ETV are increasing with the advancements in technology.

**Keywords:** neuroendoscopy, hydrocephalus, endoscopic third ventriculostomy

---

## 1. Introduction

In the past decades, endoscopic third ventriculostomy (ETV) became a novel procedure for the treatment of obstructive hydrocephalus of various etiologies including aqueductal stenosis and tumors obstructing cerebrospinal fluid (CSF) pathways. As experience in this field grows, the indications for ETV are expanding to meningocele, Chiari malformation, or Dandy-Walker-related hydrocephalus cases or even to noncommunicating types of hydrocephalus. In select cases, ETV is becoming more and more preferable to ventriculoperitoneal (VP) shunt placement due to avoidance of shunt dependency and complications that come with the shunting [1]. Like indications, the technique for ETV is also refining gradually. Efficiency and safety of the procedure increase day by day with the advancements of tools, neuroimaging, and stereotactic technologies.

## 2. History

Walter Dandy is considered by many the father of neuroendoscopy. He described an endoscopic approach to choroid plexectomy for treatment of hydrocephalus [2]. Dandy also performed a fenestration in lamina terminalis via craniotomy in 1922, pioneering the concept of ventriculostomy, although the first successful endoscopic ventriculostomy is attributed to William Mixter. In 1923 Mixter performed a ventriculography combined with ventriculostomy using an ureteroscope in a 9-year-old girl with noncommunicating hydrocephalus [3]. Tracy Putnam and John Scarff, respectively, designed endoscopes suitable for ventricular surgery [4, 5]. Scarff made several modifications to the design like angled view, continuous irrigation system for replacing the CSF, a mobile unipolar electrode [5, 6].

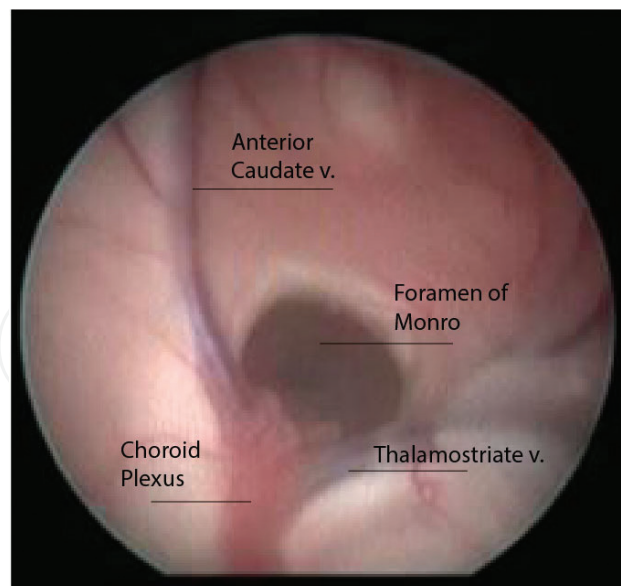
CSF diversion techniques became widely popular starting the 1950s [7]. The high rate of mortality and morbidity in endoscopic techniques with the technical difficulties led the shunt operations taking place in this era. However, even with the advancements in the shunt technology, CSF diversion was never perfect and had its own rate of complications like infection and dysfunction. After the introduction of shunting systems in the 1950s, ETV lost its popularity but only to regain in the 1970s and 1980s. Starting at the end of the 1970s, an interest in minimally invasive surgery emerged with the advancements in neuroimaging, stereotaxis, lighting, and computer technology [7]. Since then, endoscopic third ventriculostomy became a routine modality for the treatment of obstructive hydrocephalus with many other indications.

## 3. Operative technique

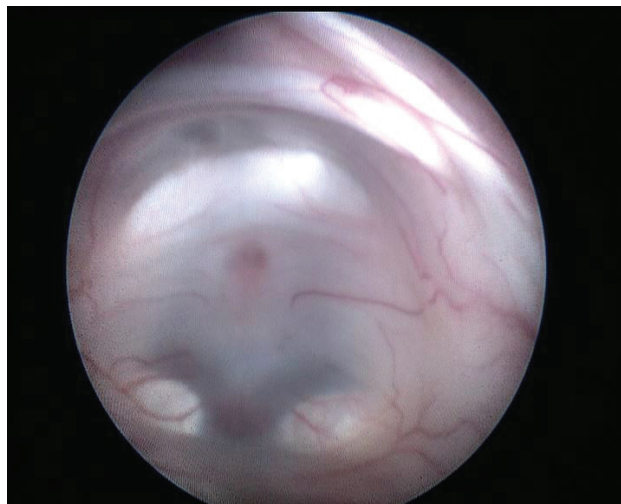
### 3.1. Important landmarks

Recognition of critical landmarks and structures in the ventricles is very important to achieve a successful ETV. The choroid plexus is an important anatomical landmark in the lateral ventricle as its anterior part extends to the foramen of Monro and then to the third ventricle (**Figure 1**). Recognizing the choroid plexus in the lateral ventricle gives the surgeon a road map to the third ventricle. Even with gross distortions in the ventricular anatomy, the choroid plexus remains at choroidal fissure and gives the surgeon an important navigational tool. Another important anatomical landmark is the fornix, which forms the superior and anterior margin of the foramen of Monro. Because of its location, the fornix is prone to injury when endoscope advancement is made from lateral to the third ventricle. The risk of injury increases with multiple passages. The thalamostriate vein is also an important landmark when recognized, as it dives to the foramen of Monro with the choroid plexus (**Figure 1**).

Hypothalamus forms the lateral walls of the third ventricle. The supraoptic and paraventricular arcuate nuclei are the structures most prone to injury during an ETV because of the localization in the lateral wall and proximity to the trajectory. Injury to these structures may result in severe endocrinologic disturbances as vasopressin and oxytocin are produced in these nuclei [8].



**Figure 1.** Endoscopic view of the foramen of Monro and adjacent structures.



**Figure 2.** Endoscopic view of the floor of the third ventricle.

The third ventricular floor is essentially a thin portion of the hypothalamus between two parts of it located in the lateral walls of the third ventricle. The limits to the floor are mammillary bodies posteriorly, the walls of the third ventricle laterally, and infundibular recess anteriorly. The third ventricle perforation is generally made in a safe zone accepted in just anterior of the midway between the infundibular recess and mammillary bodies (**Figure 2**). If penetrated more posterior to this point, one may encounter the basilar tip and anteriorly clivus.

### 3.2. Endoscope

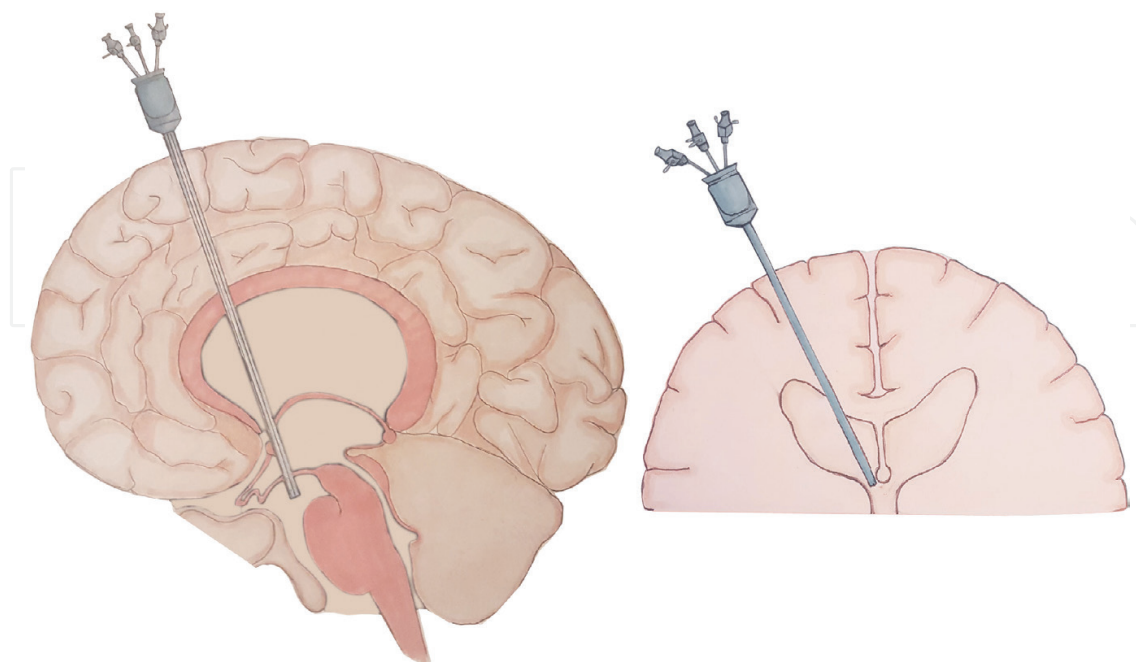
Basically, there are three types of endoscopes: rigid, semirigid, and flexible. In terms of optic systems available, neuroendoscopes are currently rod-lens and fiber-optic [9]. Different types of

endoscopes might be optimal for treatment of different types of disease. The choice of the endoscope must be made considering separate pathologies and the anatomical variations. Visibility, adaptability, and invasiveness of endoscopes vary from type to type; thus, neuroendoscopist must be flexible choosing the endoscope system with consideration of different diseases [10].

### 3.3. Approach

Since the introduction of ETV, many operative techniques have been proposed [11–14]. The main approach to the floor of the third ventricle stays consistent; surgical trajectory is from a frontal burr-hole to the lateral ventricle and foramen of Monro (**Figure 3**) [10]. Anatomical considerations are very important for the success of the procedure. Many authors have studied the endoscopic anatomy of ventricular system [15–17]. Distortion of the ventricles by hydrocephalus can lead to anatomical variations like persistence of the infundibular recess and empty sella. Successful perforation of the ventricular floor is thought to be correlated to the absence of these variations. Neuronavigation and preoperative advanced neuroimaging are powerful tools for understanding these variations and taking precaution for increasing the success rate of the procedure.

The trajectory is almost standard for a typical hydrocephalus patient with enlarged ventricles undergoing ETV for the first time. This trajectory consists of an entry point slightly anterior to the coronal suture and slightly lateral to the midpupillary line. The authors recommend an entry point 3 cm lateral to the midline and 1 cm anterior to the coronal suture. The orientation of the endoscope should be slightly medial and in line with external acoustic meatus in the anterior–posterior direction. This approach that has a trajectory is optimal in a patient with



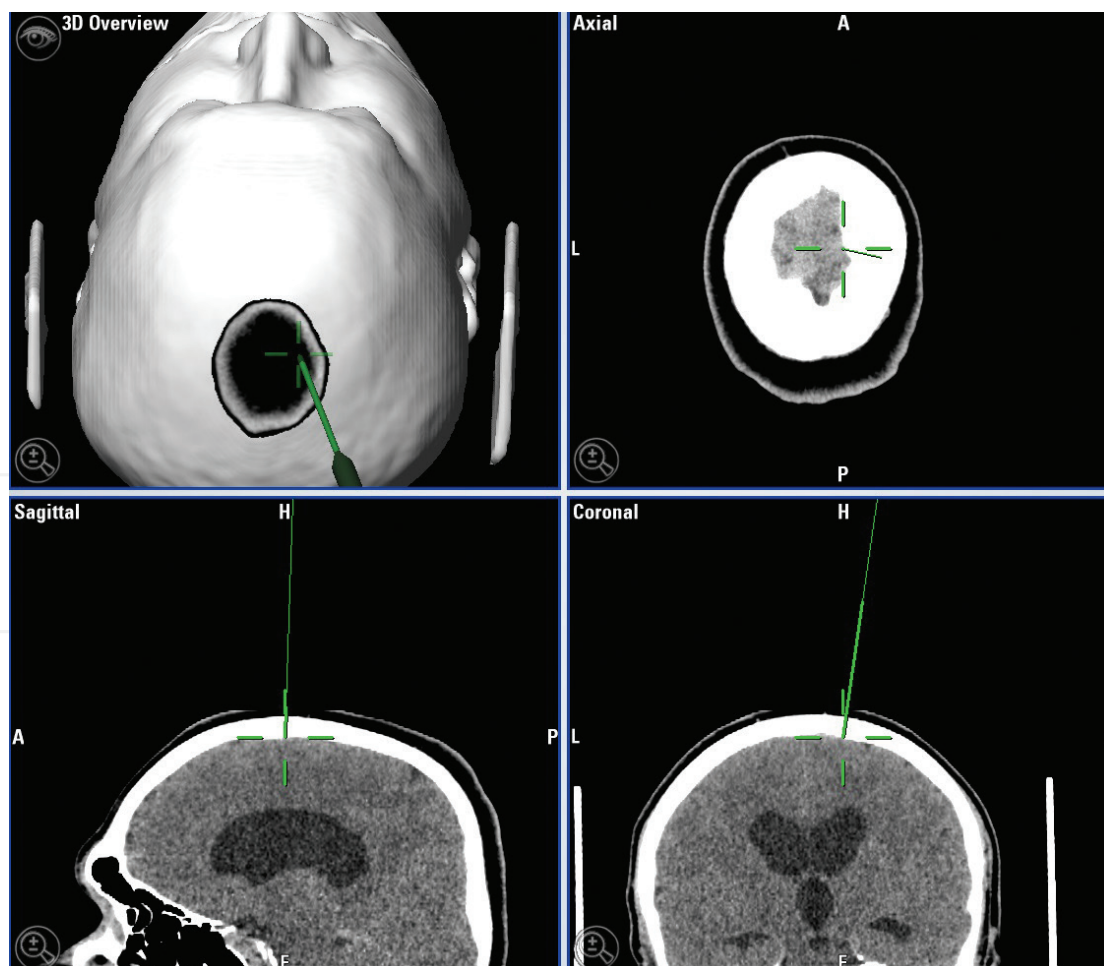
**Figure 3.** Trajectory of the endoscope for the third ventriculostomy.



enlarged ventricles for entering the lateral ventricle, passing the foramen of Monro and reaching the floor of the third ventricle.

In previously operated patients for a shunt with the use of Kocher's point, the existing burr-hole might not be ideal because it will be located more anteriorly. In this situation, a new burr-hole and sometimes a new incision are often recommended for an optimal and safe approach to the third ventricle floor. The orientation of the trajectory still could be changed considering the ventricle size and shape. Examining radiographic features beforehand is always crucial—especially coronal and sagittal sections—and may cause slight changes to the approach. The entry point might be slightly medial in case of ventricles not obviously dilated, for example.

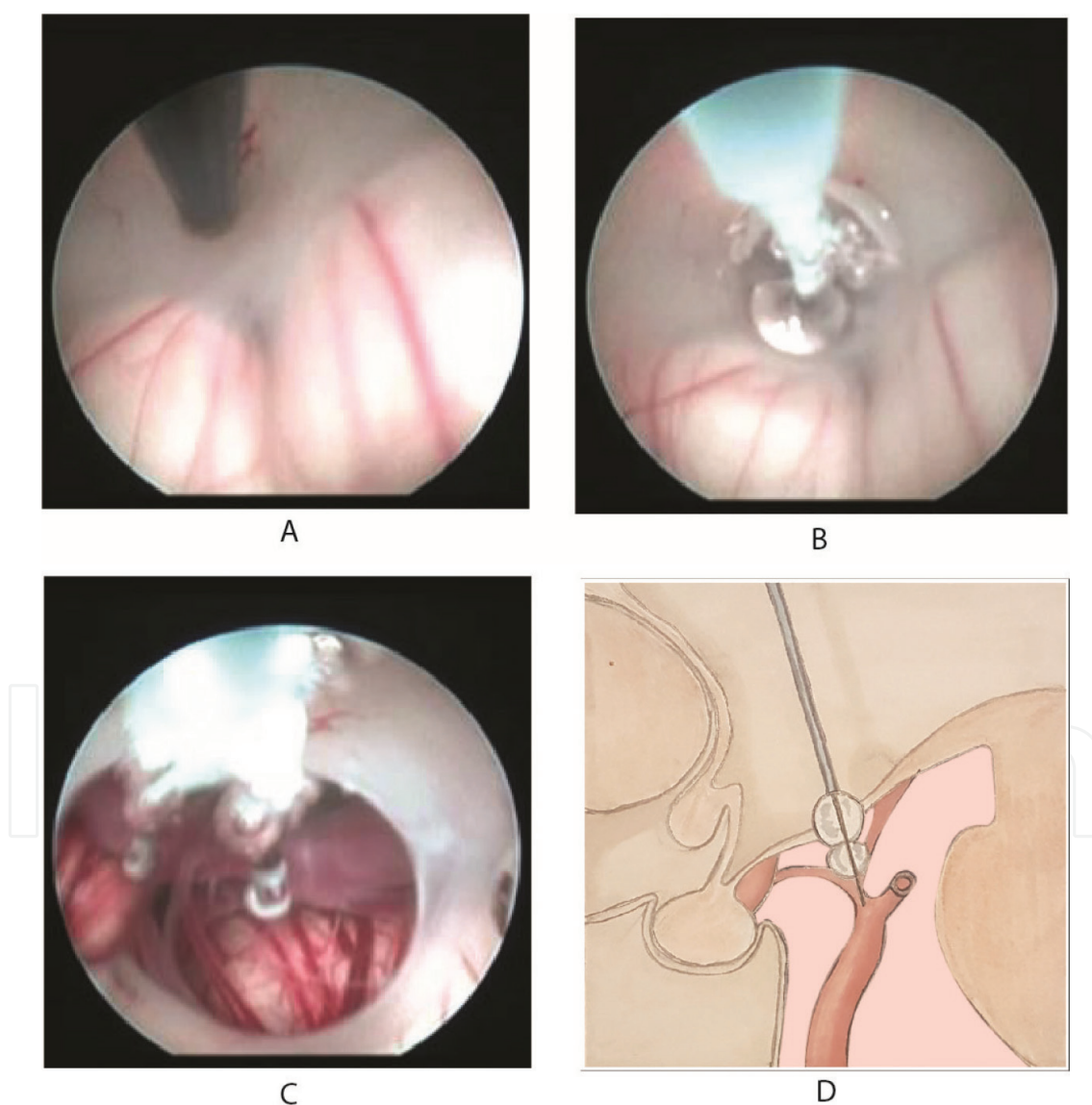
As the stereotactic and neuronavigation system advance, application of these systems became available for ETV [18, 19]. These systems provide planning and executing a precise trajectory for a safe procedure (**Figure 4**). Other than trajectory planning, these systems help the surgeon accurately puncture the safe zone in the floor of the ventricle preventing gross complications as basilar artery or hypothalamic injury. Doppler ultrasound can be applied to ETV with a microprobe for localization of the basilar artery preventing injury [7].



**Figure 4.** Trajectory planning with neuronavigation software.

### 3.4. Fenestration techniques

Balloon dilatation technique is the most widespread technique used for ventriculostomy [10, 20, 21]. In this technique, surgeon opens the floor using a blunt dissector or a blunt monopolar coagulator tip through the working channel of the endoscope. Then, the dissector is drawn, and a Fogarty three-French balloon catheter (might be two-French depending on the working channel diameter of the endoscope) or a specialized NeuroBalloon catheter with two balloon compartments is passed through the initial fenestration. The balloon is slowly inflated inside the fenestration to enlarge the opening (**Figure 5**). Next, the balloon is deflated and pulled back. There are many advantages with this technique: the procedure can be repeated many times safely, the floor of the ventricle and even the prepontine cistern are



**Figure 5.** Endoscopic third ventriculostomy using balloon dilatation. The floor of the third ventricle is perforated with a blunt cauter tip (A), and the NeuroBalloon is passed through the hole and inflated (B). The structures in the prepontine cistern are visible through the fully inflated balloon (C, D).

visualized during with inflation, and balloon inflation can be used as a hemostatic tool in the event of capillary bleeding from the floor. The advancement of the endoscope after fenestration is recommended for visualization of arachnoid strips and Liliequist membrane [10]. These advantages make balloon dilatation the safest technique for fenestration.

A variation of techniques can be used for puncturing the floor of the third ventricle. Perhaps, the most basic technique is performing the fenestration via the tip of the endoscope. Multiple series showed the efficiency of this technique [6, 19]. However, some drawbacks exist for this approach. The endoscope should be small in diameter, vision is obscured during dissection of the floor, and a steep learning curve is present. Many other techniques exist like saline torch and laser energy; however, the safety and efficiency of these techniques are questionable [22].

## 4. Indications

The most common indication for ETV is obstructive hydrocephalus caused by primary aqueductal stenosis. Various authors published many series demonstrating the effectiveness of ETV in aqueductal stenosis patients. The success rate in aqueductal stenosis is reported up to 90%. Thus, ETV is established almost universally as treatment of choice for aqueductal stenosis [6, 23, 24].

Many other obstructive pathologies can be treated with ETV. Although shunting is a treatment option, hydrocephalus caused by lateral ventricle entrapment can be adequately treated with endoscopic septal fenestration combined with ETV [25]. In case of the isolated fourth ventricle, aqueductoplasty with endoscopic approach presents a safe and effective method [26]. This approach seems to be less invasive than microsurgical fenestration and more reliable than the fourth ventricle shunts. Endoscopic third ventriculostomy proved to be effective in the fourth ventricle outlet obstruction without Chiari malformation or visible obstructive mass [27]. These idiopathic stenosis cases are treated successfully with ETV even resolving accompanying pathologies like syringomyelia. Dandy-Walker malformation can also be treated with ETV and a stent between the third ventricle and posterior fossa when accompanied by aqueductal stenosis [28–30]. In complex obstructive syndromes, neuroendoscopy and ETV are frequently used by neurosurgeons.

In case of acute intraventricular hemorrhages, ETV can be used as a replacement for external ventricular drainage. In supratentorial intraventricular hemorrhages, ETV is shown to be useful for relieving acute hydrocephalus in addition to clot aspiration [31]. Although the use of the ETV for supratentorial hemorrhages is controversial, in posterior fossa hemorrhages, ETV is proven to be very effective for the treatment of acute hydrocephalus [32]. In case of obstruction caused by the fourth ventricular or cerebellar hematomas, ETV seems to be an effective and a safe alternative to external ventricular drainage.

Neuroendoscopy offers the possibility to combine ETV and tumor biopsy in selected intraventricular and paraventricular tumors [33–36]. Developing technologies like endoscopic ultrasonic aspirator makes total removal of the tumors possible. Endoscopic third ventriculostomy is even possible for tumors located in the third ventricle floor without any morbidity [37]. Although ETV is an effective treatment for relief of hydrocephalus in intraventricular tumors,



neuroendoscopic approach presents a difficulty when the anatomical landmarks are distorted by the growth of the tumor.

Tectal and pineal tumors presenting with acute hydrocephalus also present an indication for tumor biopsy and ETV [38]. The management of these tumors depending on histology is combined open surgery and radiotherapy or chemotherapy. In the presence of obstructive hydrocephalus, neuroendoscopy presents an opportunity for the long term relieving the hydrocephalus and adequate tumor biopsy for determining the management. Long-term control of hydrocephalus is possible with ETV in tectal plate tumors [39].

In posterior fossa tumors, preoperative hydrocephalus can be managed with external ventricular drainage as well as ETV [40–42]. Postoperative hydrocephalus in posterior fossa tumors presents a major problem in these patients. In posterior fossa tumors, about 36% of patients need a CSF diversion surgery postoperatively [43]. The outcomes of ETV in postoperative hydrocephalus are about as good as shunting; however, failure happens earlier than VP shunts [44]. It is proven that ETV performed prior to surgery reduces significantly the incidence of postoperative hydrocephalus although it does not prevent hydrocephalus in all cases. It does however prevent acute postoperative hydrocephalus due to cerebellar swelling and presents a cleaner and more physiologic method compared to external ventricular drainage [41]. The effectiveness of ETV is also demonstrated in brain stem gliomas causing hydrocephalus [45].

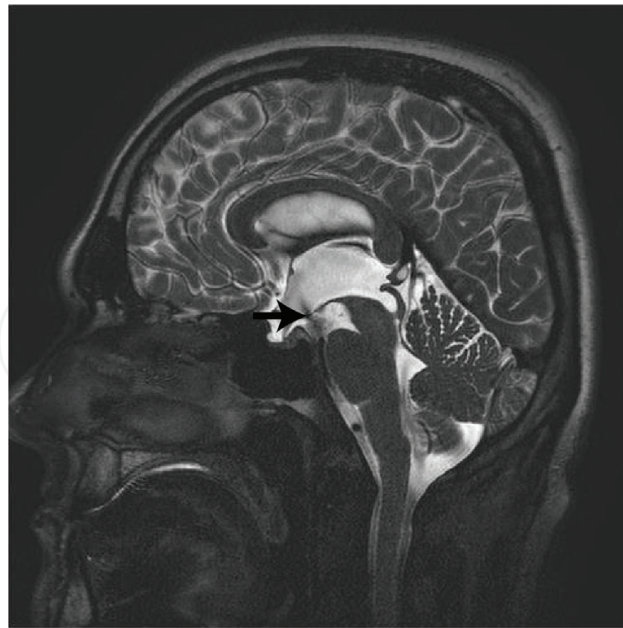The treatment of choice for suprasellar arachnoid cysts is endoscopic fenestration of the cyst into ventricular system combined with ETV (cystoventriculocisternostomy). Several series demonstrated cyst and hydrocephalus regression with this technique [46, 47]. Cystostomy and ETV might also be indicated in some pineal cysts and quadrigeminal cysts presented with hydrocephalus [48, 49].

Contrary to obstructive hydrocephalus, indications of communicating hydrocephalus are controversial [50]. There are successful series of ETV on normal pressure hydrocephalus in literature with improvement rate after ETV up to 69% [51]. However, the etiology of this success is not yet well defined. Some authors argue that the third ventriculostomy relieves periventricular tissue stress improving the perfusion [52].

In patients with Chiari malformation type I with concomitant hydrocephalus, ETV is proven to be beneficial [53]. In these patients relief of symptoms, ascent of the tonsils, regression of hydrocephalus, and syringomyelia are seen after ETV [54, 55]. The established treatment for these patients is suboccipital craniectomy and duraplasty combined with CSF diversion surgery. In these selected cases, ETV proves to be successful meaning that the cure might be achieved in a less invasive and less complicated manner. As for Chiari malformation type II, the overall success for patients with concomitant meningocele and hydrocephalus is up to 72% [56]. In these patients, ETV presents a safe and an effective way to deal with hydrocephalus and long-term shunt independence [57].

## 5. Outcomes

Success rates of EVT vary from 50–90% in literature [52, 58]. Good outcomes are highest with up to about 90% in obstructive hydrocephalus series that includes aqueductal stenosis and



**Figure 6.** Flow void in T2-weighted sagittal MRI is clearly visible in the floor of the third ventricle after an ETV (black arrow).

tumors [23, 52]. However, communicating hydrocephalus cases have a rate of success about 50%. In patients who undergone shunt operations, ETV is still effective eliminating shunt dependency [59, 60]. Infants have worse outcomes in case of ETV according to literature. Failure rates vary between 20 and 50% [61]. Many authors recommend performing ETV in patients 2 years and older with their low success rates in infants [62, 63]. However, some authors indicate that ETV is still worth trying in these patients since the success rate is still considerable and a successful ETV provides long-term shunt independence [64, 65].

Radiographic features might be misleading as ventricular volume after EVD may not show an obvious change in the early preoperative period [66]. Early postoperative improvement and ventricular volume reduction are predictive values for the success of ETV as well as demonstrating flow void in the base of the third ventricle [67]. The patency of the ETV can be shown with flow void in T2-weighted images (**Figure 6**) and also with CSF flow cine MRI. Minor flow in the base of the third ventricle appears to be a bad prognostic factor for the patency of stoma [68].

Failure of ETV is in general due to the closure of fenestration in the third ventricle floor. The causes of the fenestration failure include the insufficient size of initial fenestration, reduced CSF reabsorption, arachnoid membranes in the prepontine cistern, hemorrhage obstructing fenestration, and late gliosis and postoperative infection. Failure rates can be as high as 50% in noncommunicating hydrocephalus series even with patent ventriculostomies [58].

## 6. Complications

The overall complication rate of ETV series is found to be 8.5% by Bouras and Sgouros [69]. The complication rates varied between 0 and 31.2%. Overall permanent morbidity rate was

2.38%, and the mortality rate was found 0.28%. Complications can be categorized as intraoperative, early postoperative, and late postoperative.

Neurovascular injury and bradycardia are the most common intraoperative complications. Various authors reported arterial and venous bleeding during the procedure [59, 63, 70]. Considerable intraoperative bleeding is reported almost 3.7% of the procedures, and about 4.2% of the ETVs is abandoned due to hemorrhage. Many authors reported different rates of intraoperative bleeding. But severe bleeding rates are low as 0.6%, and the rate of the most frightening intraoperative complication of ETV—basilar artery rupture—is as low as 0.2%. Pseudoaneurysm formation in the basilar tip after basilar injury is reported. Bradycardia is reported up to 41% during ETV [71]. A proposed mechanism for bradycardia is the generation of Cushing reflex due to irrigation and stimulation of hypothalamic nuclei. Even cardiac arrest is reported during an ETV performed for posthemorrhagic hydrocephalus [72].

Immediate preoperative complications include postoperative hemorrhagic complications like subdural hematoma, intraventricular hemorrhage, intracerebral hematoma, and epidural hematoma. The total rate of hemorrhagic complications is about 0.81%, and subdural hematoma being the most common hemorrhage [69]. A large corticotomy and sudden drainage of CSF are possible risk factors for development of subdural hematoma. Increased ICP of the subdural space also seems to be the cause of subdural hygromas. Central nervous system infections are one of the severe early postoperative complications. Meningitis or ventriculitis is recorded in 1.81% of the patients. Cerebrospinal fluid leak due to increased subdural pressure from corticotomy is also a postoperative concern as it can lead to CNS infections. Electrolyte and hormonal imbalances are reported in the literature. Systemic complications including syndrome of inappropriate antidiuretic hormone secretion, diabetes insipidus, and secondary amenorrhea are also found to be complications.

The most important late complication is the failure of the ETV. Sudden deterioration and death are reported in the literature, but it occurs rarely [73, 74]. As the risk of epilepsy being very low for this procedure, seizures are still a possible complication developing after ETV. Neurological morbidity is a possibility although rare with a total rate of 1.44%. Memory deficits may occur after ETV, and suggested hypothesis is fornix injury during the procedure. Fornix contusion is reported in ETV patients up to 16.4% [33]. Memory problems can be transient as well as permanent. Other than neuropsychiatric problems, hemiparesis, decreased consciousness, and gaze palsy are some of the rare neurological complications [69].

## 7. Conclusion

Endoscopic third ventriculostomy is a novel treatment for noncommunicating hydrocephalus. Safety and efficiency of the procedure are proven. Indications of ETV are expanding day by day with good results reported for various diseases. Compared to CSF diversion techniques, ETV is preferable for select cases with avoidance of shunt dependency and thus shunt complications.

## Acknowledgements

We wish to acknowledge Dr. Altay Sencer of the Department of Neurosurgery, Istanbul University, Istanbul Faculty of Medicine, Istanbul, for his assistance.

## Conflict of interest

Authors declare that they have no conflict of interest.

## Thanks

We wish to thank Cristina Brinza for her illustrations.

## Author details

Tugrul Cem Unal<sup>1\*</sup> and Aydin Aydoseli<sup>2</sup>

\*Address all correspondence to: [tugrulcem@gmail.com](mailto:tugrulcem@gmail.com)

1 Department of Neurosurgery, Tunceli State Hospital, Tunceli, Turkey

2 Department of Neurosurgery, Istanbul University, Istanbul Faculty of Medicine, Istanbul, Turkey

## References

- [1] Sufianov A, Sufianova G, Iakimov I. Neuroendoscopic procedures in achievement of shunt independence: Outcome analysis of 28 patients with shunt malfunction. *Minimally Invasive Neurosurgery*. 2008;**51**:158-164
- [2] Dandy WE. An operative procedure for hydrocephalus. *Bulletin of the Johns Hopkins Hospital*. 1922;**33**:189-190
- [3] Mixter WJ. Ventriculostomy and puncture of the floor of the third ventricle. *The Boston Medical and Surgical Journal*. 1923;**188**:277-278
- [4] Putnam TJ. Treatment of hydrocephalus by endoscopic coagulation of the choroid plexus. Description of a new instrument and preliminary report of results. *The New England Journal of Medicine*. 1934;**210**:1373-1376
- [5] Scarff JE. Treatment of obstructive hydrocephalus by puncture of the lamina terminalis and floor of the third ventricle. *Journal of Neurosurgery*. 1951;**8**:204-213

- [6] Jones R, Kwok B, Stening W, Vonau M. The current status of endoscopic third ventriculostomy in the management of non-communicating hydrocephalus. *Minimally Invasive Neurosurgery*. 1994;**37**:28-36
- [7] Schmitt PJ, Jane JA. A lesson in history: The evolution of endoscopic third ventriculostomy. *Neurosurgical Focus*. 2012;**33**:E11
- [8] Coulbois S, Boch AL, Philippon J. Diabetes insipidus after endoscopic third ventriculostomy. A case report and review of the literature. *Neuro-Chirurgie*. 2001;**47**:435-438
- [9] Gaab MR. Instrumentation: Endoscopes and equipment. *World Neurosurgery*. 2013;**79**:S14. e11-S14.e210
- [10] Brockmeyer D. Techniques of endoscopic third ventriculostomy. *Neurosurgery Clinics of North America*. 2004:51-59
- [11] Avman N, Kanpolat Y. Third ventriculostomy by microtechnique. *Acta Neurochirurgica Supplementum (Wien)*. 1979;**28**:588-595
- [12] Jaksche H, Loew F. Burr hole third ventriculo-cisternostomy. An unpopular but effective procedure for treatment of certain forms of occlusive hydrocephalus. *Acta Neurochirurgica*. 1986;**79**:48-51
- [13] Brocklehurst G. Trans-callosal third ventriculo-chiasmatic cisternostomy: A new approach to hydrocephalus. *Surgical Neurology*. 1974;**2**:109-114
- [14] Decq P, Schroeder HWS, Fritsch M, Cappabianca P. A history of ventricular neuroendoscopy. *World Neurosurgery*. 2013;**79**:S14.e1-S14.e6
- [15] Morota N, Watabe T, Inukai T, Hongo K, Nakagawa H. Anatomical variants in the floor of the third ventricle; implications for endoscopic third ventriculostomy. *Journal of Neurology, Neurosurgery, and Psychiatry*. 2000;**69**:531-534
- [16] Decq P. Endoscopic ventricular anatomy. *Morphologie*. 2005:12-21
- [17] Pavez A, Salazar C, Rivera R, Contreras J, Orellana A, Guzman C, et al. Description of endoscopic ventricular anatomy in myelomeningocele. *Minimally Invasive Neurosurgery*. 2006;**49**:161-167
- [18] Alberti O, Riegel T, Hellwig D, Bertalanffy H. Frameless navigation and endoscopy. *Journal of Neurosurgery*. 2001;**95**:541-543
- [19] Goodman RR. Magnetic resonance imaging-directed stereotactic endoscopic third ventriculostomy. *Neurosurgery*. 1993;**32**:1043-1047
- [20] Kehler U, Gliemroth J, Knopp U, Arnold H. How to perforate safely a resistant floor of the 3rd ventricle? Technical note. *Minimally Invasive Neurosurgery*. 1998;**41**:198-199
- [21] Goumnerova LC, Frim DM. Treatment of hydrocephalus with third ventriculocisternostomy: Outcome and CSF flow patterns. *Pediatric Neurosurgery*. 1997;**27**:149-152



- [22] Vandertop PW. Traumatic basilar aneurysm after endoscopic third ventriculostomy: Case report. *Neurosurgery*. 1998;**43**:647-648
- [23] Gangemi M, Donati P, Maiuri F, Longatti P, Godano U, Mascari C. Endoscopic third ventriculostomy for hydrocephalus. *Minimally Invasive Neurosurgery*. 1999;**42**:128-132
- [24] Grunert P, Charalampaki P, Hopf N, Filippi R. The role of third ventriculostomy in the management of obstructive hydrocephalus. *Minimally Invasive Neurosurgery*. 2003;**46**:16-21
- [25] Aldana PR, Kestle JRW, Brockmeyer DL, Walker ML. Results of endoscopic septal fenestration in the treatment of isolated ventricular hydrocephalus. *Pediatric Neurosurgery*. 2003;**38**:286-294
- [26] Fritsch MJ, Kienke S, Manwaring KH, Mehdorn HM. Endoscopic aqueductoplasty and interventriculostomy for the treatment of isolated fourth ventricle in children. *Neurosurgery*. 2004;**55**:372-379
- [27] Mohanty A, Anandh B, Sastry Kolluri V, Praharaj S. Neuroendoscopic third ventriculostomy in the management of fourth ventricular outlet obstruction. *Minimally Invasive Neurosurgery*. 1999;**42**:18-21
- [28] Mohanty A. Endoscopic third ventriculostomy with cystoventricular stent placement in the management of dandy-walker malformation: Technical case report of three patients. *Neurosurgery*. 2003;**53**:1223-1229
- [29] Cartmill M, Jaspan T, McConachie N, Vloeberghs M. Neuroendoscopic third ventriculostomy in dysmorphic brains. *Child's Nervous System*. 2001;**17**:391-394
- [30] Warf BC, Dewan M, Mugamba J. Management of Dandy-Walker complex-associated infant hydrocephalus by combined endoscopic third ventriculostomy and choroid plexus cauterization. *Journal of Neurosurgery. Pediatrics*. 2011;**8**:377-383
- [31] Fuentes S, Metellus P, Dufour H, Bruder N, Do L, N'Doye N, et al. Endoscopic third ventriculostomy for management of obstructive hydrocephalus secondary to supratentorial intraventricular hematoma. Case report. *Neuro-Chirurgie*. 2002;**48**:510-515
- [32] Roux F-E, Boetto S, Tremoulet M. Third ventriculocisternostomy in cerebellar haematomas. *Acta Neurochirurgica*. 2002;**144**:337-342
- [33] Oertel J, Linsler S, Emmerich C, Keiner D, Gaab M, Schroeder H, et al. Results of combined intraventricular neuroendoscopic procedures in 130 cases with special focus on fornix contusions. *World Neurosurgery*. 2017;**108**:817-825
- [34] Beems T, Grotenhuis JA. Long-term complications and definition of failure of neuroendoscopic procedures. *Child's Nervous System*. 2004;**20**:868-877
- [35] Gaab MR, Schroeder HW. Neuroendoscopic approach to intraventricular lesions. *Neurosurgical Focus*. 1999;**6**:e5

- [36] Yurtseven T, Erşahin Y, Demirtaş E, Mutluer S. Neuroendoscopic biopsy for intraventricular tumors. *Minimally Invasive Neurosurgery*. 2003;**46**:293-299
- [37] Husain M, Jha D, Thaman D, Husain N, Gupta RK. Ventriculostomy in a tumor involving the third ventricular floor. *Neurosurgical Review*. 2004;**27**:70-72
- [38] Mottolese C, Szathamari A, Beuriat PA, Grassiot B, Simon E. Neuroendoscopy and pineal tumors: A review of the literature and our considerations regarding its utility. *Neuro-Chirurgie*. 2015;**61**:155-159
- [39] Romeo A, Naftel RP, Griessenauer CJ, Reed GT, Martin R, Shannon CN, et al. Long-term change in ventricular size following endoscopic third ventriculostomy for hydrocephalus due to tectal plate gliomas. *Journal of Neurosurgery. Pediatrics*. 2013;**11**:20-25
- [40] Azab W, Al-sheikh T, Yahia A. Preoperative endoscopic third ventriculostomy in children with posterior fossa tumors: An institution experience. *Turkish Neurosurgery*. 2012;**23**:359-365
- [41] Ruggiero C, Cinalli G, Spennato P, Aliberti F, Cianciulli E, Trischitta V, et al. Endoscopic third ventriculostomy in the treatment of hydrocephalus in posterior fossa tumors in children. *Child's Nervous System*. 2004;**20**:828-833
- [42] Di Rocco F, Jucá CE, Zerah M, Sainte-Rose C. Endoscopic third ventriculostomy and posterior fossa tumors. *World Neurosurgery*. 2013;**79**:S18.e15-S18.e19
- [43] Culley DJ, Berger MS, Shaw D, Geyer R. An analysis of factors determining the need for ventriculoperitoneal shunts after posterior fossa tumor surgery in children. *Neurosurgery*. 1994;**34**:402-408
- [44] Dewan MC, Lim J, Shannon CN, Wellons JC. The durability of endoscopic third ventriculostomy and ventriculoperitoneal shunts in children with hydrocephalus following posterior fossa tumor resection: A systematic review and time-to-failure analysis. *Journal of Neurosurgery. Pediatrics*. 2017;**19**:578-584
- [45] Kobayashi N, Ogiwara H. Endoscopic third ventriculostomy for hydrocephalus in brainstem glioma: A case series. *Child's Nervous System*. 2016;**32**:1251-1255
- [46] Ogiwara H, Morota N, Joko M, Hirota K. Endoscopic fenestrations for suprasellar arachnoid cysts. *Journal of Neurosurgery. Pediatrics*. 2011;**8**:484-488
- [47] Rizk E, Chern JJ, Tagayun C, Tubbs RS, Hankinson T, Rozzelle C, et al. Institutional experience of endoscopic suprasellar arachnoid cyst fenestration. *Child's Nervous System*. 2013;**29**:1345-1347
- [48] Gangemi M, Maiuri F, Colella G, Magro F. Endoscopic treatment of quadrigeminal cistern arachnoid cysts. *Minimally Invasive Neurosurgery*. 2005;**48**:289-292
- [49] Berhouma M, Ni H, Delabar V, Tahhan N, Memou Salem S, Mottolese C, et al. Update on the management of pineal cysts: Case series and a review of the literature. *Neuro-Chirurgie*. 2015;**61**:201-207

- [50] Tudor KI, Tudor M, McCleery J, Car J. Endoscopic third ventriculostomy (ETV) for idiopathic normal pressure hydrocephalus (iNPH). In: Tudor M, editor. *Cochrane Database of Systematic Reviews*. Chichester, UK: John Wiley & Sons, Ltd; 2015. (7). p. CD010033
- [51] Gangemi M, Maiuri F, Naddeo M, Godano U, Mascari C, Broggi G, et al. Endoscopic third ventriculostomy in idiopathic normal pressure hydrocephalus. *Neurosurgery*. 2008;**63**:62-69
- [52] Hellwig D, Grotenhuis JA, Tirakotai W, Riegel T, Schulte DM, Bauer BL, et al. Endoscopic third ventriculostomy for obstructive hydrocephalus. *Neurosurgical Review*. 2004;**28**:1-38
- [53] Wu Y, Li C, Zong X, Wang X, Gui S, Gu C, et al. Application of endoscopic third ventriculostomy for treating hydrocephalus-correlated Chiari type I malformation in a single Chinese neurosurgery centre. *Neurosurgical Review*. 2017;**1**:249-254
- [54] Métellus P, Dufour H, Levrier O, Grisoli F. Endoscopic third ventriculostomy for treatment of noncommunicating syringomyelia associated with a Chiari I malformation and hydrocephalus: Case report and pathophysiological considerations. *Neurosurgery*. 2002;**51**:500-504
- [55] Decq P, Le Guérinel C, Sol J-C, Brugières P, Djindjian M, Nguyen J-P. Chiari I malformation: A rare cause of noncommunicating hydrocephalus treated by third ventriculostomy. *Journal of Neurosurgery*. 2001;**95**:783-790
- [56] Teo C, Jones R. Management of hydrocephalus by endoscopic third ventriculostomy in patients with myelomeningocele. *Pediatric Neurosurgery*. 1996;**25**:57-63 discussion 63
- [57] Rei J, Pereira J, Reis C, Salvador S, Vaz R. Endoscopic third ventriculostomy for the treatment of hydrocephalus in a pediatric population with myelomeningocele. *World Neurosurgery*. 2017;**105**:163-169
- [58] Tisell M, Almström O, Stephensen H, Tullberg M, Wikkelsö C. How effective is endoscopic third ventriculostomy in treating adult hydrocephalus caused by primary aqueductal stenosis? *Neurosurgery*. 2000;**46**:104-111
- [59] Hopf NJ, Grunert P, Fries G, Resch KD, Perneczky A. Endoscopic third ventriculostomy: Outcome analysis of 100 consecutive procedures. *Neurosurgery*. 1999;**44**:795-806
- [60] Cinalli G, Salazar C, Mallucci C, Yada JZ, Zerah M, Sainte-Rose C. The role of endoscopic third ventriculostomy in the management of shunt malfunction. *Neurosurgery*. 1998;**43**:1323-1329
- [61] Kulkarni AV, Riva-Cambrin J, Holubkov R, Browd SR, Cochrane DD, Drake JM, et al. Endoscopic third ventriculostomy in children: Prospective, multicenter results from the hydrocephalus clinical research network. *Journal of Neurosurgery. Pediatrics*. 2016;**18**:423-429
- [62] Drake JM, Canadian Pediatric Neurosurgery Study Group. Endoscopic third Ventriculostomy in pediatric patients: The Canadian experience. *Neurosurgery*. 2007;**60**:881-886

- [63] Kadrian D, van Gelder J, Florida D, Jones R, Vonau M, Teo C, et al. Long-term reliability of endoscopic third ventriculostomy. *Neurosurgery*. 2008;**62**:1271-1278
- [64] Alvarez JA, Cohen AR. Neonatal applications of neuroendoscopy. *Neurosurgery Clinics of North America*. 1998;**9**:405-413
- [65] Buxton N, Macarthur D, Mallucci C, Punt J, Vloeberghs M. Neuroendoscopic third ventriculostomy in patients less than 1 year old. *Pediatric Neurosurgery*. 1998;**29**:73-76
- [66] Schwartz T, Yoon S, Cutruzzola F, Goodman R. Third ventriculostomy: Post-operative ventricular size and outcome. *Minimally Invasive Neurosurgery*. 1996;**39**:122-129
- [67] Kulkarni AV, Drake JM, Armstrong DC, Dirks PB. Imaging correlates of successful endoscopic third ventriculostomy. *Journal of Neurosurgery*. 2000;**92**:915-919
- [68] Fukuhara T, Luciano MG, Kowalski RJ. Clinical features of third ventriculostomy failures classified by fenestration patency. *Surgical Neurology*. 2002;**58**:102-110
- [69] Bouras T, Sgouros S. Complications of endoscopic third ventriculostomy. *Journal of Neurosurgery. Pediatrics*. 2011;**7**:643-649
- [70] Egger D, Balmer B, Altermatt S, Meuli M. Third ventriculostomy in a single pediatric surgical unit. *Child's Nervous System*. 2010;**26**:93-99
- [71] El-Dawlatly AA, Murshid WR, Elshimy A, Magboul MA, Samarkandi A, Takrouri MS. The incidence of bradycardia during endoscopic third ventriculostomy. *Anesthesia and Analgesia*. 2000;**91**:1142-1144
- [72] Handler MH, Abbott R, Lee M. A near-fatal complication of endoscopic third ventriculostomy: Case report. *Neurosurgery*. 1994;**35**:525-528
- [73] Lipina R, Palecek T, Reguli S, Kovarova M. Death in consequence of late failure of endoscopic third ventriculostomy. *Child's Nervous System*. 2007;**23**:815-819
- [74] Javadpour M, May P, Mallucci C. Sudden death secondary to delayed closure of endoscopic third ventriculostomy. *British Journal of Neurosurgery*. 2003;**17**:266-269