

We are IntechOpen, the world's leading publisher of Open Access books Built by scientists, for scientists

6,900

Open access books available

186,000

International authors and editors

200M

Downloads

Our authors are among the

154

Countries delivered to

TOP 1%

most cited scientists

12.2%

Contributors from top 500 universities



WEB OF SCIENCE™

Selection of our books indexed in the Book Citation Index
in Web of Science™ Core Collection (BKCI)

Interested in publishing with us?
Contact book.department@intechopen.com

Numbers displayed above are based on latest data collected.
For more information visit www.intechopen.com



Intestinal Transplantation

Georgios Vrakas

Additional information is available at the end of the chapter

<http://dx.doi.org/10.5772/intechopen.74825>

Abstract

Intestinal transplantation (ITx) has evolved in the past few decades moving from an experimental procedure to a life-changing modality for patients suffering from intestinal failure (IF). It is particularly for those with complications as a consequence of parenteral nutrition and/or who have a high risk of dying due to their underlying disease. In addition to this, intestinal transplantation is also increasingly considered for the treatment of conventionally unresectable abdominal tumors. With advancements in immunosuppressive drugs, induction regimens, standardization of surgical techniques and improved postoperative care, survival is increasing. The ultimate goal for intestinal transplantation would be to become as good and safe as total parenteral nutrition (TPN) and as such, it could become a viable first-line option of intestinal failure.

Keywords: intestinal failure, parenteral nutrition, multivisceral, intestine, liver, immunosuppression, intestinal transplant

1. History

Lillehei was the first to report an experimental isolated intestinal canine model in 1959 and Starzl reported the first multivisceral experimental canine model in 1960 [1, 2]. The first attempt in humans has been attributed to Deterling in Boston in 1964 [unpublished], whereas the first official report of human intestinal transplant was made by Lillehei in 1967 [1]. It should be noted that the first successful series were reported in the 1990s, coinciding with the introduction of more effective immunosuppression. The first attempts of intestinal transplantation (ITx) in the 1970s were largely disappointing because of high incidence of rejection of small bowel allografts, sepsis and technical complications [3]. The introduction of tacrolimus [4] revolutionized interest in ITx. The superior clinical outcomes from tacrolimus across a

variety of organ transplantation compared with cyclosporine set the momentum for ITx as a life-changing therapy for patients with irreversible intestinal failure (IF) [5, 6].

Over the past 30 years, there has been a gradual increase in ITx cases, with nearly 2900 ITx cases performed worldwide, although there has been a decline in recent years [7]. This change could be attributed to the formation of specialized IF units to prevent and manage intestinal failure-associated liver disease (IFALD) [8]. Other possible factors include: inadequate reimbursement rates below the cost of performing the transplant; the extensive infrastructure demands required to address the frequent social problems of IF patients; concern over the narrow risk-benefit ratio for ITx in an era of improving outcomes with long-term total parenteral nutrition (TPN) for selected diseases [9] and/or the limited availability of experienced personnel to fill key positions. Finally, some transplant centers may be more willing to judiciously offer isolated liver transplants to patients with the short bowel syndrome and IFALD who have the potential for further intestinal adaptation [10, 11].

2. Indications

IF is characterized by the inability to maintain protein energy, fluid, electrolyte or micronutrient balance due to gastrointestinal disease. If the patient does not receive parenteral nutrition or become a recipient of an intestinal transplant, IF ultimately leads to malnutrition and even death.

The leading causes of IF differ between pediatric and adult populations (**Table 1**).

TPN is the current standard of care for patients with IF. Nevertheless, as survival following ITx improves, it is anticipated that ITx will become a valid alternative to total parental nutrition. However, because of significant complications that can arise from surgery and long-term use of immunosuppressive therapy, strict eligibility criteria exist to ensure appropriate patient selection.

Paediatric	Adult
Intestinal atresia	Crohn’s disease
Gastroschisis	Superior mesenteric artery thrombosis
Crohn’s disease	Superior mesenteric vein thrombosis
Microvillus involution disease	Trauma
Necrotizing enterocolitis	Desmoid tumour
Midgut volvulus	Volvulus
Chronic intestinal pseudo-obstruction	Pseudo-obstruction
Massive resection secondary to tumour	Massive resection secondary to tumour
Hirschsprung disease	Radiation enteritis

Table 1. Leading causes for intestinal transplantation in paediatric and adult populations.

Short bowel syndrome caused by surgical removal is the leading cause of IF (68%). As an early alternative to transplantation or total parenteral nutrition (TPN) for patients with short bowel syndrome, surgical bowel lengthening without transplant may be attempted. This requires the serial transverse enteroplasty (STEP) or longitudinal intestinal lengthening and tailoring (LILT) procedures. STEP and LILT are particularly successful in patients with decreased transit times and dilated bowel. These procedures lengthen the small bowel while keeping the total surface area the same. Bowel is either split lengthwise or cut obliquely at multiple points. This will lengthen the bowel and shrink the luminal diameter [12]. If successful, this may reduce the amount of TPN required, or negate its use altogether. If patients are not acceptable candidates for STEP or LILT, sometimes a reversal of small bowel direction may effectively increase transit times. If none of these operations are successful, the standard of care is TPN.

Currently, ITx has been mainly performed in patients who developed life-threatening complications attributed to IF and/or long-term TPN. In 2000, Medicare defined failure of TPN as impending or overt liver failure (elevated serum bilirubin and/or liver enzymes, splenomegaly, thrombocytopenia, gastroesophageal varices, coagulopathy, stomal bleeding, hepatic fibrosis or cirrhosis), thrombosis of two or more central veins, frequent and severe central venous catheter (CVC)-related sepsis and frequent severe dehydration [13]. In addition, other conditions associated with early death despite optimal TPN, such as congenital mucosal disorders and ultra-short bowel syndrome, are also included as per American Society of Transplantation guidelines [14].

The European guidelines recommend TPN as primary treatment for patients with IF, with early referral to specialist centers for optimal rehabilitative therapy and timely assessment of suitability for ITx. It recommends assessment for candidacy for transplantation for the presence of one or more indications parallel to American guidelines (failure of TPN, high risk of death attributable to underlying disease and IF with high morbidity or low acceptance of TPN) resulting in rates of transplant of 62, 26 and 12%, respectively [15]. Because of a statistically significant increased risk of death on TPN from liver failure due to IFALD and invasive intra-abdominal desmoids, direct referral for ITx should be considered [16]. IFALD is partly caused by omega-6 fatty acids in TPN formulas, which can be synthesized into inflammatory molecules. IFALD can range from steatohepatitis, cholestasis or hepatic fibrosis to end-stage liver disease. Children are more likely to have cholestatic liver disease than steatohepatitis [17]. Severe liver injury has been reported in as many as 50% of patients with IF who receive TPN for longer than 5 years; this is typically fatal. If patients have life-threatening infections, IFALD, or lose their venous access, 1-year mortality is 70% without ITx [18]. Conversely, patients with CVC-related complications or ultra-short bowel syndrome did not have an increased risk of death on TPN and no patients considered to be an ITx candidate with poor quality of life (QoL) or chronic dehydration actually died while remaining on TPN. This notable finding forms the basis of non-indications in previous European guidelines [19]. Despite very limited evidence exploring the role of quality of life (QoL) as an indicator for ITx, this holistic aspect may also be factored in the decision-making process [20] (**Table 2**).

North America	Europe
Failure of TPN	Impending or overt liver failure due to IFALD-related liver failure
Impending or overt liver failure	
Central venous thrombosis of 2 central veins	
Frequent and severe central venous catheter-related sepsis	
Frequent episodes of severe dehydration despite intravenous fluids in addition to TPN	
High risk of death attributable to underlying disease	CVC-related multiple venous thrombosis (in appropriately selected patients)
Intra-abdominal invasive desmoids tumour	Intra-abdominal desmoids
Intestinal failure with high morbidity and low acceptance of TPN	Individual case by case decision for patients with IF with high morbidity or low acceptance of TPN
Congenital mucosal disorders	
Ultra-short bowel syndrome (<10 cm in infants, <20 cm in adults)	
Need for frequent hospitalization, narcotic addiction or inability to function	
Patient's unwillingness to accept long-term TPN	

Table 2. Intestinal transplantation guidelines.

3. Contraindications

The contraindications of intestinal transplantation are the same as for all other transplants and are frequently reassessed. These include:

1. significant comorbidities;
2. active uncontrolled infections or malignancies that are not totally resectable during the transplant process;
3. psychosocial factors (e.g. lack of post-operative support network);
4. anatomical challenges that can prove the operation high risk such as inferior vena cava (IVC) and portal vein (PV) thrombosis. Previous laparotomies can also complicate the operation significantly; and
5. opiate dependence is very common and rehabilitation should be considered early.

4. Types of intestinal transplant

The choice of transplant type depends on the underlying cause of IF, quality of native organs, state of liver disease (if present) and history of previous abdominal surgeries. The main types of ITx are:

1. Small bowel transplant only (SBTx) (**Figure 1**): recommended for people with IF who have not developed liver disease. The arterial supply to the allograft is secured with anastomosis between the donor's superior mesenteric artery (SMA) and the recipient's infrarenal aorta; venous drainage is either onto the IVC or the recipient's portal vein (PV) or superior mesenteric vein (SMV) at the root of the mesentery.
2. Liver and small bowel transplant (SBLTx) (**Figure 2**): recommended for people with IF who also have advanced liver disease and extensive portomesenteric venous thrombosis precluding liver transplantation alone. The inclusion of a liver graft in combined liver-small bowel transplant has been associated with improved survival rates [21].
3. Multivisceral transplant (MVTx) (**Figure 3**): recommended for people with multiple organ failure and involves transplanting the stomach, pancreaticoduodenal complex, liver and small bowel.
4. Modified multivisceral transplant (MMVTx) (**Figure 4**): recommended for people with multiple organ failure and involves transplanting the stomach, pancreaticoduodenal complex and small bowel. The difference with the previous type is the exclusion of the liver. It is usually performed in patients with preserved liver function and coexisting pancreatic insufficiency such as patients with chronic pancreatitis, type I diabetes mellitus or cystic fibrosis, patients with intestinal dysmotility with concomitant severe gastroparesis and in cases with tumor involvement of the mesentery or the duodenum (e.g. in Gardner's syndrome) [22].

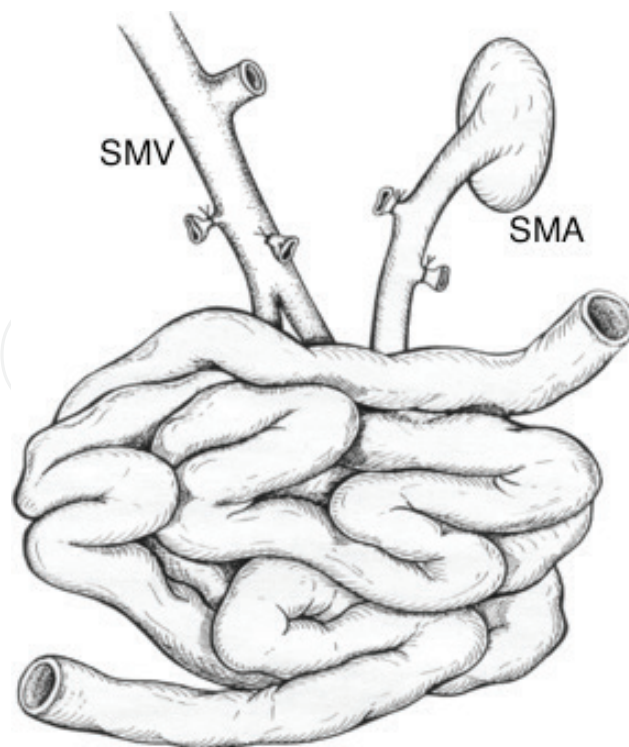


Figure 1. Small bowel transplant (SBTx).

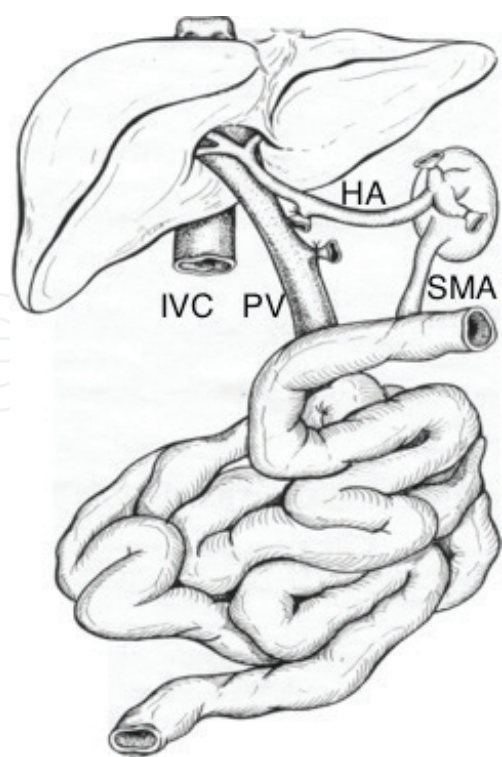


Figure 2. Liver and small bowel transplant (SBLTx).

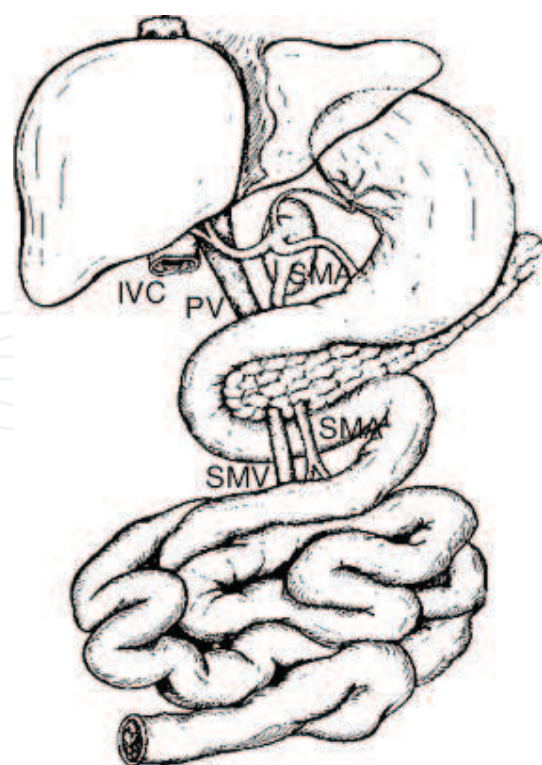


Figure 3. Multivisceral transplant (MVTx).

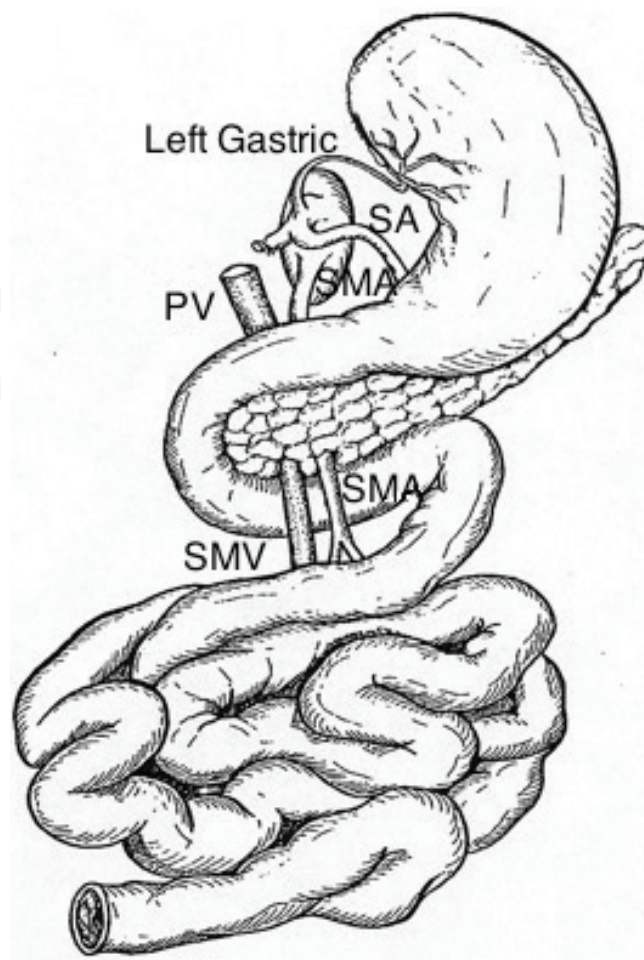


Figure 4. Modified multivisceral transplant (MMVTx).

In all the above ITx types, the right hemicolon can be included depending on the patient's native anatomy. Since 2000, there has been a sixfold increase in the inclusion of a colon segment resulting in a current inclusion rate of 30% [7]. The registry analysis has shown that inclusion of the colon did not adversely affect survival and recipients with a colon segment had a 5% higher rate of independence from supplemental parenteral nutrition (PN), as the retention of the ileocecal valve and the right colon enhance gut function through better fluid absorption and uptake of free fatty acids [23].

It's sometimes possible to carry out a small bowel transplant using a section of bowel donated by a living family member and the first standardized technique was reported by Gruessner and Sharp [24].

Because of previous surgery resulting in loss of abdominal wall domain and integrity, patients undergoing ITx face a problem with primary abdominal wall closure [25]. Surgical techniques such as reduction of the liver portion (left or right lobe) within the composite allograft [26], transplantation of composite abdominal wall tissue graft (**Figure 5**) [27, 28], the use of vascularized rectus sheath [29] and non-vascularized abdominal rectus fascia [30] have revolutionized abdominal wall reconstruction.

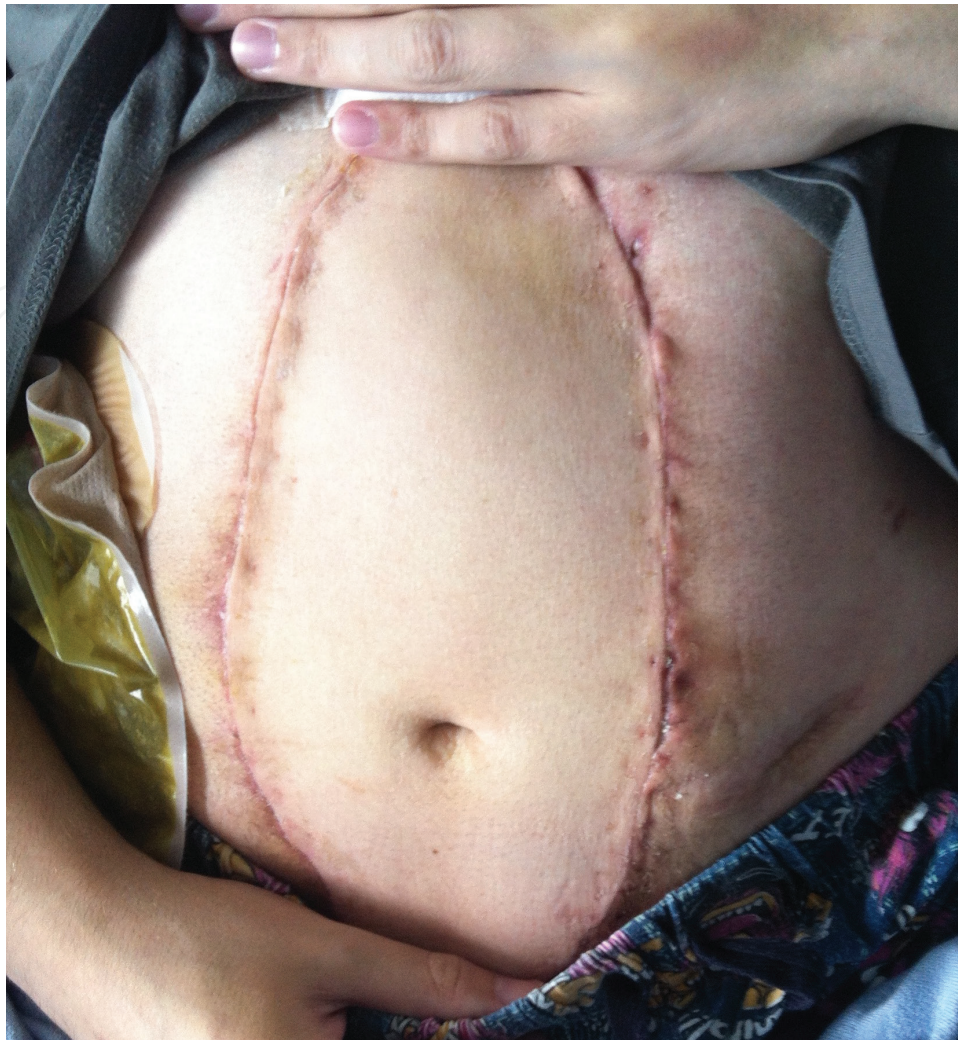

Figure 5. Abdominal wall transplant.

5. Recipient assessment

The assessment of a potential intestinal transplant recipient is robust and rigorous and needs to be done by a multidisciplinary team. This involves transplant surgery, gastroenterology, nutritional services, anesthesia, psychiatry and social work. However, due to the frequently pre-existing multiple comorbidities, consultation with other specialties may be required. Every assessment is 'tailor-made'.

Laboratory studies always include: full blood count (FBC), electrolytes and renal function, coagulation profile, ABO blood group, human leukocyte antigen (HLA) typing, panel-reactive antibody status, HIV and hepatitis B and C virus screening, cytomegalovirus (CMV) and Epstein-Barr virus (EBV) screening.

Liver biopsy is indicated, if liver disease is suspected. The native intestine should be assessed both by imaging and endoscopy.

Vascular access is of utmost importance and is assessed by magnetic resonance or computed tomography venogram. Securing upper-body vascular access is mandatory in cases where IVC occlusion is anticipated. Many patients will have central venous stenosis or obstruction and will mandate interventional radiology and/or vascular reconstruction before listing.

Manometry of the esophagus, stomach and rectum should be considered in patients with dysmotility disorders.

While on the waiting list, patients should be frequently reassessed, with specific attention given to any change in medical status, deterioration in liver function or vascular access.

6. Surgical technique

6.1. Intestinal retrieval

- Wide access to the abdominal cavity is needed and can be achieved via a midline incision from the suprasternal notch down to the symphysis pubis.
- The ascending colon and hepatic flexure are mobilized by using right-sided medial visceral rotation (Cattel-Braasch maneuver) that will expose the third and fourth portions of the duodenum.
- First, achieve control of the right common iliac artery or the distal abdominal aorta, which need to be mobilized for subsequent insertion of the infusion cannula.
- The structures of the hepatoduodenal ligament will have to be identified and slung for small bowel alone or modified multivisceral transplants.
- Depending on the type of transplant, sling the esophagus, the antrum or proximal jejunum.
- In case of MMVTx, the celiac axis has to be retrieved along with the left gastric and splenic arteries. This should be discussed with the liver implanting team in case of a left aberrant artery.
- Transect the gastrocolic ligament and, in case of large bowel retrieval, identify the middle colic vessels. Mark the transverse colon just distal to the vessels for the insertion of the gastrointestinal anastomosis (GIA) stapler. For small bowel, sling the ileum near the ileocecal valve.
- Expose the mesenteric root, abdominal aorta and infrahepatic IVC, including entry of the renal veins.
- If the pancreas is to be retrieved, the splenic flexure, spleen, and body and tail of pancreas are mobilized to allow adequate subsequent cooling of the pancreas.
- Perform proximal control for supraceliac cross-clamping, either above or below the diaphragm, depending on the presence of a cardiothoracic team.

- Cross-clamping of the supraceliac aorta is performed simultaneously with or immediately following venting of the IVC or atrium and cold perfusion is commenced.
- In situ cooling of abdominal organs, and exsanguination before removing the organs to the back table for preparation.
- University of Wisconsin (UW) Universal Organ Preservation solution for both in situ flushing and cold storage is most frequently used.
- Retrieve iliac, brachiocephalic and/or carotid arteries and veins as potential vascular grafts.

6.2. Back-table preparation of organs

Intestinal grafts require minimal back table; however, this depends on the retrieval technique and the extension of the allograft. Most commonly, back table involves to identify and tie the lymphatics. If the pancreas is retrieved along with a small bowel only graft, then it has to be removed/sacrificed on the back table.

6.3. Recipient operation

- Implantation begins commonly with adhesiolysis, as adhesions are usually abundant secondary to previous surgeries.
- Depending on the type of transplant, the aorta and IVC or SMA and SMV/PV are dissected and mobilized for the vascular anastomosis.
- The proximal and distal ends of the native digestive track are identified and dissected.
- Venous anastomosis to the graft is frequently performed to the recipient cava. However, when possible, venous anastomosis to the portal system is preferred.
- Arterial anastomosis is performed to the abdominal aorta via arterial jump graft.
- After reperfusion of the graft and careful hemostasis, the proximal and distal ends of the intestinal graft are anastomosed to the proximal and distal ends of the native digestive track. In some cases, the distal end is brought out as a permanent stoma.
- Most centers bring out a temporary stoma by utilizing various techniques (e.g. Bishop Koop), for post-operative endoscopic surveillance. This stoma is usually reversed in 6–12 months.
- Closure of the abdominal wall can be very challenging and should not be attempted under tension; if this is the case, keeping the abdominal wall open and planning for a sequential closing is preferable. Some centers are routinely performing abdominal wall transplantation from the same deceased donor in order to achieve closure.

7. Postoperative considerations

Patients are monitored in intensive therapy unit (ITU) post-operatively. It is common practice to administer broad-spectrum intravenous antibiotics and antifungals for 5–7 days post transplantation. Blood tests are sent daily and as well as arterial/venous blood gases to check bleeding and homeostasis.

Stoma output is monitored daily and will indicate the appropriate timing to resume enteral feeding via nasogastric tube or jejunostomy/gastrostomy. Some centers start elemental enteral feeding very early and gradually increase volumes depending on nasogastric tube aspirates. TPN is maintained for at least 2 weeks and can be discontinued once enteral nutrition is sufficient. Chyle leak can often be seen post-operatively due to the severed intestinal graft lymphatics. A no-fat or low-fat diet (<10 g/day) can be initiated as a first measure. Absorption of long-chain triglycerides, depends on lymphatic drainage, whereas medium-chain triglycerides are directly absorbed into the portal circulation.

Antiviral prophylaxis with intravenous ganciclovir (5 mg/kg OD) is common practice and regular CMV polymerase chain reaction (PCR) DNA tests are sent for monitoring. Oral valganciclovir is usually prescribed for 1-year post transplantation (900 mg OD). Epstein-Barr virus (EBV) is also monitored regularly by PCR. Trimethoprim-sulfamethoxazole is commonly used to prevent pneumocystis pneumonia for 1-year post operatively. Routine cultures are sent from all lines and most centers perform regular intestinal transplant endoscopies and biopsies via the stoma.

Oral medication is generally avoided in the early phase due to the unpredictable absorption and thus, bioavailability. Tacrolimus can be given sublingually and regular trough levels are sent for confirmation.

Plasma citrulline levels have emerged as a measure for overall for intestinal health as it is an indicator of enterocyte mass. However, compromised renal function is an important factor when considering plasma citrulline levels as a marker of intestinal failure as this potentially can increase circulating citrulline values [31]. Reduced citrulline levels can indicate the need for urgent investigations and also, commencement of TPN.

8. Immunosuppression

The intestine is the largest lymphoid organ in the body and hence, appropriate immunosuppression has been a real challenge. The lack of effective immunosuppressive agents hampered the first attempts of ITx in the 1960s. Over the years, advances in immunosuppression have transformed ITx with the intent of attenuating the intestinal allograft immunity and shifting it to a tolerogenic status [32].

Induction strategies to minimize rejection by reducing the recipient's T-cell load were implemented, initially with cyclophosphamide induction therapy, which was later replaced by daclizumab, an interleukin-2 receptor antagonist (IL2RA) [33]. Basiliximab, another IL2RA, in addition to tacrolimus and prednisone immunosuppression has also been utilized and shown to decrease the incidence of acute rejection [34, 35].

Alemtuzumab induction is becoming increasingly popular and Lauro et al. [36] reported significantly less early rejection episodes, with no sepsis implications. The use of Basiliximab monthly as part of maintenance immunosuppression has been associated with a decrease in acute rejection in liver-excluding transplants [37].

Immunosuppression regimen varies, with several protocols having been reported: Tacrolimus and steroids (35.8%) followed by tacrolimus, mycophenolate and steroids (18.7%), tacrolimus and mycophenolate without steroids in 15.4% of cases and tacrolimus alone in 13.8% of cases [38].

Target trough levels of tacrolimus vary between centers. Pittsburgh has reported target levels between 10 and 15 ng/ml in the first 3 months and thereafter 5–10 ng/ml [39]. Tacrolimus with low-dose steroids remains the most effective and durable long-term combination therapy [21] and is the most common maintenance immunosuppressive regimen [7].

Sirolimus, a rapamycin inhibitor, has been shown as a useful adjunct to tacrolimus in the presence of nephrotoxicity or rejection [40]. However, it carries the disadvantage of severe debilitating oromucosal ulceration. Azathioprine and mycophenolate mofetil have also been used as adjunctive immunosuppressive therapies [33]. Mycophenolate mofetil, however, causes symptomatic diarrhea (increased stoma output) and microscopically evident apoptosis in approximately 40% of solid organ transplant recipients, which could regrettably be mistaken for rejection [41].

9. Complications

Complications following ITx may result in graft failure and invariably death. Patients undergoing ITx have a higher incidence of life-threatening infectious complications than other transplant recipients. This is due to the high bacterial load of the transplanted graft [42]. Therefore, any breach to the intestinal transplant mucosal barrier can lead to bacterial translocation.

Graft loss would need TPN resuming and consideration of re-transplantation, which has a lower rate of success compared with the initial transplantation [43]. Common causes of graft loss include allograft rejection, infection, GVHD and post-transplant lymphoproliferative disorder (PTLD) [33].

9.1. Acute rejection

Allograft rejection has always been one of the most significant challenges to long-term graft and patient survival and can occur either as acute (commonly in the early phase, though can occur late) or chronic (typically taking months to years). Rejection can occur at any time but is most common in the first year, particularly the first 6 months. It affects 45% of ITx patients within the first post-transplant year, with implications on graft survival [7] and is mostly characterized by T-cell response to donor antigens.

Acute rejection should be suspected in all cases of bowel dysfunction (increased stoma output) and symptoms include fever, vomiting, abdominal pain and distension. Diagnosing acute rejection is always challenging and requires a combination of clinical, endoscopic and histopathological investigations. Intestinal allograft endoscopy and biopsies is the gold standard. However, diagnosis can be difficult to establish because of the patchy nature of rejection. Not to mention, that it is not always easy to differentiate between rejection and infection.

Most centers will endeavor to perform early, frequent endoscopies because of high prevalence of acute rejection in the early post transplantation phase [21] and then continue with regular endoscopies as part of their surveillance protocol [44].

The Oxford group, who is utilizing vascularized composite allograft (VCA) transplants from the same donor [45], is now mostly relying on the VCA as a surrogate marker for rejection and is not strictly adherent to early, intensive intestinal biopsy protocols [46]. They have reported that the VCA can provide lead time (about 7 days) before the onset of bowel dysfunction and this could be proven as a unique prognostic tool [45].

Rejection episodes are usually treated with pulses of methylprednisolone, and in resistant cases, thymoglobulin [32] or alemtuzumab [46].

A recent case series reported good outcomes in ITx of positive cross-match patients with only one patient developing acute rejection, with the use of intravenous immunoglobulin (IVIG) and rituximab [47]. Bortezomib, a proteasome inhibitor, has also been recently shown to be effective against donor-specific antibody (DSA)-related rejection [48]. Recently, Eculizumab, a monoclonal antibody that inhibits complement factor 5a, was shown to be effective in maintaining a 2-year rejection-free period in a highly sensitized patient [49]; however, high costs make this approach prohibitive for general use.

As mentioned before, biomarkers such as citrulline have gained interest in recent years. The prospective cohort study by Hibi et al. [50] reported excellent negative predictive value (range 93–99%) for citrulline levels as exclusionary marker for all types of acute rejection (cut-off point, 20 mmol/l) and moderate or severe acute cellular rejection (cut-off point, 10 mmol/l). Another study by the Bologna group [51] showed that citrulline sensitivity and specificity in detecting acute rejection, when adjusted for chronic renal failure, almost doubled the sensitivity of citrulline as a non-invasive marker of acute rejection in ITx. In general, citrulline can act as an exclusionary tool, as high levels are unlikely to be found in intestinal allograft rejection.

Recently, a large series evaluating video capsule endoscopy has shown to be potentially useful in the diagnostic management of patients with ITx [52]. Other non-invasive predictors of rejection include a recent retrospective study that revealed low insulin-like growth factor-1 and high calprotectin levels during malnutrition states post-ITx, and these findings should prompt the clinicians to investigate for acute rejection or infection [53]. Circulating apoptotic T cells following Caspase 3 activation may be a non-invasive marker for patients who are less likely to have rejection episodes than those who have lower levels [54].

9.2. Chronic rejection

Chronic rejection is diagnosed histologically with the identification of an obliterative arteriopathy in medium-sized vessels in the serosal layer with diffuse concentric intimal thickening [55]. This necessitates full-thickness biopsy and makes diagnosis challenging. Chronic rejection is clinically associated with diarrhea, ulceration, focal loss of mucosal folds, mural thickening and pruning of mesenteric artery arcades [55]. Surgery in such a hostile environment may lead to unwanted enterotomies and fistulae. Re-transplantation should therefore

be considered. Evisceration is a potential life-saving option for ITx patients who developed severe rejection, and has similar survival rates with patients who underwent simultaneous enterectomy with re-transplantation; however, high sensitization may prevent re-transplantation [56].

9.3. Donor-specific antibodies

Preformed and de-novo DSAs have been associated with acute rejection and may be implicated in chronic rejection and graft loss [46, 57]. Five-year graft survival of less than 30% was noted in ITx patients who developed de-novo DSA, whereas survival rates of more than 80% were observed in recipients without DSA [44]. Yet, others have not found a statistically significant trend towards worsening outcomes [58] between those with or without de-novo DSA formation.

9.4. Infection

The use of immunosuppression in ITx poses a significant risk of infection and, historically, high levels of immunosuppressants have been utilized in ITx. Sepsis remains the most common cause of death and graft failure, accounting for over 50% of cases [7]. Bacterial infections are common in the early phase post-ITx and have a significant impact on patient survival. Invasive candidiasis has been reported as the commonest fungal infection [59].

Cytomegalovirus (CMV) and Epstein-Barr virus (EBV) viraemias are common and can be implicated in acute and chronic rejection as well as PTLT [60, 61]. CMV status is vital to anticipate the risk of developing de-novo infection in a non-infected recipient from the donor and through reactivation of a latent infection. CMV prophylaxis with oral valganciclovir is often continued for 1 year following ITx [62]. Most programs would not accept CMV-positive donors for CMV-negative recipients as this is high risk and should be avoided [63]. Last but not least, it has been demonstrated that isolated graft CMV disease without overt CMV viraemia can indeed occur [64].

9.5. Post-transplant lymphoproliferative disorder

In the updated 2016 WHO lymphoma classification, PTLT has been sub-classified as plasmacytic hyperplasia PTLT, infectious mononucleosis PTLT, florid follicular hyperplasia PTLT, polymorphic PTLT, monomorphic PTLT and classical Hodgkin lymphoma PTLT [65]. PTLT following SOT occurs in up to 20% with the highest incidence in intestinal and multi-organ transplants (5–20%), followed by lung and heart transplants (2–10%) and then by renal and liver transplants [66].

About 70% of cases of PTLT are associated with Epstein-Barr virus (EBV), especially in cases which occur early after transplantation. Pathogenesis of the disease is linked to EBV proliferation in the setting of chronic immunosuppression leading to an inhibition of T-cells immune function. However, in 30% of EBV-negative PTLT patients, pathogenesis is not clearly understood [67].

It is believed that in ITx, the lymphatic-rich intestinal allografts in combination with splenectomy and immunosuppression pose an increased risk for PTLT [68]. It has been reported that the presence of PTLT has significantly reduced patient survival within the first post-transplant year [69]. PTLT is treated with immunosuppression reduction and rituximab containing chemotherapy regimes in the presence of CD20 positive cases [70].

9.6. Graft versus host disease

The small intestine has abundant lymphoid cells that can mount an immunologic response to the host (i.e. a graft versus host disease [GVHD]) reaction. GVHD occurs in 5–7% of intestinal transplants, compared to 1% for solid organ transplants, and risk factors include younger age, MVTx recipients and intra-operative splenectomy [71]. It is more common in intestinal transplants due to the large volume of lymphatic tissue that is transplanted along with the graft. GVHD diagnosis is allegedly difficult to establish and patients usually present 1–8 weeks after transplantation with skin rash, ulceration of oral mucosa, diarrhea, lymphadenopathy or native liver dysfunction. Diagnosis is confirmed by skin or bowel biopsy.

Treatment strategies vary and most frequently involve tacrolimus, high-dose steroids or anti-thymocyte globulin (ATG) [71].

9.7. Renal dysfunction

Renal dysfunction is invariably seen post ITx due to a combination of high-dose tacrolimus therapy [72] and dehydration episodes, especially in the presence of stomas. The incidence of stage 4 or 5 CKD is 21.3% in patients with ITx [73] and approximately 9% of ITx patients will receive renal replacement therapy by a median of 7.4 years [74].

10. Graft and patient survival

Patient survival has been steadily improving because of improved first-year graft survival [7]. Graft survival has been reported for 1, 5 and 10 years at 74, 42 and 26%, respectively (SBTx); 70, 50 and 40% (MVTx); 61, 46 and 40% (SBLTx); overall patient survival was 76, 56 and 43%, respectively. Studies evaluating 1-year and 5-year patient survival rates at various transplant centers revealed comparable results [75, 76].

Patients on TPN have 1-year, 5-year, 10-year and 20-year survival of 91–93, 70–71, 55–59 and 28%, respectively, following IF commencement [77]. It should be noted, that 11–15% of deaths while on TPN were attributed to TPN complications (5–6% from sepsis or central-line sepsis and 6–9% from IFALD) [77]. A three-year prospective study reported 94 vs. 87% three-year survival in TPN non-transplant candidates vs. TPN transplant candidates who did not undergo transplantation. In addition, the three-year survival was 89 vs. 85 vs. 70% for those having first SBTx vs. transplant candidates with central venous catheter complications vs. candidates with parenteral nutrition-related liver failure [78].

11. Quality of life

Quality of life plays an important role in the decision-making for ITx candidates. ITx patients have reported better fatigue, gastrointestinal symptoms, stoma management/bowel movements, ability to holiday/travel and global health/QoL and probably better eating ability but worse sleeping patterns [79]. Others have found that ITx recipients have similar QoL to those who are stable on TPN, but both are better than those with complicated intestinal failure on TPN [80].

12. Future perspectives

ITx and its secrets have not been deciphered yet. The main issue remains the challenging balance between appropriate immunosuppression and over-immunosuppression. Therefore, ITx teams have been trying to develop markers that will provide adequate warning in case of rejection [45].

Multivisceral organ transplantation may solidify its role in the treatment of slow-growing abdominal cancers that are deemed “non-resectable” [81–83].

Another challenge will be to understand the physiology of the transplanted small bowel, such as its altered microflora and altered motility. New research has suggested that the flora composition within the graft may be a risk factor for acute rejection when more immunogenic species predominate [84].

Tolerance remains the ‘Holy Grail’ of transplantation and is characterized by increased allograft survival in the absence of immunosuppression and absent or reduced donor-specific response. Groups have used donor-specific blood transfusion in order to induce tolerance by upregulating graft protective memory Tregs [85]. Also, centers have introduced experimental models to induce microchimerism and tolerance by transplanting bone marrow along with the intestinal allograft [86]. These protocols could allow for sufficient immunosuppression with lower doses of immunosuppressants. This ongoing research may change the future of ITx.

13. Conclusion(s)

ITx continues to evolve and graft survival rates are nowadays more comparable with the results of other solid organ transplants. The main challenge is to develop immunosuppression protocols that can ensure long-term intestine graft function and less infectious complications. When this is accomplished ITx could potentially change from being a life-saving treatment to becoming a realistic first-line therapy for IF.

Conflict of interest

The author declares no conflict of interest.

Author details

Georgios Vrakas

Address all correspondence to: georgiosvrakas@gmail.com

Oxford University Hospitals, Oxford, UK

References

- [1] Lillehei RC, Goott B, Miller FA. The physiological response of the small bowel of the dog to ischemia including prolonged in-vitro preservation of the bowel with successful replacement and survival. *Annals of Surgery*. 1959;**150**:543-560
- [2] Starzl TE, Kaupp HA Jr. Mass homo-transplantation of abdominal organs in dogs. *Surgical Forum*. 1960;**11**:28-30
- [3] Kubal CA, Mangus RS, Tector AJ. Intestine and multivisceral transplantation: Current status and future directions. *Current Gastroenterology Reports*. 2015;**17**:427. DOI: 10.1007/s11894-014-0427-8
- [4] Starzl TE, Todo S, Fung J, et al. FK 506 for liver, kidney, and pancreas transplantation. *Lancet* (London, England). 1989;**2**:1000-1004
- [5] Todo S, Fung JJ, Starzl TE, et al. Liver, kidney, and thoracic organ transplantation under FK 506. *Annals of Surgery*. 1990;**212**:295-305
- [6] Abu-Elmagd K, Reyes J, Todo S, et al. Clinical intestinal transplantation: New perspectives and immunologic considerations. *Journal of the American College of Surgeons*. 1998;**186**:512-527
- [7] Grant D, Abu-Elmagd K, Mazariegos G, Vianna R, Lagnas A, Mangus R, Farmer DG, Lacaille F, Iyer K, Fishbein T. Intestinal transplant registry & report: Global activity and trends. *American Journal of Transplantation*. 2015;**15**:210-219
- [8] Pironi L, Joly F, Forbes A, et al. Long-term follow-up of patients on home parenteral nutrition in Europe: Implications for intestinal transplantation. *Gut*. 2011;**60**:17-25
- [9] Zanfi C, Lauro A, Cescon M, et al. Comprehensive surgical intestinal rescue and transplantation program in adult patients: Bologna experience. *Transplantation Proceedings*. 2010;**42**:39-41
- [10] Taha AM, Sharif K, Johnson T, Clarke S, Murphy MS, Gupte GL. Long-term outcomes of isolated liver transplantation for short bowel syndrome and intestinal failure-associated liver disease. *Journal of Pediatric Gastroenterology and Nutrition*. 2012;**54**:547-551
- [11] Dell-Olio D, Beath SV, de Ville de Goyet J, et al. Isolated liver transplant in infants with short bowel syndrome: Insights into outcomes and prognostic factors. *Journal of Pediatric Gastroenterology and Nutrition*. 2009;**48**:334-340

- [12] Iyer KR. Surgical management of short bowel syndrome. *JPEN Journal of Parenteral and Enteral Nutrition*. 2014;**38**(1 Suppl):53S-59S
- [13] Buchman AL, Scolapio J, Fryer J. AGA technical review on short bowel syndrome and intestinal transplantation. *Gastroenterology*. 2003;**124**:1111-1134
- [14] Kaufman SS, Atkinson JB, Bianchi A, et al. Indications for pediatric intestinal transplantation: A position paper of the American Society of Transplantation. *Pediatric Transplantation*. 2001;**5**:80-87
- [15] Pironi L, Hebutterne X, Van Gossum A, et al. Candidates for intestinal transplantation: A multicenter survey in Europe. *The American Journal of Gastroenterology*. 2006;**101**:1633-1643
- [16] Pironi L, Arends J, Bozzetti F, et al. ESPEN guidelines on chronic intestinal failure in adults. *Clinical Nutrition*. 2016;**35**:247-307
- [17] Kumpf VJ. Parenteral nutrition-associated liver disease in adult and pediatric patients. *Nutrition in Clinical Practice*. 2006;**21**(3):279-290
- [18] Reyes JD. Intestinal transplantation: An unexpected journey. *Journal of Pediatric Surgery*. 2014;**49**(1):13-18
- [19] Staun M, Pironi L, Bozzetti F, et al. ESPEN guidelines on parenteral nutrition: Home parenteral nutrition (HPN) in adult patients. *Clinical Nutrition*. 2009;**28**:467-479
- [20] Pither C, Wiles A, Butler A, et al. Quality of life in patients undergoing small intestinal transplantation. *Gut*. 2011;**60**(Suppl 1):A89-A189
- [21] Fishbein TM. Intestinal transplantation. *The New England Journal of Medicine*. 2009;**361**:998-1008
- [22] Cruz RJ Jr, Costa G, Bond GJ, et al. Modified multivisceral transplantation with spleen-preserving pancreaticoduodenectomy for patients with familial adenomatous polyposis "Gardner's syndrome". *Transplantation*. 2011;**91**:1417-1423
- [23] Matsumoto CS, Kaufman SS, Fishbein TM. Inclusion of the colon in intestinal transplantation. *Current Opinion in Organ Transplantation*. 2011;**16**:312-315
- [24] Gruessner RW, Sharp HL. Living-related intestinal transplantation: First report of a standardized surgical technique. *Transplantation*. 1997;**64**(11):1605-1607
- [25] Loo L, Vrakas G, Reddy S, Allan P. Intestinal transplantation: A review. *Current Opinion in Gastroenterology*. 2017;**33**(3):203-211
- [26] Reyes J, Fishbein T, Bueno J, et al. Reduced-size orthotopic composite liver-intestinal allograft. *Transplantation*. 1998;**66**:489-492
- [27] Levi DM, Tzakis AG, Kato T, et al. Transplantation of the abdominal wall. *Lancet*. 2003;**361**:2173-2176

- [28] Allin BSR, Ceresa CDL, Issa F, et al. A single center experience of abdominal wall graft rejection after combined intestinal and abdominal wall transplantation. *American Journal of Transplantation*. 2013;**13**:2211-2215
- [29] Ravindra KV, Martin AE, Vikraman DS, et al. Use of vascularized posterior rectus sheath allograft in pediatric multivisceral transplantation-report of two cases. *American Journal of Transplantation*. 2012;**12**:2242-2246
- [30] Gondolesi G, Selvaggi G, Tzakis A, et al. Use of the abdominal rectus fascia as a nonvascularized allograft for abdominal wall closure after liver, intestinal, and multivisceral transplantation. *Transplantation*. 2009;**87**:1884-1888
- [31] Crenn P, Messing B, Cynober L. Citrulline as a biomarker of intestinal failure due to enterocyte mass reduction. *Clinical Nutrition*. 2008;**27**(3):328-339
- [32] Rege A, Sudan D. Intestinal transplantation. *Best Practice & Research. Clinical Gastroenterology*. 2016;**30**:319-335
- [33] Abu-Elmagd KM, Costa G, Bond GJ, et al. Five hundred intestinal and multivisceral transplantations at a single center: Major advances with new challenges. *Annals of Surgery*. 2009;**250**:567-581
- [34] Sudan DL, Chinnakotla S, Horslen S, et al. Basiliximab decreases the incidence of acute rejection after intestinal transplantation. *Transplantation Proceedings*. 2002;**34**:940-941
- [35] Farmer D, McDiarmid S, Edelstein S, et al. Induction therapy with interleukin-2 receptor antagonist after intestinal transplantation is associated with reduced acute cellular rejection and improved renal function. *Transplantation Proceedings*. 2004;**36**:331-332
- [36] Lauro A, Zanfi C, Bagni A, Cescon M, Siniscalchi A, Pellegrini S, et al. Induction therapy in adult intestinal transplantation: Reduced incidence of rejection with "2-dose" alemtuzumab protocol. *Clinical Transplantation*. 2013;**27**(4):567-570
- [37] Kubal CA, Mangus RS, Vianna RM, et al. Impact of positive flow cytometry crossmatch on outcomes of intestinal/multivisceral transplantation. *Transplantation*. 2013;**95**:1160-1166
- [38] Smith JM, Skeans MA, Horslen SP, Edwards EB, Harper AM, Snyderf JJ, et al. OPTN/SRTR 2012 annual data report: Intestine. *American Journal of Transplantation*. 2014;**14**:97-111
- [39] Reyes J, Mazariegos GV, Abu-Elmagd K, et al. Intestinal transplantation under tacrolimus monotherapy after perioperative lymphoid depletion with rabbit antithymocyte globulin. *American Journal of Transplantation*. 2005;**5**:1430-1436
- [40] Lauro A, Dazzi A, Ercolani G, et al. Rejection episodes and 3-year graft survival under sirolimus and tacrolimus treatment after adult intestinal transplantation. *Transplantation Proceedings*. 2007;**39**:1629-1631
- [41] Selbst MK, Ahrens WA, Robert ME, et al. Spectrum of histologic changes in colonic biopsies in patients treated with mycophenolate mofetil. *Modern Pathology*. 2009;**22**:737

- [42] Akhter K, Timpone J, Matsumoto C, Fishbein T, Kaufman S, Kumar P. Six-month incidence of bloodstream infections in intestinal transplant patients. *Transplant Infectious Disease*. 2012 Jun;**14**(3):242-247
- [43] Desai CS, Khan KM, Gruessner AC, et al. Intestinal retransplantation: Analysis of organ procurement and transplantation network database. *Transplantation*. 2012;**93**:120-125
- [44] Abu-Elmagd KM, Wu G, Costa G, et al. Preformed and de novo donor specific antibodies in visceral transplantation: Long-term outcome with special reference to the liver. *American Journal of Transplantation*. 2012;**12**:3047-3060
- [45] Gerlach UA, Vrakas G, Sawitzki B, et al. Abdominal Wall transplantation: Skin as a sentinel marker for rejection. *American Journal of Transplantation*. 2016;**c16**(6):1892-1900
- [46] Weissenbacher A, Vrakas G, Chen M, Reddy S, Allan P, Giele H, Barnardo MCNM, Vaidya A, Friend PJ, Fuggle SV. De novo donor-specific HLA antibodies after combined intestinal and vascularized composite allotransplantation—A retrospective study. *Transplant International*. 2018 Apr;**31**(4):398-407
- [47] Parekh R, Kazimi M, Skorupski S, et al. Intestine transplantation across a & positive crossmatch with preformed donor-specific antibodies. *Transplantation Proceedings*. 2016;**48**:489-491
- [48] Fujiwara S, Wada M, Kudo H, et al. Effectiveness of bortezomib in a patient with acute rejection associated with an elevation of donor-specific HLA antibodies after small-bowel transplantation: Case report. *Transplantation Proceedings*. 2016;**48**:525-527
- [49] Fan J, Tryphonopoulos P, Tekin A, et al. Eculizumab salvage therapy for antibody-mediated rejection in a desensitization-resistant intestinal re-trans-plant patient. *American Journal of Transplantation*. 2015;**15**:1995-2000
- [50] Hibi T, Nishida S, Garcia J, et al. Citrulline level is a potent indicator of acute rejection in the long term following pediatric intestinal/multivisceral transplantation. *American Journal of Transplantation*. 2012;**12**(Suppl 4):S27-S32
- [51] Pironi L, Guidetti M, Lauro A, et al. Plasma citrulline after small bowel transplantation: Effect of time from transplantation, acute cellular rejection and renal failure. *Clinical Transplantation*. 2015;**29**:1039-1046
- [52] Varkey J, Oltean M, Pischel AB, et al. Initial experience of video capsule endoscopy after intestinal transplantation. *Transplant Direct*. 2016;**2**:e119
- [53] Vrakas G, O'Connor M, Matsou A, et al. Markers of malnutrition after intestinal transplantation: The role of IGF-1 and calprotectin. *Journal of Clinical Biochemistry and Nutrition*. 2015;**56**:64-65
- [54] Ashokkumar C, Sun Q, Ningappa M, et al. Antithymocyte globulin facilitates alloreactive T-cell apoptosis by means of caspase-3: Potential implications for monitoring rejection-free outcomes. *Transplantation*. 2015;**99**:164-170
- [55] Demetris AJ, Murase N, Lee RG, et al. Chronic rejection. A general overview of histopathology and pathophysiology with emphasis on liver, heart and intestinal allografts. *Annals of Transplantation*. 1997;**2**:27-44

- [56] Nagai S, Mangus RS, Anderson E, et al. Intestinal graft failure: Should we perform the allograft enterectomy before or with re-transplantation? *Transplantation*. 2017;**101**:411-420
- [57] Cheng EY, Everly MJ, Kaneku H, Banuelos N, Wozniak LJ, Venick RS, Marcus EA, McDiarmid SV, Busuttil RW, Terasaki PI, Farmer DG. Prevalence and clinical impact of donor-specific alloantibody among intestinal transplant recipients. *Transplantation*. 2017;**101**(4):873-882
- [58] Kubal C, Mangus R, Saxena R, et al. Prospective monitoring of donor-specific & anti-HLA antibodies after intestine/multivisceral transplantation. *Transplantation*. 2015;**99**:e49-e56
- [59] Florescu DF, Sandkovsky U. Fungal infections in intestinal and multivisceral transplant recipients. *Current Opinion in Organ Transplantation*. 2015;**20**:295-302
- [60] Timpone JG, Girlanda R, Rudolph L, Fishbein TM. Infections in intestinal and multivisceral transplant recipients. *Infectious Disease Clinics of North America*. 2013;**27**:359-377
- [61] Timpone JG, Yimen M, Cox S, et al. Resistant cytomegalovirus in intestinal and multivisceral transplant recipients. *Transplant Infectious Disease*. 2016;**18**:202-209
- [62] Allan PJ, Vaidya A, Lal S. Small bowel transplantation. In: *Nutritional Management of Inflammatory Bowel Diseases*. Cham: Springer International Publishing; 2016. pp. 215-230
- [63] Ambrose T, Sharkey LM, Louis-Auguste J, et al. Cytomegalovirus infection and rates of antiviral resistance following intestinal and multivisceral transplantation. *Transplantation Proceedings*. 2016;**48**:492-496
- [64] Avsar Y, Cicinnati VR, Kabar I, et al. Small bowel transplantation complicated by cytomegalovirus tissue invasive disease without viremia. *Journal of Clinical Virology*. 2014;**60**:177-180
- [65] Swerdlow SH, Campo E, Pileri SA, et al. The 2016 revision of the World Health Organization classification of lymphoid neoplasms. *Blood*. 2016;**127**:2375-2390
- [66] Petrara MR, Giunco S, Serraino D, et al. Post-transplant lymphoproliferative disorders: From epidemiology to pathogenesis-driven treatment. *Cancer Letters*. 2015;**369**:37-44
- [67] Bishnoi R, Bajwa R, Franke AJ, Skelton WP 4th, Wang Y, Patel NM, Slayton WB, Zou F, Dang NH. Post-transplant lymphoproliferative disorder (PTLD): Single institutional experience of 141 patients. *Experimental Hematology & Oncology*. 2017;**6**:26
- [68] Lauro A, Arpinati M, Pinna AD. Managing the challenge of PTLD in liver and bowel transplant recipients. *British Journal of Haematology*. 2015;**169**:157-172
- [69] Abu-Elmagd KM, Mazariegos G, Costa G, et al. Lymphoproliferative disorders and de novo malignancies in intestinal and multivisceral recipients: Improved outcomes with new outlooks. *Transplantation*. 2009;**88**:926-934
- [70] Trappe R, Oertel S, Leblond V, et al. Sequential treatment with rituximab followed by CHOP chemotherapy in adult B-cell post-transplant lymphoproliferative disorder

- (PTLD): The prospective international multi-centre phase 2 PTLD-1 trial. *The Lancet Oncology*. 2012;**13**:196-206
- [71] Mazariegos GV, Abu-Elmagd K, Jaffe R, Bond G, Sindhi R, Martin L, et al. Graft versus host disease in intestinal transplantation. *American Journal of Transplantation*. 2004;**4**(9):1459-1465
 - [72] Suzuki M, Mujtaba MA, Sharfuddin AA, et al. Risk factors for native kidney dysfunction in patients with abdominal multivisceral/small bowel transplantation. *Clinical Transplantation*. 2012;**26**:E351-E358
 - [73] Ojo AO, Held PJ, Port FK, et al. Chronic renal failure after transplantation of a nonrenal organ. *The New England Journal of Medicine*. 2003;**349**:931-940
 - [74] Abu-Elmagd KM, Kosmach-Park B, Costa G, et al. Long-term survival, nutritional autonomy, and quality of life after intestinal and multivisceral transplantation. *Annals of Surgery*. 2012;**256**:494-508
 - [75] Ceulemans LJ, Monbaliu D, De Roover A, et al. Belgian multicenter experience with intestinal transplantation. *Transplant International*. 2015;**28**:1362-1370
 - [76] Ramisch D, Rumbo C, Echevarria C, et al. Long-term outcomes of intestinal and multivisceral transplantation at a single center in Argentina. *Transplantation Proceedings*. 2016;**48**:457-462
 - [77] Dibb M, Soop M, Teubner A, et al. Survival and nutritional dependence on home parenteral nutrition: Three decades of experience from a single referral centre. *Clinical Nutrition*. 2017 Apr;**36**(2):570-576
 - [78] Pironi L, Forbes A, Joly F, et al. Survival of patients identified as candidates for intestinal transplantation: A 3-year prospective follow-up. *Gastroenterology*. 2008;**135**:61-71
 - [79] Pironi L, Baxter JP, Lauro A, et al. Assessment of quality of life on home parenteral nutrition and after intestinal transplantation using treatment-specific questionnaires. *American Journal of Transplantation*. 2012;**12**:S60-S66
 - [80] Cameron EAB, Binnie JAH, Jamieson NV, et al. Quality of life in adults following small bowel transplantation. *Transplantation Proceedings*. 2002;**34**:965-966
 - [81] Allan P, Reddy S, Moran B, Vrakas G, Giele H, Mohamad F, Gilbert J, Sinha S, Vaidya A, Cecil T, Friend P. Cytoreductive surgery and small bowel transplantation is a feasible option for patients with end-stage pseudomyxoma peritonei. *Gut*. 2016;**65**:A106-A107
 - [82] Chi Z, Mangus RS, Kubal CA, Chen S, Lin J. Multivisceral transplant is a viable treatment option for patients with non-resectable intra-abdominal fibromatosis. *Clinical Transplantation*. 2017 [Epub ahead of print]
 - [83] Frilling A, Giele H, Vrakas G, Reddy S, Macedo R, Al-Nahhas A, Wasan H, Clift AK, Gondolesi GE, Vianna RM, Friend P, Vaidya A. Modified liver-free multivisceral transplantation for a metastatic small bowel neuroendocrine tumor: A case report. *Transplantation Proceedings*. 2015 Apr;**47**(3):858-862

- [84] Voswinkel J, Francois S, Gorin NC, Chapel A. Gastro-intestinal autoimmunity: Preclinical experiences and successful therapy of fistulizing bowel diseases and gut graft versus host disease by mesenchymal stromal cells. *Immunologic Research*. 2013 Jul;**56**(2-3):241-248
- [85] Ceulemans LJ, Braza F, Monbaliu D, Jochmans I, De Hertogh G, Du Plessis J, Emonds MP, Kitade H, Kawai M, Li Y, Zhao X, Koshiba T, Sprangers B, Brouard S, Waer M, Pirenne J. The Leuven immunomodulatory protocol promotes T-regulatory cells and substantially prolongs survival after first intestinal transplantation. *American Journal of Transplantation*. 2016 Oct;**16**(10):2973-2985
- [86] Sheng Sun D, Iwagaki H, Ozaki M, Ogino T, Kusaka S, Fujimoto Y, Murata H, Sadamori H, Matsukawa H, Tanaka N, Yagi T. Prolonged survival of donor-specific rat intestinal allograft by administration of bone-marrow-derived immature dendritic cells. *Transplant Immunology*. 2005 Mar;**14**(1):17-20

