

# We are IntechOpen, the world's leading publisher of Open Access books Built by scientists, for scientists

6,900

Open access books available

186,000

International authors and editors

200M

Downloads

Our authors are among the

154

Countries delivered to

TOP 1%

most cited scientists

12.2%

Contributors from top 500 universities



WEB OF SCIENCE™

Selection of our books indexed in the Book Citation Index  
in Web of Science™ Core Collection (BKCI)

Interested in publishing with us?  
Contact [book.department@intechopen.com](mailto:book.department@intechopen.com)

Numbers displayed above are based on latest data collected.  
For more information visit [www.intechopen.com](http://www.intechopen.com)



---

# Osteonecrosis of the Jaws

---

Vladimira Schwartzova, Marcel Riznic,  
Branislav Borza and Peter Kizek

Additional information is available at the end of the chapter

<http://dx.doi.org/10.5772/intechopen.75878>

---

## Abstract

Osteonecrosis of the jaw is a very severe complication in patients using antiresorptive drugs, which have been widely applied for the last 10 years. It has prompted an increase in number of negative complications such as significantly restricted food intake, reduced quality of life with a negative impact on the general health status of the patient as a whole. The negative influence of antiresorptive drugs on jaw bones is still not precisely known and is the subject of research. More than 30% of patients with rheumatic diseases develop osteonecrotic lesions in the jaws due to a relation with bisphosphonates, corticosteroids or other antiangiogenic treatment administered orally or parenterally. The treatment is often protracted, variable and very complicated. The clinical symptoms and treatment possibilities are presented, and, based on the clinical results, compared with many investigative researches and multicenter studies all over the world. Preventive measures are often consistent with other studies, where precautions such as radical dental treatment were observed, especially before antiresorptive treatment initiation. Despite the clinical results, which widely differ, the best way to prevent the osteonecrosis of the jaw is a necessary interdisciplinary approach and further research.

**Keywords:** osteonecrosis of the jaw, antiresorptive drugs, interdisciplinary approach, quality of life, rheumatic diseases

---

## 1. Introduction

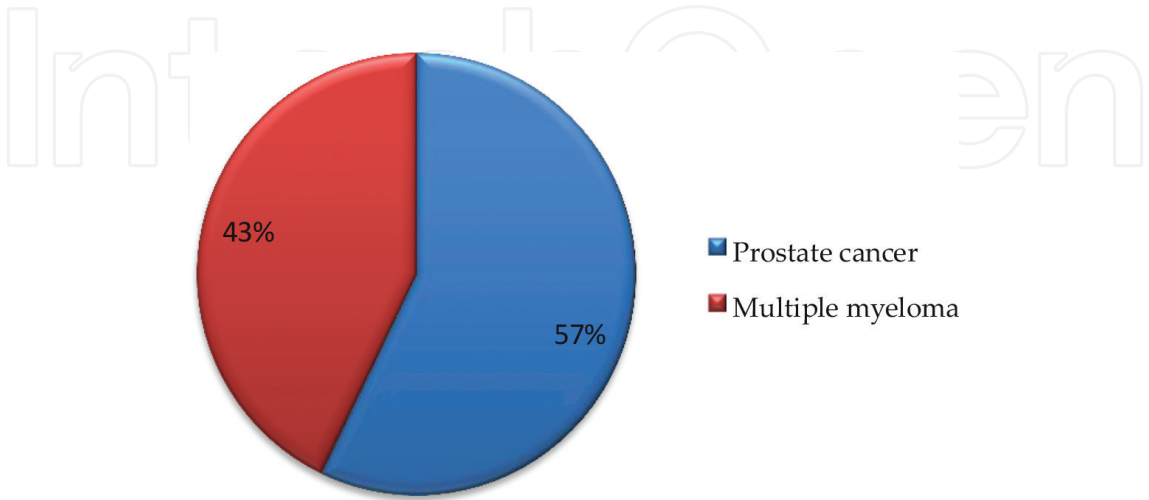
Medication-related osteonecrosis of the jaw (MRONJ) was first described in patients with multiple myeloma treated with intravenously administered bisphosphonates in 2003. At the time, the disease was classified as bisphosphonate-related osteonecrosis of the jaw (BRONJ). However, 15 years of development in diagnosing, treating and monitoring the course of the

disease revealed the correlation with drugs other than the bisphosphonates. The American Association of Maxillofacial Surgeons (AAOMS) standardized the diagnostic criteria for BRONJ in 2009, and updated the disease to MRONJ, eventually merging both diseases in 2014 [1].

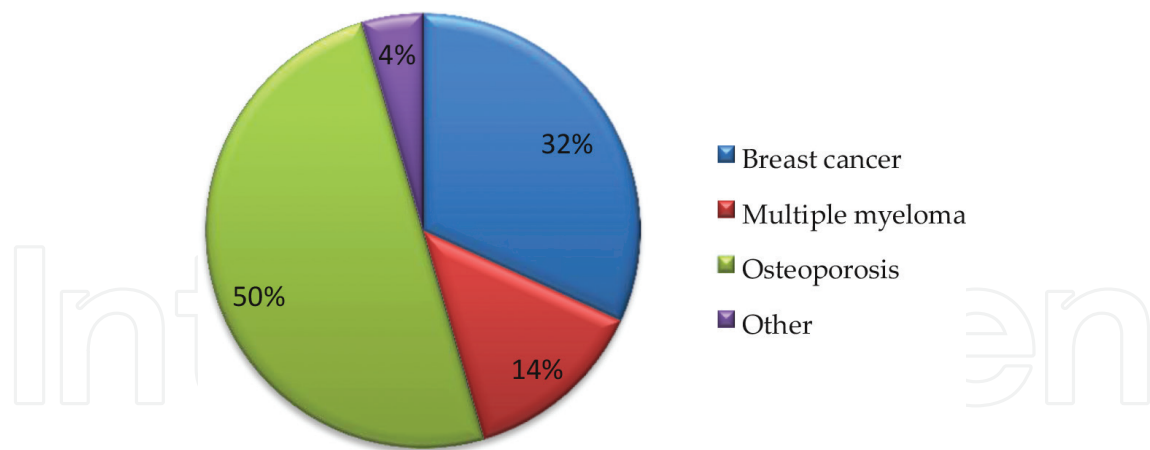
Recently, there have been a growing number of cases with osteonecrosis of the jaw diagnosed in patients treated with cytostatics, hormonal preparations combined with corticosteroids and human monoclonal antibodies. This group of drugs is known as antiresorptive medications (ARM), with proven cytotoxic effect on mucous membrane of the oral cavity. Most often, however, following an invasive procedure in oral cavity that breaches its integrity and exposes the alveolar bone, while simultaneously failing to implement measures that promote wound healing, they lead to a necrosis. Osteonecrosis of the jaw is confirmed by the clinical picture of non-healing post-extraction wound (or dental trauma), which has not healed in 8 months without medical history of radiation therapy in head and neck region, edema, loose teeth, foetor ex ore, fistulas and, in advanced stages, pain.

It is possible to locate the affected area by employing the modern methods such as MRI, CBCT or through bone resorption biomarker findings. These diagnostic methods aid in determining the stage of the disease and subsequent method of treatment. The treatment is difficult and often ineffective, with recurrent complications. When the preventive measures are observed and the disease is diagnosed early, followed up by an adequate treatment, the disease can be cured, or at least in certain cases, the symptoms in the oral cavity can be alleviated. In the majority of cases, however, MRONJ patients who have been treated with antiresorptive drugs tend to also suffer from breast cancer, prostate cancer or multiple myeloma (**Figures 1 and 2**). We also encounter increasing number of patients with osteoporosis and rheumatoid arthritis [2]. Most cases of MRONJ arise after prolonged intravenous use of nitrogen-containing bisphosphonates. Orally administered nitrogen-containing bisphosphonates cause MRONJ less often [3].

The scope and course of the disease depends on the correlation between other drugs and the patient's overall health status. Antiresorptive treatment is a common treatment method, only excluding patients with cancer, rheumatoid arthritis, osteoporosis or the so-called skeletal-related



**Figure 1.** The basis of disease in men.



**Figure 2.** The basis of disease in women.

events (SREs). This term refers collectively to specific serious complications relating to the metastatic bone disease. SREs include pathological fractures of vertebrae and long bones, malignant spinal cord compression, hypercalcemia and cases requiring orthopedic and analgesic radiotherapy. This treatment improves the quality of life for such patients, and provides them with longer lifespan, with minimal undesirable effects.

## 2. Etiopathogenesis

There are a number of theories concerning the cause of this complication. They are mostly related to the formation of necrotic bone caused by the inhibition of bone remodeling with bisphosphonates and an antiangiogenic therapy. However, several studies on the development of the disease indicate that the bone remodeling inhibition itself cannot cause bone exposure. It is necessary for local risk factors to also be present.

The most significant theories about the possible cause are based on the following arguments:

1. The only barrier between the bone and the mouth is a thin mucosa that is easily damaged by mechanical irritation (chewing, prosthesis-related trauma).
2. Oral cavity contains a diverse microbial flora that may induce pulpo-periodontal diseases, when the area becomes pathologic.
3. A surgical procedure in the area exposes the alveolar bone to a high concentration of bacteria.
4. Bone remodeling rate of the jaw and mandible is very high, which leads to a greater accumulation of bisphosphonates in the mineralized bone tissue [4].

According to a theory, keratinocytes undergo bisphosphonate-induced apoptosis resulting in diminished mucous barrier in the oral cavity, which plays a role in the development of MRONJ. If an infection in the oral cavity is caused by the naturally occurring post-surgery

bacteria (*Actinomyces israelii*, *Escherichia coli*), they will cause the drop in the wound area pH, and will release bisphosphonates and calcium salts. The hypothesis is that high concentrations of bisphosphonates increase apoptosis of keratinocytes in the attached gingiva and consequently, allow the penetration of bacteria into deeper tissues. This hypothesis may explain why MRONJ occurs only in maxilla and mandible, but not in other bones of the skeleton.

Another theory considers the unique role of bone remodeling rate. Both maxilla and mandible are examples of a bone that is subject to an increased bone remodeling, mainly in the alveolar socket area and periodontal area, as a result of intensive mechanical stress acting on teeth during chewing and other movements of the teeth. It turns out that the bone turnover is constant during the life of an individual, regardless of their age [5].

The suppression of remodeling and decrease of bone turnover results from bisphosphonates directly affect osteoclasts and their function. Studies examining osteogenesis imperfecta in kids reveal that bisphosphonates do not always reduce the level of osteoclasts, but contrary to that, under certain conditions, they tend to increase their levels [6, 7]. Suppression of bone remodeling could therefore occur through other mechanisms such as intravenous bisphosphonate application.

Longitudinal animal studies with long-term application of bisphosphonates revealed increased number of multilocular phosphatase-positive cells in jaw and long bones. On the surface of the bone, however, the number of osteoclasts is decreased, while the number of osteoclasts in the woven bone is increased [8]. A traumatized alveolar compact bone with damaged periosteal and endosteal covering and diminished osteoprogenitor cells will activate osteoclasts and start the bone remodeling process. However, osteoclasts are unable to bind themselves to the bone surface and resorb the bone matrix as a result of incorporated bisphosphonates. Traumatized bone can hold the attempted osteoclast activation signal, and the osteoclasts then accumulate near the bone surface. The purpose of these accumulated unconnected osteoclasts in bone tissue is currently unclear [9].

## 2.1. Infectious agents

The oral cavity is colonized by a number of microorganisms that may become pathogenic even after the slightest superficial trauma to the oral mucosa, which then acts as a gateway for jaw bone infection. An organism treated with ARM has altered immune response and is unable to react efficiently against infectious agents and curb the spread of infection to surrounding tissues of the oral cavity and alveolar processes.

Various in vivo studies on rats describe a link between the periodontal infection and the osteonecrosis development. Young adult rats have been administered bisphosphonates for 15 weeks and had a circumdental wire applied to the first molar for 3 weeks to induce an aggressive periodontitis. Osteonecrosis of the jaw diagnosed in this study had the identical course and histological finding to the human manifestations of the disease, with bone sequestration, numerous empty osteocyte lacunas and an expression of inflammation. Culture results proved that *Fusobacterium nucleatum* were present. After the subsequent ATB application, the signs of osteonecrosis have subsided; however, the healing ad integrum did not happen.

Numerous similar longitudinal studies confirm the significant role of infectious agents in the oral cavity with expressed osteonecrosis [10]. Surgical procedures conducted during a bisphosphonate therapy or a periodontal pathology indicating bone remodeling of the alveolar bone make it easier for bisphosphonates to accumulate in maxilla or mandible. After bisphosphonates in a bone reach the critical concentration, a trigger (tooth extraction) activates the bone remodeling, simultaneously releasing local deposits of bisphosphonates that inhibit the bone healing process. Necrotic osteomyelitis is induced by the slowed-down repair process, accompanied by a bone wound contamination by the *Actinomyces* bacteria.

Hence, efficient debridement, application of antimicrobial mouthwash and application of ATB directly on the bone defect and the wound play a very important role in the treatment of ONJ.

### 3. Clinical picture

In the past, osteonecrosis of the jaw proved to be a serious problem not only in the view of possible treatments, but also in the view of the diagnosis itself. Such lesions and conditions were usually considered to be osteitis, osteomyelitis or alveolitis, which were thought to have been the result of a preceding extraction.

Complications in the oral cavity in patients with MRONJ are usually diverse. The complications may emerge due to the progression of the disease, or as a result of medical procedures, which produce functional problems such as diminished chewing function, loss of teeth and limited rehabilitation of the chewing function. In addition, aesthetic obstructions may also emerge due to the loss of teeth, facial contour defects (owing to partial bone resections) or due to enduring oroantral fistulas. Patients experience sore mouth, impaired wound healing and drug-induced mucositis.

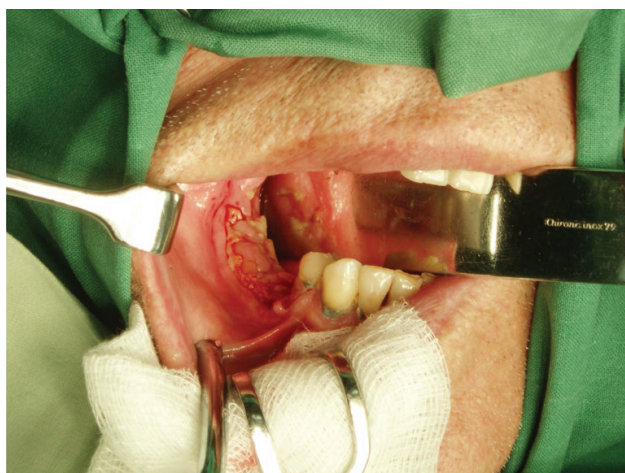
The most common clinical sign of MRONJ (up to 93.9%) is an exposed necrotic bone. The scope of bone exposure may vary greatly and is directly connected neither with the scope of the necrosis nor with the severity of the disease. Signs of infection such as swelling of soft tissues, intra/extra oral purulent discharge or abscesses may also be present. Patients may suffer from severe pain if the infection breaks out of the necrotic tissue, although this symptom is not a requirement—many patients do not report any pain. In severe cases, local infection may develop into abscesses in the deeper areas of the head and neck, resulting in life-threatening conditions. It may even lead to an abscess in brain tissues. Some rare cases of septic systemic infection have been documented.

Rare, although typical, symptom of MRONJ is the paresis of alveolar nerve, also known as the Vincent's symptom. It is interesting that it manifests itself in the earlier and in the advanced stages of MRONJ. Reduced sensitivity of nervus alveolaris inferior can also be a sign of metastatic infiltration. Histologic examination is recommended. Other symptoms associated with MRONJ include loss of teeth due to structural changes within the necrotic bone and bad breath due to bacterial inflammation.

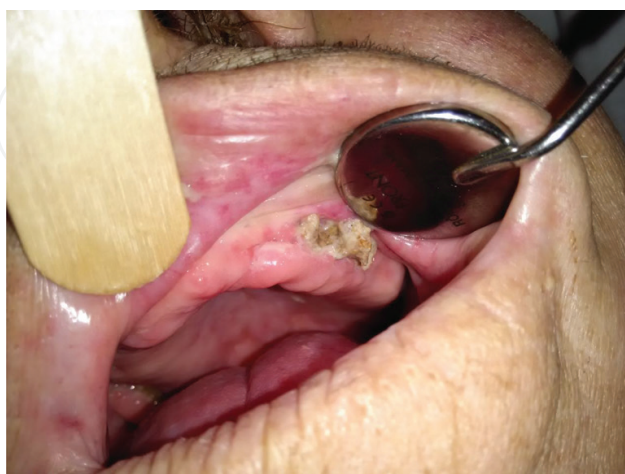Loss of teeth is the result of a progress of the necrotic damage to the alveolar bone. Bad breath as a symptom commonly occurs in patients suffering from MRONJ based on previous changes within the necrotic bone and the surrounding soft tissues. This can also be the result

of a bacterial colonization of the affected area, usually combined with a non-sterile infection of the bone and the surrounding soft tissue. This symptom occurs in 71–84% of MRONJ patients with periodontitis which form an inflammatory periodontal disease. Polymicrobial biofilm swab samples from oral cavity reveal specific bacteria such as *Porphyromonas gingivalis*, *Treponema denticola*, *Tannerella forsythia* or *Aggregatibacter actinomycetemcomitans*.

Thanks to the adequate and effective management of these diseases and their various possible stages, it is now possible to correctly diagnose the patient and consequently, try and treat them. Though, the treatment itself usually does not bring neither adequate nor successful results, which is the reason why such an amount of studies and in vivo and in vitro experiments exist. The status of oral cavity in patients undergoing intravenous bisphosphonate therapy after primary prevention can be maintained to such an extent that the cancer treatment may continue without any negative impact on the quality of life of the patient, even when osteonecrotic defects and lesions are present. **Figures 3 and 4** describe the clinical picture of ONJ.



**Figure 3.** Osteonecrosis of the right mandible.



**Figure 4.** Osteonecrosis of the left maxilla.

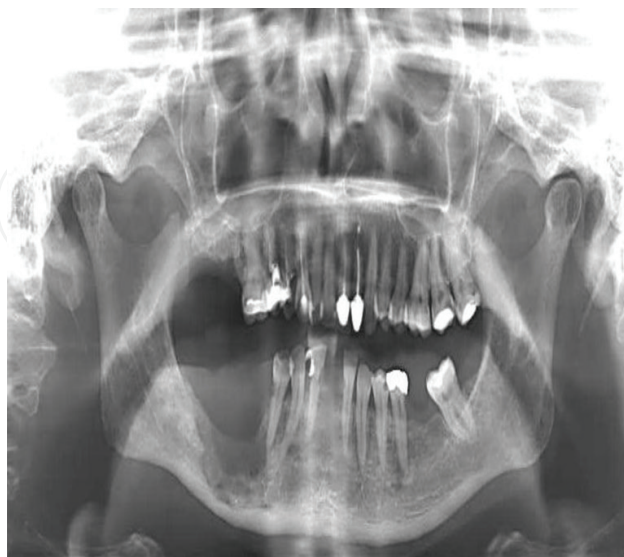
## 4. Prevention

Considering how complex the bisphosphonate-related osteonecrosis of the jaw therapy is, primary prevention may be the most important strategic approach to this complication.

Preventive measures are able to reduce, albeit not eliminate, the risk of formation of lesions. The rationale behind the primary prevention is the elimination of all focuses of infection in the jaw and total denture restoration lege artis.

The radical form of the therapy is comparable to denture restoration in patients before a radiation therapy in the head and neck region. All dentists should be familiar with the form of the therapy. Every patient should be subject to dental examination and panoramic dental X-ray before their planned antiresorptive therapy (**Figure 5**). In case surgical procedures in oral cavity (usually teeth extractions) are necessary as a part of the denture restoration procedure, it is recommended, if possible, to postpone the launch of ARM treatment by 2–3 weeks, or, preferably, until clear signs of bone healing show up on the skiagram. Other dental examinations and good oral hygiene are, of course, essential in the course of the ARM treatment.

In cancer patients taking intravenous bisphosphonates, the most conservative therapy possible is indicated for dental diseases. All invasive procedures involving jaw bones are strictly contraindicated (tooth extractions, periodontal-dentoalveolar surgery, implantology). It is recommended to refer the patients for whom these procedures are necessary to a specialized department of maxillofacial surgery. Such preventive measures are recommended to be followed not only in cancer patients who are subject to bisphosphonate treatment, but also in patients who use other drugs affecting bone metabolism or osteoclast function inhibitors.



**Figure 5.** Panoramic X-ray with osteonecrosis of the right mandible.

The secondary prevention, in terms of ARM treatment interruption—the so-called drug holiday—is bit problematic. So far, there is no scientific evidence that the interruption of a therapy prior to surgery in the oral cavity reduced the risk of developing osteonecrosis of the jaw. According to AAOMS, suspending intravenous bisphosphonates has no significant short-term benefit in case the lesions are already present. Long-term treatment suspension, however, may stabilize the affected area, alleviate the clinical signs and also reduce the risk of new sites being affected. The priority still lies in the treatment of malignant diseases, and therefore, the suspension of bisphosphonates has to be thoroughly assessed.

The situation with monoclonal antibodies is different. Based on current knowledge about the effect of denosumab on bone remodeling, it is recommended to suspend the drug prior to any planned surgery in the oral cavity, in order to reduce the risk of developing osteonecrosis of the jaw. Suspending denosumab treatment seems to be appropriate, even in cases of an already developed osteonecrosis of the jaw, which can lead to heightened healing of the lesion. Some authors recommend suspending bevacizumab 6–8 weeks before surgery and resuming the medication 4 weeks after the procedure to prevent complications with wound healing.

## 5. Treatment

The primary goal of the treatment is to minimize the occurrence of MRONJ. Even though cases of spontaneous formation of MRONJ do exist, the majority of cases develop after a surgery.

In the first place, it is necessary to carry out a preservation treatment and consequent prosthetic and surgical treatment *lege artis*. This includes restorations of carious teeth, repairing of overhanging fillings, or extracting devitalized or destroyed teeth with extensive periapical findings. ARM treatment should initiate or resume only after the extraction wound in the socket has healed thoroughly. Prevention is important in terms of maintaining the functionality of healthy teeth.

Examination of the affected mucosa is necessary in patients with prosthetic replacement, since decubiti, traumatic lesions or fissural granuloma may emerge in the area. For these reasons, temporary restoration is contraindicated in many cases. Dentoalveolar procedure must be carried out in the gentlest manner, preferably at a maxillofacial surgery facility. It is necessary to inform the patient about the possible risks. Chlorhexidine mouth washes are indicated both before and after the dentoalveolar procedure. The surgery is performed under the influence of antibiotics, which continue to be employed after the procedure.

MRONJ treatment is very demanding in terms of time; therefore, AAOMS recommends a conservative approach, in an attempt to delay the surgical resection treatment, which is indicated in the advanced stages of the disease. Palliative conservative treatment is usually applied, since only a small percentage of patients will experience complete healing *ad integrum*. The conservative approach consists of equalization of sharp bone edges, sequestrectomy, necrotic area teeth extractions, and incisions and drainages under total antibiotic and topical treatment.

Surgical treatment consists of complete removal of the necrotic foci, which serve as a fertile ground for infection, followed by wound closure with soft tissue that is finely vascularized, using layered suture. During the radical surgical resection, there are still concerns about the resulting wounds, difficulty in healing and progression of osteonecrotic foci.

Several studies point to the possibility of employing new treatment methods such as PRP, ozone or hyperbaric oxygen therapies. The benefit for cancer patients who are undergoing intravenous bisphosphonate treatment is bone pain relief and retreat of other bone complications. The basic rule is to preserve the quality of life for these patients, which includes a thorough oral health care, patient education, regular visits to the dentist, pain management and reports on health status, edemas, pain or bone exposure. It is also important to prevent the spread of new necrotic sockets by observing the proper prevention. Staging and management is described in **Table 1**.

Patients with aforementioned drugs in their medical history need to be treated as risk patients in view of invasive procedures in the oral cavity. Currently, the majority of osteonecrosis are of iatrogenic nature, caused by the incorrect choice of treatment for risk patients by the medical

Staging and Management of The ARM-Induced Osteonecrosis of The Jaw	
Stage	Clinical Stages and Management
Risk	<p>No evidence of necrotic bone. Patients who were, and still are treated with oral or intravenous antiresorptive drugs.</p> <ul style="list-style-type: none"> <li>Asymptomatic</li> <li>Not requiring treatment</li> <li>Patient education</li> </ul>
0.	<p>No clinical records of necrotic bone, with non-specific finding and symptoms</p> <ul style="list-style-type: none"> <li>Systematic management</li> <li>Analgesia</li> </ul>
I.	<p>Asymptomatic patient with an exposed bone, without pain and infection of the surrounding tissues</p> <ul style="list-style-type: none"> <li>Daily use of an antibacterial mouthwash (chlorhexidine 0.12%)</li> <li>Follow-up</li> <li>X-RAY checks, analgesia</li> </ul>
II.	<p>Osteonecrosis with signs of pain, inflammation and erythema</p> <ul style="list-style-type: none"> <li>Daily use of an antibacterial mouthwash (chlorhexidine 0.12%)</li> <li>Analgesia, ATB p.o. based on the cultivation and sensitivity identification</li> <li>Supportive treatment, polyvitaminosis (Tocopherol, Calcium)</li> </ul>
III.	<p>Extensive osteonecrosis accompanied by pain, infection, fistula, osteolysis, extraoral fistula and pathological fracture. Exposed necrotic bone, or fistula that probes to bone in patients with pain and infection and at least one associated complication: exposed and necrotic bone extended beyond the area of the alveolar bone (i.e., the lower border of the ramus in mandible, or sinus and zygomatic bone area in maxilla), which leads to pathological fractures, extra and intra oral fistulas, oronasal and oroantral communication, or osteolysis extended to the lower border of the mandible</p> <ul style="list-style-type: none"> <li>Daily use of an antibacterial mouthwash (chlorhexidine 0.12%)</li> <li>Surgical debridement/necrectomy</li> <li>Analgesia, ATB p.o./i.v. based on the cultivation and sensitivity identification</li> <li>Supportive treatment, polyvitaminosis (Tocopherol, Calcium)</li> </ul>

**Table 1.** Staging and management.

staff. The cause of this unfavorable situation lies in the lack of communication between the specialist prescribing the high-risk drug and the treating dentist. The lack of awareness of the issue, both in patients and treating dentists, also plays its role. Medical specialist prescribing a high-risk drug is obligated to inform the patient about the risks and adverse effects of the planned treatment and to remind them to specifically inform their dentist about this fact. By disregarding this obligation on the part of the specialist (clinical oncologist, internist, rheumatologist, urologist, gynecologist, endocrinologist, orthopedist, etc.), the patient usually has no idea about the risk involved; however, the development of iatrogenic osteonecrosis may be prevented by the right approach by the treating dentist. They should not underestimate drug anamnesis prior to any invasive procedure in the oral cavity. Precise and targeted medical history can help identify at-risk patients and to choose the right treatment plan.

The incidence of MRONJ can be divided into two groups: patients with non-oncological disease (osteoporosis, rheumatoid arthritis) and patients with cancer who take high doses of intravenous bisphosphonates.

In the second group, the incidence after 36 months of treatment ranges from 1 to 12%. The majority of cases described are connected with the use of zoledronate and pamidronate in treatment of multiple myeloma and bone metastases. So far, the results and recommendations on potential treatment for these conditions refer to the multicenter studies conducted in the last 15 years.

The study named DEFEND (Denosumab Evaluation for Preserving Bone Density) was a double-blind, multicenter, placebo-controlled, third phase study on 332 postmenopausal women with osteopenia and respective T-scores in the range of 1.5–2.5 SD. Denosumab was applied in 6-month intervals at a dose of 60 mg subcut, in contrast to placebo. Both groups of patients took a calcium supplement (100 mg a day) and vitamin D. The primary objective was to observe the lumbar spine bone mineral density after 24 months of treatment.

The results of the study showed that, compared with placebo, denosumab significantly increased the value of BMD in lumbar spine (by 6.5%). Denosumab also increased the density in the proximal part of femur (3.4%) and in the distal end of radius (by 1.4%). In the placebo group, the BMD decreased in these areas.

In another study, titled DECIDE (Determining Efficacy: Comparison of Initiating Denosumab vs. Alendronate), the effectiveness of denosumab with the same dosage as in the study DEFEND was compared to alendronic acid with a dosage of 70 mg, once a week, in order to reduce the risk of osteoporotic fractures. The yearlong study enrolled 1189 postmenopausal, relatively older women with more serious osteopenia than in the DEFEND, with half the women having a fracture in their medical history. Calcium and vitamin D supplementation has been the norm throughout the study. The primary measured indicator was the change in the density of proximal femur. Moreover, bone densities of lumbar spine, femoral neck, trochanter and distal radius were also monitored.

The results showed that denosumab improved bone density in all the monitored areas markedly better than alendronic acid, as early as at the end of the first month. At the same time, resorption markers significantly decreased in the group treated with denosumab, compared to the alendronic acid group.

Large, randomized, placebo-controlled study called FREEDOM (Fracture Reduction Evaluation of Denosumab in Osteoporosis Every 6 Months) studied the reduction of incidence of osteoporotic fractures. The authors monitored 7868 women aged 60–90, with an average BMD T-score of  $-2.5$ , but not lower than  $-4.0$ .

After 3 years, the incidence of new vertebral fractures identified on X-rays in women treated with denosumab was 2.3%, while the incidence in the control group was 7.2%. The treatment reduced the relative risk of vertebral fractures by 68%. The cumulative incidence of hip fractures was 0.7% in the treatment group and 1.2% in the control group (40% reduction in the risk of fractures). There were no recorded significant differences in incidence of side effects such as cardiovascular complications, infections, fracture healing time and hypercalcemia between the treated and the control group [11].

An important outcome of these studies was the discovery that denosumab significantly increases bone density, even in areas with prevalence of cortical bones. From these results, it can be concluded that alendronate has the longest half-life decay (10 years), while denosumab has a reversible effect because it does not deposit into bone tissue.

### **5.1. Combining antiresorptive drugs and hormonal therapy**

Several studies refer to clinical cases of patients with antiresorptive drug-related osteonecrosis of the jaw that describe improvement in local findings and bone remodeling and an increase in patient's quality of life after switching bisphosphonates for hormonal therapy with recombinant parathyroid hormone teriparatide [12, 13].

Teriparatide was approved for the treatment of postmenopausal osteoporosis. Unlike the antiresorptive treatment, teriparatide has anabolic effect in bone which stimulates bone remodeling and bone tissue density. Intermittent administration (once a day) leads to a temporary increase of serum concentrations and preferential stimulation of the osteoblast activity, which leads to bone formation stimulation. The effect lies in the increase of bone mass and the number of osteoblasts, and the consequent strength of bones.

Some clinical trials document a positive effect of teriparatide and parathyroid hormone which reduces the risk of vertebral fractures while increasing the bone mineral density (BMD). The preparation is administered subcutaneously, one injection a day. Recommended treatment duration is 18 months. Side effects include cephalalgia, nausea and hypercalcemia. After its administration, osteal healing in mouth cavity was documented.

According to the trial results, hormonal preparations used after stimulating the activity of osteoblast and osteoclasts could be employed in the treatment of non-oncological osteonecrosis. However, current trials are very small, and there is no sufficient evidence, which calls for more studies. Treatment is difficult, and it is therefore available only for some patients.

Teriparatide should not be used in cancer patients due to an increased risk of osteosarcomas, which were found in preclinical trials on rats. The teriparatide therapy should not be indicated in patients who inject their bisphosphonates, zoledronic acid or pamidronic acid because of the increased incidence of necrosis and associated severe complications, in contrast to orally administered bisphosphonates.

## 6. Conclusion

The aforementioned clinical recommendations are based on relevant data, scientific evidence, available literature and the empirical experience of the authors. Despite the effort, neither standard nor recommended procedure may still be defined.

Clinical recommendation and subsequent treatment should be assessed by the treating physician based on the patient's status and their needs and preferences, which should alleviate their difficulties and improve the quality of life of the patient suffering from the osteonecrosis of the jaw. Compliance with preventive measures before and during the antiresorptive treatment seems beneficial; however, it is also considerably complicated.

The ARM-induced osteonecrosis of the jaw poses a current problem with a number of yet unanswered questions. In general, it is believed that the cause of the osteonecrosis is multifactorial, dependent not only on administered preparations, but also on the underlying oncological disease, type of chemotherapy, hormonal treatment, associated illnesses, age and addiction case history. It is therefore necessary to correctly set up and indicate the pharmacological and surgical treatment, monitor the bone antiresorptive therapy, with focus on prevention and complications.

## Conflict of interest

No conflict of interest.

## Author details

Vladimira Schwartzova<sup>1</sup>, Marcel Riznic<sup>2\*</sup>, Branislav Borza<sup>1</sup> and Peter Kizek<sup>1</sup>

\*Address all correspondence to: dr.riznic@gmail.com

<sup>1</sup> Dental Clinic, Kosice, Slovakia

<sup>2</sup> Department of Stomatology and Maxillofacial Surgery, Kosice, Slovakia

## References

- [1] Ruggiero I et al. American association of oral and maxillofacial surgeons special committee position paper on medication-related osteonecrosis of the jaw. *Journal of Oral and Maxillofacial Surgery*. 2014;**72**(10):1938-1956
- [2] Abdu-id MH et al. "Bis-Phossy jaws" —High and low risk factors for bisphosphonate-induced osteonecrosis of the jaw. *Journal of Cranio-Maxillo-Facial Surgery*. 2008;**36**(2): 95-103

- [3] Otto S et al. Osteoporosis and bisphosphonates-related osteonecrosis of the jaw: Not just a sporadic coincidence—A multi-centre study. *Journal of Cranio-Maxillo-Facial Surgery*. 2011;**39**(4):272-277
- [4] Ruggiero LS et al. American association of oral and maxillofacial surgeons positions paper on bisphosphonate-related osteonecrosis of the jaws—2009 Update. *Journal of Oral and Maxillofacial Surgery*. 2009;**67**(Suppl 1):2-12
- [5] Yamashita J, McCauley LK, Van Poznak C. Updates on osteonecrosis of the jaw. *Current Opinion in Supportive and Palliative Care*. 2010;**4**:200-206
- [6] Weinstein RS, Roberson PK, Manolagas SC. Giant osteoclast formation and long-term oral bisphosphonate therapy. *The New England Journal of Medicine*. 2009;**360**:53-62
- [7] Cheung MS, Glorieux FH, Rauch F. Large osteoclasts in pediatric osteogenesis imperfecta patients receiving intravenous pamidronate. *Journal of Bone and Mineral Research*. 2009;**24**:669-674
- [8] Allen MR, Kubek DJ, Burr DB. Cancer treatment dosing regimens of zoledronic acid result in near-complete suppression of mandible intracortical bone remodeling in Beagle dogs. *Journal of Bone and Mineral Research*. 2010;**25**:98-105
- [9] Bertoldo F et al. Bisphosphonates and osteomyelitis of the jaw: A pathogenic puzzle. *Nature Clinical Practice Oncology*. 2007;**4**(12):711-721
- [10] Aghaloo TL, Kang B, Sung EC, et al. Periodontal disease and bisphosphonates induce osteonecrosis of the jaws in the rat. *Journal of Bone and Mineral Research*. 2011;**26**: 1871-1882
- [11] Zaheer S, LeBoff M, Lewiecki EM. Denosumab for the treatment of osteoporosis. *Expert Opinion on Drug Metabolism & Toxicology*. 2015 Mar;**11**(3):461-470
- [12] Harper RP, Fung E. Resolution of bisphosphonate-associated osteonecrosis of the mandible: Possible application for intermittent low-dose parathyroid hormone [Rhpth (1-34)]. *Journal of Oral and Maxillofacial Surgery*. 2007;**65**:573-580
- [13] Kwon YD, Lee DW, Choi BJ, et al. Short-term teriparatide therapy as an adjunctive modality for bisphosphonate-related osteonecrosis of the jaws. *Osteoporosis International*. 2012;**23**(11):2721-2725

