

We are IntechOpen, the world's leading publisher of Open Access books Built by scientists, for scientists

6,900

Open access books available

186,000

International authors and editors

200M

Downloads

Our authors are among the

154

Countries delivered to

TOP 1%

most cited scientists

12.2%

Contributors from top 500 universities



WEB OF SCIENCE™

Selection of our books indexed in the Book Citation Index
in Web of Science™ Core Collection (BKCI)

Interested in publishing with us?
Contact book.department@intechopen.com

Numbers displayed above are based on latest data collected.
For more information visit www.intechopen.com



All-in-One Mesh Hernioplasty: A New Procedure for Inguinal Hernia Repair

Angelo Guttadauro, Matteo Maternini,
Nicoletta Pecora, Marco Chiarelli,
Valentina Riggio and Francesco Gabrielli

Additional information is available at the end of the chapter

<http://dx.doi.org/10.5772/intechopen.75387>

Abstract

Since the 1970s, when biocompatible meshes were introduced with the consequent decrease of recurrence, one of the priorities in inguinal hernia surgery was that of minimizing postoperative chronic pain. All technical variations, proposed during the past years in order to improve patient's comfort, reported a variable incidence of chronic neuralgia. The procedure we describe, applicable to all cases of primary inguinal hernia, employs a smaller pre-cut single mesh that covers all weak areas of the inguinal canal and is enveloped in a fibro-cremasteric sheath, avoiding contact of the prosthesis with neural structures. The new procedure, already performed on 250 patients, aims to improve patients' comfort and to reduce the incidence of chronic neuralgia.

Keywords: inguinal hernioplasty, tension-free hernia repair, hernioplasty technique, mesh for groin hernia, neuralgia posthernioplasty

1. Introduction

A major goal of modern surgery is to achieve better outcomes with less invasive techniques while sparing functional tissue and reducing pain and long-term complications. Pain and restriction of daily activity rank high among patient concerns. The variety of surgical procedures for inguinal hernia repair might arouse suspicion that, because none to date has proven effective, old techniques need to be refined and new ones developed.

In 1974, Lichtenstein revolutionized hernia surgery with the use of tension-free mesh repair that would eventually supplant sutured procedures (Bassini, Shouldice) in which the area of weakness is strengthened by overlapping and suturing the musculoaponeurotic structures of the inguinal canal. Placement of an easy-to-use, biocompatible mesh prosthesis allowed for inguinal hernia repair was tension-free and so could potentially reduce its recurrence [1]. In the Lichtenstein procedure, a prosthetic mesh is placed under the external oblique muscle fascia (**Figure 1**) and fixed without tension to the surrounding musculoaponeurotic structures, thus reducing the rate of hernia recurrence. Later, Trabucco developed a pre-shaped monofilament polypropylene mesh that is inserted under the aponeurosis of the external oblique muscle where it is held in place by intra-abdominal pressure. This sutureless, tension-free technique also entails the placement of a “plug” prosthesis to reinforce the area of weakness of the floor of the inguinal canal after the hernia sac has been reduced in the abdominal cavity (**Figure 1**) [2]. Fibroblastic proliferation through the mesh and formation of fibrin already hours after prosthesis implantation, together with precipitation of collagen, provide for a natural seal of the mesh and tension-free hernioplasty.

Several problems remain, however:

- Persistent postoperative pain that may progress to chronic neuropathic or somatic pain

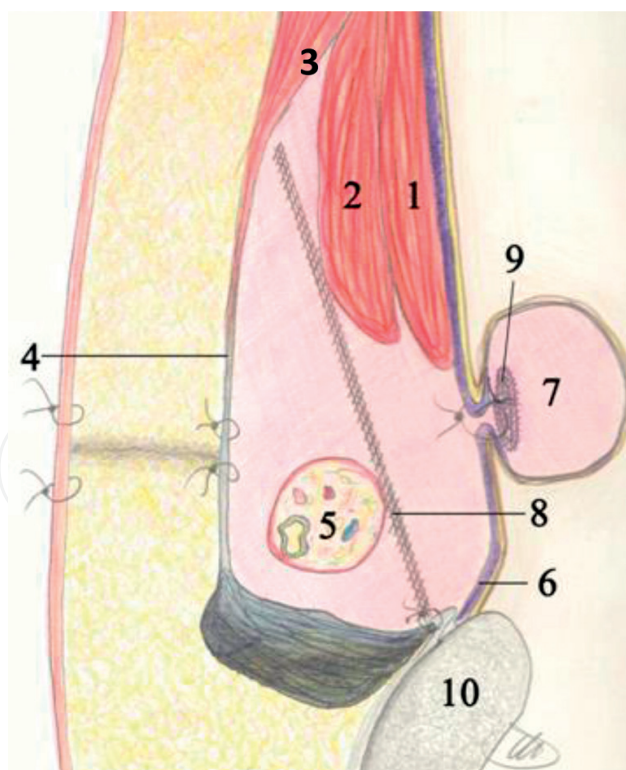


Figure 1. (1) Transverse muscle, (2) internal oblique muscle, (3) external oblique muscle, (4) aponeurosis of external oblique muscle, (5) spermatic cord, (6) transversalis fascia, (7) reduced direct inguinal hernia and sutured transversalis fascia, (8) prosthetic mesh placed according to Lichtenstein procedure, (9) prosthetic plug inserted into point of weakness according to Trabucco repair, (10) pubic tubercle.

- Severe complications, albeit rare, due to plug migration
- Long-term risk of recurrence

Postoperative pain is usually transient and subjective and varies from one patient to another. Somatic pain arises from the presence of a foreign body (prosthetic mesh) which, owing to its size and implantation site, may affect muscles. Chronic neuropathic pain is often debilitating and generally caused by nerve entrapment in the subaponeurotic layer [3, 4], which is why some authors have underlined the need to isolate or transect nerves to prevent the development of chronic pain [5, 6]. Nerve resection is known to alter sensation of the skin area where the nerve has been resected and may induce a neuralgic effect, with the formation of a neuroma that causes chronic pain. Over the years, a variety of “plugs and patches,” as well as surgical techniques (e.g., laparoscopy), have been developed without substantially changing the situation [7–10].

In 2012 a newly designed surgical technique began to be standardized for the placement of a pre-cut mesh prosthesis that would reinforce the areas of weakness of the inguinal canal without affecting the nerve structures of the inguinal canal. To better illustrate this system, a brief anatomic review is given below.

2. Anatomy of the inguinal region

The inguinal canal is located at the midpoint of the inguinal ligament that runs between the anterior superior iliac spine (ASIS) and the pubic tubercle. It is about 5 cm long and passes obliquely downward and inward. It is bounded by four walls: anteriorly, the aponeurosis of the external oblique muscle; posteriorly, the transversalis fascia; superiorly (roof), the fascia of the internal oblique and transverse abdominal muscles (joined by the conjoint tendon in 5% of cases); and inferiorly (floor), the rolled up portion (lacunar ligament) of the inguinal ligament. The deep inguinal ring is an opening in the transversalis fascia; it is located between the epigastric vessels and the fascia of the internal oblique and the transverse muscles and reinforced by Hesselbach's ligament. The superficial inguinal ring is a triangular opening formed by the external oblique where it inserts on the pubic crest and the pubic tubercle. It is bounded on either side by the margins of the opening in the aponeurosis, the crura of the ring. Lying superficial to the inguinal aponeurosis and deep to the superficial abdominal ring is Colles' ligament (reflected inguinal ligament), a triangular fibrous connective tissue band running from the pubic bone and lacunar ligament medially and upward to the linea alba [11–13].

The posterior wall of the inguinal canal is reinforced laterally by Hesselbach's (interfoveolar) ligament, medially by the conjoint tendon, and the reflected part of Colles' ligament at the distal end of Henle's ligament (formed by the union of the inferior terminal fibers of the aponeurosis of the transverse muscle and the iliopubic band) and is present only in the central part of the transversalis fascia. This oval area is particularly weak between the lower edge of the aponeurosis of the transverse muscle superiorly, the iliopubic band (thickening of the transversalis fascia near the inguinal ligament) inferiorly, Henle's ligament at the medial end, the junction of the inferior edge of the transverse muscle, and the iliopubic band at the lateral end (**Figure 2**) [11–13].

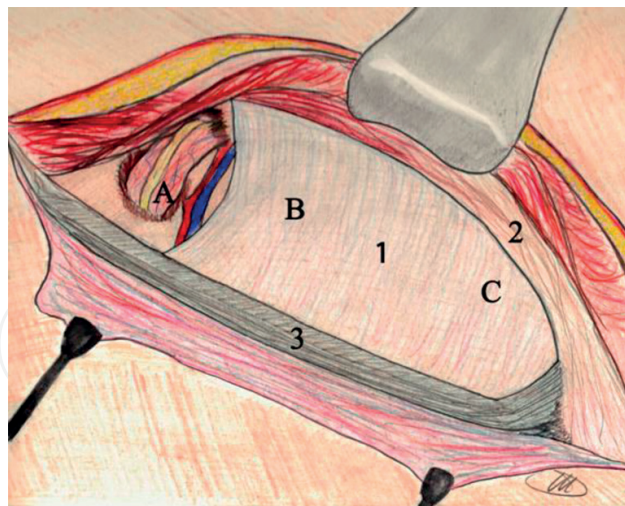


Figure 2. (1) Transversalis fascia (inguinal hiatus), (2) falx inguinalis, (3) inguinal ligament (iliopubic band), (A) lateral fossa (origin of external oblique inguinal hernia), (B) middle fossa (origin of direct inguinal hernia), (C) medial fossa (origin of internal oblique inguinal hernia).

This area of weakness comprises the deep inguinal ring, the site of indirect hernias, the area underlying it, and the site of direct hernias. Topographically, beneath the transversalis fascia, the inferior epigastric vessels run vertically and medially to the deep inguinal ring. Medial to the epigastric vessels and passing outward and downward is the remnant of the umbilical artery. Based on their relationship with the epigastric vessels and the remnant of the umbilical artery (**Figure 3**), three types of hernia can be distinguished:

1. External oblique hernia originates from the deep inguinal ring in an area of weakness termed the lateral fossa.
2. Direct hernia originates from an aperture in the posterior wall of the inguinal canal between the epigastric vessels and the remnant umbilical artery in an area of weakness termed the middle fossa.
3. Internal oblique hernia protrudes medially to the site of direct hernia in an area of weakness between the remnant of the umbilical artery and the urachus, termed the medial fossa. This type of hernia occurs rarely owing to the protective effect of the conjoint tendon, Colles' ligament, and Henle's ligament.

This universally recognized classification of inguinal hernia was recently simplified by the European Hernia Society into two areas of weakness of the inguinal canal floor: the medial area (direct hernias) and the lateral area (indirect hernias) [14].

Detailed anatomic study of the inguinal region shows how the transversalis fascia, together with the aponeurosis of the oblique internal and transverse abdominal muscles, by virtue of their anatomic structure and function, works to retain the content of the abdominal cavity. The aponeurosis of the external oblique muscle appears to have two roles: to cover and to oppose intra-abdominal pressure. In 1884 Edoardo Bassini conceived of a method to reinforce




Figure 3. (1) Epigastric vessels, (2) spermatic cord, (3) transversalis fascia, (4) remnant of umbilical artery, (5) external oblique inguinal hernia, (6) direct inguinal hernia, (7) internal oblique inguinal hernia.

the wall using a triple layer in which the transversalis fascia, along with the internal oblique and the transverse muscles, was sutured to the posterior border of the inguinal (Poupart's) ligament. The drawback to this technique was that tension on the sutures led to high rates of hernia recurrence. To demonstrate the retainment capability of the transversalis fascia, Bassini showed that incidence of recurrence was higher when a double layer comprising only the internal oblique and the transverse muscles was employed to repair the defect. Later, Lichtenstein and Trabucco independently understood the need to reinforce the wall weakness using instead of sutures a mesh prosthesis with or without placing a "plug" in the weak point of the transversalis fascia. The drastic reduction in recurrence rates with the use of these techniques has made prosthesis hernioplasty the gold standard in inguinal hernia repair [1, 2].

Observing the anatomy of the transversalis fascia, we can imagine it as a thin layer lining the abdominal cavity, contracting relationships with the muscles and aponeurotic and bony structures. Cephalad fuses with the diaphragmatic fascia, in contact with the lower ribs, the first lumbar vertebrae, and the lumbodorsal fascia. Inferolaterally, it is continuous with the psoas fascia and the quadratus lumborum muscles and anteriorly with the rectus abdominis muscles and the aponeurosis of the transverse muscle. The image is that of a sac hung on the musculoaponeurotic and bony structures of the upper abdomen, with posterior and lateral connections in which the only area of passage is the semicircular arch of Douglas. The transversalis fascia then thickens medially (Henle's ligament) at the lateral concave edge (he called it the *falx inguinalis*) which inserts at its base in Cooper's ligament and anteriorly attaches to the conjoint tendon [11–13].

More lateral to the arch of Douglas is a thickening that continues to Hesselbach's (interfoveolar) ligament and inserts between the two fossas, the superficial inguinal ring and the medial fossa. It then inserts in the inguinal ligament after having circled the deep inguinal ring inferiorly. More laterally, the transversalis fascia forms a U-shaped sling around the ring and is continuous with the internal spermatic fascia. The so-called transversalis fascial sling, on contraction of the transverse muscle due to increased intra-abdominal pressure, is flattened at

its base, producing partial closure of the ring. The transversalis fascia performs a containing function by virtue of its bony and musculoaponeurotic attachments, particularly in the upper abdomen, attachment of Henle's ligament to Cooper's ligament and Hesselbach's ligament, and its attachment to the transverse muscle (transversalis fascial sling) and valve mechanism.

Other structures that assist in this function include:

- The internal oblique muscle surrounding the deep inguinal ring superiorly and then forming the medial wall of the inguinal canal. Contraction of the transversus abdominis causes this structure to move down toward the inguinal (Keith) ligament in a kind of protective shutter mechanism, which reinforces the weakest area of the groin on elevation of intra-abdominal pressure.
- The transverse muscle, which forms the medial wall of the inguinal canal and, together with the internal oblique muscle, unites in the conjoint tendon. The conjoint tendon then forms a lateral concavity and inserts on the pubic symphysis, the pubic tubercle, and Cooper's ligament. Posteriorly, it fuses with Henle's ligament (falx inguinalis). When the transverse muscle contracts, the deep inguinal ring narrows via the action of Hesselbach's ligament (Lytle's sling), another protective mechanism.
- Colles' ligament is made of fibers of the aponeurosis of the contralateral external oblique muscle that crosses at the midline.

The falx inguinalis, together with the inguinal ligament, forms the curved upper edge of the inguinal hiatus; its base is formed by the inguinal ligament (**Figure 2**). In healthy conditions, the falx inguinalis and the transversalis fascia contribute synergistically to retainment of the walls of the inguinal canal [11–13].

Three principal nerve structures pass through the inguinal canal:

1. The iliohypogastric nerve (anterior branch) runs along the internal oblique muscle, parallel and cranial to the spermatic cord; it exits the inguinal canal through a small aperture above the superficial inguinal ring.
2. The ilioinguinal nerve runs along the anterosuperior border of the spermatic cord between the cremasteric fibers.
3. The genital branch of the genitofemoral nerve enters the inguinal canal medial to the deep inguinal ring and runs along the posterolateral cremasteric fascia together with the external spermatic vessels [11–13].

2.1. Pathophysiological aspects

Changes in strength and resistance of anatomical structures, often associated with congenital or acquired degenerative disorders, and remodeling of collagen and elastic fibers can lead to widening of the deep inguinal ring and weakening of the posterior wall of the inguinal canal

by increased intra-abdominal pressure. The abdominal cavity can be compared to a container holding a dense, viscous content. Since its walls are subject to the laws of plasticity, the content of the abdominal cavity exerts a force per unit area perpendicularly to a surface, commonly defined as pressure. An imbalance between the force of intra-abdominal pressure and resistance of the inguinal wall at an area of weakness of the inguinal canal can result in plastic deformation that will increase even when the pressure remains unchanged [15]. It is this deformation at the points of weakness of the transversalis fascia that leads to its weakening.

The work by Wegh and Read showed that the fascia of hernia patients had low hydroxyproline content [16]. Histology demonstrated in many cases degeneration of collagen and elastic fibers in the musculoaponeurosis of the transverse muscle, like that seen in patients with Marfan syndrome [17, 18], apparently due to collagen catabolism because of a metabolic defect [18]. The use of prosthetic material that can promote rapid fibroblast proliferation is therefore required for reinforcing the inguinal wall and renders its resistance enough to ensure mesh stability after the patient has left the operating table, assumes the upright position, and begins to go about his daily activities.

Lichtenstein procedures are performed in part directly on the transversalis fascia since the mesh is placed in the subaponeurotic space (anterior wall of the inguinal canal) [1], and Trabucco procedures involve the floor of the inguinal canal through the application of plugs. The use of isolated plugs does not reduce the risk of recurrence at the site of insertion nor recurrence at other sites due to differences in the distribution of pressure. Hence, there is a need to apply also a prosthetic mesh to reinforce the aponeurosis of the external oblique muscle [2]. The support mechanism is similar to that provided by hernia support garments that apply targeted compression to prevent failure of the inguinal canal floor due to elevation of intra-abdominal pressure.

The absence of tension on the musculoaponeurotic layer after application of a prosthetic mesh under the anterior wall of the inguinal canal has reduced hernia recurrence rates; however, this type of mesh can cause pain due to contact with the musculoaponeurotic and nerve structures or induce a foreign body sensation due to wrinkling of the mesh. Analysis of hernia recurrence causes shows that they always occur in an area beneath a subaponeurotic mesh that has become well integrated with the anterior wall of the inguinal canal. In a review of 1276 patients operated on for hernia recurrence, Lichtenstein found a hernia defect near the pubic tubercle in 47% of cases, at the deep inguinal ring in 40%, and involving the entire suture in 13% [1].

This gave rise to the idea of a tension-free mesh prosthesis designed to provide direct reinforcement of the entire area of weakness of the inguinal canal floor, thus restoring its normal function. In addition, a technique was developed to apply a mesh that would not interfere with nerves and muscles in the area. Mesh shape and size were derived from repeated measurement of the inguinal canal floor for targeted application. No isolated plugs or subaponeurotic patches are needed. The mesh conforms to anatomy, with the less use of foreign body material, thus reducing the risk of pain and increasing patient comfort.

Furthermore, the presence of a missed hernia sac, which may be the cause of early hernia recurrence after a Lichtenstein or Trabucco procedure, is no longer possible. The areas of

weakness of the transversalis fascia at the floor of the inguinal canal are contemporaneously reinforced by apposition of a single prosthetic mesh designed to conform to the anatomy and function of the inguinal canal. The resulting rapid integration of fibroblasts into the mesh and the transversalis fascia strengthens the new wall, rendering the entire area of weakness of the inguinal canal floor more resistant to weakening under elevated intra-abdominal pressure.

3. Surgical technique

A skin incision is made, the aponeurosis of the external oblique muscle is opened, and the spermatic cord is identified. The subaponeurotic nerves (iliohypogastric and ilioinguinal nerves) need not be identified. Using a diathermy coagulator, a longitudinal medial incision is made along the cremasteric muscle and external spermatic cord fascia (fibrous cremasteric sheath); these are then separated from the spermatic cord to the inguinal ligament. The cremaster muscle, a continuation of the internal oblique abdominal muscle, arises at the pubic tubercle and the inguinal ligament. It forms the middle covering layer of the spermatic cord between the external and internal spermatic fascias, as it passes through the inguinal canal and distally to the common tunica vaginalis, an extroflexion of the transverse fascia.

The medial borders of the cremasteric sheath are grasped with Klemmer clamps (**Figure 4**), and the hernia sac is identified and separated from the spermatic cord. In direct or internal oblique inguinal hernia, the sac should be isolated from the surrounding anatomical structures and the transversalis fascia up to its neck when present. The area of weakness is then flattened by plicating the transversalis fascia. The deep internal inguinal ring is then prepared for applying section A of the mesh (**Figure 5**). In external oblique inguinal hernia, the hernia sac should be freed from the deep inguinal ring so that it can be completely reduced in the abdominal cavity. If present, a

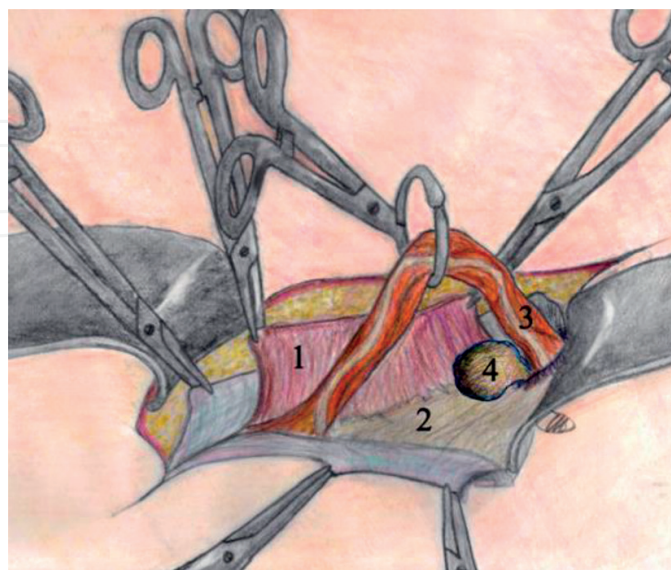


Figure 4. (1) Cremasteric sheath, (2) transversalis fascia, (3) spermatic cord, (4) external oblique inguinal hernia.

voluminous prehernia lipoma can be resected or reduced in the abdominal cavity together with the hernia sac. If necessary, the deep inguinal ring is then narrowed with resorbable interrupted sutures. In all cases, the posterior wall is reinforced with the prosthetic mesh, as shown in **Figure 5**.

This innovative, semiresorbable pre-cut mesh (70% polyglycolic acid and 30% polypropylene) is designed to reinforce the entire floor of the inguinal canal. It is shaped to conform to anatomy without the risk of wrinkling or need to trim it. Polypropylene is noted for its ability to induce an inflammatory fibrous reaction that promotes rapid, firm adhesion of the mesh onto tissues [19]. The mesh is available as a large-pore woven mesh that promotes infiltration and integration of connective tissue [16, 20, 21]. Less susceptible to bacterial colonization, the mesh can be left in place in case of infection [20, 22, 23].

Section A of the mesh is applied to surround the spermatic cord contents and form a cone around them by overlapping the two tails (A1 and A2). The length of the tails can be shortened to adjust the opening of the cone apex to the diameter of the spermatic cord. If present, diffuse lipomatosis

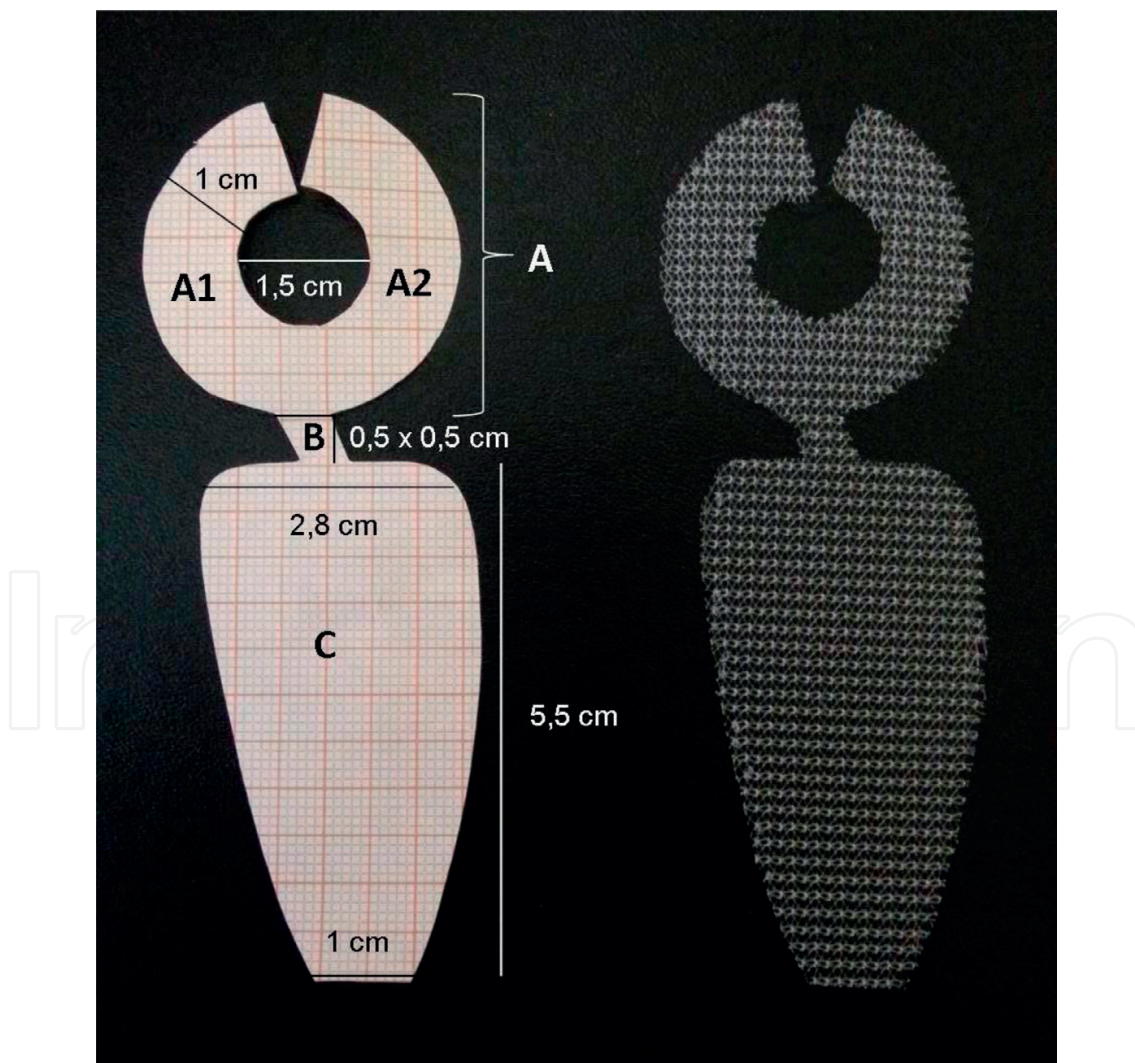


Figure 5. “All-in-one mesh” device.

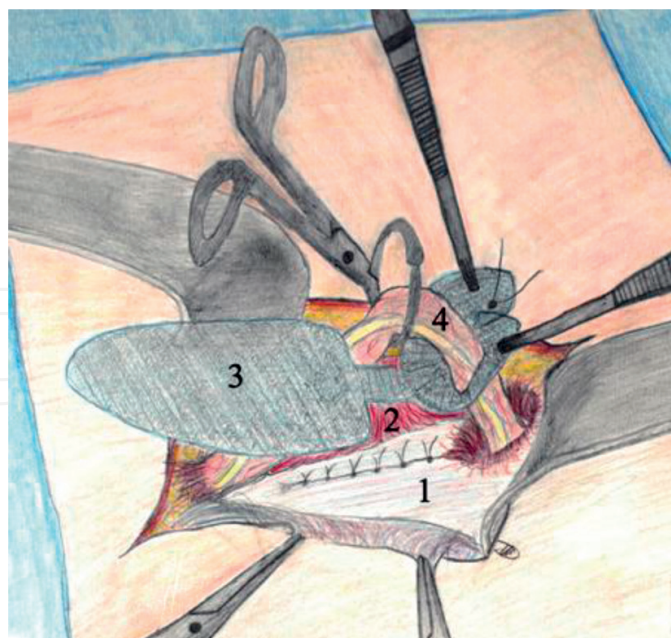


Figure 6. (1) Transversalis fascia after flattening the direct inguinal hernia, (2) isolation of the cremasteric sheath, (3) prosthetic mesh reinforcing the inguinal hiatus, (4) spermatic cord.

of the spermatic cord can be resected. The cone is closed with a suture tying the overlapping tails. While the assistant elevates the spermatic cord with Bottini forceps, the surgeon inserts the prosthetic ring into the deep inguinal ring using two anatomic forceps (**Figure 6**).

The cone serves to strengthen the area of weakness at the deep inguinal ring. When inserted into the ring, the cone depth is such that the implant does not interfere with or compromise the many underlying vessels, including the iliac vein medial to the artery and collateral vessels. Bendavid reported that the distance between the iliac vein and the transversalis fascia at the deep inguinal ring is between 0.8 and 1.2 cm [24]. A plug inserted any deeper would certainly comprise vessel function.

Sections B and C of the mesh are placed on the transversalis fascia. Section B connects section A in a medial angle to section C, which covers the entire floor of the inguinal canal and reinforces the middle and the medial fossa. So applied, the mesh sits laterally with its lesser convexity abutting the concavity of the inguinal ligament and extends medially to the conjoint tendon or above it, depending on the length of the canal, so as to avoid mesh wrinkling. A smooth mesh surface prevents the formation of dead spaces that delay fibroblast infiltration to the site and increase the risk of mesh-related infection and hernia recurrence. The distal end of section C (about 1 cm) is fixed to the pubic tubercle (not the periosteum) using resorbable suture (**Figure 7**). The shape of the mesh is configured so that it can be used for left- and right-sided inguinal hernia repair.

The medial edge of the previously identified cremasteric muscle is retrieved and sutured to the musculoaponeurotic structures using a running resorbable suture to cover the mesh (**Figure 8**). The cremaster serves only as a cover to prevent contact between the spermatic cord and the underlying mesh. If the muscle is injured during dissection, it can be repaired with

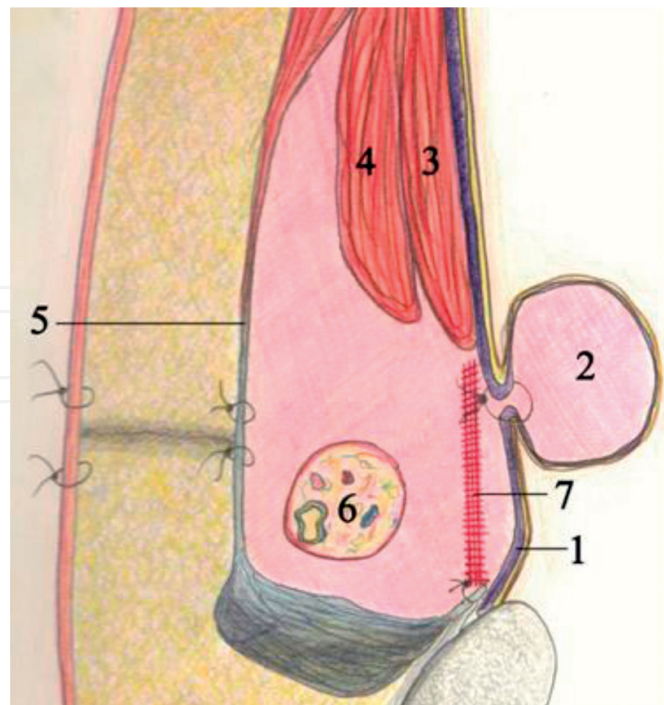


Figure 7. (1) Transversalis fascia, (2) reduced direct inguinal hernia flattened by suturing the transversalis fascia, (3) transverse muscle, (4) internal oblique muscle, (5) aponeurosis of the external oblique muscle, (6) spermatic cord, (7) all-in-one mesh placed as described in the text. The special mesh configuration allows for deployment in left and right hernioplasty.

a resorbable suture. The spermatic cord is returned to its natural position, and the external oblique aponeurosis is closed over the cord with interrupted resorbable sutures, as are the superficial layers.

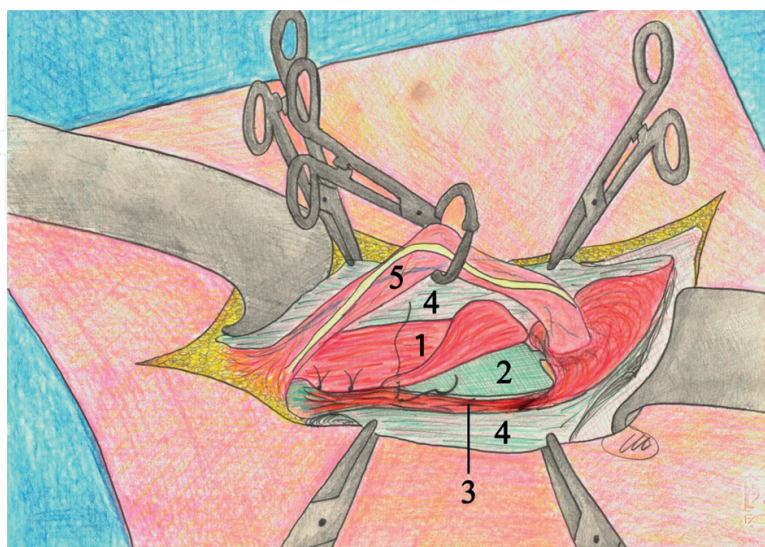


Figure 8. (1) Cremaster, (2) prosthetic mesh, (3) musculoaponeurotic layer, (4) external oblique muscle fascia, (5) spermatic cord.

Fixed between the deep inguinal ring and the pubic tubercle, the mesh reinforces the posterior inguinal wall as it extends between the cremaster muscle and the transversalis fascia. The spermatic cord, subaponeurotic structures, and pressure exerted by the tissues compress it. Rapid fibroblast infiltration of the prosthesis incorporates it into the tissues to form a triple retaining layer, without the formation of dead space which could lead to the development of hematoma and/or seroma or nerve entrapment, all of which are causes of chronic pain that is notoriously difficult to treat. Surgery is performed with local anesthesia [25].

3.1. Advantages

Compared with other techniques currently in use, this novel procedure has the following advantages:

- 1. A relatively simple procedure with a short learning curve.
- 2. Shorter operating time and greater ease of execution, without the need to isolate nerves, prepare the site for subaponeurotic placement, trim the mesh, fix it to the surrounding musculoaponeurotic structures, or apply one or more plugs.

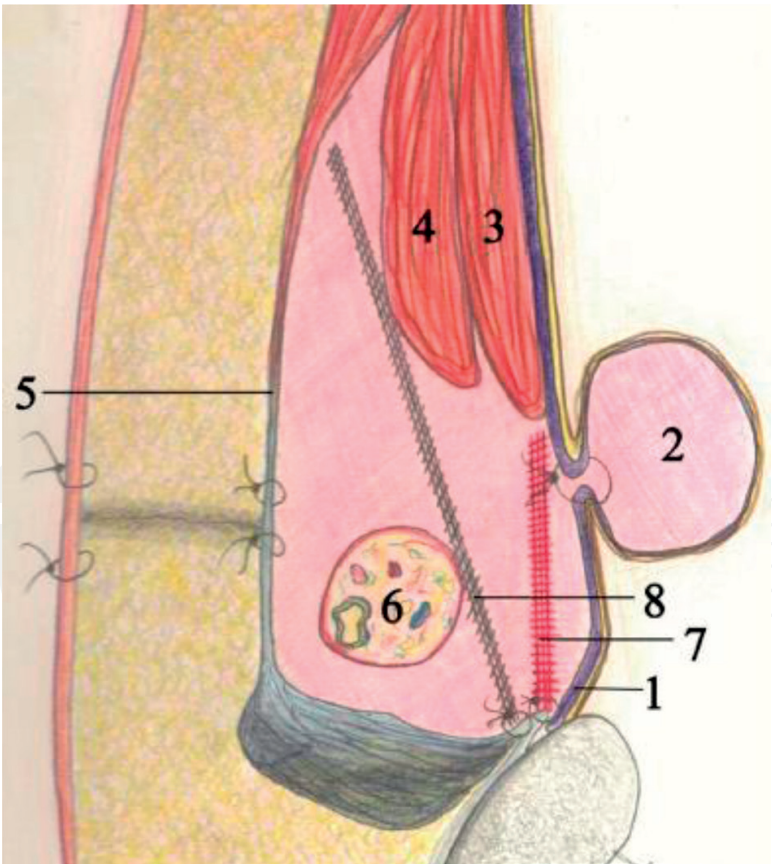


Figure 9. (1) Transversalis fascia, (2) reduced direct inguinal hernia flattened by suturing the transversalis fascia, (3) transverse muscle, (4) internal oblique muscle, (5) aponeurosis of the external oblique muscle, (6) spermatic cord, (7) all-in-one mesh placed as described in the text, (8) mesh prosthesis placed according to Lichtenstein procedure or modifications thereof.

3. Reduced surgical trauma, with no or minimal postoperative pain and rapid return to activities of daily living.
4. Minimal use of mesh material and elimination of problems related to mesh wrinkling.
5. Early hospital discharge.
6. Reduced risk of chronic neuropathic or somatic pain caused by contact of mesh prosthesis with nerves and surrounding musculoaponeurotic structures.
7. No plugs used; no risk of plug migration.
8. Potential reduction of hernia recurrence since the mesh covers the entire area of weakness of the floor of the inguinal canal and does not come into contact with the overlying layer, as occurs with the Lichtenstein and Trabucco procedures (**Figure 9**).

4. Personal case

4.1. Population

We considered a cohort of patients suffering from primary unilateral inguinal hernia that underwent the “all-in-one” mesh hernioplasty technique consecutively, at our institution. Hernias were divided according to the European Hernia Society criteria (**Table 1**). The work described has been carried out in accordance with the code of ethics of the World Medical Association. Written informed consent was obtained from each patient included in the study. All data of the cohort were registered in a specific database. Spinal anesthesia was adopted, and 2.0 g cefazolin was administrated intravenously over 30 minutes before the incision for all patients, and the procedure was performed on a 1-day surgery basis. From September 2012 to August 2015, we treated 250 adult patients for primary inguinal hernia, 241 males and 9 females with an average age of 61.7 years (range, 22–90).

4.2. Follow-up

Postoperative pain was gauged on the ward by a surgeon of the team. At discharge, all patients received a data sheet designed for the evaluation of postoperative pain using visual analogue scale (VAS) score, quantity of pain medication, and any postoperative discomfort. The patient's discomfort was assessed in terms of limitation of daily activities during the postoperative period, and return to work, and sports. Patients were asked for an overall opinion on the operation, on the postoperative period, and on the final result. These data were recorded by patients themselves on data sheet after 1, 2, and 3 weeks from discharge. The first clinical evaluation was made 7 days after surgery by a member of the surgical team. The second and third week interviews were made on the phone. The postoperative data registered by patients were collected. Follow-up, made to evaluate local signs, any kind of chronic pain, any sensation of foreign body, and recurrence, took place at 3, 6, 12, 18, and 24 months after surgery in the outpatient clinic by a surgeon of the team. All patient data were collected in a database of our institution.

Type	No. of patients
P L1M0F0	53
P L2M0F0	53
P L3M0F0	33
P L2M2F0	24
P L1M1F0	20
P L0M2F0	16
P L0M1F0	12
P L3M3F0	12
P L1M2F0	12
P L0M3F0	8
P L1M3F0	3
P L2M1F0	2
P L2M3F0	1
P L3M2F0	1

Table 1. Hernias were divided according to the European hernia society classification.

4.3. Results

Three (1.2%) patients complained of urinary retention, 2 (0.8%) of orchitis, and 14 (5.6%) showed bruising of the external genitalia. No other early complications were reported. Pain reported by patients in the immediate postoperative period was slight (mean VAS score = 2.1). A total of 79 (31.6%) patients required no pain medication, while the remaining 171 (68.4%) were given nonnarcotic analgesics. Average VAS score during the first postoperative week 171 was 1.2, and 119 (47.6) patients took no medication (**Table 2**). During the second postoperative week, 8 (3.2%) subjects still complained of slight pain referred to the wound

VAS 0	46.8% (117 pts)
VAS 1	17.6% (44 pts)
VAS 2	17.6% (44 pts)
VAS 3	10.8% (27 pts)
VAS 4	3.2% (8 pts)
VAS 5	3.2% (8 pts)
VAS 6	0.8% (2 pts)

Average pain VAS 1.2; SD 1.5.

Table 2. Postoperative pain in the first week.

VAS 0	96.8% (242 pts)
VAS 1	0.8% (2 pts)
VAS 2	1.2% (3 pts)
VAS 3	1.2% (3 pts)
Average pain VAS 0.06; SD 0.4.	

Table 3. Postoperative pain in the second week.

(average VAS score = 0.06). None of the patients took medication (**Table 3**). During the third postoperative week, only 0.4% (1) of patients complained of slight pain (average VAS score 0.01) which needed no medication (**Table 4**). Only 23 (9.2%) subjects experienced slight limitations of normal activities during the first week (**Table 5**). Thirty (20.1%) patients were able to engage in sports as early as 1 week from surgery, while 46 (30.9%) started between 7 and 21 days after surgery. Patients underwent to planned follow-up at 3 months (50 patients), 6 months (35 patients), 12 months (25 patients), 18 months (35 patients +1 patient lost), and 24 months (104 patients). Average follow-up is 15 months. None of our patients suffered from postoperative neuralgia, sensation of foreign bodies, or even simply discomfort. One recurrence was seen. All patients seemed satisfied with the operation, the recovery, and the final result [25].

4.4. Discussion

Tension-free techniques dramatically reduced recurrence rates making them the standard in hernia surgery. A not negligible incidence of postoperative chronic neuralgia [8, 26, 27] brought the attention of surgeons to new precautions even with the use of meshes [28].

Postoperative pain is temporary, usually controlled by medication. When persistent after 3–6 months from surgery, pain becomes disabling and may compromise the patient's quality of life. Pain may be related to the presence of the mesh that, because of size and location, takes contact with muscular structures or caused by fibrotic entrapment of nerves by a subfascial prosthesis [4, 13]. Studies conducted on animals also showed perineural alterations with myelinic degeneration due to contact between nervous structures and mesh [29]. Therefore, there is a necessity of identifying and dissecting subfascial nerves [30] and even of dividing them to avoid chronic pain [5, 6]. New surgical techniques and numerous kinds of meshes were proposed in the past years in the attempt to reduce postoperative neuralgia; nevertheless, the results of these new procedures were not completely satisfactory [7–10].

VAS 0	99.6% (249 pts)
VAS 1	0.4% (1 pt)
Average pain VAS 1.2; SD 1.5.	

Table 4. Postoperative pain in the third week.

	First week n. pt	Second week n. pt	Third week n. pt
No restriction	227	246	250
Slight restriction	23	4	0
Severe restriction	0	0	0

Table 5. Restriction in daily activities.

This led to the setting of guidelines for prevention and treatment of this situation [31].

If we consider the areas of weakness within the inguinal canal from which the three types of hernia arise, we see an oval-shaped surface surrounded by known muscular and fascial structures on the canal's floor and a further weak zone in proximity to the deep inguinal ring (**Figure 2**).

The transversalis fascia is an important restraining element for both structure and functionality in a region lacking overlying muscular structures. Then, the idea of a prosthesis specifically shaped to obtain containment by acting directly on the weak areas of the transversalis fascia without involving muscular or nervous structures avoiding to place a sub-aponeurotic mesh. This allows the procedure more anatomical with minimal foreign body implantation.

The prosthesis size, defined after numerous measurements of the inguinal canal made at the operating table, is notably smaller than the ones used as of now, allowing a precise and smooth positioning in a different plane to where the nerves lie.

The weak areas along the transversalis fascia are strengthened, all at once, by the prosthesis (all-in-one mesh), so that losing a hernia sac can no longer happen [2].

Polypropylene was chosen because of its capacity of inducing a lively inflammatory and fibrotic response with quick and strong adhesion to adjacent tissues. A prompt fibroblastic reaction between transversalis fascia and mesh immediately takes place because of the absence of any dead space and quickly forms a new wall.

This new technique is simple to perform and guarantees quick discharge and return to normal activities without any long-term discomfort. The average operative time was 25 min. The surgeon needs not dissect the cremaster, which may cause damage to the nerves, nor create a subfascial "nest," because no mesh is inserted at that level.

Furthermore, no plugs nor mesh trimming are necessary, and the prosthesis does not have to be sutured to adjacent structures. The use of a smaller quantity of prosthetic material allows the envelopment of the mesh by the fibro-cremasteric sheath, avoiding contact with surrounding nerves. Because of its shape, the mesh is placed in a deeper site directly over the weak areas of the floor of the inguinal canal and, although smaller, it seems not to increase rate of recurrence.

The most common technique of Lichtenstein provides a prosthesis which, to remain on the transversalis fascia, must be fixed to the sides and becomes necessarily under aponeurotic in the upper third.

In our technique, the prosthesis is positioned and remains on the transversalis fascia because it is coated with the fibro-cremasteric sheath and it remains anchored on the inguinal floor with a single fixing point at the pubic level and with the prosthetic conical ring on the deep inguinal ring. It is not directly under-aponeurotic at any point, and it stays in place and therefore does not require lateral fixation.

In addition, the prosthesis is not in contact with the ilioinguinal and iliohypogastric nerves. Our paper is an observational cohort study with only midterm (2 years) follow-up. Clinical trials comparing the “all-in-one mesh” hernioplasty to the most common surgical techniques are required to obtain a validation of our procedure. Indeed, a much longer follow-up could highlight the actual recurrence rate of the new procedure.

5. Conclusion

This new procedure claims many technical advantages and helps the less experienced surgeon to avoid pitfalls in dealing with nerves. According to our series, “all-in-one mesh” hernioplasty presents a low rate of long-term complications. Employing a smaller amount of prosthetic material, placed where no contact with nerves occurs, avoids neuralgia and sensation of foreign body.

A multicenter study is underway to compare this new procedure with the most common techniques.

Author details

Angelo Guttadauro^{1*}, Matteo Maternini¹, Nicoletta Pecora¹, Marco Chiarelli²,
Valentina Riggio³ and Francesco Gabrielli¹

*Address all correspondence to: angelo.guttadauro@unimib.it

1 Department of Medicine and Surgery, General Surgery Unit, Istituti Clinici Zucchi,
University of Milano-Bicocca, Monza, Italy

2 General Surgery Unit, Ospedale di Lecco, Italy

3 Department of Medicine and Surgery, University of Milano-Bicocca, Italy

References

- [1] Lichtenstein IL. Herniorrhaphy. A personal experience with 6321 cases. *American Journal of Surgery*. 1987;**153**(6):553-559
- [2] Trabucco E, Trabucco A, Rollino R, et al. L'ernioplastica inguinale tension-free con rete presagomata senza suture secondo Trabucco. *Chirurgia*. 1998;**11**:142-148

- [3] Canzani M, Frattini F, Cavalli, et al. Trattamento chirurgico nel dolore cronico posternio-plastica. Atti del 110 Congresso SIC; 2008
- [4] Heise CP, Starling JR. Mesh inguinodynia: A new clinical syndrome after inguinal herniorrhaphy? Journal of the American College of Surgeons. 1998;**187**:514-518
- [5] Karakayali F, Oksuz E, Turk E, et al. Effectiveness of multiple neurectomies to prevent chronic groin pain after tension-free hernia repair. International Surgery. 2010;**95**:40-48
- [6] Mui WL, Ng CS, Fung TM, et al. Prophylactic ilioinguinal neurectomy in open inguinal hernia repair: A double-blind randomized controlled trial. Annals of Surgery. 2006;**244**:27-33
- [7] Amid PK. Groin hernia repair: Open techniques. World Journal of Surgery. 2005;**29**:1046-1051
- [8] Valenti G, Baldassarre E, Testa A, et al. Dynamic self-regulating prosthesis (protesi autoregolantesi dinamica): The long-term results in the treatment of primary inguinal hernias. The American Surgeon. 2006;**72**:244-248
- [9] Koeninger J, Redecke J, Butters M. Chronic pain after hernia repair: A randomized trial comparing Shouldice, Lichtenstein and TAPP. Langenbeck's Archives of Surgery. 2004;**389**:361-365
- [10] Birk D, Hess S, Garcia-Pardo C. Low recurrence rate and low chronic pain associated with inguinal hernia repair by laparoscopic placement of Parietex ProGrip™ mesh: Clinical outcomes of 220 hernias 340 with mean follow-up at 23 months. Hernia. 2013;**17**:313-320
- [11] Testut L, Jacob O. Trattato di Anatomia Topografica. In: UTET, editor. Torino. 1967. Vol. II 405-431, Vol. III 568-576
- [12] Terranova O, Battocchio F. La chirurgia delle ernie della regione inguinale e crurale. Anatomia. Padova: La Garangola; 1988
- [13] Pellissier E. Tecniche Chirurgiche Addominali. Anatomia Chirurgica Dell'inguine. Elsevier; 40-105. DOI: 10.1016/S1283-0798(07)49266-X
- [14] Miserez M, Alexandre JH, Campanelli G, et al. The European hernia society groin hernia classification: Simple and easy to remember. Hernia. 2007;**11**:113-116
- [15] Hoffman CH, Vinton Traverso A. Preperitoneal prosthetic herniorrhaphy. One surgeon's successful technique. Archives of Surgery. 1993;**128**(9):964-969
- [16] Campanelli G, Bottero L, Leopaldi E, et al. Cosa sta cambiando nella chirurgia dell'ernia inguinale. Chir Arch Trim. 1993;**17**:13-17
- [17] Campanelli G, Bottero L, Campagnoli P, et al. L'approccio pre-peritoneale in anestesia locale nella chirurgia delle recidive di ernia inguinale. Atti SPIGC; 1992

- [18] Nyhus LM, Pollak R, Bombeck CT, et al. The pre-peritoneal approach and prosthetic buttress repair for recurrent hernia. The evolution of a technique. *Annals of Surgery*. 1988;**208**(6):733-737
- [19] Bendavid R. L'intervento di Shouldice. Una tecnica per la riparazione dell'ernia inguinale. In: Terranova O, Battocchio F, editors. *La chirurgia delle ernie della regione inguinale e crurale*. La Garangola; 1988. pp. 76-83
- [20] Shulman AG, Amid PK, Lichtenstein IL. The "plug" repair of 1402 recurrent inguinal hernias. 20-year experience. *Archives of Surgery*. 1990;**125**(2):265-267
- [21] Shulman AG, Amid PK, Lichtenstein IL. Prosthetic mesh plug repair of femoral and recurrent inguinal hernias: The American experience. *Annals of the Royal College of Surgeons of England*. 1992;**74**(2):97-99
- [22] Gilbert A. Sutureless repair of inguinal hernia. *American Journal of Surgery*. 1992;**163**(3):331-335
- [23] Barnes JP Jr. Inguinal hernia repair with routine use of Marlex mesh. *Surgery, Gynecology & Obstetrics*. 1987;**165**(1):33-37
- [24] Bendavid R. The space of Bogros and the deep inguinal iliac circulation. *Surgery, Gynecology & Obstetrics*. 1992;**174**(5):356-357
- [25] Guttadauro A, Maternini M, Frassani S, et al. "All-in-one mesh" hernioplasty: A new procedure for primary inguinal hernia open repair. *Asian Journal of Surgery*. 2017; Aug 26. pii: S1015-9584(17)30162-8. DOI: 10.1016/j.j.PMID:28851612
- [26] Campanelli G, Sfeclan C, Cavalli M, et al. Reducing postoperative pain: The use of Tisseel for mesh fixation in inguinal hernia repair. *Surgical Technology International*. 2012;**22**:134-139
- [27] Bueno J, Serralta A, Planells M, et al. Inguinodynia after two inguinal herniorrhaphy methods. *Surgical Laparoscopy, Endoscopy & Percutaneous Techniques*. 2004;**14**:210-214
- [28] Lionetti R, Neola B, Dilillo S, et al. Sutureless hernioplasty with light-weight mesh and fibrin glue versus Lichtenstein procedure: A comparison of outcomes focusing on chronic postoperative pain. *Hernia*. 2012;**16**:127-131
- [29] Demirer S, Kepenekci I, Evirgen O, et al. The effect of polypropylene mesh on ilioinguinal nerve in open mesh repair of groin hernia. *The Journal of Surgical Research*. 2006;**131**:175-181
- [30] Alfieri S, Rotondi F, Di Miceli D, et al. Chronic pain after inguinal hernia mesh repair: Possible role of surgical manipulation of the inguinal nerves. A prospective multicentre study of 973 cases. *Chirurgia Italiana*. 2006;**58**:23-31
- [31] Alfieri S, Amid PK, Campanelli G, et al. International guidelines for prevention and management of post-operative chronic pain following inguinal hernia surgery. *Hernia*. 2011;**15**:239-249

