

We are IntechOpen, the world's leading publisher of Open Access books Built by scientists, for scientists

6,900

Open access books available

186,000

International authors and editors

200M

Downloads

Our authors are among the

154

Countries delivered to

TOP 1%

most cited scientists

12.2%

Contributors from top 500 universities



WEB OF SCIENCE™

Selection of our books indexed in the Book Citation Index
in Web of Science™ Core Collection (BKCI)

Interested in publishing with us?
Contact book.department@intechopen.com

Numbers displayed above are based on latest data collected.
For more information visit www.intechopen.com



Emergency and Current Approaches to Thoracic Traumas

Turkan Dubus

Additional information is available at the end of the chapter

<http://dx.doi.org/10.5772/intechopen.74713>

Abstract

Trauma is one of the main causes of death in the young population, and trauma-related deaths usually occur in the initial hours following the trauma and are frequently associated with bleeding. In elderly populations, physiological changes and concomitant conditions alleviate the negative consequences of trauma. In injuries to the head or spine, thoracic trauma is the trauma category that is mostly associated with a serious risk of mortality, being generally penetrating or blunt thoracic traumas. Of these, blunt thoracic traumas are more frequent and fatal than penetrating traumas and are caused most often by traffic accidents. The most common causes of death related to blunt thoracic trauma include injuries to the heart and main vessels, and in such cases, emergency resuscitation, early diagnosis, and fast and effective treatment could be life-saving. Penetrating thoracic traumas may result in intrathoracic organ injuries and develop following stab wounds, firearm injuries, and explosions and are likely to require very urgent interventions. Emergency medical interventions could be life-saving in the presence of penetrating thoracic trauma, while mortality in these cases is mostly due to respiratory problems and heart or lung pathologies.

Keywords: trauma, thorax, emergency, surgery

1. Introduction

Traumas are one of the main causes of mortality and morbidity worldwide, particularly among young people, and is the leading cause of death in those below 45 years of age and the fourth leading cause of death in all age groups combined [1]. Based on 2012 data from the World Health Organization (WHO), traffic accidents are the 9th leading cause of death worldwide, with more than 1.2 million people dying from traffic accidents every year [2]. Trauma-related

death occurs most frequently in the initial hours following the trauma, and is often associated with bleeding. It is, therefore, of vital importance that patients with general body trauma are urgently, accurately and reliably evaluated in emergency units and the source of bleeding identified [3].

Among all forms of trauma, thoracic traumas are the leading cause of mortality after cranial and vertebral traumas. In Turkey, thoracic traumas account for almost 10–15% of all trauma cases seen in emergency units, and approximately 70% of all of these are blunt traumas. The leading cause of blunt thoracic traumas is traffic accidents, while other causes include assault and falls from height, among others. Of all blunt thoracic traumas, almost 15% occur as isolated thoracic traumas, while the rest involve multi-organ traumas, which, in the line of frequency, are traumas of the extremities, head, abdomen, pelvis and vertebra. The rate of mortality is about 2–5% in all thoracic traumas, while this rate may increase to 35% if accompanied by multi-system injuries [4–7].

The outcome of a trauma is determined by the cause and severity of the trauma, as well as the physical status of the exposed individual. Hemodynamics and respiratory parameters gain importance in the presence of thoracic traumas, and possible outcomes may include bleeding, pneumothorax, contusions, heart failure and intrathoracic pressure changes, and such functional abnormalities as hypoxia and hypotension, which may occur due to mediastinal dislocations [4, 8]. The consequences of blunt thoracic traumas may range from simple rib fractures to more severe conditions, such as multiple displaced rib fractures, causing flail chest, tracheal bronchial ruptures and cardiovascular ruptures. The most frequent site affected by thoracic trauma is the thoracic wall, followed in order of frequency by the pleural membranes and lung parenchyma [9].

The most significant cause of mortality, on the other hand, is cardiac and major vessel injuries. Emergency resuscitation, preferential diagnosis, basic interventions (such as thoracentesis or catheter/tube thoracotomy) and effective treatment are the necessary interventions for patients presenting with a trauma. The first assessment should involve checking the circulation and airways. Sternotomies or and thoracotomies are required in 10% of all blunt injuries, while emergency thoracotomies are required in 1–2% of cases [8]. Around one-third of all deaths occur at the time of trauma, while the remaining two-thirds occur after presentation to the emergency unit and medical interventions. The period from the trauma until the first hospital admission is considered as the “golden time” [5], as mortalities could be decreased by almost 30% with the timely transfer of patients from the trauma site, the effective implemented emergency resuscitation, and the emergency diagnosis and interventions at the hospital. Due to the high probability of mortality and morbidity, patients with thoracic traumas should be routinely monitored by Chest Surgeons, Emergency Medicine Specialists, specialists from the other relevant fields, nurses and other healthcare providers, all of whom play significant roles in both the diagnosis and treatment of such patients [2].

The presence of other injuries, such as large bone fractures, head traumas, intoxication, brain hypoxia or shock findings, as identified during the physical examination of patients presenting

with blunt thoracic trauma, can lead to confusion among healthcare professionals, and so radiological imaging may become necessary [4–6]. In this respect, it is important to retain devices such as ultrasound and X-ray, electrocardiogram (ECG) and echocardiography (ECHO) for the monitoring of trauma patients in emergency clinics. Previous studies have shown that bedside ultrasonography provides more specific and reliable data than physical examinations in assessments of pleural fluid and pneumothorax at the time of initial evaluation when a patient presents to the emergency unit with thoracic trauma [10–13].

When compared with blunt thoracic traumas, penetrating thoracic traumas are less common. Gunshot injuries account for 5% of all thoracic traumas, while sharp object injuries account for almost 37% of cases [14, 15]. Penetrating traumas may occur in isolated regions that requires sudden and mechanical power, at the trauma site, the object may cause tension and contusion in the body, while very severe traumas, on the other hand, may result in organ rupture.

Currently, the probability of survival after a penetrating trauma will be higher when the transfer from the scene of the accident to hospital is quick, and as a result of improvements in the comfort of patient care. In conclusion, the urgent assessment of trauma patients and timely emergency interventions could be life-saving. Moreover, the type of sharp object involved and the time of trauma are crucial in penetrating thoracic injuries. A prospective study has shown that a thoracotomy may be required in 14% of stabbings and 15–20% of gunshot injuries [16]. Not every patient requires a thoracotomy, and so thoracotomy decisions should be based on clinical and radiological evaluations.

The present study aims to describe in detail the steps to be followed from the first presentation until medical intervention for the effective management of patients being referred with any thoracic trauma, and to discuss the current concepts related to the various types of thoracic traumas.

2. History

From Ancient Greece up to the modern era, most records of thoracic traumas are related to deadly penetrating thoracic injuries. The Edwin Smith Papyrus (3000BC) from the Egyptian era provided information on three patients with penetrating thoracic traumas, two of whom were treated conservatively, while an esophagus suture was used on a cervical esophageal injury in the other [17]. In the thirteenth century, Theodoric defined two forms of rib fracture, based on whether the end of the fracture was turned inward or outward. Ribs that were turned outward were reduced and connected to each other after the application of local medication. In 1767, Larrey spoke about the importance of occlusive dressing and tube drainage in patients with an open hemothorax, although the drainage system used in 1867 by Hillier has been reported to be the most similar to the one being used today [18]. World War II was a turning point in the history of trauma, with the importance of immediately closing the defect in the chest wall following a penetrating thoracic trauma being noted by everyone in the war [19].

3. Primary approaches in patients with thoracic trauma

Trauma patients in particular should be followed with simple and systematic interventions. In recent years, trauma patients in emergency clinics have usually been treated in line with the American College of Surgeons' advanced life support (ATLS = Advanced Trauma Life Support) protocol, which is classified into primary and secondary care. Primary care consists of approaches for the identification and emergency treatment of life-threatening problems in patients exposed to sudden trauma. The individual or individuals responsible for primary care play significant roles in any intervention carried out related to the survival of trauma patients. Primary care should follow the following stages, the order of which should never be changed: ensuring airway flow and fixation of the neck vertebra (A), evaluation of the respiratory system (B), circulatory system (C), consciousness (D) and total body evaluation (E), known as "ABCDE" [5, 20].

3.1. Initial evaluation of life-threatening thoracic trauma

Patients with thoracic traumas are evaluated according to the ATLS protocol. There are six potentially morbid conditions that may occur following thoracic trauma: massive hemothorax, tension pneumothorax, open pneumothorax, flail chest, cardiac tamponade, air embolism and respiratory obstruction. Respiratory obstructions may result in the development of stridor, apnea, cyanosis and subcutaneous emphysema. Broken teeth following trauma, secretions, the development of hematoma due to cervical bleeding, and injuries to the larynx or trachea may result in obstructions of the airways, and these generally represent an indication for emergency intubation [21].

3.2. Secondary evaluation of life-threatening thoracic trauma

Secondary care, on the other hand, comprises the urgent identification of potentially life-threatening conditions and their treatment. Even hemodynamically stable trauma patients should undergo a detailed total body evaluation, and advanced investigations and examinations should be performed by relevant specialists. Detailed investigations are crucial at this stage, as it is possible that some traumas may be overlooked during primary care. It is also important to obtain a detailed anamnesis during secondary care. In the following stage, all body parts of the trauma patients should be evaluated with a physical examination, ultrasonography and/or radiological investigations (such as direct radiographs of the lungs, vertebra, pelvis, extremities, computerized tomography and MRI, if needed), as required [4, 20].

4. Traumatic pneumothorax

Traumatic pneumothorax develops when air from the atmosphere or lung parenchyma infiltrates the pleural space following blunt or penetrating trauma. The most commonly encountered etiologic cause is injury of the pleura or the lungs due to rib fractures. In cases of blunt thoracic

trauma, the bulla or blebs that may already be present in the lungs may rupture, or tracheal bronchi injury may develop [22, 23]. Traumatic pneumothoraxes are classified into three groups as follows: simple, open and tension pneumothorax, which are detailed below.

4.1. Simple pneumothorax

Simple pneumothorax frequently develops secondary to rib fractures, but may in rare cases develop following barotrauma. The patient presents with major symptoms of pain and dyspnea, and respiratory sounds are decreased at the side of pneumothorax. Diagnosis is based on the visualization of the pleural line on a chest radiography. The air may be spontaneously resorbed in patients with mild pneumothorax, though it may be sufficient to monitor such cases under nasal oxygen therapy. A tube thoracostomy must be performed in moderate or advanced cases of pneumothorax. Considering that the pneumothorax may alleviate in patients connected to mechanical ventilators, a tube thoracostomy should not be delayed in these patients [6, 7].

4.2. Open pneumothorax

Open pneumothorax is defined as the deposition of air between the parietal and visceral pleural membranes. In cases of penetrating thoracic trauma, an open pneumothorax develops due following the infiltration of positive pressure atmospheric air into the pleural space after an injury to the thoracic wall and parietal pleura, which is a life-threatening condition that requires emergency intervention [24].

Pneumothorax may also develop as a result of injuries to the parietal pleura or small airways, even if there is no penetrating injury. With each inspiration of the patient, air enters into the pleural space through the open region on the thoracic wall, as the defect in the thoracic wall is shorter than the trachea and has a lower resistance. In the event of the defect being larger than 0.75-times the tracheal diameter, air enters through the defect instead of the trachea [25], and pushes the heart and major vessels, and the mediastinum to the opposite side. As the capacity of the thoracic space decreases during expiration, the air moves out, and the heart and other mediastinal structures relocate back. This is called “mediastinal flutter”. The patient develops hypoxia, asphyxia, respiratory acidosis and decreased cardiac output. Torsion of the vena cava inferior and superior also occurs. Cardiac output decreases upon the decrease in cardiac venous return, and the patient may go into cardiac arrest.

The first intervention for open pneumothorax should be the closure of the terminal end of the open defect on the thoracic wall in such a way to that the entry and exit of air is prevented. Alternatively, the pneumothorax could be totally closed, and the patient could be monitored following a tube thoracostomy (**Figure 1**) [22, 26].

4.3. Tension pneumothorax

Tension pneumothorax develops as a result of injury between the parietal and visceral pleural sheets, or injury to the trachea or bronchi. It may develop spontaneously or be iatrogenic, other

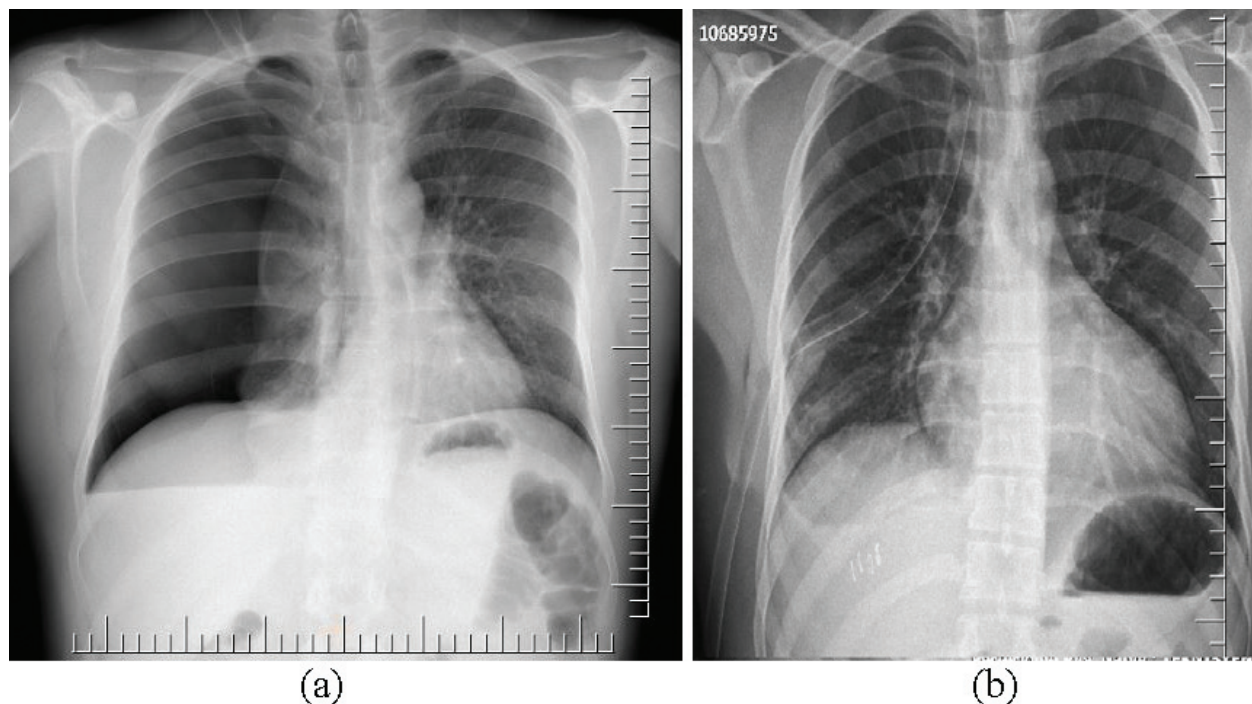


Figure 1. PA chest radiography of a case operated on with a right tube thoracostomy due to a developed traumatic right pneumothorax.

than being caused by trauma and is frequently encountered in closed pneumothorax. In tension pneumothorax, there is one-way air entry into the pleural space, and the increased air pressure within the pleural space puts pressure on the lung and pushes the mediastinum to the opposite side, which ultimately applies pressure on the other lung. Pushing the mediastinum along with the heart and other vascular structures towards the opposite thoracic space is called “mediastinal shift”.

Increased mediastinal shift impairs cardiac venous filling and presents a life-threatening condition, with the patient developing dyspnea, tachypnea, hypoxia, tachycardia, hypotension and agitation. Radiological imaging shows increased air pressure in the pleural space, the total collapse of the lung on the affected side, the widening of the costal intervals, the detrusion of the diaphragm and the translocation of the mediastinal structures to the opposite side. In the absence of an emergency diagnosis and tube thoracostomy, the patient may experience a dramatic course, including hypoxemia, metabolic acidosis, decreased cardiac output, cardiac arrest or even death.

As an emergency intervention, to empty the air in the pleural space, a thoracentesis can be performed at the point of interception between the midclavicular line and the 2nd intercostal space to empty the air from the intrapleural space, thus reducing the pressure on the lungs and vital organs. After this, a tube thoracotomy should be performed as soon as possible. Of all cases of tension pneumothorax resulting from penetrating thoracic traumas, 75% can be treated with a tube thoracostomy [27, 28].

5. Traumatic hemothorax

Hemothorax is the deposition of blood between the pleural membranes, and is most frequently caused by trauma. Traumatic hemothorax may originate from the thoracic wall, lungs, blood vessels, mediastinum or diaphragm. In blunt thoracic injuries, hemothorax frequently develops as a result of the bleeding of the pleura or the lung parenchyma, secondary to rib fractures [23]. While patients may remain asymptomatic, they may also present with hypovolemia or even shock, depending on the amount of bleeding. The development of hemothorax in structures with high blood flow, such as the heart, aorta, pulmonary artery, and vena cava inferior and superior, may very quickly become mortal [29, 30].

Hemothorax also has negative effects on the hemodynamics and respiratory system. Bleeding limits the expansion of the lung at the concerned region, and the mediastinum may shift to the opposite side if the bleeding continues. In an adult, the thorax may unilaterally be infiltrated by up to 6 L of blood. While bleeding of up to 500–750 mL can be tolerated, bleeding of 750–1500 mL can result in the development of tachycardia and hypotension, and signs of shock start to be seen in the presence of bleeding above 1500 mL (6). Diagnosis is made based on a direct lung radiography and thoracentesis, although thoracic CT is more specific for the diagnosis of hemothorax. Recently, in emergency clinics, bedside USI has also frequently been used for the diagnosis of hemothorax [6, 26, 29, 31].

A diagnosis of hemothorax can also be made when the hematocrit level in the sample obtained from the pleural space by thoracentesis is more than 50% of the hematocrit level measured in a spontaneously obtained blood sample. In the presence of penetrating traumas, hemothorax is most frequently caused by intercostal artery injuries, which, along with internal mammary artery injuries, are the most common injuries causing persistent bleeding, and therefore require thoracotomies. For patients who are taken for emergency thoracotomies due to hemorrhagic shock, even applying finger pressure to the bleeding artery can rapidly improve the patient's vital signs [32].

Treatment approaches to traumatic hemothorax vary, depending on whether the injury is blunt or penetrating, and on the amount of bleeding. In such cases, the first procedure to be performed should be a tube thoracostomy, as this can serve as an important guide for monitoring the amount of hemothorax and for the prevention of intrathoracic hematoma deposition. Vascular access should be established and appropriate fluid and blood product replacements, such as erythrocyte infusion, should be performed as necessary. The drainage of 1500 mL or more blood following a tube thoracostomy is considered as a massive hemothorax and represents an indication for a thoracotomy. Emergency thoracotomy indications in hemothorax: (**Table 1**) [23, 26, 31].

Major complications of traumatic hemothorax include thrombus/hematoma in the pleural space, pleural infection, pleural effusion and chylothorax. Clotting blood should be replaced within 1 week following the trauma, or else the hemothorax starts to be organized and the risk of infection increases (**Figure 2**) [7, 22].

-
1. Drainage ≥ 1500 mL after initial tube thoracostomy,
 2. 200 mL/h drainage during the first 2–4 h of follow-up,
 3. 100 mL/h drainage during the first 6–8 h of follow-up,
 4. ≥ 1500 mL/day drainage during the first 24 h,
 5. Progression of shock despite treatment.
-

Table 1. Emergency thoracotomy indications in hemothorax.

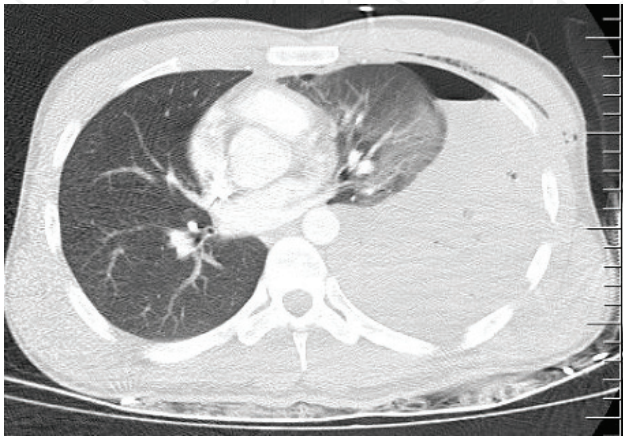


Figure 2. Thorax CT: Hemothorax following thoracic trauma.

6. Tube thoracostomy

A tube thoracostomy is performed for the treatment of traumatic pneumothorax and/or hemothorax, and it is an essential surgical intervention in cases requiring drainage of the pleural cavity in patients suffering a chest trauma. A tube thoracostomy is indicated for all open thoracic injuries, for pneumothorax of more than 10% and for radiologically-confirmed hemothorax. Even if there is no apparent pneumothorax and/or hemothorax, a tube thoracostomy could still be performed in intensive care patients with severe chest traumas who require mechanical ventilation. If a patient with penetrating or blunt chest trauma is transferred to the emergency unit when the vitals are completely lost, or about to be lost, it would not be erroneous to perform an emergency bilateral tube thoracostomy [9, 13, 33].

A tube thoracostomy is generally performed from the anterior axillary line, at the level of the 5th intercostal space from the lateral edge of the pectoralis major muscle. This is the region where the chest wall is at its thinnest, and is ideal for a tube thoracostomy. After local anesthesia, a skin incision is made 1–2 cm below the space where the chest tube is to be inserted, and using a clamp, the intercostal muscles are separated from the lower ribs to allow entry to the pleural space. Generally, a 28 or 32 F chest tube is inserted through this obliquely formed tunnel, and a closed underwater drainage system is formed by connecting the tube to the chest bottle. The chest tube should be directed as far as possible towards the apex for

pneumothorax, and towards the posterior and lateral for hemothorax. After the tube thoracostomy is complete, the position of the chest tube and the status of the air and/or fluid in the pleural space should be evaluated through a direct lung radiography. The chest tube should never be clamped for any reason while the patient is being transported or transferred outside the emergency unit. The tube thoracostomy is removed under the control of a lung radiography after the air leakage stops or drainage drops below 100 mL/day [22, 31, 34].

7. Emergency care thoracotomy

Emergency care thoracotomies are considered to be life-saving procedures for a limited patient group. Nowadays, the already effective and still developing emergency transport methods, and the fact that resuscitative interventions are performed before the patients arrive at the hospital, mean that a higher number of almost-morbid patients actually arrive at the hospital. The rate of survival following an emergency care thoracotomy has been reported to vary between 0 and 64%, with the best outcomes achieved for isolated penetrating cardiac injuries. On the other hand, this rate varies between 1 and 3% in cases of blunt and multiple trauma, for which the time of transfer to a hospital is longer. Emergency care thoracotomies are performed on almost-morbid patients in the emergency unit by making a left anterolateral incision between the 4th and 5th intercostal space. Emergency care thoracotomies should not be confused with thoracotomies performed in an operating room or in intensive care during the first hours following the initial injury [35, 36]. The reasons for an emergency care thoracotomy include the drainage of the pericardial tamponade, the control of intrathoracic or cardiac bleeding, the control of massive bronchovenous air embolisms, or bronchopleural fistula, open cardiopulmonary resuscitation or temporary occlusion of the descending thoracic aorta (cross-clamp placement) (**Table 2**) [36].

Contraindications for emergency care thoracotomies include cardiopulmonary resuscitation lasting longer than 15 minutes for penetrating chest traumas, cardiopulmonary resuscitation lasting longer than 5 minutes for blunt chest traumas, non-traumatic arrest, severe head trauma, severe multi-system injuries, the absence of appropriately trained staff and insufficient equipment. The preferable incision for emergency care thoracotomy is an anterolateral thoracotomy, which is carried out on the side with the predicted injury following a physical examination. The incision is performed transversely, the chest cavity is entered through the

Rescuable cardiac arrest after injury

- Prehospital cardiopulmonary resuscitation that lasts less than 15 min in patients exposed to penetrating trauma
- Prehospital cardiopulmonary resuscitation that lasts less than 5 min in patients exposed to blunt trauma

Serious continuous systolic hypotension after injury (≤ 60 mmHg) caused by:

- Cardiac tamponade
 - Bleeding (intrathoracic, intraabdominal, extremity, cervical)
 - Air embolism
-

Table 2. Indications of emergency care thoracotomy.

4th or 5th intercostal space and a chest retractor is inserted. After the bleeding is controlled and a steady heartbeat has been achieved, the patient must be transferred to the operating room as soon as possible [36].

8. Subcutaneous emphysema

Subcutaneous emphysema develops as a result of the entry of air into the subcutaneous soft tissue of the thoracic wall. Characteristic crepitations are felt during palpation, while diagnosis can be made through a visualization of air in the subcutaneous tissue and between the muscles in a lung radiography. The amount of skin emphysema depends on the amount of air leakage from the lungs. While only skin crepitations are present in mild cases, advanced subcutaneous emphysema can be seen when there is intense air leakage and a large defect in the parietal pleura. These cases may present with swelling of the head, neck and face, and while there is no specific treatment for subcutaneous emphysema, the underlying factor should be eliminated. To reduce subcutaneous emphysema, air drainage can be performed by injecting a few large-lumen wide-diameter granules subcutaneously and between the muscles of the anterior thoracic wall (**Figure 3**) [31, 32].

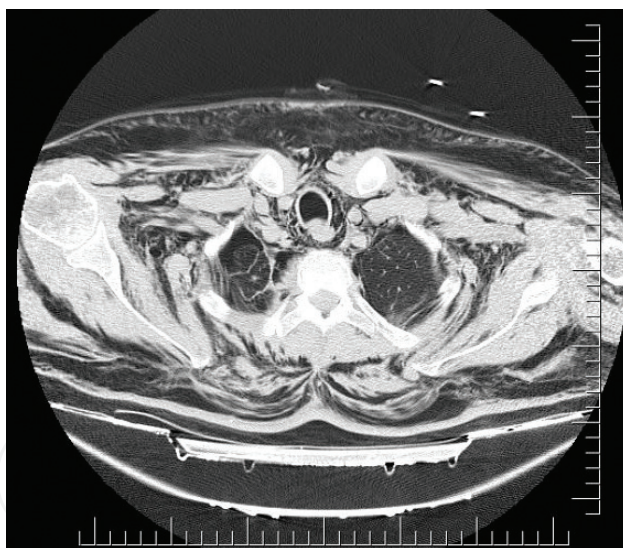


Figure 3. Thorax CT image of a patient with common subcutaneous emphysema that results from a blunt thorax trauma.

9. Contusion and hematoma of the thoracic wall

The thoracic wall is supplied by the internal thoracic artery, which originates directly from the aorta and branches to the intercostal arteries before spreading to all ribs along both sides of the

sternum. Bleeding may occur following rib fractures and the tearing of the thoracic wall muscles. As the thoracic wall has a large vascular supply, subcutaneous bleeding develops frequently, and this is more common in the elderly. Conservative treatment methods and blood transfusions, if required, are often sufficient for its management [26, 31].

10. Rib fractures

The most common type of injury, and one encountered in approximately 35–40% of all thoracic trauma cases, is rib fracture. Rib fractures are more frequent in the elderly due to the decreased elasticity of the thoracic wall. An anterior trauma to the thoracic wall generally results in rib fracture from the outer surface, while lateral traumas cause internal rib fractures. Rib fractures are mostly encountered along 4–9 and the middle axillary line, while fractures of the first and second ribs are generally rare, as these are supported by the clavicle, scapula and shoulders. That said, these ribs may be broken due to very high-energy trauma, and fractures of this kind may well be accompanied by subclavian vessel and brachial plexus injuries. It should be highlighted that rib fractures may be accompanied by lung, bronchus or cardiac injuries. Additionally, abdominal organ injuries, such as the liver and spleen, may occur in the presence of 9th–12th rib fractures, while trauma to the anterior thoracic wall may result in costochondral detachment, which is a more painful condition that requires a longer duration of treatment [22, 26, 31].

Painful tenderness is the most important symptom in the event of rib fracture, and the symptom generally increases with coughing, deep breathing and movement. Friction between the broken rib ends may be felt during a physical examination. Almost half of all rib fractures go unnoticed in lung radiographies, while thoracic CT is more specific for their diagnosis [22, 26]. The treatment of rib fractures is based on pain control and respiration exercises. Pulmonary rehabilitation, including respiration exercises, is crucial in preventing pain-induced secretions, lack of expectoration, atelectasis and pneumonia. Early-term complications of rib fractures include pneumothorax and hemothorax, and late-term complications include atelectasis and pneumonia. A tube thoracostomy is inevitable in the presence of hemothorax and pneumothorax, and surgical fixation becomes necessary when the fractured tips are displaced, and when there are fractures to more than one consecutive rib. Morbidity and mortality in rib fractures depend on the age of the patient, the number and localization of the fractured ribs, and the degree of the concomitant trauma (**Figure 4**) [6, 31, 37].

11. Flail chest

Flail chest may develop in the event of a fracture of three or more consecutive ribs, and can result in the paradoxical respiration of the thoracic wall in at least two places, preventing the formation of negative inspiratory pressure and lung expansion on the affected side of the thorax. Expiration, on the other hand, is not sufficient, due to the lack of adequate positive airway pressure as the concerned region moves outwards during expiration. This impairs

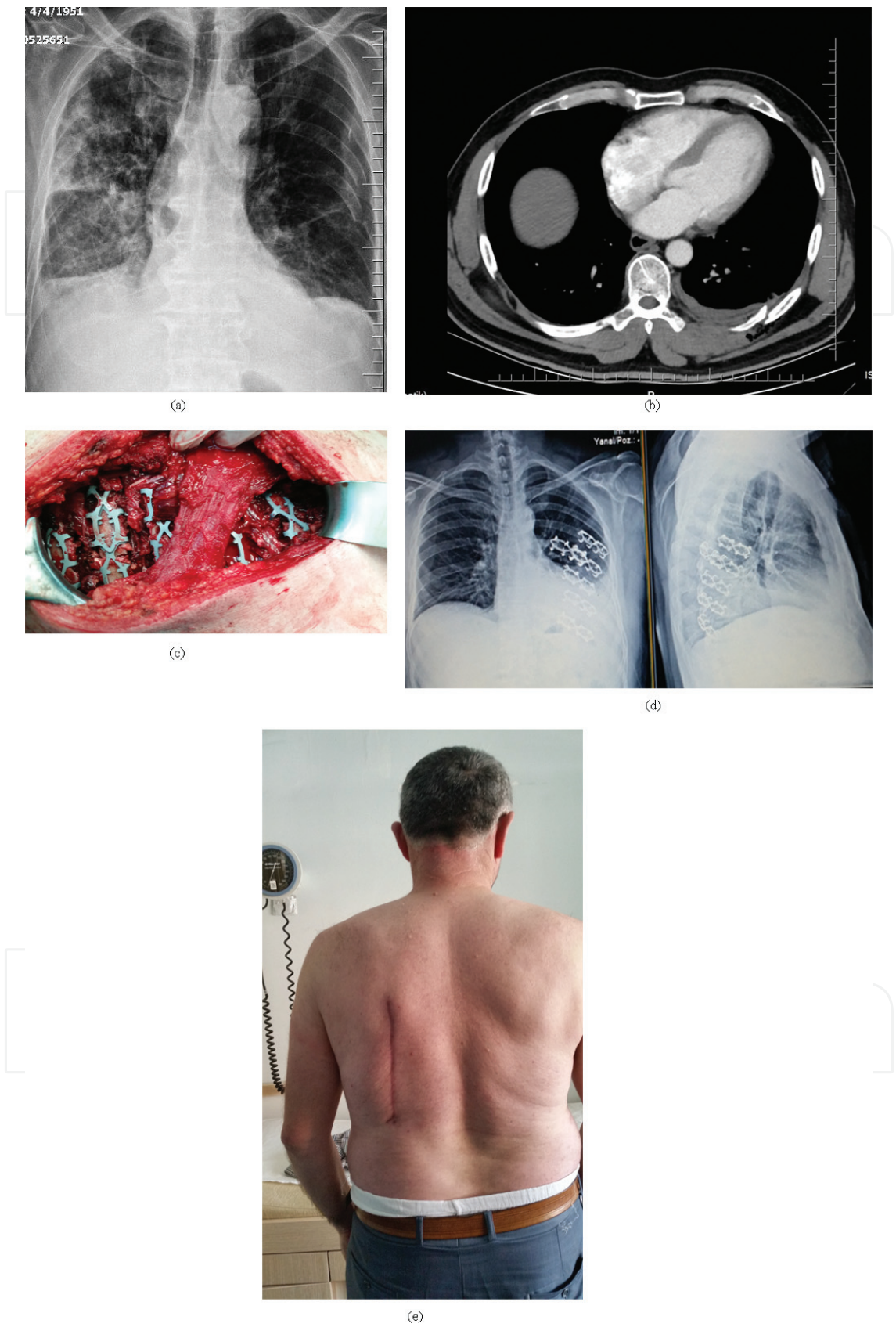


Figure 4. PA radiography, thorax CT and surgical fixation of the ribs of a patient with left multiple rib fractures developed following blunt thoracic trauma, and the post-operative appearance of the patient's skin incision scar.

hemodynamics, and there is always a risk of developing mediastinal shift, decreased cardiac output, hypotension, syncope and sudden cardiac arrest [7, 22].

Decreased respiratory sounds, as heard on auscultation, suggest hemothorax, pneumothorax and/or a lung contusion. A lung radiography and thoracic CT will show rib fractures accompanied by injuries [4, 37]. The treatment of flail chest is based on the use of strong analgesics (intercostal blockage, epidural analgesia and patient-controlled analgesia) and respiration physiotherapy, and while mechanical ventilation may become necessary, it is currently used less frequently. A bronchoscopy is also very important in preventing secretions. The rate of mortality associated with flail chest varies between 10 and 15%, and the most common causes of mortality are massive hemothorax, lung contusion and ARSD [28]. Nowadays, rib fixation (with MRI-compatible nitinol/titanium plates) is preferred in patients who stay in intensive care for long periods of time, who cannot tolerate other interventions or who need thoracotomies due to morbidity.

12. Sternum fractures

Sternum fractures mostly occur during in-vehicle traffic accidents, particularly in the elderly and in front-seat passengers. They are generally transverse fractures, and most commonly develop at the point of junction between the manubrium and corpus sterni, or at the corpus sterni. An accurate diagnosis can be made through a lateral radiography and thoracic CT, and patients should be hospitalized and closely monitored with ECHO and ECG assessments [26, 31, 38].

13. Clavicle fractures

Clavicle fractures have become more common since the use of seatbelts in vehicles became mandatory, and are seen most often in the 1/3rd middle part of the clavicle. A figure of eight bandage is often sufficient for the treatment of a clavicle fracture, and recovery is usually within 3 weeks with conservative therapy, although surgery may be required in rare cases (Figure 5) [22, 26, 31].

14. Scapula fractures

As the scapula is a thick bone and is well-protected by the muscles in the chest wall, scapula fractures only develop as a result of high-energy trauma. Scapula fractures can be diagnosed with a direct lung radiography or thoracic CT, and may be accompanied by brachial plexus injuries. For treatment, the shoulder is strapped and immobilized. Scapula fractures rarely require surgical treatment [26, 31].

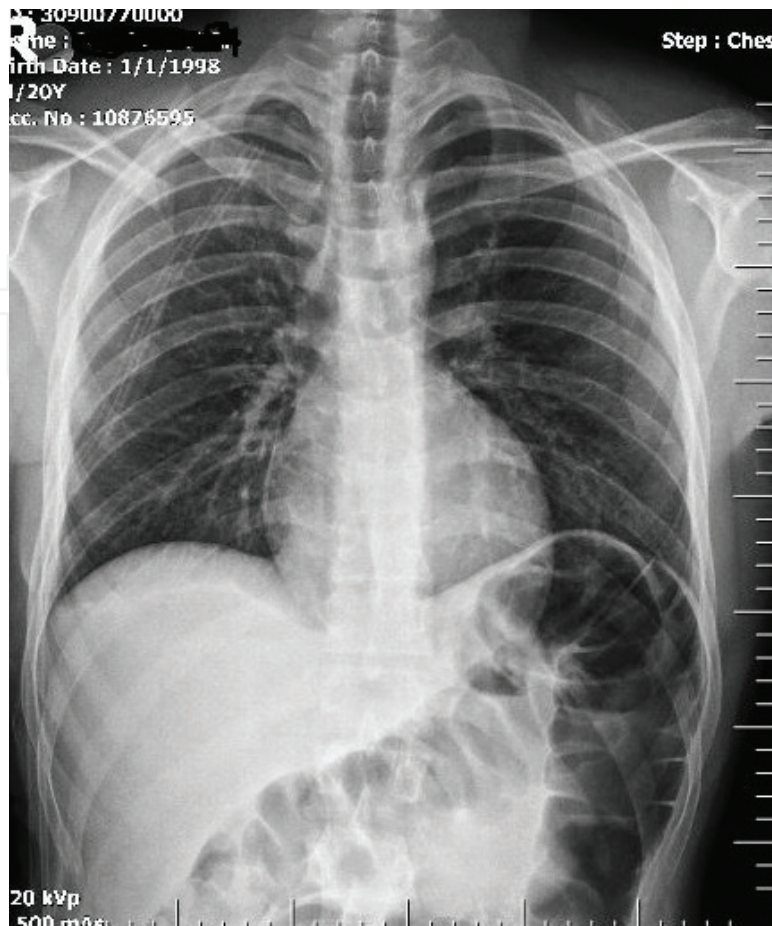


Figure 5. PA chest radiography of a case operated on with a right tube thoracostomy due to a developed traumatic right pneumothorax and right clavicle fracture.

15. Traumatic diaphragm injuries

Traumatic diaphragm injuries may occur due to blunt or penetrating traumas of the thorax and abdomen. Of all diaphragm injuries, 75% are associated with blunt traumas, and 25% are due to penetrating traumas. Their incidence varies between 1 and 5%. The right diaphragm is protected against injuries by the liver, and so diaphragm ruptures are five times more common on the left side than on the right side [9, 39, 40].

Conventional radiological investigations that can be performed when the patient is stabilized are the most important diagnostic methods. Diaphragm elevations, basal atelectasis, loss and/or irregularity of diaphragm borders, blunting of the costophrenic sinus and abnormal nasogastric tube positioning are among the key findings in a direct lung radiography. Furthermore, a fluoroscopy can indicate whether or not the diaphragm is immobile, or can display paradoxical movements [41, 42].

CT is also important for the identification of concomitant injuries, such as those to the liver, spleen or kidneys. The CT findings of a diaphragm injury include the interruption of diaphragm continuity, visualization of a defect in the diaphragm, herniation of the abdominal

organs into thoracic cavity, abnormal positioning of the nasogastric tube, direct contact of the posterior of the ribs with such organs as the liver and stomach, and injuries that progress from one side of the diaphragm towards the other side [9, 41, 42]. In cases where, despite all investigations, there is still suspicion, a thoracoscopy and/or laparoscopy can be performed during the same session.

16. Thoracoscopy

A thoracoscopy is performed to evaluate intrathoracic structures in elective conditions, and is not recommended for emergency situations [22]. It is a minimally invasive method used to clean clots from inside the thorax, to visualize diaphragm injuries, to examine the pericardium, and to remove foreign objects, to control bleeding and for the insertion of a chest tube. The patient must be stable enough to tolerate a double-lumen intubation [42, 43].

17. Conclusion

Patients with thoracic trauma should be evaluated quickly. Life-saving interventions should be implemented by the emergency physician and/or ambulance physician in the event of primary life-threatening injuries. In addition, a thoracotomy should be carried out by a thorax surgeon on site, and possible complications arising out of the specific situation should be considered. It is important to keep equipment ready and available in the event of chest surgery, and to take precautions based on the cause and severity of the trauma without losing time to distinguish between multiple traumas and isolated thoracic traumas.

Author details

Turkan Dubus

Address all correspondence to: drturkandbs@yahoo.com

Thoracic Surgery Department, Istanbul Training and Research Hospital, Health Sciences University, Istanbul, Turkey

References

- [1] Esposito TJ, Brasel KJ. Epidemiology chapter 2. In: Mattox KL, Feliciano DV, Moore EE, editors. Trauma. 7th ed. Mc Graw-Hill; 2013. pp. 19-22
- [2] Global Status Report on Road Safety 2015. World Health Organization; 2015

- [3] Lerner EB, Moscati RM. The golden hour: Scientific fact or medical “urban legend?”. *Academic Emergency Medicine*. 2001;7(8):758-760
- [4] Yüksel M, Laçın T. Travmalı hastaya yaklaşım. In: Yüksel M, Çetin G, editors. *Toraks Travmaları*. İstanbul: Turgut Yayıncılık A.Ş.; 2003. pp. 1-14
- [5] Hasdıraz L. Toraks travmaları. *Türkiye Klinikleri Journal of Thoracic Surgery Special Topics*. 2015;6:1-3
- [6] Brunett PH, Yarris LM, Cevik AA. Pulmoner travma. In: Tintinalli JE, Stapczynski JS, Cline DM, editors. *Çeviri editör: Çete Y, Denizbaşı A, Çevik AA Acil Tıp*. İstanbul: Nobel Tıp Kitabevleri Ltd. Şti; 2013. pp. 1744-1758
- [7] Graeber GM, Prabhakar G, Shields TW. Blunt and penetrating injuries of the chest wall, pleura and lungs. In: Shields TW, LoCicero J III, Ponn RB, Rusch VW, editors. *General Thoracic Surgery*. 6th ed. Vol. 2005. Philadelphia: Lippincott Williams Wilkins. pp. 951-971
- [8] Bayram S. Tezel Çağatay. Künt toraks travmaları. In: Yücel O, editor. *Toraks Travmaları Ve Tedavisi*. Ankara: Derman Tıbbi Yayıncılık; 2013. pp. 44-53
- [9] Elmalı M. Göğüs travmalarında radyolojik değerlendirme. In: Yücel O, editor. *Toraks Travmaları ve Tedavisi*. Ankara: Derman Tıbbi Yayıncılık; 2013. pp. 12-32
- [10] Soyuncu S, Cete Y, Bozan H, et al. Accuracy of physical and ultrasonographic examinations by emergency physicians for the early diagnosis of intra-abdominal haemorrhage in blunt abdominal trauma. *Injury*. 2007;38:564-569
- [11] Neri L, Storti E, Lichtenstein D. Toward an ultrasound curriculum for critical care medicine. *Critical Care Medicine*. 2007;35:S290-S304
- [12] Blaivas M, Lyon M, Duggal S. A prospective comparison of supine chest radiography and bedside ultrasound for the diagnosis of traumatic pneumothorax. *Academic Emergency Medicine*. 2005;12(9):844
- [13] Röthlin MA, Naf R, Amgwerd M, et al. Ultrasound in blunt abdominal and thoracic trauma. *The Journal of Trauma*. 1993;34:488-495
- [14] Guitron J, Huffman LC, Howington JA, Locicero J. Blunt and penetrating injuries of the chest wall, pleura and lungs. In: Shields TW, Locicero J, Reed CE, Fein RH, editors. *General Thoracic Surgery*. 7th ed. Philadelphia: Lippincott Williams-Wilkins; 2010. pp. 891-902
- [15] Vogel SB, Rout WR, Martin TD, Abbitt PL. Esophageal perforation in adults: Aggressive, conservative treatment lowers morbidity and mortality. *Annals of Surgery*. 2005;241(6):1016-1021
- [16] Demetriades D, Rabinowitz B, Markides N. Indications for thoracotomy in stab injuries of the chest: A prospective study of 543 patients. *The British Journal of Surgery*. 1986;73:880-890
- [17] Pearson's Thoracic and Esophageal Surgery. 3rd ed. Vol. 1723. Churchill Livingstone; 2008

- [18] Highlights of the History of Nonpenetrating Chest Trauma. The Surgical Clinics of North America; February 1989
- [19] Meade R. A History of Thoracic Surgery. Charles C Thomas; 1961
- [20] Baydın A. Travmalı hastaya genel yaklaşım. In: Yücel O, editor. Toraks Travmaları Ve Tedavisi. Ankara: Derman Tıbbi Yayıncılık; 2013. pp. 1-11
- [21] Kocamanoglu İS. Toraks travmasında anestezi. In: Yücel O, editor. Toraks travmaları Ve Tedavisi. Ankara: Derman Tıbbi Yayıncılık; 2013. pp. 33-43
- [22] Mansour KA, Bongiorno PF. Blunt trauma: Chest wall, lung, pleura, heart, great vessels, thoracic duct, and esophagus. In: Pearson FG, Cooper JD, Deslauriers J, editors. Thoracic Surgery. 2nd ed. Philadelphia: Churchill Livingstone; 2002. pp. 1832-1849
- [23] Oğuzkaya F. Travmatik hemotoraks ve pnömotoraks. In: Yüksel M, Çetin G, editors. Toraks Travmaları. İstanbul: Turgut Yayıncılık A.Ş; 2003. pp. 51-63
- [24] Taslak Şengül A, Başoğlu A, Kutlu T, Öztürk CD. Pil patlamasına bağlı penetran toraks travması. Turkish. The Journal of Thoracic and Cardiovascular Surgery. 2010;18(2):148-150
- [25] Hughes RK. Thoracic trauma. The Annals of Thoracic Surgery. 1965;1:778-804
- [26] Özçelik C, Alar T. Künt toraks travmaları. In: Ökten İ, Kavukçu HŞ, editors. Göğüs Cerrahisi. İstanbul: İstanbul Tıp Kitabevi; 2013. pp. 837-858
- [27] Feliciano DV. The diagnostic and therapeutic approach to chest trauma. Seminars in Thoracic and Cardiovascular Surgery. 1992;4:156-162
- [28] Sivrikoz MC. Akciğer travması. Türkiye Klinikleri Journal of Thoracic Surgery Special Topics. 2015;6:4-9
- [29] Öztürk CA. Travmatik pnömotoraks. In: Yücel O, editor. Toraks travmaları Ve Tedavisi. Ankara: Derman tıbbi yayıncılık; 2013. pp. 133-145
- [30] Altınok T. Akciğer yaralanmaları. TTD Toraks cerrahisi bülteni. 2010;1:55-59
- [31] Toker SA, Kalaycı NG. Torasik aort ve büyük damar yaralanmaları. In: Yüksel M, Çetin G, editors. Toraks Travmaları. İstanbul: Turgut Yayıncılık A.Ş; 2003. pp. 121-138
- [32] Meteroğlu F, Şahin A. Başyigit İ, ark. Toraks travması takibinde dikkat edilmesi gereken durum: Diyafragma yaralanmaları. Ulusal Travma ve Acil Cerrahi Dergisi. 2015;21:514-519
- [33] Özpolat B. Acil servis torakotomisi. In: Yücel O, editor. Toraks travmaları ve tedavisi. Ankara: Derman tıbbi yayıncılık; 2013. p. 122
- [34] Çağrı U, Samancılar Ö. Diyafragma ve frenik sinir yaralanmaları. In: Yüksel M, Çetin G, editors. Toraks travmaları. İstanbul: Turgut yayıncılık A.Ş; 2003. pp. 185-204
- [35] Bostancı K, Yüksel M. Toraks travmasında temel cerrahi prosedürler. In: Yüksel M, Çetin G, editors. Toraks travmaları. İstanbul: Turgut yayıncılık A.Ş; 2003. pp. 322-340

- [36] Nissen SO, Ebeling BC, Kandler K, et al. Indication for resuscitative thoracotomy in thoracic injuries-adherence to the ATLS guidelines. A forensic autopsy based evaluation. *Injury*. 2016;**47**:1019-1024
- [37] Yörük Y. Göğüs duvarı travması. In: Yüksel M, Çetin G, editors. *Toraks travmaları*. İstanbul: Turgut yayıncılık A.Ş; 2003. pp. 41-50
- [38] Çobanoğlu U. Künt toraks travmaları. In: Yüksel M, Balcı AE, editors. *Göğüs Cerrahisi*. İstanbul: Nobel Tıp Kitabevleri Ltd. Şti; 2015. pp. 815-836
- [39] Badmanaban B, McManus KG, Graham ANJ, McGuigan JA. Penetrating injuries of the chest. *Surgery*. 2004;**22**(5):117-120
- [40] Liman ŞT, Topçu S. Diyafram rüptürleri. *TTD Toraks Cerrahisi Bülteni*. 2010;**1**:87-95
- [41] Tekinbaş C, Karapolat S. Diyafragma yaralanmaları. *Türkiye Klinikleri Journal of Thoracic Surgery Special Topics*. 2015;**6**:31-37
- [42] Mancini M, Smith LM, Nein A, Buechter KJ. Early evacuation of clotted blood in heamothorax using thoracoscopy; case reports. *The Journal of Trauma*. 1993;**34**(1):144-147
- [43] Leppaniemi AK. Thoracoscopy in chest trauma; an update. *Trauma*. 2001;**3**:111-117