

We are IntechOpen, the world's leading publisher of Open Access books Built by scientists, for scientists

6,900

Open access books available

185,000

International authors and editors

200M

Downloads

Our authors are among the

154

Countries delivered to

TOP 1%

most cited scientists

12.2%

Contributors from top 500 universities



WEB OF SCIENCE™

Selection of our books indexed in the Book Citation Index
in Web of Science™ Core Collection (BKCI)

Interested in publishing with us?
Contact book.department@intechopen.com

Numbers displayed above are based on latest data collected.
For more information visit www.intechopen.com



Flexor Tendon Injuries

Justin Yousef and Sarah Anthony

Additional information is available at the end of the chapter

<http://dx.doi.org/10.5772/intechopen.73392>

Abstract

Even though flexor tendon injury is common, much remains to be elucidated about the best way to facilitate the intrinsic healing process and to minimise scarring. This chapter will comprise flexor tendon anatomy, types of flexor tendon injury, modes of healing, molecular updates, repair techniques and post-operative rehabilitation.

Keywords: anatomy, flexor tendon injury, rehabilitation, tendon healing, molecular updates, complications

1. Introduction

Repair of the injured flexor tendon in the hand to achieve normal function remains a difficult task and is made even more so with complications such as repair rupture and adhesions. Controversy exists as to what post-operative rehabilitation protocols should be employed and is often based on surgeon experience or the hand therapy service. This chapter aims to focus on postoperative rehabilitation and future research trends. The reader is encouraged to seek alternative resources for more detail regarding flexor tendon anatomy, pathophysiology and repair techniques as these will be covered briefly in this chapter.

2. Flexor tendon anatomy

2.1. Flexor digitorum superficialis

Flexor digitorum superficialis (FDS) is responsible for flexion of the proximal interphalangeal (PIP) joint as well as contributing to the flexion of the metacarpophalangeal (MCP) joints. The muscle body has two heads of origin. The ulnar head arises from the anterior aspect of the

medial epicondyle, the ulnar collateral ligament of elbow, medial aspect of coronoid process, and the proximal ulna. The radial head originates from the proximal radius immediately distal to the insertion of supinator. At the mid-forearm, the FDS muscle belly divides into the superficial and deep layers. The superficial layer gives a tendon to the middle finger and ring finger, whilst the deep layer supplies the index and little fingers. Each tendon arises from a separate muscle belly allowing independent flexion of PIPJ of each finger except for LF which may have cross connection with FDS tendon of RF [1] as the FDS to the little finger may be hypoplastic or absent in some people [1].

At level of the proximal phalanx, FDS divides into two slips which pass on either side of the tendon of flexor digitorum profundus (FDP) forming “Camper’s Chiasm” [1] and then unites to insert onto the volar surface of the middle phalanx. The blood supply to FDS is from both ulnar and radial arteries and its innervation is from the median Nerve which enters the muscle belly in proximal forearm.

2.2. Flexor digitorum profundus

Flexor digitorum profundus (FDP) is responsible for flexion of the distal interphalangeal (DIP) joints of the fingers as well as contributing to flexion of the PIP and MCP joints. It arises from volar and medial aspects of the proximal three quarters of the ulna and from the medial half of volar aspect of the interosseous membrane. It lies deep to FDS and adjacent to flexor pollicis longus (FPL) in the forearm. The Ulnar nerve travels distally in the forearm, loosely adhered to FDP, innervating the muscle-tendon units for the ring Finger and little fingers [1]. The anterior interosseous nerve (AIN) of the median nerve innervates the index and middle finger units.

Unlike FDS, the tendons of FDP usually arise from common muscle belly. Frequently however. The tendon to the index Finger arises from a separate muscle belly resulting in greater independence of flexion [1].

2.3. Flexor pollicis longus

Flexor pollicis longus (FPL) is responsible for flexion of the interphalangeal (IP) joint of the thumb. It arises from volar aspect of the middle one third of the radial shaft and from the interosseous membrane. It is located deep to the flexor carpi radialis tendon and the radial artery at the level of the proximal wrist crease. FPL inserts onto the base of the distal phalanx of the thumb. The AIN innervates FPL in the proximal forearm and the blood supply is predominantly from the radial artery. All nine digital flexors enter the carpal tunnel with the four FDP tendons deep to FDS tendons of the little finger and index finger. FDS tendons of ring finger and middle finger lie superficially immediately ulnar to median nerve. The tendon of FPL lies deep and radial within the carpal tunnel, adjacent to scaphoid and trapezium.

2.4. Flexor sheath and pulleys

Proximal to MCP joints the flexor tendons enter the fibro-osseous flexor sheath. This tunnel functions to hold the tendons in close proximity to the phalanges to prevent “bowstringing” and to increase the efficiency of tendon glide [2]. The flexors sheath tunnel is thickened in

certain areas called pulleys. The pulleys are either annular (A) or Cruciform (C) in shape and are numbered proximal to distal. The odd numbered pulleys A1, A3, A5 are over the MCP, PIP and DIP joints respectively [1, 3]. The A2 pulley overlies the proximal phalanx and the A4 pulley over the middle phalanx. The even numbered pulleys.

The cruciform pulleys are located proximal and distal to the PIP joints. Between the A2 and A3 pulleys is C1, between the A3 and A4 pulleys is C2, and the C3 pulley is located just proximal to the DIP joint between the A4 and A5 pulleys. The cruciform pulleys, in conjunction with A1, A3 and A5 permit compression of the flexor tendon without impingement during flexion and expansion of the tendon during extension [4]. The A2 and A4 pulleys have traditionally been deemed most important in preventing bowstringing and therefore most surgeons advocate their preservation, repair or reconstruction [4]. However, it has been demonstrated that partial distal excisions of 25% of the A2 pulley, up to 75% of the A4 pulley and 25% of combined A2 and A4 have no significant effect on digit range of motion or work of flexion [5, 6].

2.5. Tendon anatomy and nutrient supply

Tendons are collagen-based tissues that connect muscle to bone. They are composed primarily of Type I collagen, whereas the surrounding endotenon and epitenon are composed of Type III collagen [7]. The collagen itself is synthesised and secreted by tenocytes within the tendon and, once secreted, the collagen fibres arrange into triple helices to increase strength and stability.

Collagen fibre units are bound together by endotenon fascicles. These fascicles are bound in turn by the epitenon to form the whole tendon. Lymphatic, vascular and neural constituents are present within the endotenon to supply the fibroblasts whereas the epitenon contains the blood vessels and tracts for the lymphatics and nerves.

The tendon sheath is covered with synovial cells that lubricate the tendon to help gliding within the sheath. Outside of the hand, tendons are not typically enclosed within a sheath but are covered by paratenon that contains the vascular elements to supply both the endotenon and epitenon.

Both FDP and FDS tendons in the digits receive dual nutritional supply from vascular perfusion and synovial diffusion [7]. Vascular perfusion is provided by the vincula with each tendon having two: a vinculum longus and a vincula brevis. From proximal to distal, the first vinculum encountered is the vinculum longus superficialis (VLS), arising just proximal to Camper's chiasm and coming off the floor of the digital sheath of the proximal phalanx. The vinculum brevis superficialis consists of small triangular mesenteries near the insertion of the FDS. The vinculum longus profundus arises from the superficialis at the level of the PIP joint. The vinculum brevis profundus arises near the insertion of the FDP. Each vinculum inserts on the dorsal aspect of the tendon, creating a richer blood supply on the dorsal side of the tendon. The vincula are important in the repair of injured tendons as they may hold the tendons out to length after injury. Therefore, one must be careful not to injure any maintained vincula while repairing an injured tendon, thereby decreasing the already tenuous blood supply. The parietal paratenon allows for passive nutrition delivery to, and waste removal from, the tendons within the sheath by diffusion [8]. Nutrient supply is also directly from the bones of the fingers from the middle (FDS) and distal (FDP) phalanges.

2.6. Flexor zones

The volar surface of the hand is divided into five anatomic zones from distal to proximal. When describing a zone for an injury it is referred to by the zone that it would lie in the hand in the resting posture.

Zone 1 commences at the fingertip and ends at the insertion of FDS on the middle phalanx. It includes the C3 and A5 Pulleys and the FDP tendon.

Zone 2 is from the insertion of the FDS to the proximal aspect of the A1 pulley. It contains both FDS and FDP.

Zone 3 is from the proximal A1 pulley to the distal limit of the transverse carpal ligament (TCL).

Zone 4 is the area deep to the TCL i.e. the carpal tunnel.

Zone 5 is from the proximal edge of the TCL to the musculotendinous junction.

3. Types of flexor tendon injury

3.1. Patterns of injury

A sharp laceration to a flexor tendon is the most common cause of injury (for example from a knife or glass). It is rare for blunt injuries to divide the tendon but the significant crushing to the tendon can result in adhesions if not managed properly. Avulsion injuries are also common.

3.2. Lacerations

Lacerations may be complete or partial [2]. Lacerations within Zone 1 only involve FDP and those in Zone 2 usually involve both FDP and FDS tendons as well as any neuromuscular injury. Tears within the fibro-osseous sheath are more prone to restrictive adhesions than those within Zones 3–5. However, small lacerations in Zones 3–5 frequently involve multiple tendons and major neuromuscular structures

3.3. Avulsion injuries

Four factors determine the prognosis of avulsion injuries of flexor tendons: the extent of retraction of the proximal tendon, the remaining blood supply, the time interval between trauma and surgery, and the presence and size of any osseous fragments [2].

The FDP tendon is prone to avulsing from its insertion into the distal phalanx and is commonly called a “jersey injury” [9]. This occurs when the distal phalanx is extended at the DIP joint while the FDP is maximally contracted. This avulsion may involve a fragment of bone. Jersey finger most commonly affects the ring finger because it is the most proximal digit when the hand is flexed. Leddy and Packer have classified jersey injuries into Types I to III [9]. This classification has been modified by Smith who added a Type IV injury [10] and Al-Qattan who added Type V [11] (**Table 1**).

Type I	FDP and both vincula rupture with no fractures Tendon retracts into palm, presenting as a tender lump <i>Early operative repair necessary</i>
Type II	FDP ruptures but long vincula remains intact Avulsed FDP held at PIP joint here may be a small avulsed bony fragment <i>Repair required within 3 months</i>
Type III	FDP avulsion with a large bony fragment that gets caught at A4 Both vincula are preserved <i>No time limit for repair</i>
Type IV	FDP and bony fragment avulsion, with tendon avulsion from the bony fragment
Type Va	FDP and bony fragment avulsion, in association with fracture of the distal phalanx (extra-articular)
Type Vb	FDP and bony fragment avulsion, in association with fracture of the distal phalanx (intra-articular)

Table 1. Modified Leddy and Packer classification for FDP avulsion [9–11].

4. Tendon healing and latest molecular updates

Tendon healing undergoes overlapping inflammation, proliferation and remodelling [12] via two mechanisms -extrinsic and intrinsic [7]. Within the first week of injury, blood vessels within the tendon and tendon sheath form a thrombus at the injury site which acts to recruit vasodilators and proinflammatory cells [12]. These cells migrate to the injury site and help with removal of necrotic tissue, fibrin, clot and cellular debris through phagocytosis. Canine models have shown that angiogenic factors, such as vascular endothelial growth factor (VEGF), help initiate the vascular invasion to the site of injury [13].

In the third week, the tendon enters the proliferative stage whereby the fibroblasts rapidly proliferate, synthesis immature collagen in an unorganised manner, and assist with the production of extracellular matrix (ECM) [14]. This initial laid down collagen is type III collagen which is a weaker form of the type I collagen present in native tendons. The combination of type III collagen and previously initiated vascular network leads to scar formation within the tendon- this initially decreases its strength before the tendon enters the final stage of healing

At weeks six to eight, the remodelling stage predominates. Here type I collagen fibres are reorganised in a longitudinal manner along the long axis of the tendon with collagen fibrils crosslinking to one another to increase the strength of the tendon [14]. It is during this stage that adhesions between the tendon and its sheath become more apparent

4.1. Intrinsic healing

Intrinsic healing involves only the tenocytes (fibroblasts) within the tendon itself and depends on the migration and proliferation of cells from the epitenon and endotenon [7, 14]. Epitenon

tenocytes produce collagen earlier than those of the endotenon. Tenocytes of the endotenon produce large and more mature collagen than epitenon cells. In any event, both endotenon and epitenon tenocytes establish an extracellular matrix and internal neovascular network. Intrinsic healing results in improved biomechanics within the sheath, including tendon gliding. Movement of the tendon within the sheath improves synovial circulation and therefore the delivery of nutrients.

4.2. Extrinsic healing

Extrinsic healing involves the invasion of fibroblasts and inflammatory cells into the site of injury from the surrounding synovium, paratenon and tendon sheath [7, 14]. This produces scarring and peritendinous adhesions which may impair tendon movement, gliding and nutrition. It is thought that extrinsic healing predominates in the earlier stages of tendon healing. Extrinsic healing also predominates when tendons are immobilised after injury or repair. The extrinsic mechanism is activated earlier and is responsible for initial adhesions, the highly cellular collagen matrix and the high-water content of the injury site [7, 14]. The intrinsic mechanism then causes tenocytes from within the tendon to invade the defect and produce collagen which reorganises and aligns longitudinally to maintain fibrillar continuity and produce a healed tendon [15].

4.3. Research trends

Careful surgical technique and initiation of early motion after surgical repair of flexor tendon injuries have been the main strategies for decreasing tendon adhesions after surgical repair. Recent research has concentrated on improving the healing response within the tendon whilst decreasing the adhesion formation between the tendon and its sheath.

- **Transforming growth factor β (TGF- β):** Chang and colleagues [16, 17] have shown that the isoform TGF- β 1, present in small amounts in native tendon and its surrounding sheath, increase in production after tendon transection and repair. TGF- β 1 has been postulated to contribute to fibrosis and therefore scarring [18, 19]. Shah and colleagues showed that the neutralising antibody to TGF- β was able to control scarring in rat dermal wounds [18, 19]. Chang et al. added to this by demonstrating that these antibodies were able to increase the total range of motion after flexor tendon repair in a rabbit model [20]. However, suppression of TGF- β has been shown to decrease strength of tendon repair [21, 22].
- **Vascular endothelial growth factor (VEGF):** It is known that tenocytes secrete VEGF and is present in synovial fibroblasts [7]. After binding to its target, VEGF induces vasodilation [7]. VEGF mRNA levels are increased in flexor tendons after injury in the canine model [13]. These investigators are currently attempting to modify VEGF production to increase the vascular inflow to the blood supply of the healing flexor tendon.
- **Cell and molecular modulation:** Researchers have recently turned their attention to gene deletion strategies and gene therapy to modulate the healing process. Similar to inhibiting TGF- β , deletion of the TGF- β inducible early gene (*Tiegl1*) resulted in decreased collagen I deposition in an *in vitro* model of tendon healing [23]. VEGF genes delivered by adeno-associated virus

(AAV) vectors in a chicken model demonstrated that healing strength was improved without increased adhesion formation [24]. Tang and colleagues [25] also used AAV vectors harbouring rat basic fibroblast growth factor (bFGF) to transfect chicken flexor tendons. Their results showed a moderate reduction in adhesions.

- **Tissue engineering:** Basile et al. [26] used a devitalised acellular allograft tendon containing recombinant AAV expressing growth and differentiation factor-5 as a delivery model. They were able to repopulate the graft, decrease scar tissue and enhance the gliding property relative to the control graft. Zhao et al. [27] demonstrated that lubricin combined with hyaluronic acid and bone marrow stromal cells stimulated with growth and differentiation factor-5 can significantly improve gliding function in canine flexor models. However there were substantial decreases in repair strength compared to control. In large animal models, synthetic membranes [28] and tissue-engineered synovial membranes [29] have been shown to decrease peritendinous adhesions.

5. History and examination

An accurate history and examination allows for planning of surgical approach. Though it is preferable for early tendon repair [30], immediate repair of a flexor tendon may be contraindicated in extensively contaminated wounds or those with substantial injury (involving two or more elements of skin, nerve, artery, vein, flexor tendons, extensor mechanism, bone or joint). Delayed presentation may also warrant surgical reconstruction of a flexor tendon due to proximal myostatic muscle-tendon retraction resulting inability to bring the proximal and distal stumps together.

It is important to perform a clinical examination of the traumatised hand before the administration of local anaesthesia to accurately identify and document neurologic or vascular injury [3]. Firstly, any volar laceration of the hand or wrist requires careful observation of the flexor cascade. In the normal cascade, each finger is slightly more flexed than the adjacent radial finger when the wrist is neutral or slightly extended.

To assess FDS, the FDP must be blocked from acting on the PIP joint. This is done by isolating the affected finger by holding all other fingers in extension and asking the patient to flex the PIP joint. By repeating the test against resistance, applied to the middle phalanx, partial lacerations of the tendon can be identified as it will elicit increased pain. FDP, responsible for flexion of the DIP, is tested in a similar manner to FDS. The middle phalanx is held in extension and the patient instructed to flex the DIP joint of each finger. Again, this can be done against resistance to identify partial tendon lacerations. FPL is tested by stabilising the proximal phalanx of the thumb and instructing the patient to flex the IP joint. However, a more reliable test of FPL function is using the 'O' sign where the patient is asked to make an O shape between their thumb and index finger. This O shape is only possible if the FPL is intact. This test is more reliable than asking the patient to flex the IP joint as there are trick movements that can cause a flicker of movement at the IP joint, causing diagnostic confusion.

6. Repair principles and techniques

The ideal method of flexor tendon repair should allow a healing response precisely at the tendon ends but not between the tendon and its surroundings, creates a repair site with minimal bulk and low friction, and places enough force across the repair to promote motion and remodelling [14].

The characteristics of an ideal tendon repair were described by Strickland [31] and confirmed by a large body of research data [14]. These are:

- I. Core sutures easily placed in tendon
- II. Secure knots
- III. Smooth junctions
- IV. Minimal gapping
- V. Minimal interference with tendon vascularity
- VI. Sufficient strength throughout healing to permit application of early motion stress.
- VII. Motion at the repair site to increase the amount of collagen deposited at the site of injury and aid in the organisation of said deposition
- VIII. Equal tension across all suture strands

Strength of the repair immediately post operatively is reliant on the suture and is therefore entirely responsible for the stability in early motion stress. Ideally, the suture material used should have high tensile strength, be inextensible, cause no tissue reaction and be easy to handle and knot [31]. Flexor tendon repairs consist of two parts. The core sutures and the epitendinous sutures.

Core sutures provide strength to the tendon repair. A 3/0 or 4/0 non-absorbable braided or monofilament suture are optimal for use as core suture [32]. The number of core sutures in the repair and the size of the suture is proportional to the strength of the repair. However, increasing the number of suture strands within the repair leads to increased bulk of the repair. Another factor in determining strength of the tendon repair is the grip of the core sutures. Increasing the grip of the core suture prevents the suture from pulling out of the tendon after repair [32].

The epitendinous sutures ensure smoothness of gliding and also increases the tensile strength of the repair. A locked running suture also reduces the rate of gap formation [32].

Large gaps in the tendon repair prevents healing with Gelberman et al. demonstrating that 3 mm is the maximum permissible gap to allow tendon healing [33].

Other factors include minimal handling to reduce adhesions and to avoid vascular interference to the repaired tendon [33]. Tendon lacerations less than 60% of the tendon diameter should not be repaired [34].

There are many techniques available for repairing the tendon and these have been described in detail elsewhere [35]. Four-strand techniques are generally recognised to be superior to

two-strand techniques. The choice of core suture can be made independent of the choice of epitendinous repair. There is little evidence to recommend one suture material over another. Steel and fibrewire have been shown to be stronger than nylon, Prolene and braided polyester, with no significant difference between the latter three [36].

7. Postoperative rehabilitation following flexor tendon repair

The surgeon must not only be aware of how to repair a lacerated flexor tendon but must also have an understanding of the postoperative rehabilitation regimen before consenting a patient for surgery. Failure to comply with rehabilitation may result in poor patient outcomes despite meticulous repair technique. Unfortunately, the best rehabilitation regimen remains to be elucidated. This is further convoluted by a paucity of well-designed randomised control trials with a Cochrane Collaboration analysis [37] being withdrawn in 2010 for being out of date and the most recent systematic review concluding that there is weak evidence supporting both early active motion protocols and combination protocols [38]. Therefore, it is imperative that the surgeon be aware of both current rehabilitation regimens as well as future directions. Current postoperative protocols for patients with flexor tendon injuries are immobilisation, early passive mobilisation and early active mobilisation [39] (**Figure 1**).

7.1. Immobilisation

Immobilisation may seem counterintuitive considering the plethora of studies showing the benefits of early mobilisation on the repair strength, tenocyte healing and formation of adhesions [14, 40–44]. However, there are certain situations in which immobilisation is preferable. These include patients who [39]:

- Are unwilling to adhere to strict early mobilisation protocols.
- Are unable to adhere to early mobilisation protocols such as children and those with cognitive deficits.
- Have injuries to other structures that could potentially be damaged by early mobilisation such as fractures, nerves and vessels.

O'Connell et al. followed 78 children (under the age of 16) for 24 months and found no benefits in early mobilisation protocols in children when compared to immobilisation [45]. However, immobilisation for more than four weeks resulted in functional deterioration of the repaired tendon [45]. Kato et al. found it difficult to encourage early active motion protocols in children aged less than six and found immobilisation for three to four weeks did not increase the incidence of tendon rupture or decrease function [46].

For the non-compliant adult patient, the protocol of Cifaldi, Collins and Schwarze may be used [39, 47]. It involves three to four weeks of immobilisation in a forearm-based dorsal splint or cast (20° wrist flexion, metacarpophalangeal (MP) joints in 50° flexion and the interphalangeal (IP) joints in full extension) followed by a weaning program (it may also be used in children) [47]. Weaning involves modifying the splint so that the wrist is in neutral and instructing the patient to remove the splint every hour and passively flexing

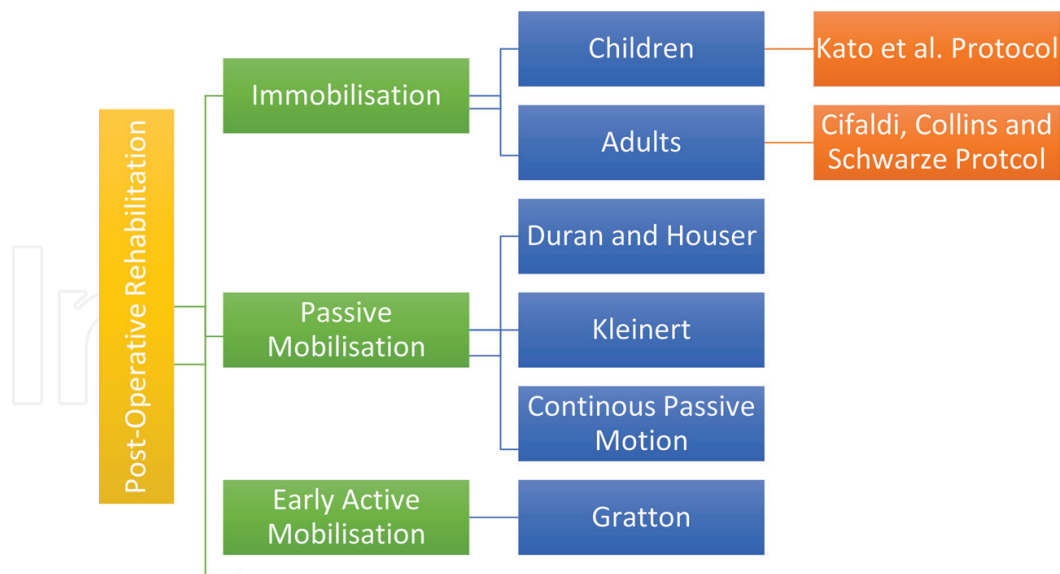


Figure 1. Summary of post-operative rehabilitation protocols.

and extending the injured digit for ten repetitions. Splint wear is then discontinued at six weeks (if flexion contractures of the wrist or fingers exist at this stage, a nocturnal volar splint holding the fingers in maximal comfortable extension may be worn). At this time differential FDS and FDP gliding exercises are performed every hour for ten repetitions. To isolate FDP gliding, both the MP and proximal interphalangeal (PIP) joints are held in extension, and the patient flexes the distal interphalangeal (DIP) joint. During this manoeuvre, the FDS tendon glide is prevented. The FDS tendon is isolated by holding all fingers in extension while the patient actively flexes the PIP joint of the affected finger. By holding the fingers in extension, the common muscle belly of the FDP is held to its full length, preventing it from assisting in flexion. At 8 weeks following surgery, sustained grip activities are added to the regimen. The resistance of these activities is gradually increased over the next four weeks. Heavy resistive exercises are avoided before 12 weeks because of the risk of tendon rupture.

7.2. Early passive mobilisation

Early passive mobilisation protocols are known to inhibit adhesion formation, promote intrinsic healing, and produce a stronger repair [42–44, 47–49]. Two well-known early passive mobilisation protocols are the Duran and Houser and the Kleinert protocols [39].

In the Duran and Houser protocol, the postoperative dorsal blocking splint holds the MP joints at 50° of flexion and the wrist at 20° of flexion. These investigators showed that three to five mm of tendon excursion was necessary to prevent firm tendon adhesions. The following regimen is followed twice daily. Using the opposite hand, the PIP and the DIP joints are brought from full flexion to full extension, with eight repetitions for each joint. Then, the patient performs eight repetitions of composite MP, PIP, and DIP flexion. This protocol continues through the fourth postoperative week. Approximately 5 weeks following surgery, the patients begin

active extension exercises with the use of a wristband. A rubber band is attached from the tip of the finger to the wristband, providing passive flexion and active extension. During this time, the patient also performs blocking and FDS gliding exercises. The late stage begins 8 weeks postoperatively. Progressive strength building is encouraged.

The Kleinert protocol uses a dorsal plaster splint immediately following surgery. This splint blocks the wrist and MP articulations in flexion. The wrist is placed at approximately 45° of flexion, and the MP joints rest at approximately 20° of flexion in the initial postoperative splint. The IP joints rest in neutral alignment in this initial splint. One week following surgery, the splint is replaced with a thermoplastic splint that maintains the same angles of flexion as the initial postoperative splint. The new splint allows for passive flexion of the digits and active extension of the digits against dynamic traction using rubber bands to facilitate the traction mechanism. The bands are placed on the volar aspect of the splint and directed toward the distal nail plate from just proximal to the wrist. Early passive ROM exercises are started within the confines of the dorsal splint. At one month following the patients remove the splint and began active flexion and extension exercises. However, patients wear the dorsal splint during periods of inactivity. About six weeks after the surgical repair, the dorsal splint is discontinued, and blocking exercises are started. Two months following the repair, resistive exercises are incorporated. Patients resume normal activities approximately three months following the surgical procedure. Problems that have arisen with the Kleinert protocol include flexion contractures of the PIP joint [50]. Treatment of contractures has consisted of continued intermittent splinting with the IP joints in neutral position [51]. In recent years, rubber band traction has been almost completely abandoned, largely because of the problems arising from the flexed resting position of the PIP joint [52]. Continuous passive motion (CPM) uses devices that allow for joints to move through a predetermined arc of motion [39]. The aim is to increase the duration and repetition of exercises. Gelberman et al. [53] performed a randomised control comparing traditional early passive motion to CPM exercises and demonstrated that, at 6 months, the CPM group had significantly greater range of motion. However further research in evaluating the CPM following flexor tendon repair is lacking.

7.3. Early active mobilisation

An Early active mobilisation (EAM) protocol refers to active contraction of the repaired muscles [54, 55]. EAM promotes formation of large diameter fibrils and demonstrates the greatest cellular response to injury [48]. There are many different EAM regimens with some using a hinged dorsal blocking splint to assist with wrist synergistic motion whereas others use place and hold or active flexion [56, 57]. A well-known protocol is that by Gratton [58] who combined the Belfast and Sheffield practices [54]. The protocol is as follows:

- At postoperative day two to five, a thermoplastic dorsal blocking splint is fashioned with the wrist positioned in 20° of flexion and the MCP joints in 80° of flexion with the IP joints in full extension. If the patient has significant oedema, the active ROM exercises are delayed until day five. Oedema is treated with compression and elevation.

- If oedema is not significant, exercises begin with passive flexion of the digits with active extension to the constraints of the splint.
- Once these exercises are completed, the patient begins with active flexion exercises where a finger of the opposite hand is placed in the palm of the affected hand and the patient flexes the affected fingers against the contralateral fingers aiming to progress one finger width per week.
- By the end of the first week, the patient should have full passive flexion, full active extension and PIP active flexion to 30°.
- The splint is discontinued between weeks four and six (week four for patients with poor tendon gliding and six for those that have excellent ROM defined as full active fist at week two). The exercises at this time consist of passive ROM and active ROM.
- At week six, blocking exercises of the individual joint is commenced. At this stage, a splint may be needed to correct any flexion contractures.
- Strengthening begins 3 weeks after the dorsal block splint is discontinued. Strengthening progresses to allow patient to have full hand function by week 12.

None of the EAM protocols should be followed exactly- the surgeons and therapist must individualise treatment to patient circumstances [39, 59]. For example, advancement to the next phase of a protocol may need to be quicker or slower based on the level of oedema, passive versus active flexion lags, and adhesion formation [59]. Interestingly, the initiation of rehabilitation is a critical factor in successfully rehabilitating flexor tendon repairs. Initiating therapy by postoperative day five has been shown to decrease the rate of secondary procedures and decrease costs of treatment irrespective of whether or not a passive or active protocol is used [60].

8. Complications of primary repair

The most common complication of flexor tendon surgery are tendon adhesions which can limit the range of movement of the tendon. This is followed by re-rupture, joint contracture and triggering of the fingers. There is a 15–25% re-rupture rate after surgical repair [61]. Treatment of re-rupture of tendons is as follows [61]:

- if <1 cm of scar is present, resect the scar and perform primary repair
- if >1 cm of scar is present, perform tendon graft
- if the sheath is intact and allows passage of a paediatric urethral catheter or vascular dilator, perform primary tendon grafting
- if the sheath is collapsed, place Hunter rod and perform staged grafting

Rarer complications of flexor tendon injury repairs are Swan-neck deformity, Lumbrical plus finger, and Quadrigia effect.

9. Conclusions

Flexor tendon injury outcomes are unsurpassed when they are treated at an early stage. Good surgical technique is vital in to avoid rupture or adhesions. However, of equal importance is the preparation of the patient to expect an individualised long and complex rehabilitation programme.

Secondary reconstruction is complex and rarely results in the same level of function as a successful primary repair.

Author details

Justin Yousef* and Sarah Anthony

*Address all correspondence to: justin.yousef@gmail.com

Department of Plastic and Reconstructive Surgery, The Northern Hospital, Melbourne, Australia

References

- [1] Rayan G, Akelman E. *The Hand: Anatomy, Examination, and Diagnosis*. 4th ed. Lippincott: Williams & Wilkins; 2011
- [2] Schöffl V, Heid A, Küpper T. Tendon injuries of the hand. *World Journal of Orthopedics*. 2012;**3**(6):62
- [3] Green DP, Hotchkiss RN, Pederson WC, Wolfe SW. *Green's Operative Hand Surgery*. Philadelphia, Pennsylvania: Elsevier Churchill Livingstone; 2005
- [4] Zafonte B, Rendulic D, Szabo RM. Flexor pulley system: Anatomy, injury, and management. *The Journal of Hand Surgery*. 2014;**39**(12):2525-2532
- [5] Mitsionis G, Bastidas JA, Grewal R, Pfaeffle HJ, Fischer KJ, Tomaino MM. Feasibility of partial A2 and A4 pulley excision: Effect on finger flexor tendon biomechanics. *The Journal of Hand Surgery*. 1999;**24**(2):310
- [6] Tomaino M, Mitsionis G, Basitidas J, Grewal R, Pfaeffle J. The effect of partial excision of the A2 and A4 pulleys on the biomechanics of finger flexion. *The Journal of Hand Surgery*. 1998;**23**(1):50-52
- [7] Myer C, Fowler JR. Flexor tendon repair: Healing, biomechanics, and suture configurations. *Orthopedic Clinics of North America*. 2016;**47**(1):219-226
- [8] Lundborg G, Rank F. Experimental intrinsic healing of flexor tendons based upon synovial fluid nutrition. *The Journal of Hand Surgery*. 1978;**3**(1):21-31

- [9] Leddy JP, Packer JW. Avulsion of the profundus tendon insertion in athletes. *The Journal of Hand Surgery*. 1977;**2**(1):66-69
- [10] Smith JJH. Avulsion of a profundus tendon with simultaneous intraarticular fracture of the distal phalanx--case report. *The Journal of Hand Surgery*. 1981;**6**(6):600-601
- [11] Al-Qattan MM. Type 5 avulsion of the insertion of the flexor digitorum profundus tendon. *The Journal of Hand Surgery*. 2001;**26**(5):427-431
- [12] Gelberman RH, Vandeberg JS, Manske PR, Akeson WH. The early stages of flexor tendon healing: A morphologic study of the first fourteen days. *The Journal of Hand Surgery*. 1985;**10**(6 Pt 1):776-784
- [13] Bidder M, Towler DA, Gelberman RH, Boyer MI. Expression of mRNA for vascular endothelial growth factor at the repair site of healing canine flexor tendon. *Journal of Orthopaedic Research*. 2000;**18**(2):247-252
- [14] Beredjiklian PK. Biologic aspects of flexor tendon laceration and repair. *The Journal of Bone and Joint Surgery. American Volume*. 2003;**85-A**(3):539-550
- [15] James R, Kesturu G, Balian G, Chhabra AB. Tendon: Biology, biomechanics, repair, growth factors, and evolving treatment options. *The Journal of Hand Surgery*. 2008;**33**(1):102-112
- [16] Chang J. Studies in flexor tendon reconstruction: Biomolecular modulation of tendon repair and tissue engineering. *The Journal of Hand Surgery*. 2012;**37**(3):552-561
- [17] Chang J, Most D, Stelnicki E, Siebert JW, Longaker MT, Hui K, et al. Gene expression of transforming growth factor beta-1 in rabbit zone II flexor tendon wound healing: Evidence for dual mechanisms of repair. *Plastic and Reconstructive Surgery*. 1997;**100**(4):937
- [18] Shah M, Foreman DM, Ferguson MW. Neutralisation of TGF-beta 1 and TGF-beta 2 or exogenous addition of TGF-beta 3 to cutaneous rat wounds reduces scarring. *Journal of Cell Science*. 1995;**108**(Pt 3):985
- [19] Shah M, Foreman DM, Ferguson MWJ. Control of scarring in adult wounds by neutralising antibody to transforming growth factor β . *The Lancet*. 1992;**339**(8787):213-214
- [20] Chang J, Thunder R, Most D, Longaker MT, Lineaweaver WC. Studies in flexor tendon wound healing: Neutralizing antibody to TGF-beta1 increases postoperative range of motion. *Plastic and Reconstructive Surgery*. 2000;**105**(1):148
- [21] Loiselle AE, Kelly M, Hammert WC. Biological augmentation of flexor tendon repair: A challenging cellular landscape. *The Journal of Hand Surgery: American Society*. 2016;**41**(1):144-149 quiz 9
- [22] Zhou Y, Zhang L, Zhao W, Wu Y, Zhu C, Yang Y. Nanoparticle-mediated delivery of TGF- β 1 miRNA plasmid for preventing flexor tendon adhesion formation. *Biomaterials*. 2013;**34**(33):8269-8278
- [23] Tsubone T, Moran SL, Subramaniam M, Amadio PC, Spelsberg TC, An KN. Effect of TGF- β inducible early gene deficiency on flexor tendon healing. *Journal of Orthopaedic Research*. 2006;**24**(3):569-575

- [24] Mao WF, YF W, Yang QQ, Zhou YL, Wang XT, Liu PY, et al. Modulation of digital flexor tendon healing by vascular endothelial growth factor gene transfection in a chicken model. *Gene Therapy*. 2017;**24**(4):234-240
- [25] Tang JB, Zhou YL, YF W, Liu PY, Wang XT. Gene therapy strategies to improve strength and quality of flexor tendon healing. *Expert Opinion on Biological Therapy*. 2016;**16**(3):291-301
- [26] Basile P, Dadali T, Jacobson J, Hasslund S, Ulrich-Vinther M, Søballe K, et al. Freeze-dried tendon allografts as tissue-engineering scaffolds for Gdf5 gene delivery. *Molecular Therapy*. 2008;**16**(3):466-473
- [27] Zhao C, Ozasa Y, Reisdorf RL, Thoreson AR, Jay GD, An K-N, et al. CORR® ORS Richard A. Brand Award for outstanding orthopaedic research: Engineering flexor tendon repair with lubricant, cells, and cytokines in a canine model. *Clinical Orthopaedics and Related Research*. 2014;**472**(9):2569-2578
- [28] Chen S-H, Chen C-H, Fong YT, Chen J-P. Prevention of peritendinous adhesions with electrospun chitosan-grafted polycaprolactone nanofibrous membranes. *Acta Biomaterialia*. 2014;**10**(12):4971-4982
- [29] Baymurat AC, Ozturk AM, Yetkin H, Ergun MA, Helvacioğlu F, Ozkızılcık A, et al. Bio-engineered synovial membrane to prevent tendon adhesions in rabbit flexor tendon model: Bio-engineered synovial membrane. *Journal of Biomedical Materials Research Part A*. 2015;**103**(1):84-90
- [30] Galloway MT, Lalley AL, Shearn JT. The role of mechanical loading in tendon development, maintenance, injury, and repair. *The Journal of Bone and Joint Surgery American volume*. 2013;**95**(17):1620-1628
- [31] Rudge WBJ, James M. Flexor tendon injuries in the hand: A UK survey of repair techniques and suture materials – 2014: Are we following the evidence? *ISRR Plastic Surgery*. 2014;**2014**(4)
- [32] Langley C, Hobby J. Focus on flexor tendon repair. *The Journal of Bone and Joint Surgery British Volume*. 2010;**22**:1-3. www.boneandjoint.org.uk/content/focus/flexor-tendon-repair
- [33] Rawson S, Cartmell S, Wong J. Suture techniques for tendon repair: A comparative review. *Muscles, Ligaments and Tendons Journal*. 2013;**3**(3):220-228
- [34] McGeorge DD, Stilwell JH. Partial flexor tendon injuries: To repair or not. *The Journal of Hand Surgery: British & European Volume*. 1992;**17**(2):176-177
- [35] Viinikainen A, Göransson H, Ryhänen J. Primary flexor tendon repair techniques. *Scandinavian Journal of Surgery*. 2008;**97**(4):333-340
- [36] Lawrence TM, Davis TRC. A biomechanical analysis of suture materials and their influence on a four-strand flexor tendon repair. *The Journal of Hand Surgery*. 2005;**30**(4):836
- [37] Thien TB, Becker JH, Theis J-C. Withdrawn: Rehabilitation after surgery for flexor tendon injuries in the hand. *The Cochrane Database of Systematic Reviews*. 2010;(10):CD003979

- [38] Chesney A, Chauhan A, Kattan A, Farrokhyar F, Thoma A. Systematic review of flexor tendon rehabilitation protocols in zone II of the hand. *Plastic and Reconstructive Surgery*. 2011;**127**(4):1583-1592
- [39] Baskies MA, Tuckman DV, Paksima N. Management of flexor tendon injuries following surgical repair. *Bulletin of the NYU Hospital for Joint Diseases*. 2008;**66**(1):35-40
- [40] Mason ML, Allen HS. The rate of healing of tendons: An Experimental study of tensile strength. *Annals of Surgery*. 1941;**113**(3):424-459
- [41] Birdsell DC, Tustanoff ER, Kindsay WK. Collagen production in regenerating tendon. *Plastic and Reconstructive Surgery*. 1966;**37**(6):504-511
- [42] Gelberman RH, Menon J, Gonsalves M, Akeson WH. The effects of mobilization on the vascularization of healing flexor tendons in dogs. *Clinical Orthopaedics and Related Research*. 1980;**153**:283-289
- [43] Woo SL, Gelberman RH, Cobb NG, Amiel D, Lothringer K, Akeson WH. The importance of controlled passive mobilization on flexor tendon healing. A biomechanical study. *Acta Orthopaedica Scandinavica*. 1981;**52**(6):615-622
- [44] Woo SL, Gomez MA, Amiel D, Ritter MA, Gelberman RH, Akeson WH. The effects of exercise on the biomechanical and biochemical properties of swine digital flexor tendons. *Journal of Biomechanical Engineering*. 1981;**103**(1):51-56
- [45] O'Connell SJ, Moore MM, Strickland JW, Thomas Frazier G, Dell PC. Results of zone I and zone II flexor tendon repairs in children. *The Journal of Hand Surgery*. 1994;**19**(1):48-52
- [46] Kato H, Minami A, Suenaga N, Iwasaki N, Kimura T. Long-term results after primary repairs of zone 2 flexor tendon lacerations in children younger than age 6 years. *Journal of Pediatric Orthopaedics*. 2002;**22**(6):732-735
- [47] Collins DC, Schwarze L. Early progressive resistance following immobilization of flexor tendon repairs. *Journal of Hand Therapy*. 1991;**4**(3):111-116
- [48] Kubota H, Manske PR, Aoki M, Pruitt DL, Larson BJ. Effect of motion and tension on injured flexor tendons in chickens. *The Journal of Hand Surgery*. 1996;**21**(3):456
- [49] Moriya K, Yoshizu T, Maki Y, Tsubokawa N, Narisawa H, Endo N. Clinical outcomes of early active mobilization following flexor tendon repair using the six-strand technique: Short- and long-term evaluations. *The Journal of Hand Surgery, European Volume*. 2015;**40**(3):250-258
- [50] May EJ, Silfverskiöld KL, Sollerman CJ. Controlled mobilization after flexor tendon repair in zone II: A prospective comparison of three methods. *The Journal of Hand Surgery*. 1992;**17**(5):942-952
- [51] Stegink Jansen CW, Minerbo G. A comparison between early dynamically controlled mobilization and immobilization after flexor tendon repair in zone 2 of the hand: Preliminary results. *Journal of Hand Therapy*. 1990;**3**(1):20-25
- [52] Elliot D, Giesen T. Avoidance of unfavourable results following primary flexor tendon surgery. *Indian Journal of Plastic Surgery: Official Publication of the Association of Plastic Surgeons of India*. 2013;**46**(2):312-324

- [53] Gelberman RH, Nunley NJA, Osterman AL, Breen TF, Dimick MP, Woo SL. Influences of the protected passive mobilization interval on flexor tendon healing. A prospective randomized clinical study. *Clinical Orthopaedics and Related Research*. 1991;**264**:189-196
- [54] Small JO, Brennen MD, Colville J. *Early Active Mobilisation Following Flexor Tendon Repair in Zone 2*. Scotland: Elsevier Ltd; 1989. pp. 383-391
- [55] Allen BN, Frykman GK, Unsell RS, Wood VE. Ruptured flexor tendon tenorrhaphies in zone II: Repair and rehabilitation. *The Journal of Hand Surgery*. 1987;**12**(1):18-21
- [56] Tang JB, Amadio PC, Boyer MI, Savage R, Zhao C, Sandow M, et al. Current practice of primary flexor tendon repair: a global view. *Hand Clinics*. 2013;**29**(2):179
- [57] Pettengill KM. The evolution of early mobilization of the repaired flexor tendon. *Journal of Hand Therapy*. 2005;**18**(2):157-168
- [58] Gratton P. Early active mobilization after flexor tendon repairs. *Journal of Hand Therapy*. 1993;**6**(4):285-289
- [59] Kannas S, Jeardeau TA, Bishop AT. Rehabilitation following zone II flexor tendon repairs. *Techniques in Hand & Upper Extremity Surgery*. 2015;**19**(1):2-10
- [60] Hsiao P-C, Yang S-Y, Ho C-H, Chou W, Lu S-R. The benefit of early rehabilitation following tendon repair of the hand: A population-based claims database analysis. *Journal of Hand Therapy: Official Journal of the American Society of Hand Therapists*. 2015;**28**(1):20-26
- [61] Lilly SI, Messer TM. Complications after treatment of flexor tendon injuries. *The Journal of the American Academy of Orthopaedic Surgeons*. 2006;**14**(7):387-396

