

We are IntechOpen, the world's leading publisher of Open Access books Built by scientists, for scientists

6,900

Open access books available

186,000

International authors and editors

200M

Downloads

Our authors are among the

154

Countries delivered to

TOP 1%

most cited scientists

12.2%

Contributors from top 500 universities



WEB OF SCIENCE™

Selection of our books indexed in the Book Citation Index
in Web of Science™ Core Collection (BKCI)

Interested in publishing with us?
Contact book.department@intechopen.com

Numbers displayed above are based on latest data collected.
For more information visit www.intechopen.com



Heterotopic Heart Transplantation

Hannah Copeland and Jack G. Copeland

Additional information is available at the end of the chapter

<http://dx.doi.org/10.5772/intechopen.74582>

Abstract

The heterotopic heart transplant was pioneered by Christian Barnard in the late 1970s as a way to treat acute rejection in the pre-cyclosporine era. The technique was also used for the treatment of severe pulmonary hypertension, in patients unable to have an orthotopic heart transplant. Some surgeons have used the heterotopic heart transplant as a way to increase the donor heart pool around the world in more recent years. The heterotopic heart transplant is a good viable option for severe pulmonary hypertension patients, and, severe pulmonary vascular resistance patients, who would otherwise, not qualify for an orthotopic heart transplant. The outcomes for these recipients have been comparable to survival outcomes for similar orthotopic heart transplant recipients.

Keywords: heterotopic, transplant, heart

1. Introduction

By August of 1975 [1], 277 patients had received an orthotopic heart transplantation and 49 were alive. The longest survivor lived 6.8 years.

Christian Barnard reported the heterotopic heart transplant (HHT) technique. In 1976 [1], Barnard noted the benefits of heterotopic heart transplantation to be that the donor heart acts as an assist device, assists during episodes of rejection, can be removed in case of severe graft rejection, and still the patient may receive a subsequent heart transplant. Barnard et al. [2] published a case report of a heterotopic heart transplant recipient that suffered acute rejection and was supported by the native heart while the heterotopic graft recovered.

At the time the paper was written, cyclosporine was not used for post-heart transplantation and the incidence of acute rejection was more common. The heterotopic heart transplant technique offered an extra layer of prevention and/or treatment during the pre-cyclosporine

era when death within 24 hours of the onset of rejection was common. In addition, to the benefits from treatment of acute rejection, the heterotopic heart transplantation technique allows selected recipients with pulmonary hypertension to receive a transplant.

2. Heterotopic heart transplantation history and current use

Between 1974 and 1982, Barnard performed 40 heterotopic heart transplants [3]. The first year, second year and five-year survival for heterotopic heart transplantation was 61, 50 and 36%. These survival rates compared well to the orthotopic heart transplant survival from Stanford of 63% at 1 year, 55% at 2 years and 39% at 5 years. The Copeland group from the University of Arizona, during the same time demonstrated 72% 1 and 2-year survival with orthotopic heart transplantation [3].

Bleasdale et al. [4] published the use of 42 consecutive, adult heterotopic heart transplantations in a single center from 1993 to 1999 and compared the outcomes to 303 consecutive orthotopic heart transplants (OHT) during the same time period. Thirty-three (33; 79%) of the heterotopic heart transplant recipients were men; and 26 recipients had ischemic heart disease (62%). In the comparative group of orthotopic heart transplant recipients, 38% had ischemic heart disease and 43% were dilated cardiomyopathy patients. The reasons for using a HHT in these recipients was urgency and need for transplant (36%), pulmonary hypertension of the recipient (55%), donor-recipient size mismatch [donor body surface area (BSA) < 75% of the recipient BSA] (62%); and the native heart was able to be repaired (19%). The patients were followed from 1 to 5 years. The heterotopic heart transplant recipients were older, more often had a donor-recipient size mismatch, and had a higher ischemic time. The ischemic time the HHT group was on average 191 minutes (165–241 minutes) vs. 165 minutes (120–202 minutes) in the orthotopic heart transplant group; which was statistically significant ($p = 0.001$). The OHT group had a higher 30-day survival of 87 vs. 76% HHT group. The 1-year survival was higher for the OHT group 74 vs. 59%. The three factors that predicted graft failure were: (1) donor recipient size mismatch, (2) donor age, and, (3) the female donor. The donors in the HHT group more often had a size mismatch, were older, and female. Of note, within the HHT group, those who were size matched had a markedly improved 1-year survival 81 vs. 45% ($p = 0.02$).

Overall, in the Bleasdale et al. [4] study HHT recipients had decreased 1-year survival. The decreased survival was predominantly in patients who had received a donor-recipient mismatched heart. The survival for size matched was comparable to those patients who received an orthotopic heart transplant. In addition, patients with severe and/or fixed pulmonary hypertension benefitted from the HHT; when, these recipients would not have been able to have an OHT.

Newcomb et al. [5] described the use of the heterotopic heart transplant to expand the donor pool in Australia. During a 6-year period from 1997 to 2003, the group performed 20 heterotopic heart transplants and 131 orthotopic heart transplants. The heterotopic heart transplant was used for: (1) fixed pulmonary hypertension (with a pulmonary vascular resistance greater than or equal to 3 Wood units, and a transpulmonary gradient (TPG) greater than or equal

to 13 mmHg), (2) donor to recipient weight ratio of less than 0.8, (3) anticipated ischemic time greater than 6 hours, and (4) a marginal donor heart. Marginal donors were described as those that required high inotropic support, had a history of a cardiac arrest or arrhythmia, wall motion abnormalities on the echocardiogram, and/or ischemic changes on the electrocardiogram (EKG). Fourteen of the donor hearts were marginal and had been declined by other centers. Most of the HHT recipients had more than one indication for an HHT.

In the study of Newcomb et al. [5], the heterotopic heart transplant recipients were significantly older (mean 58 years vs. 47.1 years for OHT); the donors were also significantly older (mean age 45.2 years vs. 34.5 years for OHT). The ischemic time was also much higher for the HHT recipients; 366 minutes vs. 258 minutes for OHT. The intensive care unit and the total length of the hospital stay was higher for HHT recipients; though, not statistically significant. The study demonstrated lower survival for heterotopic heart transplant recipients compared to orthotopic heart transplant recipients in the same time period; though, the survival benefit for OHT recipients disappeared when they performed a subgroup analysis for the recipients who had elevated pulmonary artery pressures. The study demonstrates the successful use of the heterotopic heart transplant. The survival in HHT recipients were not as good as in those of OHT recipients because of the HHT technique was more often used in marginal donors and more high-risk recipients. Marginal donor hearts may not have performed as well in OHT recipients. Furthermore, high risk recipients have decreased survival expectations especially with the use of a marginal donor heart.

Boffini et al. [6] described their single center experience with the heterotopic heart transplant; and, found the HHT to be comparable to OHT. HHT was used between in 1985–2003, in 12 patients [(1.7%) of the all the heart transplant performed during that time]. The 1-year and 5-year survival was 92 and 64% respectively. These results demonstrated when the HHT technique is used in the usual recipient risk patient, the outcomes can be effective and acceptable for recipients. The HHT technique was used for body size mismatch in 11 patients and 1 recipients for a marginal donor heart.

In addition to donor-recipient size mismatch, elevated pulmonary vascular resistance (PVR), and, fixed pulmonary hypertension are also indications for HHT. Vassileva et al. [7] reviewed 18 recipients with fixed pulmonary vascular resistance who received a HHT with the donor pulmonary artery anastomosed to the recipient right atrium. The indications were (1) $PVR > 6 \text{ units/m}^2$, (2) transpulmonary gradient (TPG) $> 15 \text{ mmHg}$, or, (3) pulmonary artery (PA) systolic pressure $> 60 \text{ mmHg}$. All of the recipients had some degree of pulmonary hypertension, and, 8 of the patients had a restrictive cardiomyopathy. Twelve of the patients were New York Heart Association class III or IV; the remaining six were in the hospital with continuous inotropic support, and, one was intubated. The mean aortic cross clamp time was 58 minutes and a mean ischemic time of 122 minutes. The follow-up right heart catheterizations demonstrated a progressive decrease in the pulmonary artery pressures after transplant with a mean systolic pulmonary artery pressure of 29 mmHg, a TPG of 10 mmHg, and, a PVR of 3.7 units/m^2 . The group concluded that the HHT technique was a valuable option for patients with elevated, and/or, fixed pulmonary artery pressures, and, elevated pulmonary vascular resistance.

3. The heterotopic surgical technique

There are two published surgical techniques for the heterotopic heart transplant. Novitzky et al. [8] published the first surgical technique pioneered by Christian Barnard in the 1970s. The heterotopic transplant technique pioneered by Barnard started with the anastomosis of the donor left atrium to the recipient left atrium. Then, the donor right atrium is anastomosed to the recipient right atrium and superior vena cava. Next, the donor aorta is sutured to the recipient aorta in an end to side fashion. The pulmonary anastomosis is the remaining anastomosis. The pulmonary artery is sutured to a dacron graft. The dacron graft is used to extend the anastomosis to the recipient pulmonary artery. Without the interposition graft, the donor and recipient pulmonary arteries would not be able to be brought together without tension or possibly not at all because of lack of length on the donor tissue (**Figure 1**).

In 2017, Copeland et al. [9] published an alternate heterotopic heart transplant technique as a biologic left ventricular assist. The donor heart left pulmonary veins and inferior vena cava are oversewn. The right pleura is widely opened, and the right posterior pericardium is opened toward the phrenic nerve at the level of the diaphragm, cephalad and in-between. The donor and recipient left atria are anastomosed first. Then, the donor aorta is anastomosed to the recipient aorta in an end to side fashion. The aortic cross clamp is removed, and, the patient is placed in Trendelenburg position. The donor pulmonary artery is anastomosed to the recipient right atrium. The donor superior vena cava (SVC) is anastomosed to the recipient superior vena cava in an end to side fashion (**Figure 2**). The anastomosis of the SVC is marked with clips, in order to be able to identify the anastomosis later for endomyocardial biopsy through the right internal jugular vein.

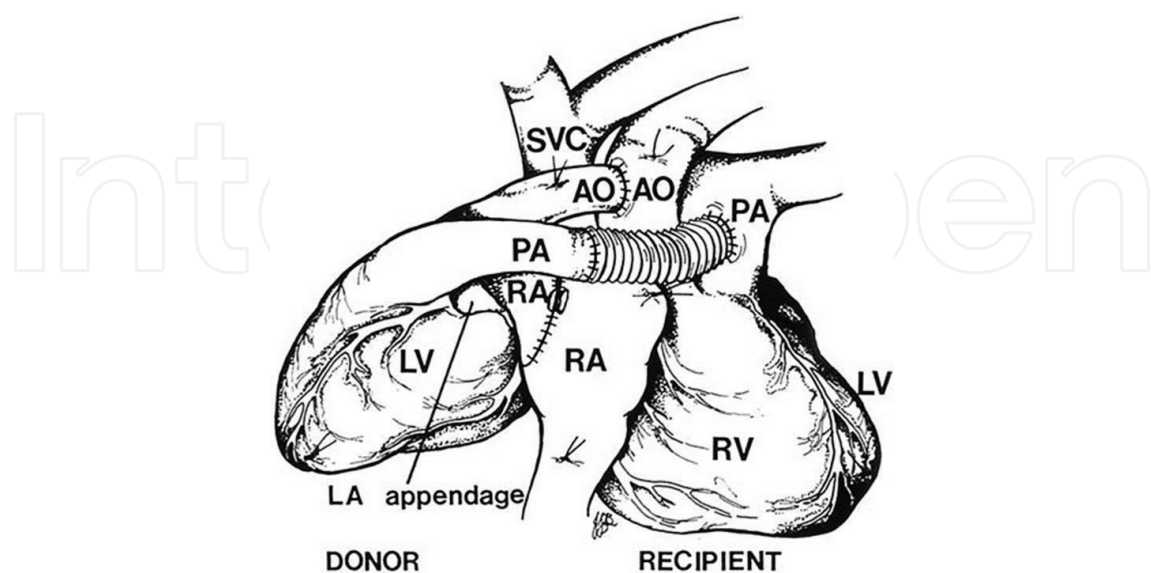


Figure 1. The Barnard heterotopic heart transplant technique with an interposition Dacron Graft. Permission Granted by Annals of Thoracic Surgery for reprint. Novitzky et al. [8].

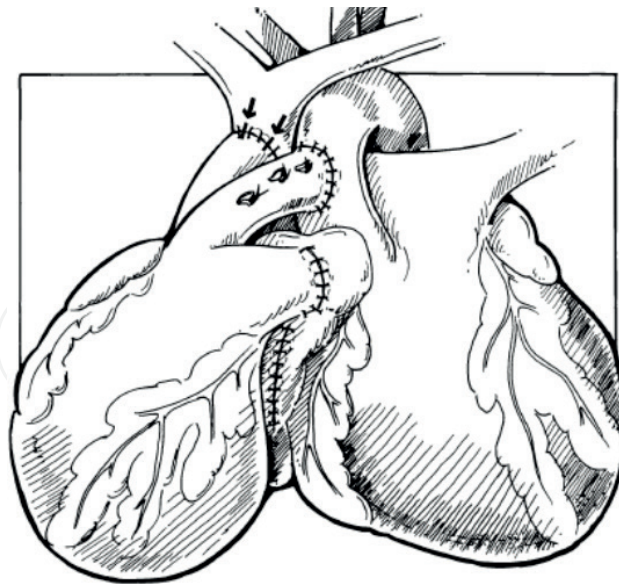


Figure 2. The Copeland heterotopic heart transplant technique. Permission granted by Annals of Thoracic Surgery for reprint. Arzouman et al. [13].

4. Series of patients with heterotopic heart transplants

The Copeland heterotopic heart transplant technique was used in the series of patients at the University of Arizona and University of California San Diego (by Jack Copeland). Between May 1984 to February 2011, 5 patients received a heterotopic heart transplant. The reasons for a heterotopic heart transplantation included the following: (1) fixed pulmonary hypertension with pulmonary artery (PA) pressures of 85/53 mmHg with a mean of 60 mmHg and pulmonary vascular resistance of 10 Woods units, (2) severe pulmonary hypertension of 85/30 mmHg with a mean of 48 mmHg and a PVR of 6 Woods units, (3) PA pressure of 69/34 mmHg with a trans-pulmonary artery gradient of 17 mmHg and pulmonary vascular resistance of 9 Woods units, and (4) and (5) donor recipient size mismatch in two patients.

Of the three patients with severe pulmonary hypertension, one was a 9-year old child was diagnosed with restrictive cardiomyopathy and had heart failure since early infancy [10]. The patient presented for transplant evaluation with incessant supraventricular tachycardia and pulmonary hypertension with a PA pressure of 85/53 mmHg with a mean of 60, and, a PVR of 10 Woods units. The patient's cardiac index was 3.1 l/min/sqM with an ejection fraction of 33% on echocardiogram with normal right ventricular function. The fractional shortening on the echocardiogram was 18%. The patient began to develop hepatomegaly and the total bilirubin was elevated to 2.8 mg/dl. The patient was on medical management for heart failure prior to transplant including: furosemide, spironolactone, digoxin, captopril, amiodarone, coumadin and prednisone. The patient was not on inotropic therapy. The patient was listed for heart transplantation and it was deemed that the child would not tolerate an orthotopic heart transplant because of the fixed pulmonary hypertension. The patient was not eligible for a left ventricular assist device (LVAD) because pediatric LVADs were not available in North America until 2000; when the first was implanted in North America.

The patient underwent a heterotopic heart transplant with the Copeland technique [9]. The patient was treated with standard institutional immunosuppressive therapy in 1997; including, rabbit antithymocyte globulin for induction, and, then followed with cyclosporine, mycophenolate and prednisone. The pulmonary artery pressures never decreased throughout the post-transplant course. At 13 years post-transplant, the patient began to have heart failure symptoms, and was re-listed for a heterotopic heart transplant. The patient was status 1B on and died while waiting for heart transplant at almost 14 years after his heterotopic heart transplant. Of note, Al-Khalidi et al. [11] reported a case report of 22-month-old who received a heterotopic heart transplant for restrictive cardiomyopathy and severe pulmonary hypertension. The patient required sildenafil in the post-operative period due to post-operative pulmonary hypertensive crisis, and, with sildenafil the patient was weaned from ventilator support and extubated.

The second patient also had severe pulmonary hypertension of 85/30 with a mean of 48 mmHg, and, a PVR of 6 Woods units. Due to his elevated pulmonary arterial pressure, the patient was listed and had a heterotopic heart transplant. He did not have clinical right heart failure. At one-year post-transplant, the pulmonary artery pressures decreased to 39/18 with a mean of 28 mmHg. Post-transplant, he had one episode of acute rejection that required hospitalizations treated with solumedrol. In addition, he had delirium and psychosis, the steroids were decreased, and the patient improved. The patient lived well for 6 years without complications. He presented to the hospital in respiratory distress. The autopsy demonstrated a pulmonary embolus, with esophageal and gastric ulcerations.

The third patient was a 36-year-old with pulmonary arterial hypertension, a dilated left ventricle with an 15% ejection fraction [a left ventricular end diastolic dimension (LVEDD) of 7.2 cm], and a slightly dilated right ventricle with preserved function and no right heart failure. His PA pressures were 69/34 mmHg with a mean of 47 with a transpulmonary gradient of 17 mmHg and a pulmonary vascular resistance of 9 Woods units. In the face of minimal evidence for right heart failure, a heterotopic heart transplant was performed. He was extubated on the first post-operative day and had normal graft function (LV ejection fraction of 64%), normal exercise tolerance, no right heart failure and a drop in his systolic PA pressure to 48 by trans-thoracic echo. Sadly, he remained impoverished and had great difficulty complying with post transplantation management. Three years later, he died of graft failure most likely from rejection.

The fourth patient was in the intensive care unit (ICU) on multiple inotropes; dobutamine, dopamine, and phenylephrine. A donor heart was accepted. The team knew the donor was "small" (5'5" and 60 kg) compared to the 6'2.5" and 90 kg recipient. The recipient was left awake in the operating room until the donor heart arrived. The surgeon (Jack Copeland) examined the donor heart and found it to be too small for an orthotopic transplant. The option of heterotopic placement was then discussed with the patient with a full explanation of increased risk from the size discrepancy. The recipient agreed to proceed. He survived for 11 months, leading a very active "normal" life. The patient succumbed to a recurrence of alcoholism associated with poor compliance and profound rejection. Prior to his demise, the patient had called the hospital relating symptoms of heart failure but was snowed in and unable to leave his home due to weather conditions. The patient had not taken his immunosuppressive medications for several days.

The fifth patient had a severely dilated left ventricle, with an 8 cm end diastolic dimension. He also was critically ill and was transplanted with a small donor heart (4.5 cm left ventricular end diastolic dimension (LVEDD)). He survived for 9.5 years. As time passed his LV continued to enlarge and he developed recurrent ventricular tachycardia of the native heart accompanied by chest pain and was treated with high dose amiodarone therapy. The side effects of the amiodarone were significant including bradycardia, lethargy, and exercise intolerance. He also had blue facial discoloration. His cardiac graft function was normal on transesophageal echocardiogram. He refused relisting for orthotopic transplantation. We also offered him a left ventricle cardiectomy of the native heart and he declined. He died at home suddenly 9.5 years post transplantation of unknown causes.

5. Conclusion and discussion

Heterotopic heart transplant patients require endomyocardial biopsies as do orthotopic heart transplant recipients. Barnard first described the endomyocardial biopsy in heterotopic heart transplant patients in 1982. [12] Arouzman et al. [13] also described the use of the endomyocardial biopsy in conjunction with the Copeland heterotopic heart transplant technique [9] by leaving clips at the SVC anastomosis for visualization at the time of endomyocardial biopsy (Figure 3).

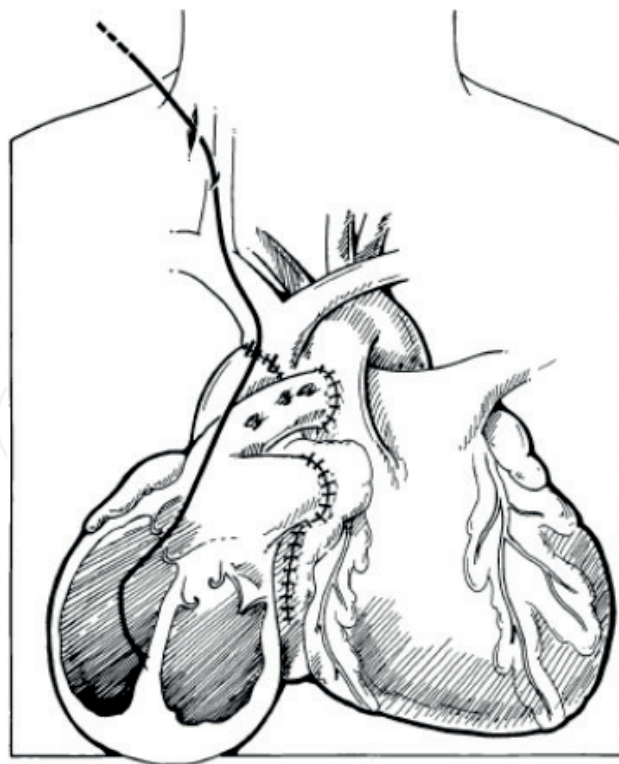


Figure 3. Endomyocardial biopsy of the donor heart in a heterotopic heart transplant. Permission granted by Annals of Thoracic Surgery for reprint. Arzouman DA et al. [13].

Heterotopic heart transplantation is a valuable treatment option for patients with severe and/or fixed pulmonary hypertension and severe pulmonary vascular resistance in the absence of native right ventricular failure. The patient cannot have an orthotopic heart transplant. Even though they may benefit from mechanical circulatory support, these patients would still benefit from a heterotopic heart transplant. The heterotopic heart transplant recipients described above lived well and had the typical post-heart transplant survival as an orthotopic heart transplant. HHT recipients must be followed as orthotopic heart transplants, have the same immunosuppression regimens and post-transplant biopsy schedule. A heterotopic heart transplant, will allow symptomatic improvement in the recipients with severe pulmonary hypertension and severely elevated PVR. Such patients may forgo LVAD implantation with attendant complications and short-term survival. Some of these patients with HHT may experience reduction of PVR while others may not such as the young heterotopic heart transplant recipient who barely had a decrease in PA pressures over the almost 14-year post-transplant course.

Based on the literature, it is difficult to determine if the heterotopic heart transplant would increase the donor pool by using size mismatched hearts. In the literature, Bleasdale et al. [4], and Newcomb et al. [5], note that the heterotopic heart transplant recipients had decreased survival compared to orthotopic heart transplant recipients. Though, the recipients in those studies were not as good candidates as the orthotopic recipients, and the heterotopic donor hearts were also considered marginal donors, often declined by other centers. Thus, the heterotopic heart transplant may still be a valuable option to increase the donor pool if the donors are not marginal and not used in less than ideal heart transplant recipients. The literature and patient review demonstrates that severe pulmonary hypertension and elevated pulmonary vascular resistance are clear indications for heterotopic heart transplantation with good survival outcomes.

Author details

Hannah Copeland^{1*} and Jack G. Copeland²

*Address all correspondence to: hannahcopeland411@gmail.com

1 University of Mississippi Medical Center, Jackson, Mississippi, United States of America

2 University of Arizona, Tucson, Arizona, United States of America

References

- [1] Barnard CN. Heterotopic versus orthotopic heart transplantation. *Transplantation Proceedings*. 1976;8(1):15-19
- [2] Barnard CN, Losman JG, Curcio CA, et al. The advantage of heterotopic cardiac transplantation over orthotopic cardiac transplantation in the management of severe acute rejection. *The Journal of Thoracic and Cardiovascular Surgery*. 1977 Dec;74(6):918-924

- [3] Hassoulas J, Barnard CN. Heterotopic cardiac transplantation. *SA Medical Journal*. 1984 April;**65**:675-682
- [4] Bleasdale RA, Banner NR, Anyanwu AC, et al. Determinants of outcome after heterotopic heart transplantation. *The Journal of Heart and Lung Transplantation*. 2002;**21**:867-873
- [5] Newcomb AE, Esmore DS, Rosenfeldt FL, et al. Heterotopic heart transplantation: An expanding role in the twenty-first century? *The Annals of Thoracic Surgery*. 2004;**78**: 1345-1351
- [6] Boffini M, Ragni T, Pellegrini, et al. Heterotopic heart transplantation: A single-centre experience. *Transplantation Proceedings*. 2004;**36**:638-640
- [7] Vassileva A, Valsecchi O, Sebastiani R, Fontana A, et al. Heterotopic heart transplantation for elevated pulmonary vascular resistance in the current era: Long-term clinical and hemodynamic outcomes. *The Journal of Heart and Lung Transplantation*. 2013 Sept;**32**(9):934-936
- [8] Novitzky D, Cooper DKC, Barnard CN. The surgical technique of heterotopic heart transplantation. *The Annals of Thoracic Surgery*. 1983;**36**:476-482
- [9] Copeland J, Copeland H. Heterotopic heart transplantation: Technical considerations. *Operative Techniques in Thoracic and Cardiovascular Surgery*. 2017;**21**:269-280
- [10] Copeland H, Kalra N, Gustafson M, et al. A case of heterotopic heart transplant as a “biologic left ventricular assist” in restrictive cardiomyopathy. *World Journal of Pediatric and Congenital Heart Surgery*. 2011 Oct;**2**(4):637-640
- [11] Al-Khaldi A, Reitz BA, Zhu H, et al. Heterotopic heart transplant combined with postoperative sildenafil use for the treatment of restrictive cardiomyopathy. *The Annals of Thoracic Surgery*. 2006;**81**:1505-1507
- [12] Cooper DKC, Fraser RC, Rose AG, et al. Technique, complications, and clinical value of endomyocardial biopsy in patients with heterotopic heart transplants. *Thorax*. 1982;**37**: 727-731
- [13] Arzouman DA, Arabia FA, Sethi GK, et al. Endomyocardial biopsy in the heterotopic heart transplant patient. *The Annals of Thoracic Surgery*. 1998;**65**:857-858

