

# We are IntechOpen, the world's leading publisher of Open Access books Built by scientists, for scientists

6,900

Open access books available

185,000

International authors and editors

200M

Downloads

Our authors are among the

154

Countries delivered to

TOP 1%

most cited scientists

12.2%

Contributors from top 500 universities



WEB OF SCIENCE™

Selection of our books indexed in the Book Citation Index  
in Web of Science™ Core Collection (BKCI)

Interested in publishing with us?  
Contact [book.department@intechopen.com](mailto:book.department@intechopen.com)

Numbers displayed above are based on latest data collected.  
For more information visit [www.intechopen.com](http://www.intechopen.com)



---

# Interferon-Induced Thrombotic Microangiopathy

---

Ajay Kundra, Mirela Andrei and Jen Chin Wang

Additional information is available at the end of the chapter

<http://dx.doi.org/10.5772/intechopen.74226>

---

## Abstract

Interferon (IFN) is an effective therapy for multiple disorders. An infrequently reported side effect is thrombotic microangiopathy (TMA): thrombotic thrombocytopenic purpura (TTP) and hemolytic uremic syndrome (HUS). We published the first comprehensive review analyzing this association with the following observations: (1) there was a higher incidence of IFN-induced TMA in myeloproliferative disorders (chronic myelogenous leukemia (CML)) than that in nonmalignant disorders (multiple sclerosis (MS), chronic hepatitis C virus infection (HCV)); (2) mean age at diagnosis was 47 years; (3) there was rare association with hairy cell leukemia (HCL), Sezary syndrome (one case each) and no cases reported for polycythemia vera (PV); (4) sex distribution was balanced (exception of higher prevalence in females for MS); (5) TMA was insidious in onset with long incubation periods (average treatment duration 40.4 months); (6) comparative analysis of mean time (months) to onset of TMA ensuing cumulative IFN exposure was: MS 68.6 vs. CML 35.5 vs. HCV 30.4; (7) confirmed TTP (low ADAMTS 13 levels) was associated with the presence of an inhibitor; (8) outcome analysis revealed complete remission in 27 (40%), persistent chronic kidney disease in 28 (42%) and fatality in 12 patients (18%); (9) corticosteroids, plasma exchange (PEX) and rituximab are effective therapies.

**Keywords:** thrombocytopenia, interferon, thrombotic microangiopathy (TMA), thrombotic thrombocytopenia purpura (TTP), myeloproliferative disorder, HCV

---

## 1. Introduction

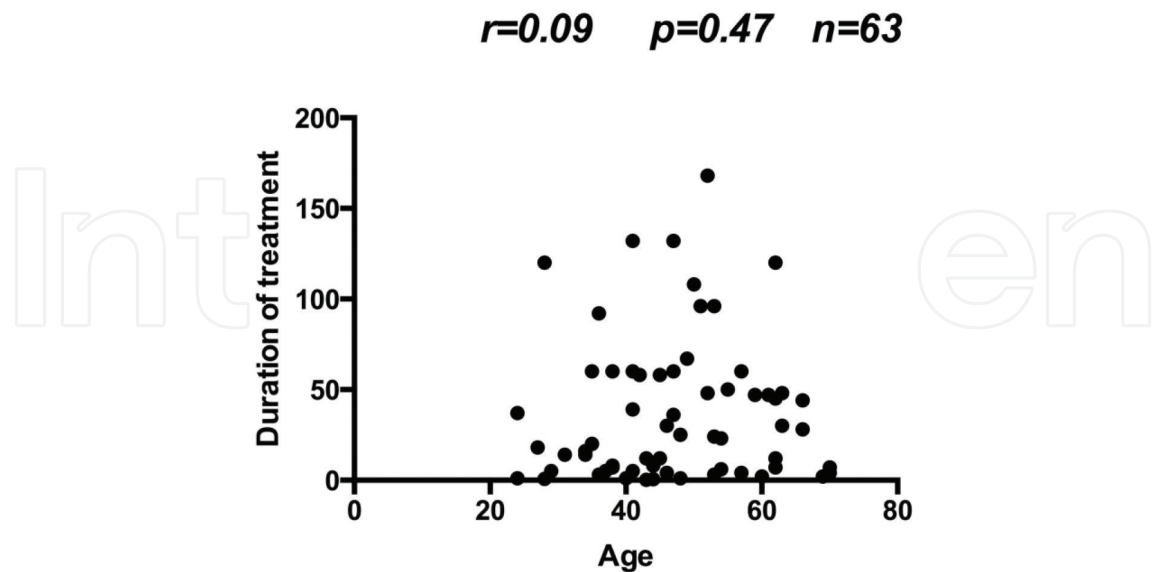
Thrombocytopenia is a common side effect of IFN treatment. TMA is a distinct clinical entity with potentially fatal consequences without precise and expeditious intervention. Classic clinical presentation includes a triad of anemia, thrombocytopenia, and evidence of microangiopathic hemolysis on the peripheral blood smear. The quintessential pathologic feature is the development of microvascular thrombi affecting small or larger vessels with variable

organ involvement. TMA, including TTP, is associated with a broad spectrum of conditions such as hemolytic uremic syndrome (HUS), disseminated intravascular coagulation (DIC), malignant hypertension, infections, autoimmune disorders and drugs. Irrespective of etiology, endothelial damage is the fundamental process and is instrumental in the generation of intravascular microthrombi [1]. Furthermore, TTP is characterized by decreased ADAMTS-13 levels, with most patients having severe deficiency (<10%). There was no prior precedent of a comprehensive review exploring IFN-associated TMA. We performed a PubMed search of all articles published between January 1993 and July 2016, focusing on interferon-induced TMA cross-referenced with the following terms: thrombotic thrombocytopenic purpura (TTP), IFN and thrombocytopenia, thrombotic microangiopathies, ADAMTS-13, autoimmune disease and IFN, interferon and hepatitis C, IFN and CML, IFN and multiple myeloma, IFN and renal cell cancer, IFN and polycythemia vera, IFN and lymphoma. Our analysis of this data was published in an exclusive review [2] with results outlined in the following sections.

2. Results

2.1. Age

Majority of patients were between 40 and 60 years of age. Mean ± SE was 47 (95% CI, 44–50). There was no correlation between age and duration of interferon treatment (**Figure 1**). For comparison of older (≥60 years) to younger (<60 years) patients with regard to the duration of IFN treatment, Mann Whitney U test was used; median and interquartile range (in months)



**Figure 1.** Correlation of age to duration of interferon (IFN) treatment before developing TMA. Sixty-eight patients including 29 CML, 20 MS, 17 Hepatitis C, 1 hairy cell leukemia, and 1 Sezary syndrome were studied. Correlation analysis using nonparametric Spearman’s method was used to correlate age and duration of treatment (months). No significant correlation between age and duration of IFN usage was found.

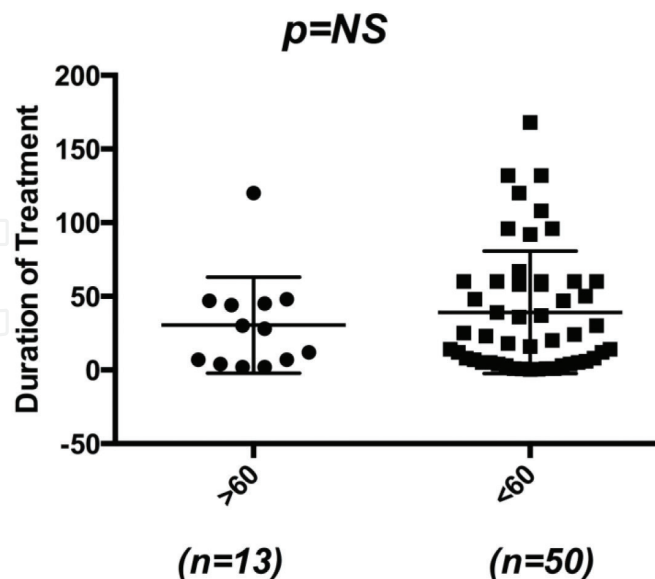
were (28, 5.5–46) and (23.50, 5–60) for older and younger age groups, respectively. Results were not statistically significant (**Figure 2**).

## 2.2. Sex

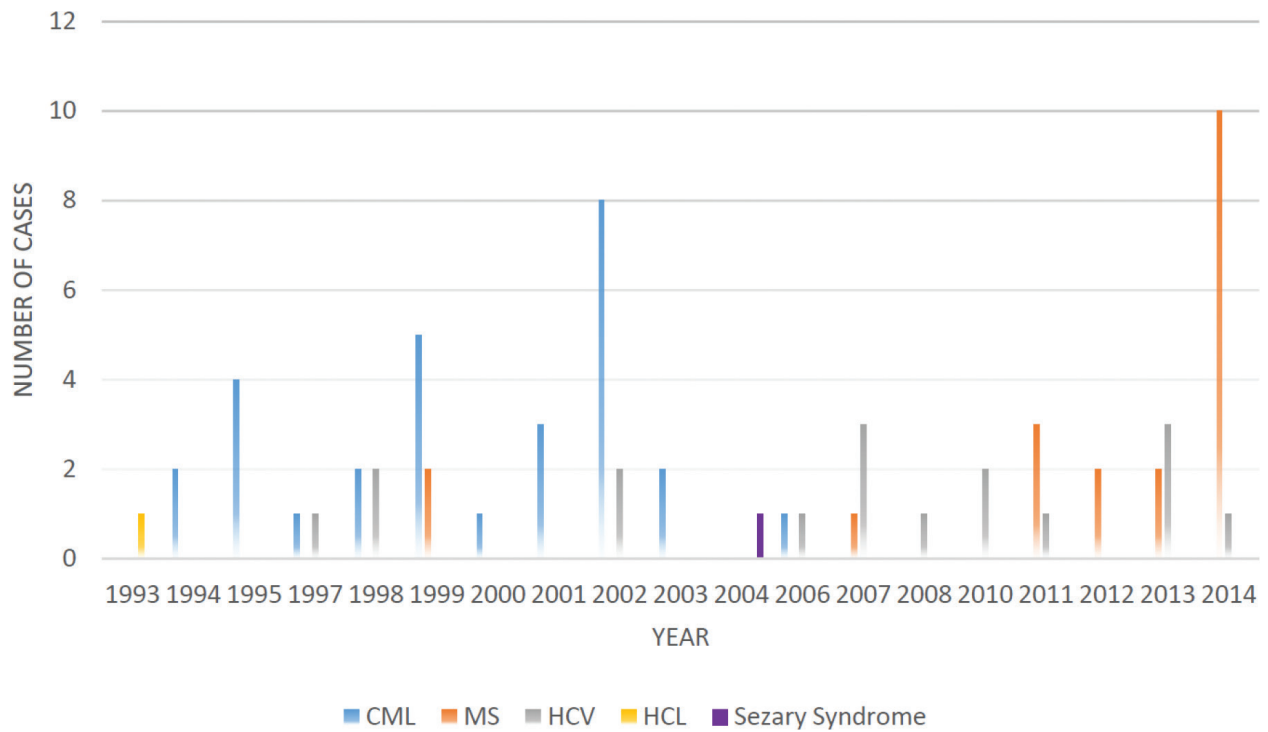
On cumulative data review, for the cases where information was available, sex distribution was balanced (30 male and 33 female patients). In subgroup analysis, patients with MS treated with IFN $\beta$  had a female predominance (12 out of 16; 75%). This may, however, just be reflective of higher prevalence of MS in women.

## 2.3. Associated clinical conditions

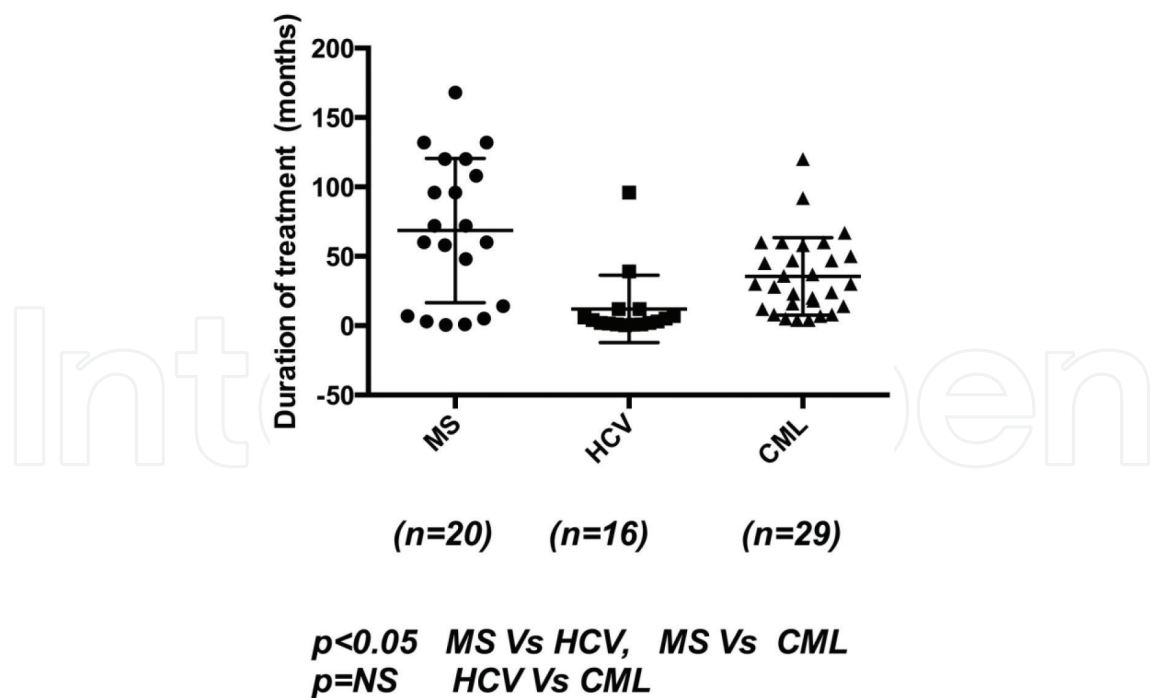
An aggregate of 68 cases reported from January 1993 to July 2016 was reviewed. The chronologic distribution of cases of IFN-induced TMA based on underlying diagnosis is shown in **Figure 3**. Incidence was highest in patients with CML followed by MS and HCV (29, 20 and 17, respectively) [3–44]. One case each was reported in patients with hairy cell leukemia (HCL) and Sezary syndrome [45, 46]. There have been no reports in patients with CML in the last 10 years correlating with the change in standard of care for the treatment of CML with tyrosine kinase inhibitors. There was no apparent difference in age distribution based on diagnosis. The cumulative duration of IFN exposure was highest in patients with MS treated with IFN  $\beta$  when compared to CML or HCV treated with IFN  $\alpha$ : mean (months)  $\pm$  SE: MS 68.6 (95% CI, 45.85–91.4), CML 35 (95% CI, 25.3–45.7) and HCV 12 (95% CI, 0.14–23.94). This was statistically significant (**Figure 4**) and is probably due to the difference in interferon type or different disease entity (IFN $\beta$  in MS vs. IFN $\alpha$  in CML and HCV).



**Figure 2.** Comparison between older age ( $\geq 60$ ) with younger age ( $< 60$ ) in relation to the duration of IFN usage. In order to compare older ( $\geq 60$  years) to younger ( $< 60$  years) patients with regard to the duration of interferon treatment, Mann Whitney U test was used; median and interquartile range (in months) were (28, 5.5–46) and (23.50, 5–60) for older and younger age groups, respectively. No statistical significance was found.



**Figure 3.** Incidence of reported cases of thrombotic microangiopathy by year and diagnosis: Results of incidence data analysis from the first reported case of IFN-induced TMA in 1993 to July 2016.

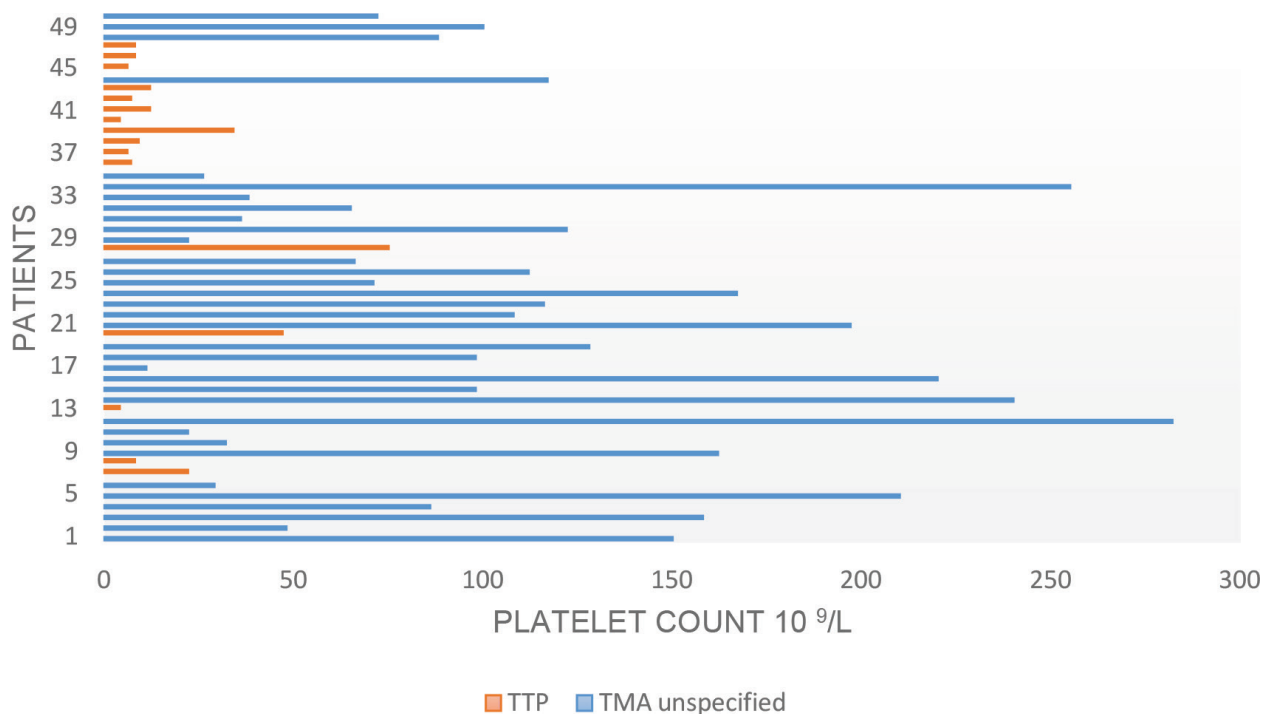


**Figure 4.** Comparison of cumulative IFN dose exposure prior to the onset of TMA in patients with CML, Hepatitis C, MS. Patients with MS treated with IFN $\beta$  showed longest duration of treatment exposure prior to the onset of TMA in comparison with patients with CML and hepatitis C treated with IFN $\alpha$ . Data were statistically significant.

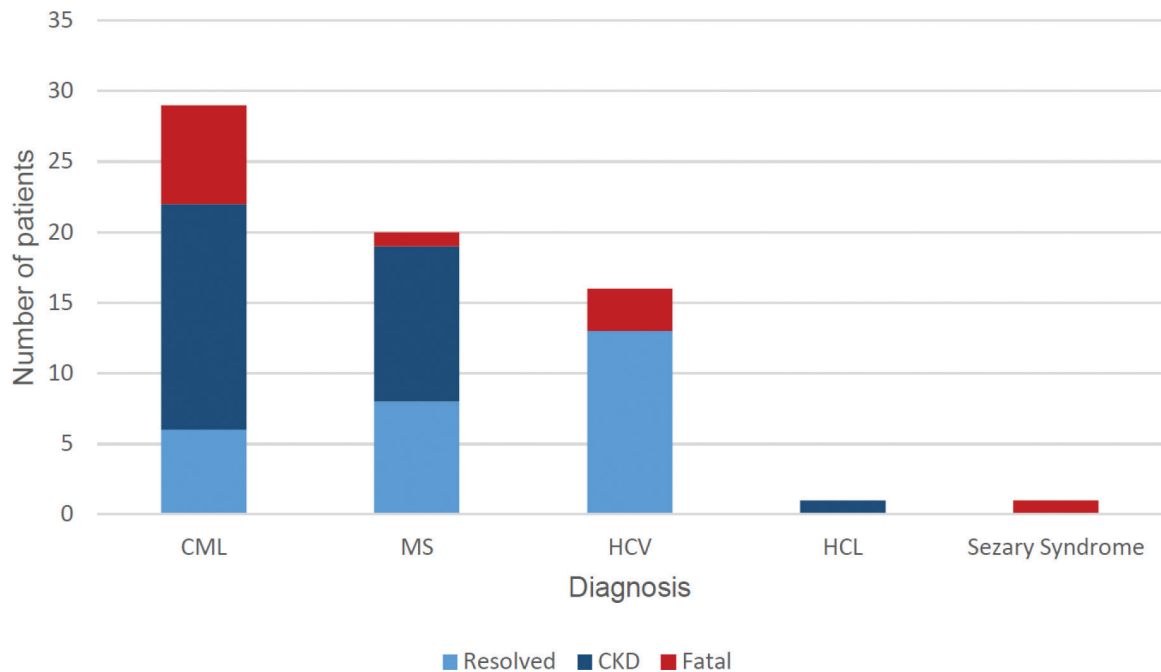
Predominant clinical presentation was neurologic dysfunction, anemia, thrombocytopenia, and renal insufficiency. Platelet counts were analyzed for 50 patients where complete blood count (CBC) data were available. Sixteen patients were diagnosed with TTP based on clinical presentation, low ADAMTS13 level, renal biopsy or other evidence of TMA and the remaining as HUS, TTP-HUS or TMA. We grouped the latter for the purpose of our analysis as TMA unspecified. It appears that all patients with TTP presented with moderate-to-severe thrombocytopenia. In the group TMA unspecified, this was not a consistent finding (**Figure 5**). A significant number of patients were diagnosed as having TMA based on characteristic renal biopsy findings of microangiopathy. There were no other clearly discernible features that set these subgroups of patients apart.

## 2.4. Treatment and outcome

In our review of the 63 patients with available treatment data, 35 (56%) were treated with plasma exchange (PEX) with or without steroids, 12 (19%) were treated with steroids with or without plasma infusion, and 16 (25%) were treated by other means including IFN discontinuation or dose reduction, antihypertensive treatment, rituximab and hemodialysis. Of the 67 patients with available outcome data, 27 patients (40%) had complete response, 28 (42%) developed persistent CKD and 12 (18%) had a fatal outcome (**Figure 6**).



**Figure 5.** Platelet count trend at the time of diagnosis of TTP and TMA unspecified. Out of the 50 patients with available CBC data, 16 were diagnosed as TTP and rest as HUS, TTP-HUS or TMA. Data from the latter group of patients were pooled for the purpose of analysis as TMA unspecified. Patients with TTP presented consistently with moderate-to-severe thrombocytopenia, whereas there were wide fluctuations in platelet counts in patients with TMA unspecified.



**Figure 6.** Outcome analysis data: Of the 67 patients with available outcome data, 27 patients (40%) had complete response, 28 (42%) developed persistent CKD and 12 (18%) died. Data were shown by underlying diagnosis.

2.5. Role of ADAMTS-13 inhibitor

There were eight cases of TTP where low ADAMTS 13 level was demonstrated, six of these also had ADAMTS 13 inhibitor. Notably, all patients with ADAMTS 13 inhibitor responded to PEX, steroids, and, in resistant cases, rituximab and vincristine. These results imply that IFN-induced TTP is probably an immune-mediated phenomenon with immune suppression being a key therapeutic intervention. ADAMTS13 levels were not available for all other cases making clear distinction between TTP and HUS difficult. We therefore analyzed results under the broader umbrella of TMA. In this context, we used a composite term TTP-HUS for clinical description.

3. Discussion

IFNs are a family of natural cytokines that interfere with viral replication, cell proliferation and immune regulation. Endogenous interferon production constitutes the initial nonspecific immune response against viral infections before specific host immune repertoire takes over. There are two major types of endogenous interferons: type 1 (IFN $\alpha$ —produced by leukocytes; IFN $\beta$ —produced by fibroblasts and epithelial cells) and type 2 (IFN $\gamma$ —produced by activated T cells and NK cells). Viral infection activates pattern recognition receptors such as toll-like receptors (TLR) on macrophages and induces early IFN-1 activation. This further accelerates viral clearance by the upregulation of adaptive immune response [47]. Clinical applications of treatment with exogenous IFN include hematologic malignancies such as CML, lymphoma, PV; solid tumors such as renal cell carcinoma; and nonmalignant



disorders such as MS and HCV. Besides CML and one case each of Sezary syndrome and hairy cell leukemia, IFN use has not been associated with TMA in any other myeloid or lymphoid malignancy [46, 48–52].

In order to understand pathologic process involved, it is important to outline the known and proposed mechanisms of action of IFN. Recombinant type I interferons ( $\alpha$  and  $\beta$ ) are pleiotropic cytokines that affect cellular function via immune regulatory mechanisms along with the regulation of cellular proliferation, apoptosis and angiogenesis. Dominant mechanisms are also disease specific. For example, in MS, T regulatory cell (Treg) dysregulation and decreased T helper (Th1) activity have been associated with clinical relapses [53]. Also, more recently, immunopathologic response from Th17 expansion and breakdown of blood brain barrier (BBB) have been implicated. Among other mechanisms, recombinant IFN $\beta$  is thought to restore Th1/Th2 balance, Treg function and regulation of T cell trafficking across BBB, thereby decreasing neuronal damage.

IFN action in myeloproliferative neoplasms (MPNs) is more complex, is incompletely understood and appears to utilize several pathways. While IFN $\alpha$  is not a Janus kinase 2 (JAK-2) inhibitor, it is able to eliminate the malignant JAK 2 mutant clone and achieve molecular remission in PV. There are a few widely accepted hypotheses for the mechanism of action of IFN $\alpha$  in MPN: enhanced cycling of quiescent leukemic stem cells (LSCs), restoration of dendritic cell function and promoting T cell activation by overcoming T cell energy [54–56].

Several possible pathophysiologic mechanisms have been described by which IFN may lead to TMA. In our review, cases with a clear diagnosis of TTP (with measured low levels of ADAMTS 13) also had ADAMTS 13 antibodies (ADAMTS 13 inhibitor). It appears that IFN-induced immune response plays a pivotal role in the production of cross-reacting anti-ADAMTS-13 antibodies with resultant microangiopathic hemolysis. While seemingly speculative, this observation has to be seen in the context of association of interferon therapy with the development of other autoimmune diseases. Prospective studies from patients treated with IFN $\alpha$  for hepatitis C showed that approximately 40% patients developed antithyroid antibodies with 15% developing clinical disease [57]. There are three different types of thyroid dysfunction associated with the IFN treatment: autoimmune (often subclinical) hypothyroidism, destructive thyroiditis and Graves hyperthyroidism. Females carry a higher risk to develop autoimmune thyroid disorders (AITDs) upon IFN treatment, with a relative risk of 4.4 (95% CI, 3.2–5.9) [58]. The pattern of thyroid disease observed resembles endogenous immunostimulation in the postpartum period. Development of multiple sclerosis has also been reported following the treatment of chronic phase CML with IFN $\alpha$ 2b [59]. Taken together, these observations lend support to our inference that immune activation is fundamental for IFN-induced TTP.

The pathogenesis of TMA may also involve inhibition of vascular endothelial growth factor (VEGF) in renal podocytes [60]. Under physiologic conditions, VEGF stimulates signal transduction pathways and transcription through activation of its receptor VEGFR2. These events are essential for angiogenesis. The physiologic role of VEGF in kidneys is unclear but it has been associated with the pathophysiology of various renal diseases. Renal consequences of VEGF inhibition have been studied for VEGF antagonist bevacizumab. It has been proposed



that local production of VEGF plays a critical protective role in microangiopathic processes. VEGF inhibitors such as bevacizumab disrupt this pathway and promote thrombotic microangiopathy [61]. IFN type 1 family also causes VEGF inhibition and hence may have a shared pathogenetic mechanism with VEGF antagonists. Vasoconstrictive and pro-coagulant effects of type I interferon have also been studied in pulmonary arterial hypertension. Experimental models have shown that IFN $\alpha$  increases pulmonary vascular resistance by the activation of thromboxane cascade [62].

There are various mechanisms proposed for IFN-induced HUS. Increased leukocyte adhesion to endothelial cells triggers endothelial damage and releases large multimers of von Willebrand factor causing endothelial swelling, platelet aggregation and intraluminal microthrombi formation causing tissue injury [63]. The development of antiphospholipid antibodies [64], antiendothelial cell antibodies and overexpression of class I antigens rendering cells vulnerable to cytotoxic response are some of the other described mechanisms [65].

Kavanagh et al. described potential immune-mediated and toxic mechanisms of IFN-induced TMA in MS patients [66]. They also reported a cumulative dose-toxicity relationship similar to our observation. In their analysis of data from a single institution involving eight patients, the duration of exposure was similar for IFN $\alpha$  and IFN $\beta$ , with TMA developing with long-term therapy at higher doses. In our analysis of a larger patient cohort, however, there is a statistically significant difference between the duration of exposure in MS (treated with IFN $\beta$ ) versus CML and HCV (treated with IFN $\alpha$ ). Although there is a complex interplay of a multitude of factors, our observations suggest that the underlying disease process is a key determinant accounting for the differences in the duration of exposure to IFN preceding onset of TMA. Additionally, however, the differences in IFN subtype (due to the differences in potencies of immunomodulatory and antiproliferative properties) is probably an additional, but secondary factor. In MS, among the accepted underlying mechanisms of IFN action is the ability to regain immunologic balance by restoring Treg cell function. On the other hand, in CML, IFN treatment creates a proinflammatory state for effective immune surveillance. This is supported by the observation of clonal T cell expansion in CML patients treated with IFN $\alpha$ . This difference between immune modulation and immune escalation could possibly account for the earlier development of TMA in CML. Similarly, in treatment of HCV, exogenous IFN binds to cell surface receptors and causes activation of IFN response genes (IRGs) via signal transduction through JAK-STAT pathway. This augments inflammatory response creating an antiviral state [67]. Immune dysfunction is commonly seen in lymphoproliferative disorders wherein the malignant cells originate from the immune system itself. It is therefore possible that impaired autoantibody production in this setting may be the reason for the lack of any observed cases of TMA in lymphoma. Limited clinical indications for IFN use may explain similar finding in PV.

Early diagnosis and prompt institution of treatment is of paramount importance in TMA. In contrast to drug-induced thrombocytopenia, IFN-induced TMA is insidious in onset with long incubation periods (average 40.2 months) and may masquerade as a more benign condition. It is therefore imperative that this association is recognized in clinical practice. Since ADAMTS13 results are not available in real time, a proposed quick guide to determine the likelihood of severely deficient ADAMTS13 activity is PLASMIC score (platelets, lysis, active

cancer, stem cell or solid organ transplant, MCV, INR, creatinine): 0–4 score is associated with a low risk of severe ADAMTS13 deficiency, 5 score with intermediate risk and 6–7 scores with high risk [68].

Determining appropriate treatment for drug-associated TMA is challenging. Discontinuation of offending medication is the logical first step. Plasma exchange remains the standard treatment for acquired TTP. That said, since antibodies are present in only a small proportion of drug-associated TMA, the efficacy of plasma exchange in this setting is unclear [66]. A novel upcoming treatment option for patients with acquired TTP is Caplacizumab. This anti-von Willebrand factor (vWF) humanized immunoglobulin blocks vWF-mediated plasma aggregation and showed a 67% reduction in recurrence, 74% reduction in TTP-related death and a trend toward faster normalization of the three organ damage markers: lactate dehydrogenase (LDH), troponin and serum creatinine in the double-blind, placebo-controlled, phase 3 HERCULES trial [69]. These novel strategies may be a harbinger for new, more effective therapeutic options in TTP.

In the past few decades, most of the reported cases of IFN-induced TMA have been associated with CML, MS and chronic hepatitis C. Tyrosine kinase inhibitors are now the treatment standard for CML. Therefore, not surprisingly, there have been no reports of IFN-induced TMA in patients with CML in the last decade. In addition, with the development of more effective antiviral agents, interferon-free regimens for chronic hepatitis C are emerging. Taken together, with diminishing clinical applications of IFN, we may see an overall decrease in the reports of IFN-induced TMA hereon. The last few years, however, have also seen the emergence of immuno-oncology in cancer therapeutics. Immune checkpoint inhibitors including CTLA-4 antibodies and PD-1 ligands are now approved with expanding clinical applications. These agents potentiate immune response against tumors exponentially by blocking the inhibitory pathways utilized by tumors to escape host immune surveillance mechanisms. Augmentation of host immunity, however, results in breaking self-tolerance and induction of immune-related side effects (ir-AE). Most common side effects are colitis and pneumonitis requiring immune suppression for resolution. Cortazar et al. described a 58-year-old male with melanoma who developed TMA that correlated with treatment with Ipilimumab (CTLA-4 antibody) [70]. This is an interesting observation in the context of our analysis, especially of the mechanisms involved in IFN-induced TMA. It is yet to be ascertained, as we gain more experience with these agents whether this will be an isolated or consistent observation. Nevertheless, it would be prudent to consider the likelihood of these adverse effects in the future.

## 4. Conclusion

Historically, exogenous IFN ( $\alpha$  and  $\beta$ ) has been the primary therapy for a variety of diseases such as chronic HCV, chronic phase CML, MS, lymphoma and PV. IFN can trigger autoimmune diseases such as autoimmune thyroiditis. IFN-mediated immune upregulation with the production of cross-reacting antibodies to ADAMTS 13 and complement activation from endothelial injury are the probable pathways for IFN-induced TMA. From our observation, barring differences in time of onset and cumulative dose exposure, the presentation, clinical

course and response to treatment appear to be similar among different IFN subtypes and across all indications of use. Treatment regimens utilizing plasma exchange, steroids and rituximab result in durable responses. While interferon may have a myelosuppressive effect causing gradual onset thrombocytopenia, thrombotic microangiopathy, a possible fatal complication should be considered in the differential diagnosis. Once recognized, early institution of appropriate treatment results in favorable outcome. Our analysis also indicates that in patients who had positive ADAMTS13 inhibitors, plasma exchange was a very effective therapy with complete response. Finally, while interferons may have diminishing clinical applications, interferon-induced thrombotic microangiopathy has provided us with valuable lessons pertaining to collateral consequences of immune upregulation. This has resulted in a paradigm shift in our understanding of immunobiology and will have far reaching applications in immunomodulating therapeutics.

## Acknowledgements

Vladimir Gotlieb, MD, Boris Avezbakiyev, MD, Hesham Taha, MD, Brookdale University Hospital Medical Center, Brooklyn, NY, USA.

## Conflict of interest

None.

## Author details

Ajay Kundra<sup>1</sup>, Mirela Andrei<sup>2</sup> and Jen Chin Wang<sup>3\*</sup>

\*Address all correspondence to: jcwang0005@gmail.com

1 Providence Regional Medical Center, Everett, WA, USA

2 St Mary's Regional Medical Center, Lewiston, ME, USA

3 Division of Hematology/Oncology, Brookdale University Hospital Medical Center, Brooklyn, NY, USA

## References

- [1] Scully M. Thrombocytopenia in hospitalized patients: approach to the patient with thrombotic microangiopathy. In: American Society of Hematology 59th Annual Meeting & Exposition. Atlanta, GA: American Society of Hematology Education Program; 2017 Dec 8;2017(1):651-659. DOI: 10.1182/asheducation-2017.1.651

- [2] Kundra A, Wang JC. Interferon induced thrombotic microangiopathy (TMA): Analysis and concise review. *Critical Reviews in Oncology/Hematology*. 2017;**112**:103-112
- [3] Poddar N, Wang JC. Thrombotic thrombocytopenic purpura in a patient with interferon treated hepatitis C successfully treated with rituximab. *Hematology Reports*. 2013;**5**(1):5-7
- [4] Schlaifer D, Dumazer P, Spenatto N, Mignon-Conte M, Brousset P, Lumbroso C, Cooper M, Muller C, Huguet F, Attal M, et al. Hemolytic-uremic syndrome in a patient with chronic myelogenous leukemia treated with interferon alpha. *American Journal of Hematology*. 1994 Nov;**47**(3):254-255
- [5] Harvey M, Rosenfeld D, Davies D, Hall BM. Recombinant interferon alpha and hemolytic uremic syndrome: cause or coincidence? *American Journal of Hematology*. 1994 Jun;**46**(2):152-153
- [6] Jadoul M, Piessevaux H, Ferrant A, Cosyns JP, van Ypersele de Strihou C. Renal thrombotic microangiopathy in patients with chronic myelogenous leukaemia treated with interferon-alpha 2b. *Nephrology, Dialysis, Transplantation*. 1995;**10**(1):111-113
- [7] Lipton JH, Minden M. CML may not be part of HUS. *American Journal of Hematology*. May 1995;**49**(1):100-101
- [8] Honda K, Ando A, Endo M, Shimizu K, Higashihara M, Nitta K, Nihei H. Thrombotic microangiopathy associated with alpha-interferon therapy for chronic myelocytic leukemia. *American Journal of Kidney Diseases*. Jul 1997;**30**(1):123-130
- [9] Rachmani R, Avigdor A, Youkla M, Raanani P, Zilber M, Ravid M, Ben-Bassat I. Thrombotic thrombocytopenic purpura complicating chronic myelogenous leukemia treated with interferon-alpha. A report of two successfully treated patients. *Acta Haematologica*. 1998;**100**(4):204-206
- [10] Vacher-Coponat H, Opris A, Daniel L, Harle J-R, Veit V, Olmer M. Thrombotic microangiopathy in a patient with chronic myelocytic leukaemia treated with  $\alpha$ -interferon. *Nephrology Dialysis Transplantation*. 1999;**14**:2469-2471
- [11] Ravandi-Kashani F, Cortes J, Talpaz M, Kantarijan H. Thrombotic microangiopathy associated with interferon therapy for patients with chronic myelogenous leukemia. *Cancer*. 1999;**85**:2583-2588
- [12] Lacotte L, Thierry A, Delwail V, Dreyfus B, Guilhot F. Thrombotic thrombocytopenic purpura during interferon alpha treatment for chronic myelogenous leukemia. *Acta Haematologica*. 1999;**102**:160-162
- [13] Magee CC, Abraham K, Farrell J, Dorman T, Walshe JJ. Renal thrombotic microangiopathy associated with interferon-alpha treatment of chronic myeloid leukemia. *American Journal of Kidney Diseases*. Jul 2000;**36**(1):E5
- [14] Denizon N, Beraud JJ, Mourad G, Blanc P, Bureau JP, Navarro M, Lavabre-Bertrand T. Hemolytic uremic syndrome with hypertransaminasemia following treatment by interferon

for chronic myeloid leukemia. *Gastroentérologie Clinique et Biologique*. Nov 2001;**25**(11):1039-1040

- [15] Badid C, McGregor B, Marie Faivre J, Guerard A, Juillard L, Fouque D, Laville M. Renal thrombotic microangiopathy induced by interferon- $\alpha$ . *Nephrology Dialysis Transplantation*. 2001;**16**:846-848
- [16] Zuber J, Martinez F, Droz D, Oksenhendler E, Legendre C. Alpha-interferon-associated thrombotic microangiopathy: A clinicopathologic study of 8 patients and review of literature. *Medicine*. July 2002;**81**(4):321-331
- [17] Ohashi N, Yonemura K, Sugiura T, Isozaki T, Togawa A, Fujigaki Y, Yamamoto T, Hishida A. Withdrawal of interferon-alpha results in prompt resolution of thrombocytopenia and hemolysis but not renal failure in hemolytic uremic syndrome caused by interferon-alpha. *American Journal of Kidney Diseases*. Mar 2003;**41**(3):E10
- [18] Galesic K, Bozic B, Racic I, Scukanec-Spoljar M. Thrombotic microangiopathy associated with alpha-interferon therapy for chronic myeloid leukaemia. *Nephrology (Carlton, Vic.)*. Feb 2006;**11**(1):49-52
- [19] Herrera WG, Balizet LB, Harberts SW, Brown ST. Occurrence of a TTP-like syndrome in two women receiving beta interferon therapy for relapsing multiple sclerosis. *Neurology*. Apr 1999;**52**(6 supplement 2):A135
- [20] Serrano A, Xicoy B, Grifols JR, Ribera JM. Thrombotic thrombocytopenic purpura during treatment with interferon. *Medicina clínica (Barc)*. 2007;**128**(7):276-277 (Spanish)
- [21] Li Cavoli G, Bono L, Tortorici C, Giammarresi C, Rotolo U. Renal thrombotic microangiopathy induced by  $\beta$ -interferon. *NDT Plus*. 2011;**4**(1):80-80
- [22] Broughton A, Cosyns J-P, Jadoul M. Thrombotic microangiopathy induced by long-term interferon- $\beta$  therapy for multiple sclerosis: a case report. *Clinical Nephrology*. Nov 2011;**76**(5):396-400
- [23] Bensa C, Sohier E, Pillebout L, Galicier L, Gout O. A case of thrombotic microangiopathy associated with subcutaneous beta-1a-interferon therapy. *Multiple Sclerosis*. 2011;**17**:S227
- [24] Olea T, Díaz-Mancebo R, Picazo M-L, Jorge M-A, Robles A, Selgas R. Thrombotic microangiopathy associated with use of interferon-beta. *International Journal of Nephrology and Renovascular Disease*. 2012;**5**:97-100
- [25] Modrego PJ, Gazulla J. Arterial hypertension induced by interferon beta 1b in a patient with multiple sclerosis. *Multiple Sclerosis Journal*. 2012;**18**(11):1655-1656
- [26] Nerrant E, Charif M, Ramay AS, Perrochia H, Patrier L, de Champfleury NM, Renard D, Labauge P. Hemolytic uremic syndrome: An unusual complication of interferon- $\beta$  treatment in a MS patient. *Journal of Neurology*. Jul 2013;**260**(7):1915-1916. DOI: 10.1007/s00415-013-6961-8 [Epub May 25, 2013]



- [27] Mahe J, Meurette A, Moreau A, Vercel C, Jolliet P. Renal thrombotic microangiopathy caused by interferon beta-1a treatment for multiple sclerosis. *Drug Design, Development and Therapy*. Aug 7, 2013;**7**:723-728
- [28] Larochelle C, Grand'maison F, Bernier GP, Latour M, Cailhier JF, Prat A. Thrombotic thrombocytopenic purpura- hemolytic uremic syndrome in relapsing-remitting multiple sclerosis patients on high dose interferon  $\beta$ . *Multiple Sclerosis*. 2014;**(13)**:1783-1787
- [29] Orvain C, Augusto J-F, Besson V, Marc G, Coppo P, Subra J-F, Sayegh J. Thrombotic microangiopathy due to acquired ADAMTS13 deficiency in a patient receiving interferon-beta treatment for multiple sclerosis. *International Urology and Nephrology*. 2014;**46**:239-242
- [30] Vosoughi R, Marriott J. Thrombotic microangiopathy in Interferon Beta treated multiple sclerosis patients: review of literature and report of two new cases. *Multiple Sclerosis and Related Disorders*. May 2014;**3**:321-325
- [31] Hunt D, Kavanagh D, Drummond L, Overell J, Evans S, Jackson A, Chandran S. Thrombotic microangiopathy associated with interferon beta. *New England Journal of Medicine*. Mar 27, 2014;**370**:1270-1271
- [32] Kobayashi H, Utsunomiya Y, Miyazaki Y, Tokutome G, Kawamura T, Hashimoto T, Sakai T, Takahashi S, Tojyo A, Asano S. Case of chronic myelogenous leukemia with hemolytic-uremic-syndrome like kidney during long-term interferon-alpha therapy. *Nihon Naika Gakkai Zasshi*. Jul 10, 1997;**86**(7):1259-1261
- [33] Ubara Y, Hara S, Takedatu H, Katori H, Yamada K, Yoshihara K, Matsushita Y, Yokoyama K, Takemoto F, Yamada A, Takagawa R, Endo Y, Hara M, Koida I, Kumada H. Hemolytic uremic syndrome associated with beta-interferon therapy for chronic hepatitis C. *Nephron*. Sep 1998;**80**(1):107-108
- [34] Iyoda K, Kato M, Nakagawa T, Kakiuchi Y, Sugiyasu Y, Fujii E, et al. Thrombotic thrombocytopenic purpura developed suddenly during interferon treatment for chronic hepatitis C. *Journal of Gastroenterology*. 1998;**33**(4):588-592
- [35] Creput C, Auffret N, Samuel D, Jian R, Hill G, Nochy D. Cutaneous thrombotic microangiopathy during treatment with alpha-interferon for chronic hepatitis C. *Journal of Hepatology*. Dec 2002;**37**(6):871-872
- [36] Kitano K, Gibo Y, Kamijo A, Furuta K, Oguchi S, Joshita S, Takahashi Y, Ishida F, Matsumoto M, Uemura M, Fujimura Y. Thrombotic thrombocytopenic purpura associated with pegylated-interferon alpha-2a by an ADAMTS13 inhibitor in a patient with chronic hepatitis C. *Haematologica*. 2006;**91**(8 Suppl):ECR34
- [37] Deutsch M, Manesis EK, Hadziyannis E, Vassilopoulos D, Archimandritis AJ. Thrombotic thrombocytopenic purpura with fatal outcome in a patient with chronic hepatitis C treated with pegylated interferon-a/2b. *Scandinavian Journal of Gastroenterology*. 2007;**42**(3):408-409

- [38] Sallée M, Crétel E, Jean R, Chiche L, Bourlière M, Poullin P, et al. Thrombotic thrombocytopenic purpura complicating interferon therapy in chronic C hepatitis. *Gastroentérologie Clinique et Biologique*. 2008;**32**(2):145-146
- [39] Hepburn IS, Schade R. Thrombotic thrombocytopenic purpura (TTP) associated with interferon therapy of hepatitis C. *Grand Rounds*. 2010;**10**:1-7
- [40] Lambot F, Hanson B, Sztern B. Thrombotic thrombocytopenic purpura mediated by an ADAMTS13-inhibitor related to a treatment with pegylated-interferon alpha-2a and ribavarine in a patient with chronic hepatitis C. *La Presse Médicale*. 2010;**39**(11):1207-1210
- [41] Iskander D, Wickremasinghe M, Bain BJ. Thrombotic microangiopathy complicating pegylated interferon treatment of hepatitis C infection. *American Journal of Hematology*. Oct 2011;**86**(10):859
- [42] Michaux C, Randrianasolo D, Vandenhende MA, Hessamfar M, Morlat P, Bonnet F. Thrombotic thrombocytopenic purpura associated with interferon therapy in a HIV and HCV co-infected woman. *Revue de Médecine Interne*. 2013;**34**(12):773-775
- [43] Boctor FN, Chiosea I, Bradley T. Thrombotic thrombocytopenic purpura with unusual 33 recurrences: A case report. *Annals of Clinical and Laboratory Science*. 2013;**43**(1):91-93
- [44] Evans R, Pavan M, Suri D, Harber M. Thrombotic microangiopathy (TMA) in a patient treated with antiviral therapy for hepatitis C. *BML Case Reports*. Apr 2014;**4**:2014
- [45] Stratta P, Canavese C, Dogliani M, Thea A, Degani G, Mairone L, Vercellone A. Hemolytic-uremic syndrome during recombinant alpha-interferon treatment for hairy cell leukemia. *Renal Failure*. 1993;**15**(4):559-561
- [46] Politou M, Tsaftarides P, Vassiliades J, Siakantaris M, Michail S, Nakopoulou L, Pangalis G, Vaiopoulos G. Thrombotic microangiopathy in a patient with Sezary syndrome treated with interferon- $\alpha$ . *Nephrology Dialysis Transplantation*. March 2004;**19**(3):733-735
- [47] Rosen HR. Chronic hepatitis C infection. *The New England Journal of Medicine*. 2011;**364**:2429-2438
- [48] Foon KA, Roth MS, Bunn Jr PA. Interferon therapy of non-Hodgkin's lymphoma. *Cancer*. 1987;**59**(Suppl):601-604
- [49] Avilés A. The role of interferon as maintenance therapy in malignant lymphoma. *Medical Oncology*. 1997;**14**:153-157
- [50] Gaynor ER, Fisher RI. Clinical trials of alpha-interferon in the treatment of non-Hodgkin's lymphoma. *Seminars in Oncology*. 1991;**18**(Suppl 7):12-17
- [51] Silver RT. Interferon-2b: A new treatment for Polycythemia Vera. *Annals of Internal Medicine*. 1993;**119**(11):1091-1092
- [52] Tefferi A, Elliott MA. Interferon-alpha therapy in polycythemia vera and essential thrombocythemia. *Seminars in Thrombosis and Hemostasis*. 1997;**23**:463-472



- [53] Kieseier BC. The mechanism of action of interferon- $\beta$  in relapsing multiple sclerosis. *CNS Drugs*. June 2011;**25**(6):491-502
- [54] Burchert A, Saussele S, Eigendorff E, Müller MC, Sohlbach K, Inselmann S, Schütz C, Metzelder SK, Ziermann J, Kostrewa P, Hoffmann J, Hehlmann R, Neubauer A, Hochhaus A. Interferon alpha 2 maintenance therapy may enable high rates of treatment discontinuation in chronic myeloid leukemia. *Leukemia*. Jun 2015;**29**(6):1331-1335
- [55] Kiladjan JJ, Giraudier S, Cassinat B. Interferon-alpha for the therapy of myeloproliferative neoplasms: targeting the malignant clone. *Leukemia*. 2016;**30**:776-781
- [56] Brown S, Hutchinson CV, Aspinall-O'Dea M, Whetton AD, Johnson SM, Rees-Unwin K, Burthem J. Monocyte-derived dendritic cells from chronic myeloid leukaemia have abnormal maturation and cytoskeletal function that is associated with defective localisation and signalling by normal ABL1 protein. *European Journal of Haematology*. Aug 2014;**93**(2):96-102
- [57] Mandac JC, Chaudhry S, Sherman KE, Tomer Y. The clinical and physiological spectrum of interferon-alpha induced thyroiditis. Toward a new classification. *Hepatology*. 2006;**43**(4):661-672
- [58] Fattovich G, Giustina G, Favaro S, Ruol A. Investigators of the Italian Association for the Study of the Liver. A survey of adverse events in 11,241 patients with chronic viral hepatitis treated with alfa interferon. *Journal of Hepatology*. 1996;**24**:38-47
- [59] Kataoka I, Shinagawa K, Shiro Y, Okamoto S, Watanabe R, Mori T, Ito D, Harada M. Multiple sclerosis associated with interferon-alpha therapy for chronic myelogenous leukemia. *American Journal of Hematology*. 2002;**70**(2):149-153
- [60] George JN, Terrell DR, Vesely SK, Kremer Hovinga JA, Lämmle B. Thrombotic microangiopathic syndromes associated with drugs, HIV infection, hematopoietic stem cell transplantation and cancer. *Presse Médicale*. Mar 2012;**41**(3 Pt 2):e177-e188
- [61] Eremina V, Jefferson A, Kowalewska J, Hochster H, Haas M, Weisstuch J, Richardson C, Kopp JB, Kabir MG, Backx P, Gerber HP, Ferrara N, Barisoni L, Alpers CE, Quaggin S. VEGF inhibition and renal thrombotic microangiopathy. *The New England Journal of Medicine*. 2008;**358**:1129-1136
- [62] Rot U, Ledinek AH. Interferons beta have vasoconstrictive and procoagulant effects: a woman who developed livedo reticularis and Raynaud phenomenon in association with interferon beta treatment for multiple sclerosis. *Clinical Neurology and Neurosurgery*. 2013 Dec;**115**(Suppl 1):S79-S81
- [63] Ruggerenti P, Noris M, Remuzzi G. Thrombotic microangiopathy, hemolytic hemolytic syndrome, and thrombotic thrombocytopenic purpura. *Kidney International*. 2001;**83**:831-846
- [64] Piette JC, Papo T. Potential role for antiphospholipid antibodies in renal thrombotic microangiopathy induced by interferon-alpha. *Nephrology Dialysis Transplantation*. 1995;**10**(9):1781

- [65] Leung DY, Moake JL, Havens PL, Kim M, Pober JS. Lytic anti-endothelial cell antibodies in haemolytic-uraemic syndrome. *Lancet*. 1988;**2**(8604):183-186
- [66] Kavanagh D, McGlasson S, Jury A, Williams J, Scolding N, Bellamy C, Gunther C, Ritchie D, Gale DP, Kanwar YS, Challis R, Buist H, Overell J, Weller B, Flossmann O, Blunden M, Meyer EP, Krucker T, Evans SJ, Campbell IL, Jackson AP, Chandran S, Hunt DP. Type I interferon causes thrombotic microangiopathy by a dose-dependent toxic effect on the microvasculature. *Blood*. Dec 15, 2016;**128**(24):2824-2833
- [67] Feld J, Hoofnagle J. Mechanism of action of interferon and ribavirin in treatment of hepatitis C. *Nature*. Aug 2005;**436**:967-972
- [68] Bendapudi PK, Hurwitz S, Fry A, Marques MB, Waldo SW, Li A, Sun L, Upadhyay V, Hamdan A, Brunner AM, Gansner JM, Viswanathan S, Kaufman RM, Uhl L, Stowell CP, Dzik WH, Makar RS. Derivation and external validation of the PLASMIC score for rapid assessment of adults with thrombotic microangiopathies: A cohort study. *Lancet Haematology*. 2017;**4**(4):e157-e164
- [69] Scully M, Cataland SR, Peyvandi F, et al. Results of the randomized, double-blind, placebo-controlled, phase 3 HERCULES study of capecitabine of caplacizumab in patients with acquired thrombotic thrombocytopenic purpura. Atlanta, GA: Oral presentation at: American Society of Hematology 59th Annual Meeting & Exposition; 2017 December 9-12
- [70] Cortazar FB, Marrone KA, Troxell ML, Ralto KM, Hoenig MP, Brahmer JR, Le DT, Lipson EJ, Glezerman IG, Wolchok J, Cornell LD, Feldman P, Stokes MB, Zapata SA, Hodi FS, Ott PA, Yamashita M, Leaf DE. Clinicopathological features of acute kidney injury associated with immune checkpoint inhibitors. *Kidney International*. Epub 2016 Jun 7. 2016 Sep;**90**(3):638-647. DOI: 10.1016/j.kint.2016.04.008.