

We are IntechOpen, the world's leading publisher of Open Access books Built by scientists, for scientists

6,900

Open access books available

185,000

International authors and editors

200M

Downloads

Our authors are among the

154

Countries delivered to

TOP 1%

most cited scientists

12.2%

Contributors from top 500 universities



WEB OF SCIENCE™

Selection of our books indexed in the Book Citation Index
in Web of Science™ Core Collection (BKCI)

Interested in publishing with us?
Contact book.department@intechopen.com

Numbers displayed above are based on latest data collected.
For more information visit www.intechopen.com



Metabolic and Bariatric Surgery: Evolution, Techniques, and Management

Rodolfo José Oviedo Barrera

Additional information is available at the end of the chapter

<http://dx.doi.org/10.5772/intechopen.73676>

Abstract

Metabolic and bariatric surgery involves more than altering the stomach and small bowel anatomy to provoke structural changes in the gastrointestinal tract from a mechanical point of view to treat morbid obesity. Its profound impact on the body's metabolism goes beyond anatomy and enters the realm of physiology. This is one of the most challenging and influential surgical subspecialties today due to its proven beneficial impact on the worldwide obesity epidemic and its millions of patients. A brief but comprehensive overview of the history of this fascinating yet challenging discipline and its advancement into the minimally invasive arena will be presented. Moreover, the body of this chapter will provide evidence-based data dealing with its indications, approaches, minimally invasive techniques including robotic surgery, the most common operations and the most recently introduced procedures, and management of complications. The impact of the laparoscopic revolution at the end of the twentieth century and the relevance of the robotic revolution from this century will be emphasized. An important point that will be made is the very specialized discipline of revisional bariatric surgery and its crucial role on the treatment of complications and failures that require extensive training and experience.

Keywords: metabolic, bariatric, surgery, minimally invasive, laparoscopic, robotic, evolution, techniques, management, approaches, indications, complications

1. Introduction

Bariatric surgery is the discipline of general surgery that encompasses the alteration of gastrointestinal anatomy, either by reducing the volume of the stomach, or the absorptive capacity of the intestine, or a combination of both, to provoke controlled physiologic changes that allow for a sustained and significant weight loss in morbidly obese patients. Metabolic

surgery, on the other hand, includes the physiologic aspect of this subspecialty due to its multiple benefits and effects on the body's metabolism and hormonal components that contribute to controlling and eradicating chronic medical conditions such as diabetes mellitus type 2, hypertension, hyperlipidemia, obstructive sleep apnea, and gastroesophageal reflux disease, among others.

In other words, bariatric surgery has long been associated by patients and the public in general as the subspecialty of general surgery that consists of altering the anatomy of the stomach and the small bowel, in some instances, to limit gastric capacity, promote restriction of volume, and malabsorption when applicable. Metabolic surgery goes beyond this definition, since it is recognized as the more scientific term due to its implication of change in the body's metabolism and its potential to control and eradicate some chronic diseases for which medical therapy is no rival [1]. This chapter will detail this fascinating discipline from the viewpoint of both definitions which complement one another and which should be devoted well deserved attention, especially in the setting of a worldwide morbid obesity epidemic which is affecting developed and underdeveloped countries. A detailed overview of its history, indications, approaches, minimally invasive techniques, and management of complications will be presented.

After a brief but comprehensive overview of the history of this discipline and its advancement into the minimally invasive arena, the body of the chapter will include several sections that will present the literature and high-quality evidence-based data dealing with its indications, approaches, minimally invasive techniques including robotic surgery, and management of complications. Emphasis will be made on the impact of the laparoscopic revolution at the end of the twentieth century and the relevance of the robotic revolution from this century. An important point that will be made consists of the very specialized discipline of revisional bariatric surgery and its crucial role nowadays, especially since several restrictive operations such as laparoscopic adjustable gastric band are now leading to complications that require highly trained surgeons with plenty of experience and a skill set that can only be attained with commitment to excellence.

Metabolic and bariatric surgery is not the surgery of the future, for it has been present for decades and has overtaken the place among the most challenging surgical subspecialties [2]. It has already begun, and we live in its era. This discipline deserves to be studied in detail, with a critical eye for the literature and minimally invasive techniques that will continue to elevate its high standards to new levels. The world has seen a change in the aspect, the behavior, and the diseases present in our society. The international morbid obesity epidemic that has dominated developed countries for years has already established its roots in underdeveloped countries. Metabolic and bariatric surgery must be an integral part of the twenty-first century advanced minimally invasive procedures offered to help our patients to achieve a better quality of life and survive medical conditions that were not as dominant in the past [3].

2. Historical context

Before the rise of the laparoscopic revolution at the end of the twentieth century, bariatric and metabolic surgery came to existence through the milestones and achievements of a few

individuals who continued to advance the technique and apply physiologic concepts to treat a condition that seemed impossible to manage with non-surgical options. Morbid obesity had not been specifically defined yet, but surgeons recognized its significance and began to perform operations to alter the stomach's capacity by restricting its volume either with foreign bodies or by excluding portions of it. Later, the understanding of the significance of decreased absorptive capacity of the small bowel on weight loss was applied to this field. Such an understanding arose from oncologic operations performed a century earlier, particularly for gastric cancer, when a Roux en Y reconstruction of the gastrointestinal tract revealed that the longer the Roux limb of intestine, the more pronounced the weight loss was for the patient.

The first bariatric procedure ever recorded, at least in terms of its purpose and its consistency with the definition of bariatric surgery, was a significant small bowel resection planned for purposes of weight loss by Henrikson, which was followed by the development of the jejuno-ileal bypass by Kremen. Both occurred in the 1950s. Subsequently, in the 1970s, Mason introduced the vertical banded gastroplasty as the first dedicated procedure where the stomach took a fundamental role as the primary object of anatomy alteration of the gastrointestinal tract to treat morbid obesity. A few years earlier, specifically in 1967, the same surgeon took Roux's idea of the Y configuration for gastrointestinal reconstruction and introduced the concept of the Roux-en-Y gastric bypass as a bariatric operation, which was performed starting in the 1980s. However, because of the inherent disadvantages of open surgery when applied to the challenging field of bariatric surgery, and given the expected complications that may occur when bariatric operations are performed via the open approach, the Roux-en-Y gastric bypass became the object of criticism among the surgical community and patients in general. On a separate area of this young subspecialty at that time, Scopinaro introduced the biliopancreatic diversion, while Hess, Legacé, and Marceau developed an early form of the nowadays well-known sleeve gastrectomy during the duodenal switch creation [4, 5].

The 1991 National Institutes of Health (NIH) consensus became the most fundamental event that gave validity and relevance to Bariatric Surgery when it established that the vertical banded gastroplasty and the gastric bypass were the two safest surgical options for morbid obesity at that time. The laparoscopic revolution took precedence in the 1990s and facilitated the performance of these operations with improved outcomes compared to those seen in previous decades. Bariatric surgery began to become accepted again and respected as a surgical subspecialty with powerful effects and demanding an advanced skillset to perform it. In fact, the first laparoscopic gastric bypass with a six-trocar technique was performed by Wittgrove, which consisted of a circular anastomosis retrocolic retrogastric bypass. Although the adoption of laparoscopic techniques facilitated the performance of the vertical banded gastroplasty, it eventually became less frequently performed not only due to the more complex but also efficient and successful gastric bypass. The Roux en Y gastric bypass itself has seen a variety of change in its technique, including a retrocolic retrogastric, a retrocolic antegastric, or an antecolic antegastric fashion, with circular or linear stapling techniques or with the hand-sewn laparoscopic or robotic approaches.

There is strong evidence in the literature that the Roux-en-Y gastric bypass continues to be the gold standard in bariatric surgery, despite the introduction of the adjustable gastric band and later the laparoscopic sleeve gastrectomy. Finally, to add to the historical perspective, the

robotic revolution of the late 1990s and early twenty-first century has made a powerful presence across the world and has produced multiple publications that show that robotic surgery can be successfully applied not only to complex bariatric procedures and revisional surgery but also to more routine bariatric procedures with efficiency and safety.

3. Physiology and mechanisms

The physiology of bariatric surgery, and its corresponding counterpart of metabolic surgery, is incredibly complex. In fact, it is now known after multiple animal and human studies over the last two decades that the typical understanding of restriction versus malabsorption is not the only responsible mechanism for weight loss. Rather, the gut-brain axis and its multiple components play a role when a bariatric procedure is performed, particularly when gastric and intestinal hormones and peptides that regulate metabolism are either activated or inhibited by the significant changes introduced by such operations [6, 7]. Trying to detail the immense body of knowledge that is available regarding this complex subject goes beyond the scope of this chapter. Nevertheless, it is important to understand that hunger and energy metabolism are affected not only by one hormone such as Ghrelin but also by restricting the stomach's volume or bypassing a specific length of small intestine. Instead of viewing the role of bariatric surgery as either restrictive or malabsorptive, attention must be paid to the hormonal changes that are caused by it, for they are more important to the gut-brain axis and the energy metabolism mechanisms that explain why some patients are able to lose more weight than others and why other patients regain some or most of their weight over a few years even when dietary indiscretions do not play a role.

By the same rationale, it is now logical to see how the Roux en Y gastric bypass is the gold standard of bariatric surgery, not because the excess weight loss achieved by it is superior to that of the sleeve gastrectomy on any given patient, but because of its effect on diabetes mellitus type 2 and hypertension, hypercholesterolemia, and gastroesophageal reflux. While Ghrelin is the fundamental hormone that is referred to when a sleeve gastrectomy is discussed with patients or colleagues, the Roux en Y gastric bypass can affect more hormones that interact with the gut-brain axis and provoke changes on energy metabolism, in addition to the gut microbiome and the bile acid concentration [8].

Regarding the interesting concept of the gut-brain axis and the role that the vagus nerve plays when bariatric operations are performed, it is known through neuroimaging studies that structural changes become normalized and brain connectivity improves so that morbidly obese patients can have an improved post-operative eating behavior. Hormones such as peptide YY3-36, GLP-1, ghrelin, neurotensin, and others participate in the regulation of eating behavior after surgery [9]. As it can be discerned, there is more than restriction versus malabsorption when it comes to understanding such an elegant field where science continues to advance and make discoveries that enhance the patients' quality of life. As a result of these effects on the metabolism of the body, studies such as the STAMPEDE trial continue to demonstrate that metabolic surgery is superior to medical therapy for the treatment of diabetes,

but also hypertension, hypercholesterolemia, and other chronic comorbidities compared to medical therapy [10]. The effects of the Roux en Y gastric bypass and the sleeve gastrectomy on diabetes control and eradication have been tested by time and have endured it with good outcomes over the years [11].

4. Adjustable gastric band

The laparoscopic adjustable gastric band is typically regarded as the only remaining truly restrictive procedure. It was approved in the United States in 2001, but it was already being performed in other countries prior to that. It consists of the implantation of a gastric band that is connected to a subcutaneous port and is manipulated by the surgeon usually in the outpatient setting by filling it or emptying it according to the patient's symptoms and weight loss response. The technique has been well described by other authors and it has evolved over the years. The most commonly performed technique involves its implantation in the proximal stomach by choosing a perigastric approach via the lesser curve into the lesser sac to pass it around the stomach and secure it anteriorly, and providing a plication of the gastric fundus over it.

A relevant fact is that the most common procedure related to the adjustable gastric band is not its implantation, but its explantation. The removal of an adjustable gastric band and its conversion to a sleeve gastrectomy or a Roux en Y gastric bypass, either as a two-stage or a single-stage operation, has become a frequent revisional bariatric operation at academic centers, particularly as of 2013 [12]. Compared to the more powerful effects of the sleeve gastrectomy or the Roux en Y gastric bypass, it is logical to see the reason for not choosing this procedure nowadays, since it lacks the metabolic component that the other two operations mentioned above offer, and it has a potential to produce a 30% excess weight loss at 1 year, which is lower than the excess weight loss produced by the sleeve gastrectomy or the Roux en Y gastric bypass.

Although some patients keep their adjustable gastric bands and see their surgeon on a regular basis for band adjustments in the office, it is known that the band's effects are typically stronger for the first 4 years [13]. After that, patients usually seek alternatives such as a band removal with conversion to another bariatric procedure, especially considering its potential complications such as band slippage with partial obstruction of the proximal stomach, incarceration, ischemia, and ulceration with or without band erosion into the gastric lumen.

5. Sleeve gastrectomy

The laparoscopic (and more recently robotic) sleeve gastrectomy has become the most frequently performed bariatric procedure in the United States and other countries due to its relative simplicity compared to the gastric bypass, in addition to the elegant nature of the physiologic changes that it has on the body's metabolism by restricting the stomach's volume and by reducing the Ghrelin concentrations by virtue of resecting the fundus, which is

responsible for gastric production of this important hormone [14]. It was initially introduced as a first stage, planned procedure for the biliopancreatic diversion with duodenal switch or for super obese patients who eventually would benefit from a Roux en Y gastric bypass and were too high risk to undergo such a procedure at the beginning [15].

It is superior to the adjustable gastric band in terms of its excess weight loss, which is 60% at 1 year, and its morbidity and mortality profile is superior to that of the gastric bypass, but at the expense of its weaknesses mostly in three specific cases where this operation is not the most effective one compared to the gold standard. These conditions are super morbid obesity (body mass index >50), diabetes mellitus type 2 which is insulin-dependent, and severe gastroesophageal reflux disease. In these specific cases, the gastric bypass offers more advantages to patients and a better metabolic profile. Having said this, the sleeve gastrectomy is highly effective and can be performed safely by experienced surgeons with reproducible results if some basic principles are respected and followed during surgery. To name a few, it is essential to standardize the caliber of the gastric sleeve by using a Bougie and prevent a stenosis of the gastric lumen, especially at the incisura angularis of the lesser curve, in addition to resecting the fundus completely to prevent a sacular dilation over time that will contribute to worsening reflux and increase the risk of weight regain.

Overall, however, if these principles are followed, the laparoscopic sleeve gastrectomy is an excellent single-stage bariatric operation without the need to convert to a gastric bypass or a duodenal switch later, as long as its outcomes for the patient are fulfilled [16]. As a result, the American College of Surgeons 2011 report's conclusion is that the sleeve gastrectomy morbidity and effectiveness is in between the adjustable gastric band and the Roux en Y gastric bypass [17]. Once again, it is easy to realize why this operation has become so popular over the years since it was introduced as a single-stage procedure by itself, based on its relative simplicity and its results which include a percent excess weight loss of >50%, and in most cases, up to 60% [18, 19].

The indication to perform a laparoscopic or robotic sleeve gastrectomy is either a body mass index greater than 40 kg/m² or a body mass index greater than 35 plus an obesity-related comorbidity such as diabetes mellitus type 2, hypertension, dyslipidemia, obstructive sleep apnea, gastroesophageal reflux disease, or other less frequently included medical conditions such as osteoarthritis, polycystic ovarian syndrome, and pseudotumor cerebri. However, it is important to remember that significant gastroesophageal reflux disease that occurs daily and not controlled with medical therapy is also a relative contraindication due to the risk of exacerbating this condition as a result of the high-pressure system that is created with the sleeve anatomy. On the other hand, a body mass index greater than 50, or super obesity, is also a relative contraindication due to the failure of this operation to maintain the weight loss over time in this context. Finally, for insulin-dependent diabetes mellitus type 2, a Roux en Y gastric bypass is a more efficient operation with superior results.

The following steps are this author's preferred approach to performing a robotic sleeve gastrectomy while following some essential principles that ensure a safe operation with a minimal risk of complications:

- a. With the patient in reverse Trendelenburg and after establishing pneumoperitoneum via the Veress needle or the optical trocar technique, or a combination of both, the standard robotic ports and the liver retractor are placed in a foregut surgery configuration.
- b. The greater curve of the stomach is approached first with a bipolar, ultrasonic, or vessel sealer instrument, by dividing the gastrocolic ligament while staying close to the stomach at the mid-point on the greater curve between the pylorus and the angle of His. The division of the gastrocolic ligament first approaches the distal greater curve and stops at 5 cm proximal to the pylorus to preserve the blood supply and integrity of the antrum and prepyloric region (**Figure 1**).
- c. The division of the gastrocolic ligament continues proximally toward the short gastric arteries while protecting the spleen and, if necessary, coming into contact with the fundus if it is too close to the spleen to avoid the splenic capsule (**Figures 2 and 3**).
- d. The left crus of the diaphragm is dissected along with the right crus to verify whether there is a hiatal hernia that needs to be repaired. If there is one, it should be repaired in a primary fashion and, less frequently, with mesh to prevent exacerbation of gastroesophageal reflux or development of de novo reflux (**Figure 4**).
- e. With a 36–40 Fr Bougie in place and with its tip at the pre-pyloric area, a gastrointestinal stapling device, whether laparoscopic or robotic, with or without polymer reinforcement for the staple line, is used to transect the stomach and create a vertical sleeve gastrectomy, usually with the first three firings of the stapler being appropriate for the thickest tissue at the distal stomach. It is essential not to stay too close to the Bougie to cause stenosis of the gastric lumen, especially at the incisura angularis (**Figure 5**).
- f. Verification that the staple line is hemostatic and not too close to the Bougie is important, especially in the distal stomach, where the pylorus is identified and intact, with the last 5 cm of gastrocolic ligament preserved (**Figure 6**).
- g. Gastric transection continues to the angle of His, where the entire fundus is divided to complete the staple line while staying close to the Bougie but without causing stenosis at the gastroesophageal junction (**Figure 7**).

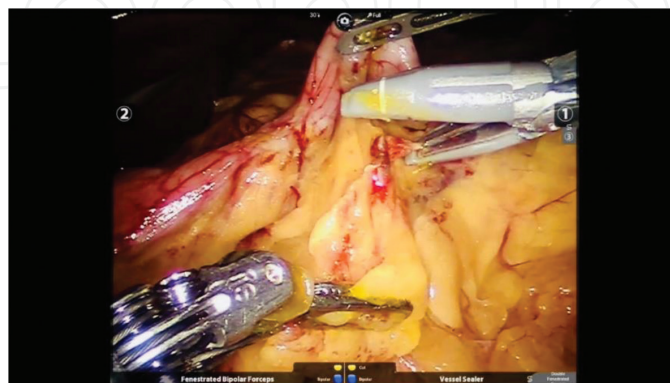

Figure 1. Division of the gastrocolic ligament begins along the greater curve of the stomach to enter the lesser sac and mobilize the greater curve, first distally, to 5 cm proximal to the pylorus.

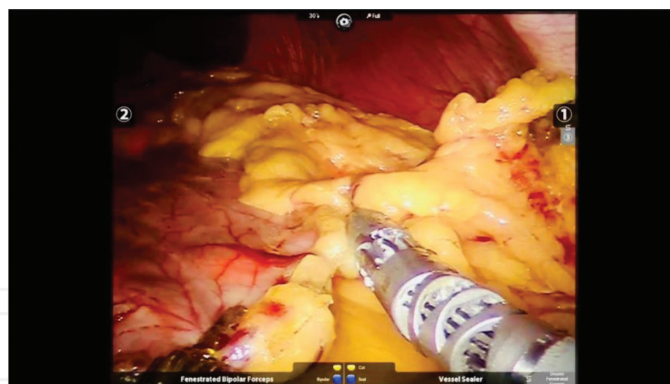


Figure 2. Division of the gastrocolic ligament continues proximally to approach the short gastric vessels.

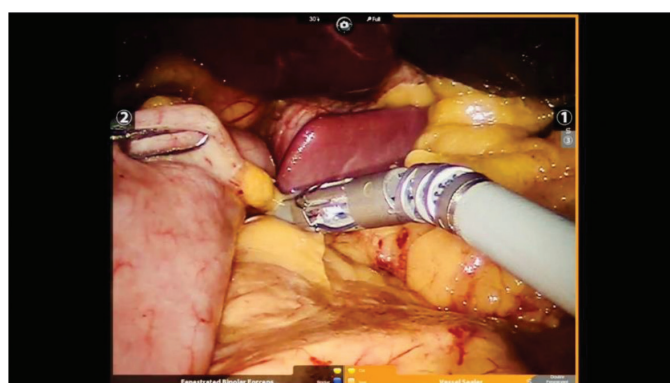


Figure 3. The short gastric vessels are divided while protecting the spleen and, if necessary, while coming into contact with the gastric fundus to avoid rupturing the splenic capsule.

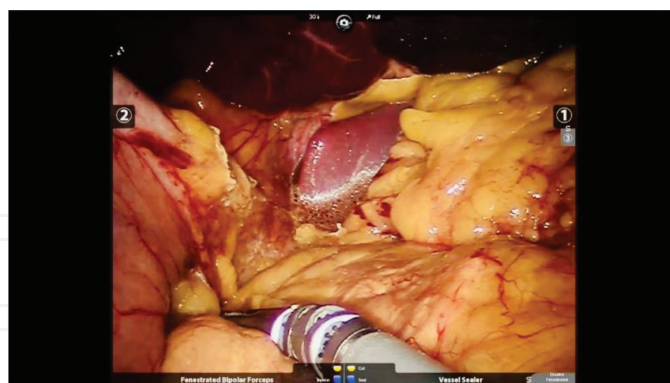

Figure 4. The left crus of the diaphragm is dissected in addition to the right crus to detect a hiatal hernia, which should be repaired if present either primarily or with mesh.

- h.** A leak test is performed, ideally with intraoperative endoscopy while clamping the prepyloric region with atraumatic graspers to prevent passage of air into the small bowel and while submerging the gastric sleeve under saline solution to look for air bubbles. Upper gastrointestinal endoscopy also reveals whether the gastric sleeve staple line is hemostatic in the lumen and if there is any potential stenosis especially at the incisura.

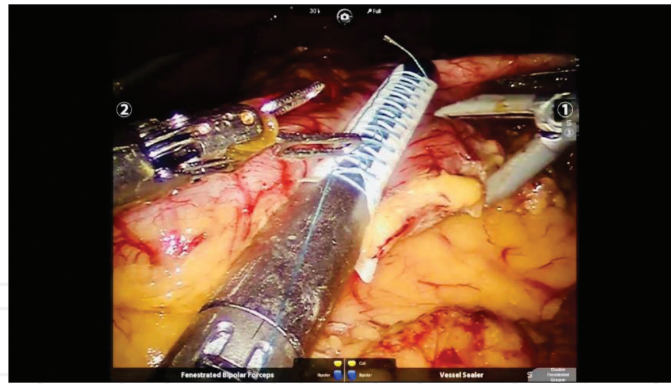

Figure 5. The surgical stapler is used to transect the stomach and create a vertical staple line while staying close to a 36–40 Fr Bougie, but without causing stenosis of the lumen, especially at the incisura angularis.

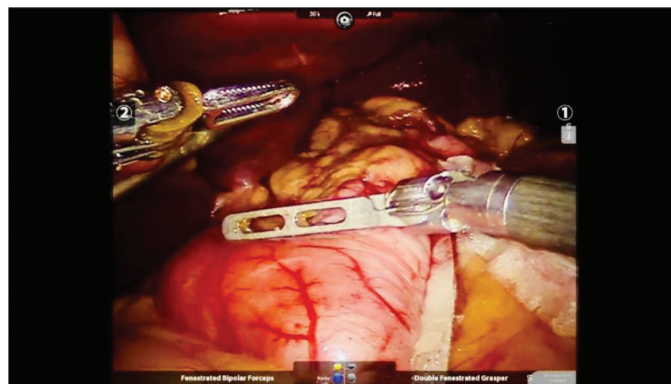


Figure 6. Constant verification that the staple line is hemostatic is essential, in addition to avoidance of gastric lumen stenosis caused by excessive proximity to the Bougie during stapler deployment.

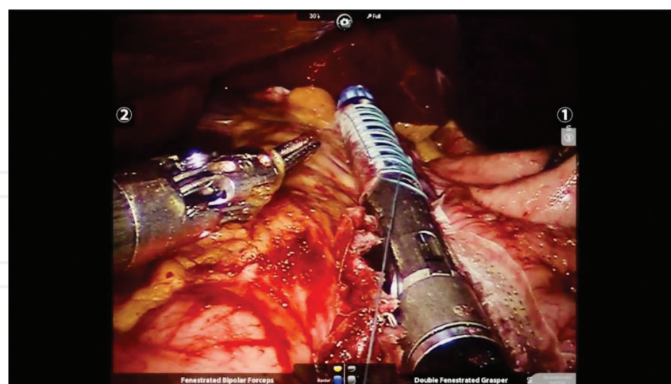

Figure 7. The vertical staple line is completed by transecting the stomach proximally, including the fundus, and staying close to the Bougie at the angle of His.

In addition, the use of the Firefly technology is an adjunct to the leak test, if available, by having the Anesthesia team inject indocyanine green (ICG) to visualize any potential ischemic areas, especially the proximal end of the gastric sleeve, where a leak is more likely to occur.

- i. The product of the sleeve gastrectomy is extracted via the longest laparoscopic incision corresponding to the stapler port.
- j. A fascial closure device is used to close the fascial defect at the stapler port site to prevent a port site incisional hernia.
- k. The liver retractor and the ports are removed, and the incisions are closed with absorbable sutures.

6. Roux en Y gastric bypass

The gold standard of bariatric surgery continues to be the Roux en Y gastric bypass, which has been established and documented with multiple studies over the last three decades with an overwhelming body of literature and evidence. While the sleeve gastrectomy is a much simpler procedure to perform, the gastric bypass involves a much more complex set of skills that, in the end, produce results that surpass the areas where the sleeve gastrectomy cannot perform well. Specifically, the Roux en Y gastric bypass is a better tool to control diabetes, especially insulin-dependent, in addition to significant gastroesophageal reflux disease, and super (BMI > 50) or super-super obese (BMI > 60) patients. The gastric bypass has proven superior in terms of controlling hypertension, hypercholesterolemia, and obstructive sleep apnea, although many times authors quote almost similar rates when referring to the sleeve gastrectomy.

A Roux en Y gastric bypass could be performed on any morbidly obese individual, with a few exceptions such as those with Crohn's disease, due to the small bowel involvement that is expected at some point during the evolution of that disease. Patients who are of childbearing age or thinking about becoming pregnant also have to exert caution when choosing their bariatric procedure, since electrolyte abnormalities and nutritional deficiencies are expected and must be prevented and treated during the post-operative recovery. Moreover, patients on hemodialysis may consider the less complex sleeve gastrectomy, particularly due to the fact that it lacks a malabsorptive component.

Critics of this operation often mention its higher morbidity when compared to the sleeve gastrectomy or the adjustable gastric band, which is mostly caused by the well-known possibility of internal herniation through one of the mesenteric defects that are created during this operation. The possibility of internal herniation can be minimized with attention to detail and good technique, including closure of mesenteric defects at the jejunojejunostomy or the transverse mesocolon for retrocolic gastric bypass or a narrow mesenteric defect at the mesentery of the Roux limb when it meets the gastric pouch to minimize the risk of a Petersen hernia. Some experts even use biosynthetic mesh at these mesenteric defects in a prophylactic fashion, although it is not common. In any case, even if an internal hernia is present months or years later, a high index of suspicion is required to avoid small bowel ischemia or necrosis and to act promptly to prevent worse complications. Internal hernias, in other words, can be prevented and can be promptly treated by expert bariatric surgeons or by general surgeons, all of whom should be familiar with this complication.

The other complication that is often quoted is an anastomotic leak, which nowadays has the same risk as a staple line leak from a sleeve gastrectomy, approximately 2%, and in expert hands at experienced centers, lower than that. Therefore, this is no longer a valid criticism. The risk of anastomotic marginal ulcers is also a significant consideration and must be decreased by particular attention to meticulous dissection and respect of the blood supply to the gastric pouch to avoid future ischemia, in addition to abstention from taking non-steroidal anti-inflammatory drugs (NSAIDs) or smoking. The most significant disadvantage for patients, on the other hand, is the fact that they must commit to a life of vitamin supplements and medications such as iron and calcium compared to only a year requirement for a sleeve gastrectomy [20–23].

A Roux en Y gastric bypass is expected to produce an excess weight loss of up to 70–75% at 1 year. In terms of the technique, although it was initially described with the retrocolic, retro-gastric technique, it has eventually evolved into the retrocolic, antegastric variant and more recently the antecolic, antegastric procedure, which is more widely used by the new generations of bariatric surgeons due to its simplicity and the fact that, if a reoperation is required, it is much easier to perform it without having to dissect the Roux limb from the posterior plane of the transverse colon. The disadvantage of the antecolic, antegastric technique lies in the fact that tension is often encountered when mobilizing the Roux limb to the epigastric area, therefore requiring division of the mesentery of the jejunum for at least 3–5 cm sometimes to allow for the tension to be minimized while respecting the blood supply to the biliopancreatic limb and the Roux limb at the same time.

The indications for a laparoscopic or robotic Roux en Y gastric bypass are the same as those for a sleeve gastrectomy, i.e., when the body mass index is greater than 40 kg/m² or greater than 35 with an obesity-related comorbidity. Nevertheless, a gastric bypass is especially indicated where the sleeve gastrectomy shows weakness, specifically when the patient exhibits significant symptoms of gastroesophageal reflux disease that is refractory to medical therapy, or insulin-dependent diabetes mellitus type 2, or when the body mass index is greater than 50. In all cases, but especially under these specific circumstances where the sleeve gastrectomy fails to provide durable weight loss or control of comorbidities, a gastric bypass produces excellent outcomes and demonstrates why it is still considered the gold standard of bariatric and metabolic surgery. Specifically, in terms of gastroesophageal reflux disease, the Roux en Y anatomy has been known to be the ultimate surgical treatment for this condition due to the fact that the gastric secretions would have to travel at least 1 m downstream via the biliopancreatic limb, plus another meter upstream via the Roux (alimentary) limb to the gastric pouch in order to eventually cause the symptoms and signs of reflux, which is extremely difficult to achieve with this reconstruction of the gastrointestinal tract. Diabetes mellitus type 2 that is insulin-dependent is better controlled with the gastric bypass, which has been shown by numerous studies including the original STAMPEDE trial and its follow-up papers, among others. Finally, super obese and super-super obese patients experience a durable weight loss that is maintained over the years with this operation.

The following steps are considered the most important components of the antecolic, antegastric Roux en Y gastric bypass, in this case via the robotic approach, although it can be easily extrapolated to the laparoscopic method:

- a. After pneumoperitoneum is obtained via the Veress needle technique or the optical trocar technique, or both, and after placing the ports in the typical foregut surgery configuration, with the liver retractor in position and with the patient in slight reverse Trendelenburg, the jejunojejunostomy anastomosis is created first. The proximal jejunum is identified at the ligament of Treitz, and 50 cm are counted distal to it to transect the jejunum with a gastrointestinal stapler to create a biliopancreatic limb and a Roux limb. It is essential to keep the correct orientation of the bowel after the division to avoid complications related to the creation of an anastomosis in the wrong portion of the bowel. Usually, the biliopancreatic limb (proximal) is kept at the right of the screen, while the Roux limb (distal) is kept at the left (**Figure 8**).
- b. The mesentery of the jejunum at the transection site should be divided 3–5 cm in a straight fashion perpendicular to the bowel to prevent ischemia of either end of the biliopancreatic or the Roux limb (**Figure 9**).
- c. Once the jejunum is transected, while keeping the orientation, 150 cm are counted distal to the staple line on the Roux limb to identify the site of the jejunojejunostomy anastomosis, where antimesenteric enterotomies are created on the biliopancreatic limb and the Roux limb (**Figure 10**).

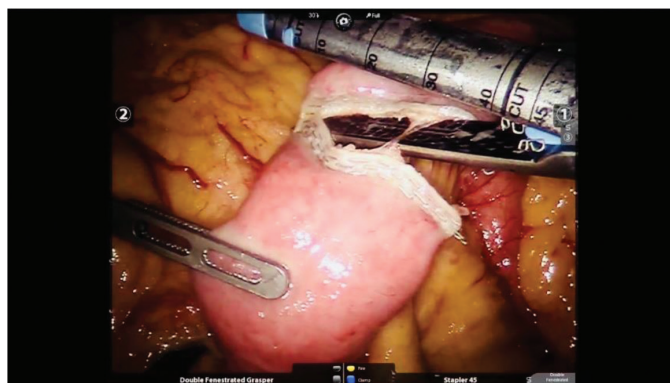


Figure 8. At 50 cm distal to the ligament of Treitz, the jejunum is transected to create a biliopancreatic limb and a Roux limb.

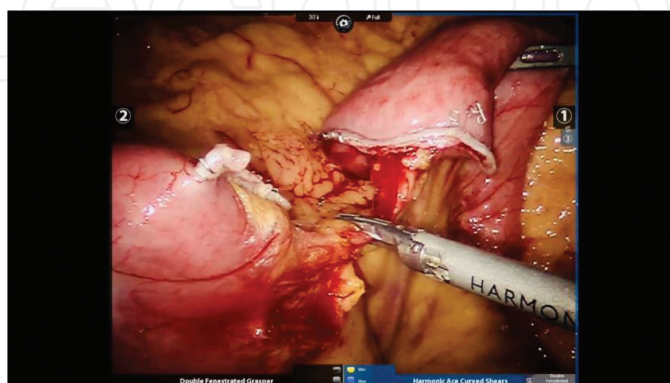


Figure 9. The mesentery of the jejunum is divided vertically for 3–5 cm to decrease the amount of tension on future mobilization of the Roux limb to meet the gastric pouch.

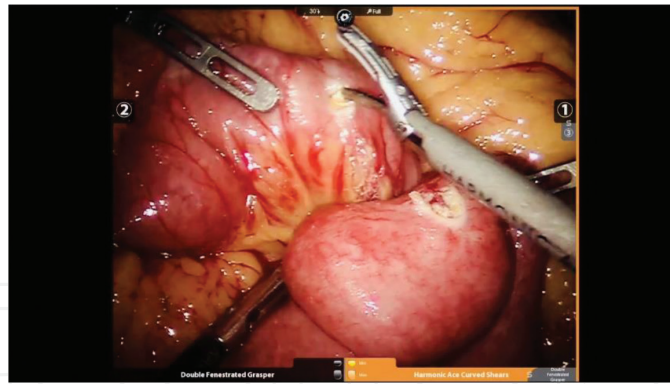

Figure 10. Antimesenteric enterotomies are created at 150 cm distal to the jejunal transection site after selecting the site of the future jejunojejunostomy anastomosis.

- d. A stapled side-to-side, functional end-to-end jejunojejunostomy is created with a linear stapler, ideally long, to prevent stenosis when closing the common enterotomy used to introduce the stapler (**Figure 11**). This author's preferred technique involves a bi-directional linear anastomosis, with the stapler fired to the right and to the left, so that the central common antimesenteric enterotomy is stapled with another linear stapler (**Figure 12**). Alternatively, the common enterotomy may be closed with the two-layer technique, first with absorbable suture with full-thickness bites and then with permanent suture with seromuscular bites.
- e. The jejunojejunostomy mesenteric defect is identified and closed with running non-absorbable suture to minimize the risk of future internal herniation (**Figure 13**).
- f. The greater omentum must be divided into half along the midline, starting at the level of the transverse colon and heading toward the greater curve of the stomach to allow the Roux limb to ascend to meet the future gastric pouch without excessive tension caused by the amount of greater omentum present in morbidly obese patients (**Figure 14**).
- g. A retrogastric plane is identified along the lesser curve of the stomach by dissecting the gastrohepatic ligament and protecting the left gastric artery. Once the posterior wall of the stomach is seen, a linear stapler is used to transect it first horizontally at 5 cm distal to the gastroesophageal junction and then vertically toward the angle of His, all of this with confirmation that the orogastric tube inserted by Anesthesia at the beginning of the case has already been removed so that it is not stapled with the stomach (**Figure 15**). All of this is done to create a 30 cc capacity, vertical gastric pouch completely separated from the gastric remnant. Many times, using a 36–40 Fr Bougie as a sizer in the gastric pouch is necessary prior to firing the stapler vertically to ensure that the gastric pouch lumen is not too constricted or too wide. If a significant hiatal hernia is present, it should be repaired, although it is known that the Roux en Y anatomy will decrease and potentially eradicate the incidence of reflux.
- h. An anterior or posterior gastrotomy is created on the gastric pouch with respect to the horizontal staple line, while an antimesenteric enterotomy is created on the Roux limb. A linear stapler is used to create a stapled side-to-side, functional end-to-end gastrojejunostomy anastomosis approximately 3 cm in length but not longer than that (**Figure 16**).

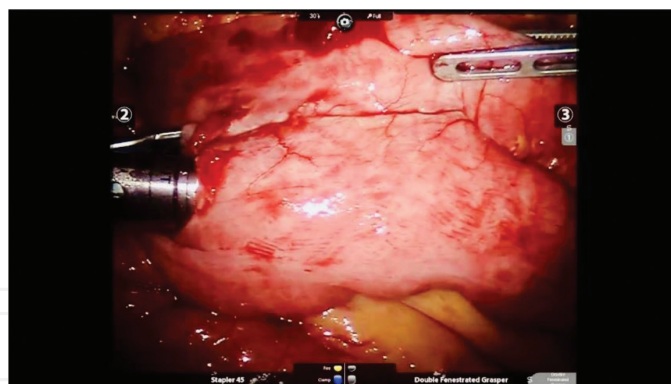


Figure 11. A bi-directional, stapled side-to-side, functional end-to-end jejunojunctionostomy anastomosis is constructed at the 150 cm mark to give rise to the common channel (the stapler firing from right to left is shown here, with an additional left to right firing deployed next).

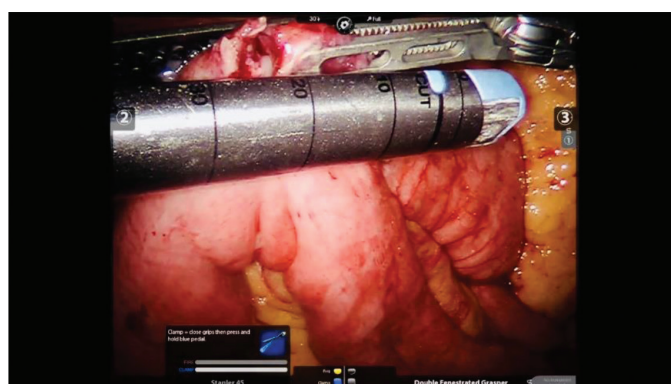


Figure 12. The central common enterotomy is transected and closed with an additional one or two linear firings of the stapler, with extreme care not to narrow the lumen of the bowel at the biliopancreatic or Roux limbs, or at the common channel.

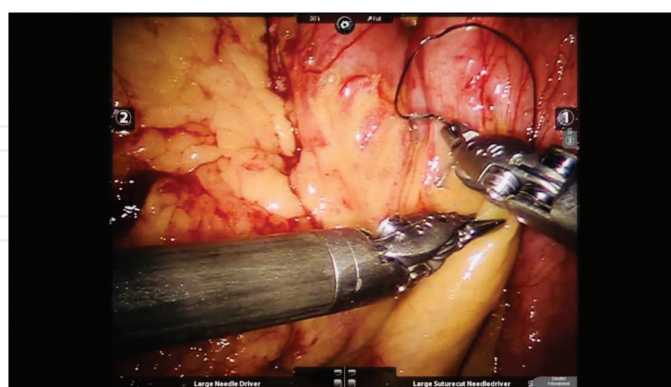


Figure 13. The jejunojunctionostomy mesenteric defect is closed with non-absorbable suture to prevent future internal herniation.

- i. The common gastrotomy and enterotomy are closed with the two-layer technique in an intracorporeal suturing fashion, first with absorbable suture with full-thickness bites, followed by non-absorbable suture with seromuscular bites to imbricate the first suture line (Figure 17).

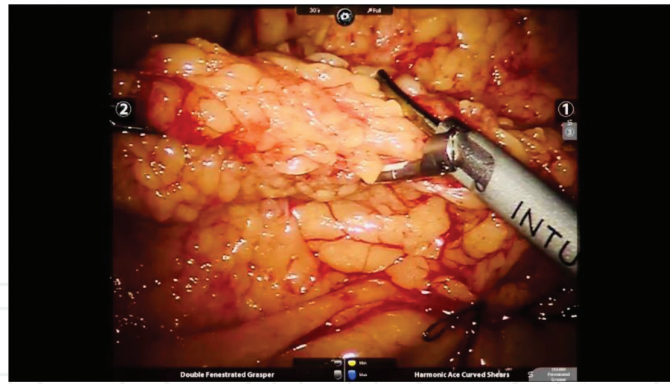


Figure 14. The greater omentum is transected along the midline from the level of the transverse colon to the greater curve of the stomach to allow the Roux limb to reach the future gastric pouch with minimal tension in an antecolic, antegastric fashion.

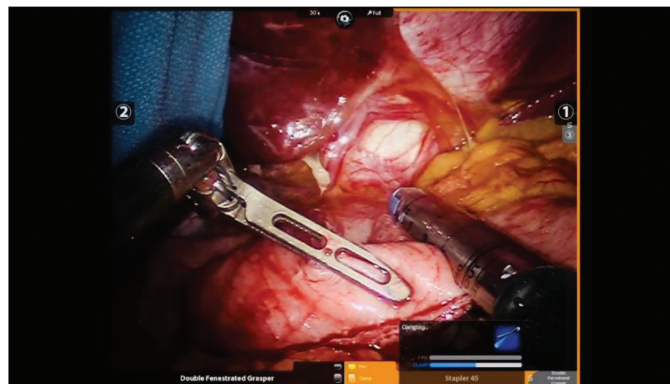


Figure 15. Once the retrogastric plane is identified from the lesser curve approach while protecting the left gastric artery, a 30 cc capacity, vertical gastric pouch is created at 5 cm distal to the gastroesophageal junction, first with a horizontal firing of the stapler, with subsequent vertical firings toward the angle of His, to completely separate the gastric pouch from the gastric remnant.

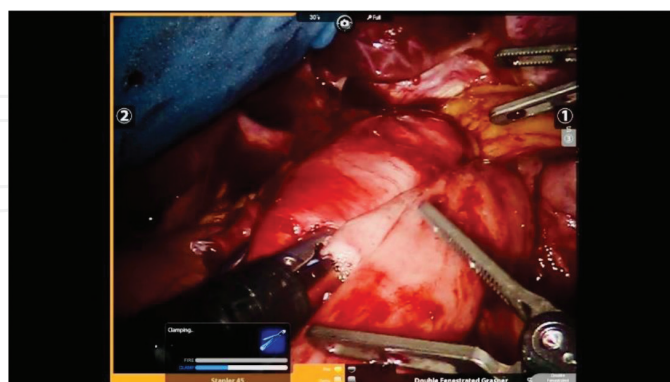


Figure 16. After creating an anterior or posterior gastrotomy on the gastric pouch and an antimesenteric enterotomy on the Roux limb, a linear stapler is used to create a 3 cm gastrojejunostomy anastomosis, with loss of a few millimeter during closure of the common gastrotomy and enterotomy.

- j. A leak test is necessary, ideally with intraoperative upper endoscopy performed by the surgeon. In addition, the use of ICG and Firefly technology can help to detect areas of ischemia at the anastomosis prior to firing of the stapler or even afterward.

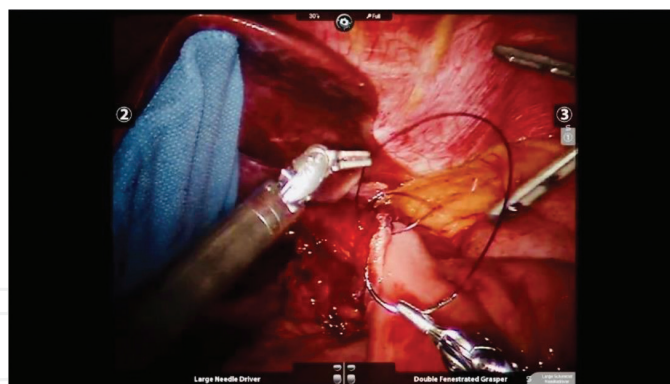


Figure 17. The common gastrotomy and enterotomy at the gastrojejunostomy are closed with the two-layer intracorporeal suturing technique, with absorbable running full-thickness bites, followed by non-absorbable running seromuscular bites, followed by a leak test with or without intraoperative endoscopy.

- k. Once both anastomoses are inspected and hemostasis is ensured, the liver retractor and ports are removed after closing the stapler site fascial defect with a fascial closure device. The incisions are closed with absorbable suture.

7. Biliopancreatic diversion with duodenal switch

The most powerful metabolic procedure is well known by a few expert bariatric surgeons and mostly misunderstood by most surgeons and the public due to some biased reports of complications that deviate themselves from the excellent outcomes derived from this operation that requires a level of expertise that surpasses that of the Roux en Y gastric bypass. This surgery is not meant to be performed by all surgeons. It is meant to be done by a few individuals who have not only mastered the technical rigor required to carry it out but also the complex potential complications and the medical and nutritional management that are associated with the duodenal switch [24]. In general, it is known that the excess weight loss at 1 year is >75%, sometimes approaching 80–85%. However, this is not the only advantage of this fascinating operation. This is the origin of the sleeve gastrectomy, when such procedure used to be performed as the first stage of the duodenal switch.

When performed correctly, with attention to detail while minimizing the risk of complications, the duodenal switch yields significant results and quality of life scores that are usually maintained over the years, even at 10 years of follow-up in some cases [25, 26]. Some critics argue that this operation produces a high percentage of reoperation cases due to complications, many times up to 40% or higher, along with nutrient and protein deficiencies in approximately 10% of patients [27]. While this may be true, it is important to realize what a tremendous impact the duodenal switch has on the super obese and the super-super obese patients' metabolism and comorbidities, with high and sustainable success rates that cannot be achieved even with the gastric bypass sometimes. This is the very reason that the duodenal switch cannot and should not be offered to all bariatric patients. This is an operation that demands a superior level of commitment and discipline on behalf of the patient and the

surgical and bariatric team, not only during the perioperative period but also, especially, during the long-term follow-up that is expected, ideally for life.

The fundamental indications for a laparoscopic or robotic biliopancreatic diversion with duodenal switch are the same as those for the sleeve gastrectomy or Roux en Y gastric bypass, i.e., a body mass index greater than 40 kg/m² or greater than 35 with an obesity-related comorbidity. However, in addition to these essential indications to qualify for bariatric surgery, it is understood that the patient must belong to the category of significant, uncontrolled insulin-dependent diabetes mellitus type 2, with a body mass index of at least 50 (super obesity) or 60 (super-super obesity), all of this in the context of excellent display of psychological maturity, reliability, medication compliance, and discipline, especially considering the potential vitamin and nutrient deficiency complications that could arise from this powerful operation. Having said that, the biliopancreatic diversion with duodenal switch, as it has been previously presented, has the most significant effect on excess weight loss, even superior to the Roux en Y gastric bypass. Although the duodenal switch exhibits lower rates of reflux compared to the sleeve gastrectomy due to the nature of a larger sleeve anatomy in this case, the Roux en Y gastric bypass surpasses it in this respect because it does not involve a sleeve reconstruction, and therefore there is not a high-pressure system in a gastric bypass that would exacerbate reflux. The biliopancreatic diversion with duodenal switch, therefore, cannot occupy the place of gold standard for bariatric and metabolic surgery simply because it should only be reserved to those patients who meet these rigorous criteria, for their own safety. On the other hand, no other metabolic procedure has the potential to impact the patient's quality of life, metabolism, and health than the duodenal switch.

In general, it is widely accepted that this operation involves the following steps:

- a. After pneumoperitoneum creation and placement of foregut surgery arranged ports and a liver retractor, the procedure begins with creation of a vertical gastric sleeve that has a larger diameter than produced during a typical sleeve gastrectomy, this time using a 54 Fr Bougie or larger.
- b. The terminal ileum is identified, and 100–150 cm are counted retrograde while running the bowel, with marking stitches placed to identify the future site of the ileoileostomy anastomosis and the creation of the common channel.
- c. From the marking stitches on the distal ileum that represent the future site of the ileoileostomy, another 150 cm are counted retrograde to identify the point of transection to divide the ileum and create a long biliopancreatic limb proximally, and a 150-cm alimentary limb distally. The ileum is divided here.
- d. The end of the alimentary limb is secured to the mesentery of the bowel in the right upper quadrant with temporary stay sutures in preparation for the post-pyloric dissection and transection.
- e. The duodenal bulb is subjected to retroduodenal blunt dissection very carefully while protecting the gastroduodenal artery and the head of the pancreas from injury, all of this with proper traction on the duodenum. Alternatively, the dissection may be performed from

the greater curve of the stomach in the pre-pyloric region and carried out to the duodenal bulb to dissect in the posterior plane.

- f. Once the duodenal bulb is mobilized, while ensuring that the common bile duct insertion into the second portion of the duodenum has not been violated, the duodenum is transected 2 cm distal to the pylorus with a linear stapler.
- g. The divided end of the alimentary limb, which was secured to the right upper quadrant bowel mesentery, is now anastomosed to the duodenal bulb in an end to side fashion (duodenum to ileum) in two layers, with the intracorporeal suturing technique, with absorbable suture first, and with non-absorbable suture next. A leak test is performed, ideally with intraoperative endoscopy. ICG testing with Firefly technology is also useful to detect ischemia prior to the anastomosis creation.
- h. Finally, once the duodenoileostomy is created, the ileoileostomy is constructed in a stapled side-to-side, functional end-to-end fashion with a linear stapler at the site where the marking sutures were placed at 100–150 cm proximal to the ileocecal valve, between the divided end of the ileum on the biliopancreatic limb and the distal ileum, to create the common channel.
- i. A surgical drain is left in the epigastric region overlying the duodenoileostomy, but it is not required.
- j. The liver retractor and ports are removed after the stapler fascial defect is sutured and closed with an endoscopic fascial closure device. The incisions are closed with absorbable suture.

8. Other procedures and devices

The mini gastric bypass has gained popularity over the years, but has not proven to be as widely accepted as the Roux en Y gastric bypass despite some evidence that it produces similar weight loss effects and control of comorbidities compared to the Roux en Y gastric bypass [28]. Nevertheless, although it appears to be simpler to perform due to the eradication of the need to create two anastomoses, the concept of a loop gastrojejunostomy without the benefit of a Roux en Y anatomy produces a higher incidence of anastomotic marginal ulcers in addition to bile reflux.

A more recently published and developed procedure, the single anastomosis duodeno-ileal switch (SADIS), has begun to gain more acceptance in the United States and other developed countries in terms of a valid metabolic operation that still requires Institutional Review Board approval in the American healthcare system, but has promising results regarding weight loss and control of comorbidities. In the same fashion as the mini gastric bypass, the concept of a single anastomosis appears to be appealing to many surgeons and patients, although it still carries a high incidence of macronutrient deficiencies on follow-up studies as the classic biliopancreatic diversion with duodenal switch does [29].

The realm of endoscopic alternatives to surgical procedures for morbid obesity treatment includes the development of devices that mimic the malabsorptive mechanisms that surgery provides. Such an example is the EndoBarrier Gastrointestinal Liner, or duodeno-jejunal bypass sleeve (DJBS). A meta-analysis conducted on a few randomized controlled trials and several observational studies revealed up to 12.6% excess weight loss when compared to dietary modification, but there was a high level of bias detected on the studies [30].

The recently introduced AspireAssist device, which consists of an endoscopically placed gastrostomy tube that allows drainage of up to 30% of consumed calories after every meal, has been reported to have superior results to those of lifestyle modification, with up to 25% excess weight loss in some patients. Some of its complications are inherent to the fact that this requires the presence of a foreign body in the stomach which is constantly used to drain its contents [31]. Other devices such as the intragastric balloons have already shown some of the complications that arise from this limitation of having a foreign body in the gastric lumen, which is something that is surpassed by surgery.

Whether these procedures affect restriction, or malabsorption, or decrease the number of calories that are consumed, they serve mostly as an adjunct to bariatric surgery, as a bridge to an operation for those patients who are not medically optimized at the beginning, or as a means to lose weight for those who do not qualify for surgery yet. In any case, these devices do not offer the ability to change and impact the body's metabolism, which is something that surgery provides.

9. Revisional bariatric surgery

Although an entire chapter should be dedicated to this challenging and fascinating field of metabolic and bariatric surgery, it is important to recognize that revisional surgery is becoming a common type of operation in this subspecialty due to the complications that are seen from prior bariatric procedures that either were not performed well, or were performed appropriately but on the wrong surgical candidates, or were properly done but eventually failed to maintain the expected weight loss and comorbidity control. To perform this type of surgery represents an enormous responsibility, since revisional bariatric operations are known to be extremely challenging and technically demanding [32–34]. In general, the following categories detail the types of revisions that are commonly performed:

- a. Removal of adjustable gastric band, with or without conversion to sleeve gastrectomy or Roux en Y gastric bypass as a single-stage or a two-stage procedure
- b. Revision of sleeve gastrectomy (re-sleeve)
- c. Roux en Y gastric bypass anastomotic revision (gastrojejunostomy, jejunojejunostomy, or both)
- d. Roux en Y gastric bypass reversal

- e. Sleeve gastrectomy conversion to Roux en Y gastric bypass
- f. Vertical banded gastroplasty conversion to Roux en Y gastric bypass
- g. Closure of internal hernia, with or without anastomotic revision.

These are some examples of the operations that have shaped the field of revisional bariatric surgery over the years. It is essential to understand that the main purpose of revisional bariatric surgery is to first define the anatomy that was created with the original bariatric procedure, which must be done with meticulous technique, with enterolysis and adhesiolysis performed with patience to eventually identify the anatomic components involved in the operation in question. Once the anatomy is defined, the next step is to revise the operation by performing the task that is demanded with the same care exercised during a new bariatric procedure that is not a revision. In other words, first the anatomy must be defined, anastomotic limbs must be identified, staple lines and fistulae must be seen, and anastomoses must be studied with intraoperative endoscopy as much as possible along with strictures or stenoses, so that at the end of the first stage of the operation, a plan of action can be implemented with relative simplicity because the most difficult task has already been executed.

It must be clear, at the same time, that all bariatric procedures may produce complications [35–37]. These are technically demanding surgeries that are not exempt from causing adverse outcomes. For instance, laparoscopic sleeve gastrectomy leaks may be treated with endoscopic therapy including placement of stents, but eventually they may require resection and conversion to Roux en Y gastric bypass. In the same manner, gastric bypass leaks may require a revision of the anastomosis in question, or a more complex type of procedure such as resection and construction of a new anastomosis, if endoscopic therapy fails. Stenotic or strictured gastric sleeves may be subjected to myotomy or gastroplasty procedures or simply treated with conversion to Roux en Y gastric bypass or duodenal switch. At the end, basic surgical concepts always apply to the most difficult revisional surgeries, with meticulous dissection, respect of the blood supply, gentle handling of tissues, avoidance of excessive tension, appropriate sizing of anastomoses, and performance of leak tests with intraoperative endoscopy, ideally, as much as possible.

10. Robotic bariatric surgery

Although the purpose of this chapter is not to discuss robotic surgery, it is essential to admit that the robotic revolution has already reached bariatric surgery and has become a part of this subspecialty to the point that several high-quality studies have already supported the observation that the surgical robot is extremely useful in this field, especially during challenging procedures such as Roux en Y gastric bypass, duodenal switch, or revisional surgery that require creation of anastomoses and closure of enterotomy or gastrotomy defects with delicate precision. Several studies have presented excellent outcomes with a hybrid or a fully robotic approach to complex procedures such as gastric bypass or duodenal switch [38–41]. However, the surgical robot is also useful for more simple procedures such as

sleeve gastrectomy due to the multiple advantages offered by the robotic platform, such as improved dexterity with wristed articulation, superior visualization with the robotic endoscope, the ability to control three arms simultaneously in addition to the camera, and most of all, the power to maneuver the instruments and the camera without the need to depend so much on the assistant, who can now focus on other important tasks such as retraction and exposure, for example.

The surgical robotic platform offers advantages to the surgeon that conventional laparoscopy cannot provide. While an excellent set of surgical skills is an essential requirement to perform challenging procedures with laparoscopic techniques, the robotic approach enables the surgeon to carry out tasks that are extremely difficult to do with laparoscopy, particularly when it comes to the first stage of any bariatric revision, i.e., the establishment and definition of the original operation's anatomy. The dissection is facilitated by the robotic technology, which is much easier to do once the surgeon has overcome the learning curve that is inherent to the adoption of any new technique.

For more details on the use of the robotic technology for the field of bariatric surgery, including its safe adoption in community hospitals that are not considered major academic centers and its application to the treatment of non-bariatric conditions on obese and morbidly obese patients such as hernia repairs, please see other studies published by this author [42–44].

11. Endoscopic management of complications

A point that has been consistently made on this chapter is the fundamental role that upper gastrointestinal endoscopy has both during and after surgery. However, the role of endoscopy on the pre-operative evaluation of the bariatric patient must not be ignored, for it is very important and most of the times necessary to perform a thorough evaluation of the gastric lumen prior to performing a bariatric operation due to its ability to detect the presence of severe ulceration, *Helicobacter pylori* infection, and significant hiatal hernias that must be repaired during surgery, especially for sleeve gastrectomy, or even the presence of gastric tumors.

Nonetheless, regardless of whether surgeons consider pre-operative endoscopy as an essential component of the bariatric surgery evaluation, it cannot be denied that intraoperative endoscopy serves an important function for many reasons. First of all, it provides valuable information regarding the lumen of the stomach, whether a gastric sleeve or a gastric pouch, including hemostasis of the staple line or the anastomosis, the diameter of the anastomosis, the absence or presence of stenosis, and of course, verification of a staple line or anastomotic leak. While it is true that a staple line or anastomotic leak test can be performed without endoscopy, usually with an orogastric tube or methylene blue injection into the gastric lumen while compressing distally, the information that intraoperative endoscopy provides cannot be surpassed. In some instances, the findings at the time of endoscopy lead to a change in the operative procedure and require a revision in the same setting.

With respect to complications, such as staple line or anastomotic leaks, sleeve stenosis, gastrojejunostomy stenosis, gastrogastic fistulae, gastrophleural fistulae, and others, the preferred approach of any experienced bariatric surgeon is usually endoscopic, not surgical. Endoscopic intervention has the ability to provide good results with less morbidity and mortality compared to revisional surgery, unless there is no more room for endoscopy after failure of this type of therapy [45–47]. The use of esophageal stents initially developed for the treatment of esophageal cancer has revolutionized the treatment of bariatric complications and is a skill that must be learned by all bariatric surgeons. It requires an excellent set of endoscopic skills which can be acquired over time and perfected to the point that the need for revisional surgery will become a rare event. This skillset also includes the ability to suture endoscopically to close fistulae or revise and reduce anastomoses or to inject fibrin glue or deploy clips, all of which are maneuvers that can be learned by a surgeon and do not have to be exclusively associated with our gastroenterology colleagues. In the end, although revisional bariatric surgery is always a challenging and exciting field, in the interest of the patient, it is best to try endoscopic therapy prior to committing to an operation that carries a higher morbidity and mortality.

12. Conclusion and personal message

Bariatric and metabolic surgery is not for everybody. It is dedicated to the treatment of patients with morbid obesity and its associated comorbidities in a way that has proven to be more effective than the most rigorous medical therapy. The benefits are so palpable and reproducible that the body of knowledge acquired over decades of basic and clinical scientific research is outstanding.

The gold standard par excellence continues to be the Roux en Y gastric bypass, whether laparoscopic or robotic, due to its metabolic profile as a reliable operation with durable effects on the patients and superior control and eradication of metabolic and chronic comorbidities such as diabetes mellitus type 2, hypertension, hyperlipidemia, obstructive sleep apnea, and gastroesophageal reflux disease. The sleeve gastrectomy is an excellent choice, too, but has limitations in particular with super obese patients, those with insulin-dependent diabetes, and individuals with severe reflux. It is less complex than the gastric bypass but offers good outcomes to patients, especially to those who are not so severely obese and are young, including female patients of childbearing age and those with Crohn's disease or on hemodialysis. The biliopancreatic diversion with duodenal switch is the most powerful bariatric procedure and should be reserved to super- or super-super obese patients with uncontrolled comorbidities who exhibit discipline and commitment to a lifetime of follow up and management of nutritional and vitamin deficiencies. The surgical robot provides the surgeon with the ability to perform bariatric operations with more versatility and more tools once the learning curve is mastered, with outcomes comparable and sometimes superior to those of laparoscopy in expert hands. Revisional bariatric surgery, whether performed with the robot or with conventional laparoscopy, is an incredibly challenging field that demands full concentration, attention to detail, meticulous dissection, and proper technique to initially define the anatomy and identify the components of the original operation and to then perform the revision with safety, ideally with assistance from intraoperative endoscopy, which is also used to treat com-

plications with multiple tools that must be known to bariatric surgeons who always look for ways to improve their skills to benefit the patients.

On the other hand, bariatric and metabolic surgery is not for all surgeons. It is the dominion of those who are courageous enough to change millions of lives while taking care of patients at high risk of morbidity and mortality with minimally invasive techniques and with a life-long relationship, in many instances, that can only be comparable to surgical oncology. The impact that metabolic and bariatric surgery has on the patient cannot be measured with simple numbers reflecting a body mass index or percent excess weight loss. It cannot be measured by hemoglobin A1C or lipid profiles or even the lack of anti-hypertensive medications. This impact goes beyond the numbers and surpasses any concept of external or inner beauty. The benefits produced by this type of operation are so significant to our patients that their quality of life truly increases, their willingness to live and achieve self-improvement becomes stronger, and they may serve as an example to others in a way that usually cancer patients do. As a result, those who are brave enough to become excellent metabolic and bariatric surgeons are humbled by this realization that we have become part of something grand, something greater than ourselves, in ways that we cannot imagine. After all, did we not go into surgery for this very reason?

Author details

Rodolfo José Oviedo Barrera

Address all correspondence to: rodolfo.j.oviedo@gmail.com

Metabolic and Bariatric Surgery, Robotic Advanced Gastrointestinal Surgery, Winchester Medical Center, Valley Health Metabolic & Bariatric Program, Winchester, Virginia, United States of America

References

- [1] DeLaet D, Schauer D. Obesity in adults. *BMJ Clinical Evidence*. 2011;**03**(Suppl. 1-25):604
- [2] Colquitt JL, Pickett K, Loveman E, Frampton GK. Surgery for weight loss in adults (review). *Cochrane Database of Systematic Reviews*. 2014;**8**:1-123. DOI: 10.1002/14651858.CD003641.pub4
- [3] Chang SH, Stoll CRT, Song J, Varela JE, Eagon CJ, Colditz GA. Bariatric surgery: An updated systematic review and meta-analysis, 2003-2012. *JAMA Surgery*. 2014;**149**(3):275-287. DOI: 10.1001/jamasurg.2013.3654
- [4] Sundbom M. Laparoscopic revolution in bariatric surgery. *World Journal of Gastroenterology*. 2014;**20**(41):15135-15143
- [5] Schirmer B. Laparoscopic bariatric surgery. *Surgical Endoscopy*. 2006;**20**:S450-S455

- [6] Stefanidis A, Oldfield BJ. Neuroendocrine mechanisms underlying bariatric surgery: Insights from human studies and animal models. *Journal of Neuroendocrinology*. 2017;**29**:e12534. DOI: 10.1111/jne.12534
- [7] Lutz TA, Bueter M. The physiology underlying Roux-en-Y gastric bypass: A status report. *American Journal of Physiology. Regulatory, Integrative and Comparative Physiology*. 2014;**307**:R1275-R1291
- [8] Yarmush ML, D'Alessandro M, Saeidi N. Regulation of energy homeostasis after gastric bypass surgery. *Annual Review of Biomedical Engineering*. 2017;**19**:459-484
- [9] Zakeri R, Batterham RL. Potential mechanisms underlying the effect of bariatric surgery on eating behaviour. *Current Opinion in Endocrinology, Diabetes, and Obesity*. 2017;**25**:3-11. DOI: 10.1097/MED.0000000000000379
- [10] Schauer PR et al. Bariatric surgery versus intensive medical therapy for diabetes: 5-year outcomes. *The New England Journal of Medicine*. 2017;**376**(7):641-651. DOI: 10.1056/NEJMoa1600869
- [11] Gulliford MC et al. Effect of contemporary bariatric surgical procedures on type 2 diabetes remission. A population-based matched cohort study. *Obesity Surgery*. 2016;**26**:2308-2315. DOI: 10.1007/s11695-016-2103-6
- [12] Koh CY, Inaba CS, Sujatha-Bhaskar S, Hohmann S, Ponce J, Nguyen NT. Laparoscopic adjustable gastric banding explantation and implantation at academic centers. *JACS*. 2017;**225**(4):532-537. DOI: 10.1016/j.jamcollsurg.2017.06.015
- [13] Chapman AE et al. Laparoscopic adjustable gastric banding in the treatment of obesity: A systematic literature review. *Surgery*. 2004;**135**(3):326-351
- [14] Benaiges D et al. Laparoscopic sleeve gastrectomy: More than a restrictive bariatric procedure? *World Journal of Gastroenterology*. 2015;**21**(41):11804-11814. DOI: 10.3748/wjg.v21.i41.11804
- [15] Daskalakis M, Weiner RA. Sleeve gastrectomy as a single-stage bariatric operation: Indications and limitations. *Obesity Facts*. 2009;**2**(Suppl 1):8-10. DOI: 10.1159/000198239
- [16] Iannelli A, Dainese R, Piche T, Facchiano E, Gugenheim J. Laparoscopic sleeve gastrectomy for morbid obesity. *World Journal of Gastroenterology*. 2008;**14**(6):821-827. DOI: 10.3748/wjg.14.821
- [17] Hutter MM et al. First report from the American College of Surgeons—Bariatric Surgery Center Network: Laparoscopic sleeve gastrectomy has morbidity and effectiveness positioned between the band and the bypass. *Annals of Surgery*. 2011;**254**(3):410-422. DOI: 10.1097/SLA.0b013e31822c9dac
- [18] Diamantis T, Apostolou KG, Alexandrou A, Griniatsos J, Felekouras E, Tsigris C. Review of long-term weight loss results after laparoscopic sleeve gastrectomy. *SOARD*. 2014;**10**:177-183. DOI: 10.1064/j.soard.2013.11.007
- [19] Hirth DA, Jones EL, Rothchild KB, Mitchell BC, Schoen JA. Laparoscopic sleeve gastrectomy: Long-term weight loss outcomes. *SOARD*. 2015;**11**:1004-1007. DOI: 10.1016/j.soard.2015.02.016

- [20] Gonzalez-Heredia R, Sanchez-Johnsen L, Valbuena VSM, Masrur M, Murphey M, Elli E. Surgical management of super-super obese patients: Roux-en-Y gastric bypass versus sleeve gastrectomy. *Surgical Endoscopy*. 2016;**30**:2097-2102. DOI: 10.1007/s00464-015-4465-6
- [21] Adams TD et al. Weight and metabolic outcomes 12 years after gastric bypass. *The New England Journal of Medicine*. 2017;**377**:1143-1155. DOI: 10.1056/NEJMoa1700459
- [22] Khotari SN, Borgert AJ, Kallies KJ, Baker MT, Grover BT. Long-term (>10-year) outcomes after laparoscopic Roux-en-Y gastric bypass. *SOARD*. 2017;**13**(6):972-978. DOI: 10.1016/j.soard.2016.12.011
- [23] Peterli R et al. Laparoscopic sleeve gastrectomy versus Roux-en-Y gastric bypass for morbid obesity: 3 year outcomes of the prospective randomized Swiss Multicenter bypass or sleeve study (SM-BOSS). *Annals of Surgery*. 2017;**265**:466-473. DOI: 10.1097/SLA.0000000000001929
- [24] Topart P, Becouarn G, Delarue J. Weight loss and nutritional outcomes 10 years after biliopancreatic diversion with duodenal switch. *Obesity Surgery*. 2017;**27**(7):1645-1650
- [25] Aasprang A, Andersen JR, Vage V, Kolotkin R, Natvig GK. Ten-year change in health-related quality of life after biliopancreatic diversion with duodenal switch. *SOARD*. 2016;**12**(8):1594-1600. DOI: 10.1016/j.soard.2016.04.030
- [26] Sethi M, Chau E, Youn A, Jiang Y, Fielding G, Ren-Fielding C. Long-term outcomes after biliopancreatic diversion with and without duodenal switch: 2-, 5-, and 10-year data. *SOARD*. 2016;**12**(9):1697-1705. DOI: 10.1016/j.soard.2016.03.006
- [27] Bolckmans R, Himpens J. Long-term (> 10 yrs) outcome of the laparoscopic biliopancreatic diversion with duodenal switch. *Annals of Surgery*. 2016;**264**(6):1029-1037. DOI: 10.1097/SLA.0000000000001622
- [28] Mahawar KK et al. Current status of mini-gastric bypass. *Journal of Minimal Access Surgery*. 2016;**12**(4):305-310. DOI: 10.4103/0972-9941.181352
- [29] Shoar S, Poliakin L, Rubenstein R, Saber AA. Single anastomosis duodeno-ileal switch (SADIS): A systematic review of efficacy and safety. *Obesity Surgery*. 2017;**1**-10. DOI: 10.1007/s11695-017-2838-8
- [30] Rohde U, Hedback N, Gluud LL, Vilsboll T, Knop FK. Effect of the endobarrier gastrointestinal liner on obesity and type 2 diabetes: A systematic review and meta-analysis. *Diabetes, Obesity and Metabolism*. 2016;**18**(3):300-305. DOI: 10.1111/dom.12603
- [31] Thompson CC et al. Percutaneous gastrostomy device for the treatment of class II and class III obesity: Results of a randomized controlled trial. *The American Journal of Gastroenterology*. 2017;**112**:447-457. DOI: 10.1038/ajg.2016.500
- [32] Dakour Aridi HN, Wehbe MR, Shamseddine G, et al. Long-term outcomes of Roux-en-Y gastric bypass conversion of failed laparoscopic gastric band. *Obesity Surgery*. 2017;**27**:1401. DOI: 10.1007/s11695-016-2529-x
- [33] Angrisani L, Vitiello A, Santonicola A, Hasani A, De Luca M, Iovino P. Roux-en-Y gastric bypass versus sleeve gastrectomy as revisional procedures after adjustable gastric band: 5-year outcomes. *Obesity Surgery*. 2017;**27**(6):1430-1437. DOI: 10.1007/s11695-016-2502-8

- [34] Noel P et al. Revised sleeve gastrectomy: Another option for weight loss failure after sleeve gastrectomy. *Surgical Endoscopy*. 2014;**28**:1096-1102. DOI: 10.1007/s00464-013-3277-9
- [35] Nedelcu AM, Skalli M, Deneve E, Fabre JM, Nocca D. Surgical management of chronic fistula after sleeve gastrectomy. *SOARD*. 2014;**9**:879-884. DOI: 10.1016/j.soard.2013.02.010
- [36] Chouillard E et al. Roux-en-Y fistulo-jejunostomy as a salvage procedure in patients with post-sleeve gastrectomy fistula. *Surgical Endoscopy*. 2014;**28**:1954-1960. DOI: 10.1007/s00464-014-3424-y
- [37] Chahine E, Kassir R, Dirani M, et al. Surgical management of gastrogastic fistula after roux-en-Y gastric bypass: 10-year experience. *Obesity Surgery*. 2017;**1**-6. DOI: 10.1007/s11695-017-2949-2
- [38] Fourman MM, Saber AA. Robotic bariatric surgery: A systematic review. *SOARD*. 2012;**8**:483-488. DOI: 10.1016/j.soard.2012.02.012
- [39] Ciocchi R et al. Current status of robotic bariatric surgery: A systematic review. *BMC Surgery*. 2013;**13**:53 <http://www.biomedcentral.com/1471-2482/13/53>
- [40] Stefanidis D, Bailey SB, Kuwada T, et al. Robotic gastric bypass may lead to fewer complications compared with laparoscopy. *Surgical Endoscopy*. 2017;**1**-7. DOI: 10.1007/s00464-017-5710-y
- [41] Sudan R, Podolsky E. Totally robot-assisted biliary pancreatic diversion with duodenal switch: Single dock technique and technical outcomes. *Surgical Endoscopy*. 2015;**29**(1):55-60. DOI: 10.1007/s00464-014-3653-0
- [42] Oviedo Barrera RJ. The surgical robot: Applications and advantages in general surgery. In: Kucuk S, editor. *Surgical Robotics*. Rijeka, Croatia, EU: InTech; 2018. pp. 39-64 Available from: <https://www.intechopen.com/books/surgical-robotics/the-surgical-robot-applications-and-advantages-in-general-surgery>
- [43] Oviedo RJ, Robertson JC, Alrajhi S. First 101 robotic general surgery cases in a community hospital. *JSLs*. 2016;**20**(3):e2016.00056. DOI: 10.4293/JSLs.2016.00056
- [44] Oviedo RJ, Robertson JC, Desai A. Robotic ventral hernia repair and endoscopic component separation: Outcomes. *JSLs*. 2017;**21**(3):e2017.00055. DOI: 10.4293/JSLs.2017.00055
- [45] Rebibo L, Hakim S, Dhahri A, Yzet T, Delcenserie R, Regimbeau JM. Gastric stenosis after laparoscopic sleeve gastrectomy: Diagnosis and management. *Obesity Surgery*. 2016;**26**:995-1001. DOI: 10.1007/s11695-015-1883-4
- [46] Nath A, Yewale S, Tran T, Brebbia JS, Shope TR, Koch TR. Dysphagia after vertical sleeve gastrectomy: Evaluation of risk factors and assessment of endoscopic intervention. *World Journal of Gastroenterology*. 2016;**22**(47):10371-10379. DOI: 10.3748/wjg.v22.i47.10371
- [47] Walsh C, Karmali S. Endoscopic management of bariatric complications: A review and update. *World Journal of Gastrointestinal Surgery*. 2015;**7**(5):518-523. DOI: 10.4253/wjge.v7.i5.518