

We are IntechOpen, the world's leading publisher of Open Access books Built by scientists, for scientists

6,900

Open access books available

186,000

International authors and editors

200M

Downloads

Our authors are among the

154

Countries delivered to

TOP 1%

most cited scientists

12.2%

Contributors from top 500 universities



WEB OF SCIENCE™

Selection of our books indexed in the Book Citation Index
in Web of Science™ Core Collection (BKCI)

Interested in publishing with us?
Contact book.department@intechopen.com

Numbers displayed above are based on latest data collected.
For more information visit www.intechopen.com



JVA, Mastication and Digital Occlusal Analysis in Diagnosis and Treatment of Temporomandibular Disorders

Serdar Gözler

Additional information is available at the end of the chapter

<http://dx.doi.org/10.5772/intechopen.72528>

Abstract

Temporomandibular joint disorder (TMJ) is a complex and multifactorial functional disorder. Best approach in the treatment of TMJ disorders needs in detail proper diagnostic study. Joint vibration analysis (JVA) device, a new age technology and one of the most important diagnostic tools, is used for detecting intra-articular sound vibrations. Every type of vibration in different frequencies shows us the status of joint. Evaluation can be made after analyzing the results applying to a diagram. Like Combining of the sound vibration diagnostic techniques with other examination methods may be very meaningful in efforts of treating TMJ problems. Another diagnosis method is the evaluation of chewing movements. Best chewing efficiency is the most important purpose of masticatory system. Final product is a very important indicator for the efficiency of the mastication, and chewing pattern. T-Scan digital occlusal analyzing system is another important occlusal diagnostic instrument. Digital occlusal analysis system is currently the most powerful method of TMD clinics for treatment of patients with muscle pain dysfunction syndrome. Digital occlusal analysis system allows us to perform the MPDS treatments, splint and occlusal rehabilitation. The three important diagnostic systems are described in this chapter.

Keywords: JVA, T-Scan, chewing pattern, mastication, temporomandibular disorders, MPDS

1. Introduction

Temporomandibular joint disorders (TMD) is one of the highly complicated fields in dentistry [1, 2]. It can emerge in various manners at any time during human life with symptoms such as limited mouth opening, pain at TMJ area, pain in masticatory muscles, headache specially around anterior temporal area, sounds emerging from temporomandibular joints, morning soreness, bruxism, clenching, head and neck pains, attrition and/or abfraction of teeth, internal derangement of temporomandibular disks, decreasing of volume in the synovial liquid. Temporomandibular joint disorder is a functional disturbance. Temporomandibular joints, masticatory muscles, teeth, bones and the central nerve system are all involved in TMJ pathology [3–6]. For many years, clinicians have employed various mechanical tools for diagnosis and to understand the reasons for the problem [7]. Due to the development of the chipset technology and software programming, we have now device-based diagnostic tools, joint vibration analysis, joint tracking measuring mastication analysis, computer-based occlusal analysis devices, and so on [8–10] available. However, there are still many questions and discussion points about some of the device-based diagnostic techniques [9]. These kind of device-based technologies require studying with a new methodology. Joint vibration analysis, joint tracker and mastication analysis, electromyography, tens devices and finally digital occlusal analysis systems all need new methodologies. That is to say if you have enough knowledge on how to conduct a joint vibration analysis or a digital occlusal analysis, it is possible to collect a lot of useful information with these devices [11–14].

All these symptoms are assembled under TMJ pathology [10, 15–19]. In dentistry, there is no other problem that must be managed in a multidisciplinary fashion like TMJ disorders.

Occlusal trauma that may occur after restorations is one of the biggest causes of temporomandibular disorders [20–23]. Dental extraction and orthodontic restorations are also important conditions that cause this discomfort [22, 24–27].

A large number of devices and methods are used for diagnosis and treatment of temporomandibular disorder. The reason for this is not only the complexity of the problem but also the demand for the use of noninvasive methods [10, 28–31].

For example, if you have enough knowledge about the joint vibration analysis or if you can use digital occlusal analysis properly, you can access very important information about the temporomandibular disorder [17, 32–34]. In addition, you may also have the opportunity to see and avoid pathology that may be related to joints according to the course of the treatment of the initial chewing pattern of orthodontic treatments [35–37]. However, it is very important to know how to use these devices, what their capabilities are, and how effective they can be so that it can be done. The predisposing factors of temporomandibular joint disorders can be eliminated before presenting whether all these devices are professionally used [28, 38–40].

Nowadays, one of the most widely used diagnostic tools in the examination of the pathology of temporomandibular joints is magnetic resonance imaging (MRI) technique [4, 11, 15]. MRI represents the golden standard among the temporomandibular diagnostic tools [41]. However, its acquisition is more difficult and costly than other diagnostic tools. Moreover, MRI examination of children is very difficult and complicated.

Craniomandibular dysfunctions are often multistructural [42] and intracapsular problems are one of the most important subjects that have been studied by dentists for a long time [33, 40, 43]. Normally, if there is no problem in a joint, no sound comes from that joint. There is no distortion in the relationship between joint-disk-articular surface. Joint is lined with synovium secreted for lubrication and nutrition. Joints are connected to a common bone, and therefore, they function together. Normal joints produce very little friction and vibration. If there is degeneration in the joint, there is sound in the joint [44–47]. The sound spectrum may be bigger or less than the human hearing limits. Scientific research has shown that TMJ sounds have been well categorized. Every TMJ sound is like a signature to a problem [48]. Since sound is a pressure energy, it has a particular frequency.

Another kind of useful information source is spectrum of TMJ sound. TMJ sounds have distinctive characteristics in clinical diagnosis efforts. Additionally, clinical-arthrographic investigations correlate arthrographic characteristics of intracapsular dysfunction of the temporomandibular joint with sound analysis. Sound patterns are reproducible and provide a noninvasive tool for diagnosis and treatment [14, 49].

In **Figure 1**, a graphic illustration screen shows the results of a clinical software that recorded and analyzed sounds emitted from the temporomandibular joint (TMJ) during simple function as a means for differentially diagnosing disorders of the joint. The patient's mouth opening distance is measured as 45 mm max. The repeated sounds emitted from the left joint peaks at around 43 mm. Spectral analysis of the same patient is shown in **Figure 2**.

Generally, spectral analysis considers the problem of determining the spectral content (i.e., the distribution of power over frequency) of a time series from a finite set of measurements, by

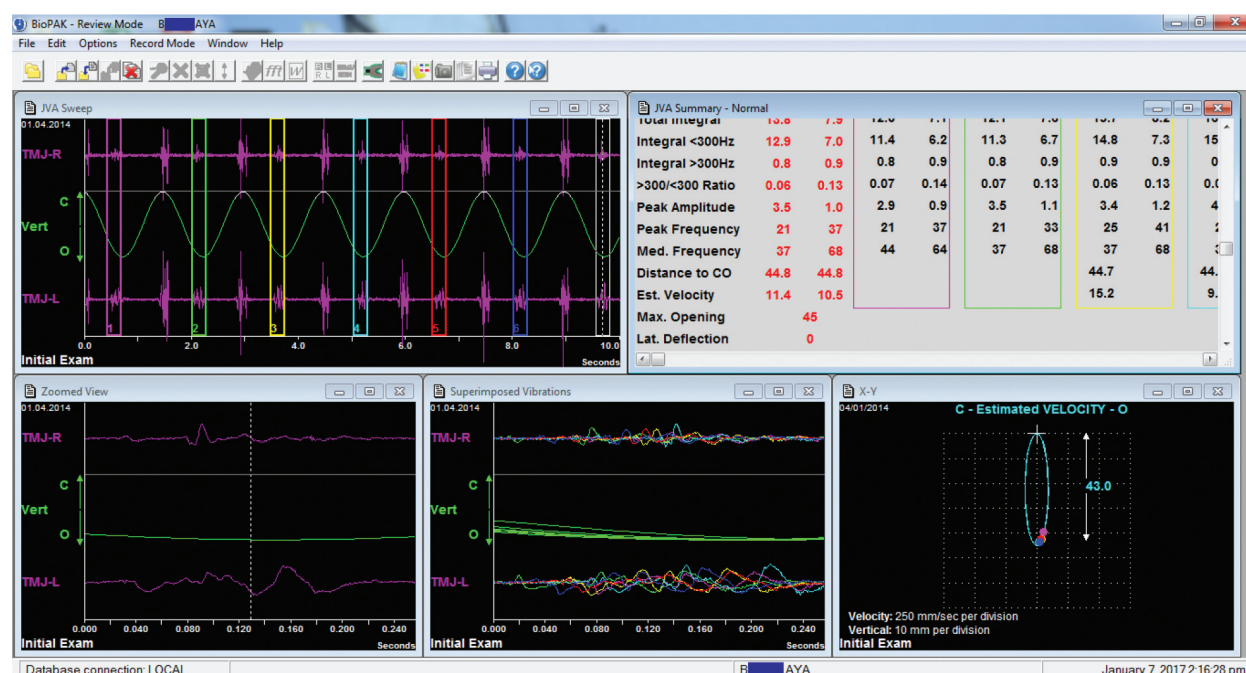


Figure 1. Maximum opening of the mouth is marked as 45 mm; however, there is a crepitation sound in the left joint at 43 mm of opening of the mouth. The crepitation sound was detected at this level in which head of the condyle is almost at the end of the protrusion. The condyle condition may be considered as only some ligament laxity.

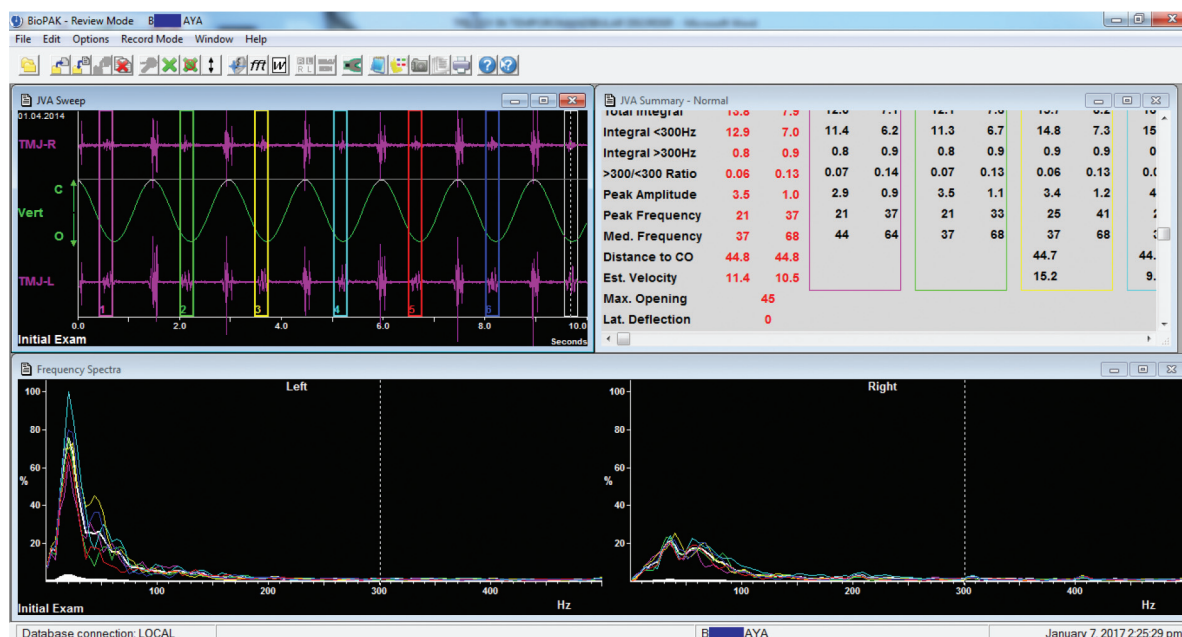


Figure 2. Spectral analysis considers the problem of determining the spectral content. Differences between energies of left and right joints are very clear. In this case, aggregation place of peak frequency is very close to the max opening limit, intracapsular deterioration has just started and it is only the beginning phase. We may consider this finding as only an MPD syndrome.

means of either nonparametric or parametric techniques. At JVA Sweep window of **Figure 2**, sound energy frequencies of left joint are shown on a time line.

Sounds due to temporomandibular joint disorders have been studied for a long time and are classified to the particular groups [45, 47, 50–52]. Very well-known sound frequencies belong to the “click” sound energy (**Figure 3**). A 2x zoom view of the click sound is shown in **Figure 3**.

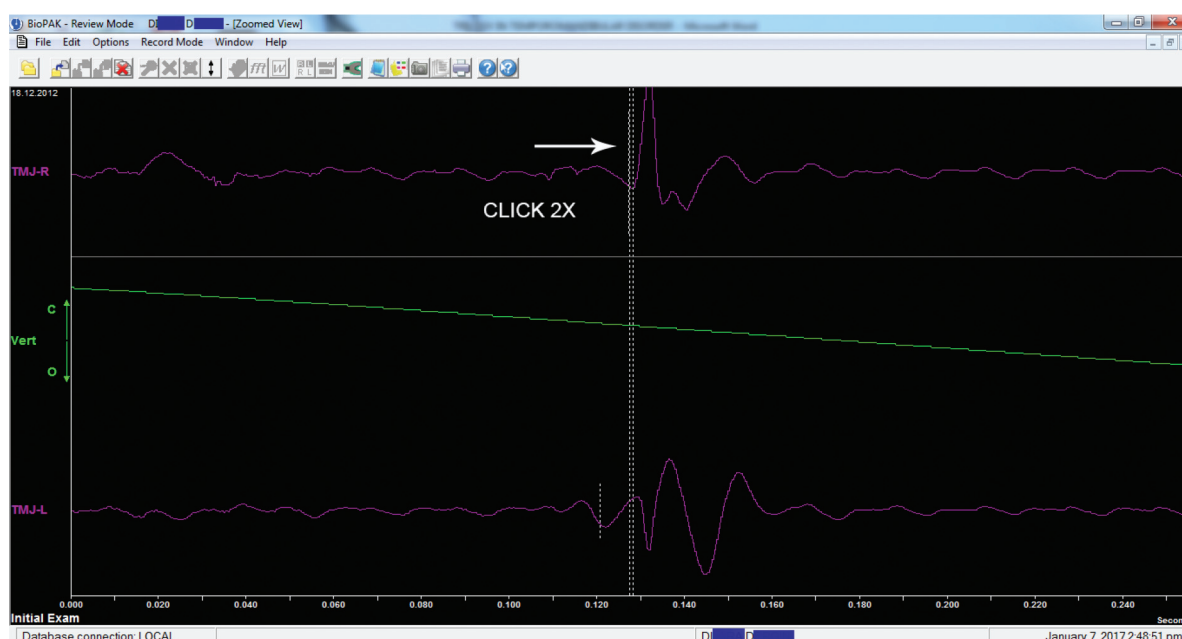


Figure 3. Click-type TMJ signal, TMJ signal (by) frequency of click sound followed by crepitation sound starts. Crepitation wave is shown on the left TMJ.

In **Figure 4**, max mouth opening is 45 mm, and a click sound is spotted around 30 mm. The click sound is located just before the eminencia.

Another important frequency type is crepitation: (**Figure 5**).

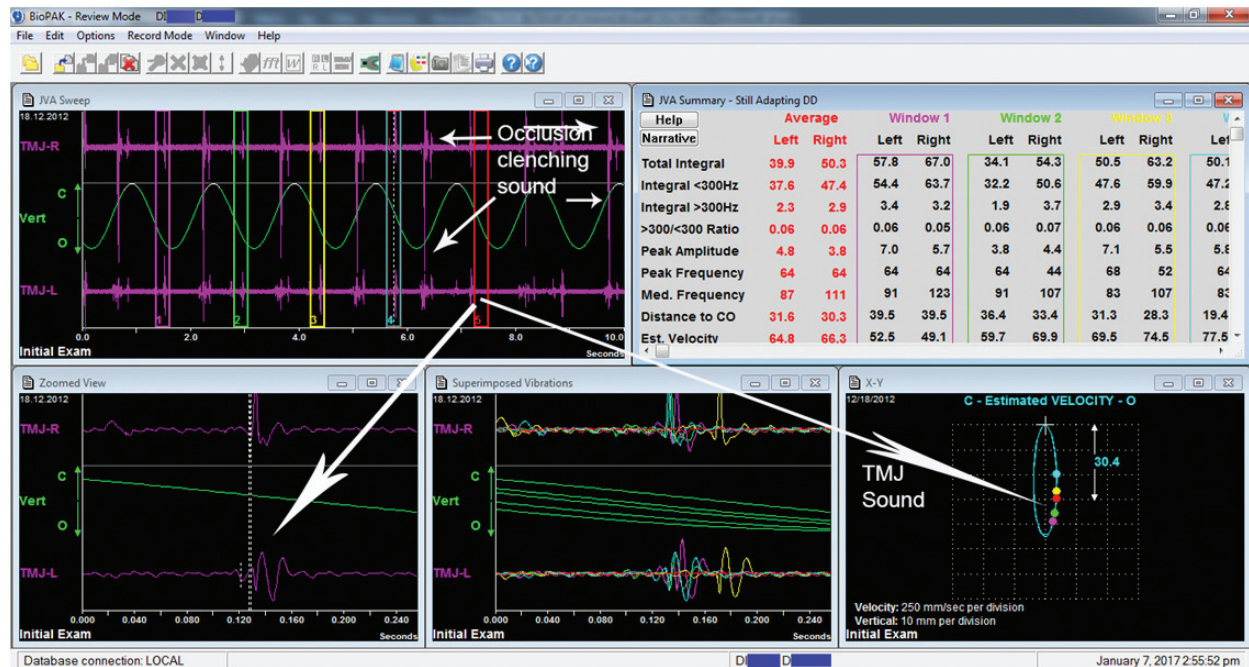

Figure 4. After six cycles of frequencies, average level of the click sound is around 30.4 mm of this patient who has a mouth opening of 45 mm. Location of the click sound is around the anterior part of the glenoid fossa. In this case, crepitation wave followed by the click sound must be considered an aggravation of the problem.

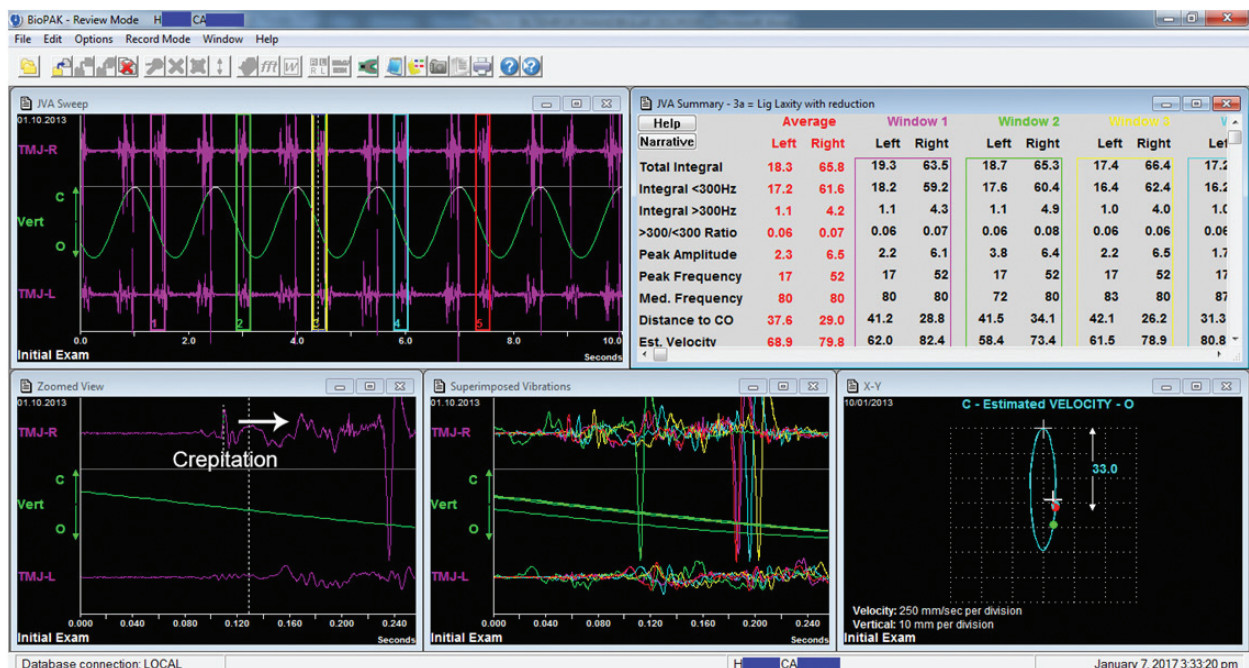

Figure 5. Crepitation wave is located just before a click frequency. It is located at the opening distance of 33.0 mm, where the patient's maximum opening distance is 49 mm.

2. How can we detect Temporomandibular joint sounds?

We can detect the temporomandibular joint sounds using frequency accelerators. An accelerator is neither a microphone nor an ultrasound; it is a typical sound receptor. In **Figure 6**, a typical sound accelerator is shown designed by Bioresearch Inc. (Milwaukee, USA).

The overall accuracy of clinical testing for TMD, using both auscultation and palpation, is 43% [53]. Vibration sound analysis procedure aids in diagnosis and thus can be helpful in treatment decisions (**Figure 7**).

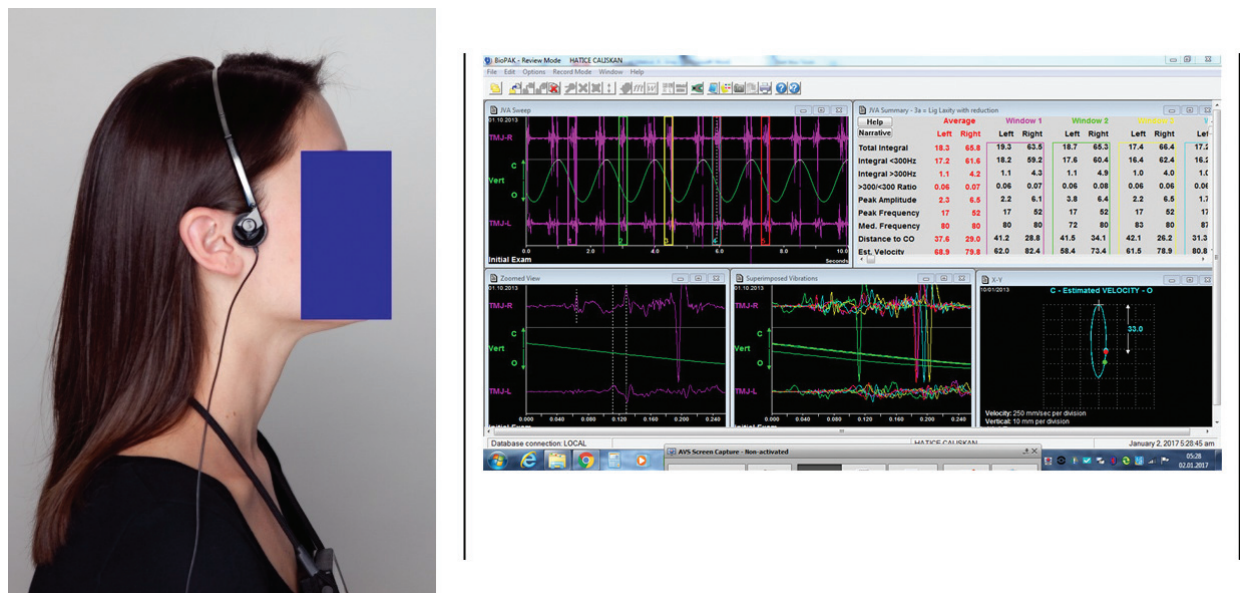


Figure 6. Research shows that experienced clinicians correctly diagnose the status of the TMJ less than 50% of the time. Inexperience can only increase this margin for error.

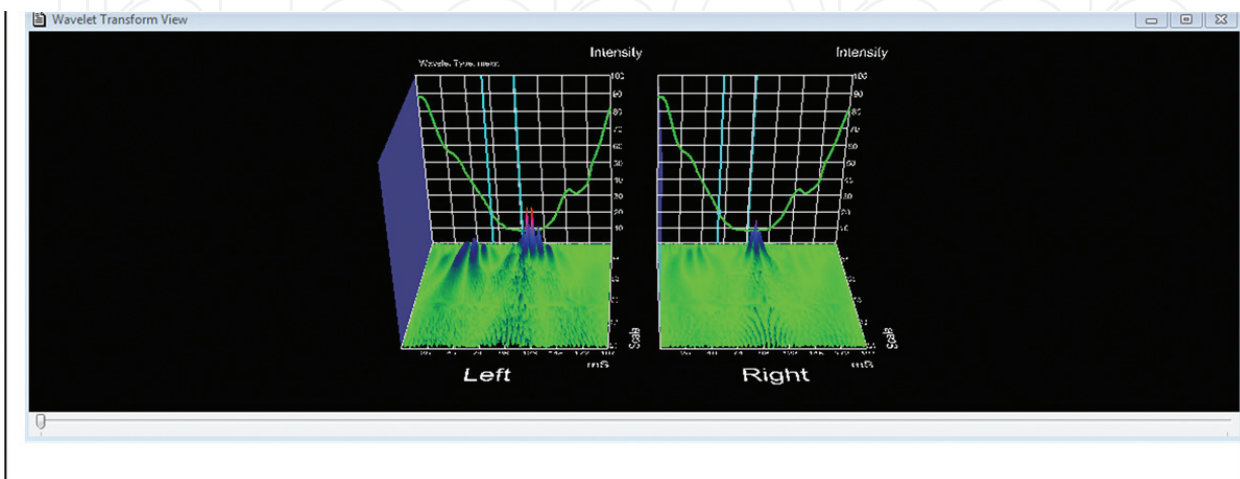


Figure 7. Wavelet transform viewer of a patient.

3. Clinical application of the joint vibration analysis

Condylar pathology is linked to articular surface degenerations [54]. Joint vibration analysis tests are helpful for the evaluation of the significance of joint sounds and can help us decide whether the condition is a progressive or degenerative one. Research shows that experienced clinicians correctly diagnose the status of the TMJ less than 50% of the time [53].

According to the Akin et al. [51],

1. Click: very short duration with high amplitude peaks,
2. Click with crepitation: a short duration click followed by multiple low amplitude peaks,
3. Hard crepitation: short duration, medium or high amplitude multiple peaks in low-frequency range,
4. Soft crepitation: long duration, low amplitude, multiple peaks that cover the whole frequency range.

The evaluation can be made according to the data mentioned above or a special table (suggested by Bioresearch Inc., Milwaukee, USA) is shown in **Figure 8**, which is useful in clinical practice.

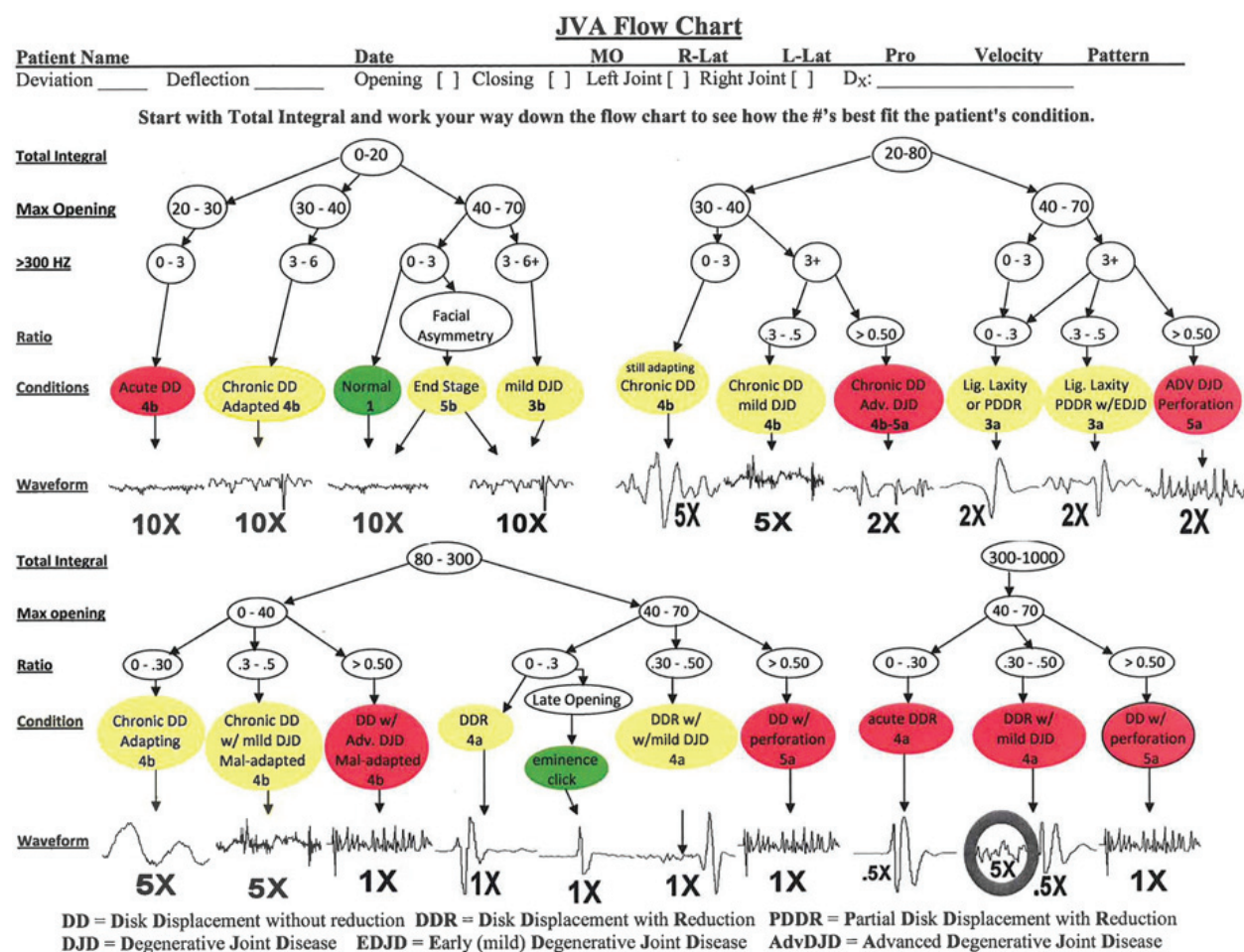


Figure 8. Clinical evaluation chart suggested by Bioresearch Inc., Milwaukee, USA.

The following evaluations can be made with the JAVA analysis data:

1. DD = Disk displacement without reduction,
2. DDR = Disk displacement with reduction,
3. PDDR = Partial disk displacement with reduction,
4. EDJD = Early degenerative joint disease,
5. ADvDJD = Advanced degenerative joint disease.

Subgroups of these main groups can also be reached with the help of additional clinical findings.

Evaluation study must start with a total integral value found in the chart. Second stage is the maximum mouth opening value of the patient, measured between the distance of anterior lower and upper teeth. Overbite distance must be added to the measured mouth opening value. Lateral deviation distance also must be measured, as it will be evaluated in the examination. To properly assess temporomandibular sounds, joint vibration sounds should be assessed with the patient's mouth opening and closing movements.

Joints are located in the glenoid fossa at the maximum occlusion position of mandible and during the opening of the mouth, translation movement is accompanied by rotation movement. Joint vibration analysis must be calibrated with other clinical findings, such as the

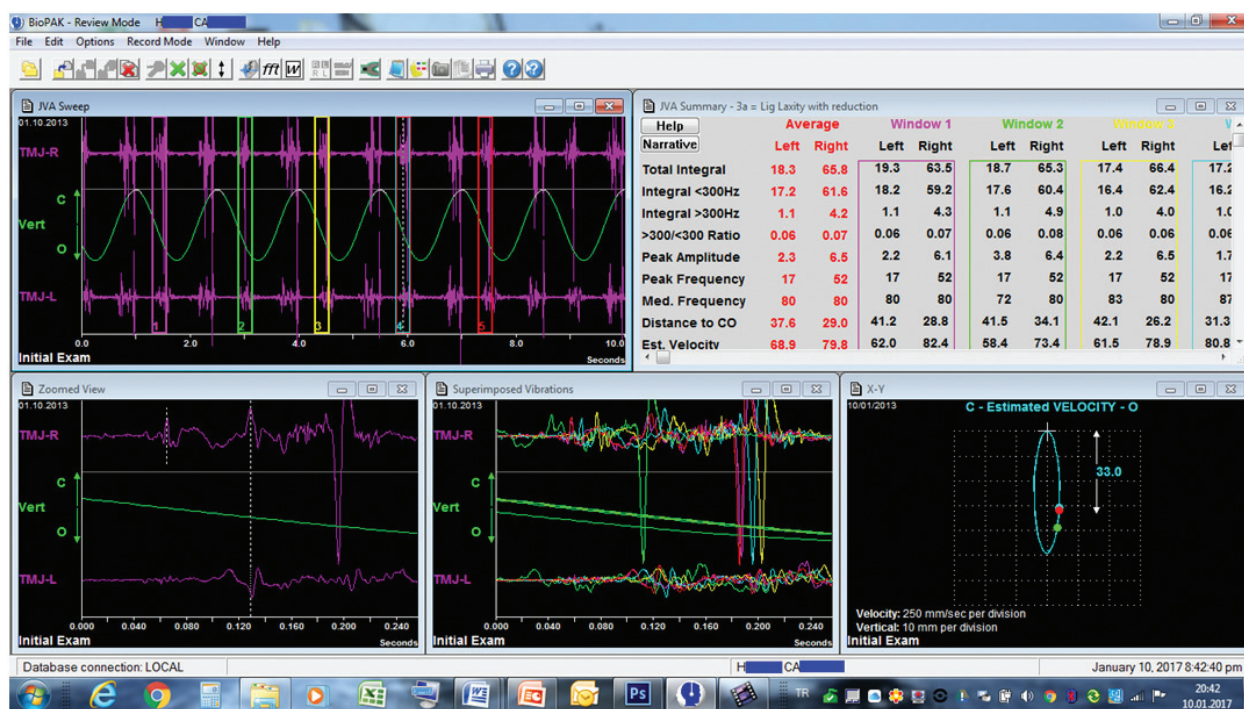

Figure 9. A patient's JVA record, total integral value has been found after capturing the frequencies of pathological sounds. According to the value of maximum opening distance, total integral value, integral >300 Hz and ratio of >300/<300 Hz value; in this case, "ligament laxity situation" may be considered.

maximum occlusion position. The patient is said to strike his teeth strongly, so at this moment a big and equal frequency in both side scan be spotted. This is the maximum occlusion position, and other intermediate frequencies indicate deterioration in the joint (**Figure 9**).

Case No.1.

Patient D.Y. 24 years old, Female (*History of the Patient, translation from her voice record*).

My name is D...Y.... Sounds coming from my joint, especially after lunches it started 4 months ago, a tooth extracted from here (*showing left side her face*), I think this is the reason of my problem ... I had it treated, because of a problem here..... Dr. xxxx made the extraction procedure, after the extraction great possible, I heard some cracking sounds. I cannot eat. When I eat something I hear a click sounds, I also have headaches.

“Clinician’s Question: When you have your headache?”

Around afternoons, but not too strong, I mean I hear only click sound. It comes from my left side, from my left joint; tooth extraction was made on that side. I have no more pain, only there is click sound *“click (click sound)”*. Oh! I want to add something more, I am in orthodontic treatment since the last year.

The patient’s JVA record results as follows (**Figures 10 and 11**):

We must consider the **Left Joint** as problem. If we apply the numerical data to JVA flow chart as follows:

	Average		Window 1		Window 2		Window 3		Window 4		Window 5	
	Left	Right	Left	Right	Left	Right	Left	Right	Left	Right	Left	Right
Total Integral	47.3	39.8	50.6	41.9	63.9	54.9	49.2	33.4	35.7	26.2	33.4	32.2
Integral <300Hz	39.4	31.5	42.2	32.0	52.8	43.0	41.3	25.0	30.2	20.1	27.7	26.2
Integral >300Hz	7.8	8.4	8.3	9.9	11.1	11.9	8.0	8.4	5.5	6.1	5.7	6.1
>300/<300 Ratio	0.20	0.27	0.20	0.31	0.21	0.28	0.19	0.34	0.18	0.30	0.21	0.23
Peak Amplitude	2.52	4.04	2.81	4.61	3.44	5.52	2.93	3.53	1.98	3.21	1.94	3.30
Peak Frequency	100	56	124	56	85	56	85	51	100	51	95	56
Med. Frequency	134	100	139	95	139	100	139	114	134	109	134	95
Distance to CO	22.2	22.2	37.0	37.0	26.2	26.2	7.2	7.2	1.0	1.0	38.9	38.9
Est. Velocity	39.0	40.3	36.0	37.9	77.2	80.3	60.9	63.7	-25.6	-25.6	10.0	10.0
Max. Opening	39											
Lat. Deflection	0											
Initial Exam 2												
JVA Summary - Still Adapting Chronic DD / 4b												

Figure 10. The patient’s JVA data show that the total integral value of the left joint is bigger than the right joint. This value is 47.3 and indicates a problem. Integral>300 Hz value is 7.8 and ratio value is 0.20.

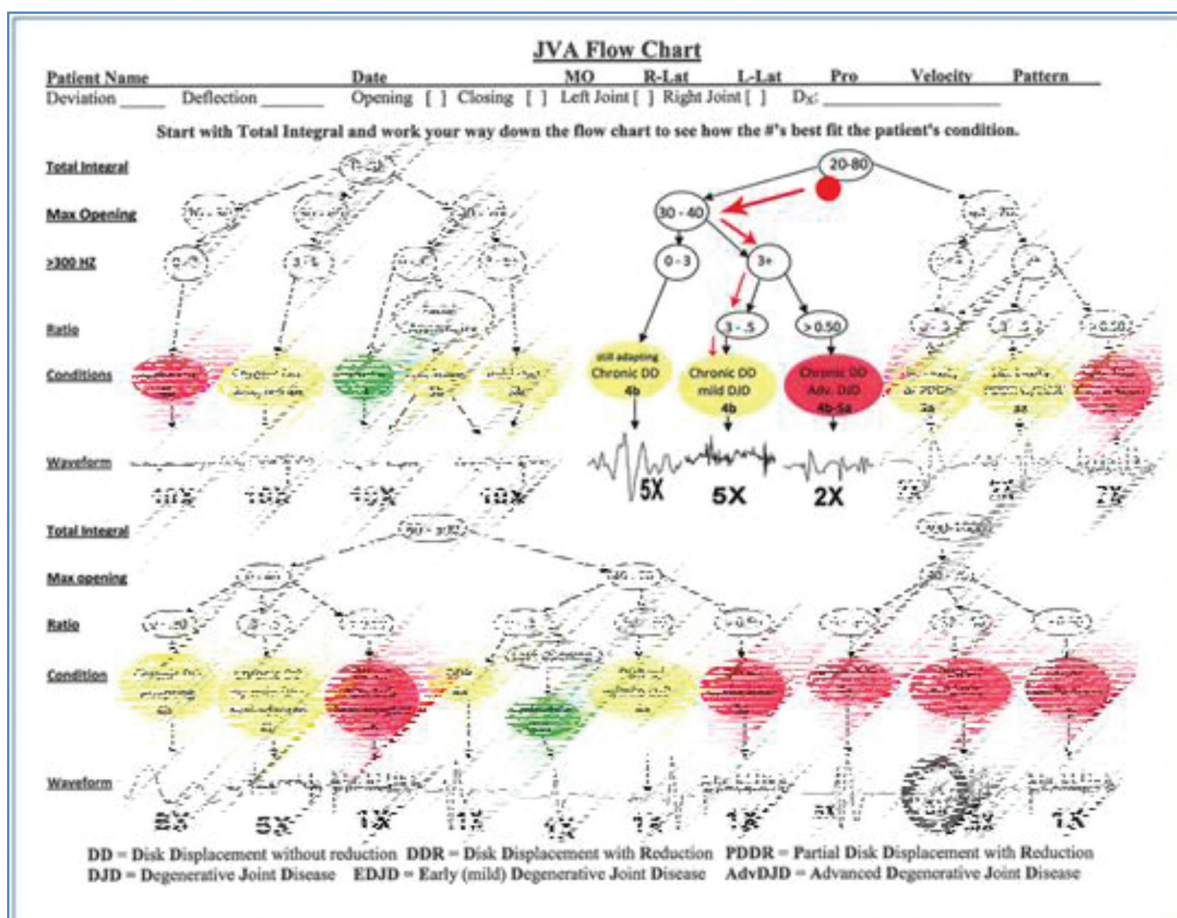


Figure 11. Total integral value is 47.3 (see Figure 10), and this value places between the range of 20 and 80. Second step maximum opening mouth is 39 mm, and this value is between the range of 30 and 40. Third step is "integral >300 Hz" value which is 7.8, and it is located in the 3+ area. Finally, we look the value of "ratio" which is 0.20 of this patient, and it is located in the range of 3–5. As a result, "Chronic disk displacement or mild degenerative joint disease (Piper's 4b)" must be considered for this patient. Other clinical examination results (extra-oral examination, radiographic findings, etc.) must be combined with the result of JVA.

4. JT mastication analysis

Chronic temporomandibular disorder (TMD) patients, specifically those with severe symptomatology, shows a reorganized activity, mainly resulting in worsening functional performances [55]. Mastication is one of the most important vital functions of human being. Occlusal disorders can cause people to swallow food without chewing enough. Shimshak and DeFuria showed that TMD patients have, on average, 112% more digestive complaints (in terms of the cost of medical treatment) than a comparable normal group [56]. High-level masticatory performance is the main purpose of dental restorative studies. Chewing pattern is linked to occlusal relationship, it may vary with the occlusal model [57, 58]. Studies have focused on two main types of motions:

- physiologic (functional) movements which occur during chewing
- nonphysiologic movements such as maximal opening/closing or lateral excursions.

Nonphysiologic movements can be difficult to reproduce (due to conscious actions of the patient) and are questionable indicators of the functional state of the stomatognathic system. During mastication, the angle of the mandible as it approaches occlusion is quite different from that occurring with lateral excursions from centric occlusion. Interferences identified in lateral excursions may or may not represent functional interferences during mastication. For these reasons, chewing motions (which are subconscious, physiologic, and reproducible) are considered to be the most applicable for a clinical classification of TMD [59].

The fundamental quantity in mastication analysis is the chewing cycle, representing the motion of the mandible from occlusion to open and from open back to occlusion. The turning point (*TP*) is defined to be the most open position of the mandible in the middle of a chewing cycle. It averages about 2 mm laterally toward the working (chewing) side and normally 16 mm open from centric occlusion. The terminal chewing position (*TCP*) is defined as the most closed position of the mandible as it approaches occlusion during mastication. There may be a difference between *TCP* and maximum intercuspal position of between 0 and 5 mm, default value being 0.3 mm. This number determines the vertical thresholds of each chewing cycle in relation to the *TCP* of each cycle. For example, a value of 2 will cause the start of opening and ending of closing of a given cycle to be positioned a distance of 2 mm below the *TCP*. The value can range from 0.0 to 5.0 mm (default is 0.3). Swallowing occurs after every 5–10 chewings approximately. Mandible is in maximum intercuspal position during swallowing.

There are great differences between orthodontically Class I normal occlusion type and Class II malocclusion or Class III malocclusion chewing patterns. When we look at the breakdown of treatments, we can see many changes in the magnitude of chewing. The analysis of the patterns of chewing in the onset of treatment and later in the course of treatment will provide us concrete information on the success of the treatment [59–61]. Nowadays, though not routinely used, especially the measurement of chewing performance is important in terms of trying to measure the success of the treatment by comparing the values before and after treatment.

A classic pattern of chewing is basically examined in three parts [62, 63] (**Figure 12**):

1. Opening phase,
2. Closing phase, and
3. Occlusal phase.

There are various methods and tools for the examination of masticatory movements [34, 48, 64]. These methods can be grouped under three main headings [65]:

1. Masticatory movement analysis,
2. Masticatory muscles analysis,
3. Analysis of mastication product (analysis of the food).

However, chewing movements may also be useful in investigating temporomandibular disorders [66]. Masticatory analysis history is based on the beginning time of modern dentistry. In early studies, a video recorder has been used for taking serial pictures of chewing pattern. A rounded white paper part was attached to the patient's chin, and serial pictures were taken from front of the face of the patient. In this system, a magnet attached onto the lower anterior teeth (**Figure 13**) and using a software, record video movie of movements of the magnet together with the mandible (**Figure 14**).

To record chewing patterns, a small magnet is placed on the vestibular side of the lower anterior teeth using a sticky wax (**Figure 13**). A headgear containing bilateral electromagnetic

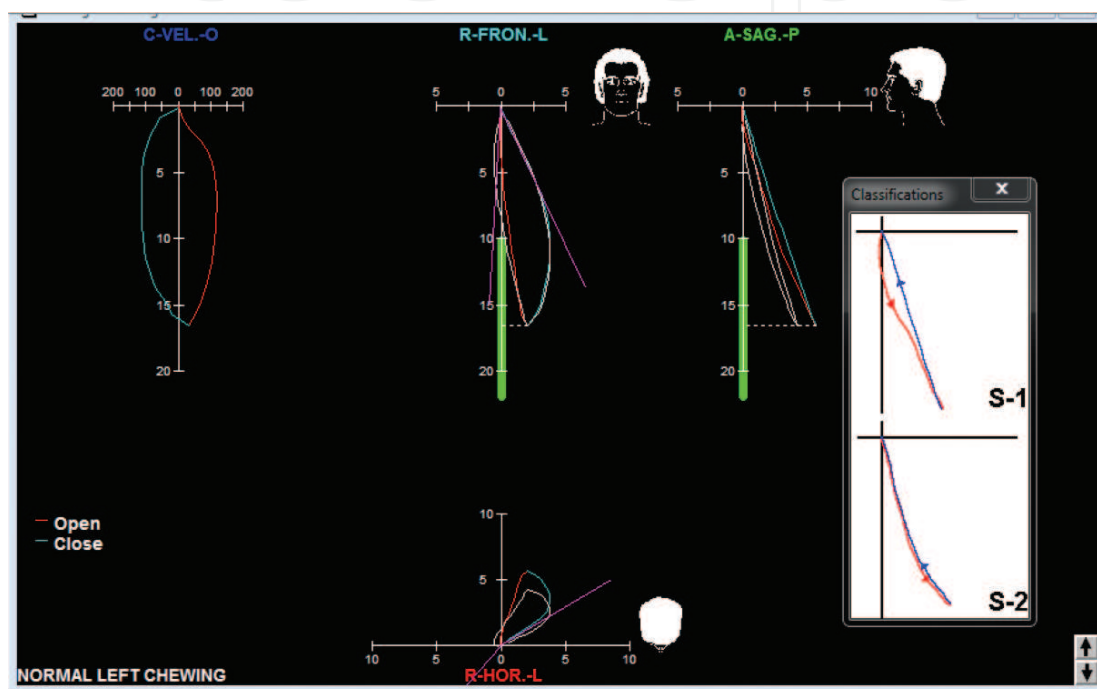


Figure 12. A chewing pattern consists of three different phases: Opening (red), closing (blue) and occlusal phase (0 point in the diagram). From the opening phase to the closing phase, basically there are three parts in one cycle of mastication. Returning from opening phase is called a “turning point.”

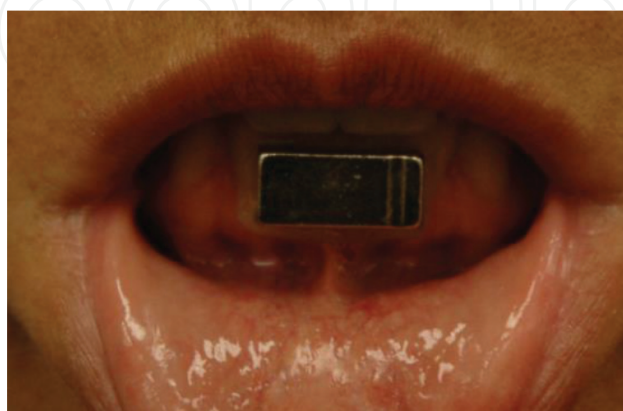


Figure 13. Placing of magnet.

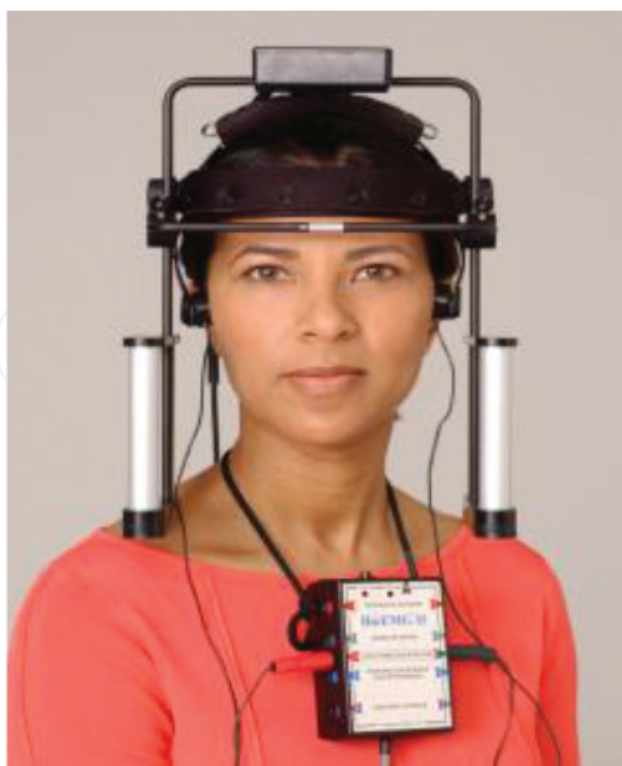

Figure 14. Head parts of Bio-JT (Bioresearch Inc., USA).

controller mechanism senses “xyz” position of the magnet within an accuracy of 0.1 mm. After aligning headgear, using its screw movements of the magnet is recorded (**Figure 14**). Besides the analysis of mastication, this gear can be used to measure and record the range of motions of the jaw during speech, distance of the freeway space (with extreme accuracy), velocity and bite registrations. We can see exact positions of the mandible if we use this equipment simultaneously together with the joint vibration analysis (JVA).

The basic parameters of mastication analysis are given as follows:

5. Starting cycle

This is the first chewing cycle to display and analyze. The cycles before the designated starting cycle are neglected. Starting cycle is the default cycle. The first few cycles may be disregarded as they are more often inconsistent.

5.1. Maximum number of cycles to analyze

The maximum number of chewing cycles are averaged to calculate the average CP. It also determines how many cycles will be taken into account in the sweep and segmented XY views. Maximum number of cycles are variable between 10 and 30 (default value of number of cycles is 15).

5.2. Occlusal threshold (OT)

This number determines the vertical thresholds of each chewing cycle in relation to the *TCP* of each cycle. Occlusal threshold is the start and the end point of a cycle. For example, a value of 1.0 will cause the start of opening and end of closing of a given cycle to be positioned a distance of 1.0 mm below the TCP. The value can range from 0.0 to 5.0 mm. (default is 0.3 mm).

5.3. Standard deviation limit

The number of standard deviations is used as a limit when validating cycles. If a given cycle differs from the average of all cycles by more than this amount, it is marked as deviated and not correct. The value can range from 1.0 to 3.0 mm (default is 2.0).

5.4. What can be read from masticatory analysis?

There is a sample screen (the record has been taken from the sample record of User Manual of Bioresearch Inc., USA) [94] in **Figure 15**:

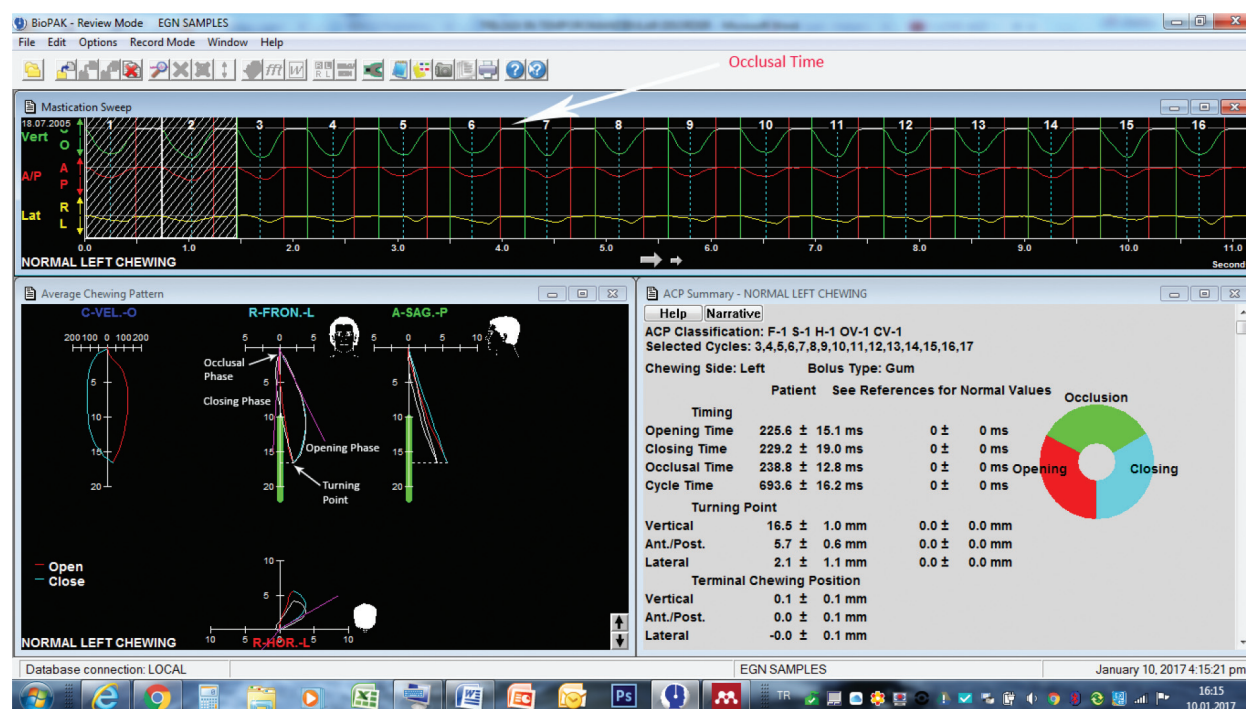


Figure 15. Mastication narrative: The patient chewed a bolus(gum) on the left side, and 15 chewing cycles were used to average the chewing pattern. The average opening time was consistently short at 225 ± 16 ms. The average closing time was consistently short at 232 ± 20 ms. The average occlusal time was consistently short at 240 ± 13 ms. The average cycle time was consistently short at 697 ± 17 ms. The average vertical turning point consistently occurred at 16.5 ± 1.0 mm from centric occlusion. The average anteroposterior turning point consistently occurred at 5.7 ± 0.6 mm from centric occlusion. The average lateral turning point consistently occurred at 2.1 ± 1.1 mm from centric occlusion. The average maximum lateral width of the chewing cycles was consistent at 4.2 ± 0.6 mm.

The following record is taken from a patient using full denture in the TMD Clinic of Istanbul Aydin University Dentistry Faculty (**Figure 16**):

In the research, studies of masticatory movements have been focused on following the two main types of motions:

- physiologic (functional) movements which occur during chewing
- nonphysiologic movements such as maximal opening/closing or maximum lateral excursions-border movements.

Average physiologic pattern of masticatory movements (**Figures 15 and 16**) is produced by a healthy stomathognathic system. It is result of a reflex mechanism and controlled by mechanoreceptors and proprioceptors located in periodontal ligaments [67]. Moreover, premature contact in masticatory occlusion may stimulate neural mechanisms in masticatory system (**Figure 17**).

The production of nonphysiologic movements otherwise is very difficult. There is also a quite difference between approaching angle of mandible in mastication and the angle of lateral excursion to the maximum intercuspal position. For these reasons, subconscious, physiologic and reflex chewing motions are considered to be the most applicable for a clinical classification of TMD. Mastication is a physiologic movement, but grinding of an empty mouth is a para-functional movement. Masticatory movements start as a conscious movement and continue as reflex [69, 70]. Physiologic masticatory movements are controlled and protected by the neuromuscular system [67].

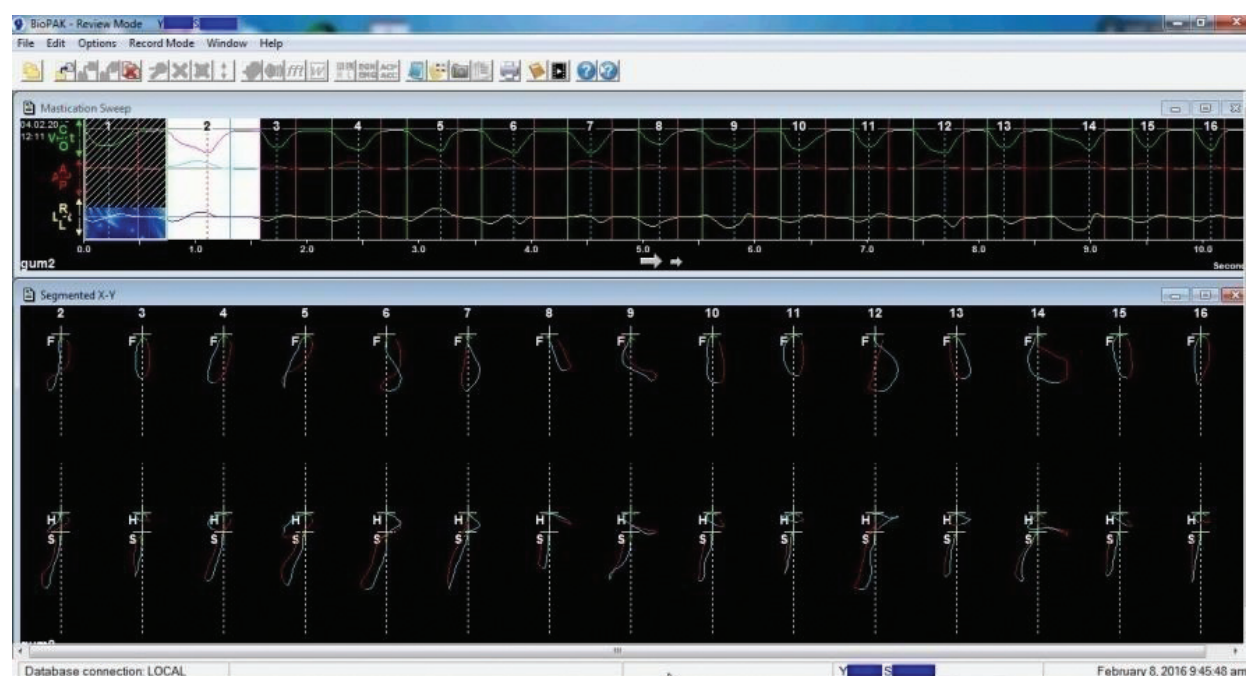

Figure 16. Chewing patterns of a CAD-CAM full denture patient.

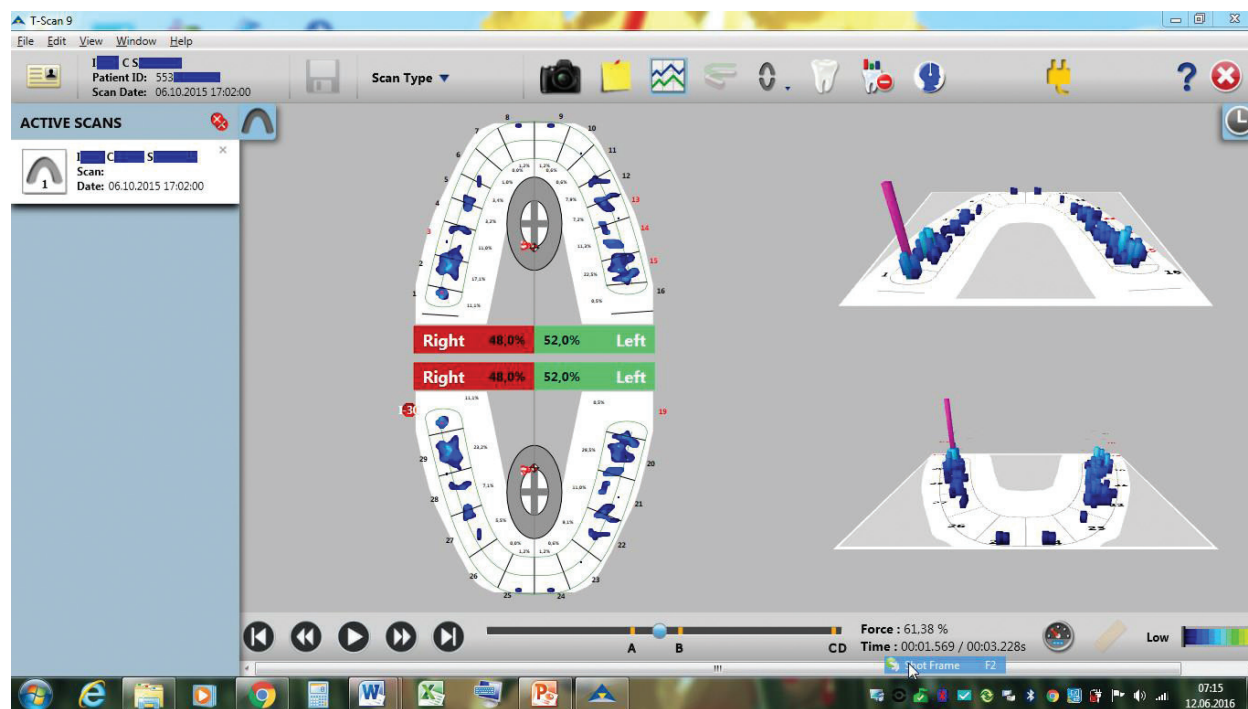


Figure 17. Discrepancy in masticatory occlusion is a trigger mechanism for the muscle pain dysfunction syndrome. Premature contacts may stimulate neural mechanism in masticatory MPD syndrome will be developed if premature contacts are not removed from the occlusion. We use also T-scan occlusal analysis system to find and remove the premature contacts from masticatory occlusion [68].

Total quantity in mastication analysis is the chewing cycle, representing the motion of the mandible from occlusion to open and from open, back to maximum masticatory occlusion. The turning point (TP) is defined to be the masticatory open position of the mandible in the middle of a chewing cycle. It averages about 2 mm laterally toward the working (chewing) side and nominally 16 mm open from centric occlusion. The terminal chewing position (TCP) is defined as the most closed position of the mandible as it approaches occlusion during mastication (masticatory occlusion).

Chewing rhythm is closely related to the patients' average chewing pattern (ACP). Average values of parts of chewing pattern are as follows:

1. Opening time is around 250 ms (± 50 ms), (one-third of total chewing cycle approx.)
2. Closing time is around 220 ms (± 50 ms), (one-third of total chewing cycle approx.)
3. Occlusion time is around 200 ms (± 50 ms), (one-third of total chewing cycle approx.)

We must consider a problem regarding to the joints if cycle time, opening, closing and occlusal time have an unusually longer or shorter value than normal.

Masticatory movements end in an occlusal phase. In an occlusal movement, lower teeth glide on upper teeth's occlusal surface and stop at top maximum contact position of masticatory movement. This is not a maximum force position because maximum force position is not a functional situation but a conscious action. Maximum top position of masticatory movement can also be named as "reverse turning point" (RTP) of masticatory movement. Upper and

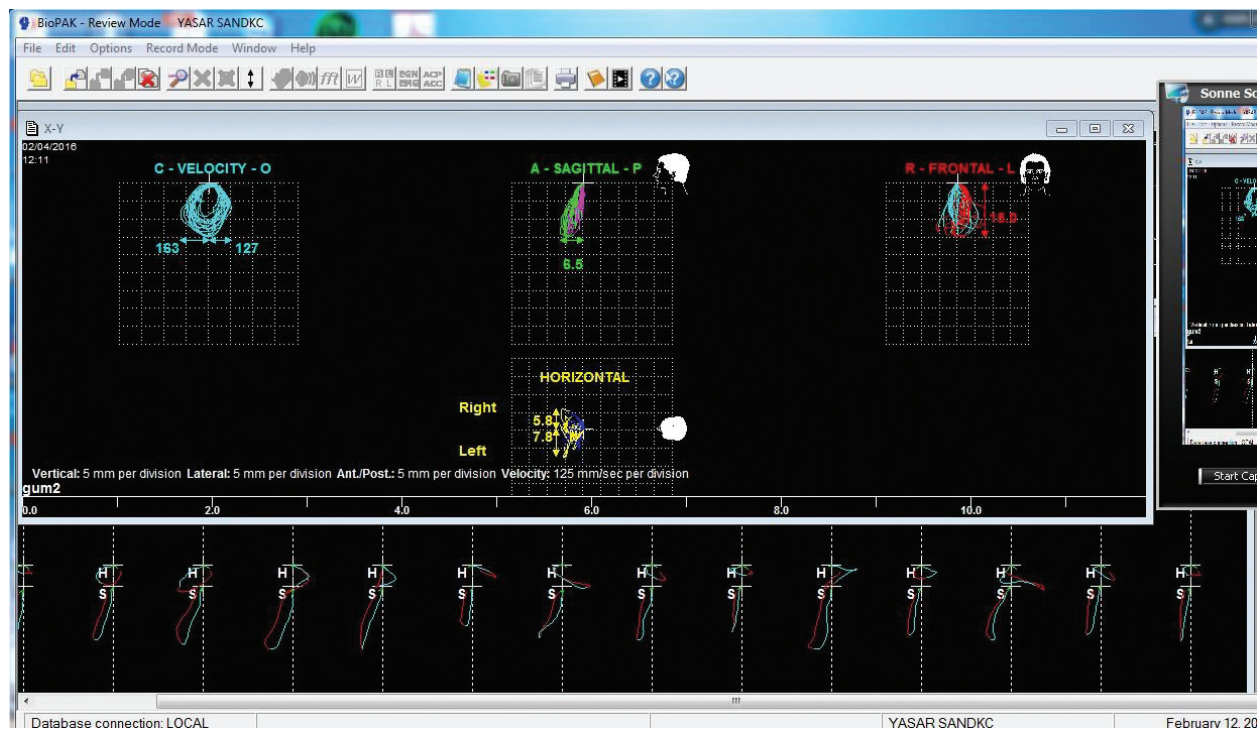


Figure 18. Opening phase of mastication starts from reverse turning point.

lower teeth are contacted slightly, or not any contact, and opening phase of mastication starts from this point. RTP point is illustrated in Figure 18:

Reverse turning position is not a harmful situation. Furthermore, the CNS reflex (Jaw Jerk Reflex) will form an early RTP point and will escape from excessive contact. This point is variable according to the harmonic masticatory movements of mandible. Normally, this

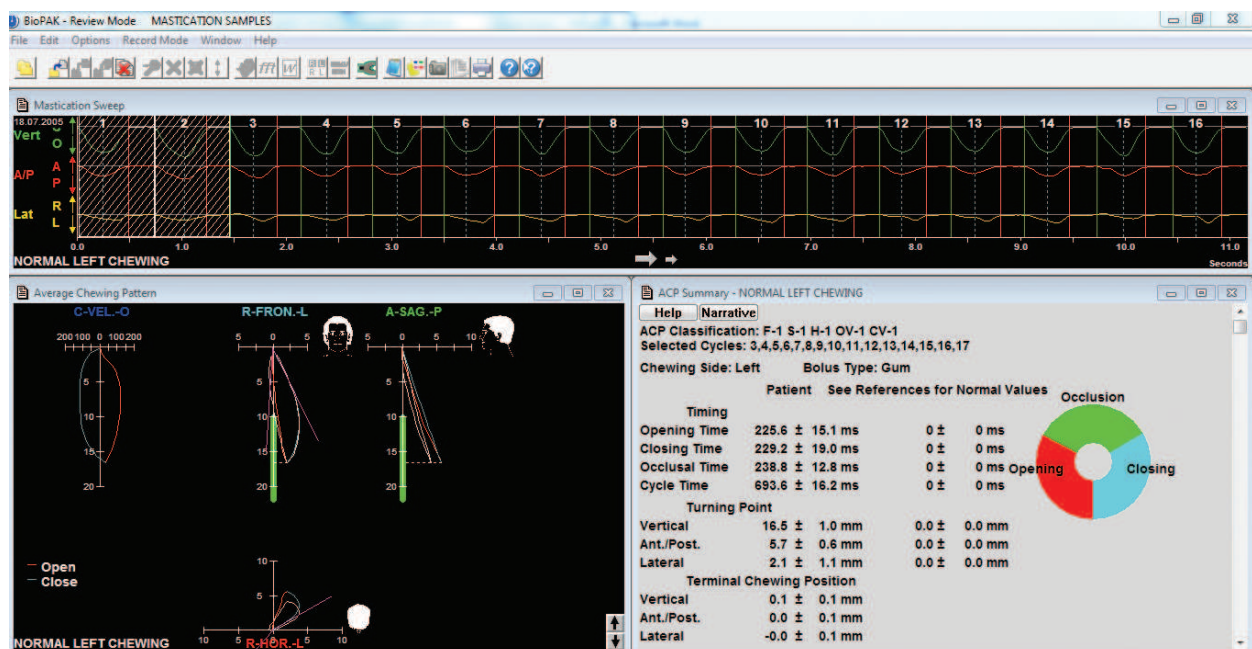


Figure 19. The chewing record formed by RTP, and the pattern of the chewing movement was also affected.

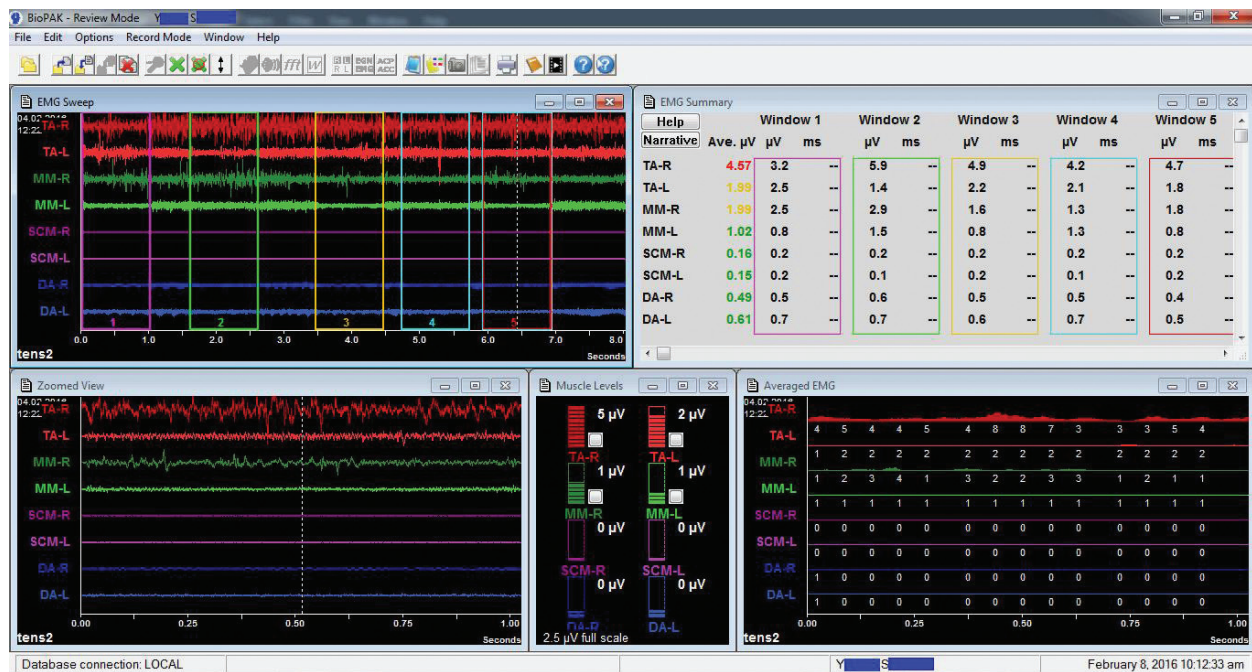


Figure 20. EMG record of a patient with RTP; right temporal and masseter muscles have hyper-activities. Right side of the joint will be under overload. At the beginning, this situation may not be harmful, though in time the condition may lead to impairment of the right-side condyle.

neuromuscular behavior will protect the teeth and will not cause a problem in the joints. But if it lasts for a long time, the working side condenses will be under constant overpressure, which will cause the working joint to eventually break down. The early occurrence of the RTP point should be seen as an adverse symptom that should be corrected clinically for joints. EMG records (**Figures 20**) of unbalanced muscle force application with the chewing record (**Figure 19**) of a person in this situation can be seen below:

6. Computerized occlusal analysis

“To look at the occlusion and to see the occlusion.”

Occlusion analysis is one of the most complicated and sophisticated areas of dentistry. According to Prof. Dr. Senih Calikkocaoglu* “Occlusion is a phenomenon related with bones, teeth, muscles and neurons.” It has four main key points:

1. Mandibular movements: controlled by joints, muscles and neural receptors,
2. Upper and lower teeth: end point of the movement - like a stopper, System likes a nut-cracker (**Figure 21**).
3. Masticatory muscles: apply force in a harmonized manner,
4. Neural system: controls the magnitude, duration and direction of forces.

*Prof. Dr. Senih Calikkocaoglu, Retired from Dentistry Faculty of Istanbul University, died in the year of 2016.

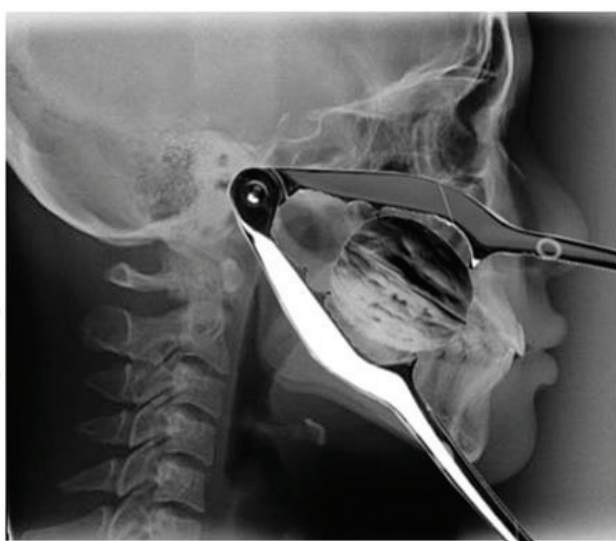


Figure 21. The system is like a second class leverage system and is similar to a nuts breaker. Masticatory muscles apply the force in a harmonic manner, joints bear forces which applied by muscles and the neural system controls the magnitude, duration, direction and peak time of that forces.

There are many dental disturbances to be linked to the occlusion: bruxism, attrition, erosion, abfraction, muscle pain dysfunction syndrome, TMJ problems, and so on, are typical examples [5, 13, 24, 61, 71–76]. Whether these disorders are related to occlusal discrepancies is the subject of occlusal analysis.

Occlusion analysis is simply the analysis of all contact positions based on the time vector during closing and departing of upper and lower teeth. Occlusal analysis gives to the clinician teeth position, relative force and time data. Additionally, occlusion analysis gives the sequential time and relative force data of occlusion. Occlusal analysis data present potential to make chance of commentary on pathological reasons of stomatognathic system. Occlusal papers and/or another occlusal indicators do not have that kind of ability.

The most disturbing situation about occlusion in dentistry is premature contact. As a dentist, we make restorations, bridges, crowns, orthodontic treatment, tooth extraction, and so on, and we may change the occlusion. In proprioceptive mechanism, premature contacts detected by mechanoreceptors in the periodontal ligaments may be harmful for teeth and other structures of stomatognathic system. Normally, temporomandibular joints are not affected immediately by this irregularity. During movements of the mandible, the inputs to muscle spindles and Golgi tendon organs change. But their outputs are differently related to their respective inputs [77]. The reflex control of the mandible is of vital importance for the normal masticatory functioning of humans. Excitatory jaw reflexes are responsible for the rapid reaction to external stimuli to the masticatory muscles [67], while inhibitory jaw reflexes protect the system when sudden loads are applied to the muscles. The fine coordination of the mandibular function is the result of the balanced activation of these reflexes together with the activity of the masticatory muscles, the temporomandibular joints and the associated tissues [78]. *Premature contacts are one of the most prominent jaw jerk reflex triggers* [68]. The jaw jerk reflex is another protection control mechanism of the stomatognathic system, but it has slightly more rapid and more reflex characteristics than

the RTP mechanism of the masticatory movements. After the first reaction, the Jaw Jerk Reflex turns to a RTP mechanism [79]. As we mentioned in the Mastication Analysis section of this chapter, if the reasons for the jaw jerk reflex persists for a long time, the working side condenses will be under constant overload and will cause the working joint to break down.

“Best Occlusion Analysis starts from Temporomandibular Joints” Peter Dawson [75, 80].

For many years, scientists created many theories on dental occlusion and its links to the occlusal problems and temporomandibular pathology. Occlusal theories have been focused on two principal matters:

1. Analysis of occlusion using simulation tools and articulators.
2. Working on the chairside, the computerized occlusal analysis technique.

There are many advantages in the second method. In-vitro occlusion analysis techniques are extremely difficult and long procedures. The main advantage of the first method is that it does not contain any risks, and dentist can work under very controlled conditions. But there are a lot of question on the details of the procedures; traditionally, more than one visit is required to complete analyzing and treatment. Working on stomatognathic system needs to be considered together with the neuromuscular mechanism. Articulators may be most useful tools for the production of dental restorations, but they cannot simulate the neuromuscular mechanism [81].

Computerized occlusal analysis systems are the fastest and safest way to check the dental occlusion. If not intervened, all occlusal contacts can be controlled in detail and sequentially together with relative force info. Analysis of the occlusion can be performed under maximum physiological conditions. Each intervention will be perceived by the neuromuscular mechanism, and the movement will not be a physiological function. Computerized occlusal analysis systems give us control of extreme physiologic occlusion [35, 82–86]. Actually, occlusal papers and similar indicators (wax, powder, shimstock, foil, etc.), which using intraoral indicators, are also not proper materials for occlusal diagnostics [87].

Because contact “hold” resistance levels are subjective. Therefore, it is a difficult guiding factor to utilize when selecting contacts to adjust the demonstrated variable forces are within occlusal contacts. Because shim stock foil does not mark the selected teeth, the articulating paper markings are the primary guide for the operator when selecting which contact(s) require adjustment.

It has been advocated in textbooks on occlusion [2, 3, 5–7] that mark area is a representative of the load contained within the mark. Legends to photographs depicting occlusal adjustment technique end results and paper mark appearance describe that large and dark marks indicate heavy load, and that smaller and light marks indicate lesser loads [5–7]. Additionally, the presence of many similar sized marks spread around the contacting arches is purported to indicate equal occlusal contact intensity, evenness, and simultaneity [1, 3].

Though occlusal indicators show prints of the end of the occlusion, they cannot provide important information such as which tooth tubercle is first in occlusion, which one is second or which one is last and the force differences between these points (**Figures 22**).

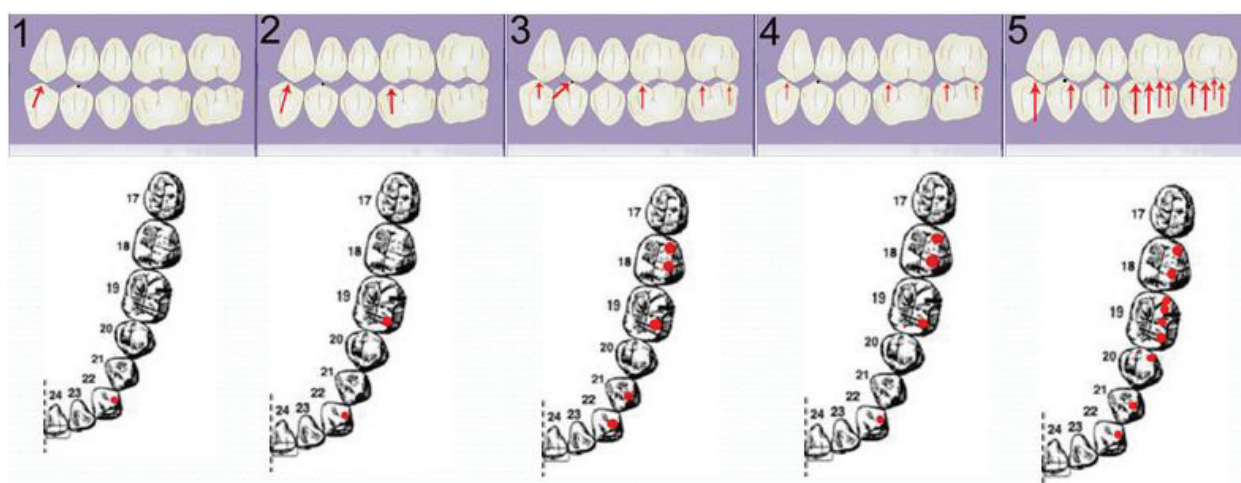


Figure 22. Occlusal indicators such as occlusion paper may first show contacts first followed by consecutive contacts, but we can only see the last picture and not the events that occurred before [88]. Which is first, second and last? Occlusal paper is like a stamp that shows the static photo of a last step.

Owing to the computer technologies developed in recent years, we now have the chance to examine the intraoral occlusion as detailed as possible.

Computerized occlusion is the system that can be best examined today without disrupting the neuromuscular mechanism of the occlusion [20, 23, 38, 39, 83]. In this method, dynamic information of all occlusal contacts that occur when the patient closes and opens mouth is recorded digitally. T-Scan computerized occlusal analysis system (COAS) is one of the most advanced devices in the market today (Tekscan Inc., Boston, USA.) It is a unique system that allows the occlusion to be recorded from the beginning to the end.

COAS basically consists of three main parts as follows:

1. Sensor,
2. Hardware: handle and computer,
3. Software.

The sensor used in the system is ultra-fine plastic with a thickness of 0.1 mm (0.004 inch). This thin **Figure 23** sensor does not change the neuromuscular pattern that defines the occlusion of the patient. When the patient bites the sensor, the mandibular functional movement is not changed. The occlusion phenomenon occurs physiologically and with the neuromuscular orientation of the patient at that time. Thus, the clinician can accurately see the functional occlusion at that time. **Figure 24** shows the sensor used in the T-Scan computerized occlusal analysis system.

Case No.2.

Patient S.S. Age: 68, Male.

The patient with headache around anterior temporal area for approximately 7 years, occurring usually on mornings due to clenching of his teeth. There was a click sound on left TMJ.




Figure 23. The T-scan sensor is an ultra-thin (0.004 inch, 0.1 mm), flexible printed circuit that detects your patient's occlusal forces. These sensors are made up of 1370 active pressure sensing locations for the large sensor (#2002 for the Novus Handpiece, and #2001 for the Evolution Handle), and 1122 pressure sensing locations for the small sensor (#2502 for the Novus Handpiece, and #2501 for the Evolution Handle). These sensing locations are referred to as "sensing elements" or "sensors." the "sensors" are arranged in rows and columns on the sensor. Each sensel can be seen as an individual square on the computer screen by selecting the 2D display mode (text is from company user manual, Teksan Inc. USA) [95] (**Figures 24 and 25**).

Radiographic (**Figure 25**) and intraoral examination: A remarkable abfraction detected and restored by fillings 3–4 times but the fillings dropped every time.

When the occlusal analysis was performed, disclusion time was found to be 0.48 s (**Figure 26**). Premature contacts identified after the evaluation of the occlusion. The premature contacts are eliminated using a fine diamond bur, and the disclusion time was reduced to 0.23 s. (**Figure 27**).

After equilibration of occlusion, composite restorations were performed on teeth with abfraction. For the next month, the patient was given another follow-up appointment. When he arrives a month later for his follow-up appointment; filling restorations are still standing. There was no headache, and the click sound was gone.

T-Scan records of before and after the occlusal stabilization of the patient are given as follows:

In the computerized occlusal analysis software, the graphic arc dimensions are automatically adjusted according to the size of the anterior teeth in routine clinical trials. (**Figure 28**).

However, if you need an in detail work and you need to see the occlusion in maximum precision you can choose to work with STL (STereoLithography) data. The great advantage of this method is that the tooth copies can be loaded automatically and individually. All teeth sizes are the same with the real dimensions. In this technique, upper and lower stone models are digitally scanned with an STL data ability scanner, and output data in the STL format are uploaded on the computer. Now, the clinician is able to analyze the occlusion in the real dimensions and locate the possible premature contacts precisely. (**Figure 29**).

Computerized occlusal analysis is currently the most powerful method of TMD clinics for the treatment of patients with muscle pain dysfunction syndrome [23, 68, 89, 90]. Especially with JAVA, it is now frequently used in clinical routine. Computerized occlusal analysis allows us to perform the following treatments [91]:

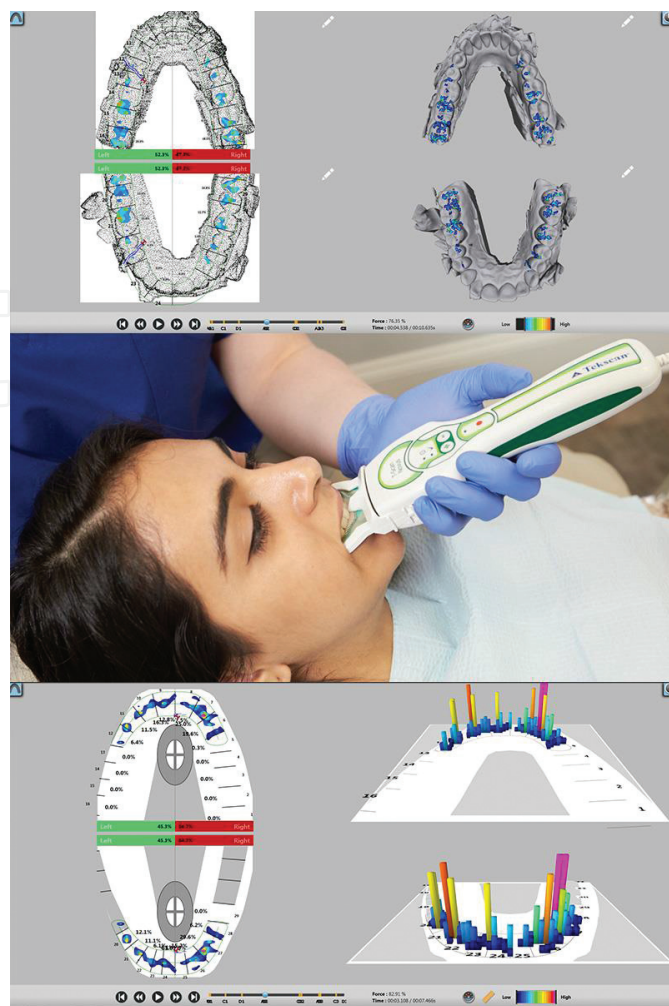

Figure 24. Application of computerized occlusal analysis system. In this case, patient's stone model was scanned and model's stl (STereoLithography) data were imported to the T-scan software. The occlusion analysis was performed on the real model's 3D image.

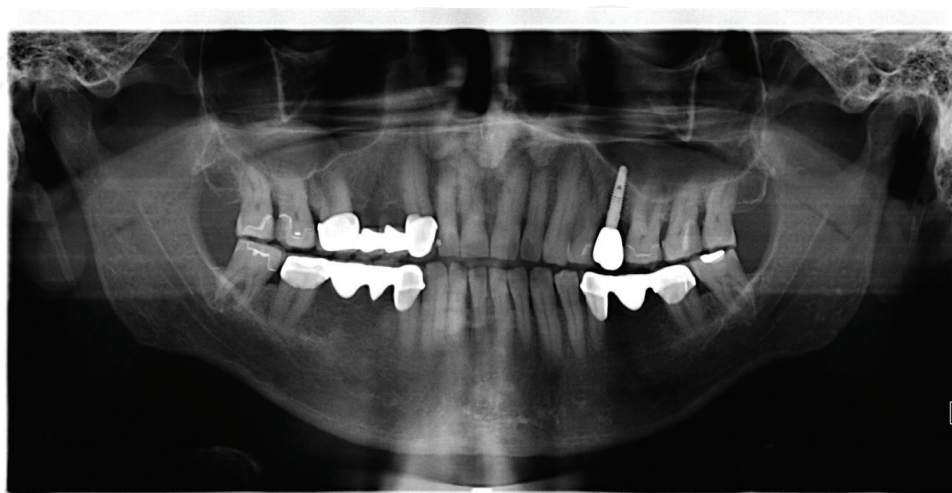


Figure 25. Panoramic X-ray of the patient. He has various restorations both the upper and lowers of the posterior area.

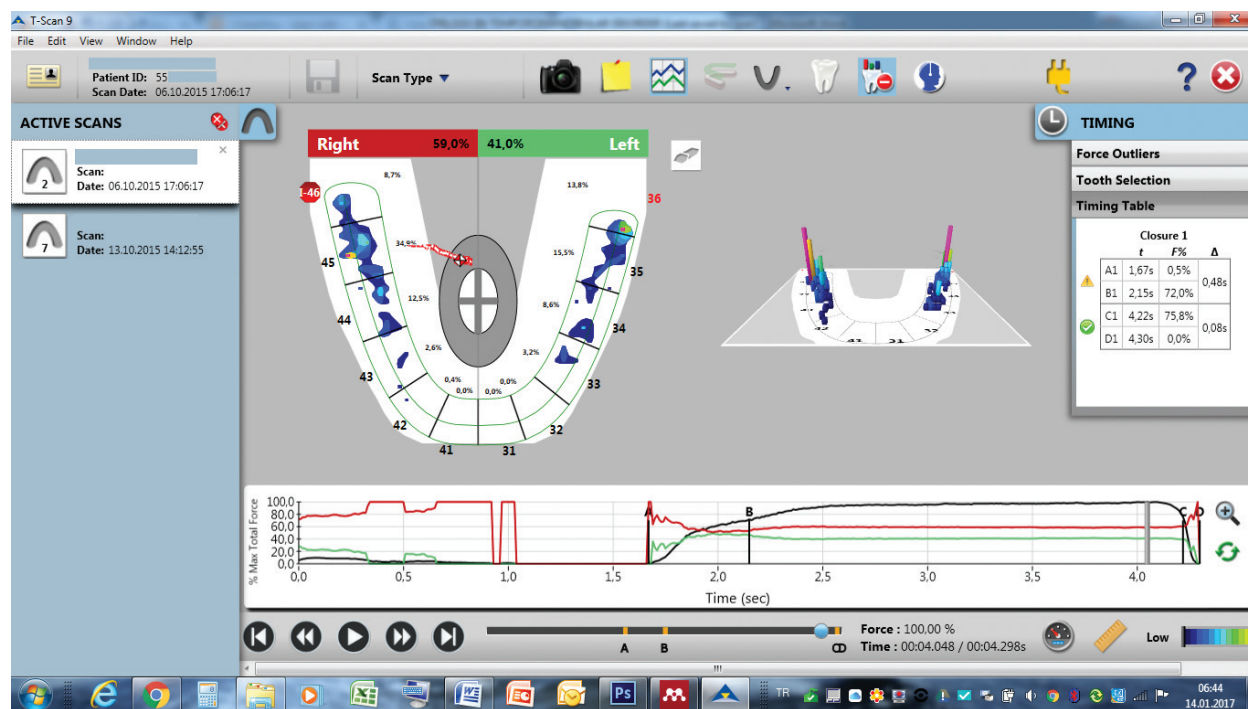


Figure 26. Before occlusal equilibration.

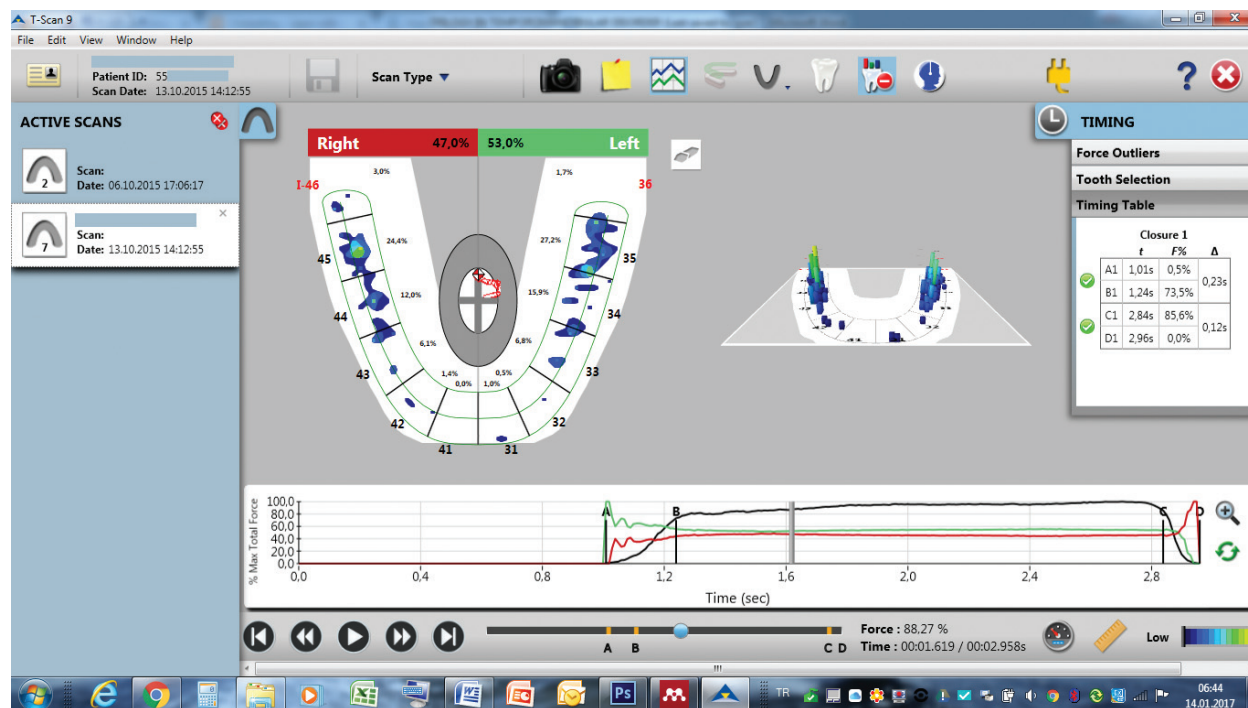


Figure 27. After occlusal equilibration.

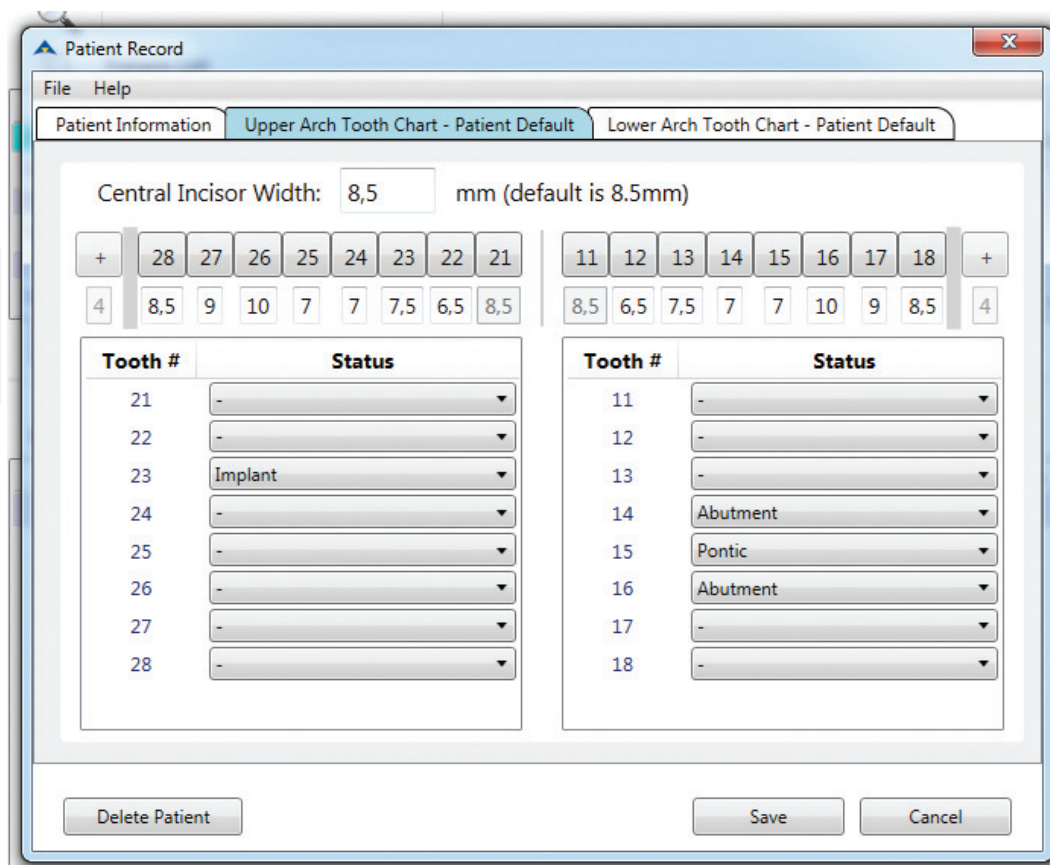


Figure 28. Central teeth dimensions are determinative; after the mesiodistal distance of the central teeth is entered, the dimensions of the other teeth are automatically calculated and the dental arch is formed.

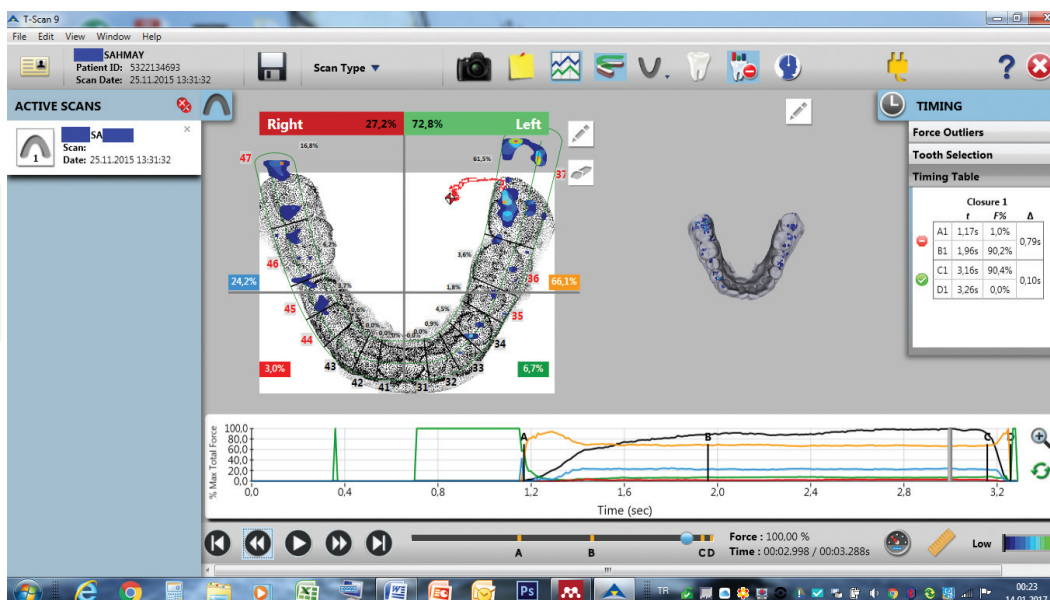


Figure 29. Computerized Occlusion Analysis is currently the most powerful method of TMD clinics for treatment of patients with muscle pain dysfunction syndrome.

1. Muscle pain dysfunction syndrome can be removed very quickly,
2. Splint dependence at unbalanced anterior dislocations can be minimized,
3. Allows for occlusion stabilization in full mouth restorations [84],
4. Allows to keep occlusal stress within physiological limits in implant prosthetic studies [7].

The impact of occlusal forces on teeth is variable. Occlusal derangements in physiological limits are absorbed with the buffer ability of periodontal ligaments [92]. However, impact of premature contacts on periodontium is like jiggling, and this effect causes the enlargement of the alveolar space of teeth causing the teeth to loosen in alveolar space [93]. Therefore, it seems important to remove the occlusal traumas without causing any disruption on temporomandibular joints.

Author details

Serdar Gözler

Address all correspondence to: serdargozler@aydin.edu.tr

Dentistry Faculty of Istanbul Aydin University, Istanbul, Turkey

References

- [1] Buescher J. Temporomandibular joint disorders. In: Am Fam Physician [Internet]. Elsevier; 2007 [cited 2016 Dec 15]. pp. 1477-1482. Available from: <http://linkinghub.elsevier.com/retrieve/pii/B9780323045742500144>
- [2] Scrivani SJ, DAS K, Kaban LB. Temporomandibular disorders. New England Journal of Medicine. 2008;2693-2705
- [3] Yuasa H, Kino K, Kubota E, Kakudo K, Sugisaki M, Nishiyama A, et al. Primary Treatment of Temporomandibular Disorders : The Japanese Society for the Temporomandibular Joint Evidence-Based Clinical Practice Guidelines. 2013
- [4] Fletcher, Piccuch, Lieblich. Anatomy and pathophysiology of the Temporomandibular joint. In: Peterson's Principles of Oral and Maxillofacial Surgery [Internet]. 2004 [cited 2016 Dec 15]. pp. 933-948. Available from: <http://dx.doi.org/10.1016/B978-0-7234-3809-0.00006-1>
- [5] McNeill C. Management of temporomandibular disorders: Concepts and controversies. The Journal of Prosthetic Dentistry. 1997;77(5):510-522
- [6] Issa TS, Huijbregts PA. Physical therapy diagnosis and Management of a Patient with chronic daily headache: A case report. The Journal of Manual & Manipulative Therapy. 2006;14(4):E88-123

- [7] Advisors E. Principles of Occlusion. Vol. 172006
- [8] Gonzalez YM, Greene CS, Mohl ND. Technological devices in the diagnosis of Temporomandibular disorders. *Oral and Maxillofacial Surgery Clinics of North America*. 2008; **20**(2):211-220
- [9] Lund JP, Widmer CG, Feine JS. Validity of diagnostic and monitoring tests used for temporomandibular disorders. *Journal of Dental Research*. 1995; **74**(4):1133-1143
- [10] Baba K, Tsukiyama Y, Yamazaki M, Clark GT. A review of temporomandibular disorder diagnostic techniques. *The Journal of Prosthetic Dentistry*. 2001; **86**(2):184-194
- [11] Dergin DO. SÜT, KARIŞIK VE DAİMİ DİŞLENME DÖNEMİNDE TEMPOROMANDİBULAR RAHATSIZLIKLARIN GÖRÜLME SIKLIĞI, ETİYOLOJİSİ VE DAĞILIMININ İNCELENMESİ. University of Marmara; 2014
- [12] Köse G. BRUKSİZMLİ HASTALARD A OKLUZAL TEMAS VE TME SESLERİ ARA-SINDAKI İLİSKİNİN DEĞERLENDİRİLMESİ. Ankara Üniversitesi Sağlık Bilimleri Enstitüsü Protetik Diş Tedavisi; 2015
- [13] Clark GT, Tsukiyama Y, Baba K, Simmons M. The validity and utility of disease detection methods and of occlusal therapy for temporomandibular disorders. *Oral Surgery, Oral Medicine, Oral Pathology, Oral Radiology Endodontology* [Internet]. 1997; **83**(1):101-106. Available from: <http://www.sciencedirect.com/science/article/pii/S1079210497900998>
- [14] Ishigaki S, Basette R, Maruyama T. Vibration of the temporomandibular joints with normal radiographic imagings: Comparison between asymptomatic volunteers and symptomatic patients. *Cranio Journal of Craniomandibular Practice*. 1993; **11**(2):88-94
- [15] Nascimento MM, Dilbone DA, Pereira PN, Duarte WR, Geraldeli S, Delgado AJ. Abfraction lesions: Etiology, diagnosis, and treatment options. *Clinical, Cosmetic and Investigational Dentistry* [Internet]. 2016 [cited 2016 Dec 22]; **8**:79-87. Available from: <http://www.ncbi.nlm.nih.gov/pubmed/27217799> <http://www.pubmedcentral.nih.gov/articlerender.fcgi?artid=PMC4861607>
- [16] Mamoun JS, Napoletano D. Cracked tooth diagnosis and treatment: An alternative paradigm. *European Journal of Dentistry*. 2015; **9**(2):293-303
- [17] Dym H, Israel H. Diagnosis and treatment of Temporomandibular disorders. *Dental Clinics of North America*. 2012; **56**:149-161
- [18] Olesen J. The international classification of headache disorders, 3rd edition. *Cephalgia* [Internet]. 2013; **33**(9):629-808. Available from: <http://www.ncbi.nlm.nih.gov/pubmed/18808500> <http://www.ncbi.nlm.nih.gov/pubmed/24409431> <http://www.ncbi.nlm.nih.gov/pubmed/22325197> <http://www.ncbi.nlm.nih.gov/pubmed/16805756> <http://www.ncbi.nlm.nih.gov/pubmed/24238370>
- [19] López-Frías FJ, Castellanos-Cosano L, Martán-González J, Llamas-Carreras JM, Segura-Egea JJ. Clinical measurement of tooth wear: Tooth wear indices. *Journal of Clinical and Experimental Dentistry*. 2012; **4**(1):48-53

- [20] Di Berardino F, Filipponi E, Schiappadori M, Forti S, Zanetti D, Cesarani A. The occlusal imaging and analysis system by T-scan III in tinnitus patients. *Biomed Journal* [Internet]. 2016;**39**(2):139-144. Available from: <http://dx.doi.org/10.1016/j.bj.2016.04.001>
- [21] Pokorny PH, Wiens JP, Litvak H, Pokorney P, Weins J, Litvak H. Occlusion for fixed prosthodontics: A historical perspective of the gnathological influence. *The Journal of Prosthetic Dentistry*. 2008;**99**(4):299-313
- [22] Okeson JP. Evolution of occlusion and temporomandibular disorder in orthodontics: Past, present, and future. *American Journal of Orthodontics and Dentofacial Orthopaedics* [Internet]. 2015;**147**(5):S216-S223. Available from: <http://dx.doi.org/10.1016/j.ajodo.2015.02.007>
- [23] Wang C, Yin X. Occlusal risk factors associated with temporomandibular disorders in young adults with normal occlusions. *Oral Surgery, Oral Medicine, Oral Pathology, Oral Radiology* [Internet]. 2012;**114**(4):419-423. Available from: <http://dx.doi.org/10.1016/j.oooo.2011.10.039>
- [24] McNamara JA. Orthodontic treatment and temporomandibular disorders. *Oral Surgery, Oral Medicine, Oral Pathology, Oral Radiology Endodontology* [Internet]. 1997;**83**(1):107-117. Available from: <http://www.sciencedirect.com/science/article/pii/S1079210497901001>
- [25] Travess H, Roberts-Harry D, Sandy J. Orthodontics. Part 6: Risks in orthodontic treatment. *British Dental Journal* [Internet]. 2004;**196**(2):71-77. Available from: <http://www.ncbi.nlm.nih.gov/pubmed/14739957>
- [26] Clark JR, Hutchinson I, Sandy JR. Functional occlusion: II. The role of articulators in orthodontics. *Journal of Orthodontics*. 2001;**28**:173-177
- [27] Luther F. Orthodontics and the temporomandibular joint: Where are we now? Part 2. Functional occlusion, malocclusion, and TMD. *Angle Orthodontist*. 1998;**68**:305-318
- [28] Alarabawy RA, El Ahwal HM, El Sergany MAES, Mehrez WW. Magnetic resonance imaging evaluation of temporo-mandibular joint disorders, criterial analysis and significance in comparison with arthroscopy. *Egypt Journal of Radiology and Nuclear Medicine* [Internet]. 2016;**47**(2):467-475. Available from: <http://dx.doi.org/10.1016/j.ejnm.2016.01.002>
- [29] Bas B, Ylmaz N, Gkce E, Akan H. Diagnostic value of ultrasonography in temporomandibular disorders. *Journal of Oral and Maxillofacial Surgery*. 2011;**69**(5):1304-1310
- [30] Chen H, Slade G, Feng Lim P, Miller V, Maixner W, Diatchenko L. Relationship between Temporomandibular disorders, widespread palpation tenderness, and multiple pain conditions: A case-control study perspective: TMD subjects with WPT experience a greater level of multiple comorbid pain condition. *The Journal of Pain*. 2012;**13**(10):1016-1027
- [31] Dolwick FM, Ambramowicz S, Bagheri SC. Diagnosis and Management of Temporomandibular Joint Pain and Masticatory Dysfunction. *Current Therapy in Oral and Maxillofacial Surgery*. 2012:859-868
- [32] Drum R. FUNCTION spectral analysis of temporomandibular. 1985;7083

- [33] Elfving L, Helkimo M, Magnusson T. Prevalence of different temporomandibular joint sounds, with emphasis on disc-displacement, in patients with temporomandibular disorders and controls. *Swedish Dental Journal* [Internet]. 2002 [cited 2016 Dec 22];**26**(1):9-19. Available from <http://www.ncbi.nlm.nih.gov/pubmed/12090160>
- [34] Fushima K, Gallo LM, Krebs M, Palla S. Analysis of the TMJ intraarticular space variation: A non-invasive insight during mastication. *Medical Engineering & Physics*. 2003;**25**(3):181-190
- [35] Iwase M, Ohashi M, Tachibana H, Toyoshima T, Nagumo M. Bite force, occlusal contact area and masticatory efficiency before and after orthognathic surgical correction of mandibular prognathism. *International Journal of Oral and Maxillofacial Surgery*. 2006;**35**(12):1102-1107
- [36] Aras K, Hasanreisoglu U, Shinogaya T. Masticatory performance, maximum occlusal force, and occlusal contact area in patients with bilaterally missing molars and distal extension removable partial dentures. *International Journal of Prosthodontics* [Internet]. 2011;**22**(2):204-209. Available from: <http://www.ncbi.nlm.nih.gov/pubmed/19418870>
- [37] Lepley CR, Throckmorton GS, Ceen RF, Buschang PH. Relative contributions of occlusion, maximum bite force, and chewing cycle kinematics to masticatory performance. *American Journal of Orthodontics and Dentofacial Orthopedics* [Internet]. 2011;**139**(5):606-613. Available from: <http://dx.doi.org/10.1016/j.ajodo.2009.07.025>
- [38] Svetlana K. EC DENTAL SCIENCE case report T-scan III computed guided Occlusal adjustment in orthodontic relapse patient. The procedure description. *EC Dental Science*. 2016;**2**(Figure 2):1297-1308
- [39] Gozler S, Vanlioglu B, Evren B, Gozneli R, Yildiz C, Ozkan YK. The effect of temporary hydrostatic splint on occlusion with computerized occlusal analysis system. *Indian Journal of Dental Research*. 2012;**23**(5):617-622
- [40] Sutton DI, Sadowsky PL, Bernreuter WK, McCutcheon MJ, Lakshminarayanan AV. Temporomandibular joint sounds and condyle/disk relations on magnetic resonance images. *American Journal of Orthodontics and Dentofacial Orthopedics*. 1992;**101**(1):70-78
- [41] Krohn S, Gersdorff N, Wassmann T, Merboldt KD, Joseph AA, Buergers R, et al. Real-time MRI of the temporomandibular joint at 15 frames per second???A feasibility study. *European Journal of Radiology* [Internet]. 2016;**85**(12):2225-2230. Available from: <http://dx.doi.org/10.1016/j.ejrad.2016.10.020>
- [42] von Piekartz H. Craniomandibular region: Clinical patterns and management. *Craniofacial Pain*. 2007;**21**:215-284
- [43] Shu L, Building F, Shu L, Building F, Kong H. Characterization of sounds emanating from the human temporomandibular joints. *Archives of Oral Biology*. 1996;**41**(7):631-639
- [44] Wänman A, Agerberg G. Temporomandibular joint sounds in adolescents: A longitudinal study. *Oral Surgery, Oral Medicine, Oral Pathology*. 1990;**69**(1):2-9

- [45] Widmalm SE, Westesson PL, Brooks SL, Hatala MP, Paesani D. Temporomandibular joint sounds: Correlation to joint structure in fresh autopsy specimens. *American Journal of Orthodontics and Dentofacial Orthopedics*. 1992;**101**(1):60-69
- [46] Rohlin M, Westesson PL, Eriksson L. The correlation of temporomandibular joint sounds with joint morphology in fifty-five autopsy specimens. *Journal of Oral and Maxillofacial Surgery*. 1985;**43**(3):194-200
- [47] Tallents RH, Hatala M, Katzberg RW, Westesson PL. Temporomandibular joint sounds in asymptomatic volunteers. *The Journal of Prosthetic Dentistry*. 1993;**69**(3):298-304
- [48] Leader JK, Boston JR, Rudy TE, Greco CM, Zaki HS. Relation of jaw sounds and kinematics visualized and quantified using 3-D computer animation. *Medical Engineering & Physics*. 2003;**25**(3):191-200
- [49] Oster C, Katzberg RW, Tallents RH, Morris TW, Bartholomew J, Miller TL, et al. Characterization of temporomandibular joint sounds. A preliminary investigation with arthrographic correlation. *Oral Surgery, Oral Med Oral Pathol*. 1984;**58**(1):10-16
- [50] Time AA. Frequency analysis and classification of temporomandibular joint sounds & Aydin Akan *, R. Bas7 ar U. *Journal of the Franklin Institute*. 2000;**337**
- [51] Akan A, Ergin A, Yildirim M, Öztaş E. Analysis of temporomandibular joint sounds in orthodontic patients. *Computers and Electrical Engineering*. 2006;**32**(4):312-321
- [52] Gay T, Bertolami CN, Donoff RB, Keith DA, Kelly JP. The acoustical characteristics of the normal and abnormal temporomandibular joint. *Journal of Oral Maxillofacial Surgery* [Internet]. 1987 [cited 2016 Dec 16];**45**(5):397-407. Available from: <http://www.ncbi.nlm.nih.gov/pubmed/3471925>
- [53] Paesani D, Westesson P-L, Hatala MP, Tallents RH, Brooks SL. Accuracy of clinical diagnosis for TMJ internal derangement and arthrosis. *Oral Surgery, Oral Medicine, Oral Pathology* [Internet]. 1992 Mar;**73**(3):360-363. Available from: <http://www.sciencedirect.com/science/article/pii/003042209290135D>
- [54] Dimitroulis G. The prevalence of osteoarthritis in cases of advanced internal derangement of the Temporomandibular joint: A clinical, surgical and histological study. *International Journal of Oral and Maxillofacial Surgery*. 2005;**34**(4):345-349
- [55] Mapelli A, Zanandréa Machado BC, Giglio LD, Sforza C, De Felício CM. Reorganization of muscle activity in patients with chronic temporomandibular disorders. *Archives of Oral Biology* [Internet]. 2016;**72**:164-171. Available from: <http://dx.doi.org/10.1016/j.archoralbio.2016.08.022>
- [56] Shimshak DG, DeFuria MC. Health care utilization by patients with temporomandibular joint disorders. *Cranio*. 1998;**16**(3):185-193
- [57] De Rossi SS, Stern I, Sollecito TP. Disorders of the masticatory muscles. *Dental Clinics of North America* [Internet]. 2013;**57**(3):449-464. Available from: <http://dx.doi.org/10.1016/j.cden.2013.04.007>

- [58] Kuninori T, Tomonari H, Uehara S, Kitashima F, Yagi T, Miyawaki S. Influence of maximum bite force on jaw movement during gummy jelly mastication. *Journal of Oral Rehabilitation*. 2014;**41**(5):338-345
- [59] Abduo J, Tennant M. Impact of lateral occlusion schemes: A systematic review. *Journal of Prosthetic Dentistry* [Internet]. 2015;**114**(2):193-204. Available from: <http://dx.doi.org/10.1016/j.prosdent.2014.04.032>
- [60] Rossi SS De, Greenberg MS, Rcsd FDS, Liu F, Steinkeler A. Temporomandibular Disorders evaluation and management. *The Medical Clinics of North America*. 2014;**98**(2014):1353-1384
- [61] Rinchuse DJ, Kandasamy S, Sciote J. A contemporary and evidence-based view of canine protected occlusion. *American Journal of Orthodontics and Dentofacial Orthopedics*. 2007;**132**(1):90-102
- [62] Slavicek G. Human mastication. *International Journal of Stomatology and Occlusion Medicine* [Internet]. 2010;**3**(1):29-41. Available from: <http://dx.doi.org/10.1007/s12548-010-0044-6>
- [63] van der Bilt A, Engelen L, Pereira LJ, van der Glas HW, Abbink JH. Oral physiology and mastication. *Physiology & Behavior*. 2006;**89**(1):22-27
- [64] Kubein-Meesenburg D, Fanghänel J, Ihlow D, Lotzmann U, Hahn W, Thieme KM, et al. Functional state of the mandible and rolling-gliding characteristics in the TMJ. *Annals of Anatomy*. 2007;**189**(4):393-396
- [65] Hill L. An Introduction to Mastication Analysis in General Practice 2015. pp. 1-5. Available from: <http://www.oralhealthgroup.com/news/anintroductiontomasticationanalysisingeneralpractice/1002121139/?&er=NA>
- [66] Kumbuloglu O, Saracoglu A, Bingol P, Hatiopglu A, Ozcan M. Clinical study on the comparison of masticatory efficiency and jaw movement before and after temporomandibular disorder treatment. *Cranio – Journal of Craniomandibular Practice*. 2013;**31**(3):190-201
- [67] Gözler S. Stomatognatik Sistemin Nöromüsküler Fizyolojisi. In: Çalikkocaoğlu PDS, editor. *Tam Protezler*. 5th ed. Istanbul: Gnatoloji Derneği; 1989. pp. 89-105
- [68] Gözler S. Aggregating stimulus increases the activity in motoneurons causing spasms. Pdf. In: Türker K, editor. 10th biennial international motoneuron meeting, Istanbul [Internet]. Istanbul: Koc University; 2016. p. 76. Available from: <https://neurist.ku.edu.tr/>
- [69] Türker KS, Sowman PF, Tuncer M, Tucker KJ, Brinkworth RSA. The role of periodontal mechanoreceptors in mastication. *Archives of Oral Biology*. 2007;**52**(4):361-364
- [70] Herring SW, Rafferty KL, Liu ZJ, Marshall CD. Jaw muscles and the skull in mammals: The biomechanics of mastication. *Comparative Biochemistry and Physiology - A Molecular and Integrative Physiology*. 2001:207-219
- [71] Ferreira LA, Grossmann E, Januzzi E, de Paula MVQ, Carvalho ACP. Diagnosis of temporomandibular joint disorders: Indication of imaging exams. *Brazilian Journal of Otorhinolaryngology*. 2016;**82**(3):341-352

- [72] Cooper BC, Kleinberg I. Relationship of temporomandibular disorders to muscle tension-type headaches and a neuromuscular orthosis approach to treatment. *Cranio – Journal of Craniomandibular Practice*. 2009;**27**(2):101-108
- [73] Yamada K, Hanada K, Fukui T, Satou Y, Ochi K, Hayashi T, et al. Condylar bony change and self-reported parafunctional habits in prospective orthognathic surgery patients with temporomandibular disorders. *Oral Surgery, Oral Medicine, Oral Pathology, Oral Radiology, and Endodontics*. 2001;**92**(3):265-271
- [74] Baldini A, Nota A, Cozza P. The association between occlusion time and Temporomandibular disorders. *Journal of Electromyography and Kinesiology*. 2015;**25**(1):151-154
- [75] Dawson PE. A classification system for occlusions that relates maximal intercuspation to the position and condition of the temporomandibular joints. *The Journal of Prosthetic Dentistry*. 1996;**75**(1):60-66
- [76] Wieckiewicz M, Boening K, Wiland P, Shiau Y-Y, Paradowska-Stolarz A. Reported concepts for the treatment modalities and pain management of temporomandibular disorders. *Journal of Headache Pain [Internet]*. 2015;**16**(1):106. Available from: <http://www.thejournalofheadacheandpain.com/content/16/1/106>
- [77] Windhorst U. Muscle proprioceptive feedback and spinal networks. *Brain Research Bulletin*. 2007;**73**(4-6):155-202
- [78] Palla S. Trigger points as a cause of Orofacial pain. *Journal of Musculoskeletal Pain*. 2004;**12**(3-4):29-36
- [79] Kurose M, Yamamura K, Noguchi M, Inoue M, Ootaki S, Yamada Y. Modulation of jaw reflexes induced by noxious stimulation to the muscle in anesthetized rats. *Brain Research*. 2005;**1041**(1):72-86
- [80] Dawson PE, Rinchuse DJ, Rinchuse DJ, Kandasamy S. Evidence-based versus experience-based views on occlusion and TMD [4] (multiple letters). *American Journal of Orthodontics and Dentofacial Orthopedics*. 2005;**128**(2):150-152
- [81] Panigrahi D, Satpathy A, Patil A, Patel G. Occlusion and occlusal indicating materials. 2015;**1**(4):23-26
- [82] Ruge S, Quooss A, Kordass B. Variability of closing movements, dynamic occlusion, and occlusal contact patterns during mastication. *International Journal of Computerized Dentistry*. 2011;**14**(2):119-127
- [83] Qadeer S, Yang L, Sarinnaphakorn L, Kerstein RB. Comparison of closure occlusal force parameters in post-orthodontic and non-orthodontic subjects using T-scan(R) III DMD occlusal analysis. *Cranio [Internet]*. 2016;**9634**(April):1-7. Available from: <http://dx.doi.org/10.1080/08869634.2015.1122277>
- [84] Gözler S. Courtesy of Dr Serdar Gözler. In: Erdemir U, Yildiz E, editors. *Esthetic and Functional Management of Diastema: A Multidisciplinary Approach [Internet]*. 1st ed. Istanbul: Springer; 2015. p. 35. Available from: <https://books.google.com/books?id=FawvCwAAQBAJ&pgis=1>

- [85] Kürklü D, Yanikoglu N, Gözler S. Oklüzal Analiz Metodları ve T-scan. Atatürk Üniv Diş Hek Fak Derg. 2009;**19**(1):55-60
- [86] Suit SR, Gibbs CH, Benz ST. Study of gliding tooth contacts during mastication. Journal of Periodontology [Internet]. 1976;**47**(6):331-334. Available from: <http://www.ncbi.nlm.nih.gov/pubmed/1064720>
- [87] Carey J, Craig M, Kerstein R, Radke J. 2_EPA articulating paper study presentation. The Open Dentistry Journal. 2007;**1**(1):1-7
- [88] Carey JP, Craig M, Kerstein RB, Radke J. Determining a relationship between applied occlusal load and articulating paper mark area. Open Dentistry Journal [Internet]. 2007;**1**: 1-7. Available from: <http://www.pubmedcentral.nih.gov/articlerender.fcgi?artid=2581523&tool=pmcentrez&rendertype=abstract>
- [89] Solow RA. Customized anterior guidance for occlusal devices: Classification and rationale. The Journal of Prosthetic Dentistry. 2013;**110**(4):259-263
- [90] Thumati P, Thumati R. The effect of disocclusion time-reduction therapy to treat chronic myofascial pain: A single group interventional study with 3 year follow-up of 100 cases. Journal of Indian Prosthodontic Society [Internet]. 2016;**0**(0):0. Available from: <http://www.j-ips.org/preprintarticle.asp?id=176529>
- [91] Clark JR, Evans RD. Functional occlusion: I. A review. Journal of Orthodontics. 2001;**28**: 76-81
- [92] Karibe H, Ogata K, Hasegawa Y, Ogihara K. Relation between clenching strength and occlusal force distribution in primary dentition. Journal of Oral Rehabilitation. 2003;**30**(3): 307-311
- [93] Daegling DJ, Hylander WL. Occlusal forces and mandibular bone strain: Is the primate jaw "overdesigned"? Journal of Human Evolution [Internet]. 1997;**33**(6):705-717. Available from: <http://www.ncbi.nlm.nih.gov/pubmed/9467777>
- [94] Biopak User Guide, Ver.7. 9275 N. 49th Street, Suite 150 Milwaukee, WI 53223 USA: BioResearch Associates, Inc.; 2011
- [95] T-Scan User Manual (Help File in T-Scan Software 9.1). 307 West First Street. South Boston, MA 02127-1309: Tekscan, Inc; 2015

