

We are IntechOpen, the world's leading publisher of Open Access books Built by scientists, for scientists

6,900

Open access books available

186,000

International authors and editors

200M

Downloads

Our authors are among the

154

Countries delivered to

TOP 1%

most cited scientists

12.2%

Contributors from top 500 universities



WEB OF SCIENCE™

Selection of our books indexed in the Book Citation Index
in Web of Science™ Core Collection (BKCI)

Interested in publishing with us?
Contact book.department@intechopen.com

Numbers displayed above are based on latest data collected.
For more information visit www.intechopen.com



Strategies for Managing Difficult Cases

Baris Komur

Additional information is available at the end of the chapter

<http://dx.doi.org/10.5772/intechopen.72477>

Abstract

Standard cataract surgery is considered as low-risk surgery for both patients and the surgeon, but some eyes have higher risk of complication due to some reasons that are generally known or can be predicted preoperatively. Knowing risky eyes and management of possible complications is important point for achieving good visual outcome after cataract surgery. We issued most encountered problems during surgery and some solutions to manage these difficult cases.

Keywords: small pupil, brunescant, hard, white, cataract, weak zonules, zonulopathy, postural problems, shallow anterior chamber, posterior polar, reverse pupillary block

1. Introduction

In ophthalmology, the clinical management of patients is constantly evolving and complication rate is getting low. On the other hand, patient expectations are increasing. Currently, the patient now expects excellent uncorrected visual acuity following cataract surgery [1]. Although routine cataract surgery considered as low-risk surgery for both patients and the surgeon, some eyes have higher risk of complication during cataract surgery. Operations on such difficult cases are also more likely to yield a poor visual outcome which is defined as best corrected vision less than 6/60 after surgery [2].

It is extremely important to recognize when eyes are at greater risk, and act accordingly, to reduce complications. Also, before the operation takes place, it is better to spare extra time on these difficult cases, explaining that surgery is somewhat different and difficult than “routine cataract surgery” and poor outcome is a possibility. Some patients may want to take a second opinion from another clinic, letting or even encouraging them to do so will be a better option than trying to explain complication may occur at every clinic after an undesired result occurred. The patients

should have realistic expectations, and understand possible complications and their other ocular problems [3]. This approach makes patients expectations much more realistic and improves postoperative compliance and follow-up. In rare cases, patients with complicated cataract will be happy if they achieve some improvement in their vision.

It is also important to prepare for difficult case both mentally and physically. Mentally, the surgeon must know what to do if any complication occurs, physically, the surgeon must prepare all the equipment to manage a possible complication, like pupil devices for small pupils, capsule tension rings (CTR) for weak zonules, sutures for scleral fixation or Cionni ring fixation and vitrectomy devices in the case of capsular rupture and vitreous loss.

In this chapter, we discuss some frequently encountered difficult situations and their solutions.

2. Small pupil

It is very important to obtain sufficient pupillary dilation that lasts for the duration of the cataract surgery. A small pupil is defined as having a diameter equal to or less than 4 mm; in these cases, although experienced surgeon can continue to surgery without any manipulation; beginner surgeon must enlarge the pupil. The surgeon must plan the operation very carefully, taking into consideration all possible situations. Methods used to deal with small pupil, must aim good return of pupil function, not causing esthetically bad results or functional problems such as photophobia and diplopia. The postoperative esthetic results of this type of surgery are potentially disturbing for the patient; any surgical alteration of the pupil may have a significant effect on its function with side effects such as iatrogenic glare that can be debilitating [4].

Preoperatively using a nonsteroidal anti-inflammatory drug (NSAID) in addition to cycloplegics and mydriatics may reduce probability of pupil contraction during the operation [5–7]. There are preparations, containing NSAID for intraoperative usage, approved by the US Food and Drug Administration, also there are some preparations combining both mydriatics and NSAIDs which can be used intraoperatively, but these preparations may not be available worldwide or may be very expensive [8–10]. Another (cheaper) option is 0.5 mL of 1:1000 preservative free adrenaline diluted in 10 mL of balanced salt solution (BSS); this is injected at the beginning of surgery, through the side-port incision or added to the infusion bottle (4 IU of 1:1000 adrenaline in 500 cc) [11, 12].

Even with pharmacological dilation, pupil may still not be large enough to allow safe surgery. Although there is no absolutely safe pupil size, generally if pupil allows creation of an adequate capsulorrhexis, it also may be sufficient for the remaining steps of the surgical procedure. Safe pupil size may depend on surgical expertise, cataract hardness, patient compliance and other anatomical restrictions.

First thing to try after failed pharmacological dilation may be viscomydriasis, which is injecting viscoelastic substance (VES) toward the iris, hoping a peripheral displacement of the central portion of the iris, resulting in expansion of the pupil. Keep in mind that, VES will enlarge the pupil only when it is anterior chamber (AC); the effect of VES is less when phacoemulsification and aspiration begins. High molecular weight cohesive products will be more effective for this purpose.

Synechiolysis can be utilized, when pupil is fixed by adhesions between the iris and the underlying lens capsule (posterior synechiae). Synechiae is broken with a blunt spatula or VES cannula that is inserted through a paracentesis, while AC filled with VES. Excessive traction may cause bleeding. Fibrous pupillary band also must be removed with a forceps for capsulorrhexis or vitreoretinal surgery [13].

Pupil stretching is more invasive procedure that induces numerous, very fine partial ruptures of the sphincter that induce mydriasis. Pupil stretching must be performed under VES protection to maintain AC depth. Two hooks are introduced into the AC; the pupil is engaged at two opposite points; and the surgeon applies peripheral pressure, sufficient to ensure moderate and controlled relaxation of the pupil edge to increase mydriasis. Repetitive gentle and progressive “push-pull” movements of the instruments are recommended. With this, rupture of the sphincter is minimized. Rapid movements may cause serious damage to the sphincter. The hook is inserted through the side-port incision and through the main incision; it is used to stretch the pupil in several different and opposite directions (initially at the 12 and 6 o’clock positions and then at the 3 and 9 o’clock positions). Then, oblique positions can be used if needed (**Figure 1**).

There are also one-handed dilators available; inserted through the main incision, these devices stretch the pupil with a single maneuver. These instruments have been designed as a handpiece with a narrow cannula containing several hooks (between 2 and 4), with a fixed hook on its outside edge. There are fewer possibilities for adjustment with this technique and the dilator instrument itself can be expensive [14].

Sphincterotomy is an invasive procedure but useful in cases in which the sclerosis of the iris tissue is restricted to the central zone, typical of the senile pupil, capsular pseudoexfoliation, postinflammatory miosis, or iatrogenic inflammation resulting from the prolonged use of miotics. The microincisions (mini-sphincterotomies), usually 6–8, are created using fine micro-scissors. The incisions continue radially for approximately two-thirds of the length of the iris sphincter (**Figure 2**). The length of the corneal incision through which the scissors are inserted determines the degree of circumferential extension of the incisions [15].

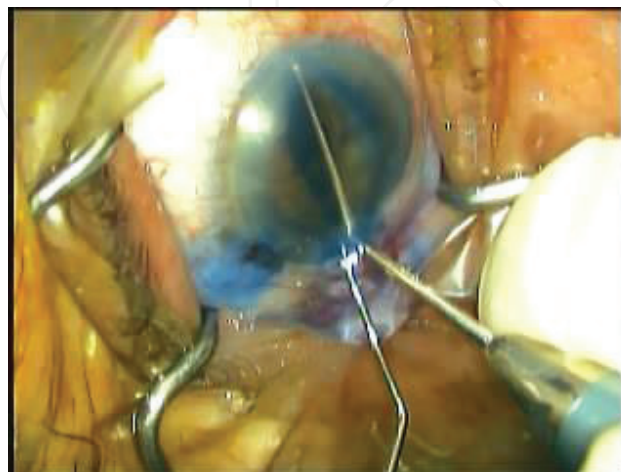


Figure 1. Pupil stretching with two instruments.

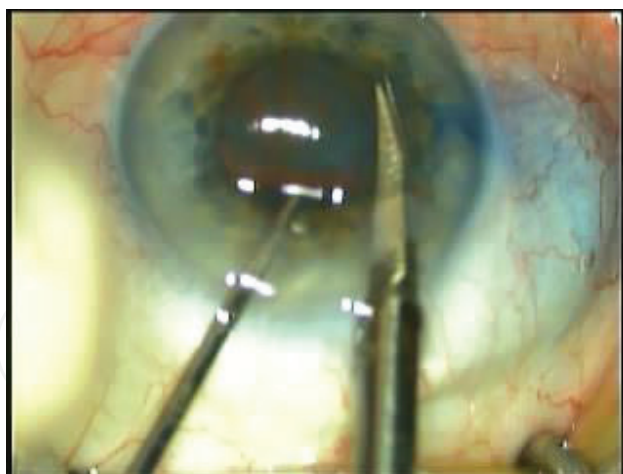


Figure 2. Mini-sphincterotomies with fine scissors.

In some cases, even after pupil stretching; size may still not be sufficient or iris laxity may cause repeated aspiration of the iris tissue itself by phaco tip. In these cases, mechanical hook retractors (dilator hooks) or iris rings can be used. Iris tissue must be sufficiently elastic to allow distention without causing lacerations. Technique for positioning iris hooks involves the creation of limbal paracenteses for the insertion of the hooks under VES. Iris hooks engage pupil margin and pull it centrifugally with silicone fragment that is engaged at the limbus. Generally, four hooks are positioned, producing a square-shaped iris. Positions of limbal paracenteses are important. For correct stretching, hooks should pull in a direction parallel to iris plane and iris must not be elevated. For this reason, incisions made close as possible to the limbus with an appropriate orientation (**Figure 3**). Once hooks positioned, the surgeon can cut the excess to avoid displacement of the hooks if the patient moves his or her eye, if topical anesthesia chosen. Iris hooks can be removed quite easily through the insertion incisions. Hooks create mydriasis that is adequate for surgery but not excessively large that can cause lax pupil postoperatively.

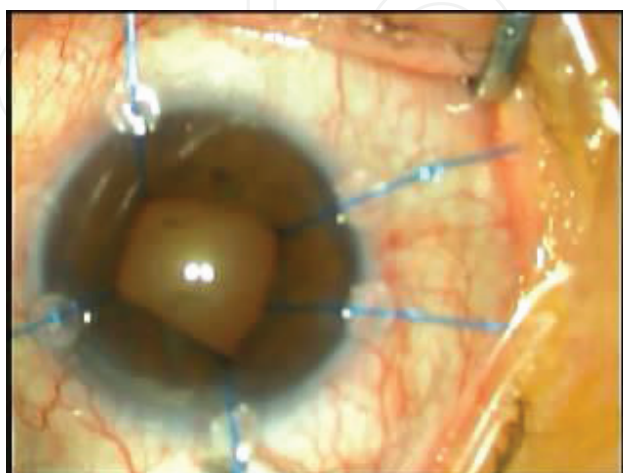


Figure 3. Iris hooks direction are better when parallel to iris plane and iris is not elevated.

Pupil expansion rings are another set of instruments designed to enlarge pupil without damaging the sphincter. These can be complete or incomplete rings; some are manufactured in polymethylmethacrylate (PMMA), others are silicone or expandable hydrogel [16]. Recently, Malyugin presented a new pupil expander [17, 18]. The use of this device also appears to be easier and faster compared to iris hooks and other pupil expansion rings. This device may be safer for dealing with a small pupil, particularly in eyes with intraoperative floppy iris syndrome. This device is a one-piece device of 5-0 Prolene. Circular buttonholes engage the pupil edge and expand the pupil. This ring has a number of advantages: it is easy to implant and induces less trauma and stretching forces are evenly distributed over the pupil edge. This may be useful in patients in which cutting the iris tissue should be avoided (e.g., iris rubeosis, chronic iritis, or systemic coagulopathies). After the surgery, the appearance of the majority of pupils is more or less the same as preoperatively, and functional activity is preserved. Additional corneal incisions are not necessary, and device is inserted through the main incision using an injector. Only negative point may be the cost of Malyugin ring.

Regardless of the method used to expand the pupil, at the end of surgery, the pupil must be constricted to avoid it being captured by part of the optic, adhering to the capsule, or other deformities.

3. Hard nucleus

Dense cataracts have always been considered challenging in phacoemulsification. The problems encountered in hard cataracts are determined not just by the hardness and the dimensions of the nucleus but also by the poor degree of hydration of the lens, absence of the red reflex, a capsule that is thin and fragile and weak or absent zonules.

Corneal tunnel should be made slightly shorter and larger. This structure will reduce the danger of wound burn, and the surgeon will probably use much ultrasound energy.

Capsulorrhexis should ideally be intact if the surgeon wishes to perform phacoemulsification. A reduced red reflex associated with the density of cataract, reduces the visualization of the anterior capsule. Changing the angle of the microscope's coaxial light beam may produce better visibility of the capsule. If the visibility remains insufficient, vital dyes (such as trypan blue) may be useful. It improves visibility of capsule during capsulorrhexis and phacoemulsification, which help the surgeon to avoid traumatizing the edge of capsulorrhexis. Adequate use of VES is important for flattening convex shape of the anterior lens surface, increasing AC depth (which has been reduced due to the large volume of the crystalline lens) to reduce zonular stretch and orient the rhexis in the desired direction [19]. Capsulorrhexis should ideally be a large rhexis (5.5–6.0 mm) to ease manipulations in the bag. In the event of difficulties, a large rhexis can also allow luxation of the nucleus in the AC and converting extracapsular cataract extraction. Beware that, too large capsulorrhexis may also make them unable to capture the optic of intraocular lens (IOL) in the event of posterior capsule rupture. In extremely mature cataracts, the anterior capsule may contain deposits of calcium or dense focal plaques, in these areas, the surgeon can cut through these dense areas with scissors.

Hydrodissection must be performed delicately. After half of the hydrodissection completed, center of raised nucleus should be pressed with cannula to depress the nucleus posteriorly; a further hydrodissection is performed on the opposite side (if needed, the surgeon can combine viscodissection procedure to rotate the nucleus). This pressing is important as the anterior shift of the large brunescent nucleus during hydrodissection may cause a capsule-lenticular blockage. In this case, if the surgeon proceeds with further and aggressive injections of liquid below the nucleus, the posterior capsule may be distended and ruptured. There may be strong corticocapsular adhesions that interfere with rotation of the nucleus; this procedure must be performed delicately without excessive force being applied. Before the surgeon begins ultrasound, it is essential that the nucleus rotate freely inside the capsular bag.

Weak zonules may be associated with the advanced age of these patients, with previous traumatic episodes that may have gone unnoticed, or with various reasons. The posterior capsule will have a greater tendency to shift toward the phaco tip even with a minimal degree of postocclusion surge. If the surgeon suspects clinically significant zonular weakness then he or she should not hesitate to use a capsular tension ring (CTR). There is a debate regarding the most suitable timing for this particular maneuver; some surgeons believe that the tension ring should be inserted as soon as any degree of weakness is observed, usually prior to the phacoemulsification procedure, while others feel that it should be inserted prior to irrigation/aspiration or before IOL is implanted.

These cataracts must be operated by expert surgeons who know modification of parameters and techniques to manage hard cataracts. When removing these nuclei, many surgeons proceed with sculpting procedures, but using techniques like “phaco chop” and the “stop and chop” technique that reduce the capsular and zonular stress, may reduce complications in these eyes [20, 21]. The “quick chop” technique is a variation of the “phaco chop” with a reduction in the amount of ultrasound used and manual fragmentation required. This allows reduction of energy with a reduction in the risk of wound burn, shortened operating times, and a reduction in the amount of stress to the zonules. Technique involves use of high vacuum and a chopper; the phaco tip is used as a pivot point to fracture the nucleus into pieces, moving them toward the chopper, which has been pushed from top down in front of the phaco tip. Regardless of the technique preferred by the modern surgeon (divide and conquer, stop and chop, chop), the basic principle is the same, to create multiple, small-size fragments. These fragments are larger and much denser than those of other types of nucleus. Comparing a standard cataract, the vacuum is much higher and occasional short bursts of ultrasound (20–40%) will be required. During this step, non-dominant hand movements are essential.

In the past, blockage of the tubing by rigid nuclear fragments was a frequent problem, as these pieces may occlude the phaco tip resulting in poor followability and in excessive turbulence which causes trauma to the endothelium. Thanks to modern phacoemulsification machines that considerably reduce the amount of energy and heat produced with increased followability associated with reduced vibration of the fragments inside the phaco tip. This technology is implemented by various companies [22, 23]. Despite this technology, signs that the surgeon must recognize when the phaco tip is partially or completely occluded are sudden appearance of emulsified milky material in front of the ultrasound tip and suddenly decreased

followability. Posterior capsule is frequently thinner and stretched by the large volume of the lens; it will be weak and flaccid and will tend to be aspirated into the phaco tip with a major risk of rupture. Also, these cases generally have an absence or reduced amount of an epinucleus to protect the posterior capsule, forcing the surgeon to work closer to the posterior capsule and the equatorial periphery. Therefore, it is advisable for several small injections of a dispersive VES, behind the nucleus during phacoemulsification, injecting it into various areas to create a thin yet uniform layer of VES between the nucleus and the posterior capsule, creating an artificial epinucleus that separates the posterior capsule from the operating plane. Because of its intrinsic properties, it is not easily aspirated by the phaco tip, and this facilitates the safe emulsification of the fragments.

Once the nucleus has been completely removed, the remaining portion of the surgery is like a standard cataract. However, at the end of the procedure, if the capsular bag appears to be too compromised as it will not support the IOL, the surgeon may consider to implant a posterior chamber IOL with transscleral or iris fixation or an anterior chamber IOL.

4. Posterior polar cataracts

Posterior polar cataract is a type of congenital cataract that occurs in the central cortex adjacent to the posterior capsule. There is an increased risk of a posterior capsular tear during cataract surgery because a capsular defect is often present. Even if a discrete capsular defect is not detected (usually visible as small vacuole), there is an increased risk of a capsular complication. Hydrodissection increases the risk of blowing out the posterior capsule. While some authors did hydrodissection in multiple quadrants with tiny amount of fluid without allowing the wave to transmit across the posterior capsule, cortical cleaving hydrodissection is considered a contraindication in eyes with posterior polar cataract [24]. A weak point can produce hydraulic posterior capsule rupture during hydrodissection. Meanwhile, hydrodelineation, which is the separation between the nucleus and the epinucleus, is mandatory. It is worth mentioning that the surgeon should avoid vigorous decompression of the capsular bag after the delineation. In addition, nuclear rotation is contraindicated as it can act as a trephine to the posterior capsule. Some authors described a technique that was described for dense and posterior polar cataract called inside-out delineation [25]. In this technique, a trench is first sculpted and a right-angled cannula is used to subsequently direct the fluid perpendicularly to the lens fibers in the desired plane through one wall of the trench. This would avoid the possibility of inadvertent subcapsular injection and overcome the difficulty of introducing cannula to a significant depth in a dense cataract.

Capsular stress must be minimized by lowering the irrigation bottle height, reducing flow and vacuum settings which is named as slow-motion phaco, maintaining a stable anterior chamber (avoid surge and chamber bounce), and minimizing manipulations of the lens [26]. Attempting to polish any residual posterior capsular plaque in the area where the posterior polar cataract was located can easily create a tear in the weakened/defective posterior capsule. Leaving a small plaque may affect the patient's vision postoperatively, but it is much better to just perform a laser posterior capsulotomy when necessary.

5. Traumatic cataract

Cataract surgery in traumatized eyes is one of the most difficult clinical situations an anterior segment surgeon is likely to encounter. Preoperative good examination is essential. Presence and extent of phacodonesis and decentration of the lens zonular disinsertion must be recorded. A wrinkled anterior capsular surface may indicate discontinuity of the capsule itself or the zonules. It should be remembered that the integrity of the capsule may be compromised even with contusive (not penetrating) trauma [27].

Sometimes it is possible to examine the fundus depending on the opacity of the media, and its examination should include identification of holes, retinal lacerations, or retinal edema. The presence of subretinal or suprachoroidal hemorrhage should lead to greater prognostic caution, as any degree of suprachoroidal hemorrhage would cause posterior pressure during surgery.

If fundus examination is not possible, only B-scan may modify the surgeon's approach to the cataract surgery itself. When a suprachoroidal hemorrhage is detected, the surgeon should consider a pars plana vitrectomy. A computed tomography (CT) scan of the orbit is indicated if the surgeon suspects the presence of an intraocular or intraorbital foreign body. With an open corneal and/or scleral laceration, generally good slit-lamp examination will be impossible, making surgical planning more critical. If a penetration of anterior capsule present, cornea is sutured without removing the cataract; capsule may heal by itself with a little opacity [28].

A foreign body of a ferrous nature must be removed, as it could lead to ocular siderosis, while inert foreign bodies (such as glass) are well tolerated even when left in eye [29, 30]. Choice of local or general anesthesia depends on the surgeon expertise and clinical situation. Conjunctival peritomy must leave a room for pars plana sclerotomy, suturing of an IOL with scleral fixation or insertion of a Cionni ring. Conjunctiva should be spared for possible glaucoma surgery in the future. If anterior hyaloid is partly exposed, a dispersive VES can tamponade the vitreous. Dispersive VES may also provide protection for the endothelium, as endothelial cell density has been already reduced by the trauma [31].

Using vital dyes such as trypan blue has advantages: useful for finding thorn point of a capsule if needed.

With significant zonular damage, CTR can also be used to stabilize the bag. If the zonular damage involves more than 4 h (90°), suturing a Cionni ring can strengthen the area of greater zonular weakness [32]. This will improve the stability of the lens during all of the successive steps of the operation.

If introduction of ring is impossible prior to phaco, the surgeon can enhance zonular support with flexible nylon iris retractors or special capsule hooks introduced through a limbal incision, these hooks support the edge of capsulorrhexis (**Figure 4**). After emulsification of nucleus, CTR or Cionni ring can be positioned much more easily.

In case of vitreous present in anterior chamber, the surgeon must always avoid aspirating vitreous. Any traction exerted on anterior vitreous can create retinal tears and eventually lead to retinal detachment. Once vitreous removed from anterior chamber, the surgeon should then concentrate on the lens material.

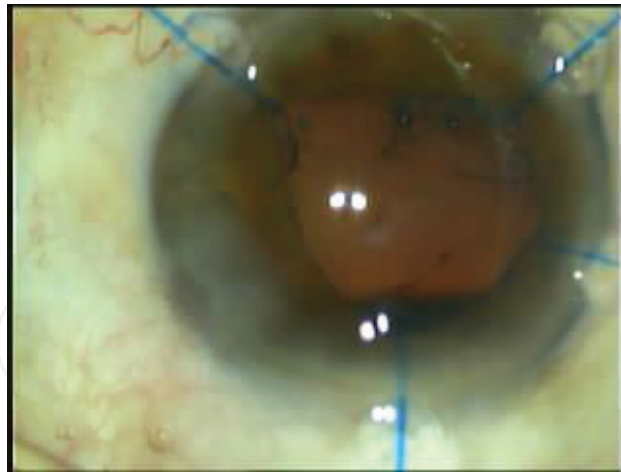


Figure 4. Iris hooks support the edge of capsulorhexis vertically, acting like artificial zonules.

For soft nucleus, phacoaspiration of nucleus is generally safe and rapid. If there is a rupture of anterior or posterior capsule, manual aspiration with a Simcoe cannula and/or automated bimanual or coaxial irrigation and aspiration can be utilized. For harder nucleus, main principle is to reduce traction forces on remaining zonules. Many variations of delicate divide and conquer and particularly, phaco chop techniques can be chosen with low parameters of slow-motion phaco as described previously. If there is a significant zonular weakness and/or posterior capsular defect with a large lateral or inferior movement of the nucleus, then converting to manual extracapsular or intracapsular extraction techniques may be the only option.

It may be difficult for the surgeon to aspirate cortical material due to a lack of resistance of zonular fibers and manipulation may increase zonular dialysis. Using tangential movement as opposes to radial may be beneficial. If there is a capsular rupture, intact anterior hyaloid may covered with VES, after the surgeon can complete the removal of the cortex using manual dry aspiration. This technique utilizes a 25- or 27-gauge cannula attached to a 3-mL syringe, chamber filled with VES without allowing vitreous escape.

If there is an inadequate capsular support, the surgeon may try to suture one or both haptics of IOL to the sclera or the iris. With inadequate capsular support, the surgeon has several types of IOL such as scleral fixation, iris suture fixation, angle-supported anterior chamber IOL, or iris enclavation IOL. IOL Choice depends on the surgeon expertise and clinical situation.

After IOL has been inserted and appears to be well-centered, fixation can be confirmed using “Bounce test.” This test is decentering the optic toward each one of two haptics and then releasing it. IOL should recenter spontaneously.

6. Femtosecond laser assistance in difficult cases

For white intumescent cataracts, using femtosecond laser to make capsulorhexis without decompressing the anterior chamber allows round capsulorhexis without any radial tears.

The surgeon may want to use additional vital dye to ensure the integrity of capsulorrhexis [33]. In traumatic cases and weak zonules even there is vitreous in the anterior chamber, femtosecond laser can make round capsulorrhexis.

Femtosecond laser assistance cataract surgery (FLACS) does not provide superior outcomes in all cases. In a recent study, two patients with bilateral posterior polar cataracts underwent traditional phacoemulsification in one eye and FLACS in the other eye. In both cases, the eye treated with FLACS developed a posterior capsule rupture during lens removal [34]. Caution may also be needed in the use of FLACS in glaucoma as docking procedure may raise intraocular pressure [35, 36]. In presence of silicone oil in AC, FLACS may result incomplete capsulotomy and lens fragmentation [37].

Use of femtosecond lasers in cataract surgery is continuing to evolve, together with its potential applications, but we think that its cost must be reduced to become popular among clinics.

7. Conclusions

Cataract surgery in difficult cases can be both enjoyable and troublesome. Knowing that every case has its own distinct features, the surgeon must treat each case in a unique way. We summarized some of the most encountered problems and solutions in this chapter. Each technique must be practiced preferably in animal's eyes or in simulation environments and then in easy standard cases. Before to try techniques for real difficult cases in real difficult situations, the surgeon must feel confident and relaxed about using mentioned techniques.

Conflict of interest

The author did not have a conflict of interest for any products mentioned in the above text.

Author details

Baris Komur

Address all correspondence to: bkomur@gmail.com

Haseki Education and Research Hospital, Istanbul, Turkey

References

- [1] Rana M, Shah S. Modern-day cataract surgery: Can we match growing expectations? *The British Journal of Ophthalmology*. 2014;**98**:1313-1314
- [2] Limburg H. Monitoring cataract surgical outcomes: Methods and tools. *Community Eye Health Journal*. 2002;**15**:51-53

- [3] Jackson H, Garway-Heath D, Rosen P, Bird AC, Tuft S. Outcome of cataract surgery in patients with retinitis pigmentosa. *The British Journal of Ophthalmology*. 2001;**85**:936-938
- [4] Masket S. Relationship between postoperative pupil size and disability glare. *Journal of Cataract and Refractive Surgery*. 1992;**18**:506-507
- [5] Solomon KD, Turkalj JW, Whiteside SB, Stewart JA, Apple DJ. Topical 0.5% ketorolac vs 0.03% flurbiprofen for inhibition of miosis during cataract surgery. *Archives of Ophthalmology*. 1997;**115**:1119-1122
- [6] Stewart R, Grosserode R, Cheetham JK, Rosenthal A. Efficacy and safety profile of ketorolac 0.5% ophthalmic solution in the prevention of surgically induced miosis during cataract surgery. *Clinical Therapeutics*. 1999;**21**:721-732
- [7] Donnenfeld ED, Perry HD, Wittpenn JR, Solomon R, Nattis A, Chou T. Preoperative ketorolac tromethamine 0.4% in phacoemulsification outcomes: Pharmacokinetic-response curve. *Journal of Cataract and Refractive Surgery*. 2006;**32**:1474-1482
- [8] Morgado G, Barros P, Martins J, Lima A, Martins N. Comparative study of mydriasis in cataract surgery: Topical versus Mydriaserit versus intracameral mydriasis in cataract surgery. *European Journal of Ophthalmology*. 2010;**20**:989-993
- [9] Korobelnik JF, Tavera C, Renaud-Rougier MB, El Meski S, Colin J. The Mydriaserit insert: An alternative to eye drops for preangiographic mydriasis. *Journal Francais D'Ophthalmologie*. 2004;**27**:897-902
- [10] Levet L, Touzeau O, Scheer S, Borderie V, Laroche LA. Study of pupil dilation using the Mydriaserit ophthalmic insert. *Journal Français d'Ophtalmologie*. 2004;**27**:1099-1108
- [11] Liou SW, Chen CC. Maintenance of mydriasis with one bolus of epinephrine injection during phacoemulsification. *Journal of Ocular Pharmacology and Therapeutics*. 2001;**17**:249-253
- [12] Lundberg B, Behndig A. Intracameral mydriatics in phacoemulsification cataract surgery. *Journal of Cataract and Refractive Surgery*. 2003;**29**:2366-2371
- [13] Osher RH. Pupillary membranectomy. Video. *Journal of Cataract and Refractive Surgery*. 1991;**7**:7
- [14] Barboni P, Zanini M, Rossi A, Savini G. Monomanual stretcher. *Ophthalmic Surgery and Lasers*. 1998;**29**:772-773
- [15] Shingleton BJ, Campbell CA, O'Donoghue MW. Effects of pupil stretch technique during phacoemulsification on postoperative vision, intraocular pressure, and inflammation. *Journal of Cataract and Refractive Surgery*. 2006;**32**:1142-1145
- [16] Goldman JM, Karp CL. Adjunct devices for managing challenging cases in cataract surgery: Capsular staining and ophthalmic viscosurgical devices. *Current Opinion in Ophthalmology*. 2007;**38**:32-57
- [17] Chang DF. Use of Malyugin pupil expansion device for intraoperative floppy-iris syndrome: Results in 30 consecutive cases. *Journal of Cataract and Refractive Surgery*. 2008;**34**:832-841

- [18] Agarwal A, Malyugin B, Kumar DA, Jacob S, Agarwal A, Laks L. Modified Malyugin ring iris expansion technique in small-pupil cataract surgery with posterior capsule defect. *Journal of Cataract and Refractive Surgery*. 2008;**34**:324-326
- [19] Miyata K, Nagamoto T, Maruoka S, Tanabe T, Nakahara M, Amano S. Efficacy and safety of the soft-shell technique in cases with a hard lens nucleus. *Journal of Cataract and Refractive Surgery*. 2002;**38**:1546-1550
- [20] Nagahara K. Video presentation. Seattle, WA: ASCRS; 1993
- [21] Koch PS, Katzen LE. Stop and chop phacoemulsification. *Journal of Cataract and Refractive Surgery*. 1994;**20**:566-570
- [22] Zeng M, Liu X, Liu Y, et al. Torsional ultrasound modality for hard nucleus phacoemulsification cataract extraction. *The British Journal of Ophthalmology*. 2008;**92**:1092-1096
- [23] Fakhry MA, El Shazly MI. Torsional ultrasound mode versus combined torsional and conventional ultrasound mode phacoemulsification for eyes with hard cataract. *Clinical Ophthalmology*. 2011;**5**:973-978
- [24] Fine IH, Packer M, Hoffman RS. Management of posterior polar cataract. *Journal of Cataract and Refractive Surgery*. 2003;**29**:16-19
- [25] Vasavada AR, Raj SM. Inside-out delineation. *Journal of Cataract and Refractive Surgery*. 2004;**30**:1167-1169
- [26] Osher RH, Yu BC, Koch DD. Posterior polar cataracts: a predisposition to intraoperative posterior capsular rupture. *Journal of Cataract and Refractive Surgery*. 1990;**16**:157-162
- [27] Saika S, Kin K, Ohmi S, Ohnishi Y. Posterior capsule rupture by blunt ocular trauma. *Journal of Cataract and Refractive Surgery*. 1997;**23**:139-140
- [28] Pieramici DJ, Capone A Jr, Rubsamen PE, Roseman RL. Lens preservation after intraocular foreign body injuries. *Ophthalmology*. 1996;**103**:1563-1567
- [29] O'Duffy D, Salmon JF. Siderosis bulbi resulting from an intralenticular foreign body. *American Journal of Ophthalmology*. 1999;**127**:218-219
- [30] Ozdemir O, Şengör T. Intraocular foreign body Detected by Gonioscopy in the anterior chamber angle. *Turkish Journal of Ophthalmology*. 2013;**43**:278-281
- [31] Fukagawa K, Tsubota K, Kimura C. Corneal endothelial cell loss induced by air bags. *Ophthalmology*. 1993;**100**:1819-1823
- [32] Cionni RJ, Osher RH. Management of profound zonular dialysis or weakness with a new endocapsular ring designed for scleral fixation. *Journal of Cataract and Refractive Surgery*. 1998;**24**:1299-1306
- [33] Asena BS, Erdur SK, Kaşkaloglu M. Early experience in femtosecond laser assisted cataract surgery. *Turkish Journal of Ophthalmology*. 2015;**45**:97-101

- [34] Alder BD, Donaldson KE. Comparison of 2 techniques for managing posterior polar cataracts: Traditional phacoemulsification versus femtosecond laser-assisted cataract surgery. *Journal of Cataract and Refractive Surgery*. 2014;**40**:2148-2151
- [35] Darian-Smith E, Howie AR, Abell RG. Intraocular pressure during femtosecond laser pretreatment: Comparison of glaucomatous eyes and nonglaucomatous eyes. *Journal of Cataract and Refractive Surgery*. 2015;**41**:272-277
- [36] Küçümen RB, Yenerel NM, Görgün E, Kohen MC, Başar D, Alimgil ML. Evaluation of changes in corneal biomechanical properties by ocular response Analyzer after femtosecond laser assisted LASIK. *Turkish Journal of Ophthalmology*. 2009;**39**:250-255
- [37] Grewal DS, Singh Grewal SP, Basti S. Incomplete femtosecond laser-assisted capsulotomy and lens fragmentation due to emulsified silicone oil in the anterior chamber. *Journal of Cataract and Refractive Surgery*. 2014;**40**:2143-2147

