

We are IntechOpen, the world's leading publisher of Open Access books Built by scientists, for scientists

6,900

Open access books available

186,000

International authors and editors

200M

Downloads

Our authors are among the

154

Countries delivered to

TOP 1%

most cited scientists

12.2%

Contributors from top 500 universities



WEB OF SCIENCE™

Selection of our books indexed in the Book Citation Index
in Web of Science™ Core Collection (BKCI)

Interested in publishing with us?
Contact book.department@intechopen.com

Numbers displayed above are based on latest data collected.
For more information visit www.intechopen.com



Myofascial Pain Dysfunction Syndrome: Etiology, Diagnosis, and Treatment

Serdar Gözler

Additional information is available at the end of the chapter

<http://dx.doi.org/10.5772/intechopen.72529>

Abstract

Myofascial pain dysfunction syndrome (MPDS) is a stomatognathic system disturbance, which consists of pain, jaw movement irregularities, and muscle spasm. Hyperexcitation of peripheral sensory neurons causes a reaction of induction in the motor neuron and then spasms of the masticatory muscles follow. Long-term spasm causes muscular pain and irregular mandibular motion. Pain is the most important inducer and therefore must be managed firstly in order to manage the muscle spasms. Symptomatic treatment approaches may be useful, but after symptom elimination, etiologically based treatment must be provided to the patient. The neurophysiology of the stomatognathic system must be well understood to determine a proper treatment for the MPDS condition. Both symptomatic and etiological treatment methods have been proposed by differing authors as potential solutions for MPDS. Occlusal splints are a commonly used treatment for relieving MPDS symptoms. Alternatively, some forms of occlusal adjustment (not all) have been shown to be an effective, permanent treatment course for myofascial pain dysfunction syndrome. This chapter describes the neural controls over the stomatognathic system and how that system can neurologically promote the MPDS disease state. It then details the computer-guided MPDS occlusal adjustment treatment known as disclusion time reduction that has been shown in many published studies to be a highly effective myofascial pain dysfunction syndrome (MPDS) therapy.

Keywords: MPDS, muscle pain dysfunction syndrome, TMD, stomatognathic system problems, masticatory muscle problems

1. Introduction

In the year 1996, the National institute of Health (NIH, USA) held a conference from which the NIH issued a pamphlet of clinical guidelines regarding temporomandibular disorders (TMD).

In the NIH report as well as from the National Institute of Dental Research (NIDR) (NIH publication no. 94-3487), no distinction was made between temporomandibular disorders and myofascial pain dysfunction syndrome (MPDS). All potential etiological factors, clinical symptoms, the diagnoses and the treatment recommendations fell under the single term, "Temporomandibular Disorders" [1]. There was no clear distinction made between TMJ internal derangements and myofascial pain dysfunction syndrome. Additionally, the final report did not recommend any definitive treatment for temporomandibular disorders. Although the NIH meeting attendees claimed to have solved the "TMJ problem," no consensus was reached making the conference a complete disappointment. However, later in 1999, Dr. Peter Dawson opposed the conference results in an article that was cosponsored by American Equilibration Society (AES, Chicago, IL, USA) [2]. After further numerous arguments, no consensus was found regarding the etiology or treatments that should be applied in TMD cases.

Of note is that 4 years before the release of the NIH report in 1991, Dr. Robert Barry Kerstein from Tufts University School of Dental Medicine in Boston Massachusetts had developed a T-Scan I time-based coronoplasty procedure, which focused on reducing excursive movement disclusion times [3]. According to this study, the length of disclusion time was correlated to high levels of masseter and temporalis excursive muscle activity levels [3] that were of diagnostic importance when evaluating differing etiologic factors of chronic MPDS [2]. These early studies were the beginning of a series of studies about this topic [3, 4]. As Dawson noted in his article, there had been found an evidence-based relationship between occlusion and MPDS. Often MPDS symptoms affected the chewing system mechanics because the symptoms had a close association with the dental occlusion and its relationship to the central nervous system (CNS).

Myofascial pain dysfunction syndrome is a common term that is used in other medical branches outside of Dentistry [5–7]. But in the last few decades, this term has been used in Dental Medicine to describe orofacial chronic pain [8, 9], often abbreviated in the literature as MPDS [3]. MPDS is a functional disease related to the masticatory muscles, the neural structures and the temporomandibular joint structures. MPDS syndrome can be a very uncomfortable condition for a patient. The patient can barely move their mandible, and often there is pain in the face and head area. Sometimes, the pain may extend to neck and dorsal area. Most typical symptoms are acute hypercontraction (spasm) of the muscles, and laxity of the TM joint ligaments. The symptoms of the MPDS are explained in detail later in this chapter [5, 10–12].

Etiologically, the MPDS muscle and TM joint symptoms have been linked primarily to the occlusion [2, 3, 13, 14]. Muscle spasm is caused by occlusal surface friction and prolonged disclusion time overcompressing the posterior tooth PDLs causing hyperfunction and ischemia in the muscles. This leads to muscle fatigue and then poor mandibular movements. This is what leads to deterioration of the movements.

Muscle spasm is usually caused by occlusal surface friction and prolonged disclusion time [15] overcompressing the posterior tooth periodontal ligament mechanoreceptors causing hyperfunction and ischemia in the muscles. This leads to muscle fatigue and then poor mandibular movements [16].

The deterioration of mandibular movements can be accelerated by deterioration of the occlusion. A filling, crown, or a bridge will always cause the occlusion to deteriorate. Alternatively,

ligament laxity affects the movements of the joint structures in the glenoid fossa and often occurs without patient awareness of the problem's existence.

Myofascial pain dysfunction syndrome (MPDS) is one particular type of temporomandibular disorder (TMD) [12]. Historically, clinicians and researchers have subclassified TMDs into either intracapsular disorders or masticatory muscle disorders (such as local myalgia, myofascial pain, centrally mediated myalgia, myospasm, myositis, myofibrotic contracture, and masticatory muscle neoplastic disease). TMJ internal derangement may not be involved with MPDS. However, when a temporomandibular joint irregularity occurs along with the symptoms of MPDS, the complete problematic condition should be considered as temporomandibular joint disease [17, 18]. All masticatory organs participating in oral function may or may not be involved in MPDS.

Before discussing about the etiologic factors and treatment techniques related to MPDS, it is necessary to properly understand the neural mechanisms of masticatory system.

Muscular pain is a typical and a decisive symptom of MPDS. Functional disorders that occur in the stomatognathic system are a cause of pain. If the functional disorders are not successfully treated, pain may be present for years. Pain minimization during function is the result of the protective mechanisms within the stomatognathic system.

The most important stomatognathic function is chewing. There is a great relationship between impairment of chewing function and painful muscle problems [13, 16, 17, 19–24]. During the chewing function, tooth contact occurs at the extreme end of the chewing cycle when occlusal force is applied to crush the food bolus. In this way, the resultant chewed food is readied for swallowing. For the chewed food product to be effectively prepared for swallowing, all related functions must occur in a harmonious order. Hence, the duration of chewing, the control of the mandibular movements, the masticatory muscle contractions, the level of force applied during the bolus crush, temporomandibular joint movements, the tooth-tooth interactions, and the neural feedback mechanisms all must interact synergistically (**Figure 1**).

The relationship between muscle malfunction and MPDS is a two-sided problem, where each affects the other. Muscle malfunction triggers MPDS, while MPDS causes impairment of masticatory movements. Stomatognathic system functions are the best diagnostic indicator of dysfunction. The main purpose of the stomatognathic system is to perform the best chewing possible, which requires a very well-coordinated system. As proper chewing evolves within the developmental period of human growth, it becomes optimal during the adult years. Deciduous, mixed, and permanent dentitions have their own chewing patterns [25], with the chewing pattern being closely linked to a person's dental condition [24]. However, corruption of the chewing pattern indicates the beginnings of myofascial distortion [26, 27].

As is the case with other body functions, the chewing pattern results from a complex integration of the neural and the myofascial structures. The resultant product of chewing is chewed food that is readied for swallowing. The most effective determining factor of a good chewing pattern is the dental occlusion [28], whereby the structural posture, the stretching of muscles and the chewing process itself are improved by upper and lower tooth contact. However, changes to the dental occlusion from tooth loss, orthodontic tooth movement, restorative dentistry, or mechanical trauma, all of which can alter the neurologic input significantly, may be the most important etiological factor leading to the impairment of chewing mechanism [19].

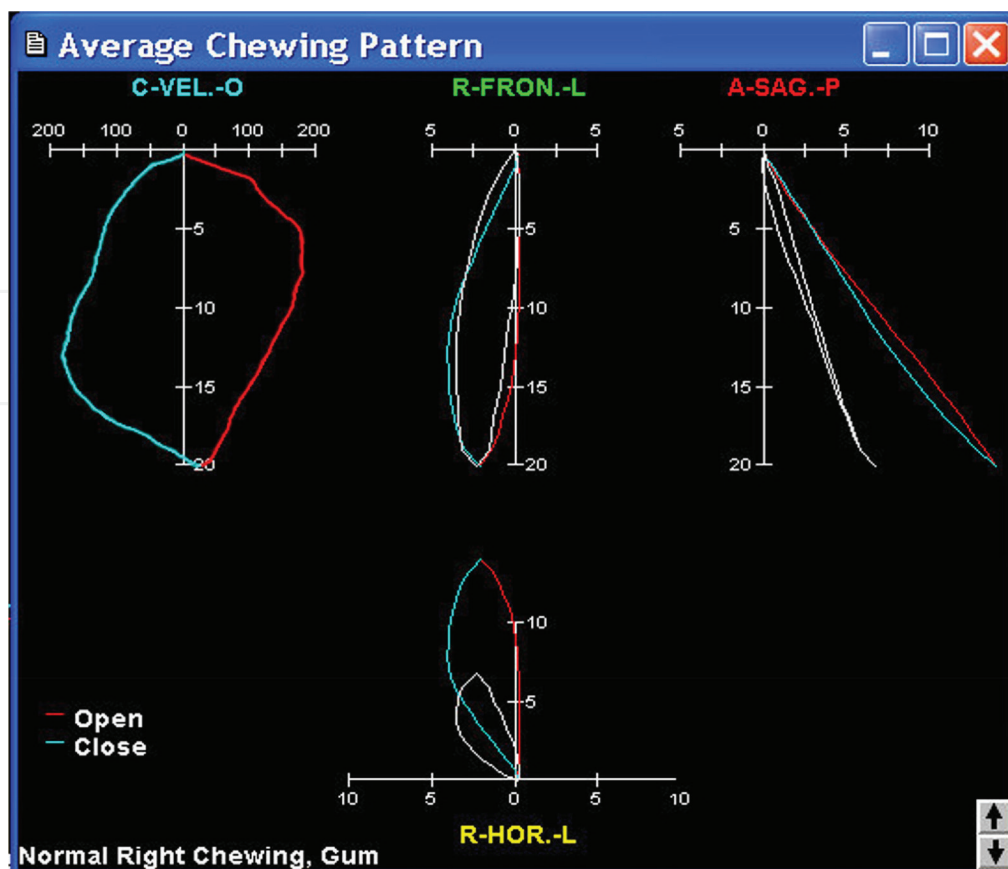


Figure 1. A normal mastication pattern in three planes as recorded by a Jaw Tracker (3-D Electrognathograph, BioResearch Assoc., Milwaukee, WI, USA). Excellent chewing ability evolves in the developing human from youth into the adult years. An ideal chewing pattern requires harmony between all the masticatory functional organs.

Nervous system mechanoreceptors in and around the teeth transmit neural information to the central nervous system (CNS) regarding the nature of the masticatory function. This neural feedback mechanism is designed to protect the physiologic borders of the chewing pattern and controls the masticatory system mechanics. Neural sensors collect all the necessary neural input during chewing function as it is a sensory process. However, the mandibular functional and parafunctional movements are controlled by the motor function of the neural system. The neuromuscular mechanism of stomatognathic system collects the neural input that controls mandibular motion [29, 30].

2. Neuronal mechanism of masticatory system

Myofascial pain dysfunction syndrome (MPDS) can be used as general definition for one type musculoskeletal human disease state that consists of specific muscular symptoms. In a patient with temporomandibular disorders, MPDS often results from the hypercontraction of the masticatory elevator muscles. Spasm of one or more elevator muscles is a serious problem, which may cause pain, muscle tenderness, limitation of mandibular movements, and induce changes in the temporomandibular joint structural alignment. Muscle spasm usually emanates through the central nervous system (CNS) from the neural mechanoreceptors located

in and around the teeth that hypercontract the elevator muscles. Along with muscle spasm, painful trigger points can also be a component of the MPDS condition. Some trigger points may be classified as latent [5, 6, 31, 32], in that they only occur when a muscle is pressed upon.

The neuronal mechanism is a determining factor in the development of MPDS. The central nervous system (CNS) controls all activities of the masticatory system including the contraction of masticatory muscles, the sequence of contractions, the level of contraction, the posture of mandible, the mandibular movements, and the resultant occlusal force, all of which are influenced by the occlusal relationship of upper and lower teeth [33]. The control mechanism of the nervous system is based on environmental neural data input. Every function of the masticatory system has a characteristic pattern that occurs within certain physiologic limits. Any overreaching from a physiologic limit can lead to a symptom of a particular problem. For example, any deviation in the opening (or closing) movement of the mandible is often the result of a muscle spasm that occurs during the opening movement. Limited mouth opening mouth (or S-shaped masticatory movement) is also an indication there is a problem within the stomatognathic system. Functional movements that designed by central nervous system (CNS) are outside of their physiologic limits. Many pathological conditions can also be produced by the central nervous system (CNS). If there is a strong but problematic feedback mechanism present in stomatognathic system, certain pathological conditions may increase in frequency and intensity, unless the pathology is not removed. Every type of nonphysiological movement has its own specific characteristics.

3. Central nervous system and the stomatognathic system

The neural system mechanics must be very well understood to ascertain the etiology of a stomatognathic system pathology.

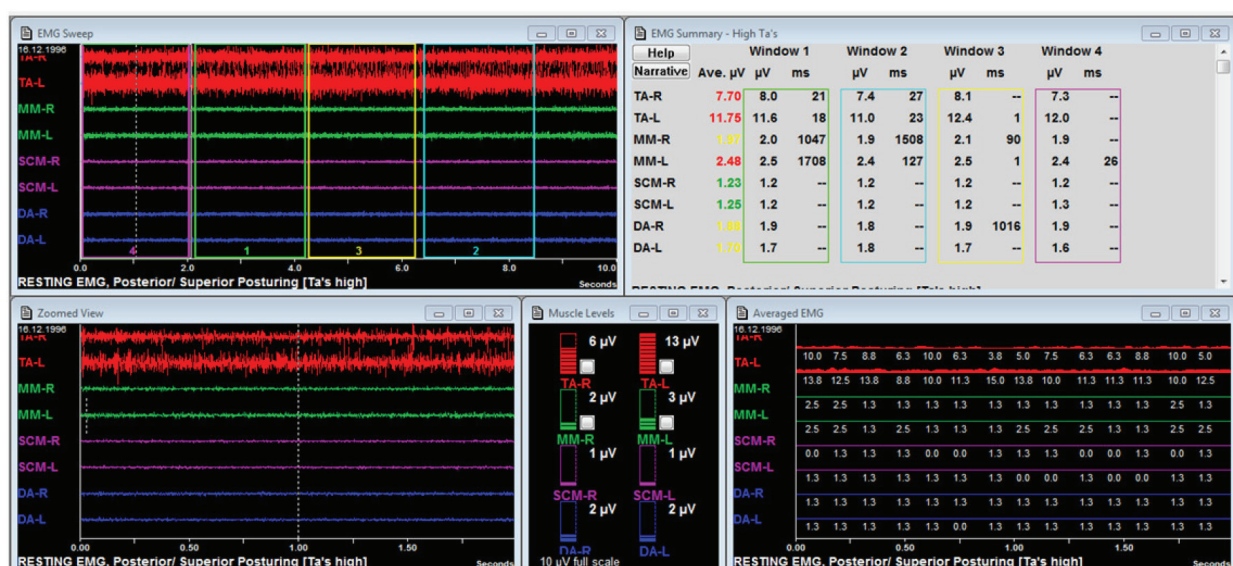


Figure 2. A resting EMG recording of the masseter and temporalis muscles. Note, there is slight electrical activity providing tension to these muscles when holding the mandible in the rest position.

The stomatognathic system neural network is comprised of three basic parts:

1. Perception of the sensory inputs.
2. Evaluation of the gathered inputs.
3. Reaction to the inputs.

Sensory input collection is an ongoing function of the neural system that can be conscious or unconscious. There is a continuous data stream entering the CNS from the peripheral nervous system (PNS), which gathers environmental data that send impulses to the masticatory muscle fibers to establish postural tonus activity. This occurs even when there is no function, such that there is a slight tension in the muscles when at rest (**Figure 2**).

4. Neurons and myocytes (muscle cells)

The human body consists of billions of similarly constructed cells that contain the cytoplasm, a nucleus, some chromosomes, some mitochondria, and some ribosomes. But some cells are different from the ordinary cells, despite that they also have cytoplasm, a nucleus, and ribosomes, but also contain neurons. Neurons and muscle cells are an excitable type of cell because they can receive electrical impulses and transfer the environmental neurologic data biochemically. These special cells are known as inducible cells.

The functional unit of the motor system, the motor unit, is composed of a motor neuron and a group of muscle fibers with similar, if not identical, structural and functional properties. These are inducible cells known as neurons and myocytes (muscle cell).

5. Membrane potential difference and the firing of a neuron

There is a static electrical balance between the outside and inside of a cell membrane. This steady state is called the “resting membrane potential,” which does not change unless there exists a stimulus. This steady-state electrical potential difference between the outside and inside of a cell membrane is between -50 mV and -100 mV. A stimulus changes this steady state to an action state, whereby the resting potential difference is turned into an action potential difference. The main cause of the potential difference results from the existence of anions and cations on both sides of the cell membrane. Outside the membrane are positively charged sodium cations. Positively charged sodium ions attach to negatively charged chlorine ions (Cl^-) that are outside of the membrane. However, despite the presence of negative ions (such as chlorine and HCO_3^-), the outer side of the membrane remains positively charged. Alternatively, the inside of the membrane is negatively charged because positively charged potassium (K^+) ions diffuse “down” its steep concentration gradient to move out of a cell via leakage channels. This K^+ ion movement to outside of the cell membrane makes the outside more positively charged than inside the cell membrane. Outside the positive ions side at the edge of the membrane, with the inside negative ions located at the inner edge of the membrane.

Therefore, the electrical potential difference exists on both sides of the membrane. A change in the electrical activity within the cell membrane plays an important role in the character of sensory conduction.

6. Neural receptors in the stomatognathic area: the collection of peripheral data and the neural response

All masticatory system functions are governed by the central nervous system (CNS). In order to coordinate what function occurs, and when, how much, and how it should occur physiologically, the CNS gathers information about the environment in which the function is to take place. There is a continuous flow of information between the sensory and motor neurons within the stomatognathic system and the central nervous system (CNS). Physiologically, proper oral functions like mastication, swallowing, and speaking need a rhythmic process whereby all parts of the masticatory system are coordinated so that the activity of the jaw muscles, the tongue, the cheeks, and the lips work synergistically to achieve correct function.

There are two basic neurologic components of mastication:

- the central pattern generator (and the)
- the peripheral control mechanisms

For controlling and managing oral function, the central nervous system (CNS) must initially sense the environmental data. This data collection process is provided to the CNS by the mechano and sensory receptors of the peripheral nervous structures (PNS). Data collected from these receptors are transferred to the other levels of central nervous system (CNS). These receptors are specialized neurons for gathering the environmental sensory data related to the many sensorimotor functions, involving the coordinated contraction and inhibition of the musculature located around the mouth, at the tongue, larynx, pharynx, and esophagus bilaterally [34]. Moreover, according to the localization of the function, there are many differing types of receptors present in the mouth. The data received from receptors are transferred electrochemically to differing levels of the central nervous system (CNS). In this way, the peripheral neural control modulates the output of the central pattern generator and associated motor neurons, so that most effective occlusal forces are developed during chewing, without overly damaging the masticatory organs.

Transmission of the peripheral neural data is provided to the CNS by a neuron's axons and dendrites. Dendrites receive the potential from the previous neuron. If a nerve cell is stimulated, the transmembrane voltage is necessarily changed. The stimulation may be excitatory or inhibitory. If the membrane stimulus is insufficient to cause the transmembrane potential to reach the threshold, then the membrane will not activate. If the excitatory stimulus is strong enough, the transmembrane potential reaches the threshold, and the membrane produces a characteristic electric impulse, known as the *nerve impulse*. This is the basic principle of the stimulus and transmission of a neuron.

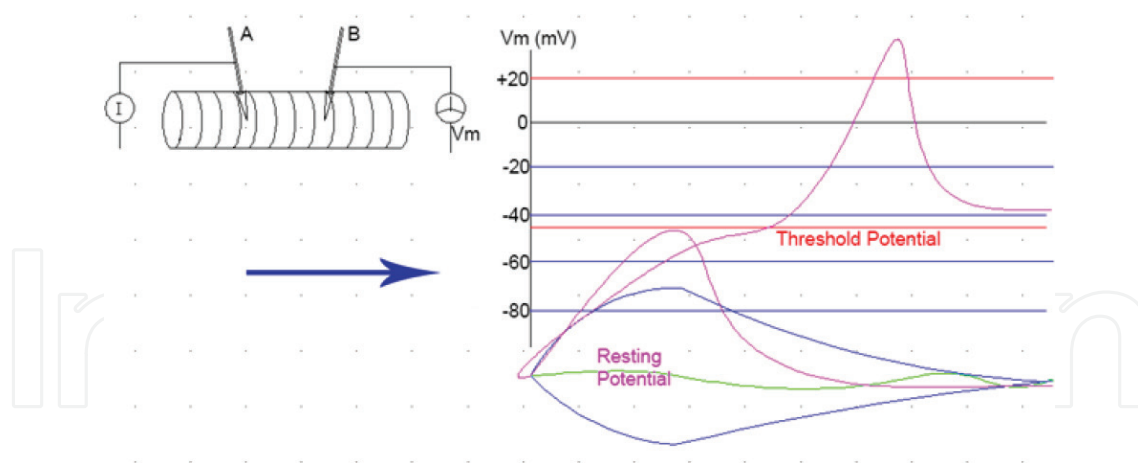


Figure 3. A very tiny premature contact that is not removed for a long time will have a sufficient excitatory level for instigating a nerve impulse. When the total sum level of stimulus reaches the threshold level, an action potential can emerge. This is known as the All-or-None principle.

The membrane potential may reach the threshold by a short, strong stimulus, or by a *longer, weaker stimulus*. A very tiny premature contact that is not removed and is clinically present for a long time will have a sufficient excitatory level for starting a nerve impulse (**Figure 3**). This is the result of nerve cell's All-or-None principle. Premature contacts can lead to pain, which then leads to the formation of a stronger stimulus. The CNS sends a nociceptive warning to the muscles to move the mandible toward the opposite arch side as a reflex action to lessen the pain. If the premature contact on one side was not removed, spasm on the other side tends to persist. Aggregating stimuli will increase the spasms, which may be a major etiological cause of myofascial pain dysfunction syndrome [14] (**Figure 3**).

A sudden nociceptive stimulus can cause a special type escape reflex known as the “jaw jerk reflex.” The jaw-jerk myotatic reflex is activated by the sudden stretching of the jaw-closing muscles spindles. The jaw jerk reflex is one of the most important neuronal patterns as it may or may not be nociceptive. The repetition of nociceptive stimuli that causes a reflex action early on during the development of dysfunction may after awhile cease to exist. This adaptation to the stimulus initiates the failure of the CNS to continue to respond to the stimulus. With the jaw jerk mechanism reflex over time, this insensitivity to further immediate noxious stimulation develops irritated neural tissue, which worsens from the intense and prolonged stimulation [7]. This worsening can lead to reduced mandibular vertical opening (**Figure 4**).

Information from the peripheral nervous system (PNS) tissues outside the CNS is continuously transferred into the CNS onto higher centers in the brain stem and cortex for interpretation and evaluation. All human functional and parafunctional movements are based on five major sensory systems:

- Olfaction
- Taste
- Vision
- Hearing
- Touch

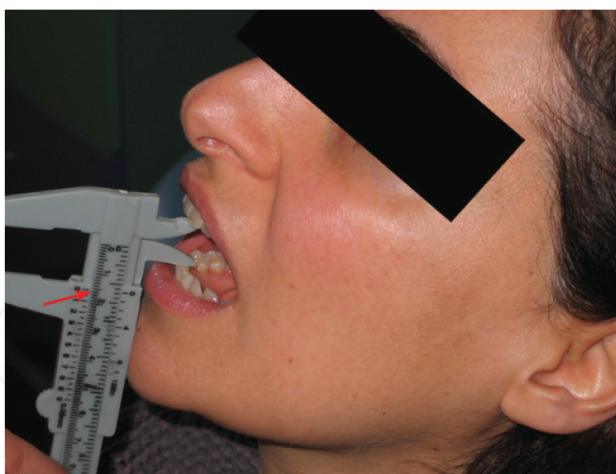


Figure 4. Spasm of the elevator muscles and limited maximum mouth opening of less than 25 mm indicates this women exhibits significant muscular dysfunction. This critical distance of healthy limited opening in men is 35–40 mm.

Touch sensory activity (Touch) is the critical neurologic control for the stomatognathic system's functional and parafunctional movements.

Neural receptors perform two important tasks:

- The gathering of sensory information
- The transfer of the sensory response into the CNS and then back out to the muscles.

Mandibular functional movement sensory detection and the associated reflex responses are shaped by information gathered from the periodontal ligament mechanoreceptors in response to tooth compressions during chewing and from the temperature and touch receptors present in the pulp, the gingival tissues, and the mucobuccal tissues. One of the most important neural receptors is the pulpal mechanoreceptors, which together with periodontal mechanoreceptors carry tooth loading information to the CNS. These receptors transmit the intensity of force acting on a tooth as it contacts its opposing tooth counterpart, the changes of the force velocity at occlusal impact, a tooth's movement direction during chewing, and the hardness of the food bolus. Moreover, the periodontal ligaments are also extremely important structures because their mechanoreceptors within the PDL are highly concentrated [34–38]. Receptors in the periodontal ligaments control and guide all functional and parafunctional movements because they relay information about the magnitude of tooth loads, which is described by the mean firing rate response of loaded periodontal receptors [34].

Several studies have indicated that the extracellular matrix collagens of the periodontal ligament have a high turnover and remodeling rate that are much higher than collagen turnover observed in the gingiva, skin, and bone [39]. The periodontal ligaments themselves are basically striated muscles with muscle spindles located within the fibers of the ligaments. These ligament fiber muscle spindles gather stretching and compression information when teeth are under tooth movement within the PDL space.

Periodontal mechanoreceptors respond to the forces that are applied to teeth. They have been studied in histological and electrophysiological investigations that illustrated periodontal mechanoreceptors signal information about the degree of tooth loads because they have special

force-encoding properties, which provides for functional control of human mastication. Microneurography recordings from single nerve fibers revealed that human periodontal receptors adapt slowly to maintained tooth loads. Most receptors are broadly tuned to the direction of force application, while about half respond to forces that are applied to more than one tooth at a time. Populations of periodontal receptors reliably encode information about both how the teeth are stimulated, and the direction that forces are applied to the individual teeth.

Another important receptor type is “periodontal ligament integrins” [40], which are cell-surface receptors that connect cells to the collagen-rich and mechanically stressed periodontal ligament microenvironment. Mutations in integrin subunits have been found to cause clinical disorders in man that correlate well with mice, in which the same integrins are deleted [40]. Integrins are able to transduce signals intracellularly following ligand binding (“outside-in” signaling). However, unlike most other cell receptors, integrins can shift between high- and low-affinity conformations for ligand binding, whereby the signal direction is reversed (“inside-out” signaling). Depending on the cell type, integrins can be either basally activated, as is the case with most adherent cells that are attached to a basement membrane, or they can be basally inactive, like platelets or leukocytes that freely circulate until activated to undergo platelet aggregation or mediate an inflammatory response [41].

Ultimately, all the collected load data from the pulp, the periodontal ligament receptors, and the mucosa are transmitted to the CNS via the trigeminal nerve (V) ganglions. Ganglions are the neurologic distribution center for both the afferent and efferent neural pathways.

Basically, there are two important ganglions involved in craniofacial area with neuroanatomic ties to the stomatognathic system:

- Trigeminal ganglion
- Mesencephalic nucleus

6.1. Pain: an alarm system for protection of the body

Living organisms need to be able to sense their immediate environment if they are to withdraw from or avoid potentially hazardous situations. One of the most typical examples of this protective mechanism is jaw jerk reflex. Sudden, strange matter that is perceived during chewing leads to the formation of this reflex. However, shortly after the identification of a hard substance, the central nervous system (CNS) reduces the reflex level to normal levels. Sometimes, the jaw jerk reflex may occur as a nociceptive reaction. For example, touching the pulp meter to the tooth surface can lead to a typical jaw jerk reflex.

Reflexes are involuntary and relatively stereotyped responses to specific stimuli. Stimulated receptors send afferent impulses to the central nervous system (CNS), which are then transmitted through efferent nerve fibers to the cells, muscles, and organs that carry out the *reflex response*. The entire pathway is known as the *reflex arc* [42]. The afferent impulses generated at the receptors are conveyed via fast-twitch Ia fibers to the spinal alpha motor neuron. Their α_1 process impulses excite the agonistic muscle of an opposing muscle pair. Despite the monosynaptic nature of intrinsic reflexes, extrinsic reflexes are polysynaptic, where there are both afferent and efferent arms within the chain of spinal interneurons.

A protective reflex is not continuous because the reflex stimulus is defined in the memory, and after few cycles, it does not cause the repeated reflex. Development of the multicellular structures in the nervous system evolves a specialized apparatus that detects and reacts to external stimuli, when combined together with the evolution of specific transduction proteins, and enables the CNS to accurately differentiate between innocuous and noxious stimuli. This early warning system, which is further elaborated, develops the capacity to increase its sensitivity following an exposure to an injurious stimulus, which is known as nociceptive sensitization. In mammals, the early warning protective pain that occurs in response to noxious stimuli (nociceptive pain) is mediated by specialized, high-threshold primary sensory neurons (nociceptors) [43].

Pain management is one of the most important therapeutic interventions. Chronic pain is the main reason that patients seek out health care, while also being the most common reason for disability and addiction, and being the highest driver of health care costs. Most often, myopain conditions are the pain source. As such, it has been reported that in the United States, more than 100 million adults suffer from myofascial pain dysfunction syndrome. In dentistry, MPDS is defined as one type of masticatory system problem [32]. However, myofascial pain (MFP) is the most common cause of persistent regional back pain, headaches, and facial pain [10].

Myofascial pain is pain that arises from the muscles or the related fascia. The trigger point concept has been a widely studied aspect of myofascial pain dysfunction syndrome. Many hypotheses of how trigger points evolve are based on the opinions of experienced clinicians who treat and research trigger points. Trigger points are most often discussed as a component of myofascial pain syndromes where widespread or regional muscular pain is associated with hyperalgesia, psychological disturbance, and significant restriction of daily function [44]. Trigger points are 2–5 mm diameter points of increased hypersensitivity in palpable bands of the skeletal muscle, tendons, and ligaments with decreasing hypersensitivity as one palpates the band further away from the trigger point. As stated before, trigger points may be active or latent. An active trigger point causes spontaneous pain at rest, with an increase in pain on contraction or stretching of the involved muscle. There is often restricted muscular range of motion. Any pain on motion may cause “pseudo-muscle weakness” due to pin reflex inhibition. A latent trigger point is a focal area of tenderness and tightness in a muscle that does not result in spontaneous pain, but must be palpated to elicit the pain. However, a latent trigger point may restrict the range of motion and result in weakness of the muscle involved.

The characteristic symptoms of a myofascial pain dysfunction syndrome trigger points have been previously described by R. Bennett as follows [5]:

1. A focal point of tenderness to palpation of the muscle involved,
2. Patient complaint from trigger point palpation,
3. Palpation reveals an induration of the adjacent muscle (the “taut band”),
4. A restricted range of motion in the muscle involved,
5. Pain is accompanied by pseudo-weakness of the muscle involved,
6. Referred pain can result with continuous applied pressure on the trigger point that lasts approximately 5 s in duration.

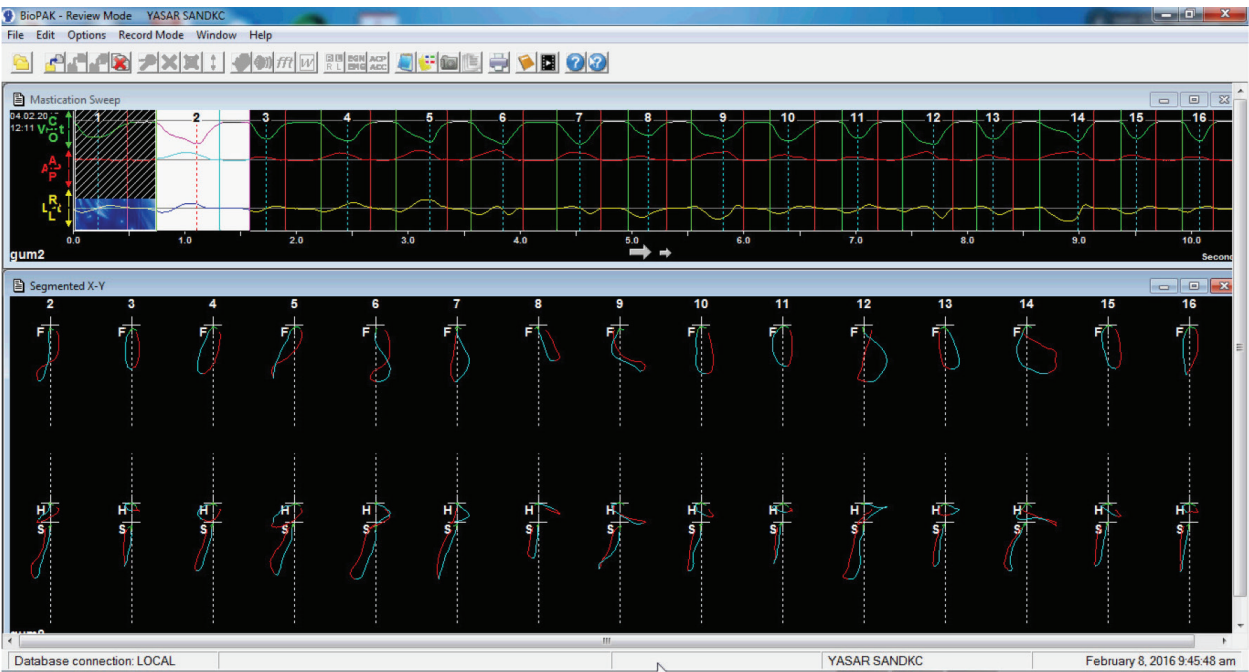


Figure 5. Irregular masticatory pattern of a patient with new denture while the CNS tries to develop a new chewing pattern to accommodate the new denture. Chewing patterns are not similar to each other and irregular.

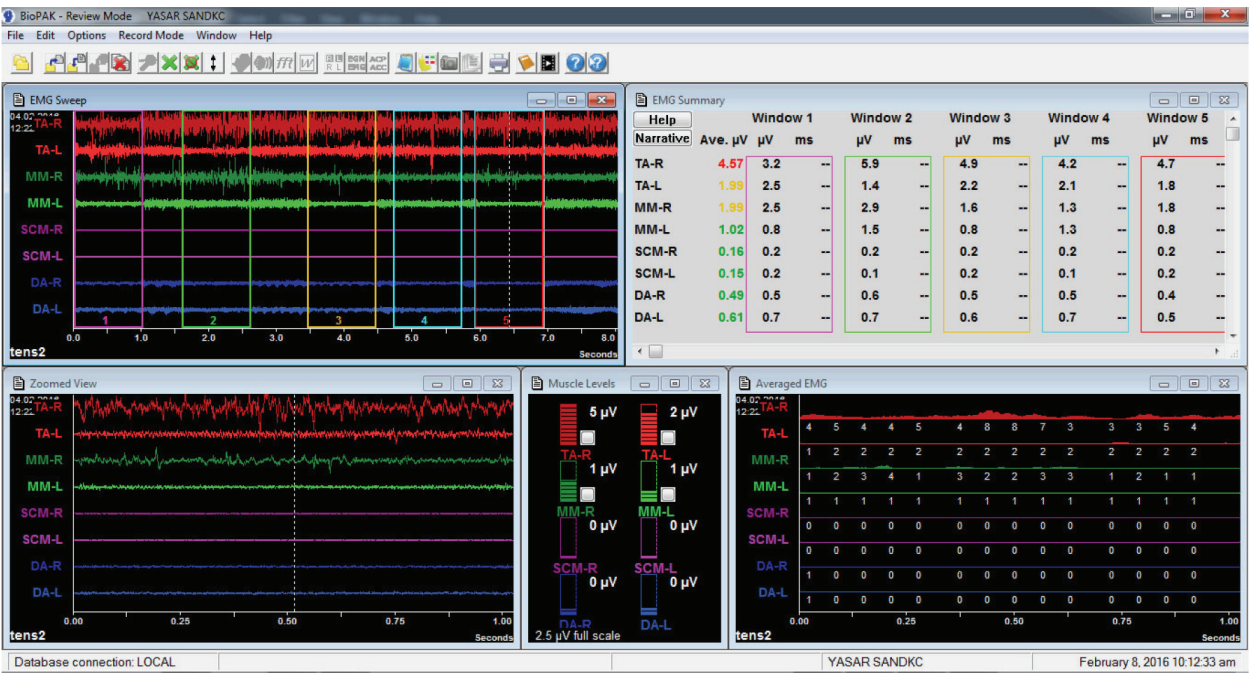


Figure 6. Both the temporalis and masseter muscle electrical activity levels are higher than the physiological average resting values. This is not unexpected during the development of new prosthesis adaptation.

Pain perception is not simply determined by the intensity of nociceptive stimulation but also depends upon psychological factors such as the emotional and motivational state of the patient. The chronic pain threshold is divergent from the patient's level of fear and/or anxiety [45]. Memory and pain, though two richly diverse fields, have many underlying commonalities. Both,

for example, contain conscious and unconscious processes that allow for the acquisition of altered behavior in response to environmental stimuli [46]. After a very hot liquid is brought into the mouth, this warm sensation will be placed in the permanent memory to be remembered easily in later scenarios where the patient will drink a very hot liquid once again. However, if a new hot liquid experience is repeated a number of times over a long time frame, the patient's reflex response to hot liquid will slowly disappear. As a learned function repeats, it becomes a reflex state.

A new complete denture adaptation process a patient must go through when receiving a different prosthesis than they are physically used to involves the development of a new denture chewing model. If the new prosthesis causes pain, the pain will be perceived as more prominent in the patients' psyche, compared to the known chewing pattern of the old denture that was saved in the patient's memory. The central nervous system (CNS) will develop a reflex protective mechanism against the pain, such that the protected pattern of chewing will take a very different shape from a healthy average chewing pattern (**Figure 5**).

The electromyographic record of the same patient with the new denture shows that all four elevator muscles are in hyperactivity, exhibiting higher than the average values (**Figure 6**).

7. The importance of breaking the pain cycle in treatment of MPDS; the role of occlusal splints

Chronic pain is a habitual pattern generated by the central nervous system (CNS) that must be broken before trying to treat myofascial pain dysfunction syndrome.

Chronic pain is a nonphysiologic and extraordinary somatosensory process that can take place either in the peripheral or central nervous systems that is sustained beyond the normally expected time frame relative to the existence of a stimulus. This scenario, although somewhat explanatory, only provides for part of the story. Chronic pain is often clandestinely ambiguous and can be difficult to pinpoint its primary causative location. The perception of pain results from the summation and culmination of the nerve transduction process that arises from temporarily stimulated and affected peripheral nociceptors. Nociceptors may be specific for painful stimuli or they may be generally responsive to a wide range of mechanical, thermal, chemical, and/or electrical stimuli. Nociceptive responses are transmitted from peripheral sites into the CNS via myelinated (type A-delta) or unmyelinated (type C) nerve fibers [47].

Masticatory system myofascial pain constitutes one of the most important chronic problems that is encountered in clinical dental practice. Pain is a critical factor in evolving this chronic problem because pain increases muscle contraction, and more spasms from the excess contractions increase the level of pain. Elongation of the contraction time leads to the formation of trigger points.

Within the literature, dental occlusion appears to be a key causative agent for MPDS because all kinds of treatment suggestions for MPDS are targeted on changing the occlusion in some way. In a study by Laskin et al. [48], the authors remarked that although many aspects of the MPDS are either controversial or unexplored, most investigators and clinicians seem to agree

that the majority of patients with MPDS report relatively rapid improvement or symptom disappearances with splint therapy [48]. Splint therapy is a very effective occlusion determinant because when splint is placed between occluding teeth, the occlusion changes dramatically which can quickly break the pain generating pattern. However, all researchers agree that a splint therapy protocol must be provided by only skilled clinicians.

There are many types of splints in dentistry such as custom splints, prefabric splints, posterior splints, anterior jig, hard splints, soft splints, etc. Each splint is described in detail by its advocate. The following factors should be taken into account during splint construction [44, 49]:

1. The treatment protocol must be provided by skilled clinicians
2. All masticatory activities can be changed by changing the occlusion
3. Splint therapy changes the tooth-to-tooth occlusal relationships, which then changes the neuromuscular activity accordingly
4. Prolonged hyperactivity of muscles can cause heightened synaptic transmission. Consequently, long contraction durations decrease action potential threshold levels and decrease the patient's pain threshold.
5. During the use of a splint, there must be careful follow-up; if complications occur from splint treatment, the therapy should be terminated immediately.
6. If the splint is only used for a temporary occlusal correction, a 3–4 day use period should be sufficient. The best splints to be used for this purpose are either hydrostatic splints or hard splints because the surface of these designs does not allow teeth to engage and clash, which allows the masticatory muscles to freely exist in a harmonic balance.
7. After acquiring muscle balance and improved physiologic muscle contraction reestablishment, splint therapy must be stopped and an etiological treatment must be initiated.

Basically, splints are applied for a specific purpose [48, 50–52]. Therefore, it is very important to determine the type of splint, application period, and schedule, if applicable (**Figure 7**). Using a proper splint for a longer period of time may cause the patient to worsen in a variety of ways (worsening of MPDS symptoms; creating an open occlusion, intruding of teeth out of occlusal contact). Hence, splint treatment duration and its daily schedule are important to manage properly.

7.1. Occlusal analysis and occlusal adjustments

Removing of premature contacts with occlusal adjustment is one of the most important methods for breaking the neuromuscular cycle in myofascial pain dysfunction syndrome [53]. Changing the occlusal scheme and balancing of the occlusion are very effective methods for pinpointing and eliminating extraordinary neural firings. Hence, an occlusal analysis has always been an important diagnostic component of the treatment efforts to resolve MPDS symptoms. Several decades ago, dentists were performing occlusal analysis solely with mounted casts on semi-adjustable or fully adjustable dental articulators. There was no scientific method for performing intraoral occlusal analysis, and no real effective way to measure occlusal forces between all the contacting teeth.

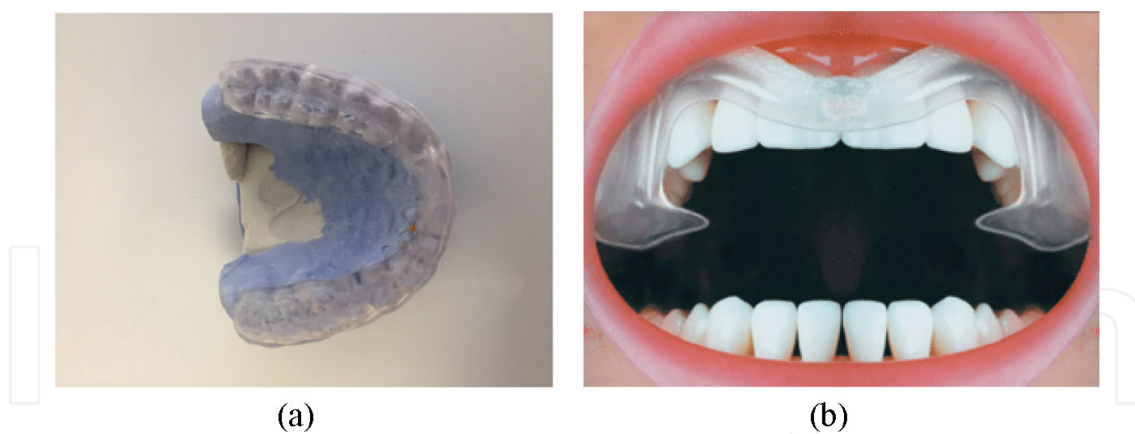


Figure 7. Splint therapy must be performed by a skilled clinician. Hard splints are very effective for changing the occlusal relationship between upper and lower jaws (maxillary splint; left pane). Hydrostatic soft splints (right pane) are helpful in creating muscular balance and physiologic harmonization. An etiologically based treatment for MPDS can be instituted after 3–5 days of successful splint therapy.

The very simple principal rule that was widely believed, purported is that proper occlusal function resulted from the close relationship between condylar movements and the occlusal contact relationships. To utilize this thinking clinically, most articulator systems were designed with the following requirements:

1. Some special equipment was built to detect condylar movements. The Lauritzen Hinge Axis Locator [54, 55] or Condylator Joint Tracer [56, 57] are examples of these types of condylar movement analysis tools. However, these devices are not easy to manage, often require repeated and difficult-to-make registrations, both intra- and extra-orally [58].
2. Completion of the condylar tracing procedure usually requests more than one visit.
3. Registration of centric relation location needs special devices and careful working.
4. Articulator-based diagnostic work is not repeatable and cannot be digitally stored. It is difficult to compare two different analyses on the same articulator, as one must be removed to mount another set of casts.
5. Two different registrations may be quite different, spatially. This difference can arise from making registrations at different times of the day for both the operator and the patient, from impression material setting distortion, registration material setting distortion, and from differing degrees of poured stone setting contraction. Because many variables come into play with the articulating of dental casts, precision levels of the differing analyses may be quite inconsistent from one analysis to another.

Therefore, occlusal analysis performed on articulators for occlusal adjustment can be difficult and time-consuming; and once completed, it is not necessarily reliably to be accurate for diagnosis and treatment.

The development of the computerized occlusal analysis method (T-Scan 9, with the Novus Recording Handle, and the HD Recording Sensor, Tekscan, Inc. S. Boston, MA, USA) has been

removed from the making of occlusal analyses, the necessity of using inaccurate articulator-based methods, which present the clinician with many challengers that complicate their clinical usefulness.

7.2. Computer-based occlusal analyses and computer-guided occlusal adjustments

Computer-based occlusal analyses have many clinical advantages over the articulator-based method:

1. Digital occlusal analysis is usually completed in one session. It can be repeated at another session, if there is a need.
2. Digital occlusal analysis data can be stored and recalled easily, so that many analyses of a single patient can be compared with each other, over time, to observe changes in the occlusal status as the patient ages.
3. The recording and data acquisition is quick to accomplish chairside, so that many occlusal analyses and corrective adjustments can be performed in same treatment session.
4. Adjustment results can be compared with the preoperative status of the occlusion to observe that occlusal force and timing improvements have been therapeutically obtained.
5. The cost of performing the occlusal analysis has decreased sharply.

As with every new method, the earliest T-Scan computer-based occlusal analyzing systems (T-Scan I, II, III; Tekscan Inc. S. Boston, MA, USA) were questioned as to their clinical reliability [59, 60]. However, the modern The T-Scan HD recording sensor (**Figure 8a**) has been shown to accurately measure 256 differing relative occlusal force levels [3–6, 55, 61] with 95% of force reproduction capability [4]. Other recent T-Scan studies show the T-Scan accurately records occlusal contact time sequencing [62, 63]. Today's T-Scan Novus System with the version 9 software is a highly advanced digital occlusal force and timing analyzer that can be used



Figure 8. (a) The T-Scan Novus Definition (HD) sensor records 256 levels of relative occlusal force in 0.003 s time frames to reveal an occlusal playback video that illustrates changing occlusal force levels across time. (b) The T-Scan Novus recording handle with the HD sensor in place, connected directly to a computer with a USB plug.

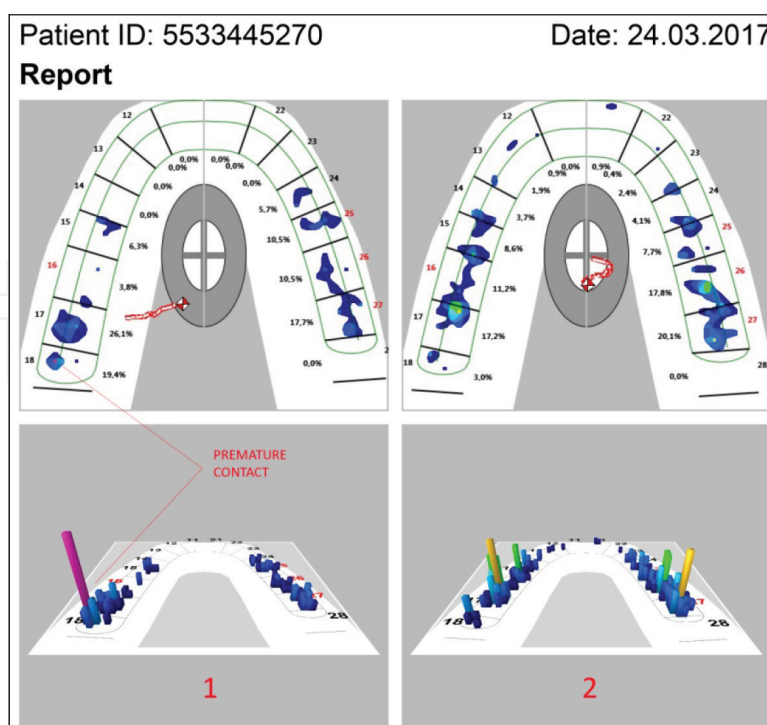


Figure 9. Premature contacts are contacts that rise to very high force well before the maximum intercuspal position (MIP) (pane 1) are visible with the T-Scan occlusal analysis system. Tooth #18 rises quickly to high occlusal force (tall pink column; left pane #1), as other closure contacts are low force (dark blue columns; left pane #1). Then later in the same T-Scan recording (pane 2), the #18 forceful contact lessens to low force while other occluding teeth increased in force bilaterally (pane #2).

chairside to treat a wide range of commonly encountered occlusal force problems. Moreover, additional research and clinical publications have illustrated how the T-Scan occlusal analysis method can be used in many dental medicine disciplines (**Figure 8a and b**) [64–67].

The correction of orthodontic and prosthodontic occlusal problems has become much easier for clinicians who use computerized occlusal analysis. Prior to the development of the T-Scan, dentists could only “look at” the occlusion, and now with T-Scan sensor interposed between occluding teeth during mandibular functional movements, dentists are able to see occlusal force changes over time as occlusal contacts on opposing teeth engage and interact frictionally (**Figure 9**). Note in **Figure 9** how during the early part of a patient self-closure into MIP, tooth #18 rises quickly to high occlusal force (tall pink column; left pane #1), as all the other closure tooth contacts maintain a low force state (dark blue columns; left pane #1). Then later in the same T-Scan recording, when more of the patient’s teeth fully interdigitate closer to complete intercuspation, the #18 premature forceful contact lessens to a low force state, while other occluding teeth increased in force bilaterally (light green and yellow columns: right pane #2).

7.3. Disclusion time reduction therapy with the immediate complete anterior guidance development coronoplasty

Changing occlusal relationships between the upper and lower teeth breaks sharply the neuro-muscular loop that causes acute muscle spasm. There are many studies that have shown the effect periodontal receptors have on functional and parafunctional occlusal excursions [34–38, 68]. An

occlusal movement is modeled within the central nervous system (CNS), but the main trigger of action potential firing is the excitation of peripheral neurons from the peripheral nervous system (PNS) [33]. Continuous peripheral neuronal firing causes ongoing muscle contractions that lead to muscle fatigue and ischemia from toxic lactic acid buildup, which all ultimately leads to muscle spasms that rise and repeatedly peak, unless the continuous neuronal firing stopped.

This neurologic mechanism is the main reason why adjusting the dental occlusion with T-Scan time-based occlusal surface modifications has been highly effective MPDS therapy [4–38, 59, 69–71]. Applying occlusal splints, local anesthetic injections, botox injections, and similar nonocclusal treatment methods are temporary and symptomatic. Orthodontic treatment, restorative dentistry that changes the occlusal relationship, and occlusal coronoplasty are treatments aimed at the neurologic etiologically and are permanent treatment methods.

It has long been advocated that to achieve a balanced occlusal relationship, the acute spasm must be eliminated before commencing definitive occlusal changes. Occlusal splints are the most common method for eliminating the acute symptoms of MPDS. However, since 1991, a new T-Scan-based “Disocclusion Time Reduction Therapy (DTR)” method has been developed by Dr. Robert B. Kerstein, for changing and breaking of the firing-reaction-spasm in the neuromuscular loop. The treatment itself requires no pretreatment splint therapy and has been shown in multiple studies performed over the past 26 years to rapidly lessen muscle activity levels and improve human chewing function in 7 days following initial treatment because the therapy works from within the CNS [69, 70, 72–74]. According to Dr. Kerstein, “Disocclusion Time Reduction Therapy” reduces the Disocclusion Time [15], which lessens the time posterior teeth frictionally engage during excursions, which thereby stops the neuronal action potentials from hyperfunctioning the masticatory muscles. To accomplish this, the Disocclusion time must be less than 0.4 s per excursion. However, this particular time of 0.4 s cannot be accurately calculated without using the T-Scan occlusal analysis system. Disocclusion time reduction therapy is one of the most important, etiologically directed treatment methods available because it drastically lessens the volume of PDL mechanoreceptor compressions thereby disrupting the neuronal trigger for occlusally induced MPDS symptoms. However, there are still many disagreements on the reliability of the “Disocclusion Time Reduction Therapy”, despite it being repeatedly shown in multiple studies to affect positive physiologic changes within the stomatognathic system. As DTR is usually performed as a coronoplasty (known as immediate complete anterior guidance development (ICAGD)), [9] these disagreements about DTR’s patient benefits are founded in that prior, unmeasured occlusal adjustment studies where no T-Scan measurements of the occlusion were involved in the rendered treatment have shown limited occlusal equilibration effectiveness in treating MPDS symptoms. Occlusal equilibration procedurally lacks precision and treats positionally eliminating the prematurity from CR-CO, while only adjusting nonworking side interferences [75–78]. Periodontal neuronal mechanoreceptors surround all teeth on all sides of the roots. By leaving the working side teeth untreated meant occlusal equilibration to CR did not alter the CNS input enough to obtain predictable therapeutic MPDS results.

ICAGD is very different occlusal adjustment procedure from occlusal equilibration [79], in that ICAGD is an excursively focused coronoplasty performed from the maximum intercuspal position (MIP) without mandibular manipulation to centric relation. ICAGD is a measurement-driven, computer-guided occlusal adjustment procedure that shortens prolonged excursive

movement occlusal surface contact frictional durations. The main objective of ICAGD is to shorten the posterior disclusion time to ≤ 0.5 s per excursion because 0.41 was the first studied, physiologic mean disclusion time. ICAGD is always performed today with the T-Scan synchronized to the BioEMG III Electromyography system (T-Scan 9/BioEMG III, Tekscan Inc. S. Boston, MA, USA; Bioresearch Assoc., Milwaukee, WI, USA). The patient wears electromyography electrodes upon the masseter and temporalis muscles throughout the entire occlusal adjustment process to ensure that changes in muscle hyperactivity can be properly observed post treatment. Most importantly, ICAGD treats both the working and nonworking sides including all premolars involved in excursive contacts, thereby greatly reducing the PDL and pulpal mechanoreceptor CNS input from all fictionally engaged posterior occlusal surfaces. All these procedural differences are published in occlusal adjustment studies, ICAGD has been shown to be far more effective than Occlusal Equilibration in treating MPDS.

8. Disclusion time reduction case example

An example of disocclusion time reduction therapy performed with the immediate complete anterior guidance development coronoplasty is presented below.

8.1. Patient description

A 30-year-old female airline flight attendant presented with a Class I anterior relationship post orthodontics that was completed in her teenage years. A number of posterior teeth demonstrated cuspal wear and appear slightly sanded away. All third molars were previously extracted (**Figures 10 and 11a, b**).

8.2. History and presentation of occlusal disease

For 1.5 years before consultation, the patient had experienced chronic bilateral masseter tension, with regular morning jaw soreness that worsened during stressful periods. The patient reported clenching during the day and bruxing to some degree during the nighttime. Most of her discomfort was in the masseter region bilaterally, with some temporal headache

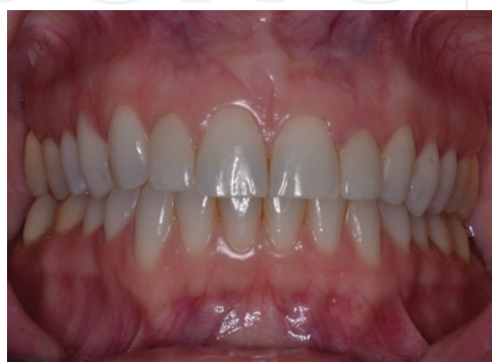

Figure 10. Frontal view of an MPDS female patient showing a Class I anterior relationship with average vertical overlap and available canine guidance contacts bilaterally.

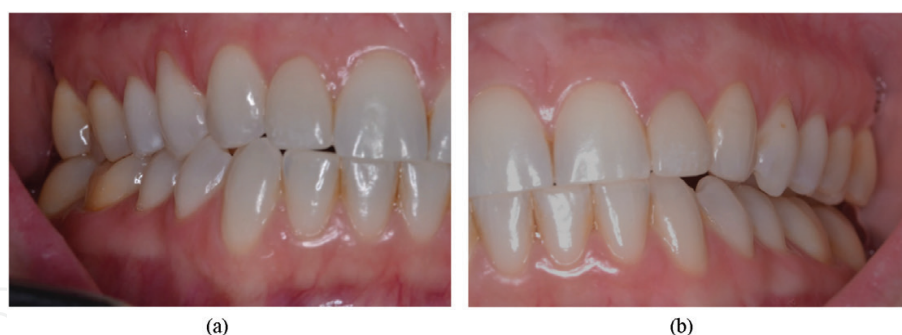

Figure 11. (a) 1 mm into the right excursion as the canine teeth began to engage. Note the complete buccal posterior group function and excursive friction visible. (b) Early in the left lateral movement, opposing posterior teeth frictionally engage both buccally and lingually (unseen). The posterior group function visible is worsened by the nonvertical opposing tooth orientation.

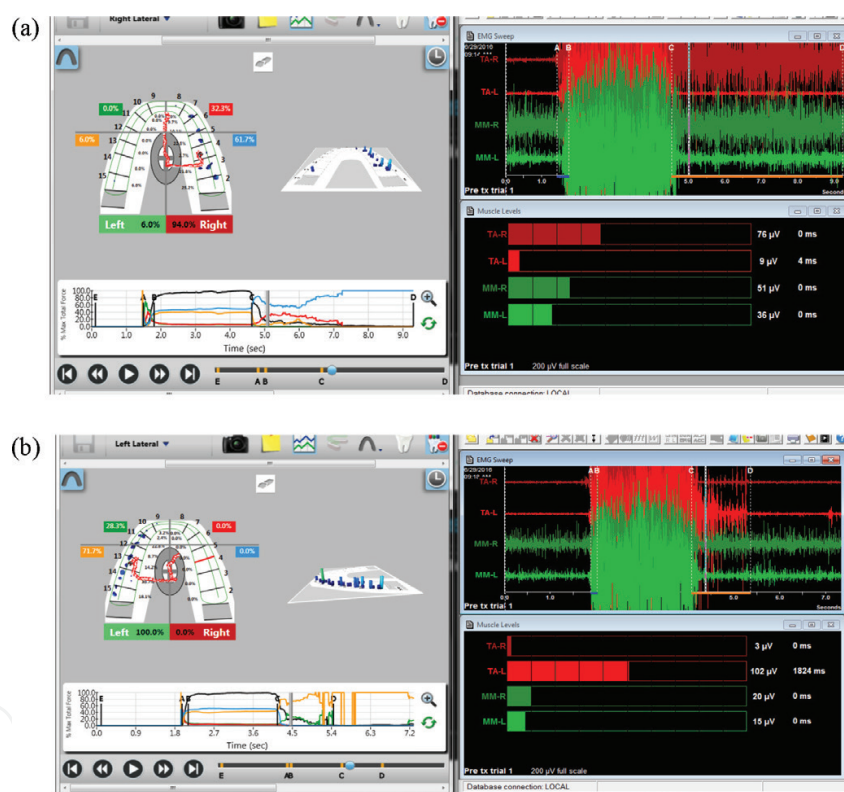


Figure 12. (a) The preoperative right excursive T-Scan/BioEMG data showed (in the T-Scan left pane) prolonged disclusion time with mostly working and minimal balancing excursive frictional occlusal contacts present in the 2D and 3D ForceViews. Between C and D (in the EMG data right pane), there was very high muscle contractions visible in the two masseter MM-R MM-L and right temporalis muscles TA-R, as the patient moved laterally across their teeth toward the right canine. The nonworking (left temporalis TA-L) does not fire in the right excursion. The right disclusion time pretreatment was 3.58 s long, causing this high muscle firing and the MPDS symptoms the patient has been forced to live with since her bite changed after the upper premolar fillings were done. (b) The preoperative left excursive T-Scan/BioEMG data showed (in the T-Scan left pane) prolonged disclusion time with only working side excursive frictional occlusal contacts present in the 2D and 3D ForceViews the total force (black) line “step downs,” indicating sharp force drops as the patient’s posterior teeth frequently stopped the mandible from moving freely laterally. Between C and D (in the EMG data right pane), there was very high muscle contractions left temporalis TA-L muscle with right temporalis TA-R spasm visible for the same duration the left temporalis hyperfunctions. The right and left masseters MM-R and MM-L both fired excursively well above rest. The left disclusion time pretreatment was 1.37 s long causing the visible high muscle firing and the MPDS symptoms the patient has been forced to live with since her bite changed after the upper premolar fillings were done.

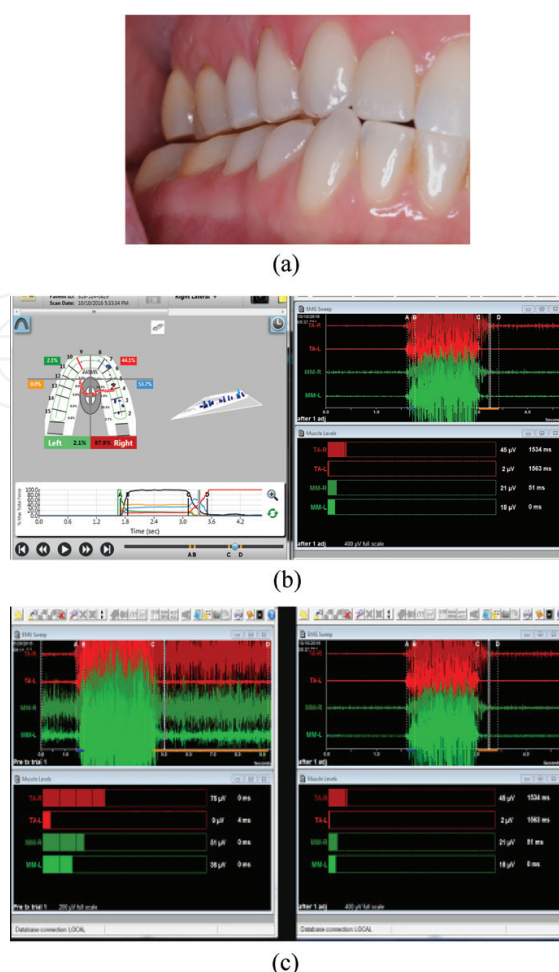


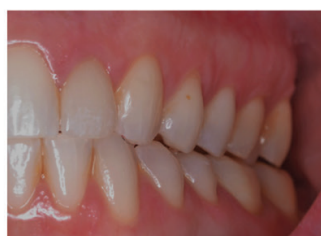Figure 13. (a) The post-ICAGD right excursion showing slight space between the group function teeth that was not there before performing of the ICAGD coronoplasty. (b) The right excursion after ICAGD. The disclusion time equaled 0.45 s duration, which reduced the right temporalis and right and left masseter excursive hyperactivity dramatically compared to pretreatment. (c) Right excursive EMG improvements from pretreatment (left pane) to after ICAGD (right pane), where there is markedly lowered muscle activity levels post treatment at rest (before A), and in the excursion (to the right of C). With lessened excursive muscular hyperactivity, the muscle physiology can heal and MPDS symptoms can then abate.

component present, as well. Her symptoms came on after having two fillings placed in her two upper premolar teeth #s 14 and 15. Muscular pain ensued shortly after the fillings were done as they changed her occlusal contact comfort. Since then, further occlusal adjusting to the teeth involved did not resolve her MPDS symptoms.

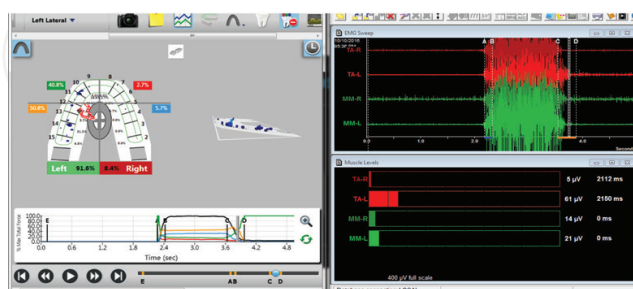
8.3. Previous unsuccessful treatments

The patient reported wearing an appliance for 10 months nightly, but also reported symptom worsening with his attempted regular appliance use. She felt it made her clench more than if it was not worn. As such, she stopped wearing the appliance some months before consultation. Anti-inflammatory and pain medication gave her some marginal relief that would last only for a few hours.

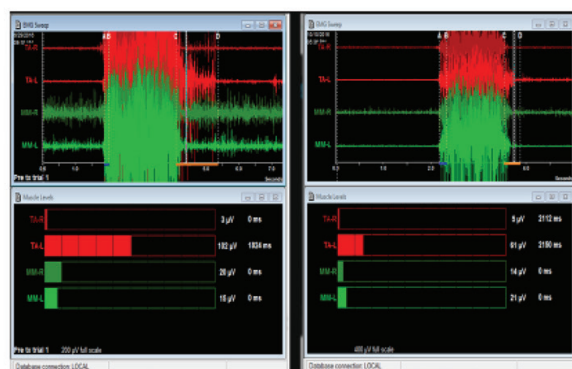
The following figures (**Figures 12–15**) detail the patients in preoperative occlusal and muscle physiology status, as well as her post-ICAGD disclusion time reduction changes. For brevity, only the right and left excursions were illustrated, and protrusive excursions were not described.



(a)



(b)



(c)

Figure 14. (a) The post ICAGD left excursion showing slight space between the group function teeth that was not there before performing of the ICAGD coronoplasty. (b) The left excursion after ICAGD when the disclusion time equaled to 0.34 s. The excursive EMG improvements show markedly lowered muscle activity levels post-treatment at rest (before A), and in the excursion (to the right of C). (c) The left excursive EMG improvements from pretreatment (left pane) to after ICAGD (right pane), where there is markedly lowered muscle activity levels present at rest (before A), and in the excursion post-treatment (to the right of C). With lessened excursive muscular hyperactivity, the muscle physiology can heal and MPDS symptoms can then abate.

With the pretreatment T-Scan/BioEMG data showing prolonged disclusion times and very high levels of excursive muscular hyperactivity, the patient was a good candidate to undergo the ICAGD coronoplasty. She was a Class I MPDS patient with adequate bilateral canine contact present to be safely treated with ICAGD.

It is through the measurement of the occlusion and muscles together using the T-Scan 9/BioEMG III synchronized occlusal measurement technologies so that these diagnostic and treatment improvements demonstrated within this case can become clinically predictable in managing MPDS patient. By quantifying occlusal function and muscle function together, the therapeutic effectiveness the ICAGD measured occlusal adjustment procedure has a dramatic effect on the central nervous system (CNS) that greatly reduces muscle activity levels and quickly lessens many common MPDS symptoms.

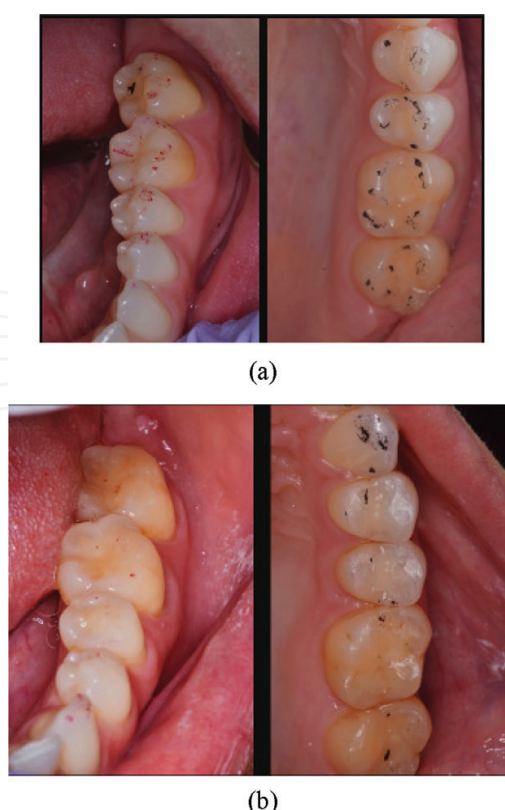


Figure 15. (a) Opposing occlusal surfaces with many pre-ICAGD articulating paper ink lines that describe that long disclusion time friction is present on all upper and lower posterior opposing occlusal surfaces (teeth #s 28–24 and #s 38–34). Note the very long red ink line visible on #37 distolingual occlusal incline. Its counterpart frictionally prolonged contact is the #27 distopalatal black ink line. (b) Post-ICAGD articulating paper markings showing 1–2 short disclusion time red and black pinpoint closure contacts per tooth, present on the opposing posterior occlusal surfaces (teeth #s 28–24 and #38–34). There are anterior guidance ink tracks visible across the occluding canine surfaces (#s 23 and 33). The small posterior closure contacts allow for the minimum posterior excursive contact, which are indicative of a disclusion time of <0.4 s. This small overall volume of tooth contact posteriorly is how the ICAGD coronoplasty controls the repetitive PDL mechanoreceptor neuronal action potential from heading into the CNS. Without the neural input, muscle contractions are dramatically lessened (**Figures 13c** and **14c**).

9. Final thoughts

This chapter describes in detail how the peripheral neural receptors that are located in and around the posterior teeth periodontal ligaments and in the dental pulp create ongoing masticatory muscle hyperactivity that can lead to the clinical appearance of myofascial pain dysfunction syndrome symptoms. MPDS commonly afflicts the masticatory musculature with chronic muscular pain, frequent temporal headaches, chewing pain and weakness, opening limitations, and frequent clenching and bruxing of teeth. Because unmeasured, published Occlusal Equilibration studies did not predictably treat the MPDS condition, conventional MPDS treatments have focused on lessening MPDS symptoms without treating the occlusion directly. The use of occlusal splints, physical therapy, and trigger point injections has been predominant. However, since the development of the T-Scan system in the 1980s, and the discovery of prolonged posterior disclusion time, a computer-guided alternative coronoplasty to occlusal equilibration, has evolved to treat MPDS (known as disclusion time reduction (DTR) with the ICAGD coronoplasty).

DTR is an etiologically based treatment aimed at reducing prolonged occlusal surface friction, which drastically limits the tooth socket compressions and pulpal occlusal contact impacts that the posterior teeth sustain multiple times on a daily basis (and nightly, if there is parafunction). By cutting down the volume of socket compressions and impacts, the molar and premolar peripheral action potential response to the occlusal contacts is drastically lessened, which remove the stimulus that the occlusion inputs into the central nervous system (CNS) to fire muscles and create ischemia. This limiting neurophysiologic change allows the masticatory muscles to calm down and relax physiologically, because the ischemia reverses intramuscularly from within the CNS, requiring the patient to not wear an occlusal splint. In short order following the ICAGD coronoplasty, studies repeatedly show the MPDS symptoms, then abate, and lessen in severity and frequency.

Author details

Serdar Gözler

Address all correspondence to: serdargozler@aydin.edu.tr

TMD Clinic, Dentistry Faculty of Istanbul Aydin University, Istanbul, Turkey

References

- [1] Lipton JA, Dionne RA. National institutes of health technology assessment conference statement: Management of temporomandibular disorders, April 29-May 1, 1996. *Oral Surgery, Oral Medicine, Oral Pathology, Oral Radiology* [Internet]. 1996;**83**(1):177-183 Available from: <http://cat.inist.fr/?aModele=afficheN&cpsidt=2551680>
- [2] Kerstein RB. Disclusion time measurement studies: A comparison of disclusion time between chronic myofascial pain dysfunction patients and nonpatients: A population analysis. *The Journal of Prosthetic Dentistry*. 1994;**72**:473-480
- [3] Kerstein RB. Treatment of myofascial pain dysfunction syndrome with occlusal therapy to reduce lengthy disclusion time—A recall evaluation. *CRANIO®* [Internet]. 1995 Apr 1; **13**, **105**(2):15. DOI: 10.1080/08869634.1995.11678053
- [4] Baldini A, Nota A, Cozza P. The association between occlusion time and temporomandibular disorders. *Journal of Electromyography & Kinesiology* [Internet]. 2015;**25**(1):151-154. DOI: 10.1016/j.jelekin.2014.08.007
- [5] Bennett R. Myofascial pain syndromes and their evaluation. *Best Practice & Research: Clinical Rheumatology*. 2007;**21**(3):427-445. Available from: <http://www.ncbi.nlm.nih.gov/pubmed/17602992>
- [6] Palla S. Trigger points as a cause of Orofacial pain. *J Musculoskelet Pain*. 2004;**12**(3-4):29-36
- [7] Ge HY, Monterde S, Graven-Nielsen T, Arendt-Nielsen L. Latent myofascial trigger points are associated with an increased intramuscular electromyographic activity during synergistic muscle activation. *Journal of Pain*. 2014;**15**(2):181-187. DOI: 10.1016/j.jpain.2013.10.009

- [8] Svensson P. Pain mechanisms in myogenous temporomandibular disorders. *Pain Forum*. 1997;**6**(3):158-165. Available from: <http://www.sciencedirect.com/science/article/pii/S1082317497700102>
- [9] Kerstein RB. Disclusion time-reduction therapy with immediate complete anterior guidance development to treat chronic myofascial pain-dysfunction syndrome. *Quintessence International*. 1992;**23**(11):735-747
- [10] Friction J. Myofascial pain: Mechanisms to management. *Oral and Maxillofacial Surgery Clinics of North America*. 2016;**28**(3):289-311. DOI: 10.1016/j.coms.2016.03.010
- [11] Farella M, Michelotti A, Bocchino T, Cimino R, Laino A, Steenks MH. Effects of orthognathic surgery for class III malocclusion on signs and symptoms of temporomandibular disorders and on pressure pain thresholds of the jaw muscles. *International Journal of Oral and Maxillofacial Surgery*. 2007;**36**(7):583-587
- [12] De Rossi SS, Stern I, Sollecito TP. Disorders of the masticatory muscles. *Dental Clinics of North America*. 2013;**57**(3):449-464. DOI: 10.1016/j.cden.2013.04.007
- [13] Schindler H, Eckehard S, Spiess WEL. Standardization of the registration and analysis of mastication: Proposal for clinical application. Turker K, editor. *Journal of Prosthetic Dentistry*. 2016;**9**(3):1-7. DOI: 10.1016/j.prosdent.2014.04.032
- [14] Gözler S. Aggregating stimulus increases the activity in motoneurons causing spasm a case from our study. In: 10th Biennial International Motoneuron Meeting, Istanbul-Motoneuron Congress. 2017
- [15] Kerstein RB, Wright NR. Electromyographic and computer analysis of patients suffering from chronic myofascial pain-dysfunction syndrome: Before and after treatment with immediate complete anterior guidance development. *The Journal of Prosthetic Dentistry*. 1991;**66**:677-686
- [16] Kerstein RB, Radke J. Average chewing pattern improvements following disclusion time reduction. *Cranio: The Journal of Craniomandibular Practice*. 2016;**9634**(February):1-17. DOI: 10.1080/08869634.2016.1190526
- [17] Olesen J. The international classification of headache disorders, 3rd edition. *Cephalgia*. 2013;**33**(9):629-808. Available from: <http://www.ncbi.nlm.nih.gov/pubmed/18808500%5Cnhttp://www.ncbi.nlm.nih.gov/pubmed/24409431%5Cnhttp://www.ncbi.nlm.nih.gov/pubmed/22325197%5Cnhttp://www.ncbi.nlm.nih.gov/pubmed/16805756%5Cnhttp://www.ncbi.nlm.nih.gov/pubmed/24238370%5Cnhttp://www.ncbi.nlm>
- [18] Dawson PE. A classification system for occlusions that relates maximal intercuspation to the position and condition of the temporomandibular joints. *The Journal of Prosthetic Dentistry*. 1996;**75**(1):60-66
- [19] De Rossi SS, Stern I, Sollecito TP, Fushima K, Gallo LM, Krebs M, et al. The relationship between skull morphology, masticatory muscle force and cranial skeletal deformation during biting. *Journal of Prosthodontic Research*. 2016;**25**(3):51-59. DOI: 10.1016/j.jfoodeng.2016.06.008
- [20] Learreta JA, Beas J, Bono AE, Durst A. Muscular activity disorders in relation to intentional occlusal interferences. *Cranio: The Journal of Craniomandibular Practice*. 2007;**25**(3):193-199

- [21] van der Bilt A. Assessment of mastication with implications for oral rehabilitation: A review. *Journal of Oral Rehabilitation*. 2011;**38**(10):754-780
- [22] Meyer RA. Chapter 163 The Temporomandibular Joint Examination. 2017. pp. 2-4
- [23] Friction JR. Etiology and management of masticatory miofascial pain. *Musculoskeletal Pain*. 1999;**7**(1/2):143-160
- [24] Fuentes AD, Sforza C, Miralles R, Ferreira CL, Mapelli A, Lodetti G, et al. Assessment of electromyographic activity in patients with temporomandibular disorders and natural mediotrusive occlusal contact during chewing and tooth grinding. *Cranio: The Journal of Craniomandibular Practice*. 2016;**9634**(February 2017):1-10. DOI: 10.1080/08869634.2016.1173312
- [25] Wickwire NA, Gibbs CH, Jacobson AP, Lundeen HC. Chewing patterns in normal children. *The Angle Orthodontist*. 1981;**51**(1):48-60
- [26] Kuwahara T, Besette R, Maruyama T. Characteristic chewing parameters for specific types of TMJ internal derangements, Kuwahara et al.pdf. *Cranio: The Journal of Craniomandibular Practice*. 1996;**14**(1):9086871
- [27] National Institutes of Health Tecnology Assesment Conference Statment. Management of Temporomandibular disorders. *Journal of the American Dental Association* (1939). 1996;**127**(11):1595-1606
- [28] De Abreu M, Domingues M, Furtado F, Pereira G, Prado R, Mestriner W, et al. Science-Direct masticatory efficiency and bite force in individuals with normal occlusion. *Archives of Oral Biology*. 2014;**59**(10):1065-1074
- [29] Gözler S. Stomatognatik Sistemin Nöromüsküler Fizyolojisi. In: Çalikkocaoğlu PDS, editor. *Tam Protezler*. 5th ed. Istanbul: Gnatoloji Derneği; 1989. pp. 89-105
- [30] Gözler S, Tüzer E, Çalikkocaoğlu S. Nöromüsküler mekanizmanın protetik diş hekimliğindeki yeri. *İstanbul Üniversitesi Diş Hekimliği Fakültesi Dergisi*. 1982;**16**(1):83-114
- [31] Huguenin LK. Myofascial trigger points: The current evidence. *Physical Therapy in Sport*. 2004;**5**(1):2-12
- [32] Cummings M, Baldry P. Regional myofascial pain: Diagnosis and management. *Best Practice & Research. Clinical Rheumatology*. 2007;**21**(2):367-387
- [33] Türker KS, Brinkworth RSA, Abolfathi P, Linke IR, Nazeran HA. Device for investigating neuromuscular control in the human masticatory system. *Journal of Neuroscience Methods*. 2004;**136**:141-149
- [34] Trulsson M, Gunne HS. Food-holding and -biting behavior in human subjects lacking periodontal receptors. *Journal of Dental Research*. 1998;**77**(4):574-582
- [35] Trulsson M. Sensory-motor function of human periodontal mechanoreceptors. *Journal of Oral Rehabilitation*. 2006;**33**(4):262-273
- [36] Bessette RW, Mohl ND, Bishop B. Contribution of periodontal receptors to the masseteric silent period. *Journal of Dental Research*. 1974;**53**(5):1196-1204
- [37] Dessem D, Iyadurai OD, Taylor A. The role of periodontal receptors in the jaw-opening reflex in the cat. *The Journal of Physiology*. 1988;**406**:315-330

- [38] Schindler HJ, Stengel E, Spiess WEL. Feedback control during mastication of solid food textures—A clinical-experimental study. *The Journal of Prosthetic Dentistry*. 1998;**80**(3):330-336
- [39] McCulloch CA, Lekic P, McKee MD. Role of physical forces in regulating the form and function of the periodontal ligament. *Periodontology* 2000. 2000;**24**:56-72
- [40] Barczyk M, Bolstad AI, Gullberg D. Role of integrins in the periodontal ligament: Organizers and facilitators. *Periodontology* 2000. 2013;**63**(1):29-47
- [41] Zent R, Pozzi A. Cell-extracellular matrix interactions in cancer. *Cell-extracellular Matrix Interact Cancer*. 2010:1-314
- [42] Windhorst U. Muscle proprioceptive feedback and spinal networks. *Brain Research Bulletin*. 2007;**73**(4-6):155-202
- [43] Ji RR, Kohno T, Moore KA, Woolf CJ. Central sensitization and LTP: Do pain and memory share similar mechanisms? *Trends in Neurosciences*. 2003;**26**(12):696-705
- [44] Harden RN, Bruehl SP, Gass S, Niemiec C, Barbick B. Signs and symptoms of the myofascial pain syndrome: A national survey of pain management providers. *Clinical Journal of Pain*. 2000;**16**(1):64-72. Available from: <http://www.scopus.com/inward/record.url?eid=2-s2.0-0034015338&partnerID=tZOtx3y1>
- [45] Rhudy JL, Meagher MW. Fear and anxiety: Divergent effects on human pain thresholds. *Pain*. 2000;**84**(1):65-75
- [46] Rahn EJ, Guzman-Karlsson MC, David Sweatt J. Cellular, molecular, and epigenetic mechanisms in non-associative conditioning: Implications for pain and memory. *Neurobiology of Learning and Memory*. 2013;**105**:133-150. DOI: 10.1016/j.nlm.2013.06.008
- [47] Greene SA. Chronic pain: Pathophysiology and treatment implications. *Topics in Companion Animal Medicine*. 2010;**25**(1):5-9. DOI: 10.1053/j.tcam.2009.10.009
- [48] Greene CS, Laskin DM. Splint therapy for the myofascial pain-dysfunction (MPD) syndrome: A comparative study. *Journal of the American Dental Association*. 1972;**84**(3): 624-628. DOI: 10.14219/jada.archive.1972.0090
- [49] Donovan TE, Anderson M, Becker W, Cagna DR, Hilton TJ, JR MK. Annual review of selected scientific literature: report of the committee on scientific investigation of the American Academy of Restorative Dentistry. *Journal of Prosthetic Dentistry*. 2012; **108**(1):15-50. DOI: 10.1016/S0022-3913(10)60087-X
- [50] Conti PCR, De Alencar EN, Da Mota Corrêa AS, Lauris JRP, Porporatti AL, Costa YM. Behavioural changes and occlusal splints are effective in the management of masticatory myofascial pain: A short-term evaluation. *Journal of Oral Rehabilitation*. 2012; **39**(10):754-760
- [51] Gozler S, Vanlioglu B, Evren B, Gozneli R, Yildiz C, Ozkan YK. The effect of temporary hydrostatic splint on occlusion with computerized occlusal analysis system. *Indian Journal of Dental Research: Official Publication of Indian Society for Dental Research*. 2012;**23**:617-622
- [52] Aldemir K, Üstüner E, Erdem E, Demiralp AS, Oztuna D. Ultrasound evaluation of masseter muscle changes in stabilization splint treatment of myofascial type painful

- temporomandibular diseases. *Oral Surgery, Oral Medicine, Oral Pathology, Oral Radiology*. 2013;**116**(3):377-383. DOI: 10.1016/j.oooo.2013.06.011
- [53] Wang C, Yin X. Occlusal risk factors associated with temporomandibular disorders in young adults with normal occlusions. *Oral Surgery, Oral Medicine, Oral Pathology, Oral Radiology*. 2012;**114**(4):419-423. DOI: 10.1016/j.oooo.2011.10.039
- [54] Lauritzen AG, Bodner GH. Variations in location of arbitrary and true hinge axis points. *Journal of Prosthetic Dentistry*. 1961;**11**(2):224-229. Available from: <http://linkinghub.elsevier.com/retrieve/pii/0022391361901962>
- [55] Helms RB, Katona TR, Eckert GJ. Do occlusal contact detection products alter the occlusion? *Journal of Oral Rehabilitation*. 2012;**39**(5):357-363
- [56] Mongini F. Condylar remodeling after occlusal therapy. *The Journal of Prosthetic Dentistry*. 1980;**43**(5):568-577
- [57] Mongini F. Anatomic and clinical evaluation of the relationship between the temporomandibular joint and occlusion. *The Journal of Prosthetic Dentistry*. 1977;**38**(5):539-551
- [58] Condylator C. Gerber-Condylator Gerber-Condylator [Internet]. Available from: www.condylator.com/en/articles/advantages_of_the_condylator.pdf
- [59] Garrido García VC, García Cartagena A, González Sequeros O. Evaluation of occlusal contacts in maximum intercuspation using the T-Scan system. *Journal of Oral Rehabilitation*. 1997;**24**(12):899-903
- [60] Da Silva Martins MJ, Caramelo FJ, Ramalho da Fonseca JA, Gomes Nicolau PM. In vitro study on the sensibility and reproducibility of the new T-Scan®III HD system. *Revista Portuguesa de Estomatologia, Medicina Dentária e Cirurgia Maxilofacial*. 2014;**55**(1):14-22. DOI: 10.1016/j.rpemd.2014.01.001
- [61] Kerstein RB, Lowe M, Harty M, Radke J. A force reproduction analysis of two recording sensors of a computerized occlusal analysis system. *Cranio*. 2006;**24**(1):15-24
- [62] Kerstein RB, Chapman R, Klein M. A comparison of ICAGD (immediate complete anterior guidance development) to mock ICAGD for symptom reductions in chronic myofascial pain dysfunction patients. *Cranio: The Journal of Craniomandibular Practice*. 1997;**15**(January 1997):21-37
- [63] Koos B, Höller J, Schille C, Time AG. Dependent analysis and representation of force distribution and occlusion contact in the masticatory. *Cycle*. 2012;**73**(3):3-4
- [64] Svetlana K. Case report T-scan III computed guided occlusal adjustment in orthodontic relapse patient. The procedure description. *EC Dental Science*. 2016;**2**:1297-1308
- [65] Qadeer S, Yang L, Sarinnaphakorn L, Kerstein RB. Comparison of closure occlusal force parameters in post-orthodontic and non-orthodontic subjects using T-Scan(R) III DMD occlusal analysis. *Cranio*. 2016;**9634**(April):1-7. DOI: 10.1080/08869634.2015.1122277
- [66] Makofsky HW, Sexton TR, Diamond DZ, Sexton MT. The effect of head posture on muscle contact position using the T-Scan system of occlusal analysis. *Cranio: The Journal of Craniomandibular Practice*. 1991;**9**:316-321

- [67] Qadeer S, Abbas AA, Sarinnaphakorn L, Robert B. Comparison of excursive occlusal force parameters in post-orthodontic and non-orthodontic subjects using T-Scan® III. *Cranio*®. 2016;**9634**, January):1-8. DOI: 10.1080/08869634.2016.1259785
- [68] Lund JP. Mastication and its control by the brain stem. *Critical Reviews in Oral Biology & Medicine*. 1991;**2**(1):33-64. Available from: <http://cro.sagepub.com/content/2/1/33.short>
- [69] Kerstein RB, Radke J, Dmd RBK, Mba JR. Average chewing pattern improvements following Disclusion Time reduction. *Cranio*®. 2017;**9634**(January):1-17. DOI: 10.1080/08869634.2016.1190526
- [70] Yiannios N, Kerstein RB, Radke J. Treatment of frictional dental hypersensitivity (FDH) with computer-guided occlusal adjustments. *Cranio*®. 2016;**9634**(November):1-11 Available from: <https://www.tandfonline.com/doi/full/10.1080/08869634.2016.1251692>
- [71] Thumati P, Kerstein R, Thumati R. Disclusion time reduction therapy in treating occluso-muscular pains. *Journal of Indian Prosthodontic Society*. 2016. Available from: <http://www.j-ips.org/preprintarticle.asp?id=194948>
- [72] Kerstein RB, Chapman R, Klein MA. Comparison of ICAGD (immediate complete anterior guidance development) to mock ICAGD for symptom reductions in chronic myofascial pain dysfunction patients. *Cranio*. 1997;**15**:21-37
- [73] Kerstein RB, Radke J. Masseter and temporalis excursive hyperactivity decreased by measured anterior guidance development. *Cranio: The Journal of Craniomandibular Practice*. 2012;**30**(4):243-254
- [74] Thumati P, Manwani R, Mahantshetty M. The effect of reduced disclusion time in the treatment of myofascial pain dysfunction syndrome using immediate complete anterior guidance development protocol monitored by digital analysis of occlusion. *Cranio: The Journal of Craniomandibular Practice*. 2014;**32**(4):289-299
- [75] Goodman P, Greene CS, Laskin DM. Response of patients with myofascial pain-dysfunction syndrome to mock equilibration. *Journal of the American Dental Association*. 1976;**92**(4):755-758. Available from <http://www.ncbi.nlm.nih.gov/pubmed/1068180>
- [76] Forssell H, Kirveskari P, Kangasniemi P. Effect of occlusal adjustment on mandibular dysfunction. A double-blind study. *Acta Odontologica Scandinavica*. 1986;**44**(2):63-69. Available from <http://www.ncbi.nlm.nih.gov/pubmed/3524093>
- [77] Wenneberg B, Nystrom T, Carlsson GE. Occlusal equilibration and other stomatognathic treatment in patients with mandibular dysfunction and headache. *The Journal of Prosthetic Dentistry*. 1988;**59**(4):478-483
- [78] Tsolka P, Morris RW, Preiskel HW. Occlusal adjustment therapy for craniomandibular disorders: A clinical assessment by a double-blind method. *The Journal of Prosthetic Dentistry*. 1992;**68**(6):957-964
- [79] Kerstein RB, Neff PA. A comparison of traditional occlusal equilibration and immediate complete anterior guidance development. *Cranio*®. 1993;**11**(2):126-140. DOI: 10.1080/08869634.1993.11677954

