

# We are IntechOpen, the world's leading publisher of Open Access books Built by scientists, for scientists

6,900

Open access books available

185,000

International authors and editors

200M

Downloads

Our authors are among the

154

Countries delivered to

TOP 1%

most cited scientists

12.2%

Contributors from top 500 universities



WEB OF SCIENCE™

Selection of our books indexed in the Book Citation Index  
in Web of Science™ Core Collection (BKCI)

Interested in publishing with us?  
Contact [book.department@intechopen.com](mailto:book.department@intechopen.com)

Numbers displayed above are based on latest data collected.  
For more information visit [www.intechopen.com](http://www.intechopen.com)



---

# Imaging of Hypoxia in Retinal Vascular Disease

---

Derrick J. Feenstra, Faye M. Drawnel and  
Ashwath Jayagopal

Additional information is available at the end of the chapter

<http://dx.doi.org/10.5772/intechopen.72252>

---

## Abstract

Retinal tissue hypoxia is a key mediator in the pathogenesis of many leading causes of irreversible vision loss, including diabetic retinopathy. Retinal hypoxia in diabetic retinopathy has been shown to drive the production of pro-inflammatory cytokines and pro-angiogenic growth factors. Together, these factors contribute to disease progression by causing unregulated growth of new blood vessels, increased vascular permeability and cell death within the retina. Studies have shown that retinal hypoxia precedes many of the pathologic events that occur during the progression of diabetic retinopathy such as angiopathy, microaneurysms, and capillary dropout. Therefore, early detection of hypoxia in the retinas of diabetic patients could help clinicians identify problems in patients before irreversible damage has occurred. Currently, oxygen sensitive electrodes remain the gold standard for direct measurement of oxygen tension within the retinal tissue; however the procedure is highly invasive and is therefore limited in its applicability towards preclinical models. Less invasive techniques such as retinal oximetry, phosphorescence-lifetime imaging, and hypoxia-sensitive fluorescent probes have shown promising diagnostic value in facilitating detection of oxygen imbalance correlated with neurovascular dysfunction in DR patients. This review highlights the current progress and potential of these minimally invasive hypoxia-imaging techniques in diabetic retinopathy.

**Keywords:** diabetic retinopathy, hypoxia, angiogenesis, neovascularization, imaging techniques

---

## 1. Introduction

### 1.1. Oxygen supply and consumption in the healthy retina

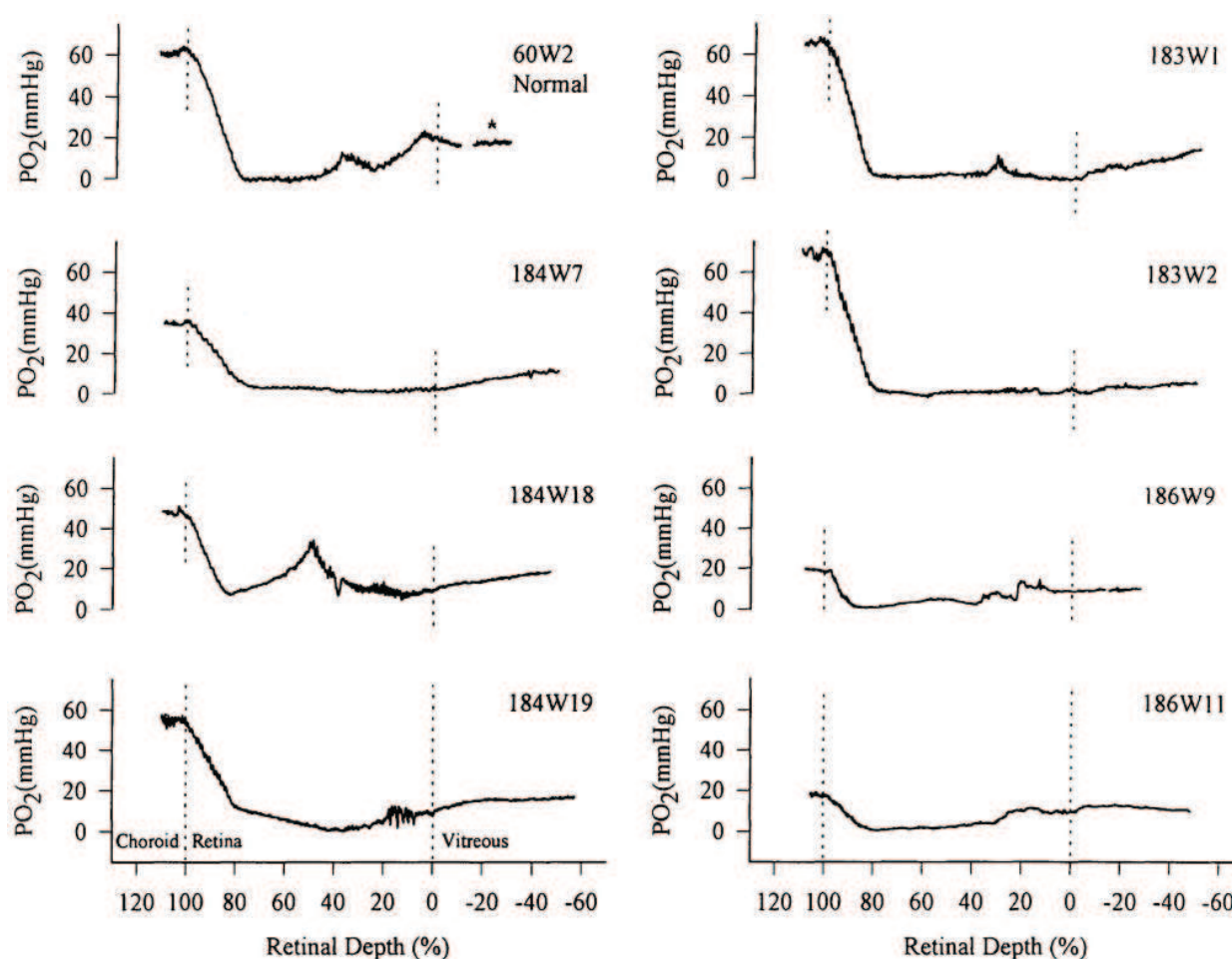
The retina is one of the most metabolically active sites of the entire body and is therefore dependent on a consistent supply of oxygen and other nutrients. In order to meet these metabolic

demands, the retina requires two distinct blood supplies, the inner retinal circulation and choroidal circulation. The inner retinal circulation stems from the central retinal artery which enters the retina near the optic disc. From there, it branches to form the deep and superficial retinal capillary plexuses. In a healthy individual, these blood vessels are found only in the peripheral retina and do not enter into the avascular fovea. The central retinal artery is responsible for supplying the inner retina with oxygen and nutrients and receives about 20–30% of the blood flow to the retina [1]. The second blood supply is the choroidal circulation. The choroidal circulation is a dense network of capillaries located just posterior to the retinal pigment epithelium (RPE) cell layer and is responsible for supplying the outer retina (RPE and photoreceptors) with oxygen. Due to the high metabolic demand of the photoreceptors the choroid receives the majority (65–85%) of the blood that is supplied to the retina [1].

Studies in cats have used oxygen sensitive microelectrodes to measure oxygen tension ( $PO_2$ ) in the various layers of the healthy retina. These studies have shown that oxygen levels are highest ( $\approx 60$  mmHg) in the rod outer segment layer due to their close proximity to the oxygen saturated choroid (**Figure 1**) [2]. Oxygen tension drops to nearly 0 mmHg in the outer nuclear layer, indicating that the oxygen that is perfused from the choroidal circulation is consumed almost entirely by the photoreceptors during visual phototransduction [2]. Moving inward,  $PO_2$  climbs gradually in the inner retina due to the inner retinal circulation, with two small spikes in  $PO_2$  occurring in the deep ( $\approx 20$  mmHg) and superficial ( $\approx 25$  mmHg) retinal capillary plexuses [2]. Therefore, any vascular changes, especially in the inner retinal circulation can lead to tissue hypoxia since the choroidal circulation cannot adequately supply oxygen to the inner retina. Because of this, perturbations in oxygen supply play a significant role in many of the most common vision threatening diseases including age-related macular degeneration (AMD) [3–6], glaucoma [7, 8], retinopathy of prematurity [9–11], and diabetic retinopathy (DR) [2, 12–15].

## 1.2. Hypoxia in diabetic retinopathy

Hypoxia has been implicated as a potential key contributor to the pathogenesis of many retinal diseases, including diabetic retinopathy (DR). The cellular hypoxia response is transcriptionally regulated by hypoxia inducible factors (HIFs) [16, 17], heterodimeric complexes comprising oxygen-sensing HIF1/2/3 $\alpha$  subunits and HIF $\beta$ . The HIF alpha subunits share common features, although HIF3 $\alpha$  has a distinct structure and is found in multiple variants which exert different transcriptional outcomes [18, 19]. Under normoxic conditions, proline residues in the oxygen-dependent degradation domain of HIF $\alpha$  are modified by oxygen-dependent prolyl hydroxylases (PHD) [20], creating a binding site for the von Hippel-Lindau (VHL) E3 ubiquitin ligase complex [21, 22]. HIF $\alpha$  bound by VHL is targeted for proteasomal destruction [23, 24], thus preventing transcriptional activity. However, during hypoxia HIF $\alpha$  proline hydroxylation is abrogated, stabilizing the protein. Transcriptional activity of HIF1 $\alpha$  and HIF2 $\alpha$  is also promoted during hypoxia, as hydroxylation of a key asparagine residue located in the transactivation domain is prevented, promoting interaction between HIF and the p300/ CBP transcriptional co-activator complex [25]. HIF3 $\alpha$ , which lacks the key asparagine residue, is not subject to this regulatory mechanism [18]. The HIF $\alpha$ -HIF $\beta$  complex can activate transcription of genes with promoters featuring hypoxia response elements (HRE) including VEGF and erythropoietin (EPO).



**Figure 1.** PO<sub>2</sub> gradient across the retinal layers in a healthy (60 W2) and diabetic (all other tracings) cat. The tracing of the healthy cat shows normal oxygen perfusion in the choriocapillaris and inner retina. The diabetic cats show evidence of decreased oxygen perfusion in the inner retina and inadequate compensation by the choriocapillaris. Disclaimer: This figure has been reproduced with permission from original article by Linsenmeier et al. [2].

Although regulatory mechanisms are similar between HIF1 $\alpha$  and HIF2 $\alpha$ , expression of the proteins has been suggested to be confined to distinct cellular populations in the ischemic inner retina [26]. Expression of both HIF1 $\alpha$  and HIF2 $\alpha$  is temporally correlated with VEGF expression during retina ischemia [26, 27], and HIF2 $\alpha$  haploinsufficiency has been shown to reduce pro-angiogenic factor expression and neovascularization in the oxygen-induced retinopathy (OIR) model [28]. Interestingly, PHD-dependent HIF1 $\alpha$  degradation is also regulated by citric acid cycle intermediates such as succinate [29], which accumulate during hypoxia as oxygen tension is insufficient to support oxidative phosphorylation, leading to feedback inhibition of citric acid cycle enzymes [30]. Succinate inhibits PHD activity, further stabilizing HIF1 $\alpha$  when cellular oxidative metabolism is compromised [29]. Succinate is also thought to have an additional role in the hypoxic retina, binding and signaling through the G protein coupled receptor 91 (GPR91) [31]. GPR91 regulates VEGF production in retinal ganglion cells via mitogen-activated protein kinase and prostaglandin signaling [32, 33] which contributes to the neovascular response following hypoxia [34].

Some of the hallmarks of DR progression which include the formation of acellular capillaries, capillary occlusion and associated nonperfusion could lead to this cellular hypoxia response

in the diabetic retina [35–40]. Studies point toward an increase in the number of leukocytes and increased leukocyte adhesion as a source of capillary occlusion and tissue nonperfusion [36, 41, 42]. Furthermore, it has been shown that there is tissue hypoxia in the diabetic retina since the choriocapillaris cannot adequately provide the inner retina with oxygen. Linsenmeier et al. used oxygen-sensitive microelectrodes to directly measure  $PO_2$  in the retinas of long term diabetic and non-diabetic cats (> 6 years) and showed that mean  $PO_2$  was significantly lower in inner retina of diabetic (7.66 mmHg) compared to normal cats (16.42 mmHg) (**Figure 1**) [2]. These studies showed that hypoxia was evident early in disease progression, prior to observation of angiopathy, microaneurysms, hemorrhages and capillary dropout. Studies using magnetic resonance imaging (MRI) have also shown that there is a decrease in oxygen levels in galactosemic rats before retinal lesions appear [43]. These studies support the hypothesis that hypoxia may be a driving force in DR progression, rather than an outcome of other factors. Consistent with this hypothesis, hypoxia itself has been shown to stimulate production of a number of proangiogenic factors such as vascular endothelial growth factor (VEGF), one of the predominant targets of many therapeutic interventions in DR [44–48]. Steffanson et al. provided further evidence that oxygen delivery plays a crucial role in DR progression when they observed increased oxygen tension in the areas of the retina that had undergone pan-retinal photocoagulation compared to untreated areas [15]. This finding supports therapeutic strategies in DR which aim to restore normal oxygen supply in order to normalize disease.

Interestingly, although hypoxia has long been hypothesized as a potential driver of DR, it must be noted that there are a number of studies that were unable to detect the presence of hypoxia in the diabetic retina. Some studies in diabetic mice show that there is an initial decrease in retinal blood flow between three to 4 weeks due to arteriolar constriction, however arteriolar diameter and blood flow return to normal measurements at later time points of diabetes (12 weeks) [49–52]. Despite the initial decrease in blood flow these studies did not find any evidence of hypoxia in these animals at either 3 or 12 weeks of diabetes [53–55]. This may indeed be accounted for by compensatory vascular mechanisms in the rodent retina, such as autoregulation which may counteract early hypoxia in these species, and that onset of hypoxia may only occur at very late time points (>1.5 years) that are beyond typical published experimental endpoints in these models.

We are therefore in concurrence with a number of investigators in the ophthalmic and clinical research who identify retinal hypoxia as a significant mediator of initiation and progression of DR. Along with other researchers, we have sought to develop and translate strategies for optical detection of early retinal oxygen imbalance in patients to facilitate earlier clinical interventions and improved outcomes to reduce risk of future vision loss.

## **2. *In vivo* imaging of hypoxia in diabetic retinopathy**

### **2.1. Overview of hypoxia sensing and imaging technologies**

Oxygen-sensitive microelectrodes have long been considered the gold standard for measurement of  $PO_2$  in tissues including the retina [2, 56–60]. While this technique gives an accurate and direct measurement of retinal tissue  $PO_2$ , there are many drawbacks, most importantly the highly invasive nature of the measurement, as it requires a direct puncture of the retinal tissue which prevents its use in clinics. Furthermore, oxygen imbalances in retinal vascular diseases



such as DR originate largely from capillary occlusion and local changes in the retinal vasculature. These occlusions are likely to create small areas of regional hypoxia rather than an entirely hypoxic retinal tissue. Since oxygen sensitive microelectrodes provide point measurements that depend on the placement of the electrode this method will likely miss areas of focal hypoxia that are surrounded by large areas of normoxic tissue unless multiple measurements are made.

Other methods such as MRI have been used to provide insight into oxygen distribution within the retina and are less invasive than oxygen-sensitive microelectrodes. The advantages of MRI are that it is minimally invasive, offers a large field of view, and has no depth limitation. These MRI techniques are often based on the blood oxygenation level-dependent (BOLD) contrast that was first described by Ogawa et al. which rely on natural differences in MR signal between deoxygenated hemoglobin versus oxygenated hemoglobin [61–63], but can also utilize exogenous contrast agents for increased sensitivity as seen in Dynamic Contrast-Enhanced MRI (DCE-MRI) [64]. The use of MRI to detect changes in oxygen levels was first used in the brain but has since been adapted to visualize oxygen fluctuations in the diabetic retina. Berkowitz et al. have used MRI to show increases in blood retinal barrier permeability in rats after 8 months of diabetes [64] and changes in retinal oxygenation in galactosemia-induced diabetic-like retinopathy [43]. The primary limitation of MRI is that the information is typically displayed as either a cross section of the eye or single slice heat maps which are then pieced together to give an overview of the retina [43, 64–67]. This severely limits the techniques ability to provide the adequate resolution required to identify small regions of focal hypoxia in the diabetic retina.

Laser Doppler is another method that has been established to determine blood flow within the retinal vasculature but does not provide information on oxygen  $PO_2$  within the retinal vasculature or tissue [68–70]. More recently however, a number of minimally invasive techniques have been established and adapted to measure oxygen tension optically and identify areas of regional hypoxia in the retina. These techniques take full advantage of the unique anatomy of the eye, which unlike other organs is readily accessible and easy to image due to the naturally transparent front of the eye. Methods such as dual wavelength and full spectral retinal oximetry, and also phosphorescence lifetime imaging all provide information on oxygen levels in the retinal vasculature. Other techniques such as hypoxia sensitive fluorescent probes can help to image hypoxic regions within the retinal tissue itself. These techniques are prime candidates for use in a clinical setting due to their minimally invasive nature and their ability to detect areas of focal hypoxia in the diseased retina.

This review will examine the advantages and disadvantages of the imaging techniques that have emerged as potential diagnostic tools for early detection of DR.

## 2.2. Dual wavelength retinal oximetry

Retinal oximetry is a non-invasive technique used to measure the percent of hemoglobin oxygen saturation ( $SO_2$ ) in the retinal vasculature. Oximetry is based on the principle that oxygenated ( $HbO_2$ ) and deoxygenated hemoglobin ( $Hb$ ) have a different light absorption spectra. The use of spectrophotometric measurements to determine oxygen levels in large retinal vessels was first described by Hickam et al. in 1963, however their method required an independent arteriolar  $SO_2$  measurement for external calibration [71]. Since this initial work, Delori [72], Beach [73], and Hardason et al. [74] have expanded the field by developing new techniques that decrease the invasiveness of retinal oximetry by eliminating the need for an

external calibration measurement, while at the same time increasing sensitivity, accuracy, and reproducibility. More recently investigators have advanced this technology to develop new systems such as the Flow Oximetry System (FOS) that are able to measure oxygen saturation and blood flow within the retinal vasculature [75, 76].

Most studies have measured  $SO_2$  by using dual wavelength oximetry. Here, two images at distinct wavelengths are taken simultaneously. A traditional fundus camera is attached to a beam splitter and digital camera in order to obtain digital images at multiple distinct wavelengths. One image is taken at an isobestic wavelength that is insensitive to differences in hemoglobin oxygen saturation. This is required for compensation against variables such as hematocrit, path length and light intensity that will not differ between the two images. In the image obtained from the isobestic wavelength there is no visual difference between oxygen saturated arteries compared to oxygen depleted veins. Simultaneously, a second image is taken at a wavelength that is sensitive to hemoglobin oxygenation. In this image there are clear differences between the oxygen saturated arteries and oxygen depleted veins. Software has now been developed to automatically detect blood vessels in order to help minimize other factors that contribute to optical density. This has led to highly reproducible measurements of  $SO_2$  in large retinal vessels that can be depicted numerically or as a color map on the fundus image [74].

Since diabetes has been linked to abnormal oxygen distribution in the diabetic retina, retinal oximetry serves as a useful tool to examine changes in oxygen saturation in the retinal vasculature of diabetic patients. A number of studies have measured changes in venous ( $S_vO_2$ ) and arterial ( $S_aO_2$ ) oxygen saturation in patients with mild, moderate, or severe non-proliferative DR, and also proliferative DR. These studies consistently report increased  $S_vO_2$  values as the severity of DR increases [77–83]. Interestingly, the results on whether arterial oxygen saturation changes during DR progression differ between studies. A number of studies have found that  $S_aO_2$  increases with increased disease severity and these changes may not be present until the patient develops proliferative diabetic retinopathy [78–83], while others saw no difference in arterial oxygen saturation between DR patients in any stage compared to healthy individuals [77]. Studies using FOS saw no significant difference in either  $S_aO_2$  or  $S_vO_2$  between healthy individuals and DR patients, however identified significant changes in arteriovenous difference [75]. Together, these data indicate that there is increased venous oxygen saturation in DR patients; however due to the conflicting reports on  $S_aO_2$  levels in DR patients, the cause of this  $S_vO_2$  increase remains to be confirmed. This increase in venous oxygen saturation could be a result of decreased oxygen perfusion into the tissue which could lead to tissue hypoxia, but could also be a result of increased arterial oxygen saturation as observed in some reports, which could lead to subsequent increases in venous oxygen saturation with the same level of perfusion.

The advantages of retinal oximetry are that it is a non-invasive procedure that easily be performed in patients. This technique gives accurate and reliable measurements of  $SO_2$  in the retinal vasculature to help provide insight into the dynamics of oxygen perfusion and consumption in these patients. Furthermore, retinal oximetry has shown that laser photocoagulation helps to improve oxygen delivery to the retina, and has therefore proven to be a useful tool in identifying the mechanisms of current DR treatments [15]. Another advantage of retinal oximetry is that systems are commercially available. However, since the use of retinal oximetry is restricted to the large retinal vessels, this technique might not adequately detect many of the changes seen in DR progression such as microaneurysms and acellular capillaries that

occur in the small capillary beds of the retinal microvasculature. Furthermore, retinal oximetry provides a measurement of  $SO_2$  levels within the vasculature, but does not give a direct measurement of what is happening within the retinal tissue itself. Whether the changes in vascular  $SO_2$  observed in diabetic patients actually correlates to regions of hypoxia within the retina itself cannot be confirmed with retinal oximetry alone. This has been shown in studies examining the correlation between regional differences in oxygen saturation versus lesion formation in patients with proliferative diabetic retinopathy and diabetic maculopathy [84]. The study found that total  $SO_2$  was increased in diabetic patients compared to healthy individuals indicating that there was decreased oxygen perfusion from the retinal vasculature, however the regional differences in  $SO_2$  in the large retinal vessels did not correlate with the areas of retinal lesions [84]. This implies that other factors such as local changes in the microcirculation and within the tissue itself play a significant role in lesion formation and DR progression.

### 2.3. Full spectral imaging

In addition to dual wavelength oximetry, full spectral methods have also taken advantage of the differences between Hb and  $HbO_2$  absorption spectra. Here, rather than using distinct isobestic and non-isobestic wavelengths to measure  $SO_2$ , a continuous range of wavelengths between visible and near-infrared spectrum are transmitted for measurement. Schweitzer et al. first described the technique by illuminating the retina with a narrow slit ( $1.5 \times 40$  mm) of light and capturing the image using an imaging ophthalmospectrometer, which consisted of a fundus camera adapted with a spectrograph coupled to an intensified CCD camera for detection [85, 86]. This allowed for collection of the full spectral data in a narrow band in a single dimension. Since then, full spectral imaging has developed into hyperspectral imaging (HSI) with algorithms used to construct a two dimensional image in order to visualize the data as an oxygen map [87–89]. Whereas this process originally took several seconds due to sequential acquisition of many single-dimension images, new technology allows for enough images to be taken to cover a 15 degree field with good spatial resolution in only a few milliseconds [90]. Today, HSI has been further developed into hyperspectral computed tomographic imaging spectroscopy (HCTIS), which in addition to giving detailed oxygen saturation maps, can give information about changes in the retina such as lesions, perfusion, and pigment density [90, 91].

Full spectral imaging has been used to examine oxygen imbalances in a number of vascular diseases including age-related macular degeneration [85], arteriovenous occlusion [88], and glaucoma [87, 89]. A limited number of studies have utilized full spectral imaging to examine changes in oxygen saturation in diabetic retinopathy. Kashani et al. used HCTIS to examine changes in  $S_aO_2$  and  $S_vO_2$  between healthy individuals and patients with DR and determined that  $S_aO_2$  was significantly lower, while  $S_vO_2$  was significantly higher in patients with proliferative DR [91]. This was confirmed by a significant difference in the arteriovenous difference between the two groups [91].

### 2.4. Phosphorescence-lifetime imaging

Phosphorescence-lifetime imaging is another minimally invasive technique that can be used to image  $PO_2$  within the retina. The use of oxygen-dependent quenching of phosphorescence as a method of optical measurement of  $O_2$  concentration was first described by Vanderkooi



et al. [92, 93]. At the time, a similar method using oxygen-dependent quenching of fluorescence, rather than phosphorescence, had already been established [94]. The use of fluorescence however, was limited by low sensitivity to oxygen and by the fact that the decay in fluorescence brightness is rapid, which meant that only fluorescence intensity and not lifetime could be measured. Intensity measurements are complicated by variables such as solution composition and absorption in the tissue. By using phosphorescence, Vanderkooi et al. were able to measure lifetime, rather than intensity, due to the much slower decay in brightness of phosphorescence compared to fluorescence [92, 93]. It was observed that phosphorescence-lifetimes were directly dependent on oxygen concentration, with an increase in phosphorescence signal as  $PO_2$  decreased, as described by a Stern-Volmer relationship [92, 93]. This technique was modified for use *in vivo* to measure  $PO_2$  in the retinal and choroidal vasculature of large animals such as cats and pigs [95–97], and later for smaller animals such as mice and rats [98–104]. More recently Shahidi et al. have made significant advances by using phosphorescence-lifetime to image oxygen tension within the retinal tissue itself [105, 106]. This minimally invasive technique requires an intravenous injection of a phosphor that can be imaged using an intensified CCD camera to provide a clear image of retinal arteries, veins and even some capillaries with good spatial resolution.

To date, many of the studies utilizing phosphorescence-lifetime have sought to establish the technique and examine changes in oxygen tension during normal physiologic processes such as retinal response to light stimulation [68, 104]. A limited number of studies have utilized phosphorescence-lifetime to study oxygen imbalances in ischemic retinal diseases. Studies in a mouse model of oxygen-induced retinopathy (OIR) have shown that although there was no significant difference in arterial or venous  $PO_2$  between control and OIR mice, the arteriovenous difference was significantly higher in OIR mice [107]. This was attributed to a decreased vascular network in these OIR mice resulting in greater oxygen extraction from the larger vessels [107]. Other investigators have examined whether phosphorescence-lifetime imaging can be used to detect regions of local hypoxia created by laser photocoagulation. In these studies, a laser was used to create small (75  $\mu\text{m}$ ) focal lesions within the capillary network of the mouse retina [100]. Upon imaging and analysis using an oxygen map of the laser burn and surrounding area they observed a circular lesion with a central area of hypoxia ( $< 7$  mmHg) that extended approximately 150–200  $\mu\text{m}$  outward from the initial laser injury [100]. After imaging the lesion again 1 hour later there was no evidence of leakage of the phosphor into the tissue [100]. This study indicates that phosphorescence-lifetime imaging is a useful tool for identifying focal areas of regional hypoxia. Further experiments are needed to confirm whether these results translate into animal models of diabetic retinopathy.

The primary advantage of phosphorescence-lifetime imaging is that it is minimally invasive, requiring only an intravenous injection of a phosphor. These phosphors are readily available as nontoxic, water soluble forms so they can be easily dissolved in blood, providing further potential for use in a clinic. Furthermore, studies have shown that this technique is capable of identifying small areas of regional hypoxia created by focal lesions similar to those seen in DR [100]. This can be combined with traditional fundus photographs and fluorescein angiography to determine whether the areas of regional hypoxia correlate with the location of retinal lesions or leakage during the progression of DR. Finally, the information gathered can be displayed as an easy to read oxygen map showing retinal vascular function. The disadvantage of phosphorescence-lifetime imaging is similar to retinal oximetry in that it is a measurement of

oxygen levels within the retinal vasculature rather than the retinal tissue itself. It must be noted however, that a number of studies have compared PO<sub>2</sub> measurements between the vasculature (using phosphorescence-lifetime) and a variety of tissues including the retina (using O<sub>2</sub> micro-electrodes) and found comparable results, with only slight decreases in PO<sub>2</sub> within the tissue [95, 108]. The second disadvantage to phosphorescence-lifetime imaging is primarily due to the lack of evidence in animal models of DR. Although it has been proven useful in a number of vascular ischemic diseases that share commonalities with DR it would be necessary to confirm the applicability of phosphorescence-lifetime imaging in animal models of DR before proposing the technique as a potentially useful tool for determining PO<sub>2</sub> levels in DR patients.

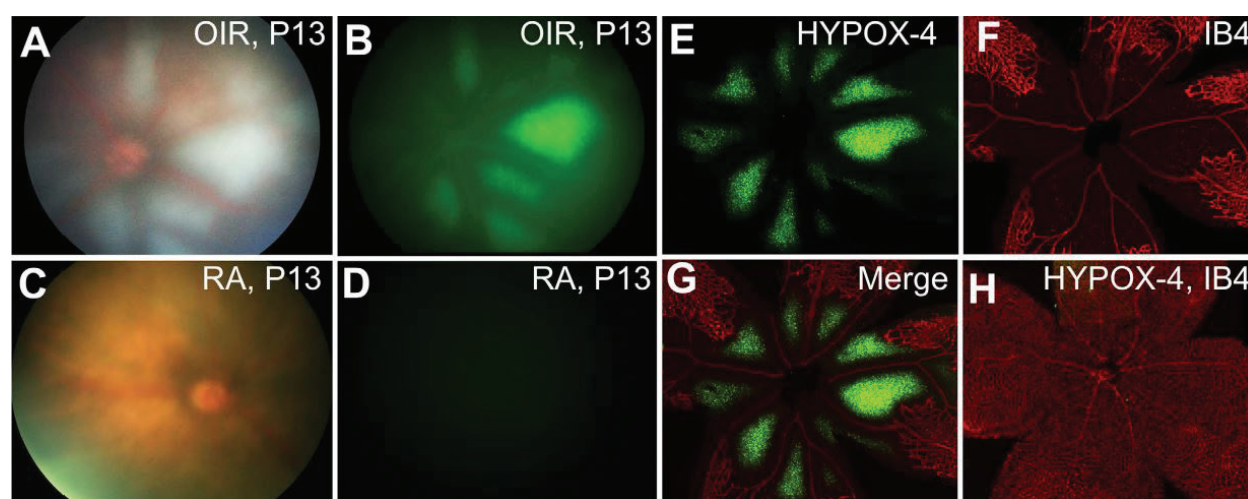
## 2.5. Hypoxia-sensitive fluorescent probes

Another technique for imaging oxygen imbalances in the diabetic retina is the use of hypoxia-sensitive fluorescent probes. Hypoxia-sensitive compounds such as 2-nitroimidazoles are bio-reduced by nitroreductases in hypoxic tissues (PO<sub>2</sub> < 10 mmHg) which leads to the formation of adducts with thiol containing proteins [109–113]. These compounds were originally discovered and used for detecting hypoxic areas within tumors and were imaged by autoradiography [112, 114]. Shortly after, immunohistochemical analysis was made possible by the production of antibodies that recognized the adducts formed by the reduced 2-nitroimidazoles and showed that the fluorescence intensity correlated with the severity of hypoxia [110, 111, 115]. More recently, 2-nitroimidazoles, such as pimonidazole, have been used to detect areas of hypoxia in a number of retinal vascular diseases, including extensive studies in diabetic retinopathy. *Ex-vivo* studies in non-diabetic and diabetic mice and rats have found significantly increased pimonidazole labeling in the retinas of even short-term diabetic mice and rats compared to their non-diabetic counterparts [53, 116–119]. Furthermore, the pimonidazole labeling was confirmed by increased staining of hypoxia inducible factor-1 $\alpha$  (HIF-1 $\alpha$ ) and decreased ganglion cell function measured by electroretinogram (ERG) [53, 116].

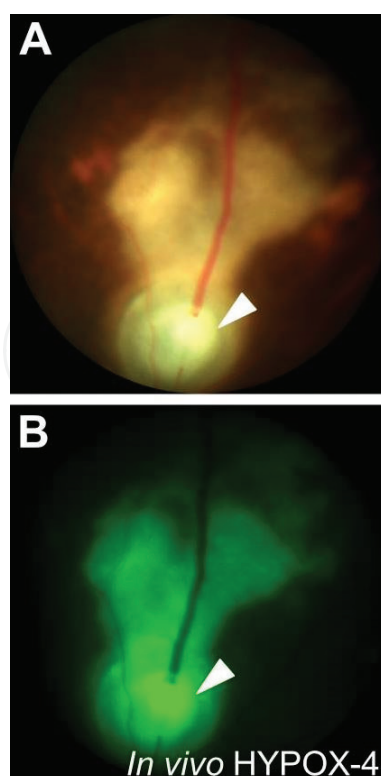
Work by our group has sought to develop clinically useful hypoxia sensitive imaging agents by conjugating FDA-approved fluorescein dyes to adduct forming 2-nitroimidazoles. In preliminary studies, fluorescein isothiocyanate (FITC) was conjugated to a 2-nitroimidazole containing reagent to create the HYPOX-1 probe, and also to pimonidazole to create HYPOX-2. Both HYPOX-1 and HYPOX-2 formed adducts leading to accumulation in a variety of hypoxic retinal cells and allowed for imaging with excellent signal-to-noise ratio *in vitro* [120]. Furthermore, these imaging agents were capable of detecting hypoxic areas *ex vivo* in the retinas oxygen induced retinopathy (OIR) mice with no apparent toxicity [120]. Following the success of these fluorescent imaging agents, a new probe, HYPOX-3, was developed in order to create an “on-off” imaging agent for hypoxia [121]. Here, a near-infrared (NIR) imaging agent was coupled to Black Hole Quencher 3 (BHQ3), which had been shown to quench NIR dyes by Förster resonance energy transfer (FRET) [122]. Interestingly, BHQ3 features a hypoxia-sensitive azo-bond that is cleavable by azoreductases under hypoxic conditions [122, 123]. HYPOX-3 displayed high sensitivity and specificity in forming adducts in a variety of hypoxic retinal cells *in vitro* with no detectable toxicity [121]. The ability to detect hypoxia in retinal vascular disease animal models was examined using a laser-induced choroidal neovascularization (LCNV) mouse model. In RPE-choroid flatmounts, HYPOX-3 clearly identified hypoxic regions in LCNV mice and showed increased fluorescence around the lesion, with minimal fluorescence in control animals [121].

Due to the pharmacokinetics of HYPOX-1, -2, and -3, a new probe was designed with goal of creating an imaging agent for use *in vivo* with a potential for clinical application. This new probe, HYPOX-4, was characterized for *in vitro* and *in vivo* use and compared to immunostaining of pimonidazole-adducts [124, 125]. *In vitro*, HYPOX-4 displayed increasing fluorescence with decreasing oxygen concentration in a variety of different retinal cell lines [124]. *Ex vivo*, HYPOX-4 successfully identified avascular regions in the retinal flatmounts of OIR mice [124] (**Figure 2**) and hypoxic regions downstream of the occluded vein in the retinas of laser-induced retinal vein occluded (RVO) mice [125] (**Figure 3**). Using a micron IV imaging system, HYPOX-4 was then used for *in vivo* imaging of hypoxia in both the OIR and RVO mice. In both models, HYPOX-4 clearly identified areas of hypoxia *in vivo* [124, 125]. HYPOX-4 had no effect on proliferation (as measured by BrdU assay), toxicity (TUNEL), or function (ERG) [124].

The advantages to these hypoxia sensitive fluorescent probes are that they can be conjugated to already FDA approved fluorescent dyes and they allow for direct imaging of hypoxia within the retinal tissue, rather than the microvasculature. Furthermore, studies in the OIR mice have shown they are capable of detecting hypoxia in diseases where there is oxygen imbalance in the entire retina, while the RVO model has shown that they are also capable of detecting regional, focal hypoxia downstream of either a single or double vein occlusion. This alone makes these probes particularly useful in diseases such as DR where there is likely capillary occlusion leading to localized hypoxia within the retinal tissue. A disadvantage of these hypoxia sensitive fluorescent probes are that they only give an image of hypoxic areas without providing actual values for  $PO_2$ , although the  $PO_2$  threshold for bioreduction and adduct formation is well characterized. Furthermore, these probes have been used in OIR and LCNV models to show their ability to identify focal hypoxia; however their use in models of diabetic retinopathy needs to be examined.



**Figure 2.** Imaging of HYPOX-4 in a mouse model of oxygen-induced retinopathy (OIR). Fundus and fluorescein channel *in vivo* images in OIR mice at P13 indicate accumulation of imaging probe in central, avascular hypoxic regions (A, B), which was not reflected by imaging in room air-reared age-matched controls (C, D). Findings in the OIR model correlated with microscopic imaging of retinal flatmounts (E, F, merged in G). Likewise, *ex vivo* analysis of room air control retinal flatmounts confirmed lack of HYPOX-4 accumulation in healthy, fully vascularized retinas (H). Disclaimer: This figure has been adapted from the original article by Uddin et al. [124] under Creative Commons Attribution 4.0 International License.



**Figure 3.** HYPOX-4 mediated retinal imaging of laser-induced retinal vein occlusion (RVO) in the mouse. HYPOX-4 injected 2 hours post vein occlusion with an argon photocoagulator in tandem with rose Bengal photosensitization. The imaging agent accumulated within the venous occlusion site (A, arrowhead) and downstream capillary bed (B). Disclaimer: this figure has been adapted from the original article by Uddin et al. [125] under Creative Commons Attribution 4.0 International License.

### 3. Summary

Hypoxia has been shown to play a significant role in DR progression. Hypoxia stimulates the production of a number of different pro-inflammatory cytokines (IL-1 $\beta$ , TNF- $\alpha$ , ICAM-1) [7, 126, 127] and growth factors (VEGF and PDGF) [45, 47, 128, 129] that lead to neovascularization, increased vascular permeability and cell death. Studies have found that treatments such as laser photocoagulation provide benefits by restoring oxygen tension in the diabetic retina [15]. Furthermore, studies have indicated that oxygen imbalance actually precedes many of the pathological events that occur throughout the progression of diabetic retinopathy [2, 43, 130]. Therefore, early detection of hypoxic regions in the diabetic retina can potentially help clinicians choose appropriate treatment strategies before irreversible damage has already occurred.

New advances in imaging strategies allow for optical measurement of oxygen levels *in vivo*. Oxygen sensitive microelectrodes have been the gold standard for direct measurement of oxygen levels in the retinal tissue, however the measurement is highly invasive and unable to consistently identify small areas of focal hypoxia. Together these factors prevent oxygen sensitive microelectrodes from being used in DR patients. More recently, less invasive techniques such as retinal oximetry, phosphorescence-lifetime imaging and hypoxia sensitive fluorescent probes have been developed in an effort to detect oxygen imbalances and allow for optical identification of hypoxic regions *in vivo*. Retinal oximetry and phosphorescence-lifetime have



been used primarily to measure oxygen saturation in the retinal vasculature. These methods have been used in a number of different animal models and have shown that they can successfully identify regions of focal hypoxia surrounded by predominantly normoxic tissue, similar to what is hypothesized in DR. Hypoxia sensitive fluorescent probes differ from these techniques in that they detect hypoxic regions within the retina itself, rather than the microvasculature. These probes have been developed by the conjugation of fluorescein dyes, such as FITC, to 2-nitroimidazoles. These 2-nitroimidazoles are bioreduced by nitroreductases in under hypoxic conditions, causing them to aggregate within the hypoxic cells. A number of these hypoxia sensitive fluorescent probes have been developed and characterized for *in vitro*, *ex vivo*, and *in vivo* use with low toxicity.

The imaging techniques reviewed here have all been shown to optically identify regions of focal hypoxia *in vivo*. Clinically, these techniques can help to give an accurate depiction of oxygen imbalances within the diabetic retina before retinal pathologies are detectable and may therefore guide future treatment strategies in DR patients.

## Author details

Derrick J. Feenstra, Faye M. Drawnel and Ashwath Jayagopal\*

\*Address all correspondence to: ash.jayagopal@gmail.com

Pharma Research and Early Development, Roche Innovation Center Basel, F. Hoffmann-La Roche, Ltd., Basel, Switzerland

## References

- [1] Kolb H. Simple anatomy of the retina. In: Kolb H, Fernandez E, Nelson R, editors. Webvision Organ. Retina Vis. Syst. Salt Lake City (UT): University of Utah Health Sciences Center; 1995
- [2] Linsenmeier RA, Braun RD, McRipley MA, Padnick LB, Ahmed J, Hatchell DL, McLeod DS, Luty GA. Retinal hypoxia in long-term diabetic cats. *Investigative Ophthalmology & Visual Science*. 1998;**39**:1647-1657
- [3] Blasiak J, Petrovski G, Vereb Z, Facsko A, Kaarniranta K. Oxidative stress, hypoxia, and autophagy in the neovascular processes of age-related macular degeneration. *BioMed Research International*. 2014. DOI: 10.1155/2014/768026
- [4] Stefánsson E, Geirsdóttir Á, Sigurdsson H. Metabolic physiology in age related macular degeneration. *Progress in Retinal and Eye Research*. 2011;**30**:72-80. DOI: 10.1016/j.preteyeres.2010.09.003
- [5] Arjamaa O, Nikinmaa M, Salminen A, Kaarniranta K. Regulatory role of HIF-1α in the pathogenesis of age-related macular degeneration (AMD). *Ageing Research Reviews*. 2009;**8**:349-358. DOI: 10.1016/j.arr.2009.06.002

- [6] Kurihara T, Westenskow PD, Gantner ML, Usui Y, Schultz A, Bravo S, et al. Hypoxia-induced metabolic stress in retinal pigment epithelial cells is sufficient to induce photoreceptor degeneration. *eLife*. n.d.; **5**. DOI: 10.7554/eLife.14319
- [7] Kaur C, Foulds WS, Ling E-A. Hypoxia-ischemia and retinal ganglion cell damage. *Clinical Ophthalmology* (Auckland, N.Z.). 2008;**2**:879-889
- [8] Tezel G, Wax MB. Hypoxia-inducible factor 1alpha in the glaucomatous retina and optic nerve head. *Arch Ophthalmol* (Chic Ill 1960). 2004;**122**:1348-1356. DOI: 10.1001/archophth.122.9.1348
- [9] Hartnett ME, Penn JS. Mechanisms and management of retinopathy of prematurity. *The New England Journal of Medicine*. 2012;**367**:2515-2526. DOI: 10.1056/NEJMr1208129
- [10] Sapieha P, Joyal J-S, Rivera JC, Kermorvant-Duchemin E, Sennlaub F, Hardy P, et al. Retinopathy of prematurity: Understanding ischemic retinal vasculopathies at an extreme of life. *The Journal of Clinical Investigation*. 2010;**120**:3022-3032. DOI: 10.1172/JCI42142
- [11] Di Fiore JM, Kaffashi F, Loparo K, Sattar A, Schluchter M, Foglyano R, et al. The relationship between patterns of intermittent hypoxia and retinopathy of prematurity in preterm infants. *Pediatric Research*. 2012;**72**:606-612. DOI: 10.1038/pr.2012.132
- [12] Holekamp NM, Shui Y-B, Beebe D. Lower intraocular oxygen tension in diabetic patients: Possible contribution to decreased incidence of nuclear sclerotic cataract. *American Journal of Ophthalmology*. 2006;**141**:1027-1032. DOI: 10.1016/j.ajo.2006.01.016
- [13] Arden GB, Sivaprasad S. Hypoxia and oxidative stress in the causation of diabetic retinopathy. *Current Diabetes Reviews*. 2011;**7**:291-304
- [14] Nyengaard JR, Ido Y, Kilo C, Williamson JR. Interactions between hyperglycemia and hypoxia: Implications for diabetic retinopathy. *Diabetes*. 2004;**53**:2931-2938
- [15] Stefánsson E, Machemer R, de Juan E, McCuen BW, Peterson J. Retinal oxygenation and laser treatment in patients with diabetic retinopathy. *American Journal of Ophthalmology*. 1992;**113**:36-38
- [16] Forsythe JA, Jiang BH, Iyer NV, Agani F, Leung SW, Koos RD, et al. Activation of vascular endothelial growth factor gene transcription by hypoxia-inducible factor 1. *Molecular and Cellular Biology*. 1996;**16**:4604-4613
- [17] Wiesener MS, Turley H, Allen WE, Willam C, Eckardt KU, Talks KL, et al. Induction of endothelial PAS domain protein-1 by hypoxia: Characterization and comparison with hypoxia-inducible factor-1alpha. *Blood*. 1998;**92**:2260-2268
- [18] Duan C. Hypoxia-inducible factor 3 biology: Complexities and emerging themes. *American Journal of Physiology. Cell Physiology*. 2016;**310**:C260-C269. DOI: 10.1152/ajp-cell.00315.2015
- [19] Zhang P, Yao Q, Lu L, Li Y, Chen P-J, Duan C. Hypoxia-inducible factor 3 is an oxygen-dependent transcription activator and regulates a distinct transcriptional response to hypoxia. *Cell Reports*. 2014;**6**:1110-1121. DOI: 10.1016/j.celrep.2014.02.011

- [20] Appelhoff RJ, Tian Y-M, Raval RR, Turley H, Harris AL, Pugh CW, et al. Differential function of the prolyl hydroxylases PHD1, PHD2, and PHD3 in the regulation of hypoxia-inducible factor. *The Journal of Biological Chemistry*. 2004;**279**:38458-38465. DOI: 10.1074/jbc.M406026200
- [21] Min J-H, Yang H, Ivan M, Gertler F, Kaelin WG, Pavletich NP. Structure of an HIF-1 $\alpha$ -pVHL complex: Hydroxyproline recognition in signaling. *Science*. 2002;**296**:1886-1889. DOI: 10.1126/science.1073440
- [22] Hon W-C, Wilson MI, Harlos K, Claridge TDW, Schofield CJ, Pugh CW, et al. Structural basis for the recognition of hydroxyproline in HIF-1  $\alpha$  by pVHL. *Nature*. 2002;**417**:975-978. DOI: 10.1038/nature00767
- [23] Jaakkola P, Mole DR, Tian YM, Wilson MI, Gielbert J, Gaskell SJ, et al. Targeting of HIF- $\alpha$  to the von Hippel-Lindau ubiquitylation complex by O<sub>2</sub>-regulated prolyl hydroxylation. *Science*. 2001;**292**:468-472. DOI: 10.1126/science.1059796
- [24] Tanimoto K, Makino Y, Pereira T, Poellinger L. Mechanism of regulation of the hypoxia-inducible factor-1  $\alpha$  by the von Hippel-Lindau tumor suppressor protein. *The EMBO Journal*. 2000;**19**:4298-4309. DOI: 10.1093/emboj/19.16.4298
- [25] Lando D, Peet DJ, Whelan DA, Gorman JJ, Whitelaw ML. Asparagine hydroxylation of the HIF transactivation domain a hypoxic switch. *Science*. 2002;**295**:858-861. DOI: 10.1126/science.1068592
- [26] Mowat FM, Luhmann UFO, Smith AJ, Lange C, Duran Y, Harten S, et al. HIF-1 $\alpha$  and HIF-2 $\alpha$  are differentially activated in distinct cell populations in retinal ischaemia. *PLoS One*. 2010;**5**:e11103. DOI: 10.1371/journal.pone.0011103
- [27] Ozaki H, Yu AY, Della N, Ozaki K, Luna JD, Yamada H, et al. Hypoxia inducible factor-1 $\alpha$  is increased in ischemic retina: Temporal and spatial correlation with VEGF expression. *Investigative Ophthalmology & Visual Science*. 1999;**40**:182-189
- [28] Dioum EM, Clarke SL, Ding K, Repa JJ, Garcia JA. HIF-2 $\alpha$ -haploinsufficient mice have blunted retinal neovascularization due to impaired expression of a proangiogenic gene battery. *Investigative Ophthalmology & Visual Science*. 2008;**49**:2714-2720. DOI: 10.1167/iovs.07-1469
- [29] Koivunen P, Hirsilä M, Remes AM, Hassinen IE, Kivirikko KI, Myllyharju J. Inhibition of hypoxia-inducible factor (HIF) hydroxylases by citric acid cycle intermediates: Possible links between cell metabolism and stabilization of HIF. *The Journal of Biological Chemistry*. 2007;**282**:4524-4532. DOI: 10.1074/jbc.M610415200
- [30] Benzi G, Pastoris O, Dossena M. Relationships between gamma-aminobutyrate and succinate cycles during and after cerebral ischemia. *Journal of Neuroscience Research*. 1982;**7**:193-201. DOI: 10.1002/jnr.490070210
- [31] He W, Miao FJ-P, Lin DC-H, Schwandner RT, Wang Z, Gao J, et al. Citric acid cycle intermediates as ligands for orphan G-protein-coupled receptors. *Nature*. 2004;**429**:188-193. DOI: 10.1038/nature02488

- [32] Li T, Hu J, Du S, Chen Y, Wang S, Wu Q. ERK1/2/COX-2/PGE2 signaling pathway mediates GPR91-dependent VEGF release in streptozotocin-induced diabetes. *Molecular Vision*. 2014;**20**:1109-1121
- [33] Hu J, Li T, Du S, Chen Y, Wang S, Xiong F, et al. The MAPK signaling pathway mediates the GPR91-dependent release of VEGF from RGC-5 cells. *International Journal of Molecular Medicine*. 2015;**36**:130-138. DOI: 10.3892/ijmm.2015.2195
- [34] Sapieha P, Sirinyan M, Hamel D, Zaniolo K, Joyal J-S, Cho J-H, et al. The succinate receptor GPR91 in neurons has a major role in retinal angiogenesis. *Nature Medicine*. 2008;**14**:1067-1076. DOI: 10.1038/nm.1873
- [35] Bek T, Ledet T. Vascular occlusion in diabetic retinopathy. A qualitative and quantitative histopathological study. *Acta Ophthalmologica Scandinavica*. 1996;**74**:36-40
- [36] Schröder S, Palinski W, Schmid-Schönbein GW. Activated monocytes and granulocytes, capillary nonperfusion, and neovascularization in diabetic retinopathy. *The American Journal of Pathology*. 1991;**139**:81-100
- [37] Niki T, Muraoka K, Shimizu K. Distribution of capillary nonperfusion in early-stage diabetic retinopathy. *Ophthalmology*. 1984;**91**:1431-1439
- [38] Hammes H-P, Lin J, Renner O, Shani M, Lundqvist A, Betsholtz C, et al. Pericytes and the pathogenesis of diabetic retinopathy. *Diabetes*. 2002;**51**:3107-3112
- [39] Feit-Leichman RA, Kinouchi R, Takeda M, Fan Z, Mohr S, Kern TS, et al. Vascular damage in a mouse model of diabetic retinopathy: Relation to neuronal and glial changes. *Investigative Ophthalmology & Visual Science*. 2005;**46**:4281-4287. DOI: 10.1167/iovs.04-1361
- [40] Mohr S, Vincent J, Kern T. Minocycline prevents the formation of acellular capillaries in mouse models for diabetic retinopathy. *FASEB Journal*. 2006;**20**:A1150
- [41] Braun RD, Fisher TC, Meiselman HJ, Hatchell DL. Decreased deformability of polymorphonuclear leukocytes in diabetic cats. *Microcirculation (New York, N.Y.: 1994)*. 1996;**3**:271-278
- [42] Harris AG, Skalak TC, Hatchell DL. Leukocyte-capillary plugging and network resistance are increased in skeletal muscle of rats with streptozotocin-induced hyperglycemia. *International Journal of Microcirculation, Clinical and Experimental*. 1994;**14**:159-166
- [43] Berkowitz BA, Kowluru RA, Frank RN, Kern TS, Hohman TC, Prakash M. Subnormal retinal oxygenation response precedes diabetic-like retinopathy. *Investigative Ophthalmology & Visual Science*. 1999;**40**:2100-2105
- [44] Behzadian MA, Wang X-L, Shabrawey M, Caldwell RB. Effects of hypoxia on glial cell expression of angiogenesis-regulating factors VEGF and TGF- $\beta$ . *Glia*. 1998;**24**:216-225. DOI: 10.1002/(SICI)1098-1136(199810)24:2<216::AID-GLIA6>3.0.CO;2-1
- [45] Stone J, Itin A, Alon T, Pe'er J, Gnessin H, Chan-Ling T, et al. Development of retinal vasculature is mediated by hypoxia-induced vascular endothelial growth factor (VEGF) expression by neuroglia. *The Journal of Neuroscience*. 1995;**15**:4738-4747



- [46] Namiki A, Brogi E, Kearney M, Kim EA, Wu T, Couffinhal T, et al. Hypoxia induces vascular endothelial growth factor in cultured human endothelial cells. *The Journal of Biological Chemistry*. 1995;**270**:31189-31195. DOI: 10.1074/jbc.270.52.31189
- [47] Xin X, Rodrigues M, Umapathi M, Kashiwabuchi F, Ma T, Babapoor-Farrokhran S, et al. Hypoxic retinal Muller cells promote vascular permeability by HIF-1-dependent up-regulation of angiopoietin-like 4. *Proceedings of the National Academy of Sciences of the United States of America*. 2013;**110**:E3425-E3434. DOI: 10.1073/pnas.1217091110
- [48] Adamis AP, Miller JW, Bernal MT, D'Amico DJ, Folkman J, Yeo TK, et al. Increased vascular endothelial growth factor levels in the vitreous of eyes with proliferative diabetic retinopathy. *American Journal of Ophthalmology*. 1994;**118**:445-450
- [49] Wang Z, Yadav AS, Leskova W, Harris NR. Attenuation of streptozotocin-induced microvascular changes in the mouse retina with the endothelin receptor A antagonist atrasentan. *Experimental Eye Research*. 2010;**91**:670-675. DOI: 10.1016/j.exer.2010.08.008
- [50] Yadav AS, Harris NR. Effect of tempol on diabetes-induced decreases in retinal blood flow in the mouse. *Current Eye Research*. 2011;**36**:456-461. DOI: 10.3109/02713683.2011.556300
- [51] Lee S, Morgan GA, Harris NR. Ozagrel reverses streptozotocin-induced constriction of arterioles in rat retina. *Microvascular Research*. 2008;**76**:217-223. DOI: 10.1016/j.mvr.2008.07.005
- [52] Wright WS, Harris NR. Ozagrel attenuates early streptozotocin-induced constriction of arterioles in the mouse retina. *Experimental Eye Research*. 2008;**86**:528-536. DOI: 10.1016/j.exer.2007.12.012
- [53] Wright WS, McElhatten RM, Messina JE, Harris NR. Hypoxia and the expression of HIF-1 $\alpha$  and HIF-2 $\alpha$  in the retina of streptozotocin-injected mice and rats. *Experimental Eye Research*. 2010;**90**:405-412. DOI: 10.1016/j.exer.2009.12.002
- [54] Wright WS, McElhatten RM, Harris NR. Increase in retinal hypoxia inducible factor-2 $\alpha$ , but not hypoxia, early in the progression of diabetes in the rat. *Experimental Eye Research*. 2011;**93**:437-441. DOI: 10.1016/j.exer.2011.06.003
- [55] Wright WS, Singh Yadav A, McElhatten RM, Harris NR. Retinal blood flow abnormalities following six months of hyperglycemia in the Ins2(Akita) mouse. *Experimental Eye Research*. 2012;**98**:9-15. DOI: 10.1016/j.exer.2012.03.003
- [56] Linsenmeier RA. Effects of light and darkness on oxygen distribution and consumption in the cat retina. *The Journal of General Physiology*. 1986;**88**:521-542
- [57] Linsenmeier RA, Braun RD. Oxygen distribution and consumption in the cat retina during normoxia and hypoxemia. *The Journal of General Physiology*. 1992;**99**:177-197
- [58] DY Y, Alder VA, Cringle SJ, EN S, Burns M. Intraretinal oxygen distribution in urethan-induced retinopathy in rats. *The American Journal of Physiology*. 1998;**274**:H2009-H2017

- [59] DY Y, Cringle SJ, Alder V, SEN. Intraretinal oxygen distribution in the rat with graded systemic hyperoxia and hypercapnia. *Investigative Ophthalmology & Visual Science*. 1999;**40**:2082-2087
- [60] D-Y Y, Cringle SJ, E-N S, YPK. Intraretinal oxygen levels before and after photoreceptor loss in the RCS rat. *Investigative Ophthalmology & Visual Science*. 2000;**41**:3999-4006
- [61] Ogawa S, Lee TM, Kay AR, Tank DW. Brain magnetic resonance imaging with contrast dependent on blood oxygenation. *Proceedings of the National Academy of Sciences of the United States of America*. 1990;**87**:9868-9872
- [62] Ogawa S, Lee TM. Magnetic resonance imaging of blood vessels at high fields: In vivo and in vitro measurements and image simulation. *Magnetic Resonance in Medicine*. 1990;**16**:9-18
- [63] Ogawa S, Lee TM, Nayak AS, Glynn P. Oxygenation-sensitive contrast in magnetic resonance image of rodent brain at high magnetic fields. *Magnetic Resonance in Medicine*. 1990;**14**:68-78
- [64] Berkowitz BA, Roberts R, Luan H, Peysakhov J, Mao X, Thomas KA. Dynamic contrast-enhanced mri measurements of passive permeability through blood retinal barrier in diabetic rats. *Investigative Ophthalmology & Visual Science*. 2004;**45**:2391-2398. DOI: 10.1167/iovs.03-1381
- [65] Berkowitz BA, Wilson CA. Quantitative mapping of ocular oxygenation using magnetic resonance imaging. *Magnetic Resonance in Medicine*. 1995;**33**:579-581. DOI: 10.1002/mrm.1910330419
- [66] Duong TQ, Ngan S-C, Ugurbil K, Kim S-G. Functional magnetic resonance imaging of the retina. *Investigative Ophthalmology & Visual Science*. 2002;**43**:1176-1181
- [67] Ito Y, Berkowitz BA. MR studies of retinal oxygenation. *Vision Research*. 2001;**41**:1307-1311
- [68] Falsini B, Riva CE, Logean E. Flicker-evoked changes in human optic nerve blood flow: Relationship with retinal neural activity. *Investigative Ophthalmology & Visual Science*. 2002;**43**:2309-2316
- [69] Petrig BL, Riva CE, Hayreh SS. Laser Doppler flowmetry and optic nerve head blood flow. *American Journal of Ophthalmology*. 1999;**127**:413-425
- [70] Longo A, Geiser M, Riva CE. Subfoveal choroidal blood flow in response to light-dark exposure. *Investigative Ophthalmology & Visual Science*. 2000;**41**:2678-2683
- [71] Hickam JB, Frayser R, Ross JC. A study of retinal venous blood oxygen saturation in human subjects by photographic means. *Circulation*. 1963;**27**:375-385
- [72] Delori FC. Noninvasive technique for oximetry of blood in retinal vessels. *Applied Optics*. 1988;**27**:1113-1125

- [73] Beach JM, Schwenger KJ, Srinivas S, Kim D, Tiedeman JS. Oximetry of retinal vessels by dual-wavelength imaging: Calibration and influence of pigmentation. *Journal of Applied Physiology*. 1999;**86**:748-758
- [74] Hardarson SH, Harris A, Karlsson RA, Halldorsson GH, Kagemann L, Rechtman E, et al. Automatic retinal Oximetry. *Investigative Ophthalmology & Visual Science*. 2006;**47**:5011-5016. DOI: 10.1167/iovs.06-0039
- [75] Ibrahim MA, Annam RE, Sepah YJ, Luu L, Bittencourt MG, Jang HS, et al. Assessment of oxygen saturation in retinal vessels of normal subjects and diabetic patients with and without retinopathy using flow oximetry system. *Quantitative Imaging in Medicine and Surgery*. 2015;**5**:86-96. DOI: 10.3978/j.issn.2223-4292.2014.11.26
- [76] Lemaillot P, Duncan DD, Lompado A, Ibrahim M, Nguyen QD, Ramella-Roman JC. Retinal spectral imaging and blood flow measurement. *Journal of Innovative Optical Health Sciences*. 2010;**03**:255-265. DOI: 10.1142/S1793545810001131
- [77] Hammer M, Vilser W, Riemer T, Mandecka A, Schweitzer D, Kühn U, et al. Diabetic patients with retinopathy show increased retinal venous oxygen saturation. *Graefes Archive for Clinical and Experimental Ophthalmology*. 2009;**247**:1025-1030. DOI: 10.1007/s00417-009-1078-6
- [78] Guduru A, Martz TG, Waters A, Kshirsagar AV, Garg S. Oxygen saturation of retinal vessels in all stages of diabetic retinopathy and correlation to ultra-wide field fluorescein angiography retinal oximetry and IVFA in diabetic retinopathy. *Investigative Ophthalmology & Visual Science*. 2016;**57**:5278-5284. DOI: 10.1167/iovs.16-20190
- [79] Dong Y, Lin L, Yan H, Fu Y, Zong Y, Yuan Y, et al. Shifts in retinal vessel diameter and oxygen saturation in Chinese type 2 diabetes mellitus patients. *BMC Ophthalmology*. 2016;**16**:43. DOI: 10.1186/s12886-016-0217-1
- [80] Jørgensen CM, Hardarson SH, Bek T. The oxygen saturation in retinal vessels from diabetic patients depends on the severity and type of vision-threatening retinopathy. *Acta Ophthalmologica*. 2014;**92**:34-39. DOI: 10.1111/aos.12283
- [81] Jørgensen C, Bek T. Increasing oxygen saturation in larger retinal vessels after photocoagulation for diabetic retinopathy. *Investigative Ophthalmology & Visual Science*. 2014;**55**:5365-5369. DOI: 10.1167/iovs.14-14811
- [82] Khoobehi B, Firn K, Thompson H, Reinoso M, Beach J. Retinal arterial and venous oxygen saturation is altered in diabetic patients. *Investigative Ophthalmology & Visual Science*. 2013;**54**:7103-7106. DOI: 10.1167/iovs.13-12723
- [83] Hardarson SH, Stefánsson E. Retinal oxygen saturation is altered in diabetic retinopathy. *The British Journal of Ophthalmology*. 2012;**96**:560-563. DOI: 10.1136/bjophthalmol-2011-300640
- [84] Jørgensen CM, Bek T. Lack of differences in the regional variation of oxygen saturation in larger retinal vessels in diabetic maculopathy and proliferative diabetic retinopathy.

The British Journal of Ophthalmology. 2017;**101**:752-757. DOI: 10.1136/bjophthalmol-2016-308894

- [85] Schweitzer D, Thamm E, Hammer M, Kraft J. A new method for the measurement of oxygen saturation at the human ocular fundus. *International Ophthalmology*. 2001;**23**:347-353
- [86] Schweitzer D, Hammer M, Kraft J, Thamm E, Königsdörffer E, Strobel J. Vivo measurement of the oxygen saturation of retinal vessels in healthy volunteers. *IEEE Transactions on Biomedical Engineering*. 1999;**46**:1454-1465
- [87] Khoobehi B, Beach JM, Kawano H. Hyperspectral imaging for measurement of oxygen saturation in the optic nerve head. *Investigative Ophthalmology & Visual Science*. 2004;**45**:1464-1472
- [88] Yoneya S, Saito T, Nishiyama Y, Deguchi T, Takasu M, Gil T, et al. Retinal oxygen saturation levels in patients with central retinal vein occlusion. *Ophthalmology*. 2002;**109**:1521-1526
- [89] Beach J, Ning J, Khoobehi B. Oxygen saturation in optic nerve head structures by hyperspectral image analysis. *Current Eye Research*. 2007;**32**:161-170. DOI: 10.1080/02713680601139192
- [90] Kashani AH, Kirkman E, Martin G, Humayun MS. Hyperspectral computed tomographic imaging spectroscopy of vascular oxygen gradients in the rabbit retina in vivo. *PLoS One*. 2011;**6**:e24482. DOI: 10.1371/journal.pone.0024482
- [91] Kashani AH, Lopez Jaime GR, Saati S, Martin G, Varma R, Humayun MS. Noninvasive assessment of retinal vascular oxygen content among normal and diabetic human subjects: A study using hyperspectral computed tomographic imaging spectroscopy. *Retina (Philadelphia, Pa.)*. 2014;**34**:1854-1860. DOI: 10.1097/IAE.0000000000000146
- [92] Vanderkooi JM, Maniara G, Green TJ, Wilson DF. An optical method for measurement of dioxygen concentration based upon quenching of phosphorescence. *The Journal of Biological Chemistry*. 1987;**262**:5476-5482
- [93] Wilson DF, Rumsey WL, Green TJ, Vanderkooi JM. The oxygen dependence of mitochondrial oxidative phosphorylation measured by a new optical method for measuring oxygen concentration. *The Journal of Biological Chemistry*. 1988;**263**:2712-2718
- [94] Knopp JA, Longmuir IS. Intracellular measurement of oxygen by quenching of fluorescence of pyrenebutyric acid. *Biochimica et Biophysica Acta (BBA) - General Subjects*. 1972;**279**:393-397. DOI: 10.1016/0304-4165(72)90158-4
- [95] Shonat RD, Wilson DF, Riva CE, Pawlowski M. Oxygen distribution in the retinal and choroidal vessels of the cat as measured by a new phosphorescence imaging method. *Applied Optics*. 1992;**31**:3711-3718. DOI: 10.1364/AO.31.003711
- [96] Shonat RD, Wilson DF, Riva CE, Cranstoun SD. Effect of acute increases in intraocular pressure on intravascular optic nerve head oxygen tension in cats. *Investigative Ophthalmology & Visual Science*. 1992;**33**:3174-3180



- [97] Blumenröder S, Augustin AJ, Koch FH. The influence of intraocular pressure and systemic oxygen tension on the intravascular pO<sub>2</sub> of the pig retina as measured with phosphorescence imaging. *Survey of Ophthalmology*. 1997;**42**(Suppl 1):S118-S126
- [98] Shonat RD, Kight AC. Frequency Domain Imaging of Oxygen Tension in the Mouse Retina. *Oxyg. Transp. Boston, MA: Tissue XXIII*. Springer; 2003. pp. 243-247. DOI: 10.1007/978-1-4615-0205-0\_40
- [99] Shonat RD, Kight AC. Oxygen tension imaging in the mouse retina. *Annals of Biomedical Engineering*. 2003;**31**:1084-1096
- [100] Wilson DF, Vinogradov SA, Grosul P, Vaccarezza MN, Kuroki A, Bennett J. Oxygen distribution and vascular injury in the mouse eye measured by phosphorescence-lifetime imaging. *Applied Optics*. 2005;**44**:5239-5248
- [101] Wilson DF, Vinogradov SA, Grosul P, Kuroki A, Bennett J. Imaging Oxygen Pressure in the Retina of the Mouse Eye. *Oxyg. Transp. Boston, MA: Tissue XXVI*, Springer; 2005. pp. 159-165. DOI: 10.1007/0-387-26206-7\_22
- [102] Shahidi M, Shakoor A, Blair NP, Mori M, Shonat RD. A method for chorioretinal oxygen tension measurement. *Current Eye Research*. 2006;**31**:357-366. DOI: 10.1080/02713680600599446
- [103] Shakoor A, Gupta M, Blair NP, Shahidi M. Chorioretinal vascular oxygen tension in spontaneously breathing anesthetized rats. *Ophthalmic Research*. 2007;**39**:103-107. DOI: 10.1159/000099246
- [104] Shakoor A, Blair NP, Mori M, Shahidi M. Chorioretinal vascular oxygen tension changes in response to light flicker. *Investigative Ophthalmology & Visual Science*. 2006;**47**:4962-4965. DOI: 10.1167/iovs.06-0291
- [105] Shahidi M, Wanek J, Blair NP, Little DM, Wu T. Retinal tissue oxygen tension imaging in the rat. *Investigative Ophthalmology & Visual Science*. 2010;**51**:4766-4770. DOI: 10.1167/iovs.09-4710
- [106] Felder AE, Wanek J, Tan MR, Blair NP, Shahidi M. A method for combined retinal vascular and tissue oxygen tension imaging. *Scientific Reports*. 2017;**7**:10622. DOI: 10.1038/s41598-017-10955-1
- [107] Mezu-Ndubuisi OJ, Teng P, Wanek J, Blair NP, Chau FY, Reddy NM, et al. In vivo retinal vascular oxygen tension imaging and fluorescein angiography in the mouse model of oxygen-induced retinopathy. *Investigative Ophthalmology & Visual Science*. 2013;**54**:6968-6972. DOI: 10.1167/iovs.13-12126
- [108] Buerk DG, Tsai AG, Intaglietta M, Johnson PC. Comparing Tissue PO<sub>2</sub> Measurements by Recessed Microelectrode and Phosphorescence Quenching. *Oxyg. Transp. Boston, MA: Tissue XX*, Springer; 1998. pp. 367-374. DOI: 10.1007/978-1-4615-4863-8\_44
- [109] Gross MW, Karbach U, Groebe K, Franko AJ, Mueller-Klieser W. Calibration of misonidazole labeling by simultaneous measurement of oxygen tension and labeling density in multicellular spheroids. *International Journal of Cancer*. 1995;**61**:567-573

- [110] Raleigh JA, Miller GG, Franko AJ, Koch CJ, Fuciarelli AF, Kelly DA. Fluorescence immunohistochemical detection of hypoxic cells in spheroids and tumours. *British Journal of Cancer*. 1987;**56**:395-400
- [111] Miller GG, Best MW, Franko AJ, Koch CJ, Raleigh JA. Quantitation of hypoxia in multicellular spheroids by video image analysis. *International Journal of Radiation Oncology*. 1989;**16**:949-952. DOI: 10.1016/0360-3016(89)90893-6
- [112] Chapman JD, Franko AJ, Sharplin J. A marker for hypoxic cells in tumours with potential clinical applicability. *British Journal of Cancer*. 1981;**43**:546-550
- [113] Varia MA, Calkins-Adams DP, Rinker LH, Kennedy AS, Novotny DB, Fowler WC, et al. Pimonidazole: A novel hypoxia marker for complementary study of tumor hypoxia and cell proliferation in cervical carcinoma. *Gynecologic Oncology*. 1998;**71**:270-277. DOI: 10.1006/gyno.1998.5163
- [114] Franko AJ, Chapman JD. Binding of <sup>14</sup>C-misonidazole to hypoxic cells in V79 spheroids. *British Journal of Cancer*. 1982;**45**:694-699
- [115] Aguilera KY, Brekken RA. Hypoxia studies with pimonidazole in vivo. *Bio-Protocol*. 2014;**4**
- [116] Ly A, Yee P, Vessey KA, Phipps JA, Jobling AI, Fletcher EL. Early inner retinal astrocyte dysfunction during diabetes and development of hypoxia, retinal stress, and neuronal functional loss. *Investigative Ophthalmology & Visual Science*. 2011;**52**:9316-9326. DOI: 10.1167/iovs.11-7879
- [117] Rothschild P-R, Salah S, Berdugo M, Gélizé E, Delaunay K, Naud M-C, et al. ROCK-1 mediates diabetes-induced retinal pigment epithelial and endothelial cell blebbing: Contribution to diabetic retinopathy. *Scientific Reports*. 2017;**7**:8834. DOI: 10.1038/s41598-017-07329-y
- [118] Curtis TM, Gardiner TA, Stitt AW. Microvascular lesions of diabetic retinopathy: Clues towards understanding pathogenesis? *Eye (London, England)*. 2009;**23**:1496-1508. DOI: 10.1038/eye.2009.108
- [119] Gooyer de TE, Stevenson KA, Humphries P, Simpson DAC, Gardiner TA, Stitt AW. Retinopathy is reduced during experimental diabetes in a mouse model of outer retinal degeneration. *Investigative Ophthalmology & Visual Science*. 2006;**47**:5561-5568. DOI: 10.1167/iovs.06-0647
- [120] Evans SM, Kim K, Moore CE, Uddin MI, Capozzi ME, Craft JR, et al. Molecular probes for imaging of hypoxia in the retina. *Bioconjugate Chemistry*. 2014;**25**:2030-2037. DOI: 10.1021/bc500400z
- [121] Uddin MI, Evans SM, Craft JR, Marnett LJ, Uddin MJ, Jayagopal A. Applications of azo-based probes for imaging retinal hypoxia. *ACS Medicinal Chemistry Letters*. 2015;**6**:445-449. DOI: 10.1021/ml5005206
- [122] Myochin T, Hanaoka K, Komatsu T, Terai T, Nagano T. Design strategy for a near-infrared fluorescence probe for matrix metalloproteinase utilizing highly cell permeable

- boron dipyrromethene. *Journal of the American Chemical Society*. 2012;**134**:13730-13737. DOI: 10.1021/ja303931b
- [123] Kiyose K, Hanaoka K, Oushiki D, Nakamura T, Kajimura M, Suematsu M, et al. Hypoxia-sensitive fluorescent probes for in vivo real-time fluorescence imaging of acute ischemia. *Journal of the American Chemical Society*. 2010;**132**:15846-15848. DOI: 10.1021/ja105937q
- [124] Uddin MI, Evans SM, Craft JR, Capozzi ME, McCollum GW, Yang R, et al. *In Vivo* imaging of retinal hypoxia in a model of oxygen-induced retinopathy. *Scientific Reports*. 2016;**6**:srep31011. DOI: 10.1038/srep31011
- [125] Uddin MI, Jayagopal A, McCollum GW, Yang R, Penn JS. In vivo imaging of retinal hypoxia using HYPOX-4-dependent fluorescence in a mouse model of laser-induced retinal vein occlusion (RVO). *Investigative Ophthalmology & Visual Science*. 2017;**58**:3818-3824. DOI: 10.1167/iovs.16-21187
- [126] Joussen AM, Poulaki V, Le ML, Koizumi K, Esser C, Janicki H, et al. A central role for inflammation in the pathogenesis of diabetic retinopathy. *FASEB journal : official publication of the Federation of American Societies for Experimental Biology*. 2004;**18**:1450-1452. DOI: 10.1096/fj.03-1476fje
- [127] Zheng L, Gong B, Hatala DA, Kern TS. Retinal ischemia and reperfusion causes capillary degeneration: Similarities to diabetes. *Investigative Ophthalmology & Visual Science*. 2007;**48**:361-367. DOI: 10.1167/iovs.06-0510
- [128] Simpson DA, Murphy GM, Bhaduri T, Gardiner TA, Archer DB, Stitt AW. Expression of the VEGF gene family during retinal vaso-obliteration and hypoxia. *Biochemical and Biophysical Research Communications*. 1999;**262**:333-340. DOI: 10.1006/bbrc.1999.1201
- [129] Kernt M, Thiele S, Liegl RG, Kernt B, Eibl K, Haritoglou C, et al. Axitinib modulates hypoxia-induced blood-retina barrier permeability and expression of growth factors. *Growth factors (Chur, Switzerland)*. 2012;**30**:49-61. DOI: 10.3109/08977194.2011.639300
- [130] Tiedeman JS, Kirk SE, Srinivas S, Beach JM. Retinal oxygen consumption during hyperglycemia in patients with diabetes without retinopathy. *Ophthalmology*. 1998;**105**:31-36