

# We are IntechOpen, the world's leading publisher of Open Access books Built by scientists, for scientists

6,900

Open access books available

186,000

International authors and editors

200M

Downloads

Our authors are among the

154

Countries delivered to

TOP 1%

most cited scientists

12.2%

Contributors from top 500 universities



WEB OF SCIENCE™

Selection of our books indexed in the Book Citation Index  
in Web of Science™ Core Collection (BKCI)

Interested in publishing with us?  
Contact [book.department@intechopen.com](mailto:book.department@intechopen.com)

Numbers displayed above are based on latest data collected.  
For more information visit [www.intechopen.com](http://www.intechopen.com)



---

# Immune-Mediated Skin Reactions Induced by Recombinant Antibodies and Other TNF-Alpha Inhibitors

---

Karolína Vorčáková, Péč Juraj, Péčová Tatiana and Martinásková Klára

Additional information is available at the end of the chapter

<http://dx.doi.org/10.5772/intechopen.72449>

---

## Abstract

Biologic agents that act by inhibiting tumour necrosis factor alpha (TNF-alpha) have become a breakthrough treatment for chronic inflammatory diseases. This highly effective treatment has surprisingly brought us new adverse effects that we had not encountered before the age of biologics. Immune-mediated reactions are a group of adverse effects with not clearly understood etiopathogenesis. It turns out that TNF-alpha inhibitors are able to disrupt the cytokine cascade in genetically predisposed individuals. Some of the theories assume a cross reaction and overproduction of interferon (INF) alpha, while others put an emphasis on dysregulation of cytokines, in particular interleukin (IL)-17. Similarly, debatable is the role of the reactions mentioned in the etiopathogenesis, the production of antibodies against biologics and the production of antinuclear antibodies. The most common immune-mediated skin reactions are psoriasis and psoriasiform reactions, lupus-like syndrome, sarcoidosis, alopecia areata, vasculitis and lichenoid reactions. Less common reactions described in our paper include pyoderma gangrenosum and morphea. Most of these reactions belong to the so-called paradoxical reactions. Paradoxical psoriasis is an adverse effect, represented by occurrence of a disease caused by the therapeutic class of drugs normally used to cure or improve symptoms of such disease.

**Keywords:** TNF-alpha inhibitors, psoriasiform reaction, paradoxical reaction, antibodies, Th17

---

## 1. Introduction

Immune-mediated adverse reactions are a new group of diseases developing during anti-TNF-alpha treatment. Their clear etiopathogenesis is not known. Most authors assume that there

is a link to possible significant interference of the anti-TNF- $\alpha$  therapy with the immune system, which subsequently induces the above-mentioned responses. Others associate the diseases with the production of antibodies against the biologic agents and include the symptoms among hypersensitivity reactions. However, the individual genetic predisposition, which may be essential in detecting of immune-mediated reactions, must not be overlooked. The reactions include a broad variety of diseases such as lupus-like syndrome, autoimmune arthralgia, psoriasis, sarcoidosis, dermatomyositis, hepatitis, vasculitis, neurological demyelinating diseases and the like. In this chapter, we will briefly characterise the most common skin immune-mediated reactions induced by TNF- $\alpha$  inhibitors.

TNF is produced as a transmembrane protein (tmTNF), which is later cleaved by an enzyme metalloproteinase to its soluble form, sTNF [1]. Both TNFR1 and TNFR2 receptors signal through pathways that are proinflammatory and anti-apoptotic. Moreover, TNFR1 can signal directly through death domain caspase-dependent pathways that lead to apoptosis [2]. TNFR1 plays a role in response to bacterial infection [3] and TNFR2 may downregulate inflammatory signals driven by TNF [4].

Currently, five complete recombinant antibodies—infliximab, etanercept, adalimumab, golimumab and certolizumab pegol—are available TNF- $\alpha$  inhibitors. They are biotechnologically produced and administered as systemic drugs modifying the biological response and signalling on the molecular level. The structural differences are key to different risk for adverse effects such as granulomatous infections, with TNF antibodies associated with higher risk compared to soluble receptor, possibly due to binding to tmTNF receptor on the activated cells [5].

Infliximab is a recombinant chimeric monoclonal antibody containing human IgG1 Fc and variable murine regions, which forms complexes with both sTNF and tmTNF. It induces the lysis of macrophages and monocytes by cytotoxicity dependent on complement and antibodies [6]. The intravenous administration is applied by a weight-dependent dose. Drug-mediated apoptosis and monocytopenia are linked to infliximab as well as its ability to bind more avidly to different forms of TNF- $\alpha$  [7]. Adalimumab is a humanised monoclonal antibody containing human IgG1 Fc and human variable regions that bind sTNF as well as tmTNF. The other available humanised monoclonal antibody, certolizumab pegol is a pegylated monoclonal Fab fragment with polyethylene glycol binding to soluble and membrane-bound TNF- $\alpha$ , inhibiting the proinflammatory actions of this cytokine. Unlike other TNF inhibitors, owing to its lack of the Fc component, it is incapable of fixing complement or binding to Fc receptors. Golimumab is a human anti-TNF monoclonal antibody containing the IgG1 constant region.

The other group of TNF inhibitors consists solely of etanercept, which is soluble TNF receptor containing the human IgG1 Fc portion fused to the extracellular portion of human TNFRp75. It creates less stable complexes with tmTNF and firmly binds to trimeric forms of soluble TNF.

## 2. Psoriasis

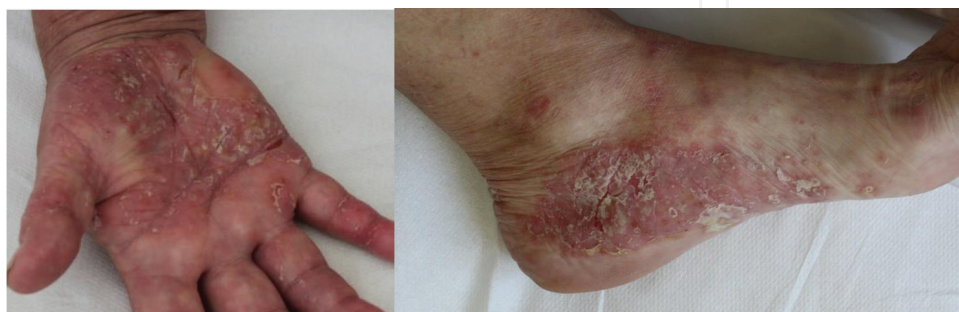TNF- $\alpha$  inhibitors have become a revolutionary medication in the treatment of chronic psoriasis in recent years. Conversely, psoriasis or psoriasiform reaction is one of the most common

immune-mediated reactions. Therefore, the formation of TNF alpha-induced psoriasis is also called a paradoxical reaction. All of the mentioned TNF-alpha antagonists can induce psoriasis. Cases have been reported from all indications where anti-TNF-alpha treatment is given. According to the literature, the incidence of paradoxical psoriasis is 1.04–3.0 cases per 1000 patient-years, the percentages varying widely from 0.6 to 5.3% [8]. The incidence of the manifestation is not age and gender related; some studies also show other controversial data. Manifestation may occur in any period of time during the treatment, from weeks, months, up to the years. The average time of developing psoriasis is 10 months [9, 10]. Concomitant treatment with another immunosuppressant does not appear to prevent paradoxical psoriasis, although combined suppression is used in the treatment of immune-mediated reactions.

The clinical manifestation of paradoxical psoriasis may be variable in nature. Paradoxical psoriasis includes not only newly developed psoriasis but also a radical worsening of already existing psoriasis. The disease is most commonly manifested in the area of palms and soles in the form of palmoplantar pustulosis, which is reported in 56% of cases, other most common forms include chronic plaque psoriasis in 50% of the patients and guttate manifestations, which affect 12% of the patients. Patients may also suffer from multiple forms of disease simultaneously (15%) [11]. Other manifestations include scalp or nail involvement. There are also cases of alopecia areata and paradoxical psoriasis. Some authors assume that monoclonal antibodies are associated with development of de novo-induced psoriasis, while the etanercept fusion protein causes a worsening of pre-existing psoriasis [12] (**Figure 1**).

The exact etiopathogenesis of paradoxical psoriasis is not clear, and there are several opinions and theories. The first of them states that the manifestations are a hypersensitive reaction to a drug, not a newly developed classical disease. There are papers that due to the increased production of antibodies against biologics describe manifestations of induced generalised pustulosis that could fit into the spectrum of hypersensitivity reactions. Other papers disprove this theory on the basis of skin biopsy of the patients with TNF-alpha-induced psoriasis. The incidence of palmoplantar pustulous psoriasis in the common psoriatic population is significantly lower, representing 1.7% compared to 46.2% in patients with paradoxical reaction. This fact supports the theory that it should not be a new classical form of psoriasis [13].

The most widespread theory links the relationship between TNF-alpha and type 1 interferon alpha. TNF-alpha inhibits the maturation of plasma dendritic cells that produce IFN-alpha.



**Figure 1.** Patient with severe palmoplantar pustular psoriasis induced after 4 weeks of using adalimumab, this severe reaction lead to discontinuation of adalimumab.

The central role of INF- $\alpha$  in the etiopathogenesis of paradoxical psoriasiform reaction consists of cross-regulation between TNF- $\alpha$  and INF- $\alpha$ . TNF- $\alpha$  blockers can lead to overproduction of INF- $\alpha$ . In papers that confirm this theory, increased expression of interferon alpha was demonstrated in skin biopsy compared to common psoriatic findings [14]. It is also believed that the expression of CXCL9 and CXCR3 chemokine receptors is increased, which promote the migration of lymphocytes into psoriatic dermis resulting in skin damage. INF- $\alpha$  induces the expression of chemokine receptors on T lymphocytes [15].

One of the latest theories involves the Th17 pathway. In recent years, the Th17 signalling pathway is considered to be the major pathway of psoriasis etiopathogenesis. TNF- $\alpha$  may cause dysregulation in the immune system, which may cause the following changes. Activation of the IL-12/IL-23 pathway activates the Th17 signalling pathway followed by the production of IL-1b, IL-17, IL-21 and IL-22 together with an increased production of IL-17A and IL-22, hyperactivation of the Th17 and Th1 pathway and reduction of Treg activity [8, 15].

The genetic predisposition in patients with paradoxical reactions is not fully elucidated. Comorbidities are diseases that occur simultaneously with primary disease in higher prevalence compared to general population. Psoriasis comorbidities include a large group of diseases that are treated with anti-TNF- $\alpha$  therapies. It is believed that the genetic predisposition of an individual should also be essential for the development of immune-mediated reactions. There is a large group of “susceptibility” genes that are characteristic of several diseases and encode common inflammatory pathways. Polymorphisms of these genes are the subject of scientific research. Cabaleiro et al. presented the first paper studying 25 patients who developed paradoxical psoriasis genotyped for 173 single-nucleotide polymorphisms (SNPs) using the Illumina Veracode genotyping platform. Multivariate logistic regression revealed that five SNPs (rs11209026 in IL23R, rs10782001 in FBXL19, rs3087243 in CTLA4, rs651630 in SLC12A8 and rs1800453 in TAP1) were associated with paradoxical reactions [16].

Recently, we presented a study where we analysed antinuclear antibodies (ANA) and anti-double stranded DNA (dsDNA) antibodies in 10 patients with anti-TNF- $\alpha$  treatment induced psoriasis. ANA and anti-dsDNA antibodies were detected by ELISA. ANA serum samples were positive in 10% patients and anti-dsDNA antibody samples in 70% patients. The mechanism driving the formation of ANA and anti-dsDNA antibodies is poorly understood and their clinical significance is unknown [17]. In the literature, the frequency of ANA and anti-dsDNA antibodies in the patients after anti-TNF- $\alpha$  treatment varies extremely, possibly due to different methods of detection used. Pink et al. in their study, suggest that the development of ANA and anti-dsDNA antibodies on anti-TNF treatment may act as a marker of forthcoming treatment failure. In anti-TNF- $\alpha$ -induced lupus erythematosus, ANA and anti-dsDNA antibodies are well established and quite common (ANA, 90%; anti-dsDNA, 70–90%), but we have limited data about other immunological mediated adverse reactions [18]. Our data suggest that paradoxical psoriasis induced by anti-TNF inhibitors is associated with production of anti-dsDNA autoantibodies, but not with production of ANA antibodies. Further prospective research is necessary before general recommendations for daily practice can be announced. Genetic predisposition, clinical manifestation and production of anti-dsDNA antibodies seem to be fundamental in differentiation between adverse effects of anti-TNF- $\alpha$  treatment and associated disease comorbidity.



The therapeutic approach for anti-TNF-alpha-induced psoriasis is individual in each patient. A very important factor is the condition of the underlying disease, for which the treatment was indicated. In case of a serious condition that was stabilised with the treatment, we try to keep the biologic agent as long as possible. Equally important is what other therapeutic options are available. While in rheumatology we have a wide variety of biological medications for most diseases, including some others than anti-TNF-alpha inhibitors, the situation in patients with inflammatory bowel diseases (IBD) is much more complex.

Literature sources mention the following procedures: if the skin psoriatic manifestations involve up to 5% of the body surface, the first-line therapy should be topical (corticosteroid therapy, keratolytic therapy, treatment with vitamin D derivatives) followed by phototherapy and, in case of resistance, introducing methotrexate to the patient's therapy. In case that more than 5% of the body surface is involved, the recommended first-line therapy consists of topical corticosteroids and phototherapy, followed by methotrexate, cyclosporine and retinoids [11]. When setting up the combined suppression, the patient's comorbidities are very important. Most patients with underlying rheumatologic disease were treated with methotrexate in the past. For IBD patients, it is important to use the injection form of methotrexate, otherwise the drug may not be resorbed. In case of refractory manifestations and contraindications of combined systemic therapy, we consider discontinuing the anti-TNF-alpha agent. Interdisciplinary cooperation, consideration of the underlying disease and reassessment of further therapeutic procedure are all very important.

### 3. Sarcoidosis

One of the so-called paradoxical reactions is also newly developed sarcoidosis during the anti-TNF-alpha therapy. The anti-TNF-alpha therapy was described as a possible successful therapeutic modality in severe sarcoidosis manifestations. On the other hand, there is a growing number of cases that are caused by the treatment. More than 50 cases of TNF-alpha-induced sarcoidosis have been reported in the literature. Treatment with etanercept induced nearly 2/3 of the cases, and others were caused equally by infliximab and adalimumab. In most patients, the symptoms appeared after several months (1–69). Concomitant diseases include rheumatoid arthritis (in 60%), ankylosing spondylitis (in 20%), as well as psoriasis, Juvenile idiopathic arthritis (JIA) and IBD. In the clinical picture of anti-TNF-alpha-induced sarcoidosis, the pulmonary and cutaneous forms of the disease were dominant. In an aggregate paper including 38 patients, 74% of the patients suffered from the pulmonary form and 29% from the skin manifestations. The skin symptoms were manifested as erythema nodosum, pigmented scars and nodular lesions [19]. Literature data indicate a possible occurrence of sarcoidosis in 0.04% of the patients treated with TNF-alpha inhibitors [20]. Differential diagnosis of symptoms along with histological examination is important.

The role of anti-TNF on granuloma [21] and the different behaviour of antibodies and soluble anti-TNF alpha receptor in granulomatous diseases, with a greater tendency of etanercept to induce granulomatous reactions, may account for the occurrence of lesions. Monoclonal antibodies may induce apoptosis in activated monocytes and T cells. Sarcoidosis-like lesions

may develop during the anti-TNF- $\alpha$  treatment. The anti-TNF- $\alpha$  treatment increases the IL-17 and IFN- $\gamma$  expression and disturbs the balance between Th17 and Treg in favour of Th17. These two factors may result in the development of sarcoidosis [22].

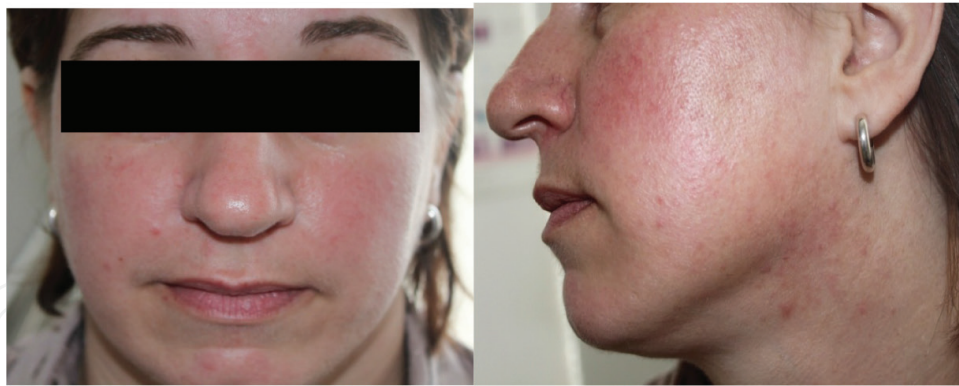#### 4. Lupus-like syndrome

Systemic lupus erythematosus (SLE) is a common autoimmune disease, with 10% of SLE cases being drug-induced. The autoimmune drug-induced response is idiosyncratic, influenced by multiple factors, such as genetics, comorbidities, interactions with other medicinal products and external environmental factors [23]. Drug-induced lupus erythematosus (DILE) is defined as a lupus-like disease that is temporally related to drug exposure (from 1 month after the commencement of drug application but sometimes even more than 10 years) [24].

DILE may not meet all the SLE criteria. The most common manifestations are arthritis, serositis, the presence of ANA antibodies and anti-histone antibodies. The most important criterion is that the symptoms cease after discontinuing application of the suspected drug [25].

DILE induced by TNF- $\alpha$  inhibitors appears to be a separate DILE group with different signs compared to classical DILE. Women are more often affected than men, with an average age between 46.2 and 50.9 years. The average time to the manifestation of symptoms is 40.6 weeks from the commencement of drug treatment. Skin manifestations occur more frequently than in classical DILE and include butterfly erythema, photosensitivity and other skin manifestations of systemic and sub-acute lupus. The exact mechanism of DILE formation during anti-TNF- $\alpha$  treatment is unknown. Post-marketing follow-ups have demonstrated that DILE induced by TNF- $\alpha$  inhibitors may occur across all anti-TNF- $\alpha$  inhibitors. However, it is more often reported with the use of infliximab (0.19–0.22%) and etanercept (0.18%) compared to adalimumab (0.10%). An increase in ANA or anti-DNA antibodies in patients treated with anti-TNF- $\alpha$  therapy is known and relatively common [26]. The frequency of elevated ANA antibodies was higher in a greater number of patients treated with infliximab compared to a group of patients treated with etanercept [27]. Anti-dsDNA antibodies as well as ENAs (extractable nuclear antibodies) and low complement levels have been described more often than in case of classical DILE. Particularly, anti-histone antibodies have been more common in DILE induced by anti-TNF- $\alpha$  treatment [28, 29] (**Figure 2**).

The basic therapeutic procedure is the discontinuation of the treatment with the drug that induced the symptoms. In more severe conditions, it is necessary to add suppressors—corticosteroids, azathioprine, cyclosporine and methotrexate. Treatment selection is also based on the status of the underlying disease and comorbidities of the patient. In psoriasis, it is recommended to avoid systemic corticosteroids for a possible rebound phenomenon after discontinuation. There is no need to discontinue the treatment of anti-TNF- $\alpha$  in the case of ANA positivity or in very mild DILE manifestations [26]. Only limited data are available in the literature describing a switch of the treatment to another anti-TNF- $\alpha$  agent. Some authors claim that a similar reaction can be caused by any of the agents from the group of anti-TNF- $\alpha$  inhibitors [30]. As stated by Lomicova et al., an alternative treatment for chronic



**Figure 2.** Significant facial erythema, total weakness and laboratory elevated ANA antibodies were observed. After discontinuation of the treatment, gradual regression of skin manifestations and neutralisation of ANA antibodies took place. Manifestations were assessed as DILE after infliximab.

plaque psoriasis is ustekinumab. Ustekinumab is also a good alternative in the treatment of inflammatory bowel disease and in the treatment of spondylarthritis or psoriatic arthritis [31]. However, the literature contains also cases of an ustekinumab-induced DILE. Biologics with a different mechanism of action are alternative treatments, but it cannot be said whether other mechanisms of action (anti-IL13/23, anti-IL-17, anti-IL 6) will be a potential threat to DILE induction in genetically predisposed individuals.

## 5. Vasculitis

The manifestations of vasculitis are another disease that is associated with the anti-TNF-alpha treatment. Several case reports and patient groups have been described in the literature. In almost half of the cases, leukocytoclastic vasculitis was histologically described, while the other patients included cases of necrotising vasculitis, lymphocytic vasculitis and urticarial vasculitis [32].

An aggregate paper of 118 cases of vasculitis newly formed during the anti-TNF-alpha treatment (99 cases of rheumatoid arthritis, 8 Crohn's disease, 5 juvenile rheumatoid arthritis, 3 ankylosing spondylitis, 3 psoriasis) presented skin manifestations in 86% of patients. The anti-TNF agent administered was etanercept in 60 (51%) cases, infliximab in 51 (43%), adalimumab in 5 (4%) and other agents in 2 (2%). Purpura was manifested in 63% of the patients, whereas others had other skin manifestations of vasculitis, such as ulcerations, nodosities, maculopapular manifestations, etc. Systemic involvement was observed in 24% of patients. Immunological examinations showed that the antinuclear antibodies (ANAs) were positive in 27 patients and antineutrophil cytoplasmic antibodies (ANCAs) in 11 patients (pANCA in 5 patients and cANCA in 1 patient). Treatment in the form of anti-TNF-alpha discontinuation was used in 11 patients, 71 of whom completely recovered (41% of them had additional immunosuppressive therapy) [33]. Mohan et al. describe in an aggregate paper including 50 patients that almost 63% of patients experienced a complete recovery of the manifestations after discontinuation of the anti-TNF-alpha treatment [34].



Vasculitis manifestations in patients with severe seropositive rheumatoid arthritis are debatable, because the manifestations may be evaluated as rheumatic vasculitis, which is an extra-articular manifestation of rheumatoid arthritis and not drug-induced vasculitis. In such cases, some authors recommend discontinuation of the anti-TNF- $\alpha$  treatment with possible re-exposure to the given treatment [32]. The same situation applies also to patients with IBD, where leukocytoclastic vasculitis can be associated with the disease itself [35].

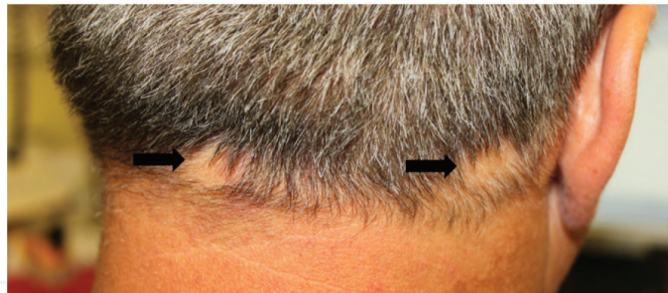
The pathogenesis of vasculitis associated with anti-TNF treatment is not completely explained. An immune complex-mediated hypersensitivity vasculitis may be related to the development of antibodies against anti-TNF agents, but in this hypothesis, the cases with etanercept should be less frequent since the treatment with the soluble receptor induces less antibody formation than monoclonal antibodies. Overexpression of type I interferon secondary to imbalance between Th1 and Th2 cytokine production under TNF inhibition may favour induction of autoimmune disorders such as vasculitis [15].

## 6. Pyoderma gangrenosum

Pyoderma gangrenosum (PG) is a rare neutrophilic dermatosis. PG is manifested by severe painful non-infectious pustules, nodules and necrotising ulcerations. The defects are sharply demarcated, round, with distinctly dark red undermined edges. The manifestations occur mostly on the shins, but they can also be found on the torso and other body parts. The manifestations of PG can be divided into several clinical forms, namely pustulous, bullous, a vegetative form of the disease and a separate peristomic form [36]. The peristomic form is a sign of pyoderma gangrenosum with pathergy; any trauma and injury of skin cover can cause new manifestations of the disease. The peristomic form may develop from 2 weeks to 3 years after the initial creation of the stoma [37]. Key factors in the etiopathogenesis of the disease are IL1B, IL-17, TNF- $\alpha$  and other chemokines that activate neutrophils for their activity. Genetic examinations point to several autoinflammatory genes, including pyrin innate immunity regulator (MEFV) and proline-serine-threonine phosphatase interacting protein-1 (PSTPIP1) [38]. About 50% of PG cases are associated with underlying diseases, such as inflammatory bowel disease, rheumatoid arthritis, myelodysplastic syndrome and haematological malignancies [39, 40]. Several papers indicate that refractory forms of PG are well responsive to the treatment with TNF- $\alpha$  inhibitors. One of the latest summary papers on drug-induced manifestations of pyoderma gangrenosum describes five case reports of pyoderma gangrenosum induced by an anti-TNF- $\alpha$  therapy. Three patients had manifestations induced by infliximab, one case of PG was induced by etanercept and one by adalimumab. Etiopathogenesis of PG induced by TNF- $\alpha$  inhibitors may represent paradoxical reaction due to a shift towards Th-17 polarisation [41].

## 7. Alopecia areata

Pathogenesis of alopecia areata is associated with TNF- $\alpha$ , which, as demonstrated in *in vitro* studies, inhibits hair follicle growth. However, in clinical trials with etanercept, the efficacy of



**Figure 3.** Adalimumab induced alopecia areata, spontaneous complete disappearance of the symptoms after 10 months without the drug discontinuation.

anti-TNF-alpha therapy for the alopecia areata was not confirmed. In the literature, however, there are cases of newly developed manifestations of alopecia areata, total and universal alopecia during anti-TNF-alpha treatment [42, 43].

French authors present data from a multicentre prospective study of patients who received anti-TNF-alpha treatment due to dermatological (11 patients), rheumatological (11 patients) and gastroenterological indications (7 patients). From these patients, 10 were treated with infliximab, 11 with adalimumab and the following 8 with etanercept. In the population, a total of 29 patients were diagnosed with alopecia areata, which was confirmed by a dermatologist. The manifestations of alopecia areata were in the area of scalp and chin in 79% of the patients. There were interesting findings related to concomitantly associated immune-mediated diseases, namely the occurrence of vitiligo, psoriasis or psoriasis-like manifestations and autoimmune thyroiditis. In the study group, nine patients had a positive family history of alopecia areata or vitiligo. A total of 14 patients discontinued the anti-TNF-alpha treatment and 15 patients continued the treatment. From patients who discontinued treatment, four were treated with infliximab, six with adalimumab and four with etanercept. Improvement up to complete disappearance of the symptoms was observed in 76% of the patients, while there was no difference between the groups in which the treatment discontinued or continued [44] (**Figure 3**).

Etiopathogenesis of alopecia areata is not clear. Some authors explain the occurrence of alopecia areata similar to TNF-alpha-induced psoriasis. Inhibition of TNF-alpha results in dysregulation of cytokines and subsequent production of IFN-alpha, which results in a pathological process [43]. However, further research is needed to better understand the occurrence of alopecia areata during anti-TNF-alpha therapy.

## 8. Lichen ruber planus and lichen planus-like reaction

Several cases of lichen planus and lichen planus-like paradoxically incurred lesions induced by anti-TNF-alpha therapy were reported in the literature. The manifestations have different clinical variability, including mucosal signs, but histologically they have signs of lichen planus.

The clear cause of lichenoid reactions in the treatment of anti-TNF-alpha is not known. Lichen is T-cells and dendritic cells mediated dermatosis. As with other immune-mediated diseases,

pro-inflammatory cytokines and TNF-alpha play a key role [45]. Studies point to increased TNF-alpha levels in saliva and plasma in the patients with lichen planus [46, 47]. Papers indicating good therapeutic effect of TNF-alpha inhibitors on lichenoid lesions were also published. Some authors describe a similar theory of etiopathogenesis of lichen planus as in paradoxical psoriasis. As we have already mentioned in case of other immune-mediated reactions, the model in which anti-TNF-alpha induces IFN-alpha may also be valid for lichen and lichenoid reactions. Other studies indicate that type 1 IFN including IFN-alpha can induce lichen planus through the activation of cytotoxic CD8 + T cells [45].

## 9. Morphea-like reactions

Morphea, also called localised scleroderma, is manifested by thickening of the skin and subcutaneous tissue due to the deposition of excessive amounts of collagen. There are only a few cases of morphea induced by TNF-alpha reported in the literature. Morphea may be induced by mechanical effects or by medications. The exact etiopathogenesis of TNF-alpha-induced morphea is not known, although there are several theories of possible etiopathogenesis. TNF inhibitors can act on tumour growth factor beta (TGF beta 1), a profibrotic cytokine that effects the growth and accumulation of extracellular matrix by the action of fibroblasts and endothelial cells. An increase in Th1 and Th17 proinflammatory cytokines has been demonstrated in the early stage of localised scleroderma. Th2 lymphocytes correlate with the severity of the disease and the extent of fibrosis. Inhibition of Th1 response induced by TNF-alpha inhibitors may lead to the prevalence of Th2 lymphocytes, which may be the cause of morphea [48].

## 10. Vitiligo

Vitiligo is one of the other rare skin disorders that can occur with anti-TNF-alpha treatment. The role of anti-TNF-alpha inhibition in the development of vitiligo is complex and controversial. As with other paradoxical immune-mediated reactions, there are case studies where vitiligo has been significantly improved in anti-TNF-alpha therapy in vitiligo patients. The therapeutic effect of anti-TNF-alpha treatment on vitiligo is believed to be blocking the physiological effect of TNF-alpha on melanogenesis. According to the literature, TNF-alpha reduces tyrosinase levels. The melanocytic effect of TNF-alpha on vitiligo has also been demonstrated [49].

## 11. Other skin manifestations

Cases of newly developed dermatomyositis and polymyositis have been described in a number of papers. Most of the patients belonged to the group of patients treated for rheumatic disease. The authors predict a possible association between the presence of myositis-specific anti-Jo-1 autoantibodies and anti-TNF-alpha treatment in relation to newly developed dermatomyositis and polymyositis in patients with rheumatoid arthritis [50].

## 12. Discussion

TNF-alpha inhibitors are biotechnologically produced medicinal products that differ from conventional drugs in their properties, size and structure. These large molecules, even with the same mechanism of action in the form of inhibiting TNF-alpha, may act differently and they may have other adverse effects. Therefore, each biological agent is unique. Pre-clinical studies did not foresee that TNF-alpha inhibitors will disrupt and change immunological pathways. In 2004, the first case of TNF-alpha-induced psoriasis [51] was described, and since then a number of papers have been published with immune-mediated skin reactions induced by TNF-alpha inhibitors. Their clinical spectrum is still widening; although in some cases, there are just a few case reports worldwide. Paradoxical psoriasis is the most researched and most common skin immune-mediated adverse effect. Its exact etiopathogenesis is still unclear. Development in the area of psoriasis etiopathogenesis is significantly moving forward; the Th17 pathway, which is now considered to be crucial, was discovered only a few years ago, and now we are using anti-IL17 inhibitors in clinical practice.

In conventional systemic therapy, the emergence of immune-mediated reactions is considered a comorbidity of the disease. Comorbidities are diseases that occur more frequently with the primary disease than in the general population [52]. It is assumed that the diseases have a common genetic predisposition that encodes certain inflammatory pathways. A very good example is the IL23 receptor gene, which explains the increased incidence of psoriasis in patients with ankylosing spondylitis, Crohn's disease and ulcerative colitis [52]. The literature contains only very little data about gene polymorphisms in paradoxical psoriasis. One study of gene polymorphisms that might be responsible for the above-mentioned reactions was published in 2015 by Cabaleiro et al., who observed in a group of 161 patients with psoriasis that 25 patients experienced a change in the morphology of psoriasis and 88% of the patients in the group had guttate psoriasis [16]. From a clinical point of view, it is debatable whether the monitored group had a real paradoxical psoriasis or whether it was just a worsening of the clinical condition, which is manifested in guttate form. The definition of a paradoxical psoriasiform reaction is newly induced or markedly clinically worsened psoriasis. As mentioned earlier, Collmar et al. reported that the most common clinical manifestations were palmo-plantar pustulosis and chronic plaque psoriasis. Guttate forms are found in only 12% of the patients [11]. The problem of determining whether it is an adverse effect or not is encountered also with other immune-mediated reactions.

Wang et al. highlight in their paper the importance of properly diagnosing the adverse effect. The Naranjo Adverse Drug Reaction Probability Scale is used for determining the adverse effects. Based on this scoring system, it is possible to calculate the likelihood if it is an adverse drug reaction or not [41]. A very difficult situation is when determining the adverse effects in patients with IBD. More than 40% of the patients with chronic inflammatory bowel disease have extraintestinal manifestations. They are more common in the case of Crohn's disease (CD) than in patients with ulcerative colitis (UC). The most common manifestations are peripheral arthritis, aphthous stomatitis, uveitis and erythema nodosum and pyoderma gangrenosum. Skin is the most frequently affected organ in extraintestinal manifestations [53]. Therefore, if



the above-mentioned manifestations of anti-TNF-alpha treatment occur, we first need to think of possible extraintestinal manifestations. Erythema nodosum (EN) is the most common skin manifestation of IBD, affecting 4–15% of the patients with CD and 3–10% of the patients with UC. EN is a reactive manifestation and correlates with the severity of the intestinal disease; it is aggravated in the case of colitis attacks [54].

Conversely, erythema nodosum may also be the first manifestation of paradoxically induced sarcoidosis. Pyoderma gangrenosum is also problematic. Pyoderma gangrenosum (PG) is the second most common, most serious and most debilitating skin manifestation in IBD. Unlike EN, the manifestations are more frequent in UC (5–12%) than in CD (1–2%) [55]. As we have already stated, pyoderma gangrenosum may also be a paradoxical response to anti-TNF-alpha treatment. The issue of comorbidity or paradoxical reaction is also in the case of vasculitis present in IBD, as well as with inflammatory rheumatic diseases. As we have stated in the previous section, only discontinuation of the biologically medicinal product and spontaneous disappearance of skin manifestations is evidence of the adverse drug reaction. Acquiring a unified view of immune-mediated adverse effects requires thorough pharmacovigilance, reporting of adverse effects, long-term monitoring of safety registry data and complementing the polymorphism research. Each biological agent is original, and even the batches do not have to be absolutely identical. By introducing biological similar molecules (biosimilars), the situation can get even more complicated. The biosimilar does not need to have the same immunogenicity as the original molecule.

Today, we know that antibodies against biologic agents are more likely to play a role in drug efficacy and hypersensitivity reactions, but some of the theories of pathogenesis of immune-mediated reactions are also associated with their production. An important fact is that there are cases where a number of immune-mediated reactions have occurred in one patient [44]. We assume that in susceptible individuals, each new biological agent may interfere with a new mechanism of action with natural physiological processes and induce still new immune-mediated adverse effects. Therefore, there is a tendency to apply one biological agent as long as possible to prevent further intervention in the cytokine cascade. We also know that the clinical response to the second and other biological agent is weaker than in treatment-naïve patients, and the production of antibodies against biological medicinal products is more pronounced. The question of whether immune-mediated reactions are associated with the formation of antinuclear antibodies is also unclear. The literature describes cases of monitoring the efficacy of a biological medicinal product and the formation of antinuclear antibodies [17]. However, firm data have not yet been established; similarly, we only assume that some type of immune-mediated reactions may be associated with anti-dsDNA formation and lupus-like reactions may be induced by TNF-alpha treatment with the formation of ANA.

Our work draws attention to the issue of adverse effects that occur due to the disruption of natural mechanisms—by dysregulation of the immune system and by starting various inflammatory pathways in genetically susceptible individuals. Some of the above-mentioned reactions have a common hypothesis of formation, such as the theory of interferon induction. This knowledge may lead to the assumption that one biological agent can cause two reactions simultaneously in one patient, e.g. alopecia areata and psoriasis.



## Author details

Karolína Vorčáková<sup>1\*</sup>, Péč Juraj<sup>1</sup>, Péčová Tatiana<sup>1</sup> and Martinásková Klára<sup>2</sup>

\*Address all correspondence to: [karolina.vorcakova@gmail.com](mailto:karolina.vorcakova@gmail.com)

1 Department of Dermatology, Comenius University in Bratislava, Jessenius Faculty of Medicine in Martin, Slovakia

2 Department of Dermatovenereology, University Hospital JA Reiman Prešov, Slovakia

## References

- [1] Rauch CT, Kozlosky CJ, Peschon JJ, Slack JL, Wolfson MF, Castner BJ, Stocking KL, Reddy P, Srinivasan S, Nelson N, Boiani N, Schooley KA, Gerhart M, Davis R, Fitzner JN, Johnson RS, Paxton RJ, March CJ, Cerretti DP. A metalloproteinase disintegrin that releases tumour-necrosis factor-alpha from cells. *Nature*. 1997;**385**:729-733
- [2] Baud D, Karin M. Signal transduction by tumor necrosis factor and its relatives. *Trends in Cell Biology*. 2001;**11**:372-377
- [3] Pfeffer K, Matsuyama T, Kündig TM, Wakeham A, Kishihara K, Shahinian A, Wiegmann K, Ohashi PS, Krönke M, Mak TW. Mice deficient for the 55 kD tumor necrosis factor receptor are resistant to endotoxic shock, yet succumb to *L monocytogenes* infection. *Cell*. 1993;**73**:45-67
- [4] Peschon JJ, Torrance DS, Stocking KL, Glaccum MB, Otten C, Willis CR, Charrier K, Morrissey PJ, Ware CB, Mohler KM. TNF receptor-deficient mice reveal divergent roles for p55 and p75 in several models of inflammation. *Journal of Immunology*. 1998;**160**:943-952
- [5] Wallis RS. Tumour necrosis factor antagonists: Structure, function, and tuberculosis risks. *The Lancet Infectious Diseases*. 2008;**8**:601-611
- [6] Scallon BJ, Moore MA, Trinh H, Knight DM, Ghrayeb J. Chimeric anti-TNF-alpha monoclonal antibody cA2 binds recombinant transmembrane TNF-alpha and activates immune effector functions. *Cytokine*. 1995;**7**:251-259
- [7] Gardam MA, Keystone EC, Menzies R, Manners S, Skamene E, Long R, Vinh DC. Anti-tumour necrosis factor agents and tuberculosis risk: Mechanisms of action and clinical management. *The Lancet Infectious Diseases* 2003;**3**:148-155
- [8] Ciccarelli F, De Martinis M, Sirufo MM, Ginaldi L. Psoriasis induced by anti-tumor necrosis factor alpha agents: A comprehensive review of the literature. *Acta Dermatovenereologica Croatica*. 2016;**24**(3):169-174
- [9] Wollina U, Hansel G, Koch A, Schonlebe J, Kostler E, Haroske G. Tumor necrosis factor-alpha inhibitor-induced psoriasis or psoriasiform exanthemata: First 120 cases from the

literature including a series of six new patients. *American Journal of Clinical Dermatology*. 2008;**9**:1-14

- [10] Ko JM, Gottlieb AB, Kerbleski JF. Induction and exacerbation of psoriasis with TNF-blockade therapy: A review and analysis of 127 cases. *The Journal of Dermatological Treatment*. 2009;**20**:100-108
- [11] Collamer AN, Battafarano DF. Psoriatic skin lesions induced by tumor necrosis factor antagonist therapy: Clinical features and possible immunopathogenesis. *Seminars in Arthritis and Rheumatism*. 2010;**40**:233-240
- [12] Fiorentino DF. The yin and Yang of TNF- $\alpha$  inhibition. *Archives of Dermatology*. 2007;**143**:233-236. DOI: 10.1001/archderm.143.2.233
- [13] Joyau C, Veyrac G, Dixneuf V, Jolliet P. Anti-tumour necrosis factor alpha therapy and increased risk of de novo psoriasis: Is it really a paradoxical side effect? *Clinical and Experimental Rheumatology*. 2012;**30**(5):700-706
- [14] de Gannes GC, Ghoreishi M, Pope J, Russell A, Bell D, Adams S, Shojania K, Martinka M, Dutz JP. Psoriasis and pustular dermatitis triggered by TNF- $\alpha$  inhibitors in patients with rheumatologic conditions. *Archives of Dermatology*. 2007;**143**:223-231
- [15] Wendling D, Prati C. Paradoxical effects of anti-TNF- $\alpha$  agents in inflammatory diseases. *Expert Review of Clinical Immunology*. 2014;**10**(1):159-169. DOI: 10.1586/1744666X.2014.866038
- [16] Cabaleiro T, Prieto-Pérez R, Navarro R, Solano G, Román M, Ochoa D, Abad-Santos F, Daudén E. Paradoxical psoriasiform reactions to anti-TNF $\alpha$  drugs are associated with genetic polymorphisms in patients with psoriasis. *The Pharmacogenomics Journal*. 2016;**16**(4):336-340. DOI: 10.1038/tpj.2015.53. Epub 2015 Jul 21
- [17] Pink AE, Fonia A, Allen MH, Smith CH, Barker JN. Antinuclear antibodies associate with loss of response to antitumour necrosis factor-alpha therapy in psoriasis: A retrospective, observational study. *The British Journal of Dermatology*. 2010;**162**(4):780-785
- [18] Dalle Vedove C, Simon JC, Girolimoni G. Drug-induced lupus erythematosus with emphasis on skin manifestations and the role of anti-TNF $\alpha$  agents. *Journal der Deutschen Dermatologischen Gesellschaft*. 2012;**10**(12):889-897
- [19] Javot L, Tala S, Scala-Bertola J, Massy N, Trenque T, Baldin B, Andréjak M, Gillet P, Petitpain N; le réseau français des Centres Régionaux de Pharmacovigilance. Sarcoidosis and anti-TNF: A paradoxical class effect? Analysis of the French pharmacovigilance system database and literature review. *Thérapie*. 2011;**66**(2):149-154
- [20] Daïen CI, Monnier A, Claudepierre P, Constantin A, Eschard JP, Houvenagel E, Samimi M, Pavy S, Pertuiset E, Toussirost E, Combe B, Morel J, Club Rhumatismes et Inflammation (CRI). Sarcoid-like granulomatosis in patients treated with tumor necrosis factor blockers: 10 cases. *Rheumatology*. 2009;**48**:883-886
- [21] Furst DE, Wallis R, Broder M, Beenhouwer DO. Tumor necrosis factor antagonists: Different kinetics and/or mechanisms of action may explain differences in the risk for developing granulomatous infection. *Seminars in Arthritis and Rheumatism*. 2006;**36**(3):159-167

- [22] Vigne C, Tebib JG, Pacheco Y, Coury F. Sarcoidosis: An underestimated and potentially severe side effect of anti-TNF-alpha therapy. *Joint, Bone, Spine*. 2013;**80**(1):104-107
- [23] Chang C, Gershwin ME. Drug-induced lupus erythematosus. Incidence, management and prevention. *Drug Safety*. 2011;**34**:357-374
- [24] Marzano AV, Vezzoli P, Crosti C. Drug induced lupus: An update on its dermatological aspects. *Lupus*. 2009;**18**:935-940
- [25] Antonov D, Kazandjieva J, Etugov D, Gospodinov D, Tsankov N. Drug-induced lupus erythematosus. *Clinics in Dermatology*. 2004;**22**:157-166
- [26] Vedove CD, Simon JC, Girolomoni G. Drug-induced lupus erythematosus with emphasis on skin manifestations and the role of anti-TNF $\alpha$  agents. *Journal der Deutschen Dermatologischen Gesellschaft*. 2012;**10**:889-897
- [27] Atzeni F, Turiel M, Capsoni F, Doria A, Meroni P, Sarzi-Puttini P. Autoimmunity and anti-TNF- $\alpha$  agents. *Annals of the New York Academy of Sciences*. 2005;**1051**:559-569
- [28] Costa MF, Said NR, Zimmermann B. Drug induced lupus due to anti-tumor necrosis factor alpha agents. *Seminars in Arthritis and Rheumatism*. 2008;**37**:381-387
- [29] Williams EL, Gadola S, Edwards CJ. Anti-TNF-induced lupus. *Rheumatology*. 2009;**48**:716-720
- [30] Williams VL, Cohen PR. TNF alpha antagonist-induced lupus-like syndrome: Report and review of the literature with implications for treatment with alternative TNF alpha antagonists. *International Journal of Dermatology*. 2011;**50**:619-625
- [31] Lomicová I, Suchý D, Pizinger K, Cetkovská P. A case of lupus-like syndrome in a patient receiving adalimumab and a brief review of the literature on drug-induced lupus erythematosus. *Journal of Clinical Pharmacy and Therapeutics*. 2017;**42**(3):363-366. DOI: 10.1111/jcpt.12506
- [32] Marcoux BS, De Bandt M. Vasculitides induced by TNF $\alpha$  antagonists: A study in 39 patients in France. *Joint, Bone, Spine*. 2006;**73**:710-713
- [33] Ramos-Casals M, Brito-Zerón P, Soto MJ, Cuadrado MJ, Khamashta MA. Autoimmune diseases induced by TNF-targeted therapies. *Autoimmunity reviews. Best Practice & Research. Clinical Rheumatology*. 2008;**22**(5):847-861. DOI: 10.1016/j.berh.2008.09.008
- [34] Mohan N, Edwards ET, Cupps TR, Slifman N, Lee JH, Siegel JN, Braun MM. Leukocytoclastic vasculitis associated with tumor necrosis factor-alpha blocking agents. *J Rheumatol*. 2004;**31**:1955-1958
- [35] Tsiamoulos Z, Karamanolis G, Polymeros D, Triantafyllou K, Oikonomopoulos T. Leukocytoclastic vasculitis as an onset symptom of Crohn's disease. *Case Reports in Gastroenterology*. 2008;**2**:410-414
- [36] Georgiou G, Pasmazi E, Monastirli A, Tsambaos D. Cutaneous manifestations of inflammatory bowel disease. *Hospital Chronicles*. 2006;**1**:158-168
- [37] Callen JP. Pyoderma gangrenosum. *Lancet*. 1998;**351**:581-585

- [38] Marzano AV, Damiani G, Ceccherini I, Berti E, Gattorno M, Cungo M. Autoinflammation in pyoderma gangrenosum and its syndromic form (pyoderma gangrenosum, acne and suppurative hidradenitis). *The British Journal of Dermatology* 2016;**176**(6):1588-1598. DOI: 10.1111/bjd.15226
- [39] Crowson AN, Mihm MC Jr, Magro C. Pyoderma gangrenosum: A review. *Journal of Cutaneous Pathology*. 2003;**30**(2):97-107
- [40] Wollina U. Pyoderma gangrenosum—A review. *Orphanet Journal of Rare Diseases*. 2007; **15**(2):19
- [41] Wang JY, French LE, Shear NH, Amiri A, Alavi A. Drug-induced Pyoderma gangrenosum: A review. *American Journal of Clinical Dermatology*. 2017 Jun 17. DOI: 10.1007/s40257-017-0308-7. [Epub ahead of print]
- [42] Beccastrini E, Squatrito D, Emmi G, Fabbri P, Emmi L. Alopecia areata universalis during off-label treatment with infliximab in a patient with Behçet disease. *Dermatology Online Journal*. 2010;**16**(9):15
- [43] Hernández MV, Meineri M, Sanmartí R. Skin lesions and treatment with tumor necrosis factor alpha antagonists. *Reumatología Clínica*. 2013;**9**(1):53-61
- [44] Schmutz JL. Alopecia areata occurring during anti-TNF- $\alpha$  therapy: A French prospective multicentre study. *Annales de Dermatologie et de Vénéréologie*. 2015;**142**(5):386-387. DOI: 10.1016/j.annder.2015.02.003
- [45] Asarch A, Gottlieb AB, Lee J, Masterpol KS, Scheinman PL, Stadecker MJ, Massarotti EM, Bush ML. Lichen planus-like eruptions: An emerging side effect of tumor necrosis factor-alpha antagonists. *Journal of the American Academy of Dermatology*. 2009;**61**(1):104-111. DOI: 10.1016/j.jaad.2008.09.032
- [46] Erdem MT, Gulec AI, Kiziltunc A, Yildirim A, Atasoy M. Increased serum levels of tumor necrosis factor alpha in lichen planus. *Dermatology*. 2003;**207**:367-370
- [47] Pezelj-Ribaric S, Prso IB, Abram M, Glazar I, Brumini G, Simunovic-Soskic M. Salivary levels of tumor necrosis factor-alpha in oral lichen planus. *Mediators of Inflammation*. 2004;**13**:131-133
- [48] Ramírez J, Hernández MV, Galve J, Cañete JD, Sanmartí R. Morphea associated with the use of adalimumab: A case report and review of the literature. *Modern Rheumatology*. 2012;**22**(4):602-604. DOI: 10.1007/s10165-011-0550-4
- [49] Jung JM, Lee YJ, Won CH, Chang SE, Lee MW, Choi JH, Moon KC. Development of vitiligo during treatment with adalimumab: A plausible or paradoxical response? *Annals of Dermatology*. 2015;**27**(5):620-621. DOI: 10.5021/ad.2015.27.5.620. Epub 2015 Oct 2
- [50] Ishikawa Y, Yukawa N, Ohmura K, Hosono Y, Imura Y, Kawabata D, Nojima T, Fujii T, Usui T, Mimori T. Etanercept-induced anti-Jo-1-antibody-positive polymyositis in a patient with rheumatoid arthritis: A case report and review of the literature. *Clinical Rheumatology*. 2010;**29**:563-566
- [51] Vereza MM, Del Pozo J, Yebra-Pimentel MT, Porta A, Fonseca E. Psoriasiform eruption induced by infliximab. *The Annals of Pharmacotherapy*. 2004;**38**:54-57

- [52] Duffin KC, Woodcock J, Krueger GG. Genetic variations associated with psoriasis and arthritis found by genome-wide association. *Dermatologic Therapy*. 2010;**23**(2):101-113
- [53] VavrickaSR, BrunL, BallabeniP, PittetV, PrinzVavrickaBM, ZeitzJ, RoglerG, SchoepferAM. Frequency and risk factors for extraintestinal manifestations in the Swiss inflammatory bowel disease cohort. *The American Journal of Gastroenterology*. 2011;**106**:110-119. DOI: 10.1111/j.1529-8019.2010.01303.x
- [54] Timani S, Mutasim DF. Skin manifestations of inflammatory bowel disease. *Clinics in Dermatology*. 2008;**26**:265-273
- [55] DaneseS, SemeraroS, PapaA, RobertoI, ScaldaferriF, FedeliG, GasbarriniG, GasbarriniA. Extraintestinal manifestations in inflammatory bowel disease. *World Journal of Gastroenterology*. 2005;**11**:7227-7236



