

We are IntechOpen, the world's leading publisher of Open Access books Built by scientists, for scientists

6,900

Open access books available

185,000

International authors and editors

200M

Downloads

Our authors are among the

154

Countries delivered to

TOP 1%

most cited scientists

12.2%

Contributors from top 500 universities



WEB OF SCIENCE™

Selection of our books indexed in the Book Citation Index
in Web of Science™ Core Collection (BKCI)

Interested in publishing with us?
Contact book.department@intechopen.com

Numbers displayed above are based on latest data collected.
For more information visit www.intechopen.com



Simultaneous Excisions and Extemporaneous Skin Plastics: New Reconstructive Techniques after Tumor Surgery

Paolo Boggio, Benedetta Miglino,
Federica Veronese, Rossana Tiberio and
Paola Savoia

Additional information is available at the end of the chapter

<http://dx.doi.org/10.5772/intechopen.71691>

Abstract

Occurrence of two or more skin tumors closely situated to each other is not so rare in clinical dermasurgical practice. Excision of multiple contiguous skin lesions can represent a major dermasurgical problem that can be solved in different surgical times. However, in our opinion, the best therapeutic solution is to carry out the removal in a single surgical session; this choice allows saving time, an easier plastic reconstruction, and better esthetic results. Many different reconstructive procedures can be designed and applied, to achieve the best result. The simplest Burow's triangle flap permits excision of two contiguous lesions with less tension compared to two fusiform cuts, but many other plastic solutions can be chosen to satisfy the needs of different anatomical sites and according to skin features. In the author's personal experience, of about 8000 patients who have undergone dermatologic surgery over the past 20 years, the presence of multiple contiguous lesions occurred in about 200 cases. In all of these, triangle, rotation, advancement, or transposition flaps allowed simultaneous removals, saving time and money and giving better esthetic results compared to multiple direct excision carried out at successive times. In this chapter, the different techniques are described and illustrated in detail.

Keywords: dermatologic surgery, multiple skin tumors, plastic skin reconstruction techniques, simultaneous excisions, Burow's triangle

1. Introduction

The aim of this chapter is to focus on a new way to employ traditional techniques when skin tumors present themselves as multiple and contiguous. In fact, the occurrence of two or more skin lesions closely situated to one another is not so rare in dermatologic surgery daily practice [1]. The frequency of this condition can be greatly influenced by the grade of attention given

to the problem; in our personal experience over the last 20 years, this event was observed and treated in 3% of cases. This problem can be solved by multiple excisions in different surgical times after choosing, for the first ablation, the lesion most clinically malignant or localized in the more difficult anatomical site [1–3]. However, in our opinion the best choice is to find a solution allowing a unique surgical time, giving time-sparing, easier plastic reconstruction, and good esthetic results. This goal can be achieved with a twisted suture line and less skin traction. Many reconstructive possibilities can be found and applied for the best and easier result according to the anatomical disposition [5]. The theory of random pattern flaps can be applied to multiple simultaneous excisions, with all types of flaps.

In the following paragraphs, we present some theoretical considerations on the use of flaps for plastic reconstruction after multiple simultaneous excisions and numerous practical examples. In particular, we describe (i) advancement flaps, (ii) rotation flaps, and (iii) transposition flaps (**Figure 1**).

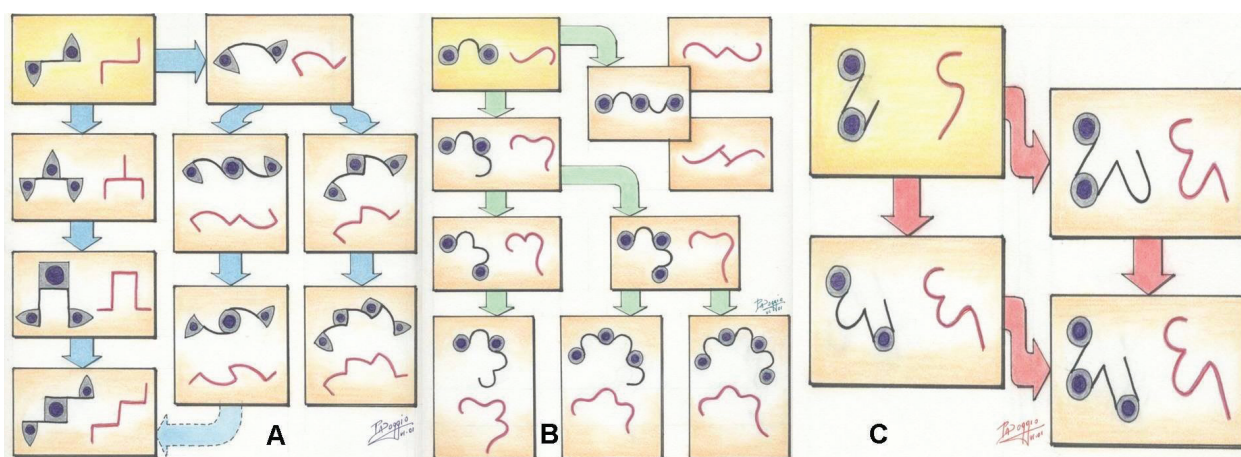


Figure 1. The different types of flaps (simple or elaborated) that can be used after simultaneous excision of multiple lesions. (A) Advancement and rotation flaps, (B) interposed transposition flaps, and (C) coaxial transposition flaps.

2. Advancement flaps

The advancement flap is one of the most basic and versatile flaps available for the dermatologic surgery. Despite its apparent straightforwardness, the advancement flap, which simply involves the linear advancement of the tissue in one direction, can be used to close a variety of defects, ranging from small defects on the scalp or extremities to large, complicated defects involving multiple cosmetic units on the face. A great deal has been written about advancement flaps, including new and innovative ways to use them [6].

Some of these ways are hereby described. All these flaps give the possibility to perform simultaneous and easier reconstructions with a single plastic, after the removal of multiple contiguous lesions of the skin. We discuss the fundamental principles underlying the advancement flap, as well as the potential uses, advantages, and disadvantages of the various types of advancement flaps in different situations of multiple lesions.

2.1. Burow's flap

The simplest way to remove cutaneous lesion is the elliptical excision, because it is simple and fast and it leaves a smaller wound than any other technique [5]. When two contiguous lesions cannot be removed with a single elliptical excision, due to the excessive tension that would result from direct suture, it is possible to use two Burow's triangle advancement flaps. This technique is a variant of the single Burow's triangle flap [1], in which the secondary triangle (the so-called Burow's wedge) contains one of the lesions.

In the case of two very close lesions, it is possible to draw two triangle flap variants, as two possible tangential incisions are available. The direction of the tangential incision should be chosen so that it fits well with the creases, folds, and skin tension lines (**Figure 2**).

The Burow's triangle advancement flap is functional only when the distance between the lesions does not exceed 2 "diameters" (width of the hypothetical elliptical excision needed to resect a lesion). The resulting suture line is in this case longer than the sum of the two potential elliptical incisions, but the more esthetic Z-shaped incision and the decreased tension are shown in **Figure 3**. In this case, the distance between the lesions is 1 "diameter," and the resulting suture line is as long as the sum of the two elliptical excisions; so, the absolute tension is the same as that obtained with a single elliptical excision. However, when the distance between the two skin lesions exceeds 2 diameters, the use of this technique is not recommended, because of the need for extensive undermining and the length of the final closure.

Overall, this technique is excellent for the simultaneous removal of two lesions that are closely approximated, as the resulting tension is comparable to that of two elliptical incisions, with acceptable esthetic results.

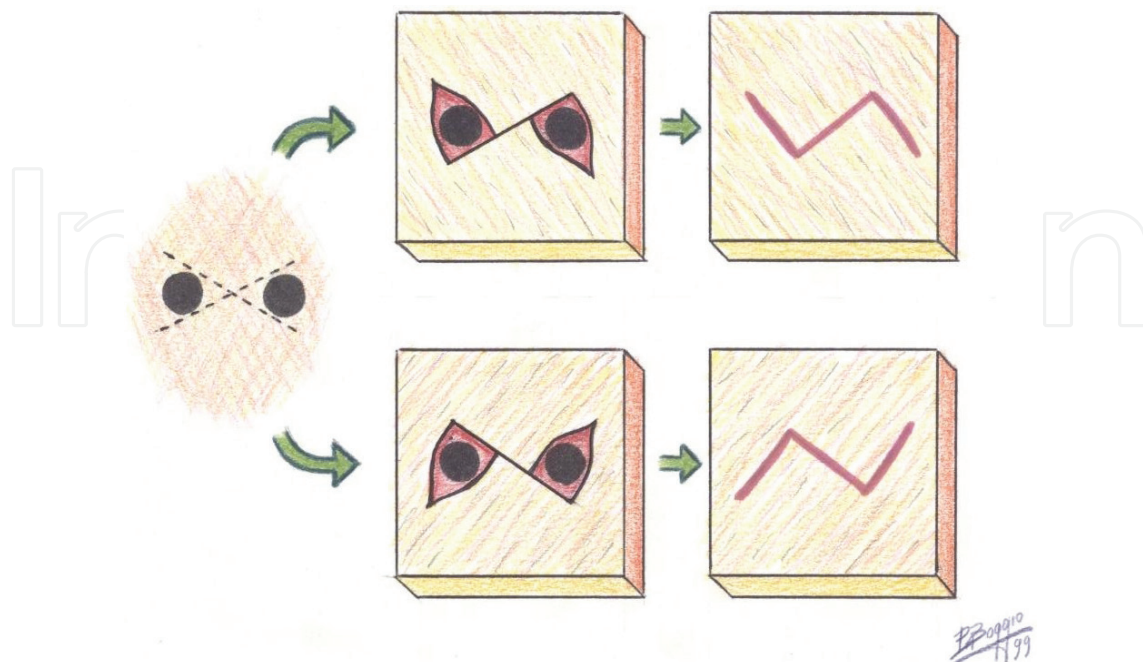


Figure 2. Burow's flap.

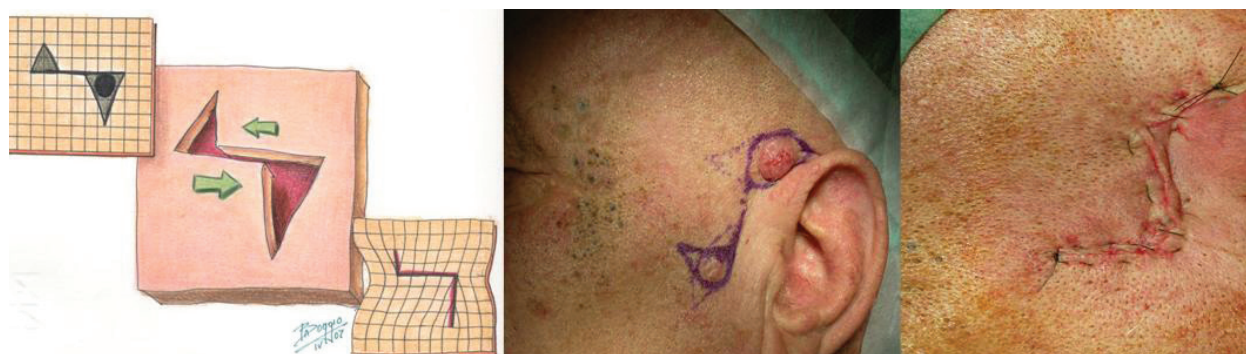

Figure 3. The graphic representation and a clinical example of a Z-shaped incision and the excision of two lesions, with a good esthetic result.

2.2. A-T flap

The A-T flap, also known as the O-T flap, can be thought as half of a double advancement flap. The basic technique for an A-T flap involves the construction of a triangular or A-shaped defect, superimposed over the primary circular or elliptical wound to be closed. The flap is constructed by making an incision along the base of an ideal triangular defect and then joining the two basal tips of the triangle with the midpoint of the base. This results in an inverted, T-shaped closure (i.e., the “T” is inverted with respect to the “A”) (**Figure 4**).

Obviously, dimensions of the imaginary triangle that guides the formation of this flap are variable, depending to the size of the wound and of the standing cutaneous cone that is formed and to the proximity of adjacent structures. However, in the absence of any such limitations, some authors [6, 7] determined that, in order to minimize the closure tension, the optimal design for an A-T flap includes a height that is twice the defect diameter, a base extension corresponding to one defect diameter on each side, and three defect diameters (measured from the center of the wound) of undermining. The A-T flap should be considered to avoid

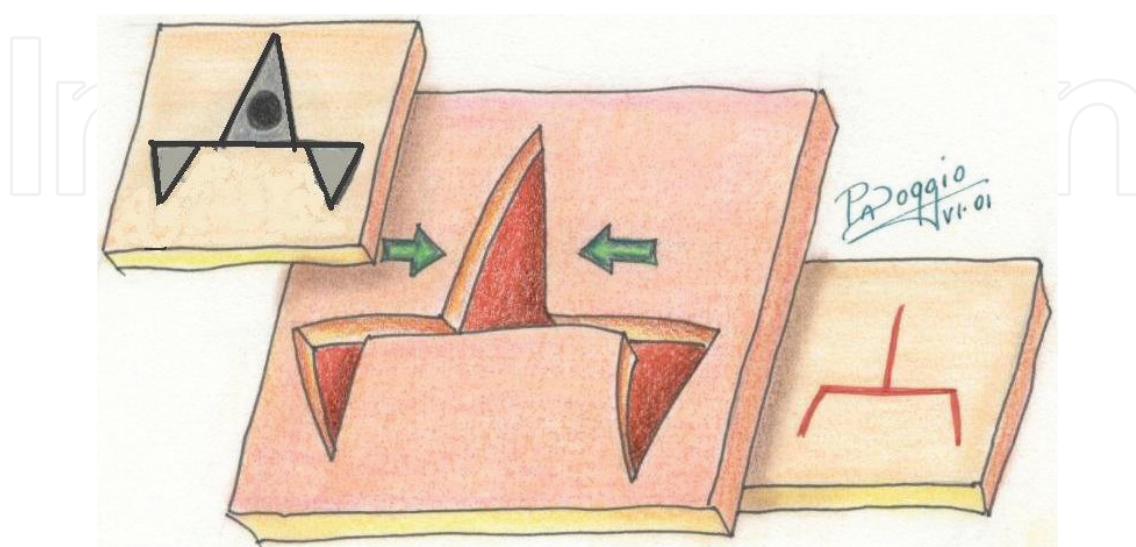


Figure 4. The A-T flap scheme.

distortion of anatomical structures near the wound edge. When this condition is needed, the base of the flap should be placed along the border of the structure to be preserved. The A-T flap prevents the damage of important anatomical structures and leads to the formation of esthetically acceptable scars. This flap is particularly useful: (i) on the forehead, where the base incision can be concealed along the eyebrow or hairline; (ii) on the chin, where the base incision can be concealed along the mental crease; (iii) on the lip, where the base incision can be concealed along the vermilion border.

The A-T flap also allows to use Burow's triangles (that are created at the base of the triangular flaps to facilitate sliding), inserting any contiguous lesions inside them. In this way it is possible to carry out a single reconstructive plastic. This technique is described in **Figure 4**.

2.3. Rectangular flap

The rectangular advancement flap is realized by tracing a rectangle contiguous to the breach to close. The direction of this triangle is chosen on the basis of the best possible esthetic results, along the lines of Langer or in the direction of greater skin distensibility. The ideal length ratio of the rectangular flap width is from 2:1 to 3:1.

Single advancement flaps are useful to repair defects on the forehead.

Single and double advancement flaps are also advantageous because the resulting scars can be camouflaged within normal anatomic boundary lines (e.g., forehead scalp junction or vermilion border).

One of the major drawbacks to constructing advancement flap is represented by the need to build two Burow's triangles to eliminate standing cones of redundant tissue. It should be remembered that the removal of each standing cone creates an extra scar. Standing cones can be sometimes eliminated or diminished simply by sewing them out using the "law of halves." However, this is not always possible. Some authors [4–7] described a fine modification of the basic advancement flap which prevents the formation of standing cones. A curvilinear incision can be performed along the limb of the flap, to redistribute the redundant tissue along the length of the incision. The result is an advancement without Burow's triangle. This modification results in a more desirable final scar; however, it has some minor limitations, including a slight narrowing of the flap pedicle and the relinquishment of the additional tissue movement gained by Burow's triangle excision. When constructing larger flaps, attempts to avoid the excision of Burow's triangles may lead to extensive stretching and subsequent thinning of the flap. It should be kept in mind that an excessively thinned flap has a poor cosmetic outcome and is more susceptible to necrosis. Hence, avoiding standing cone is not necessarily the best possible approach.

The choice to draw two Burow's triangles at the base of the rectangular flap to facilitate its advancement is often the best one. Also, this choice allows to remove three lesions with a single rectangular flap as shown in **Figure 5** (this figure shows the skin tension lines), when such triangles coincide with other skin lesions.

This theoretical principle can be adapted to the disposition of the contiguous lesions, giving rise to trapezoidal shapes other than rectangular (**Figure 6**).

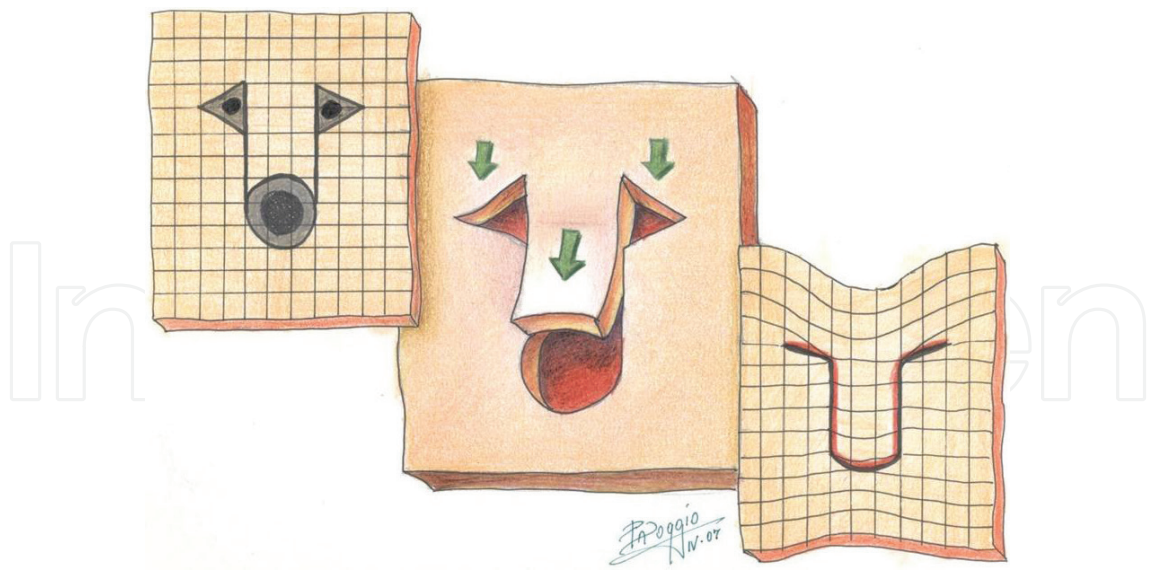


Figure 5. Rectangular flap scheme.

2.4. Opposite triangular flap

Triangular flap is a useful variant to close a surgical breach through advancing the two opposite sides, when one-on-one advancement is difficult. Sometimes, the two opposite advancements can be obtained with two rectangular flaps (**Figure 7**).

However, to reduce the number of surgical cuts, the two flaps can be transformed into two Burow’s opposite triangles, cutting one side and using Burow’s triangle on each arm. If the two

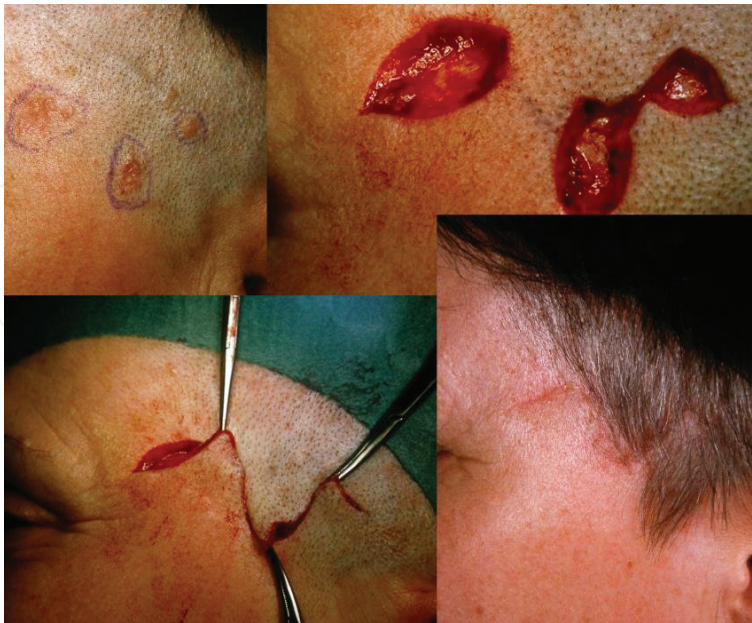

Figure 6. Clinical examples of contiguous lesions.

Burow's triangles can result in other two cutaneous lesions, we will obtain the excision and the simultaneous reconstruction of three injuries with a single broken suture line (**Figure 8**).

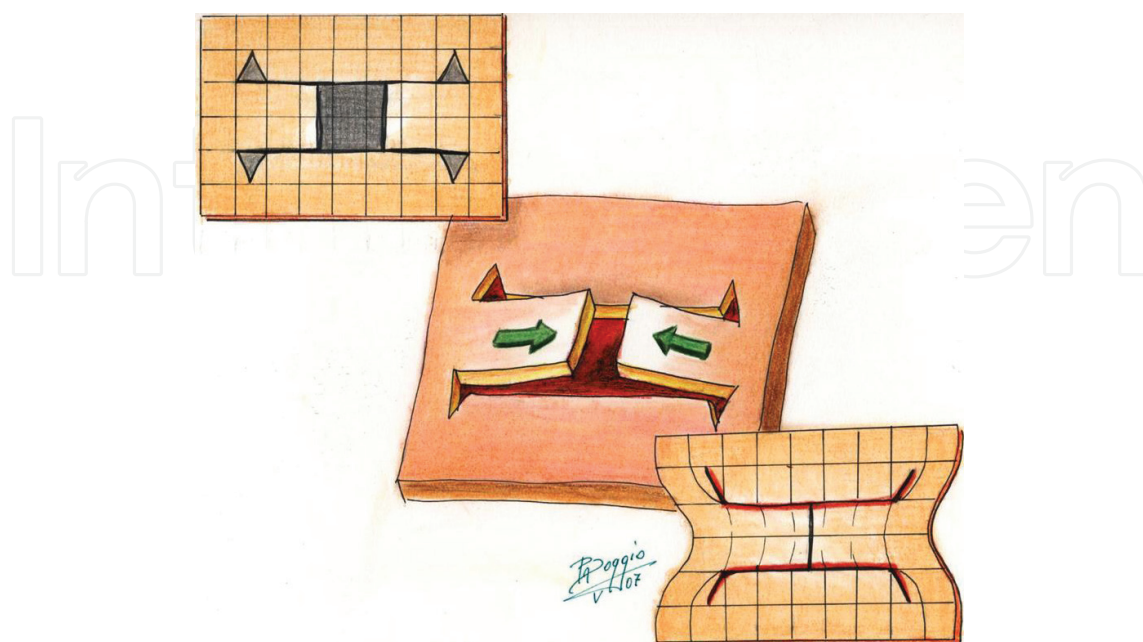


Figure 7. Opposite triangular flap graphic scheme.

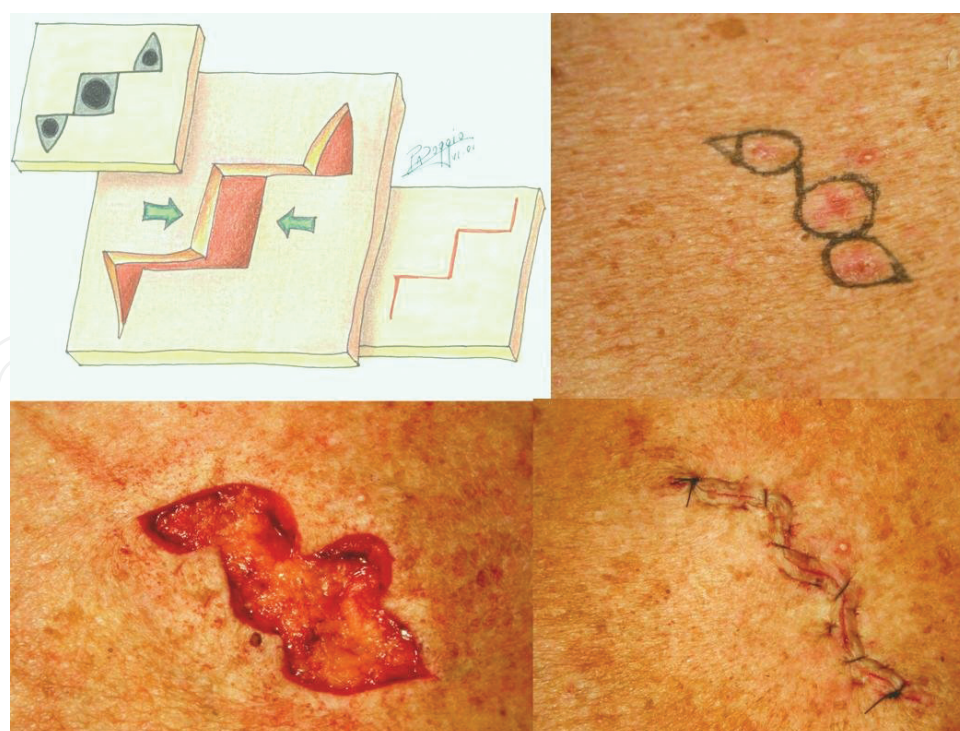

Figure 8. A clinical example for multiple lesions.

3. Rotation flaps

3.1. Fan flap

A rotation flap is usually taken from more resilient skin regions to fill losses of the tissue from adjacent less-resilient regions. It is usually fan-shaped up to two to four times wider than the excision area, and Burow's triangle is catted out at its base, to facilitate rotation. In the case of two close lesions, it is possible to obtain a simultaneous excision circumscribing one of them with Burow's triangle. This technique is similar to that adopted for Burow's triangle flap (**Figure 9**).

Four different variants are possible in this specific situation, allowing the choice of four corresponding types of the final suture based to cosmetic needs. The distance between the lesions can reach a width of 3–4 "diameters" (the width of the hypothetical rhomboid exercise needed to eradicate the lesion) (**Figure 10**).

A practical example of application of the rotation flap to removal two contiguous lesions from the eyebrow and temporal region is shown in **Figure 10**.

If the distance between the lesions is about 1 diameter, this rotation flap becomes a variant of the Dufourmentel transposition flap (a flap whose length is 1.5 times longer than the width of the lesion gap) [7]. It is possible, in fact, to cut out a flat between the lesions, whose length-width ratio is 1:1; the rotation of this flap and whose rotation is facilitated by the direct suture of one of the two gaps. In this case, all the four direction variants mentioned above are possible. The wide base makes the flap very vital, and, in contrast to the Dufourmentel flap, only a mild torsion of the peduncle occurs, with a better vascularization. It is noteworthy that this flap variant, although structurally and conceptually similar to the rotation flap, can be more appropriately considered to be a very simple type of transposition flap (**Figure 11**).

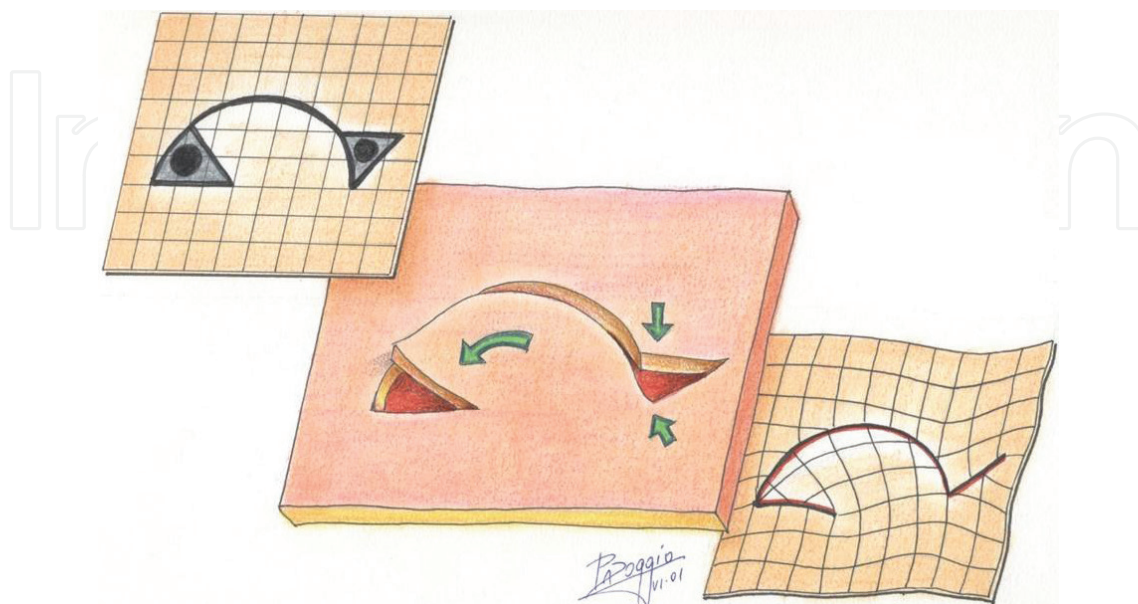


Figure 9. Fan flap scheme.

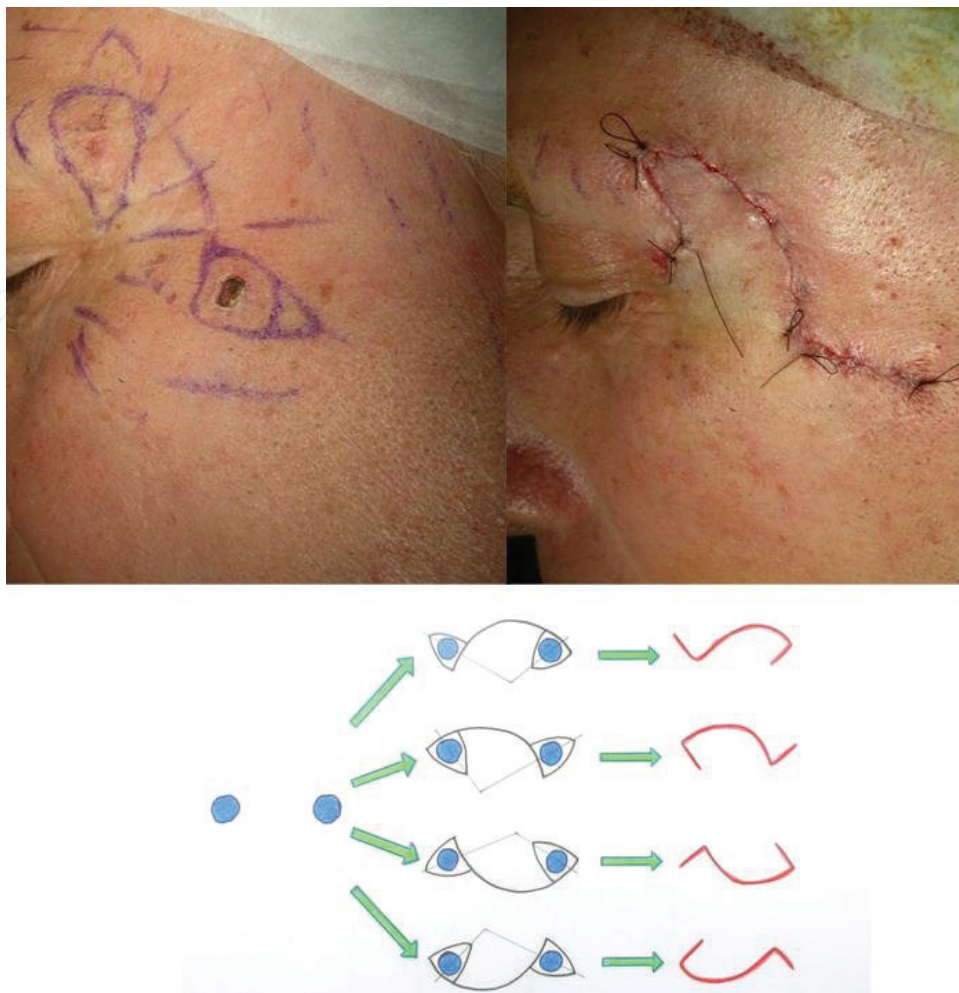


Figure 10. Clinical application of fan flap.

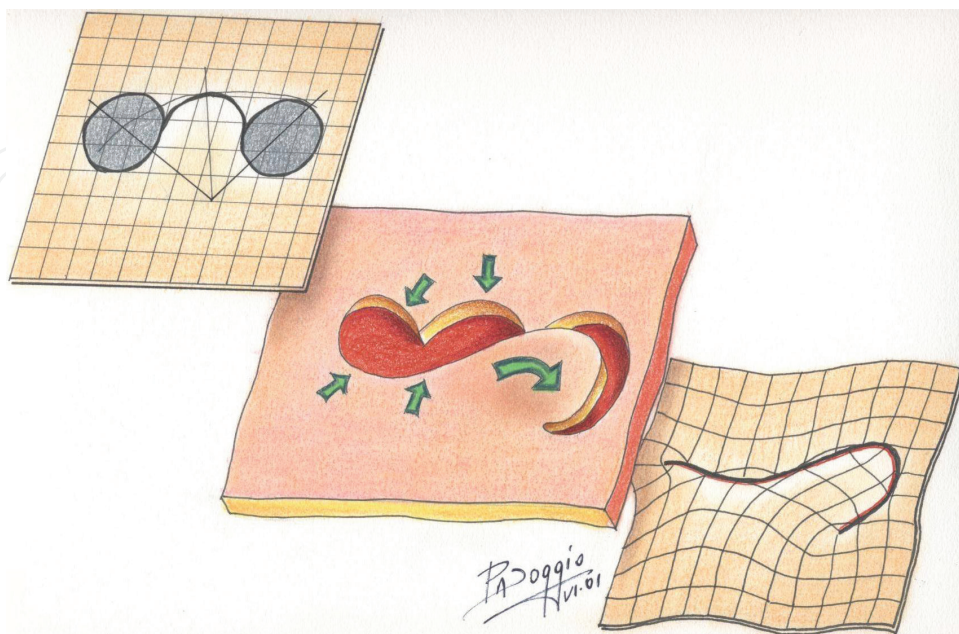


Figure 11. The scheme of the variant of fan flap.

3.2. Opposite rotation flap

Considerations similar to those reported in Section 2.1 for the double triangular advancement flap can be made for opposing rotational flaps. In this variant, the contour of the flap is curved, and the advancement movement becomes a rotation. At the base, two Burow's triangles are drawn to facilitate convergent movement. If in these triangles there are two other lesions, we can obtain the simultaneous excision of three lesions (**Figure 12**).

However, the rotation of the flaps may be divergent, taking advantage of the central break-away as facilitating the lateral movement of the flaps; in this way a final suture according to the anatomical areas can be easily obtained, with a good esthetic result (**Figure 12**).

3.3. Multidentate rotation flaps

A multidentate rotation flap can be easily modified to fit many defects, including multiple lesions localized along an ideal arcuate line.

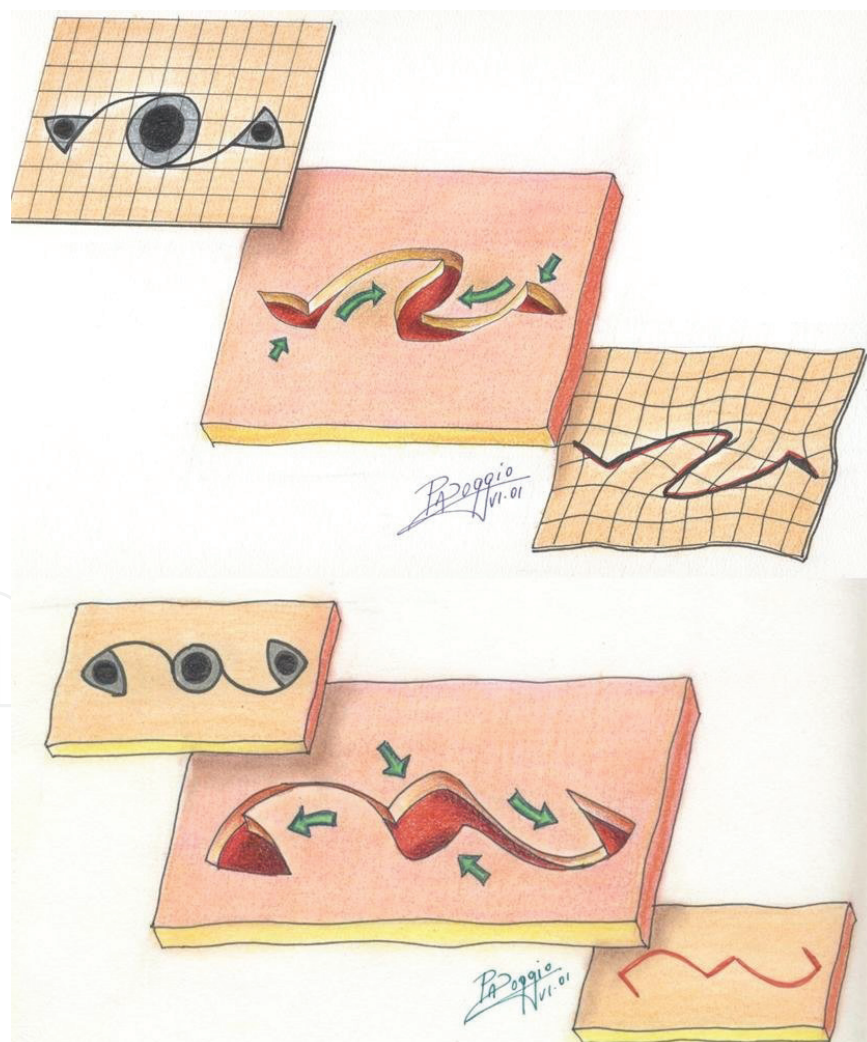


Figure 12. Opposite rotation flaps schemes.

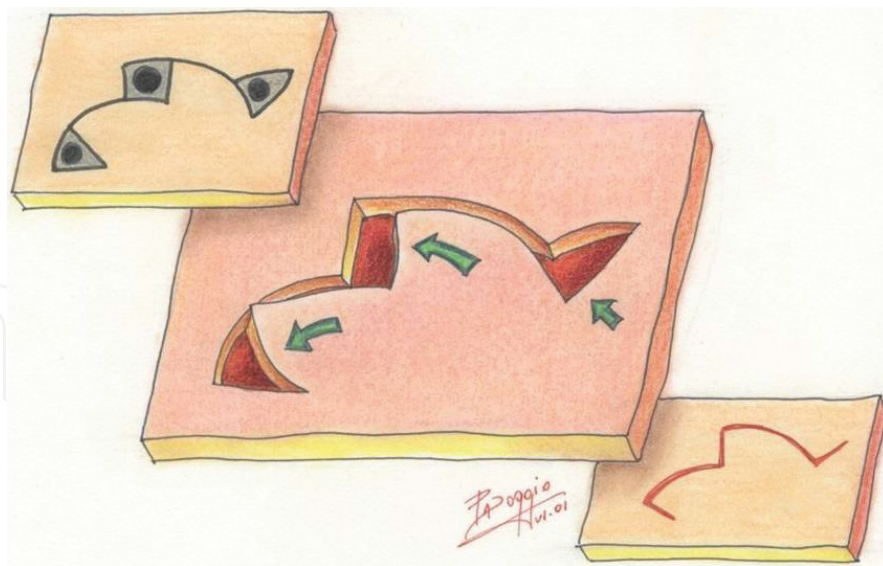


Figure 13. Multidentate rotation flap scheme.

It represents the mix of multiple fanlike rotation flaps, each of which facilitates the rotation of the previous: this is possible by using the last excision area as Burov's triangle and by closing the donor areas directly; the technique diagram is shown in **Figure 13** for the excision of three lesions and can also be applied to remove four lesions.

Obviously, the adoption of this flap should be evaluated in each individual case. When this technique is possible, it gives a very good outcome, due to the curved suture lines; a significant portion of the skin is saved, and there is a reduction of the overall surgical time.

The practical application of multidentate flap for four lesions excision is shown in **Figure 14**.

Also, in multidentate flaps, it is possible to choose between two different directions of rotation, depending on the skin distention and on the desired final esthetic result.

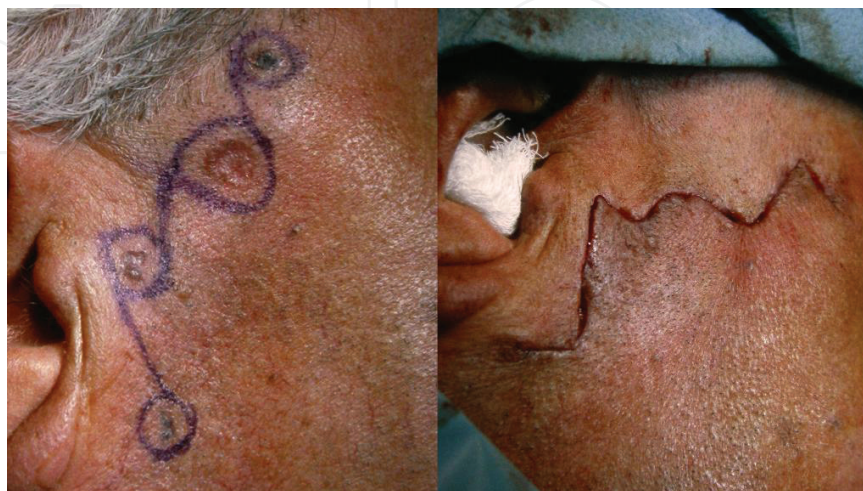

Figure 14. A clinical application of a multidentate rotation flap.

4. Transposition flaps

The transposition flap is realized by completely removing the flap from the donor area and transporting it to the receiving site by rotating it on its peduncle and overcoming a portion of healthy skin. The simplest transposition flap is Dufourmentel's flap; in this case, the flap length is about 1.5 times its width that is equal to the width of the surgical defect that must be covered (**Figure 15**).

A transposition flap can be used when the surgical wound is localized in low-resilient areas, where it is impossible to perform a direct suture. It is obtained by cutting out distant resilient donor areas that can easily be sutured. The rotation of this flap allows the surgeon to skip over the skin, although its base corresponds to the gap. The rotation angle of the flap axis can reach an angle of up to 180° (a limit to the peduncle torsion degree angle), but the rotation is usually not more than about 90° .

In the case of two close lesions, this type of plastic can be used when one of the two gaps is localized in a fairly resilient region. In this case, the flap is cut out with the gap localized in the more resilient area, in order to create a unique gap that is directly suturable, making the flap rotation to the gap easier in the low-resilient area.

In this case, it is a coaxial flap with a surgical breach. Otherwise, if the breaches are spaced apart about one in diameter, the flap can be made between the two ones and rotated to cover one of them, while the other breach (located in the denser skin zone) acts as a rotating facilitator (according to the principle of Burow's triangle). In this case, the flap can be defined as an interposed transposition flap.

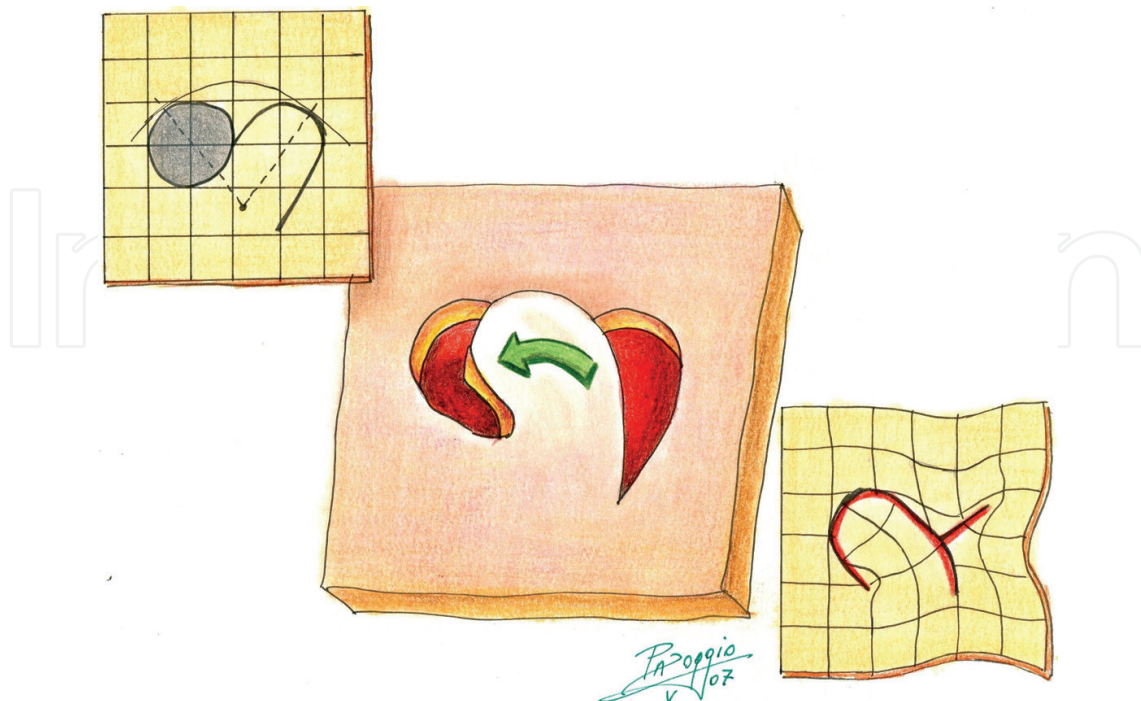


Figure 15. A transposition flap scheme.

The adoption of this technique depends on the distance between the lesions, which should not exceed 1.0–1.5 diameters, because the length of the flap must be proportional to the receiving wound so as to avoid waste-redundant skin.

4.1. Interposed transposition flaps

4.1.1. Simple transposition flap

This is the simplest form of transposition flap, useful for the closure of two contiguous surgical breaches; it is performed when the distance between the breaches is about 1 diameter (Figure 11). This simple plastic technique can be adapted according to local needs and to different skin drifts in the two breaches; at least two different types of scar can be obtained depending on the direction of flap rotation (Figure 16).

The options may even become four by flipping the cutting direction of the flap, as already described above about the simple rotation flap (see Section 3.1 and Figure 10).

A practical excursion of this plastic is summarized in Figure 16.

Starting from this simplest form of flap, it is possible to develop surgical solutions that can solve situations with multiple breaches located in very different ways.

4.1.2. Bilobed flap

When the second breach is not placed in a sufficiently drifting area, an accessory lobe can be required in the transposition flap; so, a bilobed flap is created. In this case, the donor area for

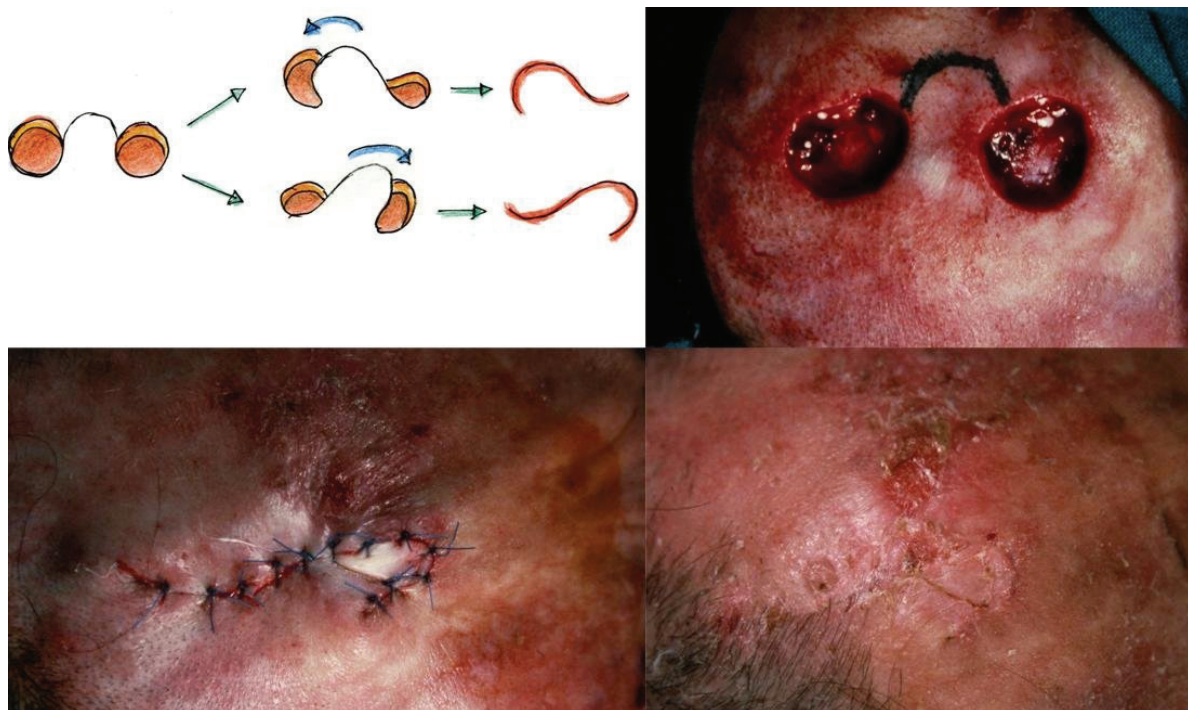


Figure 16. A clinical example of simple transposition flap and a graphic scheme of the direction of tension lines.

the first breach is closed orthogonal to the direction of rotation, while the donor area of the second flap is closed directly in the direction to the rotation, thus facilitating the movement of the flap itself (**Figure 17**).

4.1.3. Interposed bilobed flap

If the distance between the breaches is greater than 1 diameter, a bilobed flap can also be built between them, covering a gap with the first lobe and the donating area of this with the second lobe. The second breach is sutured directly, facilitating in this way the rotation of the flap. In the rotation movement, the advancement of the peduncle facilitates the direct closure of the second donor area (**Figure 18**).

4.1.4. Bilobed flap for three breach closures

It represents the extension of the concept expressed in the two previous paragraphs.

The three breaches must be spaced about a diameter and must be arranged in the shape of an arch: the most caudal of the three breaches is reduced spontaneously by the movement of the flap rotation, and the donor areas can be closed for direct suture (**Figure 19**).

4.1.5. Trilobed flaps

The concept of bilobed flap can be further expanded as trilobed flap, for multiple excisions. When the breaches are arranged along an arched line and spaced apart about 1 diameter, the flap lobes are drawn by interposing them at breaches, so that each one facilitates the rotation of the following. This can be done for three cutaneous lesions and also for four lesions (**Figure 20**).




Figure 17. A graphic representation of bilobed flap.

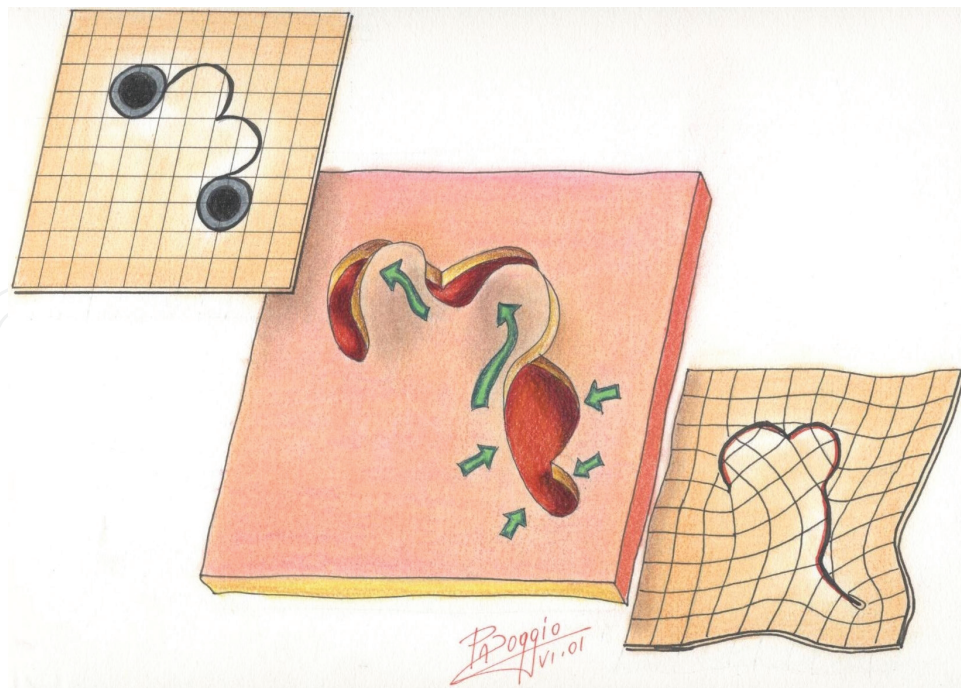


Figure 18. A graphic representation of interposed bilobed flap.

A practical application of the trilobed transposition flap is shown in **Figure 21**.

An indispensable condition for the realization of this type of plastic is that the arch along which the breach is placed should not be too tight or too large. We underline the affinity of this plastic with the multidentate flap (**Figure 13**).

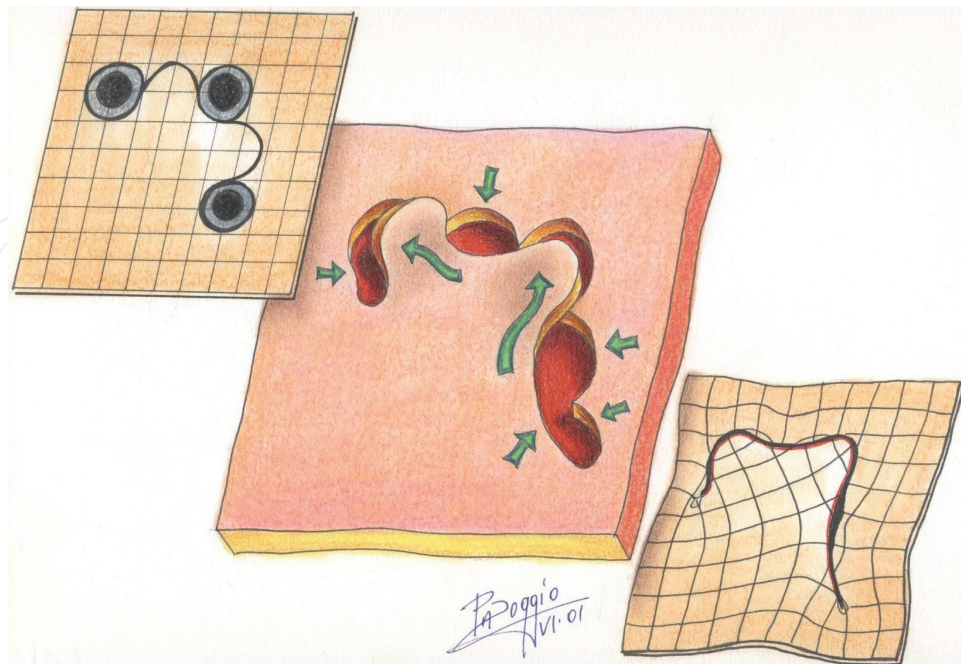


Figure 19. A graphic representation of bilobed flap for three lesions.

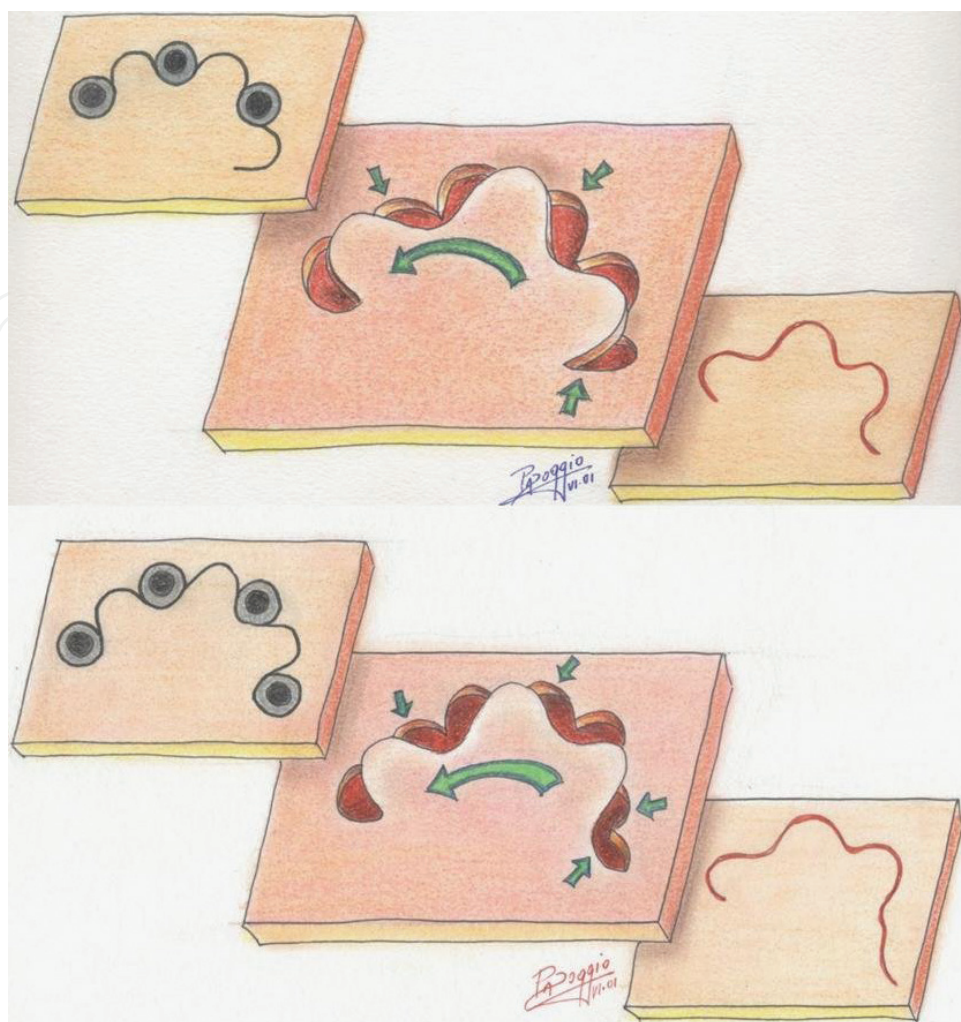


Figure 20. A graphic representation of trilobed flap and for four lesions.

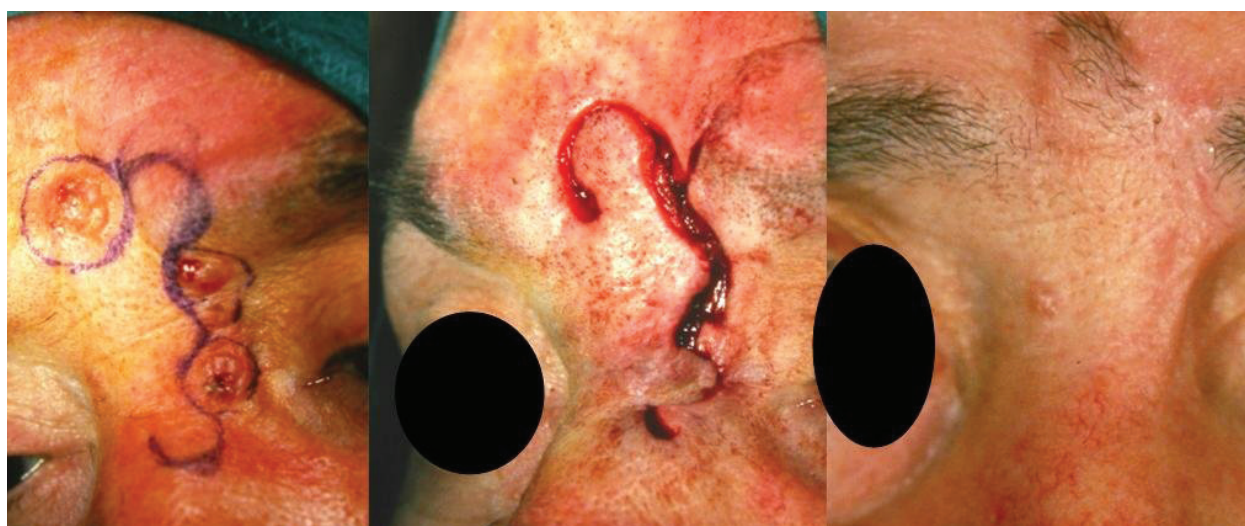

Figure 21. Clinical application of trilobed flap.

4.1.6. Centripetal and centrifugal opposite transposition flaps

In the case of three lesions of a similar size, aligned and spaced of about a diameter, we can perform a closure with a transposition flap that can be applied bilaterally in the same way. On the basis of the skin distensibility and according to the final suture shape, two flaps can be rotated in the opposite direction, exploiting, respectively, the lateral and central breaches as areas for facilitating rotation (**Figure 22**).

4.2. Coaxial transposition flaps

In case of excisions of multiple lesions, this type of plastic repair can be used when one of the gaps is localized in a fairly resilient region. A flap is cut out with the gap localized at its apex in the more resilient area, in order to create a unique gap that is directly suturable and make the flap rotation easier to the lower-resilient area.

4.2.1. Simple coaxial transposition flap

In the case of two close lesions, this type of plastic repair can be used especially when one of the two gaps is localized in a fairly resilient region. The flap is drawn with the gap localized in the more resilient area, in order to create a unique gap easy to close directly (**Figure 23**). The possibility to adopt this technique depends on the distance between the lesions, which should not exceed 1.0–1.5 diameters; in fact, the length of the flap must be proportional to the receiving wound, to avoid waste of redundant skin. In this technique, two theoretical variants of the direction of the cut are possible in order to achieve the best cosmetic result. This is obtained cutting the flap to the left or to the right of the less-resilient gap (**Figure 23**).

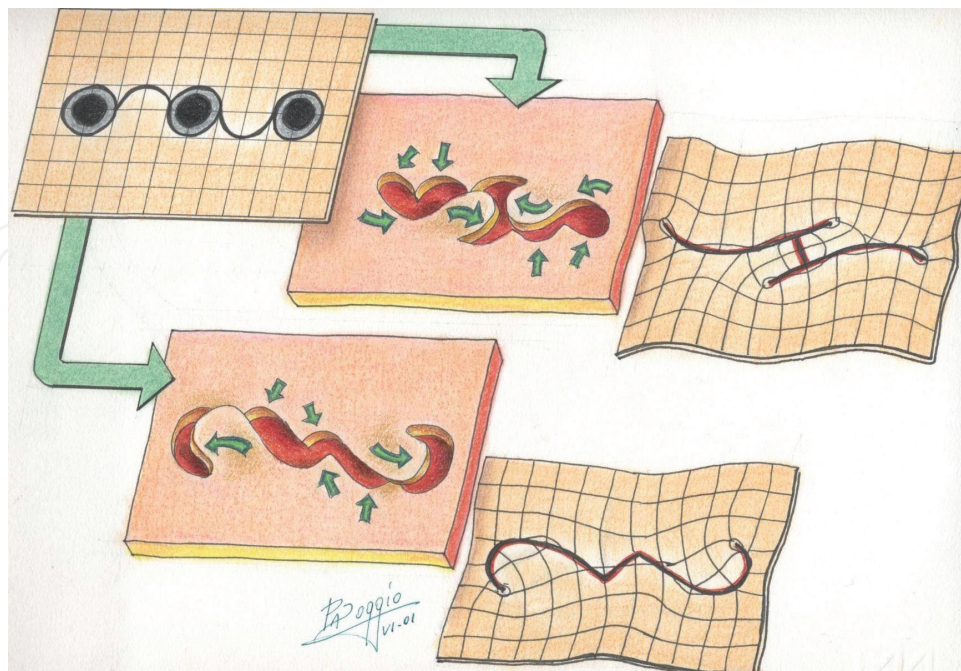


Figure 22. A graphic representation of centripetal and centrifugal opposite transposition flaps.

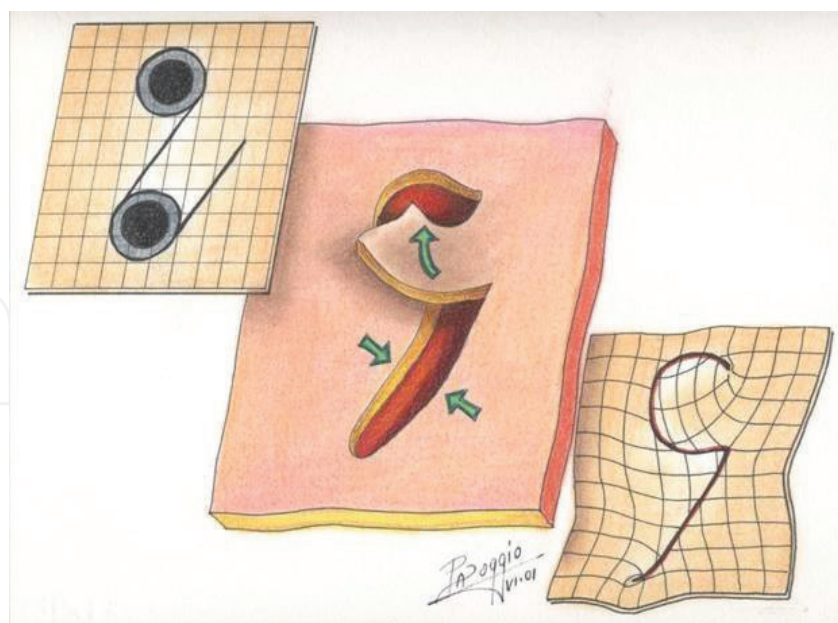


Figure 23. A graphic representation of coaxial transposition flaps.

Practical examples of the application of this technique are represented with two clinical cases; in the first one, lesions are localized in the temporal region (**Figure 24**), whereas in the second case, two lesions are localized in the retroauricular region (**Figure 25**).

4.2.2. Coaxial transposition bilobed flaps

From the type of flap described above, a variant has been developed; in this case the alignment occurs with a second accessory lobe when the lesions between them are more distant (**Figure 26**).

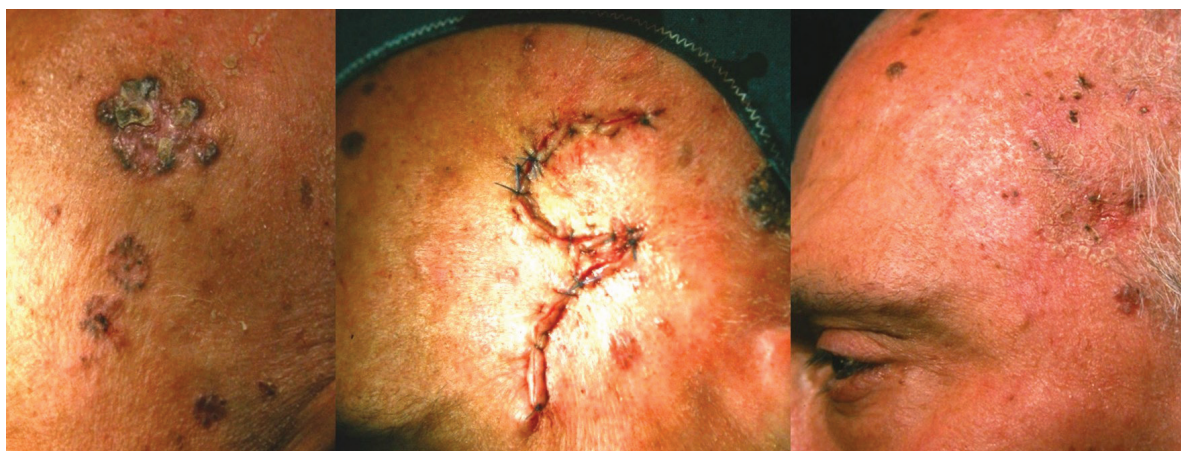

Figure 24. Clinical application of coaxial transposition flap in temporal region.

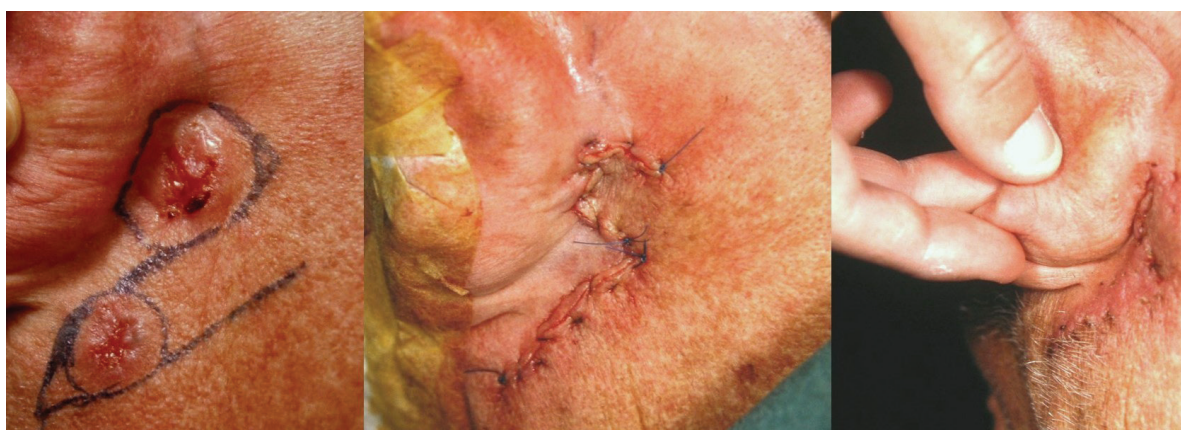

Figure 25. Clinical application of coaxial transposition flap in retroauricular region.

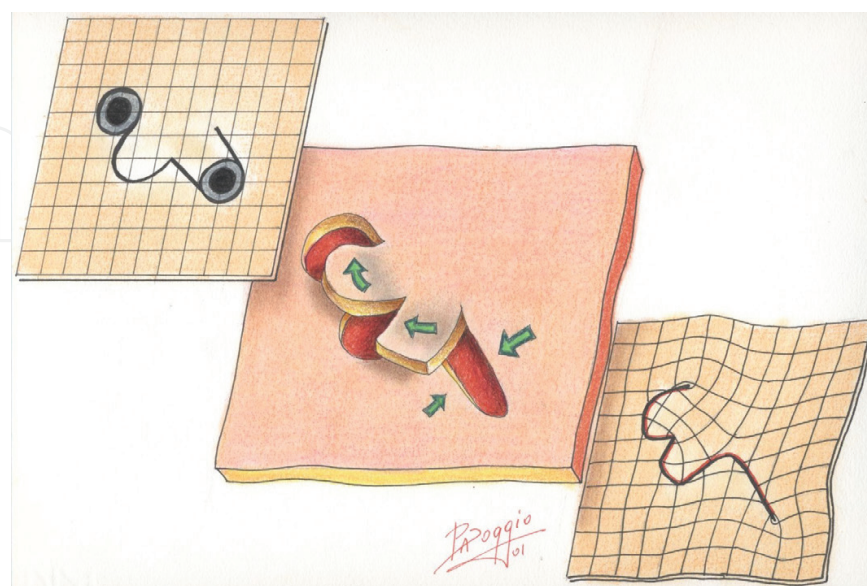


Figure 26. A graphic representation of coaxial transposition bilobed flaps.

This variant can also be applied to cases in which the second breach is in a not-sufficiently-distensible area; so, an accessory lobe is needed, to close it together with the donor area of the first lobe. **Figure 27** shows a clinical example, in which this technique is applied to the excision of two lesions on the nose.

The technique can also allow to remove three lesions: in this case, the lobes are coaxially plotted with two breaches placed in the most distensible skin areas (**Figure 28**).

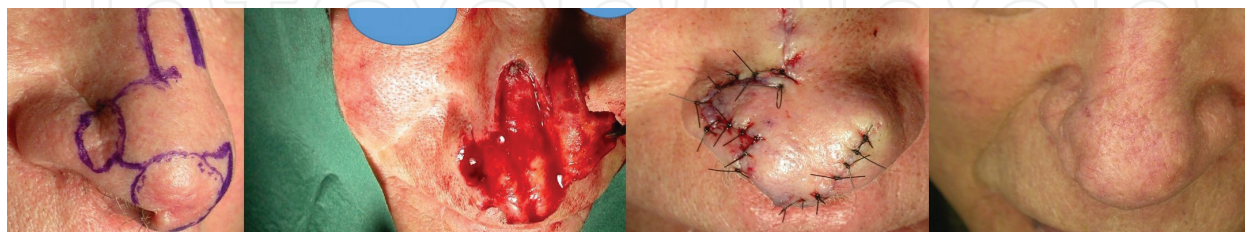


Figure 27. Clinical application of coaxial transposition bilobed flap.

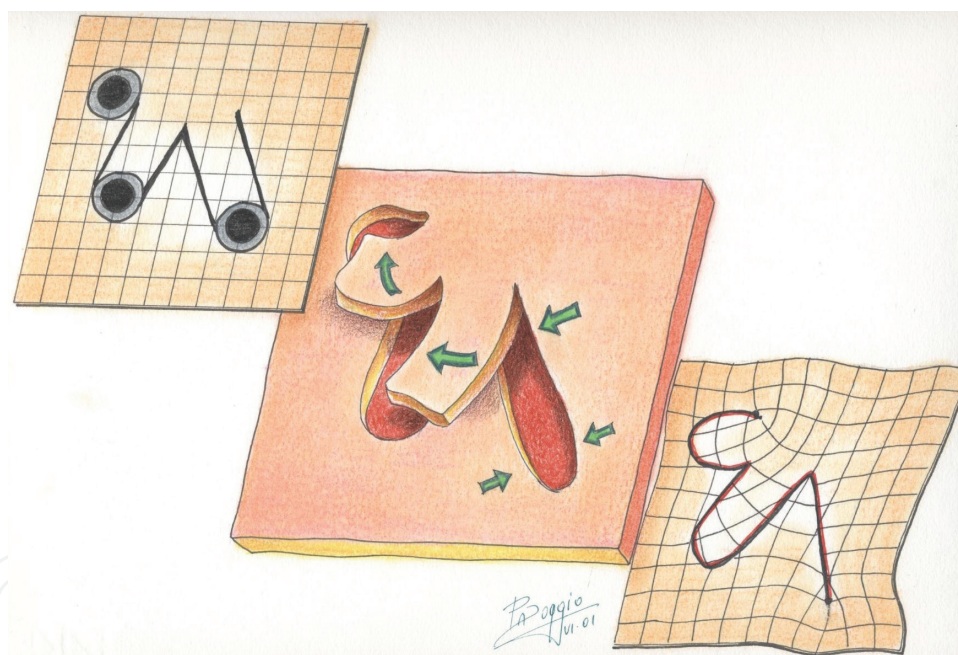


Figure 28. A scheme of a variant of coaxial bilobed flap.

5. Conclusions

We are aware of the fact that excessive schemes always have the risk of being simplistic.

The extreme variability of the cutaneous lesions areas, dimensions, and relationships between multiple lesions makes difficult to establish general rules, and at each time, the surgeon should evaluate the feasibility and the opportunity of a cutaneous plastic.

However, in this chapter we have tried to provide general guidance for the surgical treatment of multiple skin lesions, considering as many cases as possible.

In our opinion there are few general rules that you always need to keep in mind:

1. Use the minimum number of cutting lines.
2. Remove the smallest possible amount of the skin.
3. Search for the easiest plastic surgery for skin collapse.
4. Make the flaps using the cutting lines already performed for excision.
5. Search for the final suture lines respecting as much as possible the esthetic units, wrinkles, and cutaneous furrows.
6. Whenever possible, use excision areas (like Burow's triangles) to facilitate sliding of the flaps.

In conclusion, advancement, rotation, and transposition flaps should be considered as good alternatives for the simultaneous removal of close lesions, when multiple direct excisions are not feasible. However, their direction should be carefully studied in terms of distance between lesions, localization, shape, cutaneous resilience, and possible cosmetic results according to the direction of the final suture. The simultaneous ablation of multiple lesions guarantees time and cost-saving and can give better cosmetic results compared to a series of repeated rhomboid excisions. It is not possible to establish precise rules for these flaps due to the extreme variability that two close lesions can display about anatomical site, shape, and distance. For this reason, the surgeon should evaluate the advantages of a simultaneous excision with simple and conservative techniques according to each individual case. Each new case could be unique and could represent the expression of a creative, artistic, and personal intuition.

Author details

Paolo Boggio¹, Benedetta Miglino², Federica Veronese², Rossana Tiberio¹ and Paola Savoia^{2*}

*Address all correspondence to: paola.savoia65@gmail.com

1 Dermatologic Department, AOU Maggiore della Carità, Novara, Italy

2 Department of Health Science, University of Eastern Piedmont, Novara, Italy

References

- [1] Wheeland RG. Bilobed flap. In: Roenigk HH, editor. *Dermatologic Surgery*. New York: Marcel Dekker; 1989. pp. 311-313

- [2] Leigheb G. Lembo bilobato di rotazione. In: Leigheb G, Tulli A, editors. Manuale di dermo-chirurgia. Milan: Cilag sp; 1990
- [3] Kaufman R, Landes E. Simultaneous excision of two pigmented lesions. In: Kaufman R, editor. Interventi dermo-chirurgici. Mialno: Masson; 1994. p. 217
- [4] Gormley DE. The N or reversed N closure of adjacent, parallel, ellipptical excisions. The Journal of Dermatologic Surgery and Oncology. 1985;**11**:121-123
- [5] Sbano E, della Corte G. Riparazione esetica dei difetti parziali del naso mediante lembi local. G. ital. Dermatol Chir Oncologia. 1993;**2**:80-87
- [6] Salasche S. Nasal surgery. In: Roenigk RK, Roenigk HH, editors. Dermatologic Surgery. New York: Marcel Dekker; 1989. pp. 438-464
- [7] Dufourmentel C, Mouly R. Chirurgie Plastique. Paris: Flammarion; 1959