

We are IntechOpen, the world's leading publisher of Open Access books Built by scientists, for scientists

6,900

Open access books available

186,000

International authors and editors

200M

Downloads

Our authors are among the

154

Countries delivered to

TOP 1%

most cited scientists

12.2%

Contributors from top 500 universities



WEB OF SCIENCE™

Selection of our books indexed in the Book Citation Index
in Web of Science™ Core Collection (BKCI)

Interested in publishing with us?
Contact book.department@intechopen.com

Numbers displayed above are based on latest data collected.
For more information visit www.intechopen.com



Combined Approaches in Sialolithiasis of Major Salivary Glands

Iordanis Konstantinidis,
Angelos Chatziavramidis and Ioannis Iakovou

Additional information is available at the end of the chapter

<http://dx.doi.org/10.5772/intechopen.72308>

Abstract

Combined (endoscopic-transcutaneous/intraoral) techniques are an effective treatment for large and/or impacted stones of the major salivary glands. This approach results in high rates of symptom improvement and gland preservation. The complication rates are relatively low, further supporting the use of these techniques as an additional tool between the classic sialendoscopy and the external classic procedures of gland removal. In this chapter, we describe the combined approach for the parotid gland and the submandibular gland and finally, the retrograde sialendoscopy through the surgical field of an open approach.

Keywords: sialendoscopy, transcutaneous, sialolithiasis, parotid, submandibular

1. Introduction

Endoscopic techniques in the management of sialolithiasis were introduced since the 1990s and gradually became the standard treatment option, decreasing the external procedures [1]. In our days only 20–25% of all symptomatic cases require an open surgical approach of the gland [1, 2]. The introduction of interventional sialendoscopy with intraductal laser fragmentation did not solve all the problems as some stones were too large to be fragmented, and some others had associated with ductal stenosis which could not be dilated [3].

In order to avoid gland removal with its associated significant morbidity, surgeons developed combined techniques (endoscopic and transcutaneous) as a solution within the frame of a gland-preserving strategy [4–6].

Indications for this combined management are failure of interventional sialendoscopy to treat impacted calculi, stones larger than 8 mm, stones located behind a stenosis which cannot be dilated, and finally a non-successful extra- or intracorporeal lithotripsy [4–8].

In this chapter, we present approaches that we use in parotid and submandibular sialolithiasis cases in order to avoid gland removal.

2. Combined approach in parotid sialolithiasis

2.1. Surgical technique

This is a procedure performed under general anesthesia. Facial nerve monitoring is mandatory as in the majority of the cases a branch of the nerve is located closely to the main ductal system.

Before the procedure, a diagnostic sialendoscopy is carried out to ensure that endoscopic localization of the stone is possible. The sialendoscope used in surgery has usually a diameter of 1.1 mm. The first step of the procedure is the identification by means of the endoscope of the stone's location in the ductal system. Then, the skin above the stone is marked as the light of the endoscope's tip can be easily detected (**Figure 1**).

The location of the stone (proximal-distal, superficial-deep in the gland) is the factor which affects the surgeon's decision regarding the incision which is required. Three incisions have been described [8]:

1. Lazy S
2. Mini parotidectomy incision extended if required to face lift
3. Straight, small incision above the stone

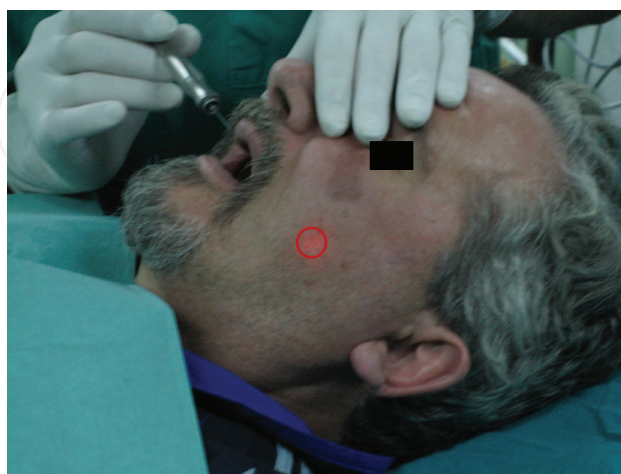

Figure 1. Transillumination of the parotid area and skin marking before the operation.

In the vast majority of cases, the first two incisions are used with the last one only in very superficial and/or proximal stones especially in aged people where the skin lines can hide a relatively small facial scar.

In cases where a parotid incision approach is required, the skin flap is elevated exposing enough surface of the gland for the stone removal. Transillumination of the sialendoscope's tip into the ductal system helps the precise gland-preserving dissection technique. In superficial stones, a longitudinal incision of the gland parenchyma (1–1.5 cm in length) above the endoscope light is performed (**Figure 2A**). In stones with deeper location (5 mm from the surface of the gland), a mini-flap of the gland parenchyma is prepared above the area of the ductal system which is lighted (**Figure 2B**) [9].

Stenting the ductal system is not obligatory. We suggest the use of a stent in cases where an opening of the ductal system larger than 1 cm has been performed and/or other traumatic manipulations in the duct have been done during removal of a polyp or an impacted stone. Usually, when a stent is used, this is placed in a retrograde fashion via the surgical field and secured in buccal mucosa with absorbable sutures (**Figure 3**). The stent can be left for a period of 3–6 weeks. The closure of the parotid duct is carried out using absorbable sutures. Fibrin glue and absorbable sutures are used for the repositioning of the gland flap in cases of non-superficial stone location (**Figure 4A and B**). A small drainage usually is needed as in parotid tumor surgery which is removed on the first postoperative day. Tight bandage for 4–5 days is proposed to avoid leak of saliva. Patients take broad-spectrum antibiotic treatment for a week and analgesics if required.

2.2. Follow-up assessment

During the first postoperative period (2–3 weeks), patients are advised to avoid nutrition which produce excessive saliva (e.g., lemon juice, etc.).

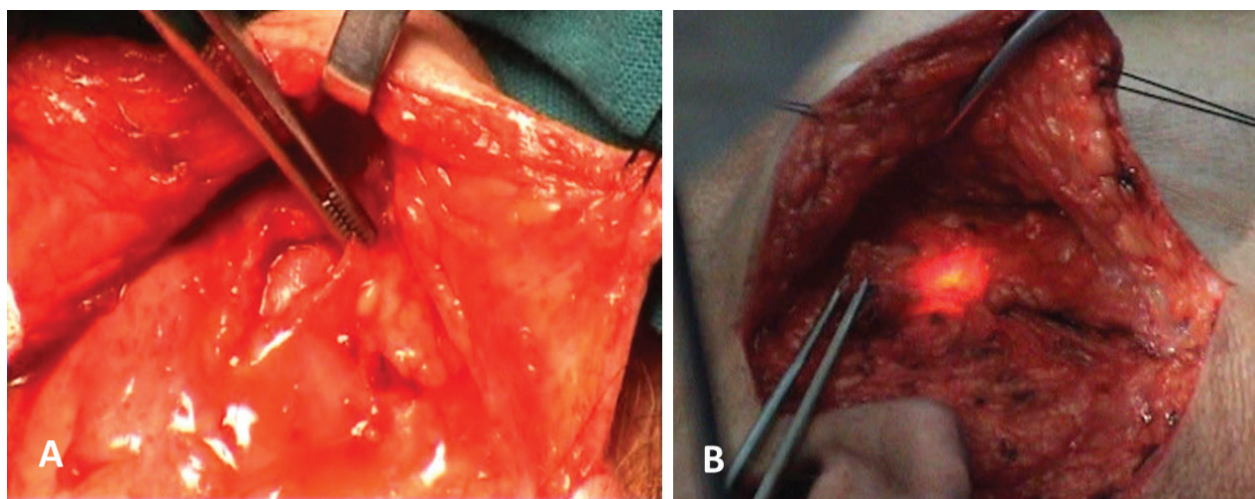


Figure 2. (A) Longitudinal incision of the gland in a superficial stone and (B) n-shaped mini-flap in a deep-located stone.

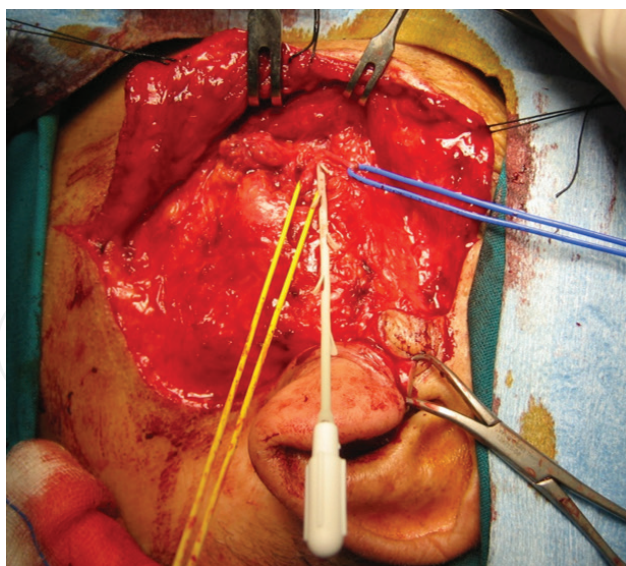


Figure 3. Stent placement in a retrograde fashion via the surgical field. The left loop isolates the main duct, and the right the facial nerve branch which run close to the ductal system.

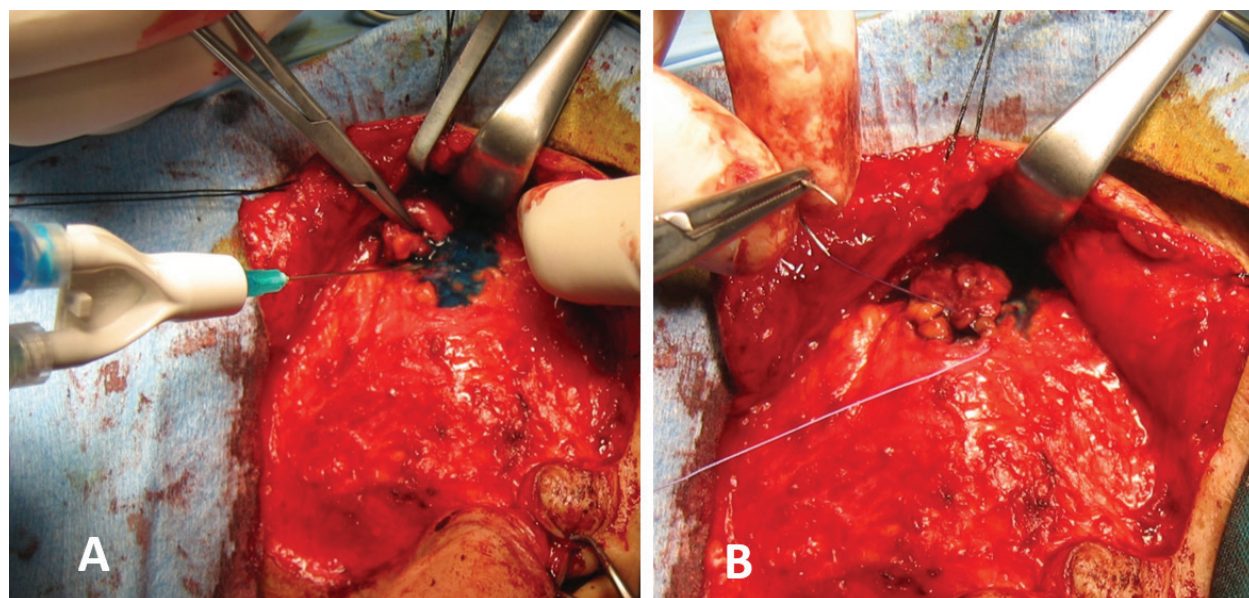


Figure 4. (A) Fibrin glue and (B) absorbable sutures are used for the repositioning of the gland flap in cases of non-superficial stone location.

Early complications such as hematoma, sialadenitis, wound infection, fistula, and obstructed and/or extruded stent have been rarely published and usually occur within the first postoperative month. In such cases, conservative management and removal of stent if needed are enough measures [9–11].

Initially, one of the surgeons' concerns about the procedure was the potential postoperative stenosis at the site of the ductal incision. This fact is expected and was confirmed in our data, as 7 patients out of 12 had an endoscopically diagnosed postoperative stenosis [9]. However,

these stenotic areas are considered without clinical impact as none of the patients suffered from postoperative swellings. The incision is parallel to the duct axon, and this may decrease the possibility for severe stenosis even in cases with extended opening. In addition stenting with precise intraoperative placement can be helpful to avoid postoperative stenosis. Undoubtedly, further studies are needed to justify the size of the ductal opening which is critical regarding postoperative stenosis.

In the same study, scintigraphic evaluation of the operated parotid glands in two phases (baseline and after stimulation) provided an objective functional evaluation 1 year after the procedures [9]. Specifically, a dynamic imaging of the whole anterior head started after a bolus intravenous injection of ^{99m}Tc . Fifteen minutes after the initial injection, diluted lemon juice was given per oz. The parameters measured were (1) uptake rate, taken as the value of the initial slope of the time-activity curve and (2) washout fraction, as a relative mobilized radioactivity from each parotid gland after the sialogogue's application. In the vast majority of cases (11/12), the procedure preserved the function of the gland with only one parotid hypofunction in a patient with long-term history of sialolithiasis.

Extracorporeal and laser intraductal lithotripsy requires expensive devices which are not always available; they are time-consuming and always have a potential risk of leaving residual stone fragments which can be a nidus for new stone formation. Moreover, some patients prefer the described surgical option as a "one shoot" intervention instead of extracorporeal lithotripsy which may need multiple sessions [10–12].

Contraindication for this procedure is the presence of diffuse ductal stenosis or multiple parenchymal stones [8, 9].

3. Combined approach in submandibular sialolithiasis

A combined approach can be also used for submandibular gland with large and/or impacted stones in a similar manner with the parotid gland.

3.1. Surgical technique

The procedure starts again with a sialendoscopy, and when the endoscope approximates, the stone then is fixed to the floor of the mouth or can be held steadily by an assistant.

Infiltration of the transilluminated area with xylocaine 2%-adrenalin 1% solution follows. The next step is an incision of the oral mucosa approximately 2 cm in length following the axis of Wharton's duct size just above the lighted area (**Figure 5A and B**). Caution should be taken at this point in order to avoid lingual nerve damage as it crosses Wharton's duct and this is the reason why some authors identify and isolate the nerve with a loop from the surgical field [8].

A useful surgical tip is the fact that the floor of the mouth can be pushed upward by external pressure at submandibular triangle below the patient's mandible, giving better access to the hilum area endorally.

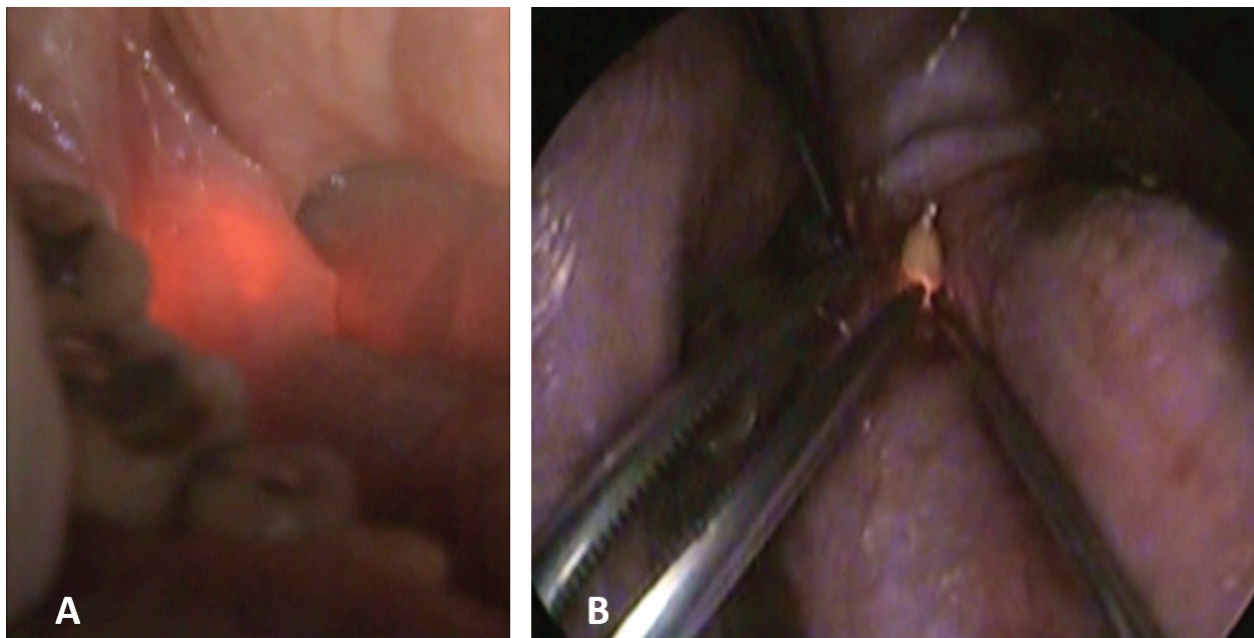


Figure 5. (A) Transillumination of the hilum area in a right submandibular gland intraorally. (B) Incision and stone removal.

After the identification of the duct, silastic loops are positioned around the duct helping its traction and dissection. The stone is palpated by the finger or surgical instrument, and a straight incision above the stone at the axis of the duct is performed. Once the stone has been removed, an endoscopy of the ductal system behind the stone is mandatory for residual stones or strictures, etc.

The use of a stent at the end of the procedure is not universally accepted; however, it is the preference of the authors as it offers a stable floor for the ductoplasty. Its insertion through the papilla can be performed directly or with the use of the endoscope or a guide-wire for more safety especially when a precise placement to the posterior portion of the duct is required. The stent is then sutured and secured with a nonabsorbable suture to Wharton's papilla area. The time of stenting varies in the literature with a period of 3 weeks being the minimum and 6 weeks usually the maximum depending on the patients' tolerance.

3.2. Follow-up assessment

Patients receive the same instructions as in parotid stones for their diet postoperatively. Similarly, they take broad-spectrum antibiotic treatment for a week and analgesics if required with the addition of oral antiseptic solution local application after meals.

Early complications are rare and include lingual nerve damage, hematoma, and gland swelling extrusion of the stent which are usually managed in a conservative way.

A certain degree of postoperative stenosis is expected in the long term; however, the region of the hilum is large enough, and these strictures run usually as asymptomatic.

This procedure is not popular in the literature as the parotid one, because many surgeons prefer the endoral marsipulization of the duct to have access in stones at the region of the

hilum. This procedure offers equally good results although does not preserve the integrity of the ductal system. Moreover, when marsipulization of the main duct reaches the hilum, the endoscopic assessment of the residual ductal system becomes problematic due to leakage during saline irrigation.

4. Retrograde sialendoscopy

In cases with parenchymal and especially multiple stones of the submandibular gland, an external approach with removal of the gland is indicated. However, some stones may slip into Wharton's duct during surgical manipulations causing symptoms at a later time. In a study by Milton et al., authors found that 5% of patients who underwent submandibular gland removal had residual stones in the remaining duct, requiring further surgery [13].

For such cases a retrograde sialendoscopy is proposed through the surgical field after the removal of the gland [14]. A standard procedure of submandibular gland resection is performed with a transcervical incision. Identification and preservation of the lingual nerve from the gland at the area of submandibular ganglion follow along with careful dissection and skeletonization of the submandibular duct. Two stay sutures are placed on the opposing sides of the duct, proximal to the gland. After the removal of the gland, these sutures are used for stretching of the duct in order to facilitate placement of a large in outer diameter (1.4 or 1.6 mm) sialendoscope for retrograde inspection (**Figure 6**).

In cases where residual stones or debris are identified, then they can be removed by wire basket or alternatively can be pushed by the endoscope into the oral cavity (retrograde) or into the neck with the endoscope coming from the oral cavity. At the end of the procedure, stay sutures help for duct traction into the neck and its ligation proximally in order to minimize the length of the remained duct.

Contraindication of this procedure is the diffuse stenosis of the duct or severe strictures due previous trauma or surgery.

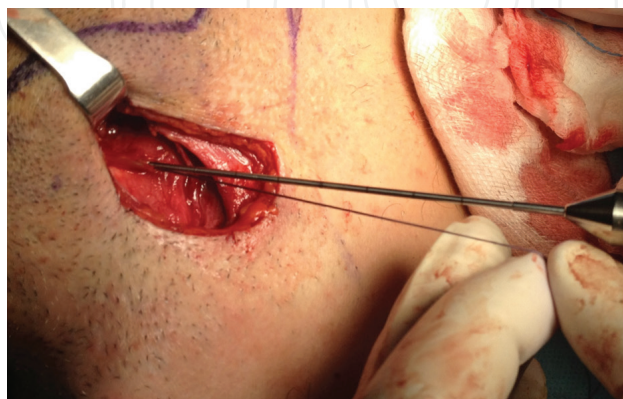


Figure 6. Retrograde sialendoscopy: insertion of the sialendoscope into Wharton's duct after removal of the submandibular gland. The duct is stretched with a silk suture.

Author details

Iordanis Konstantinidis^{1*}, Angelos Chatziavramidis¹ and Ioannis Iakovou²

*Address all correspondence to: jordan_orl@hotmail.com

1 2nd Academic ORL Department, Aristotle University, Papageorgiou Hospital, Thessaloniki, Greece

2 3rd Nuclear Medicine Department, Aristotle University, Papageorgiou Hospital, Thessaloniki, Greece

References

- [1] Iro H, Zenk J, Escudier MP, Nahlieli O, Capaccio P, Katz P, Brown J, McGurk M. Outcome of minimally invasive management of salivary calculi in 4,691 patients. *The Laryngoscope*. 2009;**119**:263-268. DOI: 10.1002/lary.20008
- [2] Koch M, Zenk J, Iro H. Algorithms for treatment of salivary gland obstructions. *Otolaryngologic Clinics of North America*. 2009;**42**:1173-1192. DOI: 10.1016/j.otc.2009.08.002
- [3] Phillips J, Withrow K. Outcomes of holmium laser-assisted lithotripsy with sialendoscopy in treatment of sialolithiasis. *Otolaryngology and Head and Neck Surgery*. 2014;**150**: 962-967. DOI: 10.1177/0194599814524716
- [4] McGurk M, MacBean AD, Fan KF, Sproat C, Darwish C. Endoscopically assisted operative retrieval of parotid stones. *The British Journal of Oral & Maxillofacial Surgery*. 2006;**44**:157-160. DOI: 10.1016/j.bjoms.2005.03.026
- [5] Walvekar RR, Bomeli SR, Carrau RL, Schaitkin B. Combined approach technique for the management of large salivary stones. *The Laryngoscope*. 2009;**119**:1125-1129. DOI: 10.1002/lary.20203
- [6] Koch M, Iro H, Zenk J. Combined endoscopic-transcutaneous surgery in parotid gland sialolithiasis and other ductal diseases: Reporting medium- to long-term objective and patients' subjective outcomes. *European Archives of Oto-Rhino-Laryngology*. 2013;**270**: 1933-1940. DOI: 10.1007/s00405-012-2286-y
- [7] Roland LT, Skillington SA, Ogden MA. Sialendoscopy-assisted transfacial removal of parotid sialoliths: A systematic review and meta-analysis. *The Laryngoscope*. DOI: 10.1002/lary.26610
- [8] Marchal F. A combined endoscopic and external approach for extraction of large stones with preservation of parotid and submandibular glands. *The Laryngoscope*. 2007;**117**: 373-377. DOI: 10.1097/mlg.0b013e31802c06e9
- [9] Konstantinidis I, Chatziavramidis A, Iakovou I, Constantinidis J. Long-term results of combined approach in parotid sialolithiasis. *European Archives of Oto-Rhino-Laryngology*. 2015;**272**:3533-3538. DOI: 10.1007/s00405-014-3391-x

- [10] Kopec T, Szyfter W, Wierzbicka M. Sialoendoscopy and combined approach for the management of salivary gland stones. *European Archives of Oto-Rhino-Laryngology*. 2013;**270**: 219-223. DOI: 10.1007/s00405-012-2145-x
- [11] Klein H, Ardekian L. The treatment of large sialoliths by sialendoscopic combined approach. *Journal of Oral and Maxillofacial Surgery*. 2014;**72**:737-743. DOI: 10.1016/j.joms.2013.09.003
- [12] Capaccio P, Torretta S, Pignataro L, Koch M. Salivary lithotripsy in the era of sialendoscopy. *Acta Otorhinolaryngologica Italica*. 2017;**37**:113-121. DOI: 10.14639/0392-100X-1600
- [13] Milton CM, Thomas BM, Bickerton RC. Morbidity study of submandibular gland excision. *Annals of the Royal College of Surgeons of England*. 1986;**68**:148-150
- [14] Potash A, Hoffman HT. Retrograde sialendoscopy: A new technique for avoiding retained ductal stones. *The Annals of Otology, Rhinology, and Laryngology*. 2012;**121**:38-43. DOI: 10.1177/000348941212100107

