

We are IntechOpen, the world's leading publisher of Open Access books Built by scientists, for scientists

6,900

Open access books available

185,000

International authors and editors

200M

Downloads

Our authors are among the

154

Countries delivered to

TOP 1%

most cited scientists

12.2%

Contributors from top 500 universities



WEB OF SCIENCE™

Selection of our books indexed in the Book Citation Index
in Web of Science™ Core Collection (BKCI)

Interested in publishing with us?
Contact book.department@intechopen.com

Numbers displayed above are based on latest data collected.
For more information visit www.intechopen.com



Passive Biomimetic Prosthesis

Smita Nayak and Prasanna Lenka

Additional information is available at the end of the chapter

<http://dx.doi.org/10.5772/intechopen.72123>

Abstract

Advancement in prosthetic technology provides the prosthesis more natural function and cosmesis to the amputee limb. But in most of the cases due to some limitations of the patient, the most appropriate prosthetic solution is not possible. Custom made silicone prosthesis with some passive function plays the major role to rehabilitate those patients. The cosmetic prosthesis mimics the natural colour and texture of the normal body. Nowadays the cosmetic prosthesis becomes the foremost choice of the amputee individuals.

Keywords: prosthesis, cosmetic, passive, custom made, silicone

1. Introduction

Prosthesis (plural prostheses), the proper name for an artificial limb, derives from the Greek roots meaning “to replace an addition”. The replacement of lost part was for the functional, cosmetic or protective reasons or some combinations of these. The earliest concept of cosmesis was started, and the first cosmetic wooden prosthesis of Hallux fitted in Egypt about 1000 BCE [1]. In the process of development and continuous research, the robotic prostheses are the new-generation prosthesis that mimics most natural movements and cosmesis. Advanced functional prostheses are with some disadvantages like high maintenance and cost and not reachable to every individual living in a rural area. The deformed shape of the stump in case of finger, partial hand and partial foot sometimes are not suitable for the fitment of functional prosthesis, but the patients are willing to fit the prosthesis to get cosmesis as well as some function. The passive prosthesis is the only option to fit any kind of irregular stump to make it cosmetic and provide some passive function. The individuals with passive prosthesis actively use their prostheses as frequently as do functional prostheses. The passive prostheses are used to stabilize objects, push against item and assist them in various ADL activities.

1.1. Cosmetic silicone prosthesis

In the development of material science, the silicone is found to be the most acceptable material to fabricate the cosmetic prosthesis. The silicone prosthesis can often restore a near-normal function in distal phalange amputations. The fabrication of the prosthesis required an artist hand with implementation of scientific knowledge [2]. The role of prosthesis is to replace the part by providing natural function and shape. The psychological aspect is more important to keep in mind during fabrication of any prosthesis. Aesthetic silicone prostheses have been shown to play a useful role in restoring normal appearance and assist in the rehabilitation of patients with amputations involving the upper limbs. Custom made finger prosthesis is aesthetically acceptable and comfortable for use in patients with amputated fingers, resulting in psychological improvement and well-being [3] (**Figures 1 and 4**).

The aesthetic hand prosthesis is previously used for cosmetic purposes, but the functional aspect has not been considered [4]. But role of this prosthesis is found in both cosmesis and passive functions (**Figure 2**). The usefulness of aesthetic prostheses is confirmed by the improvement of patients' living conditions and the continued wearing of these prostheses by the patients. Although a variety of materials have been used for aesthetic restoration, silicone is generally preferred because of its versatility, durability and compatibility with human tissue. Polymers of dimethyl siloxane (silicones) allow copying of the natural hand in every detail. Silicone prostheses are usually of high quality, match well with the patients remaining digits and thus are more aesthetically pleasing; long-term wearing of this prosthesis confirms as therapeutic tools. To achieve the normal appearance in the prosthesis, the cosmetic nail, the hair and flocking are used.

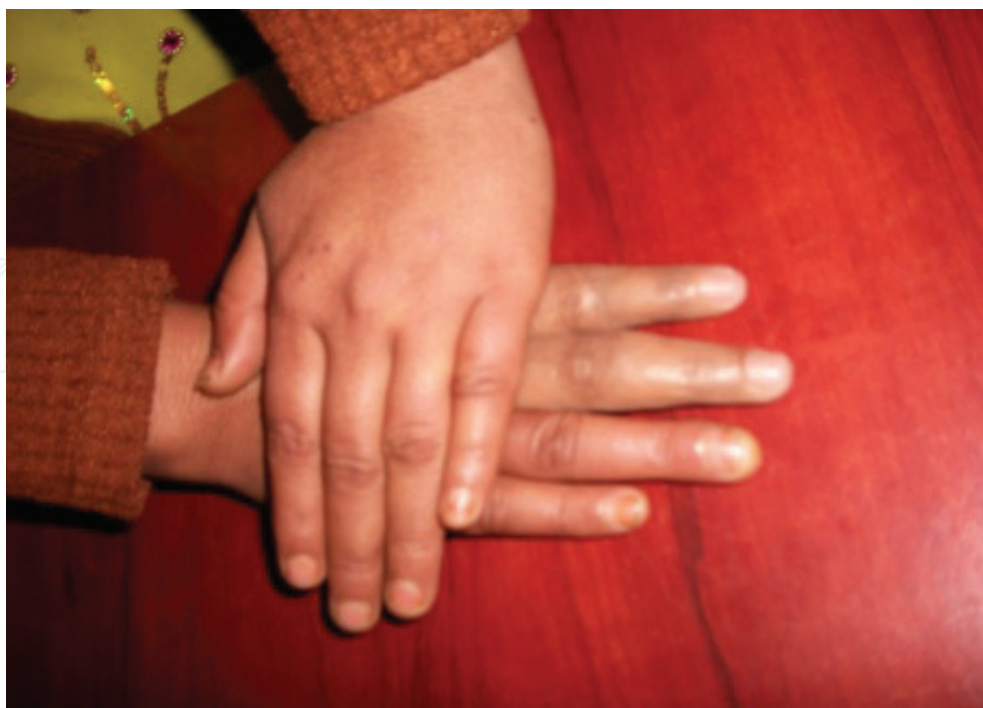

Figure 1. After fitment of silicone finger prosthesis in right side middle and index finger amputation.



Figure 2. Partial silicone hand prosthesis.

Apart from the finger and hand, toe and partial foot silicone prosthesis is mostly accepted by the patients [5] (**Figures 3, 5**). The cosmetic prosthesis mimics the natural appearance without any complicated mechanism. These are easy to use with very low maintenance. So, nowadays, the use of cosmetic prosthesis is more than a complicated functional prosthesis.

1.2. Cosmetic silicone prosthesis with passive function (custom made)

The cosmetic prosthesis of the finger and hand is not usually having the movable digits. The prosthesis is only used for the cosmesis purpose and psychological benefit for the patients. Now these prostheses are having some passive movements of the fingers due to the involvement of some copper wires inside the prosthesis during the time of fabrication. This process is cost-effective and time-saving [6] (**Figure 6**).

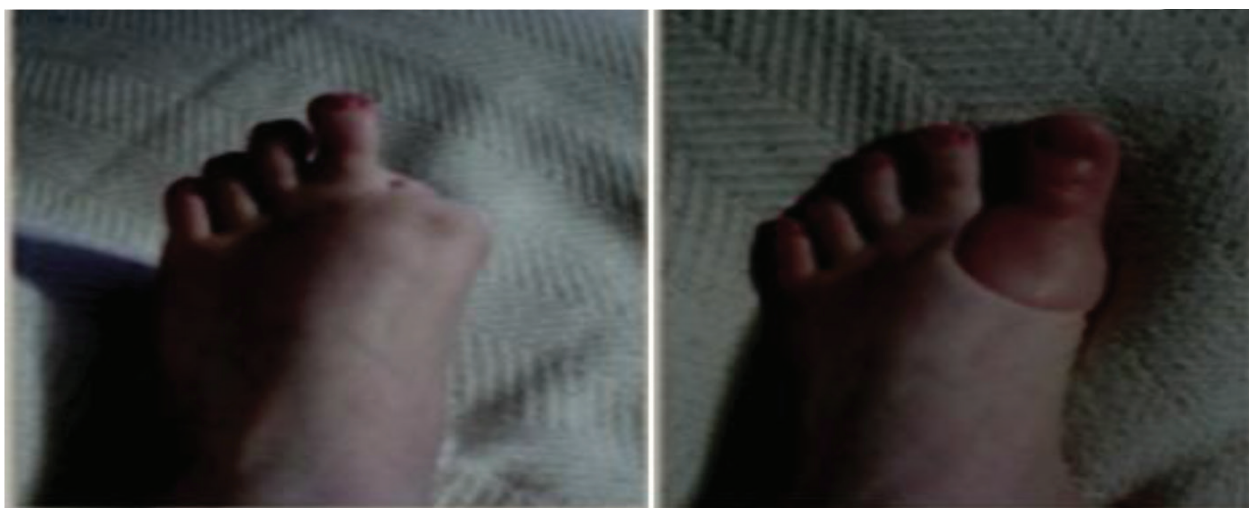

Figure 3. Before and after fitment of silicone toe.

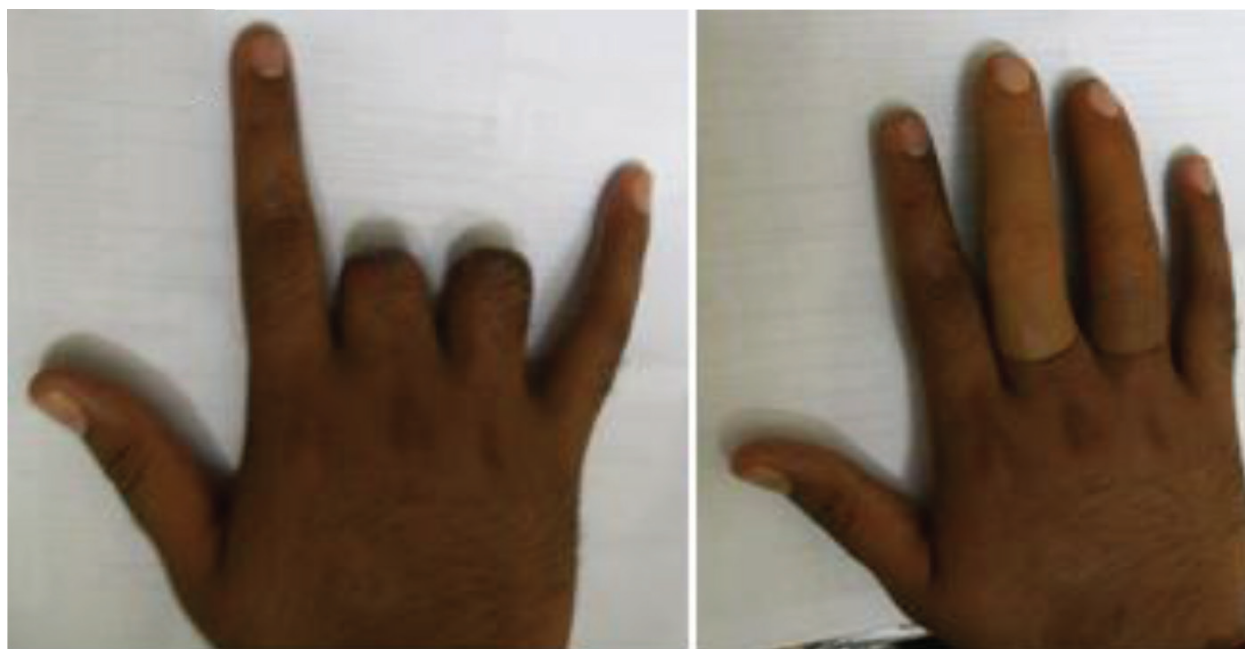


Figure 4. Fitting of silicone finger prosthesis in the middle and ring fingers.

1.3. Attachment and alignment of cosmetic prosthesis

The attachment of prosthesis depends upon the remaining part and contours of the stump. The finger amputation of PIP and DIP level, the suction suspension is the method of attachment, and amputation through metacarpophalangeal attachment is through strap suspension (**Figure 7**). The alignment is done before the fabrication during this process, and the overall length is checked with the opposite limb.

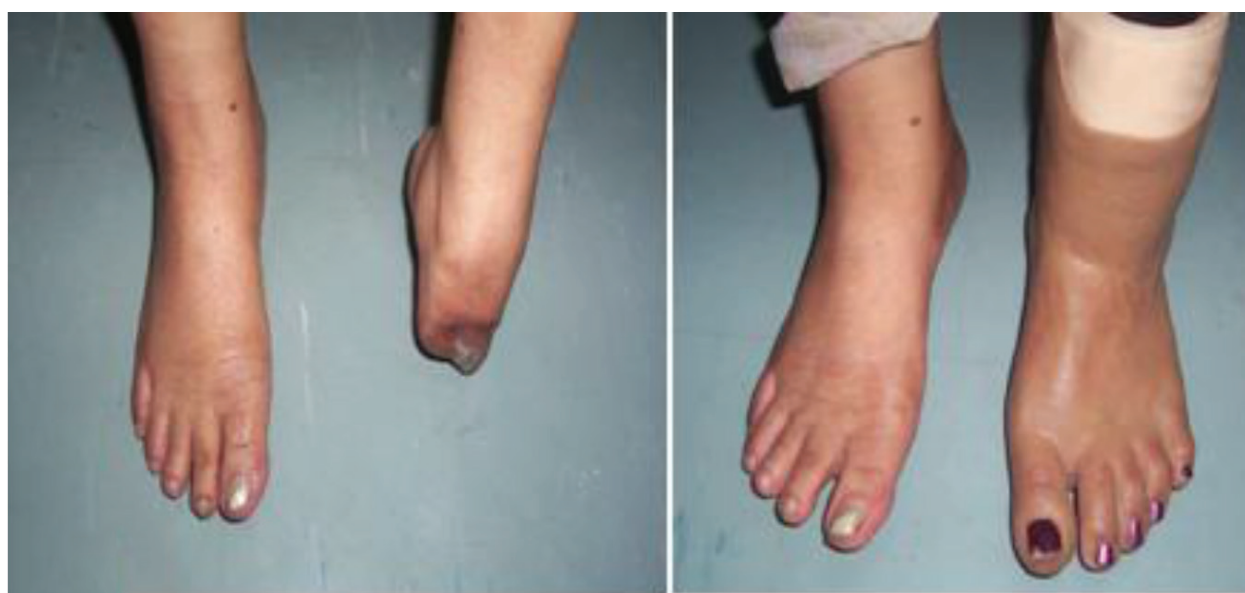

Figure 5. Silicone partial foot prosthesis.



Figure 6. Copper wire and silicone die of partial hand with copper wire.

1.4. Maxillofacial silicone prosthesis

The face is considered as the most beautiful and expressive part of the body. The eye, ear, chick and nose, play different roles in various expressions (**Figures 8–11**). If the patient lost any part of the organ in the face, they felt as a half-dead person. These kinds of people were not having the courage to face the society. In the process of plastic surgery, they may modify the structure but

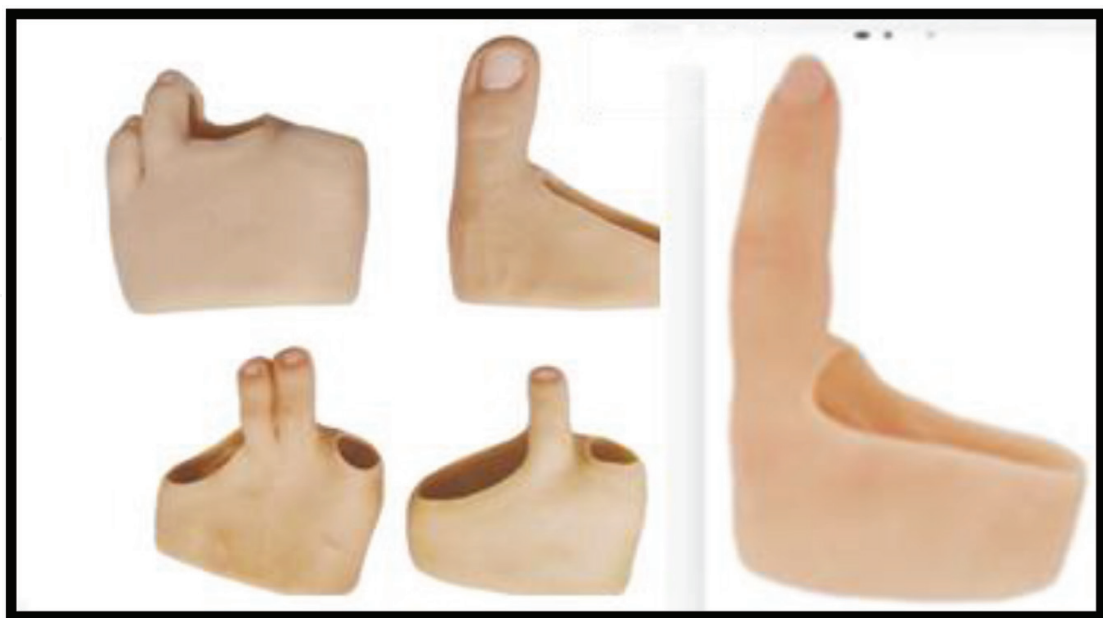

Figure 7. The finger and toes with strap suspension.

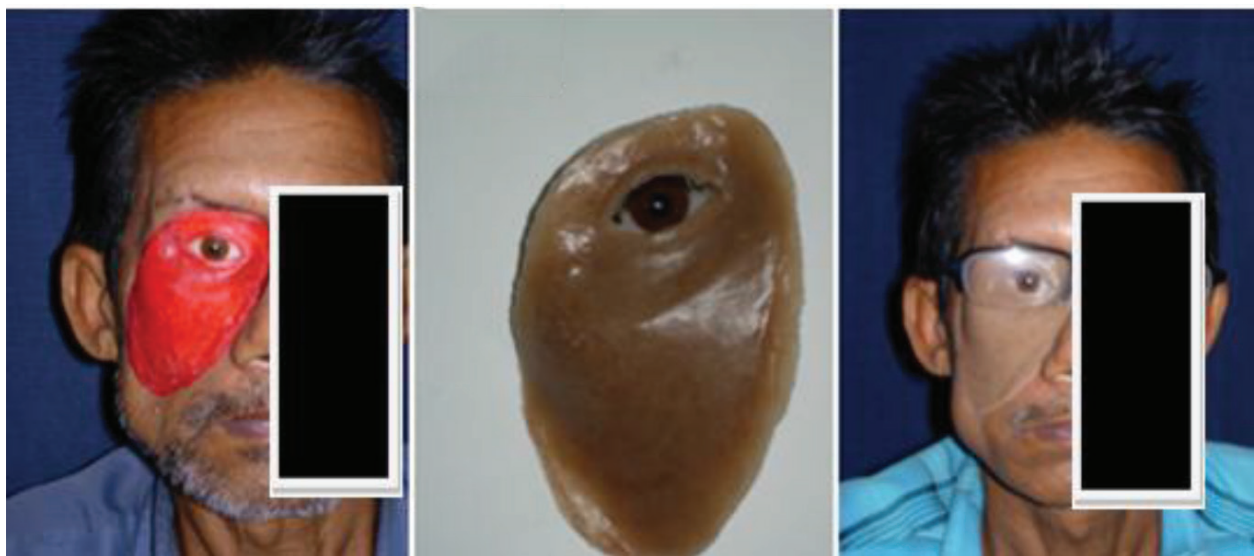

Figure 8. Patient with cosmetic eye.



Figure 9. Before and after photo of cosmetic ear.

the scar and lost part not be fulfilled. The role of rehabilitation can be able to reduce the disfigurement by the cosmetic prosthesis. The silicone is very compatible with the body and it can be used as laryngeal prosthesis in the case of patient with tracheotomy during the chemotherapy. The number of breast cancer is increasing nowadays; the silicone breast is considered as the best option to maintain the shape without any complications.

1.5. Methods

The patients for passive prosthesis are selected according to the requirement of the patients, availability of the material and condition of the stump. The patients sometimes prefer cosmesis

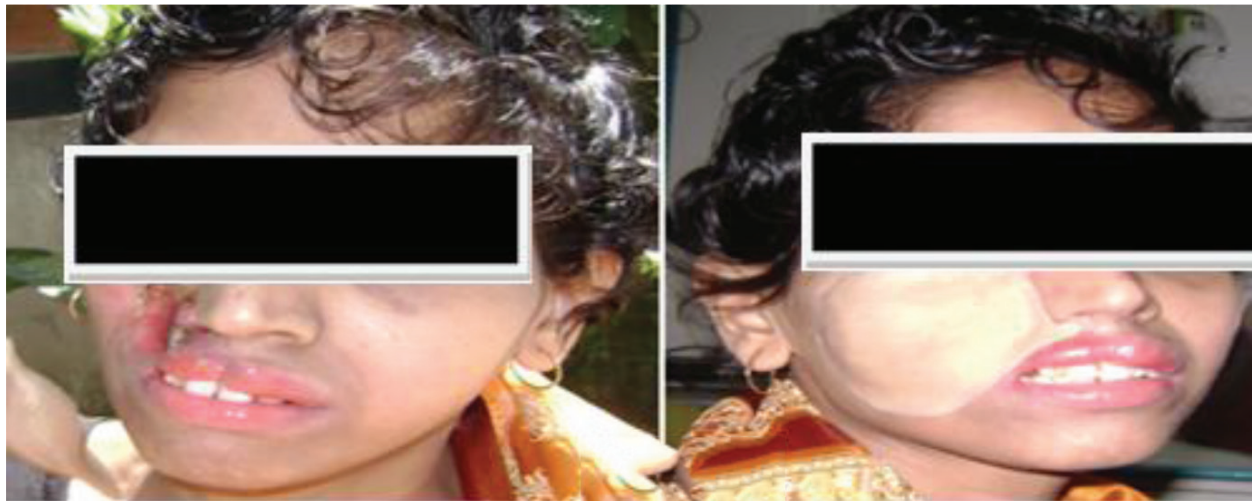

Figure 10. Before and after the use of silicone chick prosthesis.

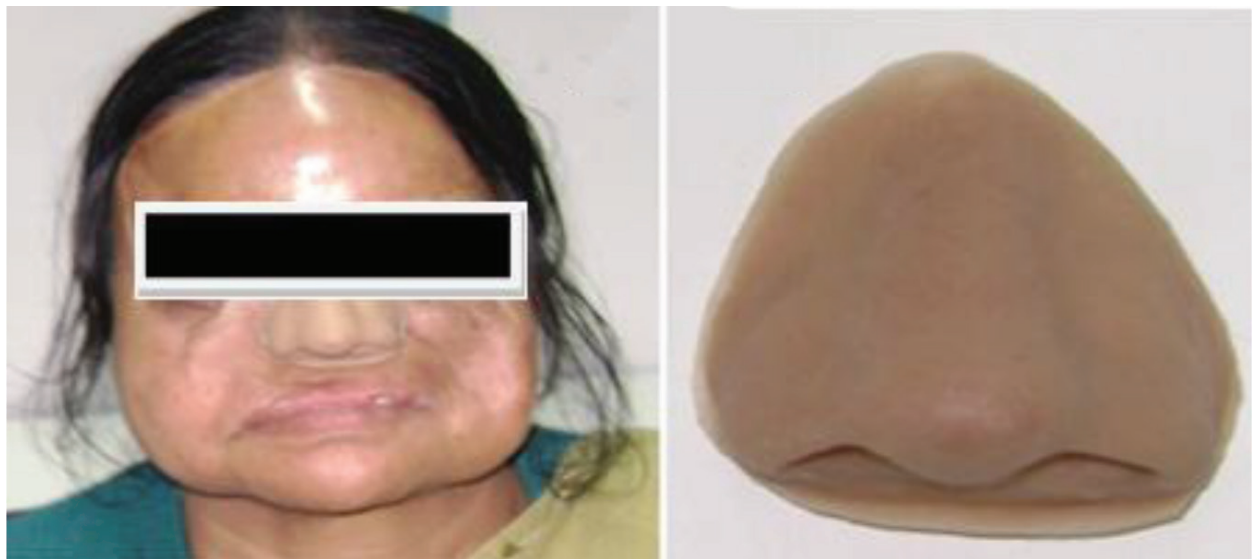

Figure 11. Patient with cosmetic silicone nose.

over functional prosthesis in that case the passive prosthesis plays the role of cosmetic prosthesis with the removal of additional component of functional prosthesis ultimately reduced the weight. The patients were assessed by the clinical team members and decided to fit the passive prosthesis, which was the suitable option for the patients. The criteria for selection of the patients were (1) uncosmetic appearance of the stump, (2) the functional prosthesis cannot be fitted, (3) the patient needs only cosmetic appearance, (4) unavailability of the functional components and (5) pain and insensitive stump. The selected patients were again assessed for the appropriate passive prosthesis such as finger prosthesis, partial hand prosthesis, toe prosthesis, below elbow prosthesis or maxillofacial prosthesis. The custom made passive prostheses were fabricated by using silicone material, which is the most preferable material nowadays having biocompatibility properties and most natural appearance [7–9]. The passive custom made

prosthesis was fabricated in the silicone laboratory and fitted to the individual patients. The fabrication processes were the same for all the passive prostheses, but the casting and mould modification differ. The processes of fabrication were casting and measurement, mould modification, wax alignment, die preparation, colour matching, pouring, die compression and finishing of the prosthesis. The overview of the fabrication procedure of finger and hand is shown in **Figure 12**. The passive movements of the finger were achieved by the placement of copper wire inside the silicone during preparation of the die (**Figure 7**). Similar methods were followed in maxillofacial prosthesis. The functionality of finger and hand prosthesis were conducted by DASH questionnaire and Jebson hand function test and found this prosthesis plays the role in enhancement of function though treated as passive prosthesis [6].

1.6. Case studies

1.6.1. Case study 1

The male of 35 years old reported to the clinic having one middle finger amputation of the LT hand. He is professionally an engineer, and the chief complaint was that he had lost his support during the activities like feeding. The stump was good to fit the cosmetic silicone prosthesis with passive function. The copper wire was inserted inside the silicone mixture during the pouring process for the passive movement of the prosthesis. After the fitment of the prosthesis, he can be able to hold the bottle, got support to write and found improvement in activities of daily living (**Figure 13**).

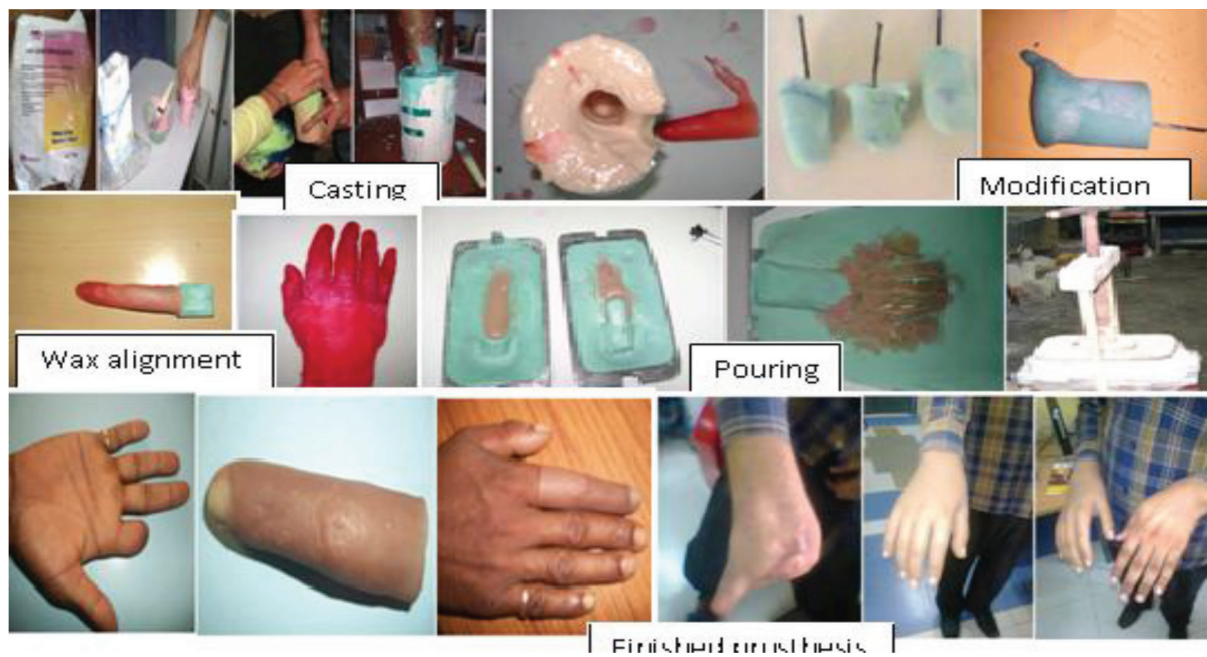

Figure 12. Procedure for fabrication of finger and hand prosthesis.



Figure 13. Patient with middle finger silicone prosthesis doing ADL.

1.6.2. Case study 2

A 12-year-old boy incurred with amputation of right first metacarpophalangeal joint (thumb) secondary to crush injury. He was a boy and a student, so the primary aim of fitting was supported during ADL's activities mainly during writing. The stump of the boy was not enough to fit the regular design with suction suspension. We decided to give him prosthesis with strap suspension. The boy was the donor for the opposite hand, and some changes in the alignment were required during the wax alignment process. For the strap the total cast of the hand was taken, and the area was decided in the hand where the maximum reduction can give to hold the finger in proper position. The prosthesis was fabricated and fitted successfully to get the support and cosmesis as required (**Figure 14**).

1.7. Components of passive cosmetic prosthesis

At present, cosmetic terminal devices consist largely of passive hands and various types of mechanical hands. It is therefore important to remember that cosmesis is attained only through the sacrifice of at least some degree of function. A woman may desire maximum cosmesis, preferring a soft, passive hand with a cosmetic glove, despite the fact that all functions are sacrificed. Different individuals may require different functions, but cosmesis is the priority for most of the users. The cosmetic silicone glove is an option, which can be used by all individuals with different occupations [10].

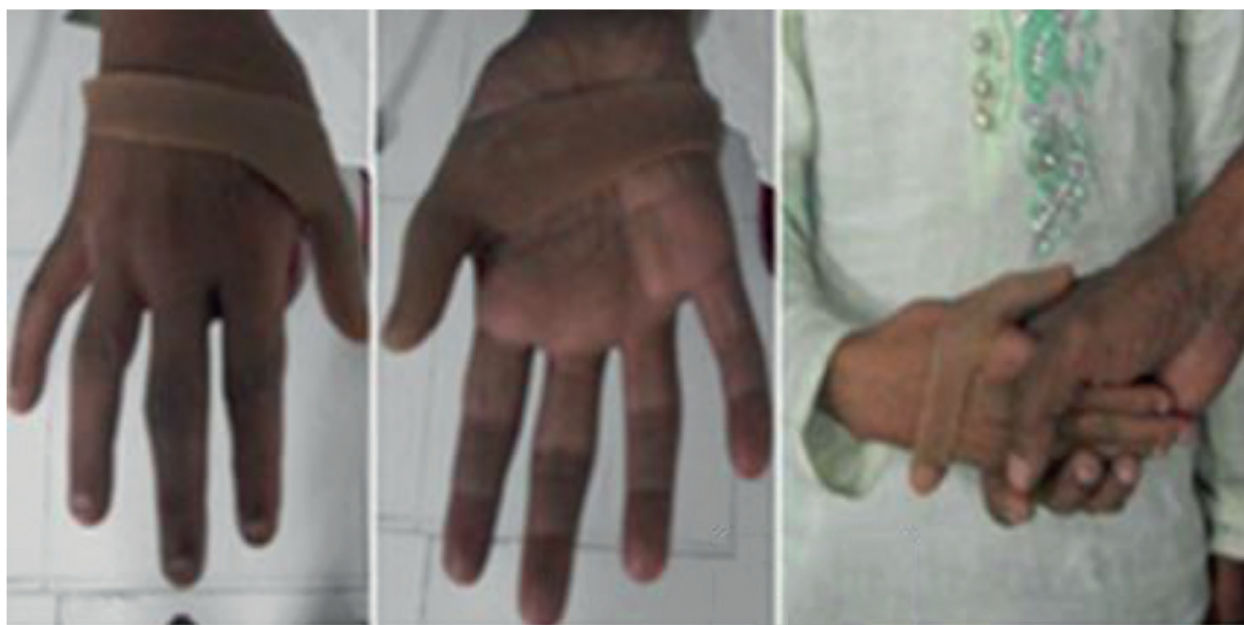

Figure 14. Cosmetic finger with strap suspension.

1.7.1. Cosmetic gloves

The gloves are made of polyvinyl chloride (PVC) plastic or advanced silicone and are made in moulds taken from human hands. As a result, all the structures like fingernails, lines, knuckles and vein prominences have a realistic appearance.

1.7.2. Glove colouring

The cosmetic glove can be of silicone and polyvinyl chloride varieties. The custom made varieties are matched maximum to the natural shape and colour of the body. The artificial hand colour remains unchanged in different climatic conditions. When choosing the colour, match the sound hand while it is hanging and in natural lighting. A colouring kit is used first to tone or “characterize” the colour of the glove. In the case of custom made silicone prosthesis during the time of colour matching, the required colour can be matched with the presence of the patient in midday time, and the colour of the nail can be fabricated by silicone or acrylic. The hair and vein can also be impregnated inside the mixed silicone to maintain the natural appearance of the prosthesis.

1.7.3. Passive hands

Passive hands are made of PVC foam over a flexible steel wire skeleton. The fingers and thumb can be positioned and repositioned by pressing the hand and bending the wire. Cosmetic gloves fit over the passive hands to give a natural looking. The passive hand is lighter than a mechanical hand and looks and feels more like human flesh. The passive hand, however, has no prehension. The passive hand is basically used for limited function in assisting the sound hand. Passive hands are also available without the wrist block; they can then be fitted directly to a socket, a forearm extension or a partial hand amputation.

1.7.4. *Passive lower arms*

Passive prosthesis for lower arm or below elbow amputation can be available in two forms, pre-fabricated or custom made. It is directly covered over the below elbow stump, and its colour is matched up to the expectation level of the amputee.

2. Discussion

The amputation of one or more fingers of the hand, as a consequence of trauma or congenital absence, carries a serious reduction in hand functional in addition to a psychological impairment [11, 12]. Jennifer Methot et al. (2010) studied grip strength in 50 subjects excluding ulnar two digits and found that the ulnar two digits also play a significant role in overall grip strength of the entire hand. Exclusion of the ulnar two digits resulted in a 34–67% decrease in grip strength, with a mean decrease of 55%. Exclusion of the little finger from a functional grip pattern decreased the overall grip strength by 33%. Exclusion of the ring finger from a functional grip pattern decreased the overall grip strength by 21%. It is clear that limitation of one or both of the ulnar digits adversely affects the strength of the hand. Custom made finger prosthesis is aesthetically acceptable and comfortable for use in patients with amputated fingers, resulting in psychological improvement and well-being [3, 4, 13]. The passive finger prosthesis in multiple finger amputation shows a significant improvement in cosmesis and function [12].

Analysis of function is an important component for hand rehabilitation. It assesses the initial limitations for the appropriate management. The hand function is the result of forceful flexion of all finger joints with the maximum voluntary force that the subject is able to exert under normal biokinetic condition. The synergistic action of flexor and extensor muscles and the interplay of muscle groups are important factors in the strength of hand [14].

The amputation of one finger of the hand, as a consequence of trauma, carries a serious reduction in hand function. The index finger plays a vital role in hand function strength [12]. According to Karle et al., the amputation of the proximal phalanx of the index finger found the loss of 17–35% in pinch strength [15]. Custom made finger prosthesis is aesthetically acceptable and comfortable for use in patients with amputated fingers, resulting in psychological improvement and well-being [3].

The functional improvement in partial hand shows after using the custom made silicone hand prosthesis in terms of ADL activities that the passive prosthesis is not only used for the cosmetic purpose but also helping in some passive functions. Pain was reduced markedly due to the compression provided by the prosthesis. Passive finger movement allowed the patient to ride his motorcycle and improved his ability to carry out different activities [6, 16]. The maxillofacial silicone prosthesis enhances the cosmesis and inner confidence of the patients to face the society [17].

Silicone elastomeric materials are more commonly used because they provide better stability and good marginal adaptation, which satisfies patient's cosmetic and aesthetic needs and possesses soft tissue-like consistency, and provide additional advantage when they are used to restore the defects in movable soft tissues [18].

Nowadays, the osseointegration of the ear with outer custom made silicone prosthesis was adopted by the patients though it integrated with the bone so the regular changing of prosthesis can be avoided [19–22]. Passive custom made tracheal prosthesis can be fabricated to provide the chemotherapy. The passive prosthesis plays the important role by providing comfort and cosmesis.

3. Conclusion

Cosmetic silicone prosthesis mimics the natural body structure, gives an aesthetic appearance and provides some passive functions. The cosmetic prosthesis are simple to use with low maintenance cost. The user can easily handle the prosthesis without any complication compared to high jagged prosthesis, but the maximum achievement of function is not possible by these prostheses. Apart from some limitations, these silicone cosmetic prostheses are found the most acceptable prosthesis nowadays and can able to retain the little smile on the face of the patients.

Acknowledgements

I would like to thank the National Institute for the Locomotor Disabilities in Kolkata, India, for providing the material and space for the study and the technical staff who actively participated in fabricating cosmetic prosthesis.

Author details

Smita Nayak^{1*} and Prasanna Lenka²

*Address all correspondence to: smitank7@gmail.com

1 Pt. Deendayal Upadhaya National Institute for the Persons with Physically Disabilities (Divyangjan), New Delhi, India

2 National Institute for the Locomotor Disabilities (Divyangjan), Kolkata, India

References

- [1] Wilson AB Jr. History of amputation surgery and prosthetics. In: Bowker JH, Michael JW editors. *Atlas of Limb Prosthetics: Surgical, Prosthetic, and Rehabilitation Principles*. 2nd ed. Rosemont, IL: American Academy of Orthopedic Surgeons; 2002. pp 3-15. (Originally published by Mosby- Year Book, 1992.)
- [2] Taylor TD. *Facial Prosthesis Fabrication Technical Aspects Clinical Maxillofacial Prosthesis*. Chicago: Quintessence Publishing Company; 2000. p. 233

- [3] Tripathi S, Singh DR, Chand P, Mishra N, Yadav LK, Singh V. A modified approach of impression technique for fabrication of finger prostheses. *Prosthetics and Orthotics International*. 2011;**36**(1):121-124
- [4] Leow MEL, Pho RWH, Pereira BP. Esthetic prostheses in minor and major upper limb amputations. *Hand Clinics*. 2001;**17**:489-497
- [5] Nayak S. Hand Book of Silicone Prosthesis. In: Editions Universitaires Europeennes 2017. pp. 4-5 ISBN: 978-3-639-56067-1
- [6] Nayak S, Lenka PK, Equebal A, Biswas A. Custom-made silicone hand prosthesis: A case study. *Hand Surgery and Rehabilitation*. 2016;**35**:299-303
- [7] Pillet J. Esthetic hand prostheses. *Journal of Hand Surgery*. 1983;**8**:778-781
- [8] Beasley RW. Hand and finger prostheses. *Journal of Hand Surgery*. 1987;**12A**:144-147
- [9] Campbell GS, Gow D, Hooper G. Low cost cosmetic hand prostheses. *Journal of Hand Surgery*. 1992;**17B**:201-203
- [10] Chapter 9 Cosmetic components. Retrieved Feb 20 2017. Available from www.cpousa.com/prosthetics/upper-extremity.
- [11] Cervelli V, Bottini DJ, Arpino A, Grimaldi M, Rogliani M, Gentile P. Bone anchored implant in cosmetic finger reconstruction. *Annales de chirurgie plastique esthetique*. 2008;**53**:365-367
- [12] Lifchez Scott D, Marchant-Hanson J, Matloub Hani S, Sanger James R, Dzwierzynski William W, Nguyen. Functional improvement with digital prosthesis use after multiple digit amputation. *Journal of Hand Surgery*. 2005 July;**30**(4):790-794
- [13] Leow MEL, Ow RKK, Lee MH, Huak CY, Pho RWH. Assessment of color differences in silicone hand and digit prostheses: Perceptible and acceptable thresholds for fair and dark skin shades. *Prosthetics and Orthotics International*. 2006 April;**30**(1):5-16
- [14] Radmin RG, Seoungyeon OH, Jenson TR, Webster JG. External finger forces in submaximal five finger static pinch Prehension. *Ergonomics*. 1992;**35**(3):275-288
- [15] Karle B, Wittemann M, Germann G. Functional outcome and quality of life after ray amputation versus amputation through the proximal phalanx of the index finger. *Handchir Mikrochir Plast chir*. 2002;**34**(1):30-35
- [16] Phillips SL, Harris MS, Latlief G. Experiences and outcomes with powered partial hand prostheses: A case series of subjects with multiple limb amputations. *Journal of Prosthetics and Orthotics*. 2012;**24**:93-97
- [17] Gunay MEBGBKY. Facilitation of facial prosthesis placement with tattoo markers: A clinical report. *Journal of Prosthetic Dentistry*. 2007;**97**:265-260
- [18] W. M. J. R. Aziza T. Analysis of the properties of silicone rubber maxillofacial prosthetic materials. *Journal of Dentistry*. 2003;**31**:67-74
- [19] Wang S, Leng X, Zheng Y, Zhang D, Wu G. Prosthesis-guided implant restoration of an auricular defect using computed tomography and 3-dimensional photographic imaging

technologies: A clinical report. *Journal of Prosthetic Dentistry*. 2014; pii: S0022-3913(14)00425-9. DOI: 10.1016/j.prosdent.2014.08.014

- [20] Hatamleh MM, Watson J. Construction of an implant-retained auricular prosthesis with the aid of contemporary digital technologies clinical report. *Journal of Prosthodontics*. 2013;**22**(2):132-136
- [21] Kumar PS, Satheesh Kumar KS, Savadi RC. Bilateral implant-retained auricular prosthesis for a patient with congenitally missing ears A clinical report. *Journal of Prosthodontics*. 2012;**21**(2):322-327
- [22] Todd JDA, Kubon M. An implant-retained auricular impression technique to minimize soft tissue. *Journal of Prosthetic Dentistry*. 2003;**89**:97-101