

# We are IntechOpen, the world's leading publisher of Open Access books Built by scientists, for scientists

6,900

Open access books available

186,000

International authors and editors

200M

Downloads

Our authors are among the

154

Countries delivered to

TOP 1%

most cited scientists

12.2%

Contributors from top 500 universities



WEB OF SCIENCE™

Selection of our books indexed in the Book Citation Index  
in Web of Science™ Core Collection (BKCI)

Interested in publishing with us?  
Contact [book.department@intechopen.com](mailto:book.department@intechopen.com)

Numbers displayed above are based on latest data collected.  
For more information visit [www.intechopen.com](http://www.intechopen.com)



---

# Dermatitis Herpetiformis

---

Salih Levent Cinar, Demet Kartal and Murat Borlu

Additional information is available at the end of the chapter

<http://dx.doi.org/10.5772/intechopen.71938>

---

## Abstract

Dermatitis herpetiformis is an autoimmune skin disease, which is strongly related to coeliac disease. Moreover, some authors accept it as the skin manifestation of coeliac disease. It is a chronic, recurrent disease with polymorphic skin eruptions and pruritus. Dermatitis herpetiformis is a disease of the young adults mostly, but can be seen at any age. It is characterized by papules, vesicles, excoriations, and urticarial plaques clinically. Histopathological examination reveals subepidermal separation, and with this finding, it needs to be differentiated from linear IgA bullous dermatitis and bullous pemphigoid. In this case, direct immunofluorescence is helpful. Granular deposition of IgA is pathognomonic for dermatitis herpetiformis. Dermatitis herpetiformis can accompany other autoimmune disorders such as type I diabetes mellitus, thyroid diseases, vitiligo, and collagen tissue diseases. Dermatitis herpetiformis is, usually, successfully treated with dapsone and gluten-free diet.

**Keywords:** autoimmune, dapsone, gluten, immunofluorescence, polymorphic eruption

---

## 1. Introduction

Autoimmune bullous diseases constitute one of the main groups of dermatological diseases. One of these bullous disorders is dermatitis herpetiformis (DH). Dermatitis herpetiformis is a chronic, recurring, autoimmune, inflammatory skin disease, which is characterized by pruritic polymorphic lesions [1].

DH was first coined by the dermatologist, Louis Duhring, in 1884. Later, in 1888, Brocq identified a similar skin disease “polymorphic pruritic dermatitis.” That is why, the disease is also named as Duhring-Brocq’s disease or mostly Duhring’s disease [2].

DH and celiac disease (CD) are two entities that are strongly related. Moreover, there are evidences that claim that DH is the cutaneous manifestation of CD, because both diseases are

seen in gluten-sensitive persons and share similar HLA haplotypes such as DQ2 and DQ8 [3]. Today, we know that gastrointestinal symptoms in DH are generally mild or absent. We also know that only 24% of the CD patients have skin lesions resembling DH [4]. Based on these, we can consider these two diseases as different entities that are closely related.

DH is mostly reported in Caucasians although it is being increasingly reported in the Japanese population [5, 6]. Its incidence is reported to be 11.5–75.3/100,000 in different countries [7, 8]. The disease is rare in the Far East and even rarer in Afro-Americans [9]. DH mostly affects individuals in the third or fourth decades, but patients of any age between 2 and 90 have been reported so far. For example, in Italy, there are many pediatric DH patients [10]. In the adult population, males are more commonly affected, whereas female-to-male ratio ranges from 2:1 to 4:1 in children [11].

## 2. Pathogenesis

The pathogenesis of DH is a complex process in which autoimmune factors, genetics, HLA predisposition, and environmental factors take part [12]. In a study of monozygotic twins, the concordance rate of the disease was found to be 0.91, which was higher than expected [13]. In two other studies, 10 and 19% of the DH patients had a first-degree relative with a diagnosis of DH [14, 15].

One possible gene associated with CD and DH is myosin 9B (MYO9B) on chromosome 9p13 [16, 17]. MYO9B regulates actin cytoskeleton functions, cell integrity, and gut barrier permeability. Increased permeability of the gastrointestinal barrier may allow more gluten penetration, and as a result, immunological processes start in CD and DH [18].

In DH, close relationship with some HLA loci has also been reported. Close association between DH and HLA-DQ2/HLA-DQ8 has been emphasized. In a study of 50 patients, 86% had HLA-DQ2 allele and the rest HLA-DQ8 allele [19].

Tissue transglutaminase (tTG) is a cytoplasmic, calcium-dependent enzyme and is the major autoantigen for CD [20]. It stabilizes the cytoskeleton and the extracellular matrix by protein polymerization. As a result, it regulates the cell matrix adhesion, cell migration, and proliferation [21, 22]. tTG is also found in the skin, dermal capillaries, and basal keratinocytes [23]. tTG acts on the alcohol-soluble part of gluten, which is the gliadin, and transforms it to an autoantigen, which has an affinity for HLA-DQ2 on antigen-presenting cells. As a result, T cells are stimulated and an inflammatory cascade starts [21, 24, 25]. In addition, tTG-gliadin complexes are formed and these complexes generate a robust autoantibody response [21, 24, 25]. This continuous inflammation causes villous atrophy and intestinal damage.

The autoantibodies in DH and CD are mostly of IgA type. Sometimes, IgG can also be seen and is important in IgA deficiency [26]. The characteristic finding of DH is the deposition of IgA in the tips of dermal papillae and along the basal membrane in a granular manner. This accumulation can be seen on direct immunofluorescence of the perilesional skin [27–29]. The IgA deposits trigger an inflammatory reaction, which results in neutrophilic deposition and vesicle formation [30].

In DH, epidermal transglutaminase (eTG) seems to be the main autoantigen rather than tTG. eTG colocalizes with IgA [27–30]. The role of eTG in the skin is the cross-linking and the maintenance of cornified envelope integrity [31, 32]. eTG is expressed in dermis, small intestine, brain, and testes. Individuals with DH have IgA antibodies specific for eTG and sometimes for tTG [29]. Blood levels of IgA-type anti-eTG antibodies are more sensitive than IgA-type anti-tTG antibodies, identifying DH [33, 34]. One recent study showed that only half of the DH patients were positive for IgA anti-eTG, claiming that other possible factors take part in the pathogenesis of the disease [27]. It was shown that skin deposits of IgA immune complexes disappear with gluten-free diet (GFD) and reappear with rechallenge supporting the effect of gluten in the pathogenesis of DH [35].

Lifestyle was also shown to affect the disease activity. For example, iodine use or iodine-rich foods (such as shellfish) cause flare of DH [36]. Triiodomethane that is used during dental procedures may also cause exacerbation of the disease [37]. In two studies, it was claimed that tobacco had protective effects in CD patients similar to that observed in ulcerative colitis. But the mechanism is unclear and is not shown in DH patients [38, 39].

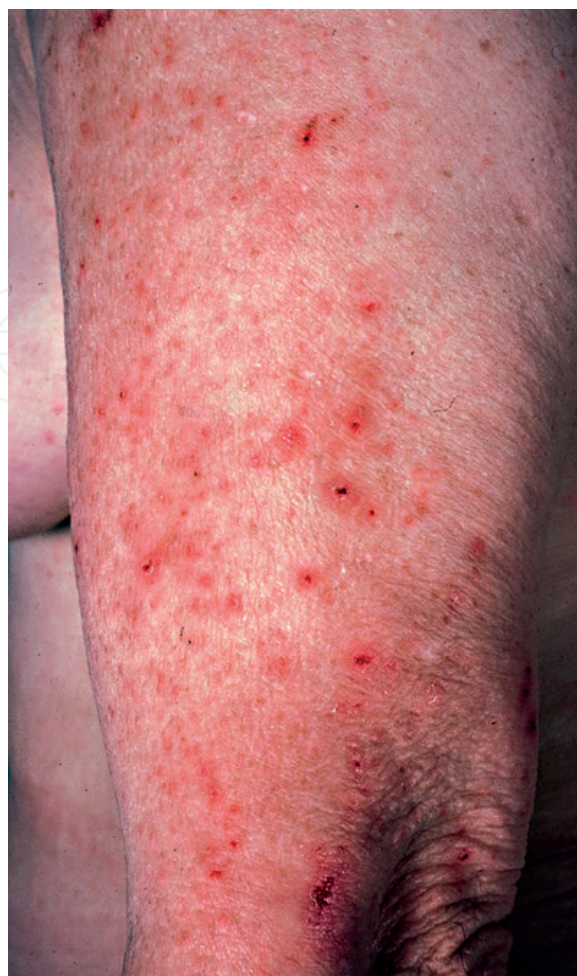### 3. Clinical findings

DH is characterized by polymorphic lesions such as 1–3 mm papules, vesicles, small blisters, erosions, crusts, excoriations, and secondary infections [40]. Sometimes, urticarial plaques, lichenification secondary to scratching, and purpura of the fingers and toes can also be present [41, 42]. Due to scratching, representative lesions are mostly missing and all the physician sees is excoriations. In DH, the lesions are mostly seen in the extensor aspects of the body such as the anterior thigh, elbows, knees, buttocks, shoulders, sacral region, scalp, fingers, and toes. Oral mucosa is mostly spared [43]. The lesions, if not secondarily infected, heal without scar formation but with postinflammatory hyperpigmentation. In mild disease, symptomatic and disease-free periods alternate, whereas in severe disease, the symptoms are continuous with variable severity [42]. **Figure 1** demonstrates polymorphic eruption consisting of excoriated papules and erosions.

Palmoplantar purpura, which is an uncommon manifestation of DH, is mostly reported in pediatric patients. Petechiae are seen on the soles and palms sparing the dorsal surfaces. Interestingly, the dominant hands are affected more commonly suggesting that trauma can be the causative agent [44, 45]. There are also few individuals with DH, manifesting with leukocytoclastic vasculitis-like appearance, urticarial wheals, palmoplantar keratosis, and prurigo pigmentosa [46–49].

Mucosal involvement is rare in individuals with DH. Most mucosal lesions lack confirmation with direct immunofluorescence studies. These mucosal lesions are mostly thought to appear due to DH-related conditions such as CD or other autoimmune connective tissue disorders [50].

Dental abnormalities have also been reported in individuals with DH and CD. Enamel defects in permanent teeth, horizontal grooves, defects in enamel color, and enamel pits are the most commonly reported dental findings [51–53].



**Figure 1.** Excoriated papules and eroded vesicles in a patient with DH.

Only 20% of the DH patients develop gastrointestinal symptoms. These symptoms include diarrhea, anemia due to malabsorption, steatorrhea, weight loss, and malnutrition [54].

In children with DH, short stature and delayed puberty and development can be observed [55].

#### **4. Dermatitis herpetiformis–associated disorders**

DH is an autoimmune disorder and we know that different types of autoimmune disorders can coexist. Thyroid abnormalities may accompany DH. Thyroid microsomal antibodies are positive in these patients [56–58]. Thyroid involvement is mostly in the form of hypothyroidism rather than hyperthyroidism [56]. Individuals with DH have a higher risk of type I diabetes mellitus with a prevalence of 2–5% [59, 60]. Pernicious anemia, Addison's disease, vitiligo, and alopecia areata are other autoimmune diseases that are reported to coexist with DH [61–63].

Autoimmune connective tissue diseases, such as rheumatoid arthritis, systemic lupus erythematosus, and Sjogren's syndrome are also commonly seen in DH patients [60, 64]. **Table 1** summarizes the autoimmune disorders that may accompany DH.



- Hashimoto's thyroiditis
- Type I diabetes mellitus
- Pernicious anemia
- Addison's disease
- Alopecia areata
- Sarcoidosis
- Scleroderma
- Sjogren's disease
- Vitiligo
- Systemic lupus erythematosus
- Myasthenia gravis

**Table 1.** Autoimmune diseases associated with dermatitis herpetiformis.

Gjone and Nordoy, in 1970, reported for the first time that individuals with DH had a higher risk of lymphoma [65]. Some other studies also reported such relationship later on [4, 66–69]. First-degree relatives of the patients with DH are believed not to have a higher risk of lymphoma, on the contrary to CD [66, 70]. There are fewer studies asserting the contrary. Lewis et al. in 2008 reported no increased risk of morbidity or mortality in DH patients [71].

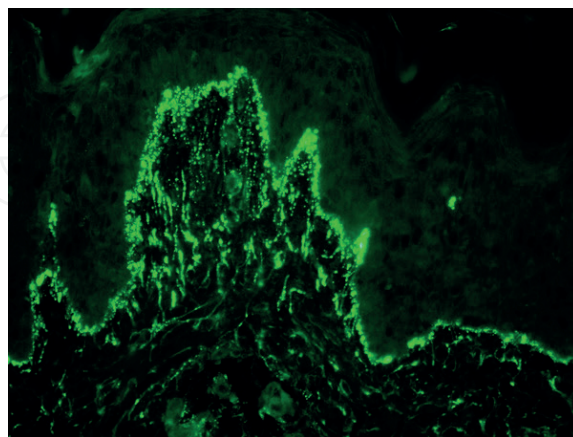
## 5. Diagnosis

Early diagnosis of DH is essential to relieve the patient. In consequence to understanding the pathogenesis of the disease, numerous serologic tests were developed. The proper diagnosis of DH is made with the evaluation of physical examination, immunofluorescence studies, routine histopathological examination, and the serology [3].

An ideal dermatological examination starts with inspection. Suspicious lesions, mostly excoriations, are commonly distributed on extensor aspects of the body. An intact vesicle, if visible, is the most specific diagnostic lesion. The patients mostly complain of itching that exacerbates during night, which may also be helpful in the diagnosis.

Routine histopathological examination must be performed with a specimen that contains an intact vesicle if possible [72]. Diagnostic findings are subepidermal clefts and neutrophilic infiltration at the tip of the dermal papillae. Sometimes, a few eosinophils can also be seen. These abscesses formed by neutrophils and eosinophils are called Pierard microabscess [73]. A perivascular mixed inflammation is usually present [65]. The histopathology of LABD, bullous pemphigoid, and bullous lupus erythematosus can resemble such features. Immunofluorescence studies help us to differentiate these similar entities [74]. In DH, granular IgA deposition at the tips of dermal papillae is pathognomonic. In LABD, linear deposition of IgA is observed. Sometimes, in less than 5% of the patients, the granular IgA deposits in DH along the basement membrane can be evaluated as linear by mistake [3]. In Japanese patients, IgA deposition in a fibrillary pattern can also be seen [75]. The immunological deposits are not affected after pharmacological therapy. Instead, the deposits diminish on a gluten-free diet (GFD) [76]. It must be kept in mind that IgA deposition is best seen in normal-appearing perilesional skin rather than in the lesional skin [77]. Warren et al. reported that in 35–40% of the individuals with

DH, the histopathological findings are not demonstrative enough, i.e. sometimes the only finding is the perivascular lymphocytic infiltrate and/or slight dermal papillary inflammation [78]. Sometimes, apart from IgA, deposition of granular IgM and C3 at the dermoepidermal junction can also be present [79]. In **Figure 2**, typical deposition of granular IgA is demonstrated.



**Figure 2.** Granular IgA deposits at the tips of the dermal papillae.

Histopathological examination of the intestine is not a must for the diagnosis of DH. But it is a known fact that even in DH patients without gastrointestinal symptoms, the inflammatory changes are present in the small bowel [80].

Serological tests are used in conjunction with pathology and immunopathology. Circulating IgA-type antibodies against endomysium are detected in both DH and CD. Endomysium is the loose connective tissue surrounding muscle fibers. This test is based on indirect immunofluorescence with monkey esophagus as the substrate [81]. IgA-type anti-tTG testing has high specificity and sensitivity and can be used to differentiate DH from LABD, in case of necessity, showing the mucosal damage [82]. Anti-eTG testing has high sensitivity and even higher specificity in diagnosis of DH. Both the levels of anti-tTG and anti-eTG reflect the level of intestinal damage. Any individual on a strict GFD shows low levels of antiendomysial, anti-tTG, and anti-eTG antibodies. Based on this, these antibodies can be used to evaluate the adherence to GFD [65]. In CD, selective IgA deficiency is seldom seen, which causes a possible delay in the diagnosis of the disease. But this is not the case for DH, i.e. IgA deficiency is not common in DH [83]. Antibodies such as antigliadin, antireticulina, antineoepitope tTG, and anti-GAF3X are also found in DH [84–86].

In individuals with DH, D-xylose absorption test is deteriorated in 10–33% of the cases. Iron deficiency anemia and megaloblastic anemia can also help to diagnose in suspicious cases [87].

Genetic testing also can be used when needed for a proper diagnosis. The absence of HLA-DQ2 and HLA-DQ8 alleles, mostly, gives the idea that the individual is unlikely to have DH. But the positivity of these alleles does not always mean that the patient has DH, because these alleles can be positive in normal population frequently [74].

Antiga and Caproni proposed a diagnostic algorithm in DH. According to this algorithm, in case of typical DIF findings and anti-tTG positivity, the diagnosis is certain. In a case with

typical DIF findings but anti-tTG negativity, HLA testing is suggested. If HLA-DQ2 and HLA-DQ8 are negative, DH is excluded. If the alleles are positive, other mentioned antibodies can be checked and intestinal biopsy can be performed. In case of DIF negativity and anti-tTG positivity, HLA testing is recommended. If negative, DH can be excluded, but if positive, a new biopsy for immunofluorescence is recommended. In individuals who are negative for both DIF and anti-tTG, DH can be excluded [1].

## 6. Differential diagnosis

DH should be differentiated from other bullous skin disorders (such as linear IgA bullous dermatitis and bullous pemphigoid), urticaria, atopic dermatitis, nummular dermatitis, contact dermatitis, and scabies. Linear IgA bullous dermatitis (LABD) has clinical features similar to DH. Larger bullae and “crown of jewels” appearance of the lesions are characteristics of LABD. “Linear” versus “granular” deposition on direct immunofluorescence is the best way to differentiate these two entities. An oil preparation will help to distinguish scabies from DH. Histopathological examination will help to rule out the other dermatoses. **Table 2** summarizes the differential diagnostic features of DH, LABD, and bullous pemphigoid.

	DH	LABD	BP
Lesion appearance	Excoriated papules, vesicles that coalesce	Small vesicles and/or large bullae	Tense bullae
Distribution	Extensor and symmetrical	Extensor and symmetrical	Trunk, extremities
Histopathology	Subepidermal bullae, neutrophils	Subepidermal bullae, neutrophils	Subepidermal bullae, sometimes eosinophils
Direct IF	Granular IgA in dermal papillae	Linear IgA at basement membrane	Linear IgG and C3 at basement membrane
Indirect IF	Mostly (–)	Linear IgA at BMZ	Linear IgG at BMZ
GIS involvement	>90%	Mostly (–)	(–)
Response to dapsone	Excellent	Good	Minimal

**Table 2.** Differential diagnostic features of DH (dermatitis herpetiformis), LABD (linear IgA bullous dermatitis), and BP (bullous pemphigoid).

## 7. Treatment

Gluten-free diet (GFD) is a must in the treatment of DH [88]. With GFD, not only the skin lesions resolve but also the pathological findings in intestine improve [89]. The IgA deposits disappear slowly and several years may be necessary for complete resolution. Ingestion of gluten leads to immediate deposition of IgA in the skin and polymorphic eruption arises thereafter [90]. It is tough to stick to GFD. Thus, consultation with a dietician may be necessary and



helpful. Cereals (wheat, barley, and rye) and products containing cereals are rich in gluten [23]. GFD also decreases the malabsorption associated with gluten intolerance. GFD is also thought to minimize the risk of lymphoma, which is believed to be caused by continuous antigenic stimulation [91]. On GFD, gastrointestinal symptoms respond first; later on, the skin lesions respond. In the absence of an additional pharmacological therapy, it may take several years for the cutaneous lesions to disappear [65].

There are few studies that showed cases of DH refractory to GFD. In 2016, Hervonen et al. reported 7 cases out of 403 (1.7%) who were refractory to GFD [92]. In another study, this ratio was nearly 7% [88].

In terms of pharmacotherapy, sulfones like dapsone and sulfapyridine, are accepted as golden standard. These drugs suppress the cutaneous disease immediately [93, 94]. Dapsone is an anti-inflammatory and antibacterial drug which, downregulates neutrophil chemotaxis. As a result, tissue damage, triggered by neutrophils and eosinophils, is inhibited [95, 96]. Skin manifestations are relieved in a few days after dapsone initiation [97]. Usually 25–200 mg/day of dapsone is necessary to control the disease. It has been shown that dapsone alone does not improve the gastrointestinal disease. Therefore, combination of dapsone and GFD is considered as the mainstay of the treatment of DH. Some authors claim that upon strict GFD the dosage of dapsone can be lowered in time and even can be discontinued and restarted in times of flares [98].

The possible side effects of dapsone are well known. Some of the known side effects are the hematological ones such as methemoglobinemia [99]. Methemoglobinemia causes insufficient oxygen to the tissues and manifests by cyanosis, grayish-blue color, weakness, nausea, tachycardia, and abdominal pain [54]. Close follow-up is necessary to rule out this side effect, especially at the beginning of the therapy. To decrease the possibility of methemoglobinemia, cimetidine and/or vitamin E supplement can be prescribed [50]. Patients with glucose-6-phosphate dehydrogenase (G6PD) are more likely to develop hemolysis [100]. The dosage of dapsone must be lowered in these patients. Agranulocytosis is a rare but serious complication and is almost always seen at the beginning of the therapy [101]. Systemic drug hypersensitivity syndrome is another side effect of dapsone treatment, which must also be kept in mind [102]. The sulfone syndrome is seen in the first 2 months of the treatment. Exfoliative dermatitis, fever, lymphadenopathy, hepatitis, vomiting, and hemolysis are independent from the dosage [103, 104]. **Table 3** summarizes the possible side effects of dapsone.

Sulfapyridine, which is the metabolite of both sulfasalazine and sulfamethoxypyridazine, is another therapeutic option in the treatment of DH. The mechanism of action is similar to that of dapsone [105].

Systemic steroids are usually reported to be useless in the treatment of DH [92]. In some instances, potent topical steroids can be used to relieve pruritus [106]. Topical steroids must be used during the acute stage together with the above-mentioned systemic agents.

Tetracycline and nicotinamide combination, colchicine, heparin, and cyclosporine are reported to be effective in the treatment of DH. But there are mostly limited case reports about these treatment options and they need further, large studies [107–109]. Sacchidanand, in 2003, reported good results in DH patients with dexamethasone-cyclophosphamide pulse therapy [110]. Topical dapsone, mycophenolate, and rituximab have also been used for the treatment of DH with variable results [111, 112].

Adverse effects of dapsone	
Blood abnormality	Hemolytic anemia
	Methemoglobinemia
	Agranulocytosis
	Leukopenia
Gastrointestinal side effects	Nausea
	Hepatitis
	Cholestasis
	Hypoalbuminemia
Neurological side effects	Headache
	Peripheral neuropathy
	Dizziness
	Insomnia
	Psychosis
Cutaneous reactions	Maculopapular eruption
	Urticarial reaction
	Fixed drug eruption
	Erythrodermia
	Stevens-Johnson syndrome
	Phototoxicity
	Drug-induced lupus erythematosus
Dapsone hypersensitivity	Hepatitis
	Fatigue
	Anorexia
	Lymphadenopathy

**Table 3.** The side effects of dapsone.

DH has a chronic nature with remissions and flares. That is why close consultation, long-term GFD, and pharmacological treatment are necessary. In the course of the disease, regular screening for other autoimmune diseases and neoplastic conditions is generally recommended. Blood samples should be taken, at regular intervals, to monitor the possible side effects of the drugs. Anti-tTG and anti-eTG IgA levels can be used to evaluate the adherence of the patients to GFD.

Spontaneous remissions that last months or years are rarely reported. A spontaneous remission is mentioned when there are no lesions for at least 6 months without adherence to GFD [42].

## 8. Childhood dermatitis herpetiformis

DH, in childhood, resembles the disease of the adulthood with some exceptional features. DH is most commonly seen between the ages of 2 and 7. Girls and boys are equally affected [113]. DH in childhood has an insidious course. It has a long period of pruritus, which is lesion free. The lesions are usually scattered in an asymmetric manner in contrast to adulthood form, which tends to coalesce [114]. Facial lesions are more common in childhood. Palmar linear petechiae and bullae are mostly seen in the childhood form. Chronic urticarial lesions, chronic dermatitis, and hemorrhagic bullae can accompany the classical lesions [48]. Aforementioned enamel defects, oral erosions, and chronic diarrhea can also be seen in the affected children [52, 53, 115].

Interestingly, children with DH can respond to topical steroid treatment initially. This response, at the beginning, diminishes in time [116]. Dapsone is the golden standard in terms of treatment. About 2 mg/kg/day is generally enough to control the disease. The response starts in 72 hours. After satisfactory response, the dosage can be lowered. The second choice is sulfapyridine at a dose of 35–70 mg/kg/day [96].

## 9. Conclusion

Dermatitis herpetiformis, when undiagnosed, is a distracting disease for the patient with its chronic nature and the itching. In case of a polymorphic eruption and pruritus, DH must come to mind. After proper history taking, physical examination, and laboratory investigations, its diagnosis is, mostly, easy. GFD and dapsone ensure an untroubled life for the patient. But we should, always, be aware of the possible side effects of the therapy.

## Author details

Salih Levent Cinar\*, Demet Kartal and Murat Borlu

\*Address all correspondence to: sleventcinar@yahoo.com

Dermatology and Venereology Department, Erciyes University Faculty of Medicine, Kayseri, Turkey

## References

- [1] Antiga E, Caproni M. The diagnosis and treatment of dermatitis herpetiformis. *Clinical, Cosmetic and Investigational Dermatology*. 2015;**13**(8):257-265. DOI: 10.2147/CCID.S69127

- [2] Mendes FBR, Hissa-Elia A, de Abreu MAMM, Gonçalves VS. Review: Dermatitis herpetiformis. *Anais Brasileiros de Dermatologia*. 2013;**88**(4):594-599. DOI: 10.1590/abd1806-4841.20131775
- [3] Caproni M, Antiga E, Melani L, Fabbri P, Italian Group for Cutaneous Immunopathology. Guidelines for the diagnosis and treatment of dermatitis herpetiformis. *Journal of the European Academy of Dermatology and Venereology*. 2009;**23**(6):633-638. DOI: 10.1111/j.1468-3083.2009.03188.x
- [4] Collin P, Reunala T, Rasmussen M, Kyronpalo S, Pehkonen E, et al. High incidence and prevalence of adult coeliac disease. Augmented diagnostic approach. *Scandinavian Journal of Gastroenterology*. 1997;**32**(11):1129-1133. DOI: 10.3109/00365529709002992
- [5] Fry L. Dermatitis herpetiformis. *Baillière's Clinical Gastroenterology*. 1995;**9**(2):371-393. DOI: 10.1016/0950-3528(95)90036-5
- [6] Ohata C, Ishii N, Hamada T, Shimomura Y, Niizeki H, et al. Distinct characteristics in Japanese dermatitis herpetiformis: A review of all 91 Japanese patients over the last 35 years. *Clinical & Developmental Immunology*. 2012;**2012**:1-9. DOI: 10.1155/2012/562168
- [7] Salmi TT, Hervonen K, Kautiainen H, Collin P, Reunala T. Prevalence and incidence of dermatitis herpetiformis: A 40-year prospective study from Finland. *The British Journal of Dermatology*. 2011;**165**(2):354-359. DOI: 10.1111/j.1365-2133.2011.10385.x
- [8] Gawkrödger DJ, Vestey JP, O'Mahony S, Marks JM. Dermatitis herpetiformis and established coeliac disease. *The British Journal of Dermatology*. 1993;**129**(6):694-695. DOI: 10.1111/j.1365-2133.1993.tb03333.x
- [9] Shibahara M, Nanko H, Shimizu M, Kanda N, Kubo M, et al. Dermatitis herpetiformis in Japan: An update. *Dermatology*. 2002;**204**(1):37-42. DOI: 10.1159/000051808
- [10] Antiga E, Verdelli A, Calabrò A, Fabbri P, Caproni M. Clinical and immunopathological features of 159 patients with dermatitis herpetiformis: An Italian experience. *Giornale Italiano di Dermatologia e Venereologia*. 2013;**148**(2):163-169. DOI: 10.2147/CCID.S69127
- [11] Llorente-Alonso MJ, Fernández-Acenero MJ, Sebastián M. Gluten intolerance: Sex and age-related features. *Canadian Journal of Gastroenterology*. 2006;**20**(11):719-722
- [12] Bolotin D, Petronic-Rosic V. Dermatitis herpetiformis. *Journal of the American Academy of Dermatology*. 2011;**64**(6):1017-1024. DOI: 10.1016/j.jaad.2010.09.777
- [13] Hervonen K, Karell K, Holopainen P, Collin P, Partanen J, et al. Concordance of dermatitis herpetiformis and coeliac disease in monozygous twins. *The Journal of Investigative Dermatology*. 2000;**115**(6):990-993. DOI: 10.1046/j.1523-1747.2000.00172.x
- [14] Hervonen K, Hakanen M, Kaukinen K, Collin P, Reunala T. First-degree relatives are frequently affected in coeliac disease and dermatitis herpetiformis. *Scandinavian Journal of Gastroenterology*. 2002;**37**(1):51-55. DOI: 10.1080/003655202753387356

- [15] Alonso-Llamazares J, Gibson LE, Rogers RS. Clinical, pathologic, and immunopathologic features of dermatitis herpetiformis: Review of the Mayo Clinic experience. *International Journal of Dermatology*. 2007;**46**(9):910-919. DOI: 10.1111/j.1365-4632.2007.03214.x
- [16] Amundsen SS, Monsuur AJ, Wapenaar MC, Lie BA, Ek J, et al. Association analysis of MYO9B gene polymorphisms with celiac disease in a Swedish/Norwegian cohort. *Human Immunology*. 2006;**67**(4-5):341-345. DOI: 10.1016/j.humimm.2006.03.020
- [17] Koskinen LLE, Korponay-Szabo IR, Viiri K, Juuti-Uusitalo K, Kaukinen K, et al. Myosin IXB gene region and gluten intolerance: Linkage to coeliac disease and a putative dermatitis herpetiformis association. *Journal of Medical Genetics*. 2007;**45**(4):222-227. DOI: 10.1136/jmg.2007.053991
- [18] Hunt KA, Monsuur AJ, McArdle WL, Kumar PJ, Travis SP, et al. Lack of association of MYO9B genetic variants with coeliac disease in a British cohort. *Gut*. 2006;**55**(7):969-972. DOI: 10.1136/gut.2005.086769
- [19] Spurkland A, Ingvarsson G, Falk ES, Knutsen I, Sollid LM, et al. Dermatitis herpetiformis and celiac disease are both primarily associated with the HLA-DQ (alpha 1\*0501, beta 1\*02) or the HLA-DQ (alpha 1\*03, beta 1\*0302) heterodimers. *Tissue Antigens*. 1997;**49**(1):29-34. DOI: 10.1111/j.1399-0039.1997.tb02706.x
- [20] Dieterich W, Ehnis T, Bauer M, Donner P, Volta U, et al. Identification of tissue transglutaminase as the autoantigen of celiac disease. *Nature Medicine*. 1997;**3**(7):797-801. DOI: 10.1038/nm0797-797
- [21] Caputo I, Barone MV, Martucciello S, Lepretti M, Esposito C. Tissue transglutaminase in celiac disease: Role of autoantibodies. *Amino Acids*. 2009;**36**(4):693-699. DOI: 10.1007/s00726-008-0120-z
- [22] Schuppan D, Dieterich W, Ehnis T, Bauer M, Donner P, et al. Identification of the autoantigen of celiac disease. *Annals of the New York Academy of Sciences*. 1998;**859**:121-126. DOI: 10.1053/gast.2000.8521
- [23] Kárpáti S. Dermatitis herpetiformis: Close to unravelling a disease. *Journal of Dermatological Science*. 2004;**34**(2):83-90. DOI: 10.1016/j.jdermsci.2003.11.004
- [24] Anderson RP, Degano P, Godkin AJ, Jewell DP, Hill AVS. In vivo antigen challenge in celiac disease identifies a single transglutaminase-modified peptide as the dominant A-gliadin T-cell epitope. *Nature Medicine*. 2000;**6**(3):337-342. DOI: 10.1038/73200
- [25] Molberg O, Mcadam SN, Körner R, Quarsten H, Kristiansen C, et al. Tissue transglutaminase selectively modifies gliadin peptides that are recognized by gut-derived T cells in celiac disease. *Nature Medicine*. 1998;**4**(6):713-717
- [26] Zone JJ, Egan CA, Taylor TB, Meyer LJ. IgA autoimmune disorders: Development of a passive transfer mouse model. *The Journal of Investigative Dermatology. Symposium Proceedings*. 2004;**9**(1):47-51. DOI: 10.1111/j.1087-0024.2004.00840.x



- [27] Hull CM, Liddle M, Hansen N, Meyer LJ, Schmidt L, et al. Elevation of IgA anti-epidermal transglutaminase antibodies in dermatitis herpetiformis. *The British Journal of Dermatology*. 2008;**159**(1):120-124. DOI: 10.1111/j.1365-2133.2008.08629.x
- [28] Kawana S, Segawa A. Confocal laser scanning microscopic and immunoelectron microscopic studies of the anatomical distribution of fibrillar IgA deposits in dermatitis herpetiformis. *Archives of Dermatology*. 1993;**129**(4):456-459. DOI: 10.1001/archderm.1993.01680250068008
- [29] Sárdy M, Kárpáti S, Merkl B, Paulsson M, Smyth N. Epidermal transglutaminase (TGase 3) is the autoantigen of dermatitis herpetiformis. *The Journal of Experimental Medicine*. 2002;**195**(6):747-757. DOI: 10.2340/00015555-2162
- [30] Reunala TL. Dermatitis herpetiformis. *Clinics in Dermatology*. 2001;**19**(6):728-736. DOI: 10.1016/S0738-081X(00)00184-X
- [31] Hitomi K. Transglutaminases in skin epidermis. *European Journal of Dermatology*. 2005;**15**(5):313-319
- [32] Lorand L, Graham RM. Transglutaminases: Crosslinking enzymes with pleiotropic functions. *Nature Reviews. Molecular Cell Biology*. 2003;**4**(2):140-156. DOI: 10.1038/nrm1014
- [33] Jaskowski TD, Hamblin T, Wilson AR, Hill HR, Book LS, et al. IgA anti-epidermal transglutaminase antibodies in dermatitis herpetiformis and pediatric celiac disease. *The Journal of Investigative Dermatology*. 2009;**129**(11):2728-2730. DOI: 10.1038/jid.2009.142
- [34] Rose C, Bröcker E-B, Zillikens D. Clinical, histological and immunopathological findings in 32 patients with dermatitis herpetiformis Duhring. *Journal der Deutschen Dermatologischen Gesellschaft*. 2009;**8**(4):265-270, 265-271. DOI: 10.1111/j.1610-0387.2009.07292.x
- [35] Leonard J, Haffenden G, Tucker W, Unsworth J, Swain F, et al. Gluten challenge in dermatitis herpetiformis. *The New England Journal of Medicine*. 1983;**308**(14):816-819. DOI: 10.1056/NEJM198304073081406
- [36] Charlesworth EN, Backe JT, Letter GRL. Iodide-induced immunofluorescence in dermatitis herpetiformis. *Archives of Dermatology*. 1976;**112**(4):555. DOI: 10.1001/archderm.1976.01630280073025
- [37] Katz KA, Roseman JE, Roseman RL, Katz SI. Dermatitis herpetiformis flare associated with use of triiodomethane packing strips for alveolar osteitis. *Journal of the American Academy of Dermatology*. 2009;**60**(2):352-353. DOI: 10.1016/j.jaad.2008.08.041
- [38] Austin AS, Logan RFA, Thomason K, Holmes GKT. Cigarette smoking and adult coeliac disease. *Scandinavian Journal of Gastroenterology*. 2002;**37**(8):978-982. DOI: 10.1186/1471-230X-14-120
- [39] Snook JA, Dwyer L, Lee-Elliott C, Khan S, Wheeler DW, et al. Adult coeliac disease and cigarette smoking. *Gut*. 1996;**39**(1):60-62. DOI: 10.1136/gut.39.1.60

- [40] Collin P, Reunala T. Recognition and management of the cutaneous manifestations of celiac disease: A guide for dermatologists. *American Journal of Clinical Dermatology*. 2003;**4**(1):13-20
- [41] Junkins-Hopkins JM. Dermatitis herpetiformis: Pearls and pitfalls in diagnosis and management. *Journal of the American Academy of Dermatology*. 2010;**63**(3):526-528. DOI: 10.1016/j.jaad.2010.05.027
- [42] Kárpáti S. An exception within the Group of autoimmune blistering diseases: Dermatitis herpetiformis, the gluten-sensitive dermatopathy. *Immunology and Allergy Clinics of North America*. 2012;**32**(2):255-262. DOI: 10.1016/j.iac.2012.04.005
- [43] Kosann MK. Dermatitis herpetiformis. *Dermatology Online Journal*. 2003;**9**(4):8. DOI: 10.1590/abd1806-4841.20131775
- [44] Hofmann S, Nashan D, Bruckner-Tuderman L. Petechiae on the fingertips as presenting symptom of dermatitis herpetiformis Duhring. *Journal of the European Academy of Dermatology and Venereology*. 2009;**23**(6):732-733. DOI: 10.1111/j.1468-3083.2009.03200.x
- [45] Marks R, Jones EW. Purpura in dermatitis herpetiformis. *The British Journal of Dermatology*. 1971;**84**(4):386-388. DOI: 10.2147/CCID.S69127
- [46] Naylor E, Atwater A, Selim MA, Hall R, Puri PK. Leukocytoclastic vasculitis as the presenting feature of dermatitis herpetiformis. *Archives of Dermatology*. 2011;**147**(11):1313. DOI: 10.1001/archdermatol.2011.293
- [47] Ohshima Y, Tamada Y, Matsumoto Y, Hashimoto T. Dermatitis herpetiformis Duhring with palmoplantar keratosis. *The British Journal of Dermatology*. 2003;**149**(6):1300-1302. DOI: 10.1111/j.1365-2133.2003.05660.x
- [48] Powell GR, Bruckner AL, Weston WL. Dermatitis herpetiformis presenting as chronic urticaria. *Pediatric Dermatology*. 2004;**21**(5):564-567. DOI: 10.1111/j.0736-8046.2004.21509.x
- [49] Saito M, Böer A, Ishiko A, Nishikawa T. Atypical dermatitis herpetiformis: A Japanese case that presented with initial lesions mimicking prurigo pigmentosa. *Clinical and Experimental Dermatology*. 2006;**31**(2):290-291. DOI: 10.1111/j.1365-2230.2005.02009.x
- [50] Nicolas MEO, Krause PK, Gibson LE, Murray JA. Dermatitis herpetiformis. *International Journal of Dermatology*. 2003;**42**(8):588-600. DOI: 10.1155/2012/239691
- [51] Aine L, Mäki M, Reunala T. Coeliac-type dental enamel defects in patients with dermatitis herpetiformis. *Acta Dermato-Venereologica*. 1992;**72**(1):25-27. DOI: 10.3109/07853899608999067
- [52] Aine L, Reunala T, Mäki M. Dental enamel defects in children with dermatitis herpetiformis. *The Journal of Pediatrics*. 1991;**118**(4 Pt 1):572-574
- [53] Mäki M, Aine L, Lipsanen V, Koskimies S. Dental enamel defects in first-degree relatives of coeliac disease patients. *Lancet (London, England)*. 1991;**337**(8744):763-764. DOI: 10.1016/0140-6736(91)91375-5

- [54] Holtmeier W, Pfänder M, Zollner TM, Kaufmann R, Caspary WF. Distinct TCR delta repertoires are present in the cutaneous lesions and inflamed duodenum of patients with dermatitis herpetiformis. *Experimental Dermatology*. 2002;**11**(6):527-531. DOI: 10.1034/j.1600-0625.2002.110605.x
- [55] Rubio-Tapia A, Murray JA. Celiac disease. *Current Opinion in Gastroenterology*. 2010;**26**(2):116-122. DOI: 10.1097/MOG.0b013e3283365263
- [56] Gaspari AA, Huang CM, Davey RJ, Bondy C, Lawley TJ, et al. Prevalence of thyroid abnormalities in patients with dermatitis herpetiformis and in control subjects with HLA-B8/-DR3. *The American Journal of Medicine*. 1990;**88**(2):145-150. DOI: 10.1016/0002-9343(90)90464-O
- [57] Kaplan RP, Callen JP. Overlapping cutaneous disorders related to dermatitis herpetiformis. *Clinics in Dermatology*. 1991;**9**(3):361-368. DOI: 10.1016/0738-081X(91)90027-I
- [58] Zettinig G, Weissel M, Flores J, Dudczak R, Vogelsang H. Dermatitis herpetiformis is associated with atrophic but not with goitrous variant of Hashimoto's thyroiditis. *European Journal of Clinical Investigation*. 2000;**30**(1):53-57. DOI: 10.1046/j.1365-2362.2000.00590.x
- [59] Hervonen K, Viljamaa M, Collin P, Knip M, Reunala T. The occurrence of type 1 diabetes in patients with dermatitis herpetiformis and their first-degree relatives. *The British Journal of Dermatology*. 2004;**150**(1):136-138. DOI: 10.1111/j.1365-2133.2004.05642.x
- [60] Neuhausen SL, Steele L, Ryan S, Mousavi M, Pinto M, et al. Co-occurrence of celiac disease and other autoimmune diseases in celiacs and their first-degree relatives. *Journal of Autoimmunity*. 2008;**31**(2):160-165. DOI: 10.1016/j.jaut.2008.06.001
- [61] Amato L, Gallerani I, Fuligni A, Mei S, Fabbri P. Dermatitis herpetiformis and vitiligo: Report of a case and review of the literature. *The Journal of Dermatology*. 2000;**27**(7):462-466. DOI: 10.1111/j.1346-8138.2000.tb02207.x
- [62] Karabudak O, Dogan B, Yildirim S, Harmaneri Y, Anadolu-Brasie R. Dermatitis herpetiformis and vitiligo. *Journal of the Chinese Medical Association*. 2007;**70**(11):504-506. DOI: 10.1016/S1726-4901(08)70049-2
- [63] Reunala T, Salmi J, Karvonen J. Dermatitis herpetiformis and celiac disease associated with Addison's disease. *Archives of Dermatology*. 1987;**123**(7):930-932. DOI: 10.1001/archderm.1987.01660310098023
- [64] Stavropoulos P, Moustou A-EI, Tsiougou M, Avgerinou G, Chatziolou E, et al. Might dermatitis herpetiformis be associated with discoid lupus erythematosus? *Journal of the European Academy of Dermatology and Venereology*. 2008;**22**(6):749-750. DOI: 10.1111/j.1468-3083.2007.02443.x
- [65] Bolotin D, Petronic-Rosic V. Dermatitis herpetiformis. *Journal of the American Academy of Dermatology*. 2011;**64**(6):1027-1033. DOI: 10.1016/j.jaad.2010.09.776

- [66] Hervonen K, Vornanen M, Kautiainen H, Collin P, Reunala T. Lymphoma in patients with dermatitis herpetiformis and their first-degree relatives. *The British Journal of Dermatology*. 2005;**152**(1):82-86. DOI: 10.1111/j.1365-2133.2005.06345.x
- [67] Nassiri M, Robertson MJ, Hertzberg L, Czader MB. Primary effusion anaplastic large cell lymphoma in a patient with long-standing dermatitis herpetiformis and celiac disease. *Annals of Hematology*. 2013;**92**(2):279-281. DOI: 10.1007/s00277-012-1554-7
- [68] Sigurgeirsson B, Agnarsson BA, Lindelöf B. Risk of lymphoma in patients with dermatitis herpetiformis. *BMJ*. 1994;**308**(6920):13-15. DOI: 10.1136/bmj.308.6920.13
- [69] Viljamaa M, Kaukinen K, Pukkala E, Hervonen K, Reunala T, et al. Malignancies and mortality in patients with coeliac disease and dermatitis herpetiformis: 30-year population-based study. *Digestive and Liver Disease*. 2006;**38**(6):374-380. DOI: 10.1016/j.dld.2006.03.002
- [70] Reunala T, Salmi T, Hervonen K. Dermatitis herpetiformis: Pathognomonic transglutaminase IgA deposits in the skin and excellent prognosis on a gluten-free diet. *Acta Dermato-Venereologica*. 2015;**95**(8):917-922. DOI: 10.2340/00015555-2162
- [71] Lewis NR, Logan RFA, Hubbard RB, West J. No increase in risk of fracture, malignancy or mortality in dermatitis herpetiformis: A cohort study. *Alimentary Pharmacology & Therapeutics*. 2008;**27**(11):1140-1147. DOI: 10.1111/j.1365-2036.2008.03660.x
- [72] Arundhati S, Raghunatha S, Mahadeva KC. A cross-sectional study of clinical, histopathological and direct immunofluorescence spectrum of vesiculobullous disorders. *Journal of Clinical and Diagnostic Research*. 2013;**7**(12):2788-2792. DOI: 10.7860/JCDR/2013/7019.3760
- [73] Pierard J. Concerning the histological aspect of the erythematous plaques of Duhring's herpetiform dermatitis. *Annales De Dermatologie Et De Syphiligraphie*. 1986;**90**:121-133
- [74] Zone JJ. Skin manifestations of celiac disease. *Gastroenterology*. 2005;**128**(4 Suppl 1):S87-S91. DOI: 10.1053/j.gastro.2005.02.026
- [75] Ko CJ, Colegio OR, Moss JE, McNiff JM. Fibrillar IgA deposition in dermatitis herpetiformis—An underreported pattern with potential clinical significance. *Journal of Cutaneous Pathology*. 2010;**37**(4):475-477. DOI: 10.1111/j.1600-0560.2009.01472.x
- [76] Zone JJ, Meyer LJ, Petersen MJ. Deposition of granular IgA relative to clinical lesions in dermatitis herpetiformis. *Archives of Dermatology*. 1996;**132**(8):912-918. DOI: 10.1001/archderm.1996.03890320060010
- [77] Beutner EH, Chorzelski TP, Reunala TL, Kumar V. Immunopathology of dermatitis herpetiformis. *Clinics in Dermatology*. 1991;**9**(3):295-311. DOI: 10.1016/0738-081X(91)90021-C
- [78] Warren SJP, Cockerell CJ. Characterization of a subgroup of patients with dermatitis herpetiformis with nonclassical histologic features. *The American Journal of Dermatopathology*. 2002;**24**(4):305-308



- [79] Barnadas MA. Dermatitis Herpetiformis. *The American Journal of Dermatopathology*. 2016;**38**(4):283-288. DOI: 10.1097/DAD.0000000000000420
- [80] Nakajima K. Recent advances in dermatitis herpetiformis. *Clinical & Developmental Immunology*. 2012;**2012**:914162. DOI: 10.1155/2012/914162
- [81] Dieterich W, Schuppan D, Laag E, Reunala T, Kárpáti S, et al. Antibodies to tissue transglutaminase as serologic markers in patients with dermatitis herpetiformis. *The Journal of Investigative Dermatology*. 1999;**113**(1):133-136. DOI: 10.1046/j.1523-1747.1999.00627.x
- [82] Rose C, Dieterich W, Bröcker EB, Schuppan D, Zillikens D. Circulating autoantibodies to tissue transglutaminase differentiate patients with dermatitis herpetiformis from those with linear IgA disease. *Journal of the American Academy of Dermatology*. 1999;**41**(6):957-961. DOI: 10.1016/S0190-9622(99)70253-7
- [83] Samolitis NJ, Hull CM, Leiferman KM, Zone JJ. Dermatitis herpetiformis and partial IgA deficiency. *Journal of the American Academy of Dermatology*. 2006;**54**(5):S206-S209. DOI: 10.1016/j.jaad.2005.06.033
- [84] Kasperkiewicz M, Dähnrich C, Probst C, Komorowski L, Stöcker W, et al. Novel assay for detecting celiac disease-associated autoantibodies in dermatitis herpetiformis using deamidated gliadin-analogous fusion peptides. *Journal of the American Academy of Dermatology*. 2012;**66**(4):583-588. DOI: 10.1016/j.jaad.2011.02.025
- [85] Lytton SD, Antiga E, Pfeiffer S, Matthias T, Szaflarska-Poplawska A, et al. Neo-epitope tissue transglutaminase autoantibodies as a biomarker of the gluten sensitive skin disease—Dermatitis herpetiformis. *Clinica Chimica Acta*. 2013;**415**:346-349. DOI: 10.1016/j.cca.2012.10.051
- [86] Sitaru C, Zillikens D. Mechanisms of blister induction by autoantibodies. *Experimental Dermatology*. 2005;**14**(12):861-875. DOI: 10.1111/j.1600-0625.2005.00367.x
- [87] Griffiths CE, Menzies IS, Barrison IG, Leonard JN, Fry L. Intestinal permeability in dermatitis herpetiformis. *The Journal of Investigative Dermatology*. 1988;**91**(2):147-149. DOI: 10.1111/1523-1747.ep12464390
- [88] Garioch JJ, Lewis HM, Sargent SA, Leonard JN, Fry L. 25 years' experience of a gluten-free diet in the treatment of dermatitis herpetiformis. *The British Journal of Dermatology*. 1994;**131**(4):541-545. DOI: 10.1111/j.1365-2133.1994.tb08557.x
- [89] Fry L, Leonard JN, Swain F, Tucker WF, Haffenden G, et al. Long term follow-up of dermatitis herpetiformis with and without dietary gluten withdrawal. *The British Journal of Dermatology*. 1982;**107**(6):631-640. DOI: 10.1111/j.1365-2133.1982.tb00520.x
- [90] Kilander AF, Gillberg RE, Kastrup W, Mobacken H, Nilsson LA. Serum antibodies to gliadin and small-intestinal morphology in dermatitis herpetiformis. A controlled clinical study of the effect of treatment with a gluten-free diet. *Scandinavian Journal of Gastroenterology*. 1985;**20**(8):951-958. DOI: 10.3109/00365528509088854



- [91] Lewis HM, Renaula TL, Garioch JJ, Leonard JN, Fry JS, et al. Protective effect of gluten-free diet against development of lymphoma in dermatitis herpetiformis. *The British Journal of Dermatology*. 1996;**135**(3):363-367. DOI: 10.1046/j.1365-2133.1996.d01-1005.x
- [92] Hervonen K, Salmi T, Ilus T, Paasikivi K, Vornanen M, et al. Dermatitis herpetiformis refractory to gluten-free dietary treatment. *Acta Dermato-Venereologica*. 2016;**96**(1):82-86. DOI: 10.2340/00015555-2184
- [93] Egan CA, O'Loughlin S, Gormally S, Powell FC. Dermatitis herpetiformis: A review of fifty-four patients. *Irish Journal of Medical Science*. 1997;**166**(4):241-244. DOI: 10.1007/BF02944243
- [94] Leonard JN, Fry L. Treatment and management of dermatitis herpetiformis. *Clinics in Dermatology*. 1991;**9**(3):403-408. DOI: 10.2147/CCID.S69127
- [95] Debol SM, Herron MJ, Nelson RD. Anti-inflammatory action of dapsone: Inhibition of neutrophil adherence is associated with inhibition of chemoattractant-induced signal transduction. *Journal of Leukocyte Biology*. 1997;**62**(6):827-836
- [96] Zhu YI, Stiller MJ. Dapsone and sulfones in dermatology: Overview and update. *Journal of the American Academy of Dermatology*. 2001;**45**(3):420-434. DOI: 10.1067/mjd.2001.114733
- [97] Booth SA, Moody CE, Dahl MV, Herron MJ, Nelson RD. Dapsone suppresses integrin-mediated neutrophil adherence function. *The Journal of Investigative Dermatology*. 1992;**98**(2):135-140. DOI: 10.1111/1523-1747.ep12555654
- [98] Paek SY, Steinberg SM, Katz SI. Remission in dermatitis Herpetiformis. *Archives of Dermatology*. 2011;**147**(3):301. DOI: 10.1001/archdermatol.2010.336
- [99] Sunilkumar MN, Ajith TA, Parvathy VK. Acute dapsone poisoning in a 3-year-old child: Case report with review of literature. *World Journal of Clinical Cases*. 2015;**3**(10):911-914. DOI: 10.12998/wjcc.v3.i10.911
- [100] Luzzatto L, Seneca E. G6PD deficiency: A classic example of pharmacogenetics with ongoing clinical implications. *British Journal of Haematology*. 2014;**164**(4):469-480. DOI: 10.1111/bjh.12665
- [101] Potočnjak I, Likić R, Šimić I, Juričić Nahal D, Cegec I, et al. Dapsone-induced agranulocytosis-possible involvement of low-activity N-acetyltransferase 2. *Fundamental & Clinical Pharmacology*. 2017;**31**(5):580-586. DOI: 10.1111/fcp.12287
- [102] Choi SY, Hwang HY, Lee JH, Park JS, Jang MS. Severe dapsone hypersensitivity syndrome in a child. *Korean Journal of Pediatrics*. 2013;**56**(6):260. DOI: 10.3345/kjp.2013.56.6.260
- [103] Glied M, Rico MJ. Treatment of autoimmune blistering diseases. *Dermatologic Clinics*. 1999;**17**(2):431-440
- [104] Sener O, Doganci L, Safali M, Besirbellioglu B, Bulucu F, et al. Severe dapsone hypersensitivity syndrome. *Journal of Investigational Allergology & Clinical Immunology*. 2006;**16**(4):268-270

- [105] Cardones ARG, Hall RP. Management of dermatitis herpetiformis. *Dermatologic Clinics*. 2011;**29**(4):631-635. DOI: 10.1016/j.det.2011.06.015
- [106] Björnberg A, Hellgren L. Topical treatment of dermatitis herpetiformis with betamethasone-17-valerate and fluocinolone acetonide. *Acta Allergologica*. 1966;**21**(6):471-472. DOI: 10.1111/j.1398-9995.1966.tb03165.x
- [107] Famaey JP. Colchicine in therapy. State of the art and new perspectives for an old drug. *Clinical and Experimental Rheumatology*. 1988;**6**(3):305-317
- [108] Shah SA, Ormerod AD. Dermatitis herpetiformis effectively treated with heparin, tetracycline and nicotinamide. *Clinical and Experimental Dermatology*. 2000;**25**(3):204-205. DOI: 10.1046/j.1365-2230.2000.00615.x
- [109] Stenveld HJ, Starink TM, van Joost T, Stoof TJ. Efficacy of cyclosporine in two patients with dermatitis herpetiformis resistant to conventional therapy. *Journal of the American Academy of Dermatology* 1993;**28**(6):1014-1015. DOI:10.1016/S0190-9622(08)80657-3
- [110] Sacchidanand S, Hiremath NC, Natraj HV, Revathi TN, Rani S, et al. Dexamethasone-cyclophosphamide pulse therapy for autoimmune-vesiculobullous disorders at Victoria hospital, Bangalore. *Dermatology Online Journal*. 2003;**9**(5):2. DOI: 10.4103/0378-6323.53133
- [111] Albers LN, Zone JJ, Stoff BK, Feldman RJ. Rituximab treatment for recalcitrant dermatitis Herpetiformis. *JAMA Dermatology*. 2017;**153**(3):315. DOI: 10.1001/jama-dermatol.2016.4676
- [112] Kotze LM da S. Dermatitis herpetiformis, the celiac disease of the skin! *Arquivos de Gastroenterologia*. 2013;**50**(3):231-235. DOI: 10.1590/S0004-28032013000200041
- [113] Lemberg D, Day AS, Bohane T. Coeliac disease presenting as dermatitis herpetiformis in infancy. *Journal of Paediatrics and Child Health*. 2005;**41**:294-296
- [114] Medica I, Zmak M, Persic M. Dermatitis herpetiformis in a 30-month-old child. *Minerva Pediatrica*. 2003;**55**:171-173
- [115] Thibaud D, Jourdain JC, Le Lorier B, et al. Herpetiform dermatitis of the infant forming hemorrhagic bullae in diarrhea. *Pediatrician*. 2001;**8**:1399-1400
- [116] Horvath K, Mehta DI. Celiac disease—A worldwide problem. *Indian Journal of Pediatrics*. 2000;**67**:757-763

