

We are IntechOpen, the world's leading publisher of Open Access books Built by scientists, for scientists

6,900

Open access books available

186,000

International authors and editors

200M

Downloads

Our authors are among the

154

Countries delivered to

TOP 1%

most cited scientists

12.2%

Contributors from top 500 universities



WEB OF SCIENCE™

Selection of our books indexed in the Book Citation Index
in Web of Science™ Core Collection (BKCI)

Interested in publishing with us?
Contact book.department@intechopen.com

Numbers displayed above are based on latest data collected.
For more information visit www.intechopen.com



Management of Knee Cartilage Defects with the Autologous Matrix-Induced Chondrogenesis (AMIC) Technique

Michael E. Hantes and Apostolos H. Fyllos

Additional information is available at the end of the chapter

<http://dx.doi.org/10.5772/intechopen.71776>

Abstract

The arthroscopic findings of knee articular cartilage lesions are reported to be as high as 60%, although only a fragment of these are considered to be symptomatic. Such lesions are believed to accelerate the onset of arthritis. Long-term results of the microfracture technique for chondral and osteochondral defects of the knee cartilage are not satisfactory. The autologous matrix induced chondrogenesis (AMIC) technique offers a promising alternative as an effective cartilage repair procedure in the knee resulting in stable clinical results and with a wide range of indications. An extensive literature review has been performed aiming at providing the rationale behind AMIC, to report clinical results of AMIC and to compare AMIC with other chondrogenesis techniques. Finally, we comment on the appropriate surgical technique and its indications, since the number of one-step arthroscopic procedure proposals is steadily increasing.

Keywords: matrix-induced chondrogenesis, cartilage, microfractures, AMIC

1. Introduction

Despite its durable mechanical properties, hyaline cartilage has low intrinsic regenerative and reparative capacity since it lacks blood supply, nerves and lymphangion. Cartilage defects potentially lead to severe osteoarthritis and disability, and painful symptomatology during that process. None of the pharmacological or surgical cartilage degeneration management options have clearly shown the potential of restoring chondral surface, in order to avoid prosthetic replacement in the final stages of the disease. Numerous reparative techniques

for resurfacing articular cartilage defects are currently under extensive clinical research, with promising results. These include cell-based and cell-free materials such as autologous and allogeneic cell-based approaches and multipotent stem-cell-based techniques [1].

Microfracture technique, a low-cost, fully arthroscopic procedure, is still considered the gold standard approach for small cartilage lesions (less than 2 cm²), not without dispute. This technique enhances migration of mesenchymal stem cells (MSCs) from bone marrow bleeding to the site of a cartilage defect; however, it often results in the formation of fibrocartilage that is biochemically and biomechanically inferior to hyaline articular cartilage, not to mention scatter of the newly formed blood clot into the joint [2]. Its efficacy as a marrow stimulating technique is being questioned due to progressive decrease of the clinical benefit after 2 years, especially as far as large defects are concerned [3].

The autologous matrix induced chondrogenesis (AMIC) offers a promising alternative as an effective cartilage repair procedure in the knee resulting in stable clinical results. It is a one-step procedure that combines microfracture with the application of a biological scaffold acting as a collagen, cell-free matrix that covers the produced blood clot, permitting the containment and ingrowing of MSCs to differentiate into the chondrogenic lineage. The clot induces a repair that covers the cartilage defect with a combination of fibrous and hyaline-like cartilage. AMIC has the potential for homogeneous distribution of MSCs under the membrane that could enhance chondrogenesis and accelerate cartilage healing.

2. Incidence, symptomatology, diagnosis and classification of chondral lesions

Chondral lesions are caused through degradation of joint cartilage, in response to metabolic, genetic, vascular or traumatic stimuli. Chondral defects have been macroscopically graded by the International Cartilage Repair Society (ICRS) in a systematic manner, a system with good inter- and intra-observer reliability [4]. Most commonly used classification systems are the ICRS system and the modified Outerbridge.

The real incidence of osteochondral lesions in humans is unknown, because a large proportion of them are asymptomatic or undiagnosed. The prevalence of single or multiple focal knee articular cartilage pathologies (excluding osteoarthritis and chondromalacia patellae) is reported as high as 30% in arthroscopies, the commonest sites being the medial femoral condyle and the patella [5, 6]. 60% of the lesions are considered to be as severe as grade 3 or worse according to the ICRS system, while 64% of all chondral lesions have a diameter of less than 1 cm [6, 7]. Medial meniscus tears (37%) and ACL ruptures (36%) are the most common concomitant injuries with articular cartilage injuries. The presence of other injuries further influences management of these lesions, such as ACL insufficiency, patellar instability and patellofemoral malalignment [8, 9].

Patients with articular cartilage injuries usually complain of arthritis-like symptoms, such as pain, effusion, and mechanical symptoms varying with location of the lesion. Patients' history is important, although only 60% of patients with a chondral defect diagnosis definitely correlate their symptoms with a specific traumatic incidence [6]. Clinicians should consider the patients'

age and presence of a meniscal tear for the odds of having a chondral lesion subsequent to having an ACL injury. Advanced patient's age and long time from initial ACL injury are predictive factors of the severity of chondral lesions, and time from initial ACL injury is significantly associated with the number of chondral lesions [8–10]. However, no reliable correlation between clinical symptoms and articular cartilage status has been established.

Appropriate imaging modality to reach diagnosis is cartilage-sensitive MRI, but definitive diagnosis and classification is set by arthroscopy. Cartilage is a soft, viscoelastic tissue with strong imaging and anisotropic mechanical properties. The MRI signal properties are dependent on the cellular composition of collagen, proteoglycan, and water, but also the MR pulse sequence utilized. Normal cartilage demonstrates "gray-scale stratification," with lower signal intensity closer to the tidemark and subchondral plate and higher signal intensity in the transitional zone, related largely to collagen orientation in the extracellular matrix. Loss of normal gray-scale stratification is an important clinical feature that may herald subsequent delamination of cartilage from the subchondral bone. The assessment and grading of chondral and osteochondral injuries by using MR imaging are straightforward when true morphologic alterations are present. In the setting of higher grade acute injury, the signal alteration in the articular cartilage is readily visible and frequently associated with altered signal intensity in the adjacent subchondral bone marrow and displaced cartilage. On the other hand, low-grade chondral injury typically involves very little morphologic change. Traditional grading systems have classically used altered T2 signal within the cartilage to infer the presence of infrastructural damage. Recent developments in quantitative MR imaging provides direct evaluation of tissue biochemistry in the setting of injury. Several techniques are available to assess the integrity of cartilage glycosaminoglycan, including sodium MR imaging, delayed gadolinium-enhanced MR imaging of cartilage, and T1 ρ imaging. To assess collagen orientation, quantitative T2 mapping is most often utilized [11, 12].

3. Indications

Operative treatment for chondral and osteochondral knee defects generally is unavoidable at some point and is indicated when nonoperative symptomatic methods fail to relieve pain and mechanical symptoms. Treatment options include debridement, marrow stimulation, transplantation to fill the defect, cell-based therapy, and the use of growth factors or pharmacological agents. The choice of procedure is based primarily on the classification of the lesion and the activity demands of the patient. AMIC is a fairly new but very promising method for cartilage regeneration and was first described by Behrens and Benthien in 2011 [13]. It is a one-step and culture-free procedure, it has the potential for homogeneous distribution of chondrocytes and MSCs to enhance chondrogenesis, and it also has the ability to regenerate hyaline-like cartilage tissue. It has been proven that MSCs can be isolated from the matrix material [14]. The literature currently supports AMIC procedures for moderate to large (greater than 6 cm²) full thickness defects in the high-demand (but also highly compliant) young patient [15]. Some authors have mentioned underlying rheumatic disease and total meniscectomy as contraindications, whereas "kissing" lesions are unanimously considered an absolute contraindication. Needless to say that

elderly patients (although the age limit is not yet determined) with advanced osteoarthritis and significant narrowing of the joint lines are more suitable for total knee arthroplasty than AMIC or similar to AMIC joint preserving interventions.

4. The basic science behind AMIC

In vivo signaling molecules and biomechanical stimuli provides a much more appropriate environment for progenitor cells to differentiate than in vitro chondrogenesis. Fibrin, PDGF and other factors contained in a natural blood clot are highly chemoattractive for MSC. PDGF-BB, EGF and TGF- β are the most important potent mitogens. These factors also contained in the blood clot after subchondral microfracture induce the migration of MSC and have at the same time the potency to enhance their proliferation. Therefore, the migration and proliferation steps of MSC can take place simultaneously in vivo, excluding the need for in vitro culturing. Furthermore, cartilage differentiation initiates in contact with subchondral bone and earliest chondrogenesis is often seen in areas where active remodeling of the subchondral bone plate occurs and, thus, enhanced nutrition and a higher anabolic rate of the cells can take place. MSCs derived from microfractures have the same phenotypic plasticity as chondrogenic cells in the cartilage basal zone. One cm³ of blood from a single microfracture hole has approximately 8000 CD34+ MSCs [16, 17].

Strength of integration of the neotissue depends on the age and metabolic activity of the tissue. The use of more immature cells has obvious benefits for integration, which argues in favor of MSC-based as opposed to chondrocyte-based repair strategies. Collagen and fibrin-based gels are subject to strong shrinking during chondrogenesis which points towards an increasing risk of partial defect filling and loss of a superclot after microfracturing during progress of chondrogenic differentiation. To be able to avoid this, a clinically applied solid collagen type I/III matrix as used in the AMIC technique appears to facilitate chondrogenesis of MSC. It has been proven that bone marrow cells can be guided directly to a cartilage defect by a collagenous matrix and MSCs can be isolated regularly from the matrix [14]. Inhibitory signals may come from the opposed cartilage surface and synovial fluid to dominate the surface area of fibrous repair tissue. The lowest cartilage layer is responsible for load transmission from cartilage into bone. Application of biomechanical loading during chondrogenesis of MSC stimulated cartilaginous matrix production in tissue engineering applications underlining the importance of mechanical signals for tissue guidance during repair [17].

5. Surgical technique

The AMIC procedure can be performed with either a mini open approach, or a combination of arthroscopy and mini arthrotomy, or even as an all-arthroscopic technique. There are different types of scaffolds available: natural protein-based or carbohydrate-based scaffolds, and synthetic scaffolds. The 3 scaffolds that have been reported in the literature for AMIC are ChondroGide (Geistlich Biomaterials, Wolhausen, Switzerland), Hyalofast (Fidia Advanced Biopolymers, Padua, Italy), and Chondrotissue (BioTissue, Zurich, Switzerland) [18]. Modifications and enrichment of the scaffold with newer biomaterials

(such as platelet-rich plasma or leucocyte-platelet-concentrated membrane) of the original AMIC technique may improve cartilage repair outcome and optimize the operative approach [19]. The basic procedural rationale is chondral defect arthroscopic debridement and preparation of smooth surrounding boundaries, followed by subchondral microfracture technique and finally stable bilayer matrix fixation.

The patient is placed supine in an ordinary arthroscopy setup, under regional or general anesthesia, antibiotic prophylaxis and with tourniquet application to the thigh. The status of the joint, ligamentous structure integrity and the cartilage lesion are assessed by arthroscopy, including location, size, and depth according to the ICRS classification. Clear, smooth and stable borders of normal adjacent cartilage are defined, followed by removal of the calcified chondral layer with a burr or a curette. According to the original technique, a mini arthrotomy is performed at this stage and access to the subchondral bone is reached by nanofractures or microfractures or by microdrilling with appropriate instruments. The gaps between the holes should permit sufficient bridging to prevent subchondral fracture. Generally, nanofractures technique is preferred, with standardized drilled holes nine millimeters deep and one millimeter in diameter and standard needle angling [20–22]. All-arthroscopic techniques have been described as well [22–24]. The collagen matrix of choice is consequently trimmed to fill the size of the defect, usually by template or imprint. Undersize of the scaffold is recommended to avoid dislocation with movement. The matrix is then pressed and sutured or glued (allogenic or partially autologous fibrin glue) or with a combination of both stabilized on the defect, making sure that a smooth transition to normal cartilage has been ensured. There are usually two sides of the membrane; the rough side faces the subchondral bone and the smooth side faces the joint. The application of fibrin glue and the attachment of the membrane is best done in a dry environment in case of all-arthroscopic technique. The scaffold acts like a sponge that holds the blood clot within the defect and induces hemostasis while protecting the underlying tissue. This may be either performed arthroscopically or as an arthroscopically assisted mini-open technique. Before closure, multiple gentle movements of the joint are advised in order to confirm unhindered membrane placement. Irrigation of the joint is discouraged as this may almost certainly result in membrane dislocation and removal of the desired blood clot. The use of a drain deems unnecessary, not to mention that suction could result in membrane dislodgement (**Figures 1–9**).

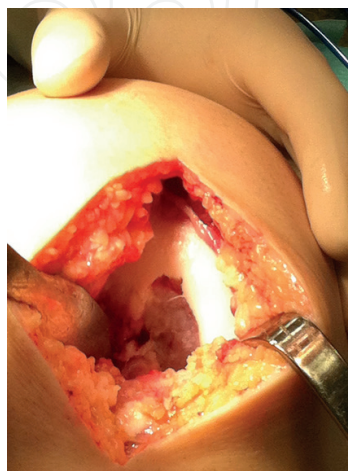


Figure 1. Mini arthrotomy, identification and classification of the lesion.

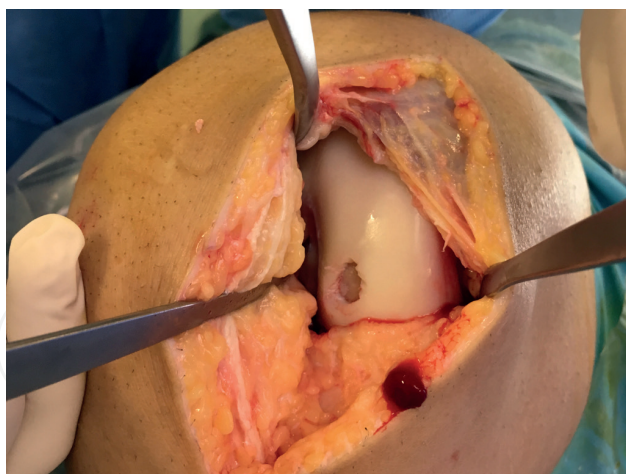


Figure 2. Osteochondral lesion (ICRS grade 4) after open debridement and preparation of boundaries.

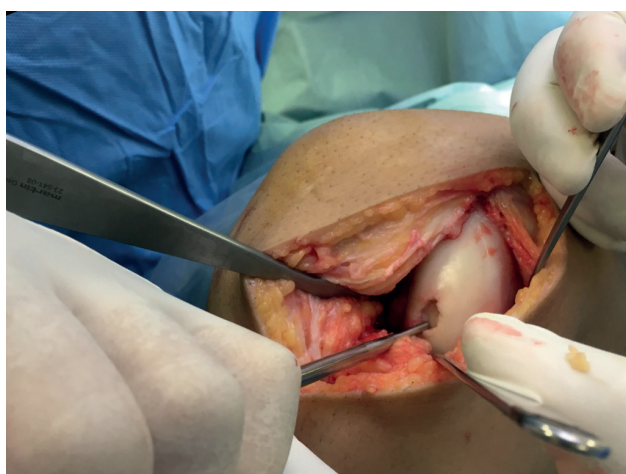

Figure 3. Performing nanofractures.

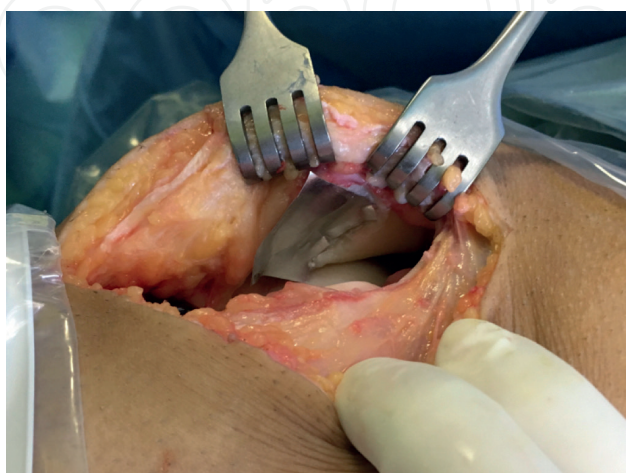


Figure 4. Imprint technique with aluminum foil.

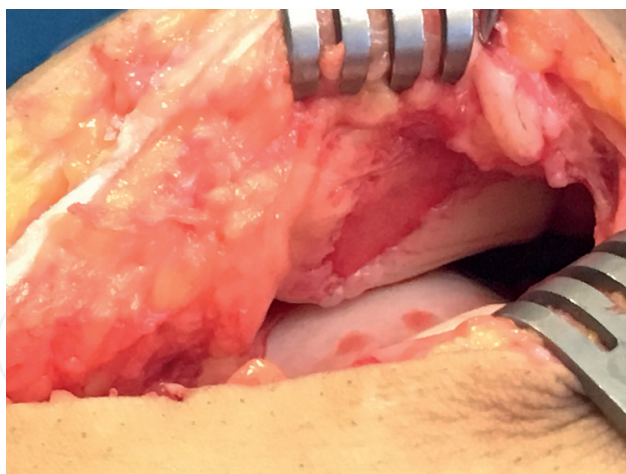


Figure 5. After open scaffold placement in a large patellar defect.

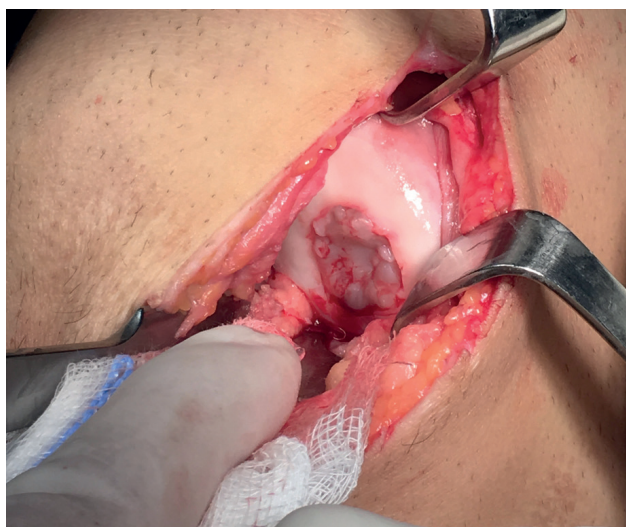

Figure 6. After open membrane placement in medial femoral condyle osteochondral lesion.

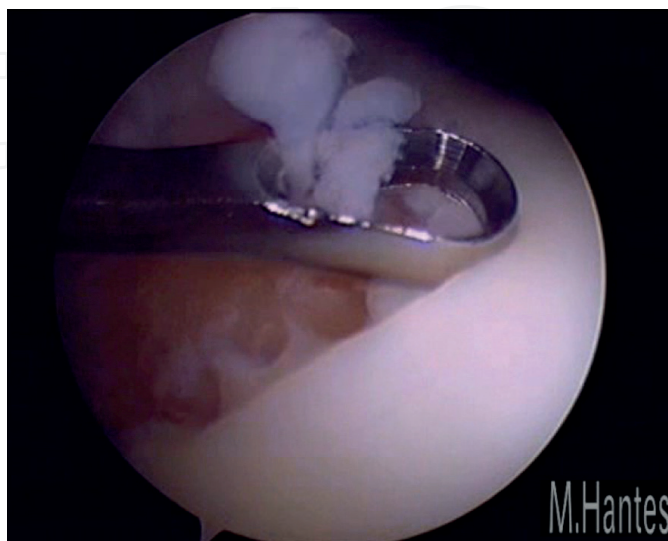


Figure 7. Arthroscopic curettage of osteochondral lesion to healthy bone depth.

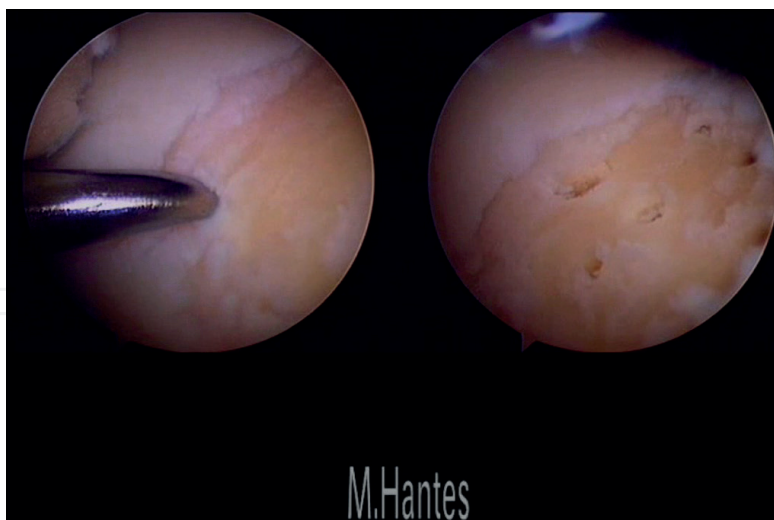


Figure 8. Arthroscopic microfracture technique.

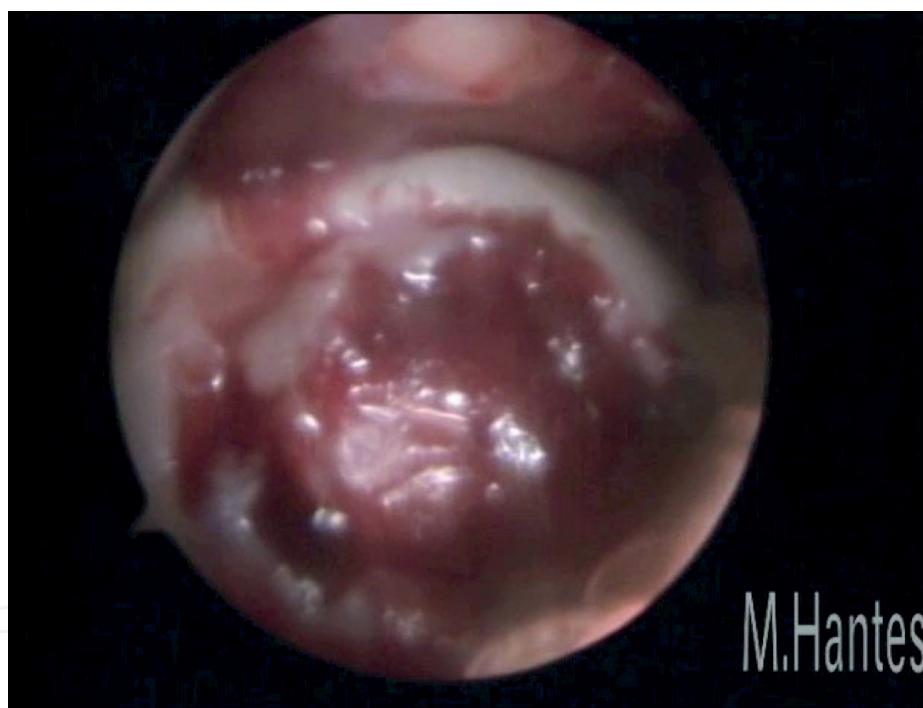


Figure 9. Membrane attached after preparation of osteochondral defect under dry arthroscopy.

6. Rehabilitation

Patient compliance is the key for success of this sensitive procedure, although consensus has not been reached. Most authors recommend foot sole contact for 6 weeks using crutches building up full weight bearing after 8 weeks. Partial weight bearing pertains to the possible risk of a compression fracture after microfracturing due to small and ill-defined bone bridges which might not bear enough weight. Articular remodeling and chondral maturation may take up to

6 months so limited weight bearing for a certain amount of time is important. However, remodeling of the chondral matrix may actually profit from early mobilization using a combination of compression and shear forces. Since there is sufficient bridging between the drilled holes and the holes are straight there should be no reason for a subchondral impression fracture. Earlier weight-bearing has been suggested after nanofractures [25–27].

Range of motion is generally restricted for 6 weeks depending on site of the lesion. When the femoral condyles are involved, active and passive knee flexion up to 90° is permitted, whereas when the patella is involved knee flexion is restricted to 60° for the first month. Mobilization exercises including continuous passive motion, electrotherapy of leg muscles and proprioception training are an integral part of the rehabilitation program. Unrestricted weight-bearing and range of motion is permitted after 8 weeks. Contact sports are prohibited for at least a year [28–30]. No study has yet addressed the effect of rehabilitation on the quality of the repair.

7. Results

Well-established rating systems have been used to summarize relevant outcome measures. The combination of the Lysholm score and the Visual Analog Score (VAS) have been recommended in the literature before. The Lysholm scoring system has demonstrated validity, reliability and responsiveness to cartilage pathology and treatment. The VAS has widely been used to monitor subjective satisfaction postoperatively [31, 32]. The Modified Cincinnati, the Modified ICRS scores and the knee injury and osteoarthritis outcome score (KOOS) have also been suggested.

Structural repair can be assessed with MRI with a focus on the extent, signal intensity, and surface of the defect filling, integration to adjacent cartilage, and bone marrow lesion. Semiquantitative MRI scores of osteoarthritis established as BLOKS and WOMS can play the part. But it is magnetic resonance observation of cartilage repair tissue (MOCART) protocol that is more often used, with almost perfect interobserver reliability. The detection of subtle cartilage changes by MRI requires high resolution imaging, which is not provided by standard sequences. With the use of a surface coil placed over the knee compartment of interest, high resolution imaging with reasonable scan times is possible on routinely used 1 or 1.5 T MRI units by performing fast spin-echo imaging. The advantage of this imaging technique is that it can be used on every standard 1 or 1.5 T scanner. Nine variables are used to describe the morphology and signal intensity of the repair tissue compared to the adjacent native cartilage, according to the MOCART system. A statistically significant correlation between the clinical outcome (as measured by VAS and KOOS) and some of the radiological variables, including the filling of the defect, the structure of the repair tissue, changes in the subchondral bone and the signal intensities has been established [33] (**Figure 10**).

Encouraging mid- to long-term results have been published that make the AMIC procedure seem promising for a wide range of indications. Gille et al. published their results after 2 years of follow-up of 57 patients who had undergone AMIC (and concomitant procedures in appropriate cases). Mean defect size was 3.4 cm² and classification grade in the Outerbridge system was III or higher, with mean patient age of 37 years. Mean Lysholm and VAS scores were

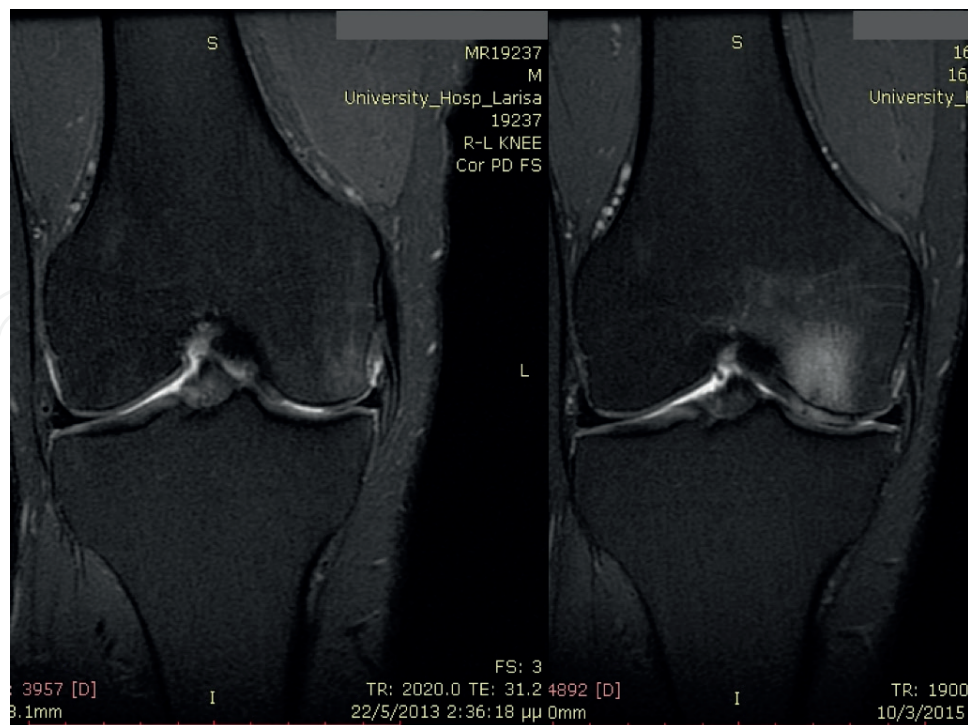


Figure 10. MRI of patient pre- and 19 months post-op, with good filling of the chondral defect in the medial femoral condyle and good integration of the neotissue.

significantly improved in all age groups at 2 years post-op. Defect size (range 0–12 cm²) had no impact on the clinical outcome and no adverse effects or procedural failures were reported [34]. Furthermore, another prospective randomized control trial of 47 patients with mean age 37 years and mean defect size 3.6 cm², directly compared results after microfracturing alone with results after AMIC. After improvement for the first 2 years in all sub-groups, a progressive and significant score degradation was observed in the microfracture group, while all functional parameters remained stable for at least 5 years in the AMIC group. At two and 5 years, MRI defect filling was more complete in the AMIC groups (at least 60% of the patients had a defect filling of more than 2/3). No serious treatment-related adverse events were reported. Biopsies were obtained at 2 years in two patients, both belonging to the AMIC group. Both showed the presence of a fibrocartilaginous matrix, without evidence of residual membrane material, and in one case cell cluster formation was observed in the deep zone of the repair tissue. Hyaline cartilage specific markers were identified, as Safranin-O, collagen-type I and II and a glycosaminoglycan. Both repair tissues were characterized as mostly fibrocartilaginous [28]. In a retrospective review of results in 40 knees with a mean follow-up of 28.8 months, AMIC alone and in combination with unloading osteotomy or patella realignment significantly improved symptomatic knees with isolated osteochondral and chondral lesions. A relatively important complication rose, knee stiffness in the subgroup with patella defects, and manipulation under anesthesia was necessary. However, subgroups varied considerably in lesion site and size, the patient population was small and radiological results according to the MOCART system were inconsistent and therefore unreliable [29]. Finally, in a prospective trial of 21 patients treated

for full-thickness defects larger than 2 cm², annual clinical reviews and an MRI was performed at 1 and 7 years postoperatively. All patients showed maintenance of good clinical and functional results 7 years after the procedure, although imaging findings did not support good clinical outcomes in all cases [30].

Two recent meta-analyses pointed out that conclusive evidence to determine whether morphological MRI is reliable in predicting clinical outcome after cartilage repair is lacking. These reports also stated that no MRI classification has been shown to correlate with clinical outcomes after different types of cartilage repair, although AMIC was not among the procedures included in the studies [35, 36]. Since the interpretation of cartilage structure from morphological MRI data is still debated and does not correlate with clinical scores, clinical and functional results should be considered as the most important outcomes, and so far, AMIC shows great clinical benefit for the patient. Finally, it should be outlined that no randomized controlled studies have been published comparing AMIC results with other cartilage repair procedures (apart from microfractures), such as autologous chondrocyte implantation (ACI) or matrix-induced chondrocyte implantation (MACI), in order to draw definite conclusions. The obvious advantage is the fact that it is a one-step procedure, faster, simpler and at a lower cost compared to ACI/MACI, since no cell culture and/or reoperation is needed. Standardization of the AMIC technique is also an issue due to different micro- or nanofracturing technique and open vs. arthroscopic procedures.

8. Conclusion

To sum up, AMIC is a one-step cartilage repair technique performed either by arthroscopy or by mini arthrotomy in the stable and well aligned knee. It shows great promise with good functional mid- and long-term results, and has a very low rate and range of complications and failures. The procedure seems to augment the healing potential thanks to homogeneous distribution of MSCs that enhances chondrogenesis, and also shows ability to regenerate hyaline-like cartilage tissue on MRI. Prospective long-term randomized trials are needed to compare the results of the AMIC procedure with other cartilage repair techniques, as well as to ensure maintenance of good clinical outcomes in the long run. A systematic and prolonged rehabilitation program is essential and outcome is absolutely dependent on patient compliance.

Author details

Michael E. Hantes^{1*} and Apostolos H. Fyllos^{1,2}

*Address all correspondence to: hantesmi@otenet.gr

1 Department of Orthopedics, Faculty of Medicine, University of Thessaly, Larisa, Greece

2 Department of Anatomy, Faculty of Medicine, University of Thessaly, Larisa, Greece

References

- [1] Makris EA, Gomoll AH, Malizos KN, Hu JC, Athanasiou KA. Repair and tissue engineering techniques for articular cartilage. *Nature Reviews Rheumatology*. 2015 Jan;**11**(1): 21-34
- [2] Kreuz PC, Steinwachs MR, Erggelet C, Krause SJ, Konrad G, Uhl M, et al. Results after microfracture of full-thickness chondral defects in different compartments in the knee. *Osteoarthritis and Cartilage*. 2006 Nov;**14**(11):1119-1125
- [3] Mithoefer K, McAdams T, Williams RJ, Kreuz PC, Mandelbaum BR. Clinical efficacy of the microfracture technique for articular cartilage repair in the knee: An evidence-based systematic analysis. *The American Journal of Sports Medicine*. 2009 Oct;**37**(10):2053-2063
- [4] Dwyer T, Martin CR, Kendra R, Sermer C, Chahal J, Ogilvie-Harris D, et al. Reliability and validity of the arthroscopic international cartilage repair society classification system: Correlation with histological assessment of depth. *Arthroscopy*. 2017 Jun;**33**(6):1219-1224
- [5] Widuchowski W, Widuchowski J, Trzaska T. Articular cartilage defects: Study of 25,124 knee arthroscopies. *The Knee*. 2007 Jun;**14**(3):177-182
- [6] Hjelle K, Solheim E, Strand T, Muri R, Brittberg M. Articular cartilage defects in 1,000 knee arthroscopies. *Arthroscopy*. 2002 Sep;**18**(7):730-734
- [7] Tandogan RN, Taser O, Kayaalp A, Taşkiran E, Pinar H, Alparslan B, et al. Analysis of meniscal and chondral lesions accompanying anterior cruciate ligament tears: Relationship with age, time from injury, and level of sport. *Knee Surgery, Sports Traumatology, Arthroscopy*. 2004 Jul;**12**(4):262-270
- [8] Logerstedt DS, Snyder-Mackler L, Ritter RC, Axe MJ. Knee pain and mobility impairments: Meniscal and articular cartilage lesions. *The Journal of Orthopaedic and Sports Physical Therapy*. 2010 Jun;**40**(6):A1-A35
- [9] Michalitsis S, Vlychou M, Malizos KN, Thriskos P, Hantes ME. Meniscal and articular cartilage lesions in the anterior cruciate ligament-deficient knee: Correlation between time from injury and knee scores. *Knee Surgery, Sports Traumatology, Arthroscopy*. 2015 Jan;**23**(1):232-239
- [10] Flanigan DC, Harris JD, Trinh TQ, Siston RA, Brophy RH. Prevalence of chondral defects in athletes' knees: A systematic review. *Medicine and Science in Sports and Exercise*. 2010 Oct;**42**(10):1795-1801
- [11] Pathria MN, Chung CB, Resnick DL. Acute and stress-related injuries of bone and cartilage: Pertinent anatomy, basic biomechanics, and imaging perspective. *Radiology*. 2016 Jul;**280**(1):21-38
- [12] Potter HG, Koff MF. MR imaging tools to assess cartilage and joint structures. *HSS Journal*. 2012 Feb;**8**(1):29-32

- [13] Benthien JP, Behrens P. The treatment of chondral and osteochondral defects of the knee with autologous matrix-induced chondrogenesis (AMIC): Method description and recent developments. *Knee Surgery, Sports Traumatology, Arthroscopy*. 2011 Aug;**19**(8):1316-1319
- [14] Kramer J, Böhrnsen F, Lindner U, Behrens P, Schlenke P, Rohwedel J. In vivo matrix-guided human mesenchymal stem cells. *Cellular and Molecular Life Sciences*. 2006 Mar;**63**(5): 616-626
- [15] Zhang C, Cai YZ, Lin XJ. One-step cartilage repair technique as a next generation of cell therapy for cartilage defects: Biological characteristics, preclinical application, surgical techniques, and clinical developments. *Arthroscopy*. 2016 Jul;**32**(7):1444-1450
- [16] Tallheden T, Dennis JE, Lennon DP, Sjögren-Jansson E, Caplan AI, Lindahl A. Phenotypic plasticity of human articular chondrocytes. *The Journal of Bone and Joint Surgery. American Volume*. 2003;**85-A**(Suppl 2):93-100
- [17] Richter W. Mesenchymal stem cells and cartilage in situ regeneration. *Journal of Internal Medicine*. 2009 Oct;**266**(4):390-405
- [18] Lee YH, Suzer F, Thermann H. Autologous matrix-induced chondrogenesis in the knee: A review. *Cartilage*. 2014 Jul;**5**(3):145-153
- [19] D'Antimo C, Biggi F, Borean A, Di Fabio S, Pirola I. Combining a novel leucocyte-platelet-concentrated membrane and an injectable collagen scaffold in a single-step AMIC procedure to treat chondral lesions of the knee: A preliminary retrospective study. *European Journal of Orthopaedic Surgery and Traumatology*. 2016 Jul;**27**(5):673-681
- [20] Steadman JR, Rodkey WG, Rodrigo JJ. Microfracture: Surgical technique and rehabilitation to treat chondral defects. *Clinical Orthopaedics and Related Research*. 2001 Oct;(391 Suppl):S362-S369
- [21] Chen H, Sun J, Hoemann C, Lascau-Coman V, Ouyang W, Trankhanh N, et al. Drilling and microfracture lead to different bone structure and necrosis during bone-marrow stimulation for cartilage repair. *Journal of Orthopaedic Research*. 2009 Nov;**27**(11):1432-1438
- [22] Benthien JP, Behrens P. Nanofractured autologous matrix induced chondrogenesis (NAMIC©)—Further development of collagen membrane aided chondrogenesis combined with subchondral needling: A technical note. *The Knee*. 2015 Oct;**22**(5):411-415
- [23] Piontek T, Ciemniowska-Gorzela K, Szulc A, Naczek J, Słomczykowski M. All-arthroscopic AMIC procedure for repair of cartilage defects of the knee. *Knee Surgery, Sports Traumatology, Arthroscopy*. 2012 May;**20**(5):922-925
- [24] Sadlik B, Wiewiorski M. Implantation of a collagen matrix for an AMIC repair during dry arthroscopy. *Knee Surgery, Sports Traumatology, Arthroscopy*. 2015 Aug;**23**(8):2349-2352
- [25] Benthien JP, Behrens P. Reviewing subchondral cartilage surgery: Considerations for standardized and outcome predictable cartilage remodelling. *International Orthopaedics*. 2013 Nov;**37**(11):2139-2145

- [26] Wang N, Grad S, Stoddart MJ, Niemeyer P, Reising K, Schmal H, et al. Particulate cartilage under bioreactor-induced compression and shear. *International Orthopaedics*. 2014 May;**38**(5):1105-1111
- [27] Schaetti O, Grad S, Goldhahn J, Salzmann G, Li Z, Alini M, et al. A combination of shear and dynamic compression leads to mechanically induced chondrogenesis of human mesenchymal stem cells. *European Cells & Materials*. 2011 Oct 11;**22**:214-225
- [28] Volz M, Schaumburger J, Frick H, Grifka J, Anders S. A randomized controlled trial demonstrating sustained benefit of Autologous Matrix-Induced Chondrogenesis over microfracture at five years. *International Orthopaedics*. 2017 Apr;**41**(4):797-804
- [29] Kusano T, Jakob RP, Gautier E, Magnussen RA, Hoogewoud H, Jacobi M. Treatment of isolated chondral and osteochondral defects in the knee by autologous matrix-induced chondrogenesis (AMIC). *Knee Surgery, Sports Traumatology, Arthroscopy*. 2012 Oct;**20**(10):2109-2115
- [30] Schiavone Panni A, Del Regno C, Mazzitelli G, D'Apolito R, Corona K, Vasso M. Good clinical results with autologous matrix-induced chondrogenesis (Amic) technique in large knee chondral defects. *Knee Surgery, Sports Traumatology, Arthroscopy*. 2017 Mar 21. [Epub ahead of print]
- [31] Flandry F, Hunt JP, Terry GC, Hughston JC. Analysis of subjective knee complaints using visual analog scales. *The American Journal of Sports Medicine*. 1991 Mar-Apr;**19**(2):112-118
- [32] Fuchs S, Friedrich M. Possible influence of knee scores. *Der Unfallchirurg*. 2000 Jan;**103**(1):44-50
- [33] Marlovits S, Singer P, Zeller P, Mandl I, Haller J, Trattnig S. Magnetic resonance observation of cartilage repair tissue (MOCART) for the evaluation of autologous chondrocyte transplantation: Determination of interobserver variability and correlation to clinical outcome after 2 years. *European Journal of Radiology*. 2006 Jan;**57**(1):16-23
- [34] Gille J, Behrens P, Volpi P, de Girolamo L, Reiss E, Zoch W, et al. Outcome of Autologous Matrix Induced Chondrogenesis (AMIC) in cartilage knee surgery: Data of the AMIC Registry. *Archives of Orthopaedic and Trauma Surgery*. 2013 Jan;**133**(1):87-93
- [35] de Windt TS, Welsch GH, Brittberg M, Vonk LA, Marlovits S, Trattnig S, Saris DB. Is magnetic resonance imaging reliable in predicting clinical outcome after articular cartilage repair of the knee? A systematic review and meta-analysis. *The American Journal of Sports Medicine*. 2013 Jul;**41**(7):1695-1702
- [36] Blackman AJ, Smith MV, Flanigan DC, Matava MJ, Wright RW, Brophy RH. Correlation between magnetic resonance imaging and clinical outcomes after cartilage repair surgery in the knee: A systematic review and meta-analysis. *The American Journal of Sports Medicine*. 2013 Jun;**41**(6):1426-1434