

# We are IntechOpen, the world's leading publisher of Open Access books Built by scientists, for scientists

6,900

Open access books available

186,000

International authors and editors

200M

Downloads

Our authors are among the

154

Countries delivered to

TOP 1%

most cited scientists

12.2%

Contributors from top 500 universities



WEB OF SCIENCE™

Selection of our books indexed in the Book Citation Index  
in Web of Science™ Core Collection (BKCI)

Interested in publishing with us?  
Contact [book.department@intechopen.com](mailto:book.department@intechopen.com)

Numbers displayed above are based on latest data collected.  
For more information visit [www.intechopen.com](http://www.intechopen.com)



---

# Perforator Flaps: Principles and Techniques

---

Goktekin Tenekeci

Additional information is available at the end of the chapter

<http://dx.doi.org/10.5772/intechopen.71270>

---

## Abstract

Evolution of flaps has continued after the introduction of fasciocutaneous and musculocutaneous flaps. Perforator flaps have evolved, and they have provided many new flaps with new pedicles all over the body presenting important advantages. Better understanding of vascular anatomy and pattern of skin circulation has become possible by numerous cadaveric studies. As a result, widespread use of perforator flaps, either pedicled or free, has become possible. Perforator flaps have provided freedom of flap design with over 350 perforators all over the body, reliability, and reduced donor site morbidity. However, success begins with planning and continues with operative procedure. Here, in this relatively new field of reconstructive surgery, the following are discussed: the correct planning of perforator flaps, microanatomy of perforators, and what to do during the operation based on previous reports. Lastly, some brief information and examples of perforator-based workhorse flaps are given.

**Keywords:** perforator, flap

---

## 1. Introduction

Two main algorithms are applied for reconstruction of tissue defects: the reconstructive ladder and the reconstructive elevator systems. The philosophy of the reconstructive ladder system is to use the simplest possible reconstructive option to reconstruct the defect. According to the “reconstructive ladder” concept primary closure, skin graft, local flap, and lastly distant flap options are evaluated and used for reconstructing a defect. The simplest option to reconstruct a defect in this order is used. However, according to the reconstructive elevator system, patients’ needs determine the reconstructive option to be used. In order to achieve a better functional and esthetic outcome, to improve donor site appearance, and to reduce its morbidity, many surgeons have used free flap transfer as the first choice over the past two decades [1]. Therefore, the reconstructive elevator system is favored since it is more functional and reduces donor site morbidity especially after the introduction of perforator-free flaps.

Modern technology has enabled us to produce finer microsurgical and surgical instruments; improvement in optics has produced improved operative microscopes [2]. Along with this, an increasing number of centers all over the world give microsurgical training opportunities, enabling more and more reconstructive surgeons to perform reconstructive microsurgical operations [2]. As a result of this, there is a general shift in favor of the reconstructive elevator versus the reconstructive ladder system all over the world. This means, more complicated operations that consider patients' future functionality and donor site morbidity are performed. Donor site morbidity does not always refer to donor site appearance but, more importantly, it refers to sacrifice of important vessels, underlying muscle, etc. After the introduction of perforator flaps to the field of reconstructive surgery, harvest and use of perforator flaps as a new option has become popular because of its numerous advantages compared to more traditional flaps. These advantages include the reliability of perforator flaps, decrease in donor site morbidity when compared to nonperforator options, and the possibility to use each perforator flap as a local pedicled flap or as a free flap. As a result of this, perforator flaps have gained legitimate popularity all over the world. Radial forearm free flaps or latissimus dorsi free flaps can be given as examples for less frequently used reconstructive options after popularization of perforator based free flaps.

In the past, before perforator flaps gained popularity, random pattern flaps with no described or known vascular supply had been frequently used to reconstruct defects. Ponten has described various lengths to width ratios for random pattern flaps in different locations of the body. However, as a result of a better understanding of blood supply to skin, a new era has begun in the field of reconstructive surgery. This has led to the development and use of fasciocutaneous and musculocutaneous flaps supported by the "angiosome theory."

Evolution of flaps has continued contrary to the belief that there is very little left to discover about flap design [2]. In 1989, Koshima and Soeda reported on a skin flap supplied by a perforating vessel originating from the deep inferior epigastric artery and perforating the deep fascia [3]. This was the first perforator flap reported and was the beginning of another era in the field of reconstructive microsurgery. Following this report, an increasing number of papers have been reported sharing experience in reconstructing defects all over the body either by using local perforator flaps or by using perforator-free flaps.

## **2. Description, classification, and nomenclature of perforator flaps**

In 2003, Blondeel et al. reported a paper representing the consensus of opinions of a group of pioneers in the field of perforator flap surgery that were reached during the Fifth International Course on Perforator Flaps in Gent in September 2001 [4]. They tried to classify perforators according to perforators' anatomy, the route they passed through until they reached the subcutaneous tissue by piercing the deep fascia. According to this paper, five types of perforators were defined: "(1) direct perforators: these perforated the deep fascia and supplied the subcutaneous tissue and skin, (2) indirect muscle perforators that gave muscular branches but predominantly supplied skin and subcutaneous tissue, (3) indirect muscle perforators that gave branches to muscle, predominantly supplied muscle but gave secondary branches to

subcutaneous tissue, (4) indirect perimysial perforators that traveled within the perimysium between the muscle fibers before piercing the deep fascia, (5) indirect septal perforators that traveled between the intermuscular septum, and pierced the deep fascia and supplied the subcutaneous tissue and skin" [4]. After the "2001 consensus" in classification of perforators, Blondeel et al. reported on roundtable talks on flap terminology at the "Sixth International Course on Perforator Flaps" that was held in Taipei from October 23 until October 26, 2002. During this meeting, they tried to simplify perforator classification and reported this simplified consensus in 2003 [5]. According to this, flaps are classified under three types: "(1) indirect muscle perforators or myocutaneous perforators that traverse through muscle and perforate the outer layer of deep fascia to supply overlying skin, (2) indirect septal perforators or septocutaneous perforators that traverse septum and supply overlying skin after perforating the outer layer of deep fascia, and (3) direct perforators that perforate deep fascia only" [5]. If we look from a practical point of view, it is important to know what kind of dissection is to be made: an intramuscular dissection or a dissection for a septocutaneous perforator. Dissection of a septocutaneous perforator requires a tedious dissection but is easier when compared with the dissection of a musculocutaneous perforator. However, dissection of a musculocutaneous perforator requires experience and much care. From this point, it is important to distinguish between two. On the other hand, we believe it is also very important to know the subtypes of musculocutaneous perforators for academic purposes.

Another issue concerns the nomenclature of perforator flaps. In Gent, they tried to reach a consensus on the nomenclature of new perforator flaps. Until this time, same perforator flaps are being reported in articles or in scientific meetings under different names, and this causes confusion among readers or audients. For this reason, the following statement is accepted:

"A perforator flap should be named after the nutrient artery or vessels and not after the underlying muscle. If there is a potential to harvest multiple perforator flaps from one vessel, the name of each flap should be based on its anatomical region or muscle" [4].

### 3. Perforasome theory and perforator anatomy

Perforasome theory has been raised by Saint-Cyr et al. as a result of a cadaveric study [6]. This theory defines the perforators supplying skin, the microanatomy of perforating vessels, perfusion characteristics, and the relationship among neighboring perforators all around the body. This theory also gives us clues in correct designing of perforator flaps. The importance of direct and indirect linking vessels has also been shown in this study. Similarly, Taylor and Palmer have defined the angiosome concept; they have demonstrated that the whole body is divided into composite blocks of tissue supplied by source vessels and each neighboring tissue block and source vessels communicate with each other by means of anastomotic vessels [7, 8]. Both are quite important studies that try to find answers to similar questions and are milestones in understanding the vascularization of skin.

The term "perforasome" has been used by Saint-Cyr et al. to describe the vascular arterial territory supplied by an individual perforator [6]. Over 350 perforators exist throughout the

body [6]. In order to correctly plan perforator flaps, we have to know the territory of each perforator, the direction along which the perforator branches travel, and the anastomoses of each perforator with its neighboring perforators. For this purpose, Saint-Cyr et al. have published a study performed on fresh human cadavers; this study is a milestone in understanding the microanatomy of perforators and provides valuable information on how to plan a perforator flap [6]. "It has been reported that each perforasome is linked to the adjacent perforasomes by "direct and indirect linking vessels" [6]. "Indirect linking vessels are effective in capturing adjacent perforasome by means of recurrent blood flow through subdermal plexus" [6]". Indirect linking vessels and the choke vessels of "angiosome theory" reported by Taylor et al. are the same [9]. According to Taylor et al., every angiosome is usually connected to other angiosomes by reduced caliber vessels named "choke vessels." "Direct linking vessels are larger vessels that link adjacent perforators resulting in capturing of neighboring perforasomes based on single perforator [6]." The synonym of direct linking vessels in perforasome theory is "true anastomosis." The vessel calibers of true anastomosis do not change and are especially found in places where vessels are accompanied by cutaneous nerves, in muscles, nerve trunks, or after flaps that have been delayed [10–15]. Therefore, knowledge about the direction along which direct and indirect linking vessels lie is very important to correctly plan perforator flaps because inclusion of direct and indirect perforators secures perforator flaps. Making sure to include direct and indirect linking vessels into the flap enables reconstructive microsurgeons to harvest a larger flap by incorporating neighboring perforasomes into the flap. "Flaps raised from the extremities should be designed parallel to the extremities since the direction of the linking vessels follow the axially of the involved limb [6]." "However, flap design should be made perpendicular to the midline for flaps that will be harvested from the trunk since the axially of the trunk follows the axially of the muscle fibers of posterior trunk and chest, and this is perpendicular to the midline [6]." That is why long axis of anterolateral thigh flaps, posterior tibial artery perforator flaps, medial sural artery perforator flaps, and many other flaps raised on the extremities are planned parallel to the long axis of the extremity, whereas long axis of dorsal intercostal artery perforator flaps, lateral intercostal artery perforator flaps, thoracodorsal artery perforator flaps, and other perforator flaps harvested from trunk and chest wall are planned perpendicular to the midline and have a horizontal oblique direction.

"Vascular filling and density is highest in the perforasomes of perforators from the same source artery, but lower in the neighboring perforasomes of other perforators branching from different source arteries [6]." This is known as the "preferential filling" of perforasomes; preferential filling occurs in the perforators branching from the same source artery initially, but later occurs in the perforators branching from neighboring source arteries. Therefore, it may be concluded that a perforator flap carrying neighboring perforasomes arising from different source arteries harvested on a single perforator will have less perfusion than a flap harvested on single perforator carrying two adjacent perforasomes arising from the same source artery. For example, when a large thoracodorsal artery perforator flap is planned, it must be planned over the latissimus dorsi muscle to incorporate neighboring perforasomes of other perforators arising from the thoracodorsal artery. It must be remembered that if perforasomes of dorsal intercostal artery perforators or circumflex scapular artery perforators



are to be incorporated instead of perforasomes of thoracodorsal artery perforators, the vascular filling pressure of that flap may be less in the perforasomes of other source arteries. This is very important in flap planning.

“Perforators found close to an articulation have a flow distribution away from this articulation [6].” “However, perforators found at a midpoint between two articulations or found at the midpoint of trunk have multidirectional flow distribution [6].” Planning of posterior tibial artery perforator flaps are good examples of perforators found close to articulations. Distal perforators of posterior tibial artery arise 9–12 cm proximal to the medial malleolus of tibia at the ankle joint [16]. Skin island of posterior tibial artery perforator flaps supplied by distal perforators of posterior tibial artery must be planned toward the proximal part of cruris (away from the articulation). On the other hand, perforators of anterolateral thigh flaps arise around the midpoint of the line drawn between anterior superior iliac spine and the superolateral part of patella. That is why, anterolateral thigh flaps may be planned proximal to and distal to the perforator due to the multidirectional flow.

#### 4. Harvesting a perforator flap

Advantages of perforator flaps include the potential to harvest flaps based on any reliable perforator throughout the body that they do not sacrifice major vessels since they are supplied by the branches of these vessels and that they do not necessarily sacrifice muscle if muscle is not needed for reconstruction. In radial forearm flaps, the radial artery is incorporated. Therefore, after the radial forearm flap has been harvested, the whole hand is supplied by ulnar artery only. Sacrificing an artery such as the radial artery is believed to produce considerable morbidity. On the other hand, when perforator flaps are used, the source artery can be preserved. In case of a musculocutaneous perforator, intramuscular dissection may become challenging. However, if intramuscular pedicle dissection is performed, sacrifice of muscle can be avoided. For instance, when a thoracodorsal artery perforator flap is being harvested based on a musculocutaneous perforator, intramuscular dissection must be performed in order to preserve underlying muscle namely latissimus dorsi muscle in this example. The same is true for anterolateral thigh flaps whenever the flap is supplied by a musculocutaneous perforator. However, if needed, such as in the obliteration of a dead space, a muscle cuff can be incorporated into the harvested flap based on a separate perforator.

Tedious dissection is very important in perforator flap harvest. It must be performed under loupe magnification and requires special expertise and experience. Especially, intramuscular perforator dissection can be challenging. That is why, perforator flap harvesting requires a learning curve. For beginners of perforator flap dissection, a detailed anatomy of the perforator flap being harvested must be known and training in one of the experienced centers on perforator flap dissection is strongly recommended.

There is a conflict about the skeletonization of the perforators supplying perforator flaps. Some groups claim that skeletonization of perforators supplying local perforator flaps is not needed, whereas some others, including us, believe that without skeletonization of perforators, flap

harvest is not completed. Groups who do not skeletonize perforating vessels claim that skeletonization of perforators is not performed in order to reduce the risk of damage to the perforating artery and its venae comitantes [17]. We believe that complete skeletonization of perforator is required, since soft tissue and fibrous bands around perforators may cause compression of perforating artery and venae comitantes, thus causing venous insufficiency and/or arterial compromise of perforator flaps. Therefore, we believe that it is a “must” in perforator dissection. We know that skin is supplied by rich vascular plexuses including subepidermal plexus, dermal plexus, subdermal plexus, subcutaneous plexus, prefascial plexus, and subfascial plexus. All these plexuses contribute to the vascularization of skin. Our opinion is to harvest the flap with the fascia overlying the muscle because it is important in vascularization of the harvested flap. This is especially so, when a large flap is being harvested since prefascial and subfascial plexuses will be left intact on the harvested flap.

## 5. Flap circulation

Flap circulation is a dynamic process. Therefore, cadaveric studies are not sufficient to help us understand the exact margins a perforator can supply. It must be remembered that when all the side branches (muscle and cutaneous branches) of a perforator emanating from the source artery are ligated, hyperperfusion of the flap pedicle will occur [6]. Hyperperfusion of the perforator artery and its increased vascular filling cause its dilatation [6]. This, in turn, will open up the anastomotic vessels, namely direct and indirect linking vessels, and result in perfusion of adjacent perforasomes belonging to neighboring perforators [6]. Choke vessels (synonymous with indirect linking vessels) dilate as much as true anastomosis size; however, this takes 2–3 days [12, 13]. During this time, hyperplasia, elongation, and hypertrophy of cells in the tunica intima, media, and adventitia occur. This leads to the thinning of vessel walls, followed by thickening by the seventh day [13]. However, if necrosis occurs, it usually takes place in this anastomotic zone. Perfusion pressure decreases, arteriovenous shunting occurs, and oxygen tension is subsequently lowered during the first 3–4 days, a process that leads to necrosis [18, 19].

There are over 350 perforators throughout the body [6]. Perforator flaps can be potentially harvested from anywhere, where there is a reliable perforator. Perforator flaps can be used as local perforator flaps or as perforator-free flaps. With the report of freestyle free flaps by Wei and Mardini [20], a new gate has been opened for reconstruction of defects using tissues harvested from anywhere of the body provided that tissue encountered is “the most suitable and similar” and is supplied by a reliable perforator. However, freestyle perforator flaps can also be used as local options for soft tissue reconstruction. For local perforator flaps, defect-perforator distance, reliability of perforator, scar tissue around the perforator, and over the planned flap (if there is) must all be considered. As mentioned before, perforator flaps can be used as local perforator flaps or as perforator-free flaps. Perforator-free flaps require vascular anastomosis onto the source vessels or onto other perforating vessels in the recipient site, whereas local perforator flaps do not. Therefore, the dissection part of the operation is similar

in local perforator flaps and perforator-free flaps. However, in order to cover the defect, local perforator flaps are mobilized in a propeller, rotational, advancement, or transpositional movement fashion. Perforator free flaps require vascular anastomosis; therefore, a longer operation is performed. Correct planning of perforator flaps is of primary importance for the success of flaps. Perforators supplying perforator flaps have a static zone and a dynamic zone. The static zone is the zone supplied by the perforator itself, whereas the dynamic zone is the zone a perforator can supply beyond its own perforasome. This means that the dynamic zone is the potential zone of a perforator to supply the perforasomes of neighboring perforators. Saint-Cyr et al. reported that vascular filling of perforators from the same source artery is more, when compared to vascular filling of neighboring perforators from different source arteries, and this is explained by “preferential filling” [6]. Therefore, a perforator flap planned incorporating perforasomes of perforators arising from the same source artery may be safer than that combining perforasomes of perforators from different source arteries. For the same reason, after identifying a large perforator at the desired flap base, Taylor et al. [21] look for another perforator close to the first perforator in all radial directions and combine both perforators on a line drawn in between; this line is going to be the flap axis. They believe that this kind of flap planning is safe [21]. The anatomical territory of a cutaneous perforator is defined as the zone that connects the perforator with adjacent perforators in all directions and is separated from the anatomical zones of other perforators by the anastomotic zone between each anatomical territory. On the other hand, the clinical territory of each perforator is wider than its particular anatomical territory as it usually captures the neighboring anatomical territory of the neighboring perforator. It may even capture the anatomical territory of the one beyond, especially when perforators are linked together by true anastomosis or direct linking vessels [7].

## 6. Assessment of perforator location

Taylor et al. have reported that locating perforators correctly in well-muscled volunteers using a handheld Doppler is comparable with the location of corresponding perforators found in fresh cadavers after dissection and concluded that there was a close correlation [22]. However, investigation in this issue continued. Color Doppler ultrasound and computed tomography angiography (CT angiography) is frequently performed for this purpose. Feng et al. have compared color Doppler ultrasound and CT angiography for their reliability and sensitivity in detecting the location of perforators accurately [23]. They have reported that, preoperative color Doppler ultrasound (95%) is more accurate with respect to CT angiography (82.5%) in detecting the localization of dominant perforators. However, this difference has not been statistically significant. The results obtained with Color Doppler Ultrasound has a mean error of  $1.11 \pm 1.29$  mm, whereas CT angiography has a mean error of  $2.55 \pm 2.63$  mm, a statistically significant difference. On the other hand, the time needed to evaluate the images using CT angiography ( $27.2 \pm 1.77$  minutes) has been less than those used for color Doppler ultrasound ( $34.83 \pm 3.55$  minutes). The success of color Doppler ultrasound has been directly related to the experience of radiologist; however, the same has not been true for CT angiography [23]. Metal implants are known to cause artifact formation in CT angiography images; however, this does



not apply to color Doppler ultrasound. On the other hand, compared to CT angiography, Doppler ultrasound is a cheaper modality [23]. As a result, Feng et al. have advocated the use of color Doppler ultrasound in experienced hands instead of CT angiography for more correctly locating perforators, and also, it is less expensive [23].

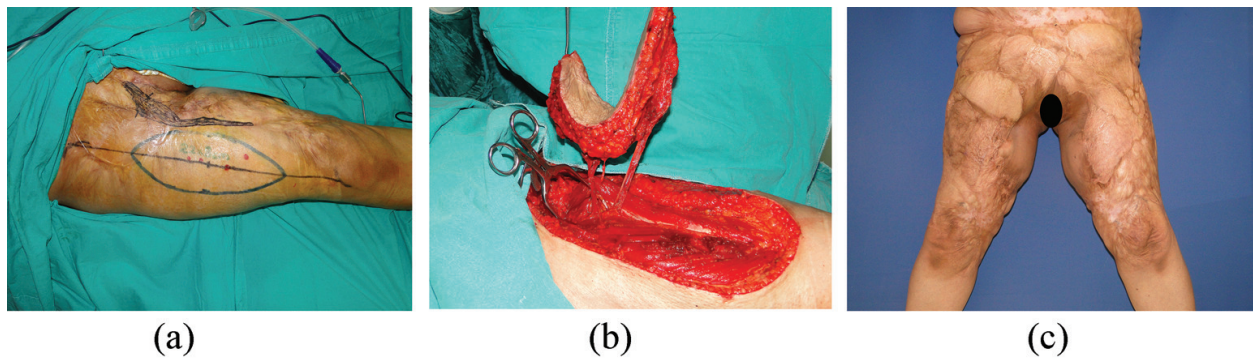
## 7. Risk factors of perforator flaps

In order to identify risk factors of perforator propeller flaps in lower extremity defects, Bekara et al. searched MEDLINE, PubMedCentral, Embase, and Cochrane databases for reported series of lower extremity reconstruction using pedicled perforator propeller flaps between 1991 and 2004 [24]. In total, 428 perforator propeller flaps from 40 articles which performed for lower extremity reconstruction were included in the study [24]. Partial necrosis was found in 10.2%, whereas total flap necrosis was found in 3.5% of cases [24]. Patients older than 60, or patients who had diabetes or arteriopathy, were determined as significant risk factors for flap failure [24]. However, smoking, acute injury, post-traumatic injury, location of defect over the distal third of lower leg, inclusion of fascia, pedicle rotation greater than 120°, accompanying bone fracture, and surface area greater than 100 cm<sup>2</sup> were found to have no significant effect on flap success [24]. Hypertension could not be evaluated due to lack of data [24]. Since this study was a meta-analysis, it had some limitations, however: lack of standardization (different surgical techniques and different approaches by different surgeons, and flaps used for reconstruction), missing data (comorbidity, localization, size of flap, cause, pedicle rotation), and including nonhomogenous patient groups [24]. Nevertheless, it is important to identify risk factors threatening perforator flap viability since patients are to be selected considering those risk factors along with many other factors. Another important issue that must be considered in reconstructive planning is defect etiology. In traumatic defects, post-traumatic vessel disease may have developed [25]. “Post-traumatic vessel disease is defined as progressive changes in vessel and perivascular tissues following trauma” [24] and “loss of normal easy dissection planes, around the vessels, loss of vasa vasorum, increased tendency of vessels to vasospasm or easily damaging vessels during dissection along with lack of thromboresistant properties of healthy vessels” [24]. Therefore, post-traumatic vessel disease is considered as a risk factor in reconstructive surgery, and the reconstructive surgeon must be aware of this. Because of this, the reconstructive surgeon must be familiar with problem solving and must have a special strategy for each case, individualizing each patient during reconstructive planning.

Brief information about some of the workhorse flaps and some case examples will be given in the following section.

## 8. The anterolateral thigh flap

The anterolateral thigh flap is probably the most commonly used perforator flap for reconstruction of soft tissue defects especially when transferred as a free flap. The anterolateral thigh

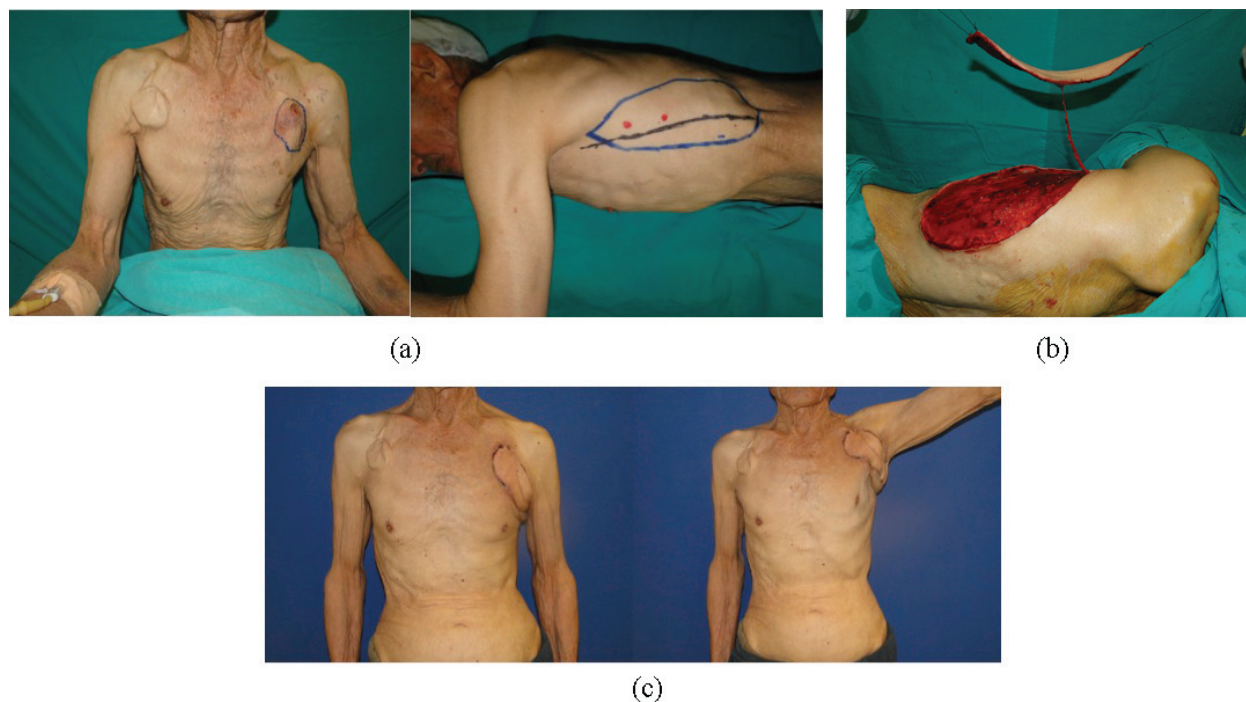


**Figure 1.** (a) The patient is feeling discomfort standing upright because of unstable scarring and a slight contracture over the right inguinal region. The operative plan is to excise the contracture band and reconstruct the defect using a pedicled anterolateral thigh flap. (b) The anterolateral thigh flap has been elevated. Note that two pedicles supplying the flap have been dissected off. (c) Patient as seen 18 months postoperatively. Note that patient can easily abduct and extend her thighs.

flap is supplied by the descending branch of lateral circumflex femoral artery, which is the branch of deep femoral artery [26]. A straight line is drawn from the anterior superior iliac spine to the superolateral edge point of patella [26]. The flap pedicle lies between rectus femoris and vastus lateralis [26]. The perforator supplying this flap can be septocutaneous or musculocutaneous. The anterolateral thigh flap has a long pedicle that is a great advantage for use as a free flap or for use in reconstruction of locoregional defects (**Figure 1**). It can be harvested with a muscle cuff or with fascia according to patients' needs [27]. This flap can be raised with a muscle cuff from vastus lateralis muscle as a chimeric flap [28] or with fascia lata for different reconstructive purposes [29].

## 9. The thoracodorsal artery perforator flap

The source vessel for the thoracodorsal artery perforator flap is the thoracodorsal artery. This artery is a branch of the subscapular system and divides into transverse and descending branches after entering to the latissimus dorsi muscle. According to the cadaveric dissections of Heitmann et al. investigating the anatomical basis of thoracodorsal artery perforator flaps, out of 20 specimens, a total of 64 musculocutaneous perforators larger than 0.5 mm were found [30]. In total, 36 of these perforators were arising from the descending branch whereas 28 were arising from the transverse branch [30]. However, in 11 dissections, there was also a direct cutaneous branch with an extravascular course [30]. The flap is raised in the lateral decubitus position, and an incision lateral to the lateral border of latissimus dorsi muscle is made [31] (**Figure 2**). After the perforator is found, dissection of the perforator is continued until adequate length is reached. However, during dissection of the flap, attention must be paid for preservation of the thoracodorsal nerve [31]. In addition to their local use, thoracodorsal artery perforator flaps are also favorable flaps for transfer as free flaps taking advantage of their long pedicle.



**Figure 2.** (a) An exposed pacemaker is seen over the left pectoral region. The operative plan is to excise the infected skin and reconstruct the defect using a thoracodorsal artery perforator flap. Flap planning is seen. A  $9 \times 9$  cm defect is formed after excision and flap dimensions are  $20 \times 9$  cm. (b) The thoracodorsal artery perforator flap has been elevated. (c) Patient as seen 3 months postoperatively.

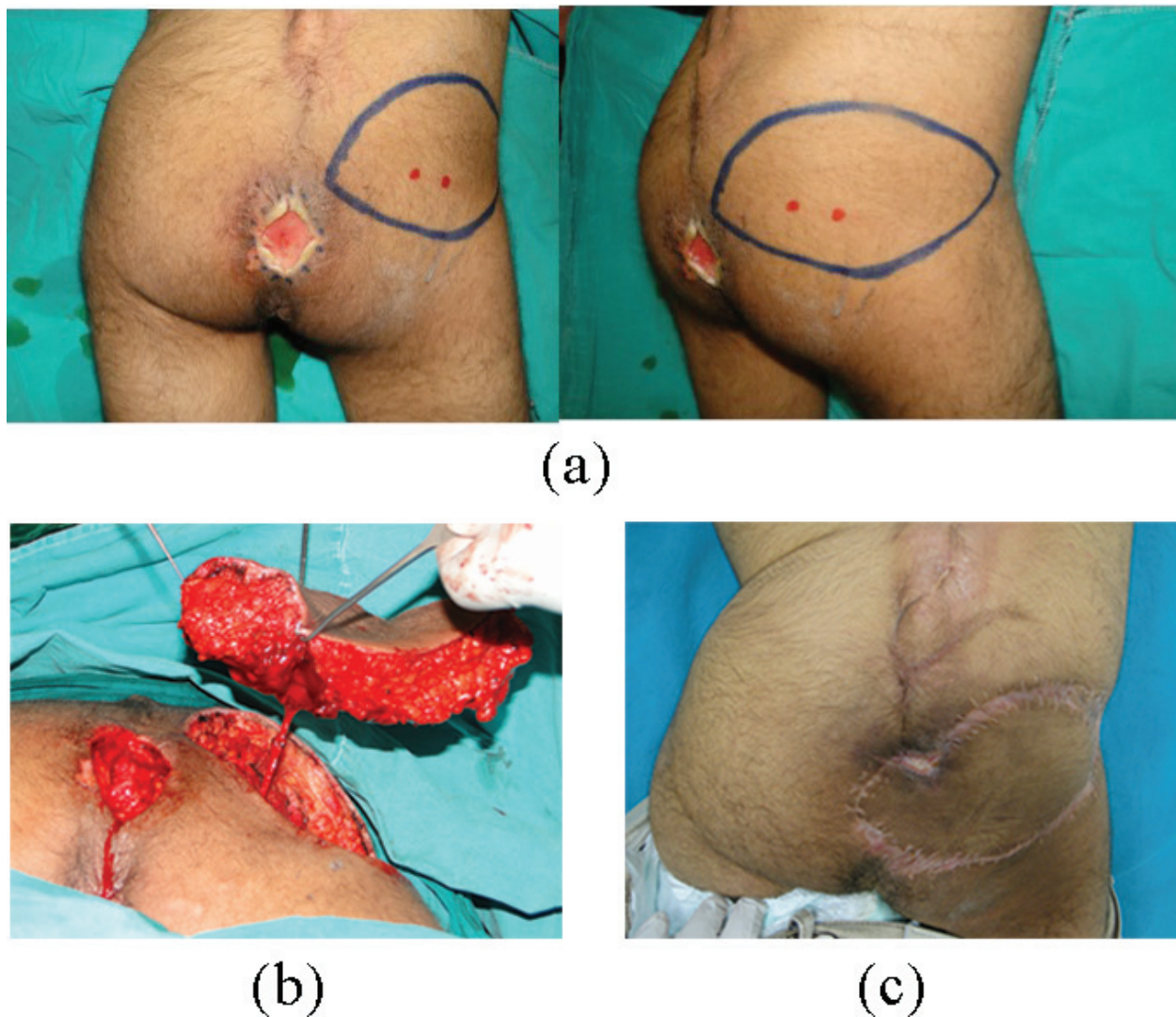
## 10. Superior gluteal artery perforator flap

Koshima et al. were probably the first to report on the use of gluteal artery perforator flaps for reconstruction of sacral pressure sores [32]. Superior gluteal artery perforator flaps can be used in soft tissue reconstruction of locoregional defects as well as in breast reconstruction when used as free flaps [33]. However, for use in breast reconstruction, they are usually indicated in those whom abdominal flaps are risky or cannot be used [31]. Usually, three perforators supply superior gluteal artery perforator flaps [31]. Superior gluteal artery perforators are found one-third of the distance along the line drawn from the posterior superior iliac spine to the greater trochanter [31]. After the localization of the pedicle using a handheld Doppler, the flap may be centered on that pedicle or may be designed eccentrically. After the incisions have been made and the perforator supplying the flap has been found, intramuscular dissection toward the sacrum is performed in order to elongate the flap pedicle (**Figure 3**). Dissection of a single perforator is adequate to supply the flap. However, one can dissect more than one perforator to supply the flap. The donor area can be closed primarily.

## 11. Conclusion

Perforator flaps have evolved as a result of better understanding of the dynamics of the vascular supply and drainage as well as the vascular microanatomy of flaps. Perforator flaps are a step forward in reconstruction of soft tissue defects; they have opened a new era in





**Figure 3.** (a) A presacral pressure sore is seen in a previously operated meningomyelocele patient. The operative plan is to reconstruct the defect using a superior gluteal artery perforator flap. The defect size is  $4.5 \times 5.5$  cm and the planned flap is  $16 \times 8.5$  cm. (b) The superior gluteal artery perforator flap has been elevated based on a single perforator. (c) The patient following reconstruction as seen 1 year postoperatively. Note that a small area of recurrence is seen at the superior border of the flap after 1 year.

reconstructive surgery. Perforator flaps provide very important advantages in reconstructive surgery. Nevertheless, they are not without hazards. For this reason, risk factors in perforator flap surgery and clues to successful planning must be kept in mind while planning reconstruction using perforator flaps.

## Author details

Goktekin Tenekeci

Address all correspondence to: [dr\\_tenekecig@hotmail.com](mailto:dr_tenekecig@hotmail.com)

Department of Plastic, Reconstructive and Aesthetic Surgery, Mersin University Hospital, Mersin, Turkey

## References

- [1] Engel H, Lin CH, Wei FC. Role of microsurgery in lower extremity reconstruction. *Plastic and Reconstructive Surgery*. 2011;**127**(1S):228S-238S
- [2] Blondeel P, Hallock G, Morris SF, Neligan PC. *Perforator Flaps: Anatomy, Technique & Clinical Applications*. St. Louis: Quality Medical Publishing Inc; 2006
- [3] Koshima I, Soeda S. Inferior epigastric artery skin flap without rectus abdominis muscle. *British Journal of Plastic Surgery*. 1989;**42**:645
- [4] Blondeel PN, Van Landuyt KH, Monstrey SJ, et al. The “gent” consensus on perforator flap terminology: Preliminary definitions. *Plastic and Reconstructive Surgery*. 2003;**112**(5):1378-1383
- [5] Blondeel PN, Van Landuyt K, Hamdi M, Monstrey SJ. Perforator flap terminology: Update 2002. *Clinics in Plastic Surgery*. 2003;**30**:343-346
- [6] Saint-Cyr M, Wong C, Schaverien M, et al. The perforasome theory: Vascular anatomy and clinical implications. *Plastic and Reconstructive Surgery*. 2009;**124**(5):1529-1544
- [7] Taylor GI, Corlett RJ, Dhar SC, Ashton MW. The anatomical (angiosome) and clinical territories of cutaneous perforating arteries: Development of the concept and designing safe flaps. *Plastic and Reconstructive Surgery*. 2011;**127**(4):1447-1459
- [8] Taylor GI, Palmer JH. The vascular territories (angiosomes) of the body: Experimental study and clinical applications. *British Journal of Plastic Surgery*. 1987;**40**:113-141
- [9] Lecours C, Saint-Cyr M, Wong C, et al. Freestyle pedicle perforator flaps: Clinical results and vascular anatomy. *Plastic and Reconstructive Surgery*. 2010;**126**(5):1589-1603
- [10] Taylor GI, Corlett RJ. The cutaneous vascular territories in pig and man. Paper Presented at: ASPRS Meeting. New York, NY: Surgical Forum No. 67; 1981
- [11] Callegari PR, Taylor GI, Caddy C, et al. An anatomic review of the delay phenomenon: I. Experimental studies. *Plastic and Reconstructive Surgery*. 1992;**89**:397-407
- [12] Morris SF, Taylor GI. Predicting the survival of experimental skin flaps based on a knowledge of the vascular architecture. *Plastic and Reconstructive Surgery*. 1993;**92**:1352-1371
- [13] Dhar S, Taylor GI. The delay phenomenon: The story unfolds. *Plastic and Reconstructive Surgery*. 1999;**104**:2079-2091
- [14] Taylor GI, Corlett RJ, Caddy CM, Zelt RG. An anatomic review of the delay phenomenon: II. Clinical applications. *Plastic and Reconstructive Surgery*. 1992;**89**:408-416
- [15] Taylor GI. The delayed TRAM flap for breast reconstruction: Why, when and how. *Operative Techniques in Plastic and Reconstructive Surgery*. 1999;**6**:74-82
- [16] Chan Wei F. *Flaps and Reconstructive Surgery*. China: Elsevier; 2009
- [17] Shin IS, Lee DW, Rah DK, Lee WJ. Reconstruction of pretibial defect using pedicled perforator flaps. *Archives of Plastic Surgery*. 2012;**39**(4):360-366



- [18] Boyd BJ, Markland B, Dorion D, Pang CY, Morris S. Surgical augmentation of skin blood flow and viability in a pig musculocutaneous flap model. *Plastic and Reconstructive Surgery*. 1990;**86**:731-738
- [19] Dorion D, Boyd JB, Pang CY. Augmentation of transmidline skin perfusion and viability in transverse rectus abdominis myocutaneous (TRAM) flaps in pigs. *Plastic and Reconstructive Surgery*. 1991;**88**:642-649
- [20] Wei FC, Mardini S. Free-style free flaps. *Plastic and Reconstructive Surgery*. 2004;**114**:910-916
- [21] Taylor GI, Gianoutsos MP, Morris SF. The neurovascular territories of the skin and muscles anatomic study and clinical implications. *Plastic and Reconstructive Surgery*. 1994;**94**:1-36
- [22] Taylor GI, Doyle M, McCarten G. The Doppler probe for planning flaps: Anatomical study and clinical applications. *British Journal of Plastic Surgery*. 1990;**43**:1-16
- [23] Feng S, Min P, Grasetti L, et al. A prospective head-to-head comparison of color doppler ultrasound and computed tomographic angiography in the preoperative planning of lower extremity perforator flaps. *Plastic and Reconstructive Surgery*. 2016;**137**(1):335-347
- [24] Bekara F, Herlin C, Mojollal A, et al. A systematic review and meta-analysis of perforator-pedicled propeller flaps in lower extremity defects: Identification of risk factors for complications. *Plastic and Reconstructive Surgery*. 2016;**137**(1):314-331
- [25] Acland RD. Refinements in lower extremity free flap surgery. *Clinics in Plastic Surgery*. 1990;**17**:733-744
- [26] DC X, Zhong SZ, Kong JM, et al. Applied anatomy of the anterolateral femoral flap. *Plastic and Reconstructive Surgery*. 1988;**82**:305-310
- [27] Mohan AT, Sur YJ, Zhu L, et al. The concepts of propeller, perforator, keystone, and other local flaps and their role in the evolution of reconstruction. *Plastic and Reconstructive Surgery*. 2016;**138**(4):710-729
- [28] Ozkan O, Ozkan O, Derin AT, et al. True functional reconstruction of total or subtotal glossectomy defects using a chimeric anterolateral thigh flap with both sensorial and motor innervation. *Annals of Plastic Surgery*. 2015;**74**(5):557-564
- [29] Yildirim S, Taylan G, Akoz T. Use of fascia component of the anterolateral thigh flap for different reconstructive purposes. *Annals of Plastic Surgery*. 2005;**55**(5):479-484
- [30] Heitmann C, Guerra A, Metzinger SW, et al. The thoracodorsal artery perforator flap: Anatomic basis and clinical application. *Annals of Plastic Surgery*. 2003;**51**(1):23-29
- [31] Saint-Cyr M, Schaverien MV, Rohrich RJ. Perforator flaps: History, controversies, physiology, anatomy, and use in reconstruction. *Plastic and Reconstructive Surgery*. 2009;**123**(4):132-145
- [32] Koshima I, Moriguchi T, Soeda S, et al. The gluteal perforator-based flap for repair of sacral pressure sores. *Plastic and Reconstructive Surgery*. 1993;**91**:678-683
- [33] Guerra AB, Allen RJ, Dupin CL. Breast reconstruction with the superior gluteal artery perforator (S-GAP) flap. *Seminars in Plastic Surgery*. 2002;**16**:27-34

