

We are IntechOpen, the world's leading publisher of Open Access books Built by scientists, for scientists

6,900

Open access books available

185,000

International authors and editors

200M

Downloads

Our authors are among the

154

Countries delivered to

TOP 1%

most cited scientists

12.2%

Contributors from top 500 universities



WEB OF SCIENCE™

Selection of our books indexed in the Book Citation Index
in Web of Science™ Core Collection (BKCI)

Interested in publishing with us?
Contact book.department@intechopen.com

Numbers displayed above are based on latest data collected.
For more information visit www.intechopen.com



Cirrhotic Ascites: Pathophysiological Changes and Clinical Implications

Abdulrahman Bendahmash, Hussien Elsiesy and
Waleed K. Al-hamoudi

Additional information is available at the end of the chapter

<http://dx.doi.org/10.5772/intechopen.70537>

Abstract

Liver cirrhosis is associated with a wide range of systemic and pulmonary vascular abnormalities. Cardiac dysfunction also occurs in patients with advanced liver disease (cirrhotic cardiomyopathy). The circulation in cirrhosis is hyperdynamic, which is typically characterized by hypotension resulting from the associated vasodilatation and reflex tachycardia. The circulatory dysfunction in cirrhosis is the proposed pathophysiological mechanism leading to sodium and water retention in patients with liver cirrhosis. Hyperdynamic circulation is triggered by increased intrahepatic resistance due to cirrhosis, leading to a progressive increase in portal venous pressure. As portal hypertension worsens, local production of vasodilators increases due to endothelial activation, leading to splanchnic and systemic arterial vasodilation. Nitric oxide (NO) is considered one of the most important vasodilator molecules in the splanchnic and systemic circulation. The reduction in the effective arterial blood volume results in diminished renal arterial blood flow and subsequently triggers the rennin-angiotensin-aldosterone system (RAAS), antidiuretic hormones (ADHs) and sympathetic nervous system (SNS), leading to renal artery vasoconstriction. All these changes lead to sodium retention and volume expansion, manifested as ascites and peripheral edema. Furthermore, disease progression is associated with various degrees of renal dysfunction.

Keywords: cirrhosis, portal hypertension, hyperdynamic circulation, ascites

1. Introduction

Liver cirrhosis is associated with a wide range of systemic and pulmonary vascular abnormalities. Cardiac dysfunction has also been described in patients with advanced liver disease (cirrhotic cardiomyopathy) [1–4]. The circulation in cirrhosis has been described as being

hyperdynamic, which is typically characterized by hypotension resulting from the associated vasodilatation and reflex tachycardia. These cardiovascular abnormalities play a major role in the pathogenesis of multiple life-threatening complications, including ascites, spontaneous bacterial peritonitis, hepatorenal syndrome (HRS), esophageal varices and pulmonary related complications [5, 6]. The hyperdynamic circulation is triggered by increased intrahepatic resistance due to cirrhosis, leading to a progressive increase in portal venous pressure [7, 8]. As portal hypertension worsens, there is an increased local production of vasodilators due to endothelial activation, leading to splanchnic and systemic arterial vasodilation. Nitric oxide (NO) is thought to be one of the most important vasodilator molecules in the splanchnic and systemic circulation. NO is overproduced in cirrhosis; measured serum levels are significantly elevated in both cirrhotic patients and in animal models [9–11]. The reduction in the effective arterial blood volume results in diminished renal arterial blood flow and subsequently triggers the rennin-angiotensin-aldosterone system (RAAS), antidiuretic hormone (ADH) and sympathetic nervous system (SNS), leading to renal artery vasoconstriction. All these changes lead to sodium retention and volume expansion, manifested as ascites and peripheral edema. Furthermore, advanced liver disease is usually associated with various degrees of renal dysfunction. In cirrhotic patients with hepatorenal syndrome (HRS), renal plasma flow and glomerular filtration rate (GFR) are significantly diminished and may reach levels similar to those seen in patients with advanced renal disease [12, 13]. Sodium retention usually occurs in association with the inability to excrete a normal water load, resulting in increased total body water and dilutional hyponatremia [14, 15]. However, unlike the situation of end-stage renal disease, no significant histological abnormality is present within the kidneys of patients with HRS, and the process is reversible after liver transplantation (LT) [16]. The aim of this chapter is to discuss the impact of portal hypertension on the cardiovascular system in cirrhosis, with special emphasis on the pathogenesis of ascites.

2. Ascites

The peritoneum is a serous membrane made up of visceral and parietal layers. The parietal peritoneum lines the coelomic cavity, and the visceral layer of the peritoneum lines the surface of organs. The peritoneal cavity is an empty space between the visceral and parietal layers of the peritoneum. The potential space of the peritoneal cavity is normally not visible on imaging as it contains only a small amount of fluid (approximately 100 mL). The fluid is mostly water with electrolytes, antibodies, white blood cells, albumin, glucose and other biochemicals [17]. Its main function is to reduce the friction between the abdominal organs as they move around during digestion. The word ascites is derived from the Greek word “askos,” which means a bag or sack and is defined as pathological fluid accumulation within the peritoneal cavity. Ascites is a frequent complication of cirrhosis and portal hypertension because of the increase of the sinusoidal hydrostatic pressure. Cirrhosis accounts for over 75% of episodes of ascites, with all other causes accounting for less than 25% (**Table 1**) [18]. Ascites has been associated with increased morbidity and mortality, with liver transplant-free mortality rates ranging from 15 to 20% at 1 year to nearly 50–60% at 5 years from the time of diagnosis [19, 20].

Causes of ascites
Portal hypertension
Infection
Heart failure
Malignancy and hematological disorders
Connective tissue disease
Pancreatic disease
Nephrotic syndrome
Severe malnutrition
Congenital causes

Table 1. Causes of ascites.

3. The heart (cirrhotic cardiomyopathy)

In 1953, Kowalski and Abelmann described an abnormal circulatory pattern in a group of cirrhotic patients. They examined the circulation in 22 alcoholic cirrhotic patients and concluded that these patients had a large stroke volume, prolonged Q-T interval and reduced peripheral vascular resistance. They were some of the first researchers to question the impact of liver disease on the heart [21]. These findings were then confirmed in multiple experimental models of portal hypertension and in patients with cirrhosis. Initially, it was thought that these circulatory manifestations were secondary to alcoholic-related malnutrition; however, future studies confirmed the same circulatory dysregulation in cirrhotic patients with various underlying etiologies [1–4]. In the absence of known cardiac disease, the diagnostic criteria for cirrhotic cardiomyopathy rest on the presence of an attenuated systolic or diastolic response to stressful stimuli and are supported by the presence of structural or histological changes in cardiac chambers, electrophysiological abnormalities and elevation in serum markers suggestive of cardiac stress [22]. In addition to abnormal systolic dysfunction, cirrhotic patients also clearly demonstrate abnormal diastolic dysfunction, especially in patients with ascites, and it has been shown that paracentesis can improve diastolic dysfunction. Left ventricular (LV) diastolic dysfunction manifests as impaired LV relaxation secondary to LV wall stiffness, which results in the increase in filling pressure. Glenn et al. investigated the role of passive tension regulators—titin and collagen—in the pathogenesis of cirrhotic diastolic dysfunction. They showed that alterations in titin modulation, PKA levels, and collagen configuration contributed to the pathogenesis of this condition [23]. Velocity of blood flow from the left atrium to the left ventricle during early (E wave) and late (A wave) phases of diastole can help in assessing diastolic function. A low E/A ratio indicates a non-compliant ventricle [24]. This finding was also confirmed in other studies [25, 26]. Multiple factors affecting cardiac cell function have been implicated in the pathogenesis of cirrhotic cardiomyopathy, including: (a) Down regulation of β -adrenergic receptors, which negatively

impacts cardiac contractility [27]; (b) Reduction in the cardiac cell membrane fluidity, which impairs the function of membrane-bound ion channels, alters control of vascular tone and reduces the β -adrenoceptor function [28, 29]; (c) Reduced muscarinic receptor activity, which has a negative inotropic effect on the heart [30]; (d) Augmented nitric oxide activity, which negatively impacts cardiac contractility [31, 32]; (e) Carbon monoxide (CO) and endocannabinoid activity negatively impacts cardiac contractility in cirrhotic patients [33–35]. Multiple other studies have demonstrated significant structural cardiac abnormalities in all cardiac chambers of cirrhotic patients [36].

4. Systemic and splanchnic circulation

Portosystemic collaterals are formed secondary to cirrhosis-induced portal hypertension, which allows gut-derived humoral substances to directly enter systemic circulation without detoxification by the liver. Arterial vasodilatation in portal hypertension results from the predominant production of various vasodilators [37]. NO is thought to be the major vasodilator molecule in cirrhotic patients. The intrahepatic microcirculation is altered significantly in liver cirrhosis, secondary to both architectural and vasoactive humoral changes, resulting in an increase in vasoactive molecules associated with a decrease in intrahepatic NO production [38, 39]. On the other hand, multiple studies have documented an elevated serum level of NO in the systemic and splanchnic circulation in both cirrhotic patients and in animal models [40–43]. NO is an endothelial-derived relaxing factor that leads to systemic arterial vasodilatation. Three isoforms of NO synthase (NOS) have been described: endothelial (eNOS), inducible (iNOS), and neuronal (nNOS). However, the leading isoform contributing to these vascular changes remains obscure [44]. Ferguson and colleagues were the first group to use a highly selective iNOS inhibitor to evaluate the role iNOS in the regulation of vascular tone in patients with ascites. Forearm blood flow was measured in eight patients with ascites and was compared with eight matched healthy volunteers, during intrabrachial infusion of 1400 W (0.1–1 $\mu\text{mol/min}$), NG-monomethyl-L-arginine (L-NMMA, a non-selective NOS inhibitor; 2–8 μmol), and norepinephrine. They showed that iNOS inhibitor causes systemic vasoconstriction in patients with ascites only. This supports the role of iNOS in the circulatory changes associated with cirrhosis [45]. One major factor that plays an important role in promoting NO production is the altered intestinal permeability in patients with advanced liver disease. As a result various endotoxins cross the intestine to the systemic circulation and stimulate the production of NO [46, 47]. TNF- α is also considered to be a NO inducers. Inhibition of TNF- α production resulted in improvement in the hyperdynamic circulation in various animal model studies [48, 49]. Endocannabinoids have also been implicated in the peripheral vasodilatation of cirrhosis. Activation of endothelial cannabinoid receptors by the endogenously produced endocannabinoids causes pronounced vasodilatation in cirrhotic rats [50, 51]. Interestingly, multiple studies have shown a potentially important role of the central nervous system (CNS) in the pathogenesis of the portal hypertension-induced hyperdynamic circulation. The cardiovascular system is controlled by neural influences that include the central nervous system (CNS) and peripheral afferent and efferent nerves. Portal hypertension activates receptors in the mesenteric area; the signals are relayed to central

Pathogenic mechanisms	Cardiovascular effect
Down regulation of β -adrenergic receptors	Decreases cardiac contractility
Reduction in the cardiac cell membrane fluidity	Alters control of vascular tone and reduces the β -adrenoceptor function
Reduced muscarinic receptor activity	Negative inotropic effect on the heart
Augmented nitric oxide activity	Decreases cardiac contractility
Carbon monoxide	Decreases cardiac contractility
Endocannabinoid activity	Decreases cardiac contractility
Portosystemic collaterals	This allows gut-derived humoral substances to directly enter the systemic circulation augmenting the hyperdynamic circulation
Systemic nitric oxide	Systemic vasodilatation
Central nervous system-gut-axis	Denervation prevents the development of hyperdynamic circulation and ascites formation
Activation of renin-angiotensin aldosterone system, sympathetic nervous system and nonosmotic release of antidiuretic hormone	Restores the normal hemodynamics in the setting of a hyperdynamic circulation through sodium and water retention

Table 2. Pathogenic mechanisms of cardiovascular disturbance in cirrhotic patients.

cardiovascular-regulatory nuclei via afferent nerves. These nuclei then process the inputs and send out signals to the cardiovascular system through efferent pathways, leading to cardiovascular changes [52]. Li and colleagues demonstrated that neonatal capsaicin denervation in rats prevented the development of hyperdynamic circulation and renal dysfunction as well as ascites formation in cirrhosis. These results indicate that intact primary afferent innervation is necessary for the development of hyperdynamic circulation and ascites formation [53]. A recent study revealed reversal of the cirrhosis associated vascular dysregulation after afferent denervation in an animal model. Portal vein ligation in cirrhotic rats activates a marker protein in the brain stem indicating CNS activation. Furthermore, blocking CNS Fos expression in cirrhotic rats resulted in eliminating the development of the hyperdynamic circulation [54]. The various potential pathogenic mechanisms leading to cardiovascular disturbance and fluid retention are summarized in **Table 2**.

5. The lymphatic system

The lymphatic vascular system plays a critical role in ascites formation [55]. Lymphatic vessels remove fluid from the interstitial fluid from various parts of the body and drain it into the blood stream. In healthy adult individuals, the lymphatic system returns as much as eight liters of interstitial fluid with 20–30 g of protein per liter to venous circulation every day. Any disturbance to this process leads to fluid accumulation, manifested as edema and ascites [55–58]. As with systemic and splanchnic circulation, the lymphatic system is also influenced by nitric oxide, leading to vasodilatation [59]. The development of portal

hypertension in cirrhosis is associated with an increase in portal lymph flow. Normally, the liver produces a large amount of lymph, which is estimated to be over 25% of the lymph flowing through the thoracic duct. Barrowman and colleagues demonstrated an increase in lymph flows from the intestine and liver in cirrhotic animals by threefold and 30-fold, respectively, over values obtained from control animals. They also demonstrated a good correlation between intestinal and liver lymph flows and portal venous pressure [60]. In portal hypertension, compensatory lymphangiogenic response may initially help to reduce the high portal pressure. Oikawa and colleagues used a morphometric analysis to examine portal hypertensive-associated changes in lymph vessels and branches of the portal vein, with use of immunohistochemical staining for alpha smooth muscle actin, and quantitated these changes using an image analysis system. They obtained wedge liver biopsies from 10 patients with advanced portal hypertension and 10 control samples from patients with gastric carcinoma without liver disease. They showed that the proliferation of lymph vessels were higher in portal hypertension samples compared to the control samples. On the other hand, the number of portal vein branches in portal hypertension samples was not different from control samples. They concluded that these alterations in portal hypertension may result in a decrease in portal flow associated with an increase in lymph flow resulting in a reduction of the high portal vein pressure in idiopathic portal hypertension [61]. With worsening liver fibrosis and ongoing portal hypertension, the lymphatic system fails, resulting in buildup of interstitial fluids and ascites formation [55].

6. Renal response

The systemic vasodilation in patients with cirrhosis leads to under filling of arterial vascular space and that leads to systemic hypotension. Consequently, baroreceptor-mediated activation of the renin-angiotensin-aldosterone system (RAAS) and sympathetic nervous system (SNS) and nonosmotic release of antidiuretic hormone (ADH) occur to restore normal hemodynamics. This leads to fluid and sodium retention (**Figure 1**). Sodium retention is the most common abnormality of renal function in patients with cirrhosis and ascites [12, 62, 63]. The total amount of sodium retained in patients with cirrhosis is dependent on sodium intake, non-renal sodium losses and sodium excreted in the urine. Minimizing sodium intake in cirrhotic patients may help control ascites. With ongoing hemodynamic disturbance in cirrhosis, the equation tips toward sodium retention. Associated with this is an increase in splanchnic permeability that, aided by the changes in oncotic pressure, combines to lead to ascites formation [63]. In the initial phases of the disease, this is compensated by an increase in lymph return. In fact, the thoracic duct lymph flow, which in normal conditions is lower than 1 liter per day, may increase by several folds. When lymph formation overcomes lymph drainage, this also results in ascites formation. As a result, renal vasoconstriction persists and results in various degrees of renal impairment. The extreme effect would result in severe renal failure with elevation of blood urea nitrogen and serum-creatinine concentration. The associated hyponatremia in portal hypertensive ascites carries a bad prognostic value and has been linked to mortality [64].

Refractory ascites refers to ascites that cannot be resolved by dietary sodium restriction and diuretic treatment. The severity of renal sodium retention increases with the progression of

MECHANISM OF ASCITES

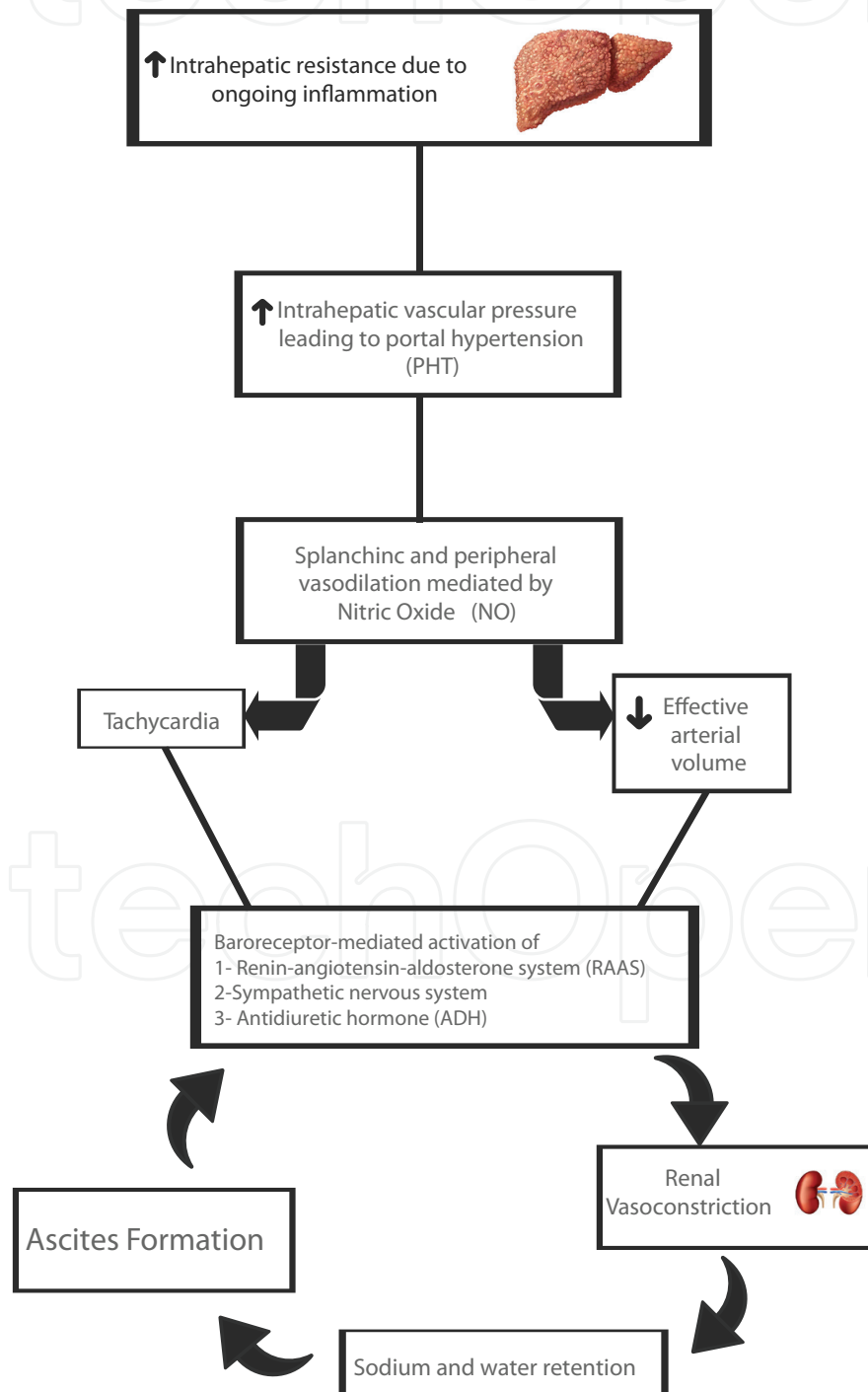


Figure 1. The cascade of changes leading to ascites formation.

the underlying liver disease and associated portal and systemic hemodynamic disturbance. The ongoing activation of the various neurohumoral pathways leads to aggressive renal reabsorption of sodium and water. Activation of the neurohormonal pathway also leads to a reduction in the glomerular filtration rate (GFR) and subsequently leads to a decline in the renal function. The enhanced sodium reabsorption at the proximal convoluted tubule leads to a significant reduction in the sodium reaching the distal segments of the nephron. This explains the failure of loop diuretics and antimineralocorticoid in treating these patients as they work predominantly at the distal segments of the nephron. Thus, renal sodium retention mainly occurs proximally to the site of action of both antimineralocorticoid and loop diuretics, and this can explain why diuretic treatment becomes unsuccessful in some patients. Furthermore, when cirrhosis progresses and the arterial vasodilation becomes more marked, the heart can no longer keep pace with the marked systemic vasodilatation. This results in an increase in the production of endogenous vasoactive compounds, which further increases sodium and water retention as a result of this physiological response to the relative arterial underfilling [63, 64]. This increased sodium and water retention contributes to increasing ascites, and in many cases, to the development of refractory ascites and type 2 HRS. Kraq and colleagues investigated the relation between cardiac and renal function in patients with cirrhosis and ascites and the impact of cardiac systolic function on survival. Cardiac function was investigated by gated myocardial perfusion imaging for assessment of cardiac index and cardiac volumes. Renal function was assessed by determination of GFR and renal blood flow, and the patients were followed up for 12 months. They demonstrated that patients with a low CI had a lower GFR and a higher creatinine level. The number of patients who developed type 1 HRS within 3 months was significantly higher in the group with low CI than that in the group with high CI. They also showed that patients with the lowest CI had significantly poorer survival at 3, 9, and 12 months than did those with a higher CI [65].

7. Clinical implications

This circulatory dysfunction in cirrhosis is the proposed pathophysiological mechanism leading to sodium and water retention in patients with liver cirrhosis. Treatment aimed at reversing this pathophysiological process would likely result in improving the outcome. Albumin has been used in clinical trials as a volume expander and, when given with a vasoconstrictor, has been shown to improve renal function in the setting of cirrhotic ascites. Martín-Llahí and colleagues randomized 46 patients with cirrhosis and HRS to receive terlipressin, a vasopressin analog, and albumin ($n = 23$) or albumin alone ($n = 23$) for a maximum of 15 days. They monitored renal function closely during the study period. Improvement of renal function occurred in 10 patients (43.5%) treated with terlipressin and albumin compared with that in two patients (8.7%) treated with albumin alone ($P = .017$) [66]. Similarly, Guevara and colleagues treated 16 patients with HRS with a combination of ornipressin, a potent vasoconstrictor agent, and albumin to improve the cardiovascular dysfunction. The combined treatment was administered for either 3 or 15 days (eight patients each). The shorter treatment duration was associated with normalization of the overactivity of renin-angiotensin and sympathetic nervous systems, a marked increase in atrial-natriuretic peptide levels, and

only a slight improvement in renal function. However, when treatment was administered for 15 days outcome was significantly better. Renal function improved dramatically manifested by normalization of serum creatinine associated with an increase in the GFR and a persistent suppression in the activity of vasoconstrictor systems [67]. In another study, Ortega and colleagues showed that terlipressin therapy reverses HRS, and the effect was augmented when coupled with albumin [68]. Patel and colleagues assessed the efficacy of midodrine and octreotide as a therapeutic approach to increasing urinary electrolyte-free water clearance in advanced cirrhosis. Patients were treated with albumin, midodrine and octreotide within the first 24 h. Urinary electrolyte-free water clearance and serum sodium concentration were assessed before and 72 h after treatment. The assessments showed a statistically significant increase in serum sodium concentration and urinary electrolyte-free water clearance with the use of midodrine and octreotide in the treatment of cirrhosis-associated hyponatremia [69]. These studies demonstrate the importance of targeting circulatory dysfunction in end-stage liver disease. A more challenging aspect in managing these patients is the associated cirrhotic cardiomyopathy. The development of HRS in the setting of advanced liver disease is associated with a drop in the cardiac output, emphasizing the additional role of cirrhotic cardiomyopathy in the pathogenesis of hepatorenal dysfunction [65]. Other reports suggested a possible role of cirrhotic cardiomyopathy in spontaneous bacterial peritonitis [70].

Transjugular intrahepatic portosystemic shunts (TIPS) have been commonly used to treat refractory ascites. Following TIPS insertion, a sudden increase in the preload results in further hemodynamic disturbance, and therefore, careful cardiovascular evaluation prior to the procedure is a necessity [71, 72]. The preexisting subclinical diastolic dysfunction becomes clinically obvious with the sudden increase in the right atrial and pulmonary circulation, leading to heart failure. In a recent study, Ascha and colleagues investigated if echocardiographic and hemodynamic changes at the time of TIPS can provide any prognostic information. After evaluating 418 patients, they showed that a change in the right atrial (RA) pressure after TIPS predicted long-term mortality [73]. Others showed a possible impact of intra-procedural RA pressure on early post-TIPS mortality [74]. Other studies suggested that an E/A ratio of ≤ 1 was predictive of slow ascites clearance and mortality post-TIPS insertion [75, 76].

Liver transplantation results in correction of portal hypertension and reversal of all the pathophysiological mechanisms that lead to hyperdynamic circulation [77]. We studied the hemodynamics in the immediate post-transplant period and compared patients with alcoholic vs. viral cirrhosis. Within the first 24 h, there was a significant decrease in HR and increase in MAP; the extent of the change was similar in both groups. The central venous pressure (CVP), pulmonary capillary wedge pressure (PCWP), and systemic vascular resistance index (SVRI) increased, and changes were more pronounced in the viral group [78]. Navasa and colleagues assessed systemic hemodynamics and plasma levels of aldosterone, glucagon and plasma renin in 12 patients with advanced cirrhosis before and 2 weeks and 2 months after LT. Elevated aldosterone, plasma renin and glucagon levels decreased to near-normal values 2 weeks after transplantation. This decrease was associated with reversal of the associated splanchnic and systemic vasodilation and restoration of normal hemodynamics [79]. Following LT, the rapid reversal of systemic vasodilatation and the associated increase in blood pressure exposes the previously subclinical cirrhotic cardiomyopathy. Cardiovascular

complications are a major cause of postoperative morbidity and mortality after liver transplantation [80]. Fouad and colleagues reviewed 197 liver transplant recipients for post-liver transplant-related cardiac complications. Eighty-two patients suffered one or more cardiac complications within 6 months after LT. Pulmonary edema was the most common complication, occurring in 61 patients; other complications included heart failure (7 patients), arrhythmia (13 patients), pulmonary hypertension (7 patients), pericardial effusion (2 patients), and cardiac thrombus formation (1 patient). In their study, cardiac causes were the leading cause of death (23.8% of all mortality) [81].

LT induces significant cardiovascular stress. Predicting the development of postoperative cardiac complications is very difficult. Two-dimensional and dobutamine stress echocardiography were utilized to predict the development of adverse cardiac events following liver transplantation, and both had a low predictive value [82]. More recently, a study utilizing dobutamine stress perfusion, which provides an assessment of both regional systolic and diastolic function as well as microvascular perfusion, revealed a better prediction of post-transplant cardiac outcome [83]. Management at the time of liver transplantation should involve careful fluid management. Immediate postoperative care should include continuous cardiac and hemodynamic monitoring and early detection of any potential arrhythmia or any other cardiac complication.

Author details

Abdulrahman Bendahmash¹, Hussien Elsiey^{2,3} and Waleed K. Al-hamoudi^{2,4*}

*Address all correspondence to: walhamoudi@gmail.com

1 Department of Pediatrics, King Faisal Specialist Hospital & Research Center, Riyadh, Saudi Arabia

2 Department of Liver Transplantation, King Faisal Specialist Hospital & Research Center, Riyadh, Saudi Arabia

3 Department of Medicine, Alfaisal University, Riyadh, Saudi Arabia

4 Department of Medicine, College of Medicine, King Saud University, Riyadh, Saudi Arabia

References

- [1] Ma Z, Lee SS. Cirrhotic cardiomyopathy: Getting to the heart of the matter. *Hepatology*. 1996;**24**:451-459
- [2] Møller S, Henriksen JH. Cirrhotic cardiomyopathy: A pathophysiological review of circulatory dysfunction in liver disease. *Heart*. 2002;**87**:9-15
- [3] Al Hamoudi W, Lee SS. Cirrhotic cardiomyopathy. *Annals of Hepatology*. 2006 Jul-Sep; **5**(3):132-139

- [4] Al-Hamoudi WK. Cardiovascular changes in cirrhosis: Pathogenesis and clinical implications. *Saudi Journal of Gastroenterology*. 2010 Jul-Sep;16(3):145-153
- [5] Salerno F, Gerbes A, Wong F, et al. Diagnosis, prevention and treatment of hepatorenal syndrome in cirrhosis. *Gut*. 2007;56:1310-1318
- [6] Arroyo V, Gines P, Gerbes AL, et al. Definition and diagnostic criteria of refractory ascites and hepatorenal syndrome in cirrhosis. *International ascites Club Hepatology*. 1996;23:164-176
- [7] Gines P, Fernandez-Esparrach G, Arroyo V, et al. Pathogenesis of ascites in cirrhosis. *Seminars in Liver Disease*. 1997;17:175-189
- [8] Arroyo V, Badalamenti S, Gines P. Pathogenesis of ascites in cirrhosis. *Minerva Medica*. 1987;78:645-650
- [9] Chang SW, Ohara N. Chronic biliary obstruction induces pulmonary intravascular phagocytosis and endotoxin sensitivity in rats. *The Journal of Clinical Investigation*. 1994;94:2009-2019
- [10] Carter EP, Hartsfield CL, Miyazono M, Jakkula M, Morris KG Jr, McMurtry IF. Regulation of heme oxygenase-1 by nitric oxide during hepatopulmonary syndrome. *American Journal of Physiology. Lung Cellular and Molecular Physiology*. 2002;283:L346-L353
- [11] Sztrymf B, Rabiller A, Nunes H, Savale L, Lebrec D, Le Pape A, et al. Prevention of hepatopulmonary syndrome and hyperdynamic state by pentoxifylline in cirrhotic rats. *The European Respiratory Journal*. 2004;23:752-758
- [12] Jalan R, Forrest EH, Redhead DN, et al. Reduction in renal blood flow following acute increase in the portal pressure: Evidence for the existence of a hepatorenal reflex in man? *Gut*. 1997;40:664-670
- [13] Ming Z, Smyth DD, Lautt WW. Decreases in portal flow trigger a hepatorenal reflex to inhibit renal sodium and water excretion in rats: Role of adenosine. *Hepatology*. 2002;35:167-175
- [14] Arroyo V, Claria J, Salo J, Jimnez W. Antidiuretic hormone and the pathogenesis of water retention in cirrhosis with ascites. *Seminars in Liver Disease*. 1994;14:44-58
- [15] McCullough AJ, Mullen KD, Kalhan SC. Measurements of total body and extracellular water in cirrhotic patients with and without ascites. *Hepatology*. 1991;14:1102-1111
- [16] Mindikoglu AL, Pappas SC. New developments in Hepatorenal syndrome. *Clinical Gastroenterology and Hepatology*. 2017 Jun 7; pii: S1542-3565(17)30672-9 [Epub ahead of print]
- [17] Pannu H, Oliphant M. The subperitoneal space and peritoneal cavity: Basic concepts. *Abdominal Imaging*. 2015;40(7):2710-2722
- [18] Reynolds TB. Ascites. *Clinics in Liver Disease*. 2000;4:151-168

- [19] Planas R, Montoliu S, Ballesté B, et al. Natural history of patients hospitalized for management of cirrhotic ascites. *Clinical Gastroenterology and Hepatology*. 2006;**4**:1385-1394
- [20] Heuman DM, Abou-Assi SG, Habib A, et al. Persistent ascites and low serum sodium identify patients with cirrhosis and low MELD scores who are at high risk for early death. *Hepatology*. 2004;**40**:802-810
- [21] Kowalski HJ, Abelmann WH. The cardiac output at rest in Laennec's cirrhosis. *The Journal of Clinical Investigation*. 1953 Oct;**32**(10):1025-1033
- [22] Yang YY, Lin HC. The heart: Pathophysiology and clinical implications of cirrhotic cardiomyopathy. *Journal of the Chinese Medical Association*. 2012;**75**:619-623
- [23] Glenn TK, Honar H, Liu H, ter Keurs HE, Lee SS. Role of cardiac myofilament proteins titin and collagen in the pathogenesis of diastolic dysfunction in cirrhotic rats. *Journal of Hepatology*. 2011;**55**:1249-1255
- [24] Lee RF, Glenn TK, Lee SS. Cardiac dysfunction in cirrhosis. *Best Practice & Research. Clinical Gastroenterology*. 2007;**21**:125-140
- [25] Finucci G, Desideri A, Sacerdoti D, et al. Left ventricular diastolic function in liver cirrhosis. *Scandinavian Journal of Gastroenterology*. 1996;**31**(3):279-284
- [26] Pozzi M, Carugo S, Boari G, et al. Evidence of functional and structural cardiac abnormalities in cirrhotic patients with and without ascites. *Hepatology*. 1997;**26**(5):1131-1137
- [27] Lee SS, Marty J, Mantz J, Samain E, Braillon A, Lebrec D. Desensitization of myocardial β -adrenergic receptors in cirrhotic rats. *Hepatology*. 1990;**12**:481-485
- [28] Ma Z, Lee SS, Meddings JB. Effects of altered cardiac membrane fluidity on beta -adrenergic receptor signalling in rats with cirrhotic cardiomyopathy. *Journal of Hepatology*. 1997;**26**:904-912
- [29] Le Grimellec C, Friedlander G, el Yandouzi EH, Zlatkine P, Giocondi MC. Membrane fluidity and transport properties in epithelia. *Kidney International* 1992;**42**:825-836.
- [30] Jaue DN, Ma Z, Lee SS. Cardiac muscarinic receptor function in rats with cirrhotic cardiomyopathy. *Hepatology*. 1997;**25**:1361-1365
- [31] Balligand JL, Kelly RA, Marsden PA, Smith TW, Michel T. Control of cardiac muscle cell function by an endogenous nitric oxide signaling system. *Proceedings of the National Academy of Sciences of the United States of America*. 1993;**90**:347-351
- [32] Liu H, Ma Z, Lee SS. Contribution of nitric oxide to the pathogenesis of cirrhotic cardiomyopathy in bile duct-ligated rats. *Gastroenterology*. 2000;**118**:937-944
- [33] Liu H, Song D, Lee SS. Role of heme oxygenase - carbon monoxide pathway in pathogenesis of cirrhotic cardiomyopathy in the rat. *American Journal of Physiology. Gastrointestinal and Liver Physiology*. 2001;**280**:G68-G74

- [34] Bonz A, Laser M, Küllmer S, Kniesch S, Babin-Ebell J, Popp V, et al. Cannabinoids acting on CB1 receptors decrease contractile performance in human atrial muscle. *Journal of Cardiovascular Pharmacology*. 2003;**41**:657-664
- [35] Ford WR, Honan SA, White R, Hiley CR. Evidence of a novel site mediating anandamide-induced negative inotropic and coronary vasodilator responses in rat isolated hearts. *British Journal of Pharmacology*. 2002;**135**:1191-1198
- [36] Alqahtani SA, Fouad TR, Lee SS. Cirrhotic cardiomyopathy. *Seminars in Liver Disease*. 2008;**28**:59-69
- [37] Kim MY, Baik SK, Lee SS. Hemodynamic alterations in cirrhosis and portal hypertension. *The Korean Journal of Hepatology*. 2010 Dec;**16**(4):347-352
- [38] Sanyal AJ, Bosch J, Blei A, Arroyo V. Portal hypertension and its complications. *Gastroenterology*. 2008;**134**:1715-1728
- [39] Hendrickson H, Chatterjee S, Cao S, Morales Ruiz M, Sessa WC, Shah V. Influence of caveolin on constitutively activated recombinant eNOS: Insights into eNOS dysfunction in BDL rat liver. *American Journal of Physiology. Gastrointestinal and Liver Physiology*. 2003;**285**:652-660
- [40] Wiest R, Shah V, Sessa WC, Groszmann RJ. NO overproduction by eNOS precedes hyperdynamic splanchnic circulation in portal hypertensive rats. *The American Journal of Physiology*. 1999;**276**:G1043-G1051
- [41] Vallance P, Moncada S. Hyperdynamic circulation in cirrhosis: A role for nitric oxide? *Lancet*. 1991;**337**:776-778
- [42] Genesca J, Gonzalez A, Segura R, Catalan R, Marti R, Varela E, Cadelina G, Martinez M, Lopez Talavera JC, Esteban R, Groszmann RJ, Guardia J. Interleukin-6, nitric oxide, and the clinical and hemodynamic alterations of patients with liver cirrhosis. *The American Journal of Gastroenterology*. 1999;**94**:169-177
- [43] Hori N, Wiest R, Groszmann RJ. Enhanced release of nitric oxide in response to changes in flow and shear stress in the superior mesenteric arteries of portal hypertensive rats. *Hepatology*. 1998;**28**:1467-1473
- [44] Martell M, Coll M, Ezkurdia N, Raurell I, Genescà J. Physiopathology of splanchnic vasodilation in portal hypertension. *World Journal of Hepatology*. 2010 Jun 27;**2**(6):208-220
- [45] Ferguson JW, Dover AR, Chia S, Cruden NL, Hayes PC, Newby DE. Inducible nitric oxide synthase activity contributes to the regulation of peripheral vascular tone in patients with cirrhosis and ascites. *Gut*. 2006;**55**:542-546
- [46] Bode C, Kugler V, Bode JC. Endotoxemia in patients with alcoholic and non-alcoholic cirrhosis and in subjects with no evidence of chronic liver disease following acute alcohol excess. *Journal of Hepatology*. 1987;**4**:8-14

- [47] García-Tsao G. Bacterial translocation: Cause or consequence of decompensation in cirrhosis? *Journal of Hepatology*. 2001;**34**:150-155
- [48] Lopez-Talavera JC, Merrill WW, Groszmann RJ. Tumor necrosis factor alpha: A major contributor to the hyperdynamic circulation in prehepatic portal-hypertensive rats. *Gastroenterology*. 1995;**108**:761-767
- [49] Lopez-Talavera JC, Cadelina G, Olchowski J, Merrill W, Groszmann RJ. Thalidomide inhibits tumor necrosis factor alpha, decreases nitric oxide synthesis, and ameliorates the hyperdynamic circulatory syndrome in portal-hypertensive rats. *Hepatology*. 1996;**23**:1616-1621
- [50] Moezi L, Gaskari SA, Lee SS. Endocannabinoids and liver disease. V. Endocannabinoids as mediators of vascular and cardiac abnormalities in cirrhosis. *American Journal of Physiology. Gastrointestinal and Liver Physiology*. 2008;**295**:G649-G653
- [51] Bátkai S, Járαι Z, Wagner JA, Goparaju SK, Varga K, Liu J, et al. Endocannabinoids acting at vascular CB1 receptors mediate the vasodilated state in advanced liver cirrhosis. *Nature Medicine*. 2001;**7**:827-832
- [52] Song D, Liu H, Sharkey KA, Lee SS. Hyperdynamic circulation in portalhypertensive rats is dependent on central c-fos gene expression. *Hepatology*. 2002;**35**:159-166
- [53] Li Y, Song D, Zhang Y, Lee SS. Effect of neonatal capsaicin treatment on haemodynamics and renal function in cirrhotic rats. *Gut*. 2003;**52**:293-299
- [54] Liu H, Schuelert N, McDougall JJ, Lee SS. Central neural activation of hyperdynamic circulation in portal hypertensive rats depends on vagal afferent nerves. *Gut*. 2008;**57**:966-973
- [55] Chung C, Iwakiri Y. The lymphatic vascular system in liver diseases: Its role in ascites formation. *Clinical and Molecular Hepatology*. 2013 Jun;**19**(2):99-104
- [56] Harvey NL, Oliver G. Choose your fate: Artery, vein or lymphatic vessel? *Current Opinion in Genetics & Development*. 2004;**14**:499-505
- [57] Oliver G, Alitalo K. The lymphatic vasculature: Recent progress and paradigms. *Annual Review of Cell and Developmental Biology*. 2005;**21**:457-483
- [58] Tammela T, Alitalo K. Lymphangiogenesis: Molecular mechanisms and future promise. *Cell*. 2010;**140**:460-476
- [59] Hagendoorn J, Padera TP, Kashiwagi S, Isaka N, Noda F, Lin MI, et al. Endothelial nitric oxide synthase regulates microlymphatic flow via collecting lymphatics. *Circulation Research*. 2004;**95**:204-209
- [60] Barrowman JA, Granger DN. Effects of experimental cirrhosis on splanchnic microvascular fluid and solute exchange in the rat. *Gastroenterology*. 1984;**87**:165-172

- [61] Oikawa H, Masuda T, Sato S, Yashima A, Suzuki K, Sato S, et al. Changes in lymph vessels and portal veins in the portal tract of patients with idiopathic portal hypertension: A morphometric study. *Hepatology*. 1998;**27**:1607-1610
- [62] DiBona GF, Sawin LL. Hepatorenal baroreflex in cirrhotic rats. *The American Journal of Physiology*. 1995;**269**:29-33
- [63] Fortune B, Cardenas A. Ascites, refractory ascites and hyponatremia in cirrhosis. *Gastroenterology report (Oxford)*. 2017 May;**5**(2):104-112
- [64] Salerno F, Guevara M, Bernardi M, Moreau R, Wong F, Angeli P, Garcia-Tsao G, Lee SS. Refractory ascites: Pathogenesis, definition and therapy of a severe complication in patients with cirrhosis. *Liver International*. 2010 Aug;**30**(7):937-947
- [65] Krag A, Bendtsen F, Henriksen JH, et al. Low cardiac output predicts development of hepatorenal syndrome and survival in patients with cirrhosis and ascites. *Gut*. 2010;**59**:105-110
- [66] Martín-Llahí M, Pépin MN, Guevara M, Díaz F, Torre A, Monescillo A, Soriano G, Terra C, Fábrega E, Arroyo V, Rodés J, Ginès P, TAHRS Investigators. Terlipressin and albumin vs albumin in patients with cirrhosis and hepatorenal syndrome: A randomized study. *Gastroenterology*. 2008 May;**134**(5):1352-1359
- [67] Guevara M, Ginès P, Fernández-Esparrach G, Sort P, Salmerón JM, Jiménez W, Arroyo V, Rodés J. Reversibility of hepatorenal syndrome by prolonged administration of orni-pressin and plasma volume expansion. *Hepatology*. 1998 Jan;**27**(1):35-41
- [68] Ortega R, Ginès P, Uriz J, Cárdenas A, Calahorra B, De Las Heras D, Guevara M, Bataller R, Jiménez W, Arroyo V, Rodés J. Terlipressin therapy with and without albumin for patients with hepatorenal syndrome: Results of a prospective, nonrandomized study. *Hepatology*. 2002 Oct;**36**(4 Pt 1):941-948
- [69] Patel S, Nguyen DS, Rastogi A, Nguyen MK, Nguyen MK. Treatment of cirrhosis-associated Hyponatremia with Midodrine and Octreotide. *Frontiers in Medicine (Lausanne)*. 2017 Mar 14;**4**:17
- [70] Lee SS. Cardiac dysfunction in spontaneous bacterial peritonitis: A manifestation of cirrhotic cardiomyopathy? *Hepatology*. 2003 Nov;**38**(5):1089-1091
- [71] Azoulay D, Castaing D, Dennison A, Martino W, Eyraud D, Bismuth H. Transjugular intrahepatic portosystemic shunt worsen the hyperdynamic circulatory state of the cirrhotic patient: Preliminary report of a prospective study. *Hepatology*. 1994;**19**:129-132
- [72] Rodríguez-Laiz JM, Bañares R, Echenagusia A, Casado M, Camuñez F, Pérez-Roldán F, et al. Effects of transjugular intrahepatic portasystemic shunt (TIPS) on splanchnic and systemic hemodynamics, and hepatic function in patients with portal hypertension. Preliminary results. *Digestive Diseases and Sciences*. 1995;**40**:2121-2127

- [73] Ascha M, Abuqayyas S, Hanouneh I, Alkukhun L, Sands M, Dweik RA, Tonelli AR. Predictors of mortality after transjugular portosystemic shunt. *World Journal of Hepatology*. 2016 Apr 18;**8**(11):520-529
- [74] Parvinian A, Bui JT, Knuttinen MG, Minocha J, Gaba RC. Right atrial pressure may impact early survival of patients undergoing transjugular intrahepatic portosystemic shunt creation. *Annals of Hepatology*. 2014 Jul-Aug;**13**(4):411-419
- [75] Rabie RN, Cazzaniga M, Salerno F, Wong F. The use of E/A ratio as a predictor of outcome in cirrhotic patients treated with transjugular intrahepatic portosystemic shunt. *The American Journal of Gastroenterology*. 2009;**104**:2458-2466
- [76] Cazzaniga M, Salerno F, Pagnozzi G, Dionigi E, Visentin S, Cirello I, et al. Diastolic dysfunction is associated with poor survival in cirrhotic patients with transjugular intrahepatic portosystemic shunt. *Gut*. 2007;**56**:869-875
- [77] Liu H, Lee SS. What happens to cirrhotic cardiomyopathy after liver transplantation? *Hepatology*. 2005 Nov;**42**(5):1203-1205
- [78] Al-Hamoudi WK, Alqahtani S, Tandon P, Ma M, Lee SS. Hemodynamics in the immediate post-transplantation period in alcoholic and viral cirrhosis. *World Journal of Gastroenterology*. 2010 Feb 7;**16**(5):608-612
- [79] Navasa M, Feu F, García-Pagán JC, Jiménez W, Llach J, Rimola A, et al. Hemodynamic and humoral changes after liver transplantation in patients with cirrhosis. *Hepatology*. 1993;**17**:355-360
- [80] Liu H, Jayakumar S, Traboulsi M, Lee SS. Cirrhotic cardiomyopathy: Implications for liver transplantation. *Liver Transplantation*. 2017 Jun;**23**(6):826-835
- [81] Fouad TR, Abdel-Razek WM, Burak KW, Bain VG, Lee SS. Prediction of cardiac complications after liver transplantation. *Transplantation*. 2009;**87**:763-770
- [82] Donovan CL, Marcovitz PA, Punch JD, Bach DS, Brown KA, Lucey MR, et al. Two-dimensional and dobutamine stress echocardiography in the preoperative assessment of patients with end-stage liver disease prior to orthotopic liver transplantation. *Transplantation*. 1996;**61**:1180-1188
- [83] Baibhav B, Mahabir CA, Xie F, Shostrom VK, McCashland TM, Porter TR. Predictive value of Dobutamine stress perfusion echocardiography in contemporary end-stage liver disease. *Journal of the American Heart Association*. 2017 Feb 20;**6**(2). pii: e005102. [Epub ahead of print]