

# We are IntechOpen, the world's leading publisher of Open Access books Built by scientists, for scientists

6,900

Open access books available

185,000

International authors and editors

200M

Downloads

Our authors are among the

154

Countries delivered to

TOP 1%

most cited scientists

12.2%

Contributors from top 500 universities



WEB OF SCIENCE™

Selection of our books indexed in the Book Citation Index  
in Web of Science™ Core Collection (BKCI)

Interested in publishing with us?  
Contact [book.department@intechopen.com](mailto:book.department@intechopen.com)

Numbers displayed above are based on latest data collected.  
For more information visit [www.intechopen.com](http://www.intechopen.com)



---

# Treatment of Class II Malocclusion (Hypodivergent Face) with MEAW Therapy

---

Paulo Augusto de Sousa Beltrão

Additional information is available at the end of the chapter

<http://dx.doi.org/10.5772/intechopen.69331>

---

## Abstract

Patients with class II deep bite malocclusion and hypodivergent skeletal typology represent complex and prolonged cases of treatment due to their muscular characteristics. The etiology of the class II deep bite is multifactorial: environmental and/or genetic factors represent an important part in the establishment of class II deep bite. However, there is a close connection between three class II factors and the adaptation of mandible and occlusal function. These factors are lack of vertical dimension, inclination of the upper occlusal plane, lack of occlusal support, and pressure of TMJ. According to Tanaka and Sato, there is a relationship between the inclination of the maxillary posterior occlusal plane and the mandibular position, consistent with the etiology of different dento-skeletal structures. The occlusal plane is more tilted in patients with class II and more flat in patients with class III than in individuals with class I occlusions. **Patients and methods:** Two male teenagers were treated with MEAW therapy, and both treatments lasted 24 months. **Results:** The MEAW therapy appropriately corrected the class II deep bite over a period of 24 months, achieving a good occlusal, functional, and esthetic result. **Conclusions:** The MEAW therapy proved to be effective in the treatment of class II deep bite malocclusion, in growing patients.

**Keywords:** class II deep bite, steep occlusal plane, hypodivergent, MEAW

---

## 1. Introduction

During the process development of skeletal class II, there are three important factors (insufficient height of bite, strong inclination of the occlusal plane, lack of occlusal support), which are closely related with the adaptation of the mandible and the occlusal function [1–3].

The maxillary dentition of patients with class II malocclusion has low vertical dimension in the posterior area, and the upper posterior occlusal plane is steep. The occlusal interferences

in the molar area prevent the mandible to adapt to a forward position, instead the mandible adapts posteriorly, aggravating the distoclusion. Actually, 70% of the class II malocclusion does not imply the protrusion of the maxilla but is known to be caused by retrusion of the mandible (McNamara [4]).

Morphological characteristics of the class II deep overbite are the following: the mandible is small and retruded, insufficient vertical dimension and occlusal support, steepening of the occlusal plane in the upper posterior area, occlusal interferences in the molar area, and labial tipping of the upper anterior teeth. The skeletal characteristics of class II deep bite malocclusion are closely related to the lack of vertical dimension and the steepness of the occlusal plane. Some authors proved that the vertical disproportion was in many cases at the origin of anterior-posterior dysplasias.

Therefore, a treatment approach based on the control of the occlusal plane and vertical dimension is essential to the success of the treatment. The treatment objectives for class II deep bite are the following: to increase the vertical dimension, to rebuild and flatten the upper posterior occlusal plane, to coordinate upper and lower dental arch width, to move the mandible forward, to improve overbite (deep bite), to obtain normal intercuspitation, and to improve the profile.

The treatment of low-angle class II malocclusions must prevent occlusal interferences and extrude the upper molars to increase their vertical height and flatten the occlusal plane. As a result, the mandible readapts to the physiological position, and occlusal function is attained. The steps of the class II deep overbite malocclusion are leveling, elimination of occlusal interferences, establishing mandibular position, reconstruction of the occlusal plane, and achieving a physiological occlusion.

## 2. The multiloop edgewise arch wire (MEAW)

In 1967, Young H. Kim created the multiloop edgewise arch wire (MEAW) to treat open bite malocclusions, which he achieved with great efficiency. Subsequently, Prof. Sadao Sato (Kanagawa Dental College, Japan) [5] developed the MEAW philosophy of treatment and applied it to all types of malocclusions. MEAW can be constructed with stainless steel 0.016 × 0.022 (bracket 0.018 inch slot) or 0.017 × 0.025 ss (bracket 0.022 inch slot).

The arches have ideal dental arch shape with five loops on each side of the arch. The loops between the teeth act as a force breaker and allow smooth and continuous forces to be distributed through the teeth, as well as individual control of vertical, horizontal, and torque forces on the teeth. The use of MEAW arches with activation must be done together with the use of intraoral elastics (appropriate to the malocclusion), in order to obtain a successful reconstruction of the posterior occlusal plane (**Figure 1**).

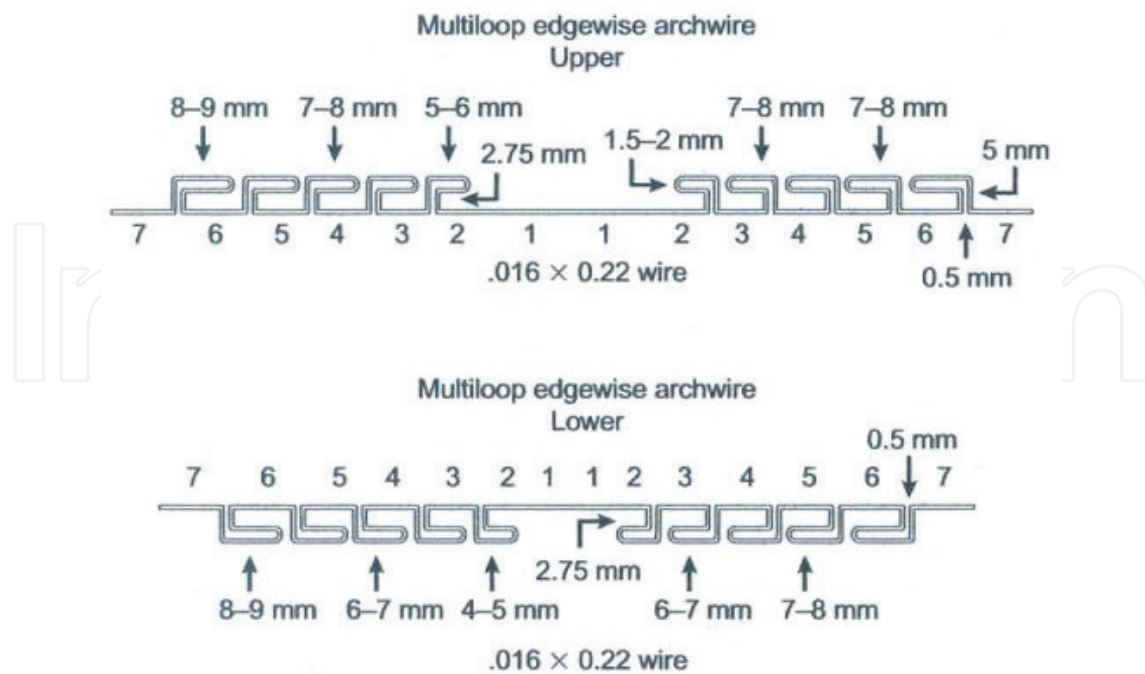


Figure 1. Upper and lower multiloop edgewise arch wire (MEAWs).

### 3. Cephalometric analysis

#### 3.1. Analysis of Kim

Kim [6, 7] developed his cephalometric analysis in order to identify the types of vertical and anterior-posterior growth and their connection with the inclination of the occlusal plane:

- Overbite depth indicator (ODI)
- Anterior-posterior dysplasia indicator (APDI)
- Combination factor (CF)

#### 3.2. Overbite depth indicator (ODI)

The ODI is the sum of two angles: the A-B plane with the mandibular plane (MP) and the palatal plane with the Frankfort horizontal (FH) plane. The angle is negative when the palatal plane inclines superiorly in relation to the FH plane and is read as a positive angle when the palatal plane inclines inferiorly in relation to the FH plane.

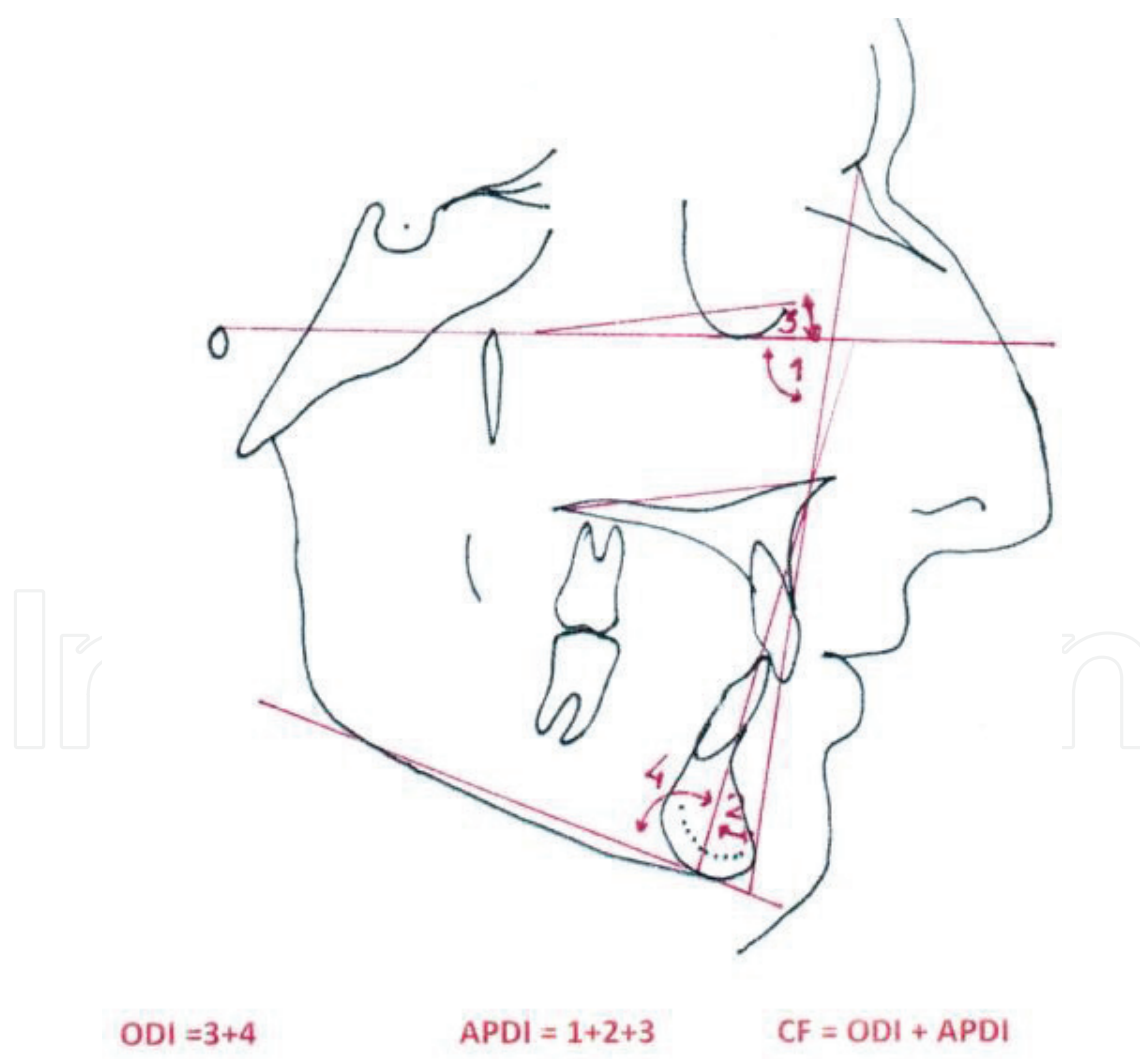
There is a norm of 74.5 degrees with a standard deviation of 6.07. A value lower than 74.5 ( $\pm 6.07$  degrees) shows a skeletal open bite tendency. A highest value of 74.5 ( $\pm 6.07$  degrees) shows a deep bite skeletal pattern tendency. In these patients with skeletal deep bite tendency,

tooth extractions should be avoided, in order not to lose occlusal support, because loss of occlusal support increases the risk of relapse (**Figure 2**).

### 3.3. Anteroposterior dysplasia indicator (APDI)

The APDI consists of three angles: the angle of the facial plane (Frankfurt horizontal (FH)/facial plane (FP)), added or decreased to the angle Downs, and added or decreased to the angle of the palatine plane in relation to the plane HF. The APDI can also be calculated by the value of the angle formed by the palatine plane (PP) (line linking points A and B).

$APDI = (FH-FP) + (AB-FP) + (FH-PP)$ . The average APDI value is  $81.4^\circ$ . A value higher than  $81.4^\circ$  shows a trend skeletal class III; on the contrary a smaller value shows the tendency for skeletal class II and molar class II relationship. APDI unlike ODI (which is slight altered by the treatment) shows the potential of the treatment of the clinical case, because the APDI can be significantly changed by growth and treatment. Kim (Kim and Vietas, 1978) [5] considered



**Figure 2.** Kim cephalometric analysis.

that at the end of the treatment the APDI should be close to the norm ( $81.4^\circ$ ) in order to have a clinical case with stability and the risk of relapse decreased.

### 3.4. Combination factor (CF)

The combination factor (CF) [8] is a combination of ODI and APDI.

A value of CF above  $155^\circ$  shows a trend for a skeletal pattern of low angle. A value of CF below  $155^\circ$  exhibits the trend for high angle, and the necessity for tooth extraction is increased.

The CF provides guidance if the clinical case should be treated with or without extractions.

## 4. The importance of cranial base and the development scheme of skeletal class II deep bite malocclusion

The base of the skull is formed by the ethmoid, sphenoid, and occipital bones, joined by spheno-occipital and sphenoethmoidal synchondrosis. The sutures fuse with age, sphenoethmoidal at 7–8 years and spheno-occipital at 18–20 years, but allow small movements. Hooper in 1986 referred to spheno-occipital synchondrosis as the most important at the base of the skull where the flexion/extension movements occurred. The various malocclusions show different cranial base angles. Thus, in class I occlusions, the angle of the base of the skull (Na-S-Ar) approaches to  $124.2^\circ$ , in class II the angle is more obtuse approaching to  $130^\circ$ , and in class III, the base of the skull presents flexion, being the angle approximately  $120^\circ$ . The movement of flexion/extension occurred in the spheno-occipital suture is transmitted by the Vomer to maxillary. According to the movement occurred in the spheno-occipital suture, also the direction of growth of the maxillary will be different. When sphenoid flexion occurs, the maxillary growth is more vertical, growing more in height and less in length, resulting in posterior dental discrepancy; this is what happens in class III skeletal frame. On the contrary, when extension at the base of the skull occurs, the force transmitted by the Vomer to maxillary will push it protrusively, and maxillary will grow more in length and less in height. This protrusive rotation of maxillary is responsible for the inclination of the incisors and spaces between them (typical in class II/1 malocclusion).

The results of a poor maxillary vertical dimension are:

- Low vertical dimension
- Decrease of occlusal support
- Steep posterior occlusal plane

When the posterior occlusal plane (POP) is steep, the mandible adapts posteriorly with molar distocclusion; on the contrary, when the POP is flat, the mandible adapts in an anterior position producing molar mesiocclusion. In 1975, Petrovic [9] reported on the cybernetic theory of Petrovic, who stated that the maxillary anterior-inferior growth was responsible for the anterior functional adaptation of the mandible followed by secondary growth of the condyles.

## 5. Low-angle class II deep bite malocclusion characteristics

McNamara and Moyers et al. have suggested that the fundamental problems in class II malocclusion are due not to maxillary prognathism but rather to mandibular retrognathism.

The characteristics of the class II deep bite malocclusion are the following: the mandible is small and retruded, the posterior maxillary occlusal plane is steep, presence of posterior occlusal interferences, upper incisors normally labially inclined with spaces between them, labial incompetence, low vertical dimension, lack of occlusal support, molar teeth slightly erupted (infra-eruption), deep overbite, low gonial angle (GOA), and small lower facial height (LFH) [10].

The APDI is less than  $74.5^\circ$ , and the overbite depth indicator (ODI) is quite high (1980s and 1990s). The angle of the cranial base is extended.

The skeletal characteristics of class II malocclusion are closely related to vertical occlusion deficiencies.

## 6. Treatment of class II low-angle malocclusion based on the control of occlusal plane

In the 1970s, several studies (Petrovic, Carlson, McNamara, and Woodside) showed the ability to change the growth pattern of the mandible according to its function. McNamara, Graber, Harvold, and Bass (1970) evidenced that the amount of changes in mandibular growth due to cell increase in the condyles was in conformity with the modifications of the occlusal function. Fushima et al. (1989) measured vertical height of molar and premolar teeth in patients with mandibular asymmetry. They verified that the vertical dimension of the posterior teeth of the displaced side was smaller than the contralateral dental height (nonshifted side).

The MEAW philosophy created by Dr. Young Kim and developed by Prof. Sadao Sato considers that the treatment of class II low-angle malocclusion should eliminate occlusal interferences, increase the vertical dimension (extruding the maxillary molars), and reconstruct the occlusal plane. Once the vertical dimension increases, the mandible moves anteriorly to a functional position [11–13].

The mandibular dentition, especially the premolars, is extruded to increase the vertical dimension and flatten the occlusal plane, creating conditions for the mandible to move to a forward position, more physiologically, and improving the occlusal function.

The forward adaptation of the mandible followed by adaptive remodeling of the TMJ is necessary for the success and stability of the treatment.

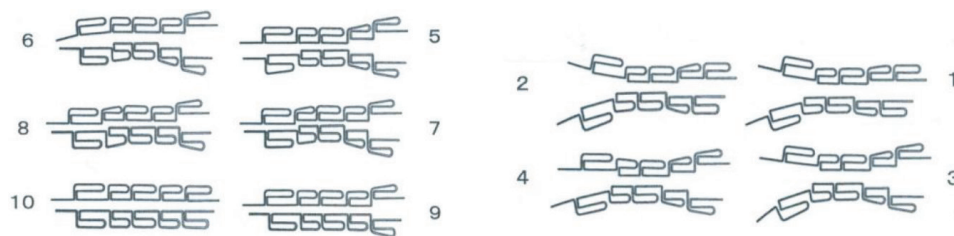
The objectives of class II deep bite treatment are:

- Increase of the vertical dimension
- Rebuilding and flattening of the upper posterior occlusal plane

- Correction of the differences of shape between the dental arches
- Mandibular advancement to obtain a physiological position
- Correction of deep bite
- Obtaining correct occlusion and improving the profile

Sequence of class II deep bite treatment:

(1) Alignment and leveling, (2) correction of occlusal interferences, (3) attaining a physiological mandibular position, (4) rebuilding the occlusal plane, and (5) attaining a physiological occlusion (**Figure 3**).



**Figure 3.** Sequence of low-angle class II deep bite treatment.

## 7. Case report 1

A male patient 14 years and 10 months old, with skeletal class II and dental class II/1 on a hypodivergent face pattern (FMA 17°), deep bite (8 mm), overjet (5 mm), steep posterior occlusal plane producing interferences in the posterior area, insufficient occlusal support on the posterior area, crossbite on the right side, crown fracture of 11, posterior discrepancy, and crowding on the anterior maxillary area. The patient began the treatment at the age of 14 years and 10 months old, and the treatment lasted 24 months. The type of appliance was an edgewise multi-bracket 0.022 × 0.028 slot, 0° torque, 0° angulation, and MEAWs arch wires along with short class II elastics.

The treatment objectives for this patient with class II deep bite were increasing the vertical dimension, elimination of the posterior interferences, reconstruction of posterior occlusal plane (flatten), coordination between both arches, production of anterior adaptation of the mandible, and secondarily induction condylar remodeling. The patient and their parents refused the extraction of 38 and 48 to eliminate the posterior mandibular discrepancy and were advised to the consequences of such refusal.

Sequence of treatment:

(a) Leveling, (b) correction of occlusal interferences, (c) achieving mandibular position, (d) rebuilding of the occlusal plane, and (e) achieving a physiological occlusion.

**Step 1:** Leveling (alignment), onset with 0.016" ss arch wires.

**Step 2:** Elimination of occlusal interferences—0.017 × 0.025 multiloop edgewise arch wires were inserted in both arches, through the use of small class II (3/16 inch, 6 ounces) elastics bilaterally.

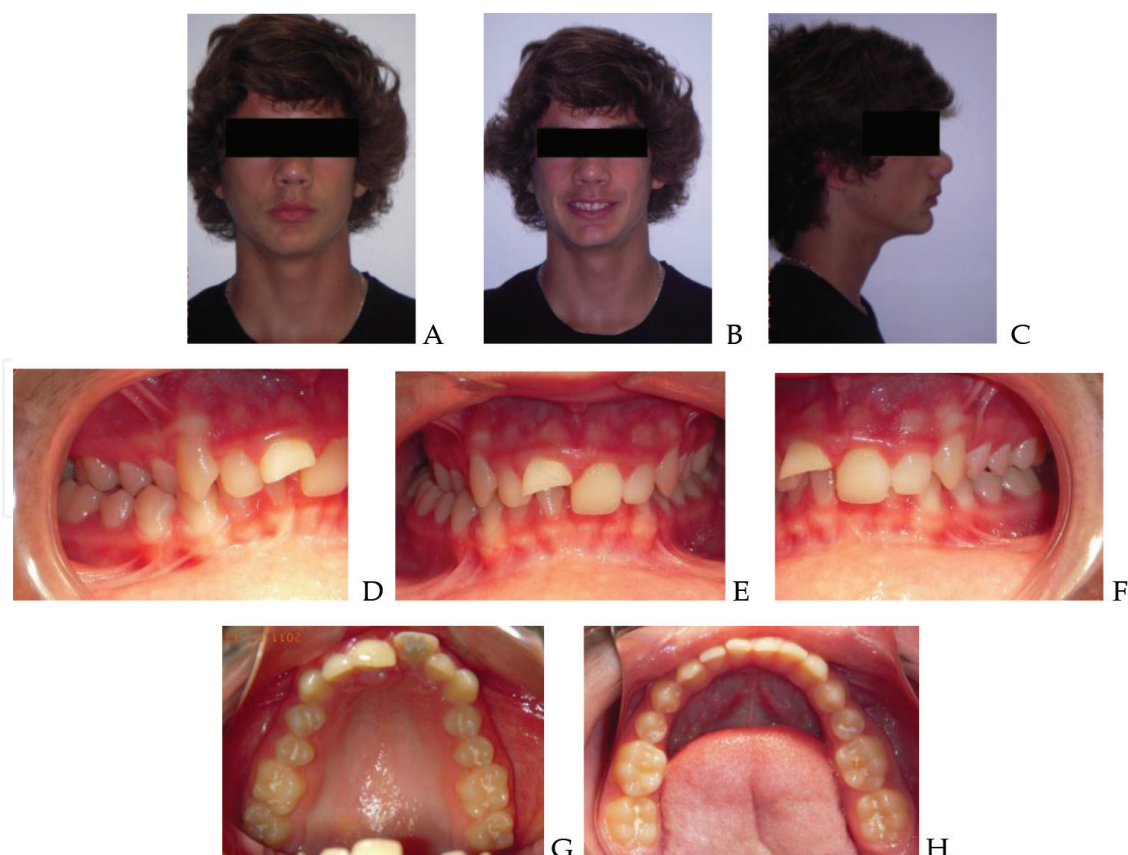
**Step 3:** Achieving a functional mandibular position: step-down bends (premolars) in the upper arch and step-up bends (premolars) in the lower arch were done to bite rising (to apply small class II, 3/16 inch, 6 ounces of elastics). When this phase is finished, the molar relationship is class I.

**Steps 4 and 5:** Rebuilding the posterior occlusal plane (flatten the posterior occlusal plane) and establishing a physiological occlusion.

The retention period was done with maxillary Hawley plate for nighttime use (12 months) and bonded lingual wire from 33 to 43.

The posttreatment results demonstrate an improved smile, profile, and facial balance.

The intraoral photos show a normal class I relationship, a correct overbite, and overjet. The cephalometric analysis shows a reduction of ANB angle of 4°, mandibular advancement (point B has advanced 3°), an AO-BO reduction of 3 mm, and a better profile. The APDI increased 7° (from 66 to 73°) showing an improvement of the skeletal class II malocclusion (**Figures 4–11, Tables 1 and 2**).



**Figure 4.** Pretreatment extraoral (A–C) and intraoral (D–H) photographs.

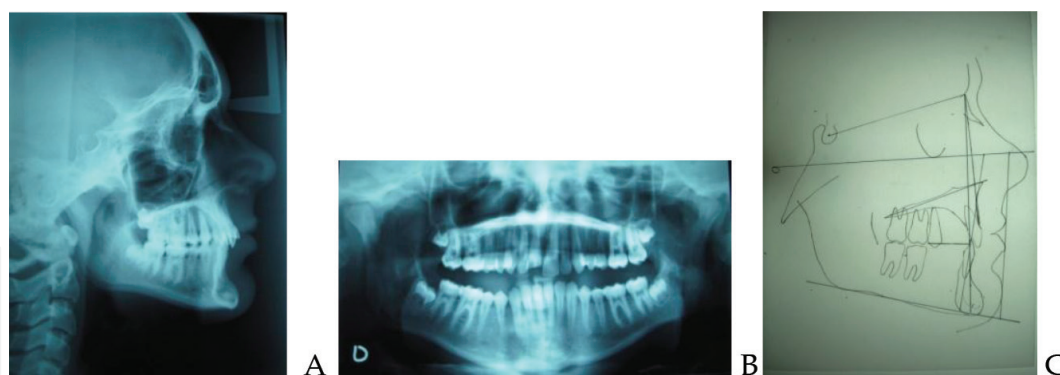


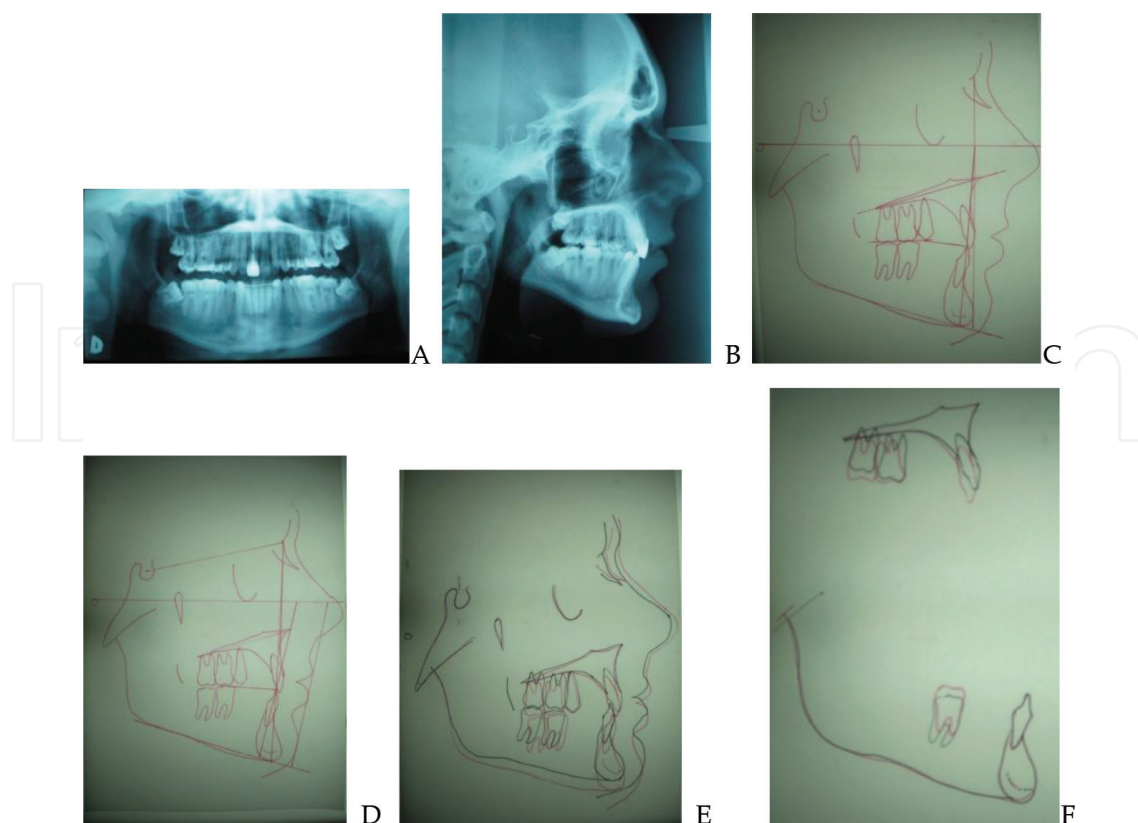
Figure 5. Pretreatment records (A–C).

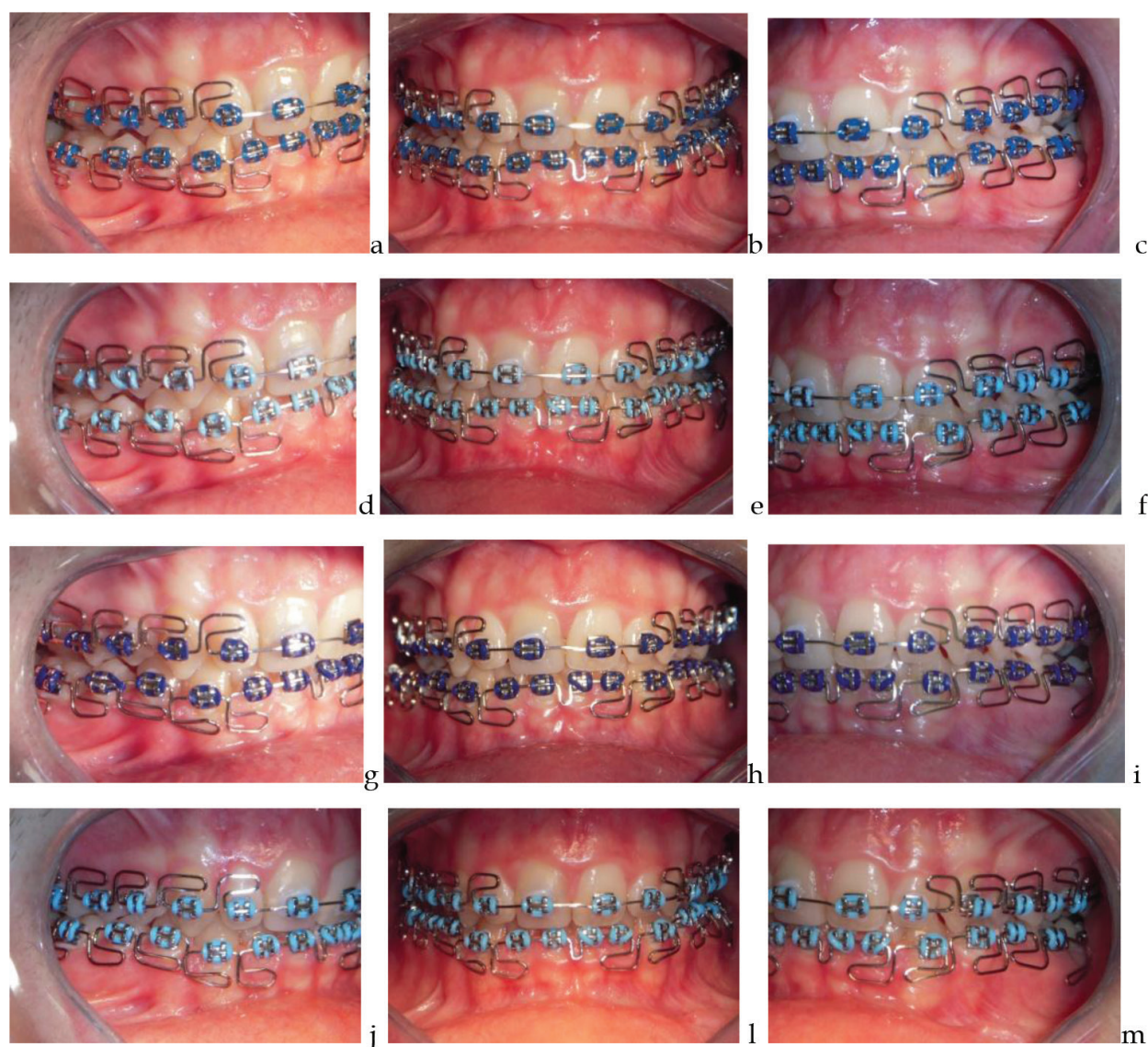
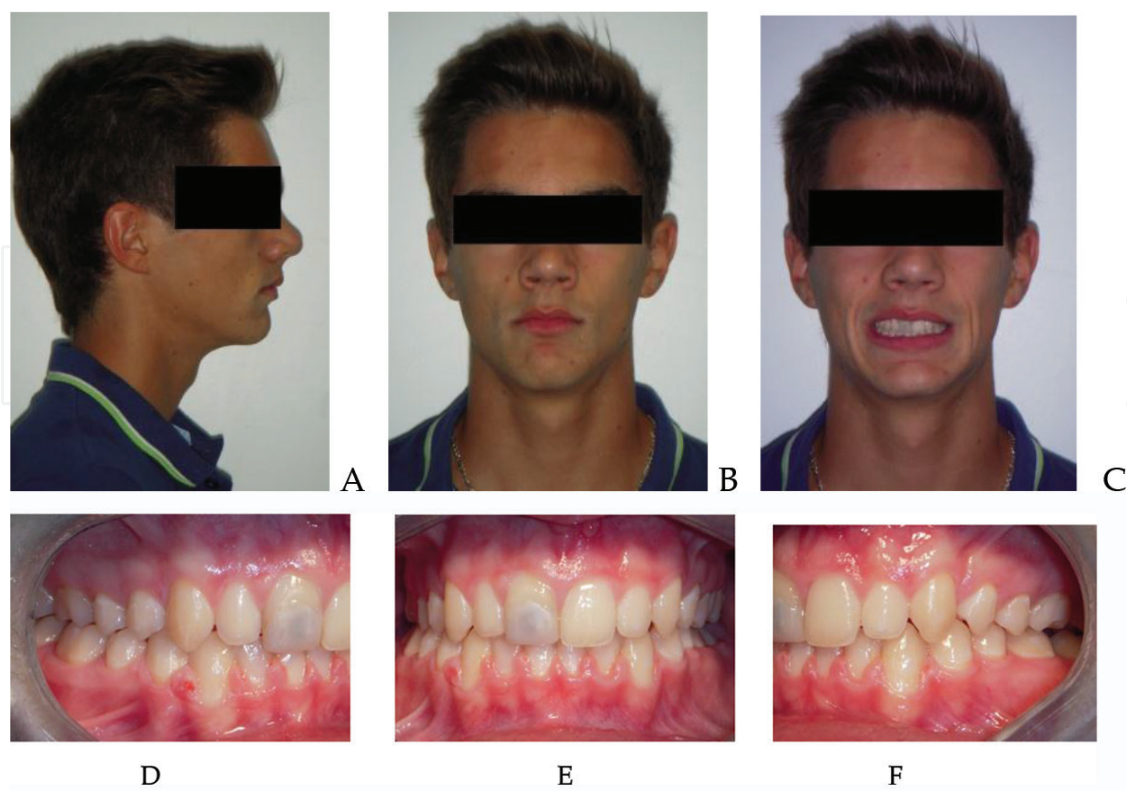
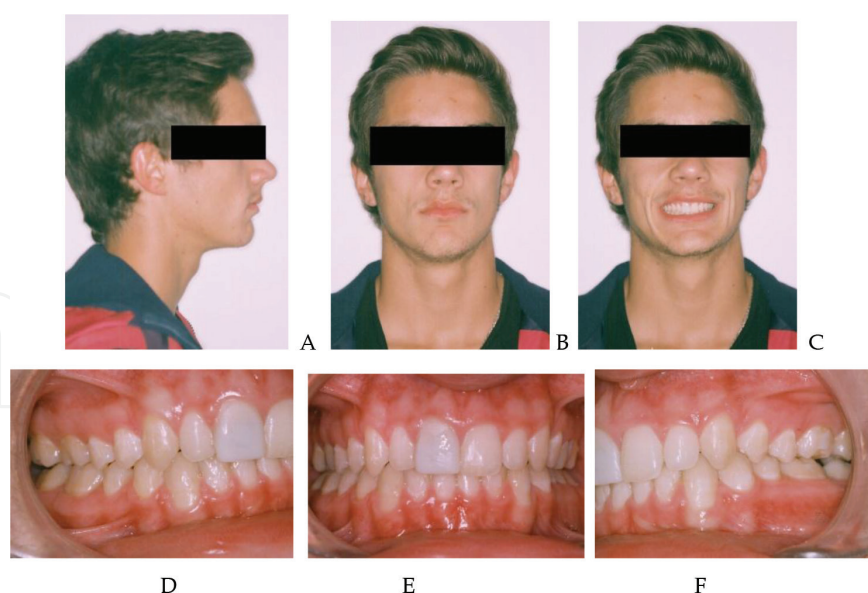Figure 6. Photos during the treatment (a–m).



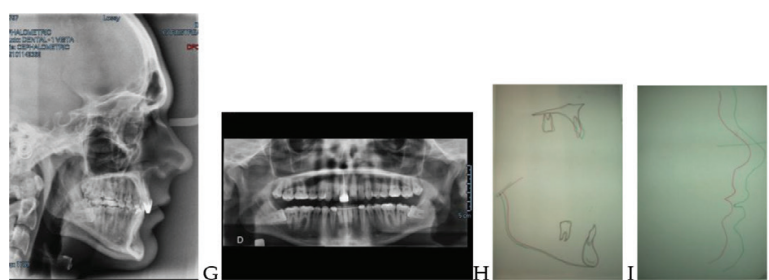
**Figure 7.** Posttreatment extraoral (A–C) and intraoral (D–F) photos.



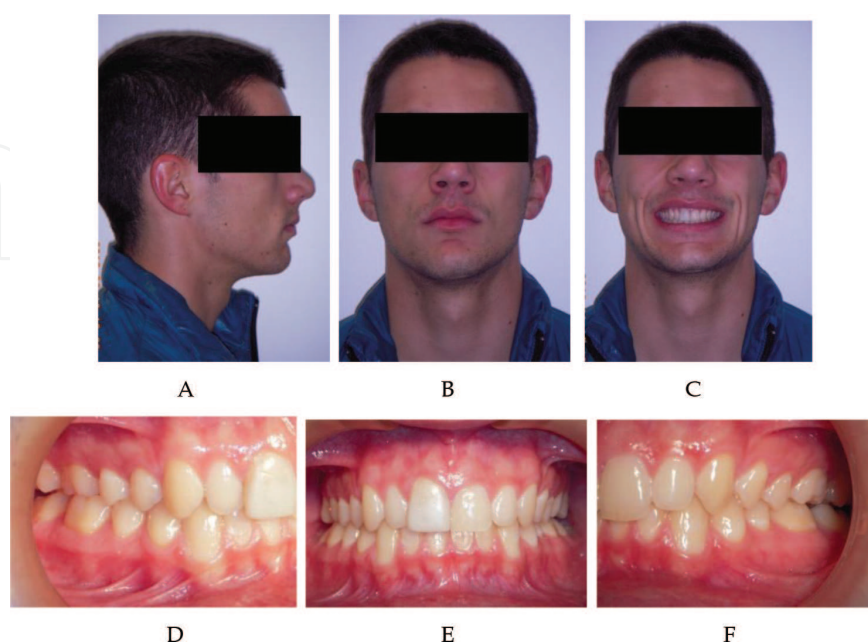**Figure 8.** Posttreatment records (A–D) and superimpositions between pre- and posttreatment (E–F).



**Figure 9.** Postretention extraoral photos (A–C) and intraoral photos (D–F).



**Figure 10.** Postretention records (G–H) and postretention superimpositions.



**Figure 11.** Three years after the end of treatment: extraoral photos (A–C) and intraoral photos (D–F).

	Pretreatment		Posttreatment		End of retention	
ODI	MP/AB	83	69	77	63	76
	FH/PP	-14		-14		-14
APDI	HF/FP	90	66	91	73	91
	FP/AB	-10		-4		-3
	HF/PP	-14		-14		-14
CF	ODI + APDI	135		136		136

**Table 1.** Cephalometric analysis (Kim).

	Range	Pretreatment	Posttreatment	End of retention
FMIA	67 ± 3°	73	73	72
FMA	25 ± 3°	17	17	17
IMPA	88 ± 3°	90	90	91
SNA	82 ± 2°	78	78	78
SNB	80 ± 2°	73	77	76
ANB	2 ± 2°	05	01	02
AO-BO	2 mm	4 mm	1 mm	1 mm
OP	10–14°	7	5	5
Z	75 ± 5°	83	80	81
PFH	45 mm	45	47	48
AFH	65 mm	66	70	72
INDEX	0.69	0.68	0.67	0.67

**Table 2.** Cephalometric analysis (Tweed-Merrifield) [14, 15].

## 8. Case report 2

A young male patient 13 years and 10 months old, with small anterior facial height, skeletal class II (FMA = 18°), dental class II/1 with deep bite of 7 mm and an overjet of 10 mm, hypodivergent face scheme, mandibular retrognathism, steep posterior occlusal plane creating interferences in the molar area, and lack of occlusal support.

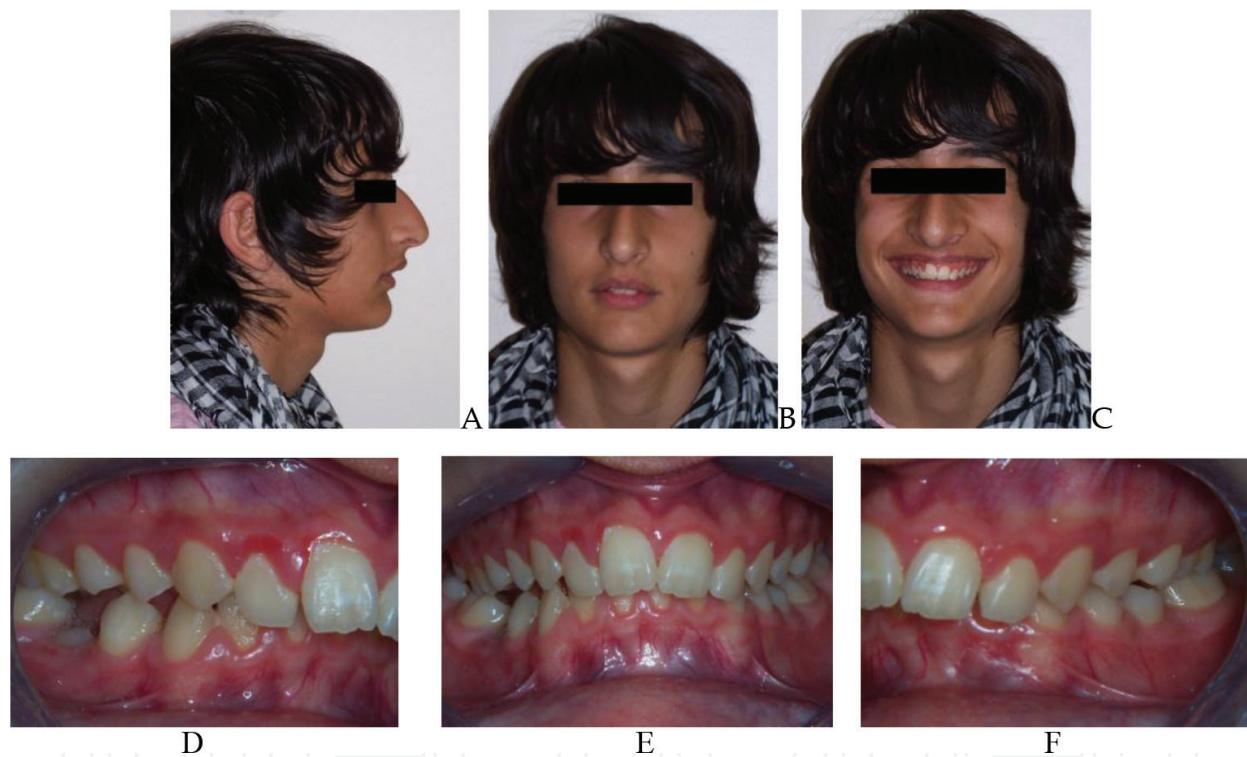The z angle of 66° confirms an unbalanced face which is based on a retrognathic chin, absence of crowding and shape of dental arches is different due to an old habit of thumb sucking.

According to Kim’s cephalometric analysis, the patient shows a low-angle skeletal pattern (ODI = 86°), and removal of permanent teeth is not advised, due to the high potential for deep bite relapse. The APDI = 70° shows a class II skeletal pattern, and the combination factor = 156°

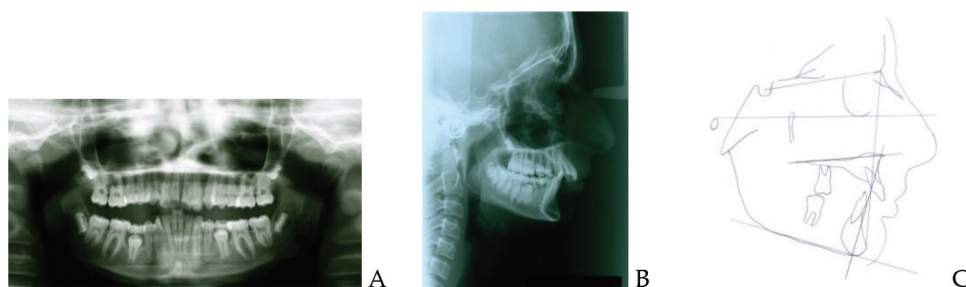
indicates a skeletal pattern that has a capacity to accommodate the entire dentition. Onset of treatment with age of 13 years and 10 months, after 2 months a double arch wire (DAW) was placed to extrude maxillary molars and to align and intrude upper incisors [16]. After 5 months, MEAWs were inserted in both dental arches, along with small class II elastics (3/16 inch, 6 ounces).

The duration of the treatment was 24 months. The posttreatment photographs (**Figure 15**) show a better pleasant face, an improved facial profile, a pleasant wide smile, a stable class I molar occlusion, and overbite and overjet corrected.

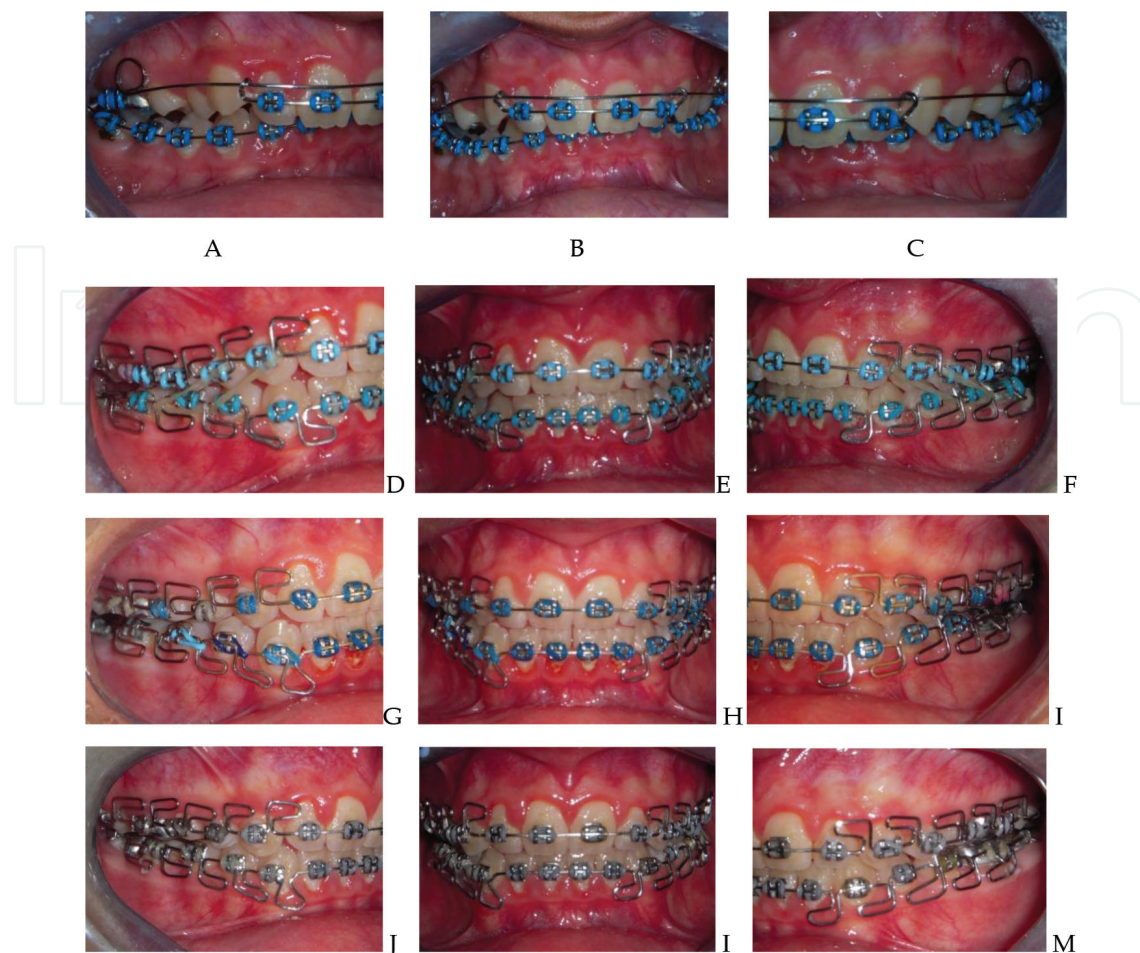The mandibular incisors were kept in its pretreatment position. The cephalometric superimposition between pretreatment and posttreatment displays the entire mandibular improvement in height and length. The APDI = 80 at the end of treatment is a guarantee to define this clinical case as stable and with little tendency to relapse (**Figures 12–20, Tables 3 and 4**).



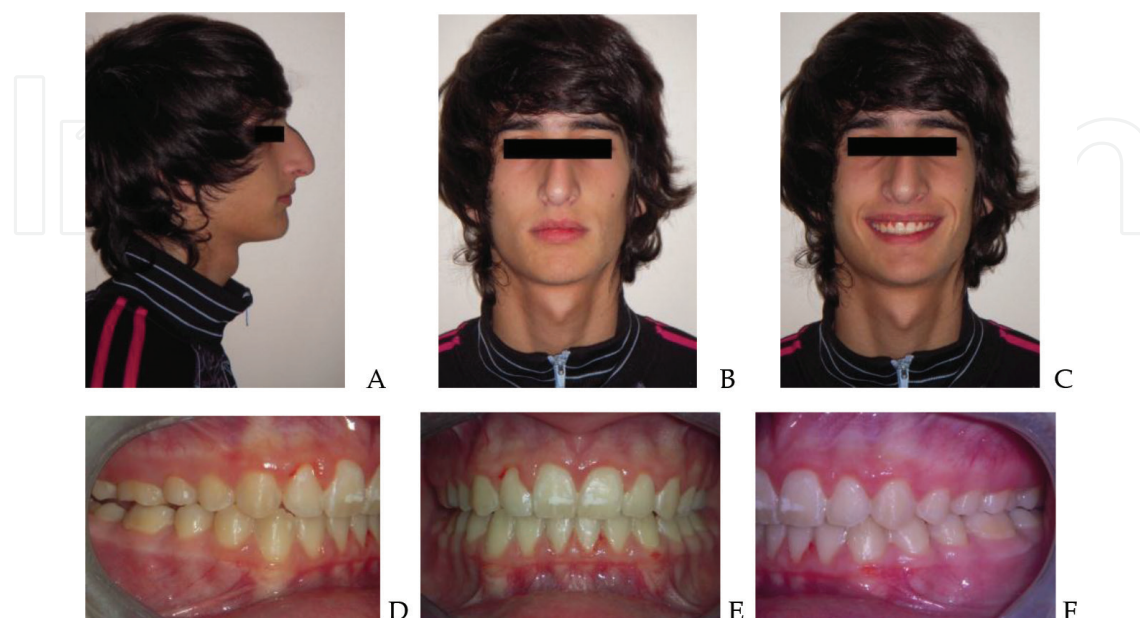
**Figure 12.** Pretreatment extraoral (A–C) and intraoral (D–F) photos.



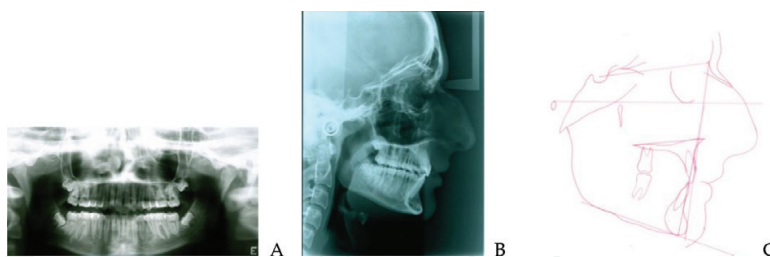
**Figure 13.** Pretreatment records (A–C).



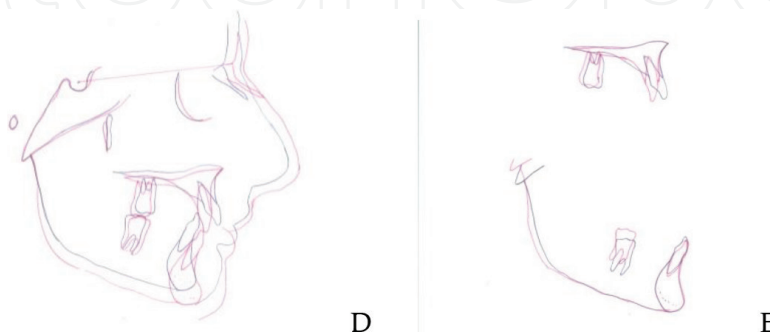
**Figure 14.** Treatment sequence images. (A–C) In the third month of treatment, a double arch wire (DAW) was placed and remained in mouth 5 months. (D–F) One year of treatment (5 months with MEAWs along with small class II elastics (6 ounces, 3/16 inch)). (G–I) Eighteenth month of treatment. (J–M) Twenty-second months of treatment.



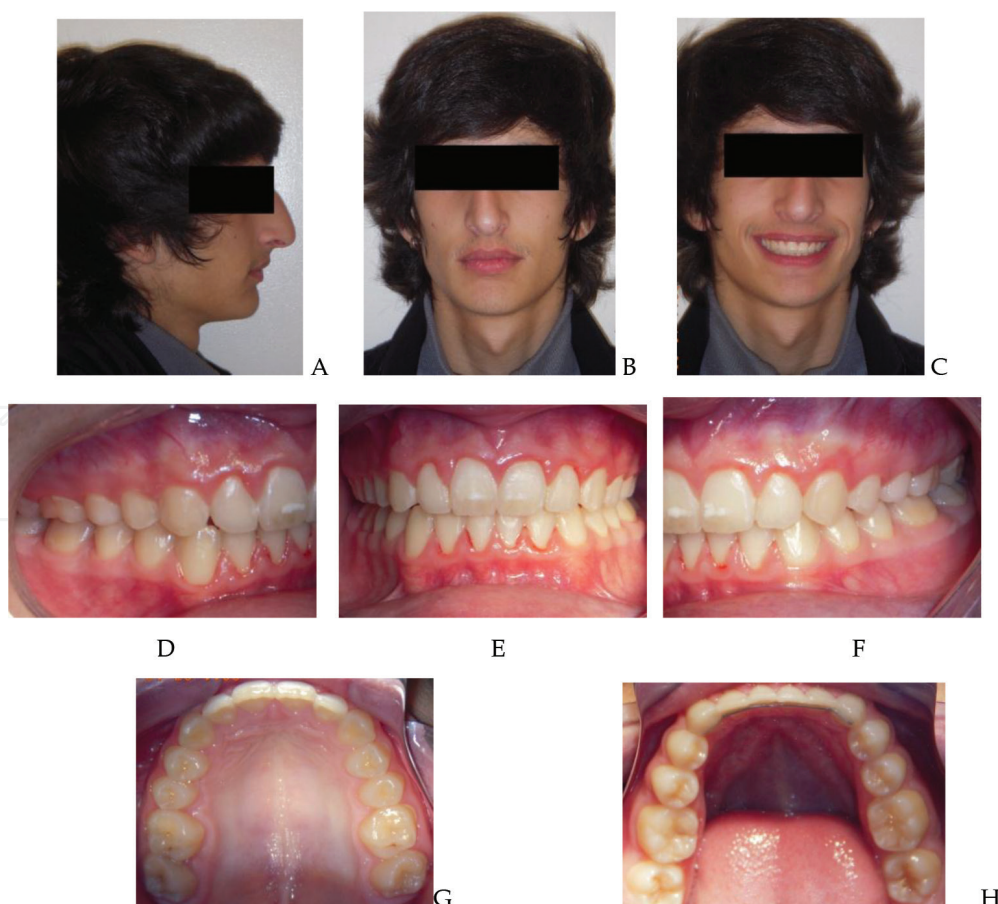**Figure 15.** End of treatment: extraoral photos (A–C) and intraoral photos (D–F).



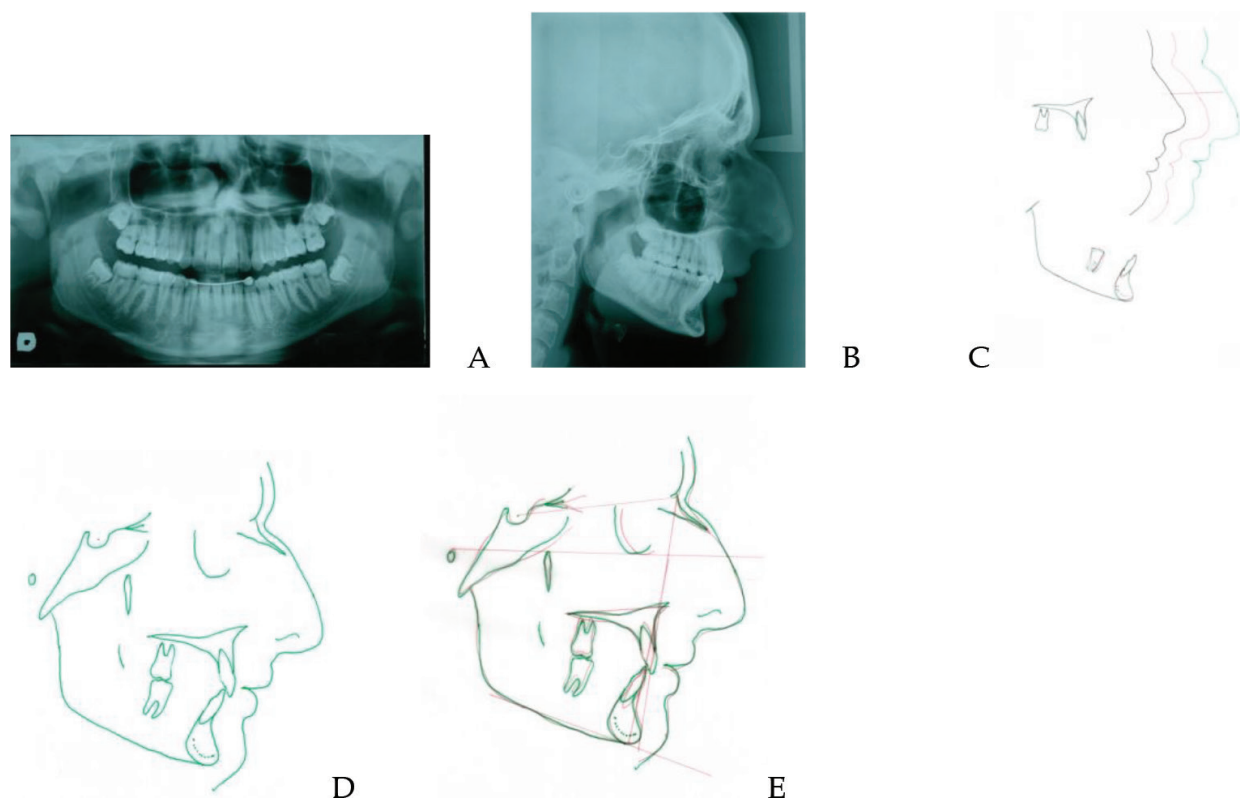
**Figure 16.** Posttreatment records (A–C).



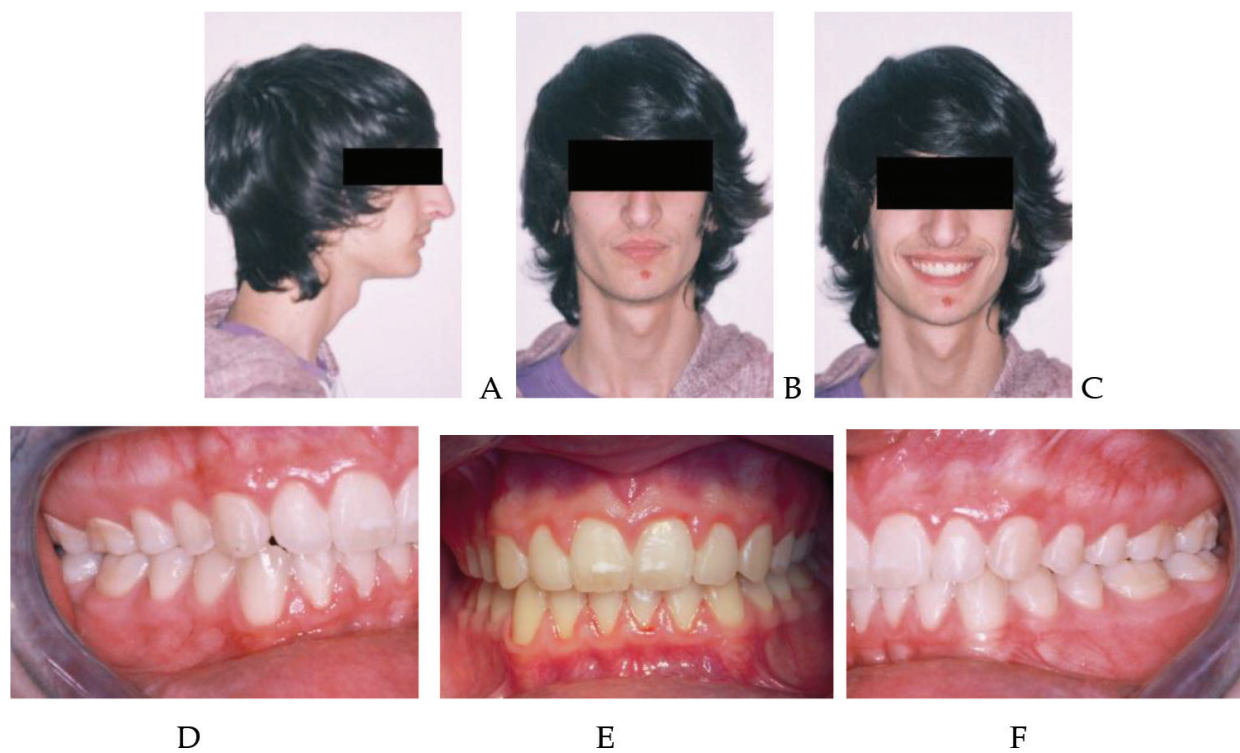**Figure 17.** Superimpositions between pre- and posttreatment (D, E).



**Figure 18.** Postretention: extraoral photos (A–C) and intraoral photos (D–H).



**Figure 19.** Postretention records (A–B) and superimpositions between posttreatment and postretention (C–E).



**Figure 20.** Three years after the end of treatment: extraoral photos (A–C) and intraoral photos (D–F).

	Pretreatment		Posttreatment		Post-retention	
ODI	MP/AB	82	80	82	80	82
	FH/PP	-2		-2		-2
APDI	HF/FP	80	73	84	80	84
	FP/AB	-5		-2		-2
	HF/PP	-2		-2		-2
CF	ODI + APDI	153		160		160

**Table 3.** Cephalometric analysis (Kim).

	Range	Pretreatment	Posttreatment	Post-retention
FMIA	$67 \pm 3^\circ$	64	61	60
FMA	$25 \pm 3^\circ$	18	20	20
IMPA	$88 \pm 3^\circ$	98	99	100
SNA	$82 \pm 2^\circ$	78	76	76
SNB	$80 \pm 2^\circ$	72	74	74
ANB	$2 \pm 2^\circ$	6	2	2
AO-BO	2 mm	7 mm	2 mm	2 mm
OP	$10-14^\circ$	7	8	8
Z	$75 \pm 5^\circ$	67	73	72
PFH	45 mm	45	50	50
AFH	65 mm	60	65	65
INDEX	0.69	0.75	0.77	0.77

**Table 4.** Cephalometric analysis (Tweed-Merrifield).

## 9. Conclusion

The superimposed tracings confirm in both cases that the mandible shifted forward, the flattening of the posterior occlusal plane, and the vertical dimension increased during active appliance therapy.

The objectives of both treatments were successfully achieved by the use of MEAW therapy. A good functional occlusion and an esthetic profile had been attained. The records 3 years after the end of treatment show the stability of the treatment and the occlusion.

The MEAW technique proved to be effective in the treatment of class II deep bite malocclusion.

## Author details

Paulo Augusto de Sousa Beltrão

Address all correspondence to: paulobeltrao@sapo.pt

French Board of Orthodontics, Portugal

## References

- [1] Tanaka E, Sato S. Longitudinal alteration of the occlusal plane and development of different dentoskeletal frames during growth. *American Journal of Orthodontics and Dentofacial Orthopedics*. 2008;**134**(5):602.e1-602.e11
- [2] Fushima K, Kitamura Y, Mita H, Sato S, Kim Y. The significance of the cant of occlusal plane in class II/1 malocclusion. *European Journal of Orthodontics*. 1996;**18**:27-40
- [3] Kim H-S, Kim S-Y. Compensatory changes of a occlusal plane angles in relation to a skeletal factors. *Korea Journal of Orthodontics*. 2004;**34**(3):229-240
- [4] McNamara JA Jr, Carlson DS. Quantitative analysis of temporomandibular joint adaptations to protrusive function. *American Journal of Orthodontics*. 1979;**76**:593-611
- [5] Sato S. *A Treatment Approach to Malocclusions Under the Consideration of Craniofacial Dynamics*. Grace Printing Press, Philippines, inc; 2001
- [6] Kim YH. Overbite depth indicator with particular reference to anterior open-bite. *AJO*. 1974;**65**:586-611
- [7] Kim YH, Vietas JJ. Anteroposterior dysplasia indicator. *American Journal of Orthodontics*. 1978;**73**:619-633
- [8] Kim YH. ODI/APDI combination factor. *Angle Orthodontics*. 1979;**49**:77-84
- [9] Petrovic AG, Stutzman J. Control process in the postnatal growth of the condylar cartilage. In: McNamara JA Jr, editor. *Determinants of Mandibular Growth, Monograph 4: Craniofacial Growth Series*. Ann Arbor: Center for Human Growth and Development, University of Michigan; 1975
- [10] Kato S, Chung W-N, Sato S. Morphological characterization of different types of class II malocclusion. *Bulletin of Kanagawa Dental College*. September 2002;**30**(2):93-98
- [11] Kim YH. Treatment of anterior openbite and deep overbite malocclusions with MEAW therapy. In: McNamara JA Jr, editor. *The Enigma of Vertical Dimension-Craniofacial Growth Series*. Vol. 36. Ann Arbor: Center for Human Growth and Development-University of Michigan; 1999
- [12] Kim YH. Treatment of severe deep overbite in juveniles and in adults: An introduction to the reverse MEAW. *International Journal of MEAW Technic and Research Foundation*. 2004;**11**(1):12-32

- [13] Knierim RW. Diagnosis of openbite and deepbite problems: A clinician`s perspective on the Kim approach. In: McNamara JA Jr, editor. The Enigma of Vertical Dimension-Craniofacial Growth Series. Vol. 36. Ann Arbor: Center for Human Growth and Development-University of Michigan; 1999
- [14] Merrifield LL. The profile line as an aid to critical evaluation of facial esthetics. American Journal of Orthodontics. 1966;**11**:804-822
- [15] Ortial JP. Les modifications faciales par l`orthodontie. Journal de l`edgewise. 1989; **20**:53-86
- [16] Beltrão P. Treatment of class II deep overbite with multiloop edgewise arch-wire (MEAW) therapy. In: Naretto S, editor. Principles in Contemporary Orthodontics. InTech; 2011

