

We are IntechOpen, the world's leading publisher of Open Access books Built by scientists, for scientists

6,900

Open access books available

186,000

International authors and editors

200M

Downloads

Our authors are among the

154

Countries delivered to

TOP 1%

most cited scientists

12.2%

Contributors from top 500 universities



WEB OF SCIENCE™

Selection of our books indexed in the Book Citation Index
in Web of Science™ Core Collection (BKCI)

Interested in publishing with us?
Contact book.department@intechopen.com

Numbers displayed above are based on latest data collected.
For more information visit www.intechopen.com



An Approach to Diagnosing Supraventricular Tachycardias on the 12-Lead ECG

Sanoj Chacko and Adrian Baranchuk

Additional information is available at the end of the chapter

<http://dx.doi.org/10.5772/intechopen.70143>

Abstract

Supraventricular tachycardia (SVT) is a general term describing a group of arrhythmias whose mechanism involves the atria and atrioventricular nodal tissue for its initiation and maintenance. SVT is a common entity in clinical practice with a prevalence of 2.25 cases per 1000 in general population. Atrial fibrillation and atrial flutter are the most common presentations of SVTs. Of the remaining subtypes of SVT, atrioventricular nodal re-entrant tachycardia (AVNRT) accounts for 60% of the cases. The atrioventricular re-entrant tachycardia (AVRT) and atrial tachycardia (AT) represent approximately 30 and 10% of the cases, respectively. The mechanisms of different forms of SVT have been elucidated and are caused by either re-entrant circuit, increased automaticity or triggered activity. This chapter provides an overview of how to systematically approach a narrow complex tachycardia.

Keywords: supraventricular tachycardia, atrioventricular nodal re-entry tachycardia, atrioventricular re-entry tachycardia, atrial tachycardia, atrial fibrillation, atrial flutter

1. Introduction

A systematic approach in the interpretation of ECG is important to arrive at a definitive diagnosis of the subtype of supraventricular tachycardia (SVT). Narrow complex tachycardias (NCT) are broadly divided as regular or irregular tachycardia. Irregular NCT are either atrial fibrillation or atrial flutter with variable ventricular response. For a regular NCT, the next key step would be to identify the presence of a P wave, positive or negative P waves, and its morphology and location of the P wave with respect to the cardiac cycle. Absence of P wave in a regular NCT narrows the differential diagnosis to either typical atrioventricular nodal re-entrant tachycardia (AVNRT) or junctional tachycardia. If the P waves are positive and are located before the QRS complex, it is likely to be sinus tachycardia. On the other

hand, if the P waves are negative, that excludes a sinus origin of the rhythm. A negative P wave in front of the QRS complex implies a low atrial tachycardia (LAT). If the P waves embedded in the QRS complex have a short RP interval, it is described as short RP tachycardia, and the differentials would include typical AVNRT or atrioventricular re-entrant tachycardia (AVRT). If the RP interval is longer than the PR interval, the tachycardia is termed as long RP tachycardia, and the differentials would include atypical AVNRT or atrial tachycardia (AT) [1, 2]. The algorithm in **Figure 1** shows the flow chart of how to systematically approach a NCT.

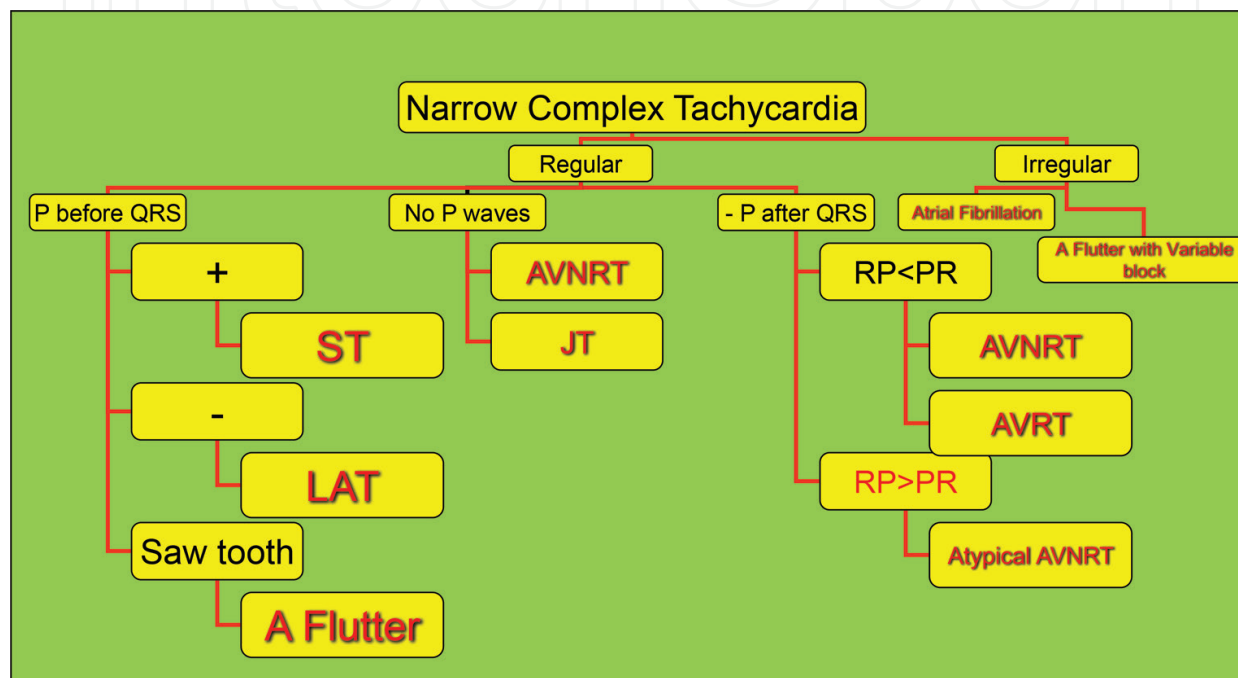


Figure 1. Algorithm for narrow complex tachycardia.

2. Subtypes of NCTs

1. Sinus tachycardia
2. Atrial fibrillation
3. Atrial flutter
4. Low atrial tachycardia
5. Typical AVNRT
6. Atypical AVNRT
7. Orthodromic AVRT
8. Junctional tachycardia

2.1. Sinus tachycardia

Sinus tachycardia is a normal physiological response to exercise or pathology in which catecholamine release is enhanced. Sinus tachycardia is described as inappropriate sinus tachycardia (IST), when individuals present with chronic non-paroxysmal sinus tachycardia, with a structurally normal heart and with no apparent causes for sinus tachycardia. Sinus tachycardia is also noted in young individuals with structurally normal heart, in whom there is an exaggerated heart rate response to upright position, termed as postural orthostatic tachycardia syndrome (POTS). ECG in **Figure 2** is an example of a regular narrow complex tachycardia with upright P-waves in front of QRS complex, in leads I and II indicating a sinus origin with 1:1 relationship, consistent with sinus tachycardia. Vagal maneuvers or atrioventricular (AV) nodal blocking agents may be useful in further determining the mechanism of tachycardia. **Figure 3** is an ECG of a patient with cardiac tamponade, showing sinus tachycardia with electrical alternans.

2.2. Atrial tachycardia (AT)

AT is a regular atrial rhythm originating from an ectopic focus either from the right or left atrium. Focal AT is usually paroxysmal but can also present as incessant tachycardia, causing left ventricular systolic dysfunction. Right ATs are usually located in the tricuspid annulus followed by crista terminalis, coronary sinus ostium, and perinodal tissues in the order of frequency. Similarly, the left ATs predominantly originate from the pulmonary veins followed by mitral annulus, interatrial septum, and left atrial appendage. Classically, an ECG reveals negative P waves in the inferior leads, suggesting a caudo-cranial atrial activation (**Figure 4**).

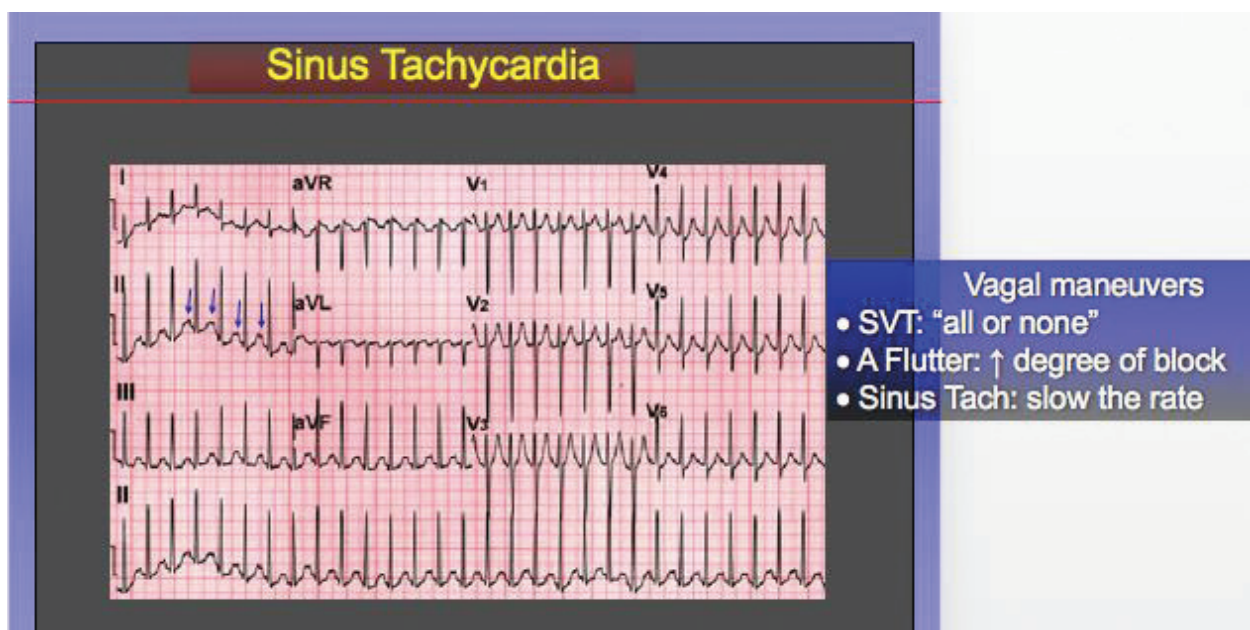


Figure 2. ECG showing sinus tachycardia with upright P-wave before the QRS complex (blue arrow) indicating sinus origin with 1:1 AV relationship.

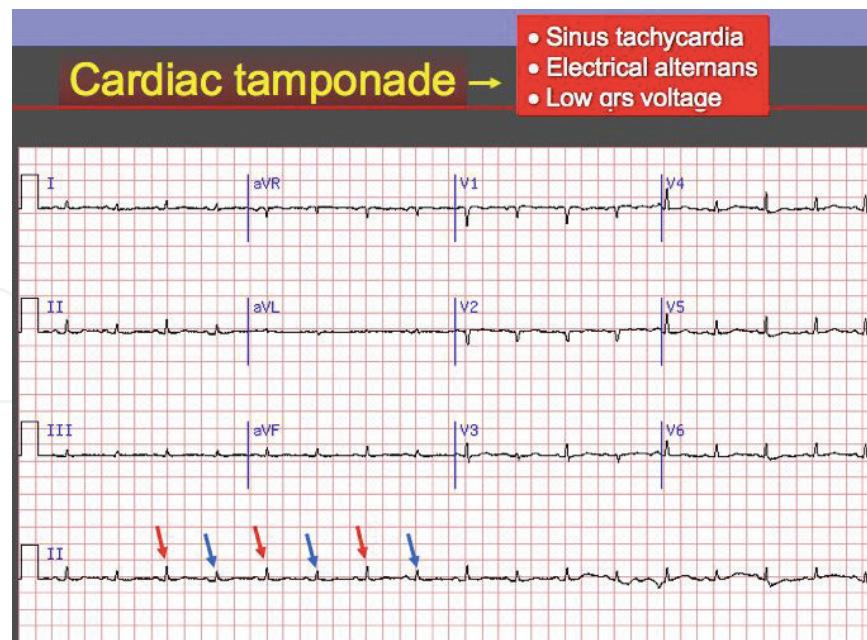


Figure 3. ECG showing sinus tachycardia with low QRS voltage and electrical alternans in a patient with cardiac tamponade.

2.3. Atrioventricular nodal re-entrant tachycardia (AVNRT)

Patients with AVNRT demonstrate dual AV nodal physiology, fast pathway with long refractory period and slow pathway with short refractory period. While 25–30% of the general population

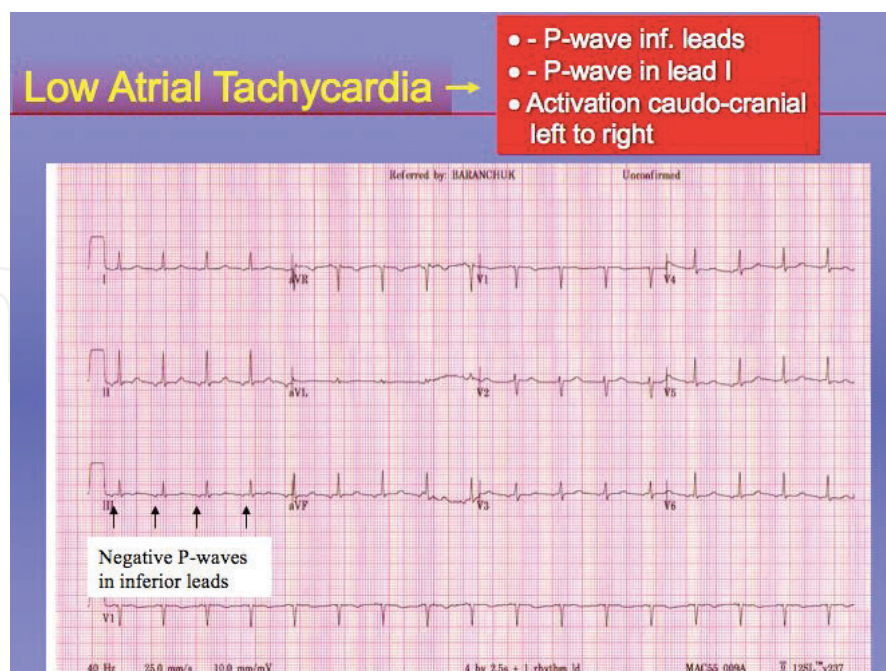


Figure 4. ECG showing negative P-waves in the inferior leads and lead I with caudo-cranial activation consistent with low atrial tachycardia.

has dual AV nodal physiology, only a minority of them develop AVNRT. Typically, a critically timed premature atrial contraction (PAC) initiates the tachycardia and the classical symptom involves abrupt onset and offset of palpitations. Typical AVNRT accounts for 80–90% of all AVNRTs. In slow–fast AVNRT, the antegrade conduction occurs through the slow pathway and retrograde conduction through the fast pathway. The 12-lead ECG typically shows a narrow complex tachycardia with absent P waves or retrograde P waves and RP interval of <100 ms (**Figure 5**) [3]. In atypical AVNRT, the antegrade conduction occurs down the fast pathway and retrograde conduction up the slow pathway [4], and the 12-lead ECG will reveal a narrow complex tachycardia, with $RP > PR$ interval, termed as long RP tachycardia.

2.4. Atrioventricular re-entrant tachycardia (AVRT)

AVRT is a re-entrant tachycardia with a circuit that consists of two distinct pathways, normal AV nodal conduction system and the accessory pathway. The accessory pathway may manifest as preexcitation in the surface ECG (delta wave) if the antegrade conduction is exclusively through the pathway or a combination of pathway and AV node or concealed (without preexcitation) if the conduction is exclusively through the AV node. AVRT is classified as orthodromic if the antegrade conduction occurs via the AV node and antidromic if antegrade conduction occurs through the accessory pathway. Orthodromic AVRT accounts for 90–95% of the AVRTs associated with Wolf-Parkinson-White (WPW) syndrome [5]. **Figure 6** shows a routine surface ECG of a young patient performed prior to a dental extraction. An ECG reveals preexcitation with positive delta wave in inferior leads, I, aVL, and negative delta

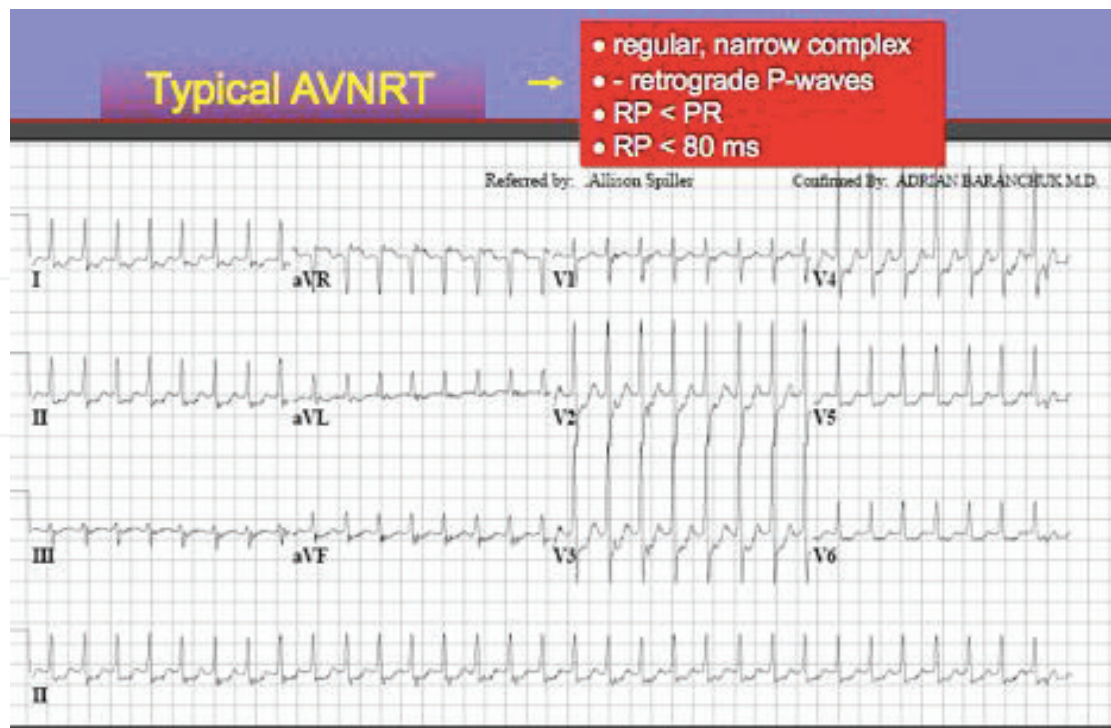


Figure 5. ECG showing regular narrow complex tachycardia with retrograde P waves. Short RP ($RP < PR$) tachycardia with a RP interval of <100 ms.

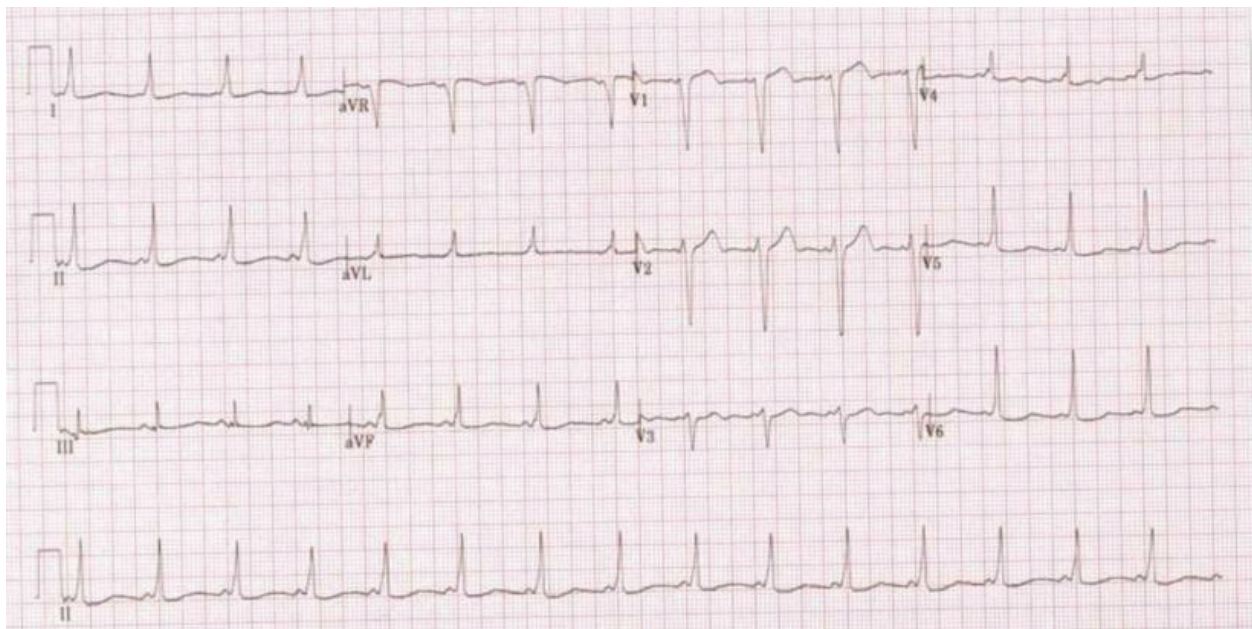


Figure 6. Surface ECG showing preexcitation with positive delta wave in inferior leads and I, aVL and negative delta wave in V1 consistent with a right anteroseptal accessory pathway.

wave in V1 consistent with possible right anteroseptal accessory pathway. **Figures 7 and 8** show a narrow complex tachycardia with retrograde P waves and long ventriculoatrial (VA) time consistent with orthodromic AVRT.

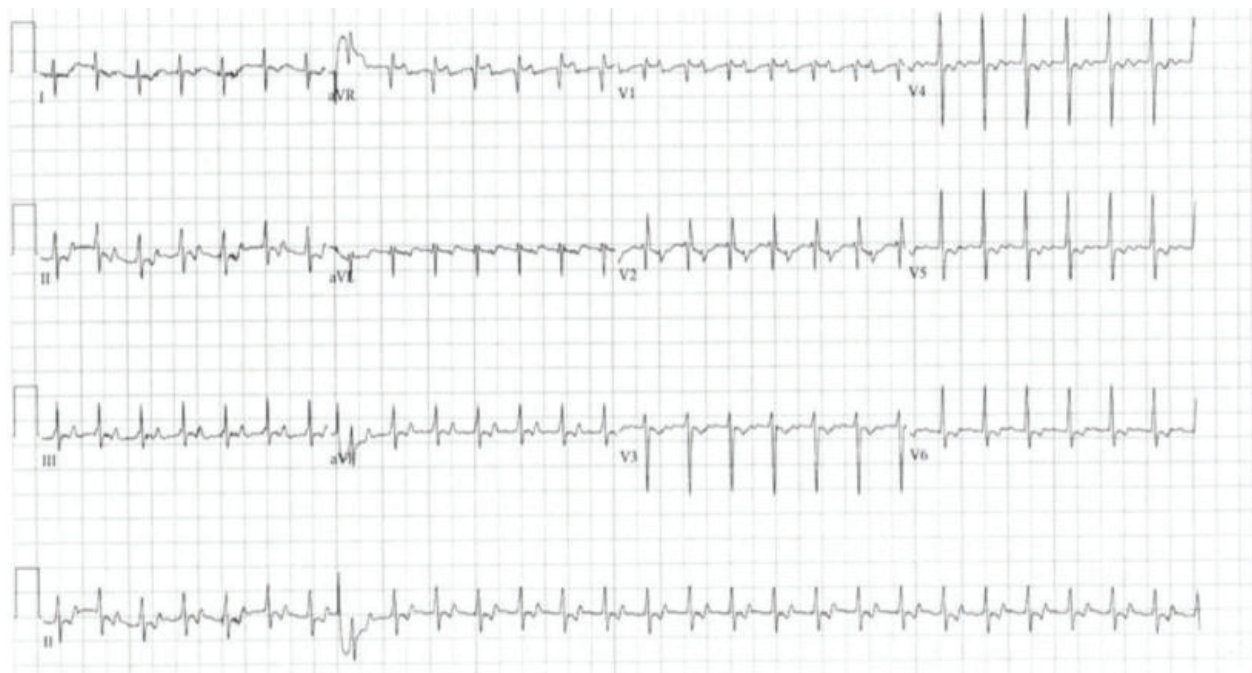

Figure 7. SVT with longer VA time (>100 ms) consistent with orthodromic AVRT.

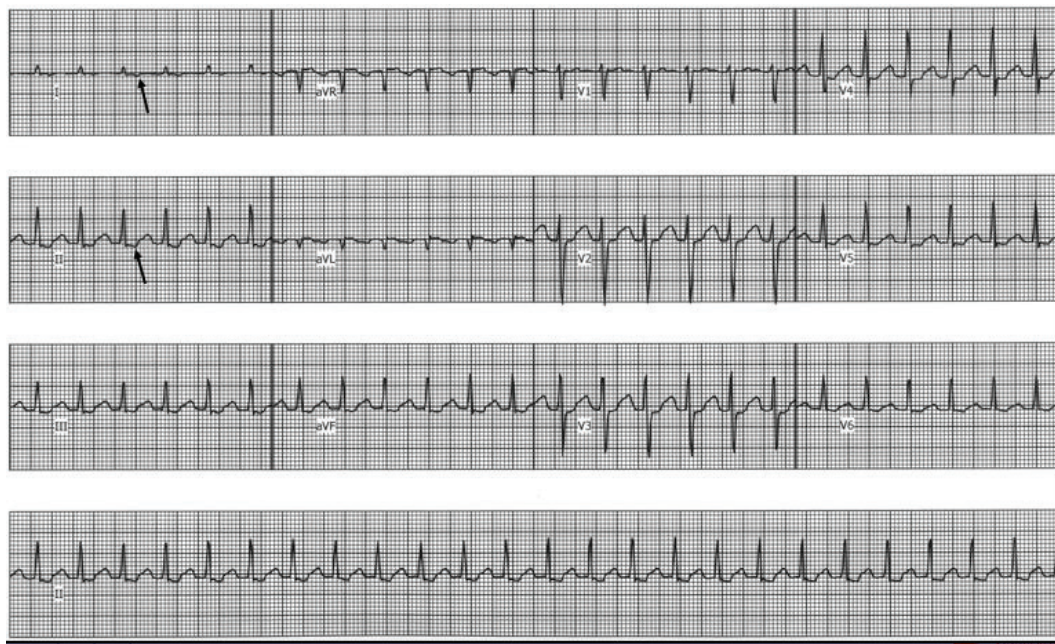

Figure 8. Regular narrow complex tachycardia with retrograde P-waves (black arrows), $RP < PR$ and $RP > 100$ ms.

3. SVT with aberrancy

Narrow complex SVT may present as wide complex rhythm in the setting of aberrant conduction or the presence of accessory pathway. This can pose a diagnostic dilemma in differentiating from ventricular tachycardia (VT). Accurate differentiation of SVT-A from VT is challenging but is key to decision making and management in the emergency setting. In an effort to distinguish between VT and SVT with aberrancy, Brugada and Wellen proposed criteria to help determine the diagnosis [6].

Brugada and Wellen's criteria

1. Absence of RS complexes in all precordial leads
2. R to S interval >100 ms in one precordial lead
3. AV dissociation
4. Morphology criteria of VT in precordial leads
5. Precordial QRS concordance
6. Capture or fusion beats
7. Left axis deviation

An ECG in **Figure 9** is an example of SVT with aberrant conduction, on a patient who presented with palpitation. Rhythm strip shows regular P waves with 1:1 atrioventricular conduction. In addition, an ECG does not meet any of the above criteria for VT. An ECG in **Figure 10** shows a wide complex tachycardia with pseudo "RBBB" morphology, R to S >100 ms in the pseudo "LBBB" morphology leads, and 2:1 VA conduction, consistent with VT.

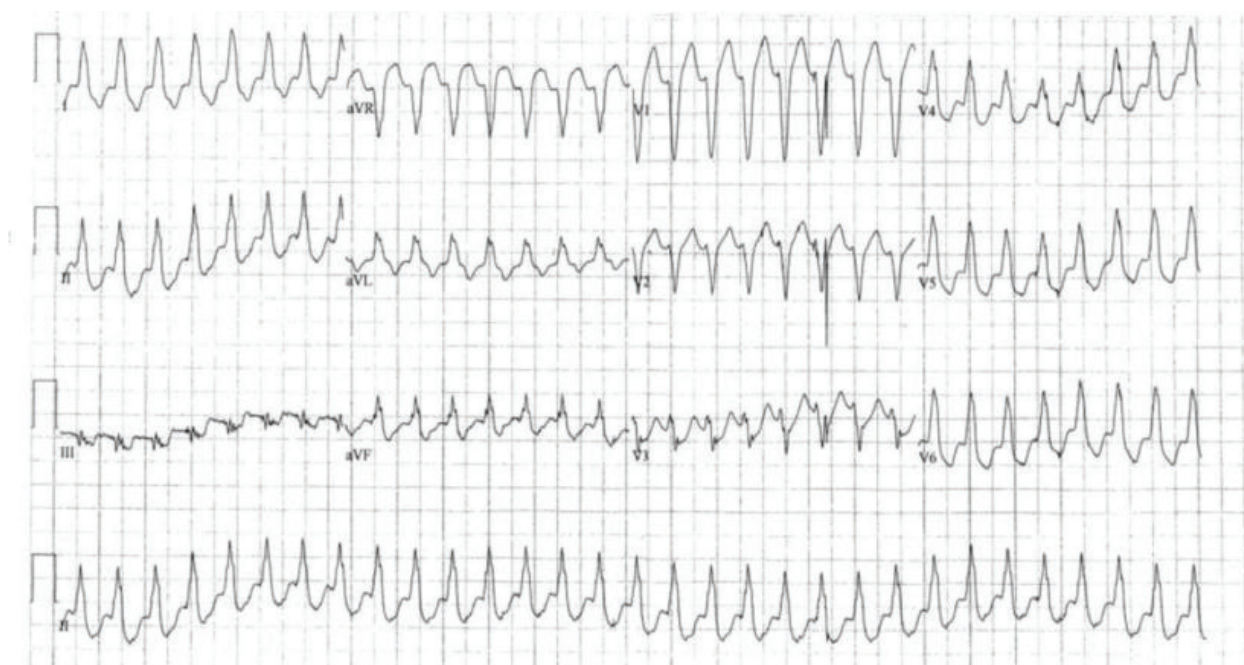


Figure 9. SVT with aberrancy.

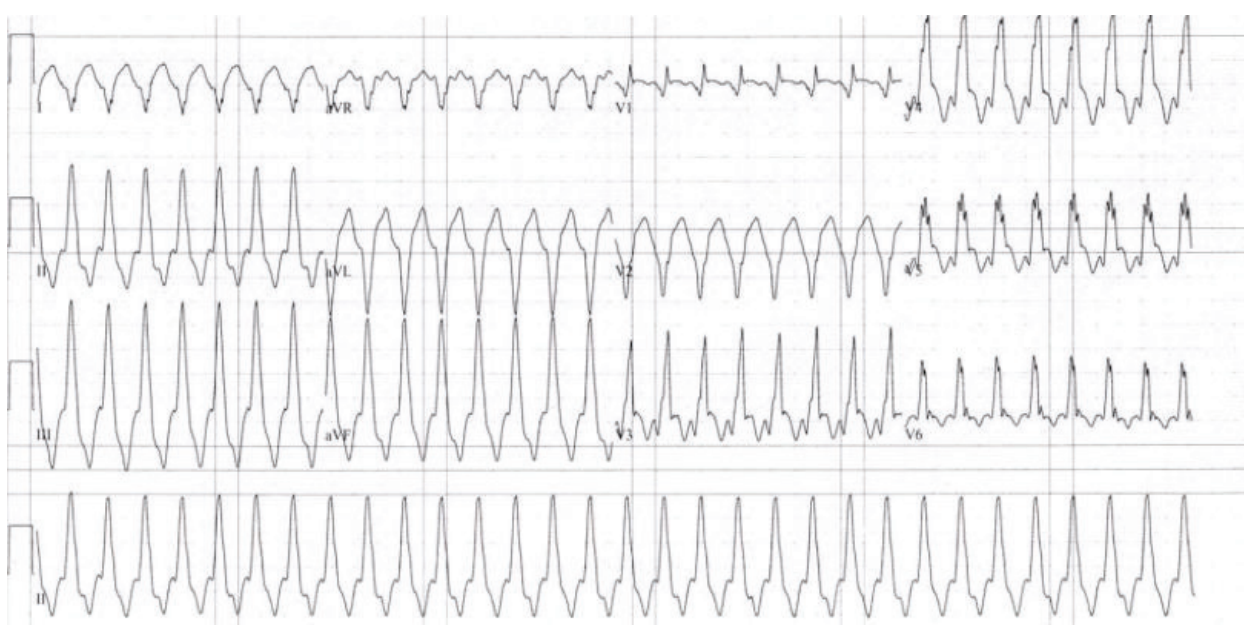

Figure 10. ECG showing wide complex tachycardia, RBBB morphology, R to S > 100 ms in V2, and 2:1 VA (blue arrows) conduction consistent with VT.

4. Conclusion

SVT includes a variety of tachycardias originating from the atria and atrioventricular nodal tissues. The subtypes of SVT differ in their physiological mechanism and presentation. The

unpredictability of the episodes and inability to control the disabling symptoms can render the patient incapacitated. Accurate diagnosis of the subtypes of SVT is essential to deliver the most appropriate therapy. Despite the highly specified symptomatic and ECG diagnostic criteria, arriving at a diagnosis is not always straightforward. A systematic approach to interpreting ECG is therefore crucial to narrow the differential diagnosis. Careful interpretation of ECGs can unfold important information, depict the underlying mechanism, and aid with the diagnosis and management.

Author details

Sanoj Chacko¹ and Adrian Baranchuk^{2*}

*Address all correspondence to: barancha@kgh.kari.net

1 Heart Rhythm Service, Kingston General Hospital, Queen's University, Kingston, Ontario, Canada

2 Division of Cardiology, Department of Medicine, Kingston General Hospital, Queen's University, Kingston, Ontario, Canada

References

- [1] Antzelevitch C, Burashnikov A. Overview of basic mechanisms of cardiac arrhythmia. *Cardiac Electrophysiology Clinics*. 2011 Mar 1;**3**(1):23-45
- [2] Kistler PM, Roberts-Thomson KC, Haqqani HM, et al. P-wave morphology in focal atrial tachycardia: Development of an algorithm to predict the anatomic site of origin. *Journal of the American College of Cardiology*. 2006 Sep 5;**48**(5):1010-1017
- [3] Katritsis DG, Camm AJ. Classification and differential diagnosis of atrioventricular nodal re-entrant tachycardia. *Europace*. 2006;**8**:29-36
- [4] Katritsis DG, Camm AJ. Atrioventricular nodal reentrant tachycardia. *Circulation*. 2010 Aug 24;**122**(8):831-840
- [5] Blomström-Lundqvist C, Scheinman MM, Aliot EM, et al. ACC/AHA/ESC guidelines for the management of patients with supraventricular arrhythmias—executive summary: A report of the American College of Cardiology/American Heart Association Task Force on Practice Guidelines and the European Society of Cardiology Committee for Practice Guidelines (writing committee to develop guidelines for the management of patients with supraventricular arrhythmias) developed in collaboration with NASPE-Heart Rhythm Society. *Journal of the American College of Cardiology*. 2003 Oct 15;**42**(8):1493-1531
- [6] Brugada P, Brugada J, Mont L, et al. A new approach to the differential diagnosis of a regular tachycardia with a wide QRS complex. *Circulation*. 1991;**83**:1649

