

We are IntechOpen, the world's leading publisher of Open Access books Built by scientists, for scientists

6,900

Open access books available

186,000

International authors and editors

200M

Downloads

Our authors are among the

154

Countries delivered to

TOP 1%

most cited scientists

12.2%

Contributors from top 500 universities



WEB OF SCIENCE™

Selection of our books indexed in the Book Citation Index
in Web of Science™ Core Collection (BKCI)

Interested in publishing with us?
Contact book.department@intechopen.com

Numbers displayed above are based on latest data collected.
For more information visit www.intechopen.com



Superior Capsule Reconstruction: Review of a Novel Operative Technique for Management of Irreparable Rotator Cuff Tears

Alexander Golant, Daiji Kano, Tony Quach,
Kevin Jiang and Jeffrey E. Rosen

Additional information is available at the end of the chapter

<http://dx.doi.org/10.5772/intechopen.70049>

Abstract

Rotator cuff tear is a common yet functionally debilitating shoulder condition. Risk factors for failure of repair or inability to repair include advancing age of the patient, chronicity of the tear, and larger tear size. Current operative management options for tears that are considered irreparable include debridement, partial repair, biceps tenotomy, interpositional grafting, tendon transfers, and reverse shoulder arthroplasty. Recently, superior capsular reconstruction has been introduced as an alternative surgical option for these tears and has demonstrated favorable short-term outcomes. However, the literature lacks studies with large numbers of patients, consistency of results, and long-term outcomes. This article reviews the anatomy and function of the rotator cuff and shoulder capsule; patho-etiology of rotator cuff tears, particularly the irreparable ones; and rationale, techniques, outcomes, and future direction of superior capsular reconstruction in the context of this clinical indication.

Keywords: shoulder, rotator cuff tear, massive rotator cuff tear, irreparable rotator cuff tear, rotator cuff repair, rotator cuff reconstruction, superior capsule reconstruction, superior capsular reconstruction

1. Introduction

Rotator cuff tears affect millions worldwide; given their age-dependent increase in prevalence, they pose a significant healthcare burden on today's aging population [1]. Chronic large to massive rotator cuff tears are often considered "irreparable" secondary to poor tissue quality, tendon retraction, and muscle atrophy and fatty infiltration [2]. Surgical options

for treatment of these tears have not demonstrated consistently good outcomes [2–4]. These include attempts at relieving pain by way of debridement with or without biceps tenotomy; balancing the anterior/posterior force couples by way of partial repair; restoring cuff integrity by way of interpositional grafting; and tendon transfers. Reverse shoulder arthroplasty has been gaining popularity and demonstrates good outcomes as a treatment option for patients with rotator cuff arthropathy, but is typically reserved for the elderly patients. Massive and irreparable rotator cuff tears in younger and more active individuals, especially without significant arthritic changes of the glenohumeral joint, remain a clinical conundrum.

Recently, a new surgical procedure called superior capsular reconstruction (SCR) was described by Mihata et al., who reported promising short-term clinical outcomes in 24 shoulders (23 consecutive patients) with symptomatic irreparable rotator cuff tears [2]. Although the procedure has a strong appeal for physicians treating patients with this difficult problem and has been quickly gaining popularity, caution regarding widespread use is warranted, as large-scale and long-term data is still lacking. This chapter reviews the anatomy and function of the rotator cuff and shoulder capsule; patho-etiology of rotator cuff tears; and rationale, techniques, outcomes, and future direction of superior capsule reconstruction for irreparable tears.

2. Anatomy, biomechanics, and functions of the rotator cuff

2.1. Structural anatomy

2.1.1. Rotator cuff, interval, crescent, and cable

The rotator cuff is composed of the musculotendinous units that bound the glenohumeral joint. Its components are supraspinatus (SS), infraspinatus (IS), teres minor (TM), and subscapularis (SSC) muscles [5, 6] (**Figure 1**). The supraspinatus, which is most commonly involved in rotator cuff tears, originates on the superior aspect of the scapular body, in the supraspinous fossa, and inserts onto the anterior-superior aspect of the greater tuberosity of the humerus. The infraspinatus originates on the posterior scapular body, from the infraspinous fossa, and inserts on the posterior-superior aspect of the greater tuberosity. The teres minor, which is rarely involved in rotator cuff tears, originates from the lateral lower-half of the scapular body, inferior to the infraspinatus, and inserts on the posterior – inferior aspect of the great tuberosity and humeral head. The subscapularis, which is the largest muscle of the rotator cuff group, originates from the anterior scapular body (the subscapular fossa), runs deep to the coracoid process, and inserts onto the lesser tuberosity of the humerus. Innervation to the rotator cuff comes from the C5-6 nerve roots, with the suprascapular nerve supplying the supraspinatus and infraspinatus, axillary nerve supplying teres minor, and the upper and lower subscapular nerves supplying the subscapularis. The close interplay and confluence of the different parts of the rotator cuff creates several structures important for glenohumeral joint stability and function. These include the rotator interval, crescent, and cable.

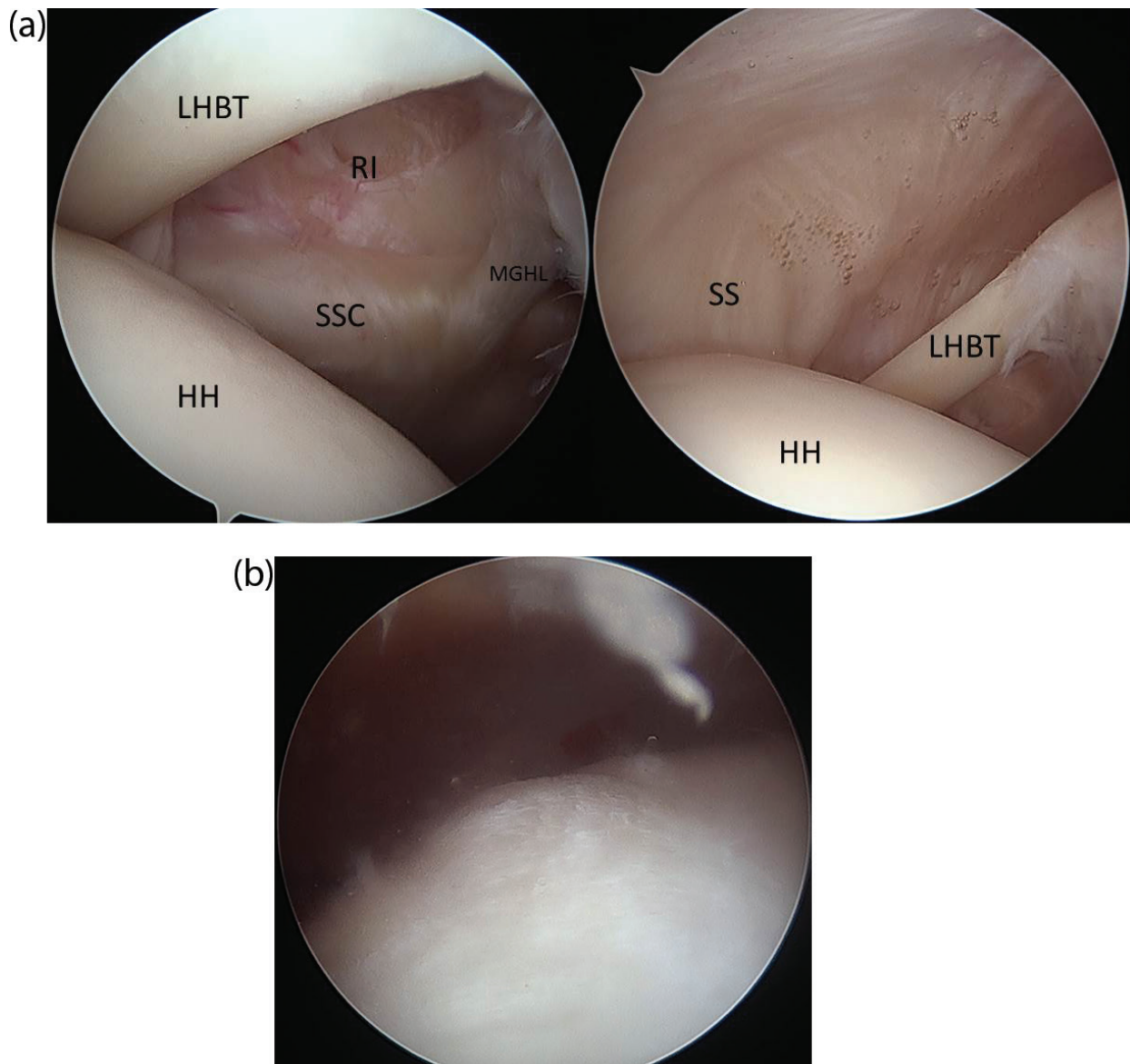


Figure 1. Arthroscopic views of the rotator cuff tendons (left shoulder). (A) Intraarticular view from the posterior portal, showing the humeral head (HH), supraspinatus (SS), subscapularis (SSC), the long-head of the biceps tendon (LHBT), the middle glenohumeral ligament (MGHL), and rotator interval (RI). (B) Bursal view of the superior rotator cuff (SS and IS)..

The rotator interval (**Figure 1A**) is the anterior triangular space between the anterior border of the supraspinatus and superior border of the subscapularis, and contains the anterior glenohumeral joint capsule, the coracohumeral ligament (CHL), and the superior glenohumeral ligament (SGHL). The interval helps maintain the biceps tendon within the bicipital groove, and also contributes to stability of the glenohumeral joint [7, 8]. The rotator interval is also often implicated in the adhesions and contractures that occur in adhesive capsulitis of the shoulder.

The rotator crescent is a thin sheet of rotator cuff tendon, comprising the distal portions of the SS and IS insertions. The crescent is proximally bound by a thick bundle of fibers—the rotator cable—that runs perpendicular to the SS and IS fibers. Burkhart et al. described a biomechanical

model of rotator cuff tears using 20 cadaver shoulders, where the rotator cable acts as a stress shield for the crescent, and the two structures form a “suspension bridge.” According to this model, tears in the crescent have minimal effects on shoulder function, while those that involve the cable impair its ability to distribute the load and tension between the anterior and posterior rotator cuff and therefore its role as a dynamic stabilizer of the humeral head [9]. This concept has clinical implications as it helps guide decision making in identifying tears that can be managed non-operatively, versus those that require surgical fixation.

2.1.2. *Shoulder capsule*

While the rotator cuff is the main dynamic stabilizer of the glenohumeral joint, the glenohumeral joint capsule acts as a static stabilizer. It is a thin membranous structure located deep to the rotator cuff; it originates medially from the glenoid neck and inserts laterally to the anatomical neck of humerus.

The capsule is thicker anteriorly than posteriorly. The anterior capsule contains focal thickened bundles, which are called superior, middle, and anterior-inferior glenohumeral ligaments (GHL). The posterior capsule has an inferior thickening called the posterior-inferior GHL, but does not have separate ligaments further superiorly. Directly inferiorly, between the anterior-inferior and posterior-inferior glenohumeral ligaments, the capsule forms the axillary pouch, which tightens in abduction, and relaxes in adduction [3–5, 10]. Contracture and loss of normal axillary pouch volume is frequently seen in adhesive capsulitis, whereas a patulous capsule with an enlarged pouch is often seen in multi-directional shoulder instability.

The superior capsule is thin and was previously less well-studied. It originates from the glenoid neck along with its anterior-posterior counterparts, courses directly underneath the SS and anterior part of the IS, and attaches to 30–61% of surface area of the greater tuberosity (GT) [5, 10]. Nimura et al. measured superior capsule attachments in cadaveric shoulders. They reported thicker footprint at the anterior edge of SS and posterior edge of IS (5.6 ± 1.6 mm and 9.1 ± 1.7 mm, respectively), whereas the attachment was thinner at the middle area of the rotator cuff, near the posterior margin of SS (4.4 ± 1.2 mm). The authors concluded that the thinnest point of the capsule could contribute to the etiology of the initiation of degenerative rotator cuff tears [5]. The superior capsule is closely associated with the SS and IS, and typically tears together with complete tears of these tendons [1–4].

2.2. Function

The muscles of the rotator cuff help initiate movement of the shoulder joint, and also serve as the main dynamic stabilizer of this joint. Supraspinatus aids in abduction of the humerus, particularly in the scapular plane; external rotation is provided by infraspinatus (more active in adduction), and teres minor (more active in abduction); and internal rotation is the function of subscapularis. Furthermore, SS prevents abnormal inferior-superior translation of the humeral head, particularly during active arm elevation, by compressing the head into the glenoid fossa. The balancing forces between SSC anteriorly and IS and TM posteriorly provide stability in the sagittal plane, and the upward force of the deltoid is balanced by that of IS, TM, and SSC in the coronal plane [11, 12].

The shoulder capsule provides static stability, serving to prevent excessive translation of the humeral head relative to the glenoid [5, 10]. The anterior capsule prevents anterior translation, while the posterior prevents posterior translation. The function of the superior capsule was previously poorly understood and continues to be studied. Ishihara et al. demonstrated in a biomechanical study that the superior capsule plays an important role in passive stability in all directions, and cutting it significantly increases abnormal translation, especially superiorly [10]. This can lead to a decrease in the acromiohumeral distance—a finding commonly seen in patients with chronic massive superior cuff tears as well as cuff-tear arthropathy [2] (**Figure 2**).

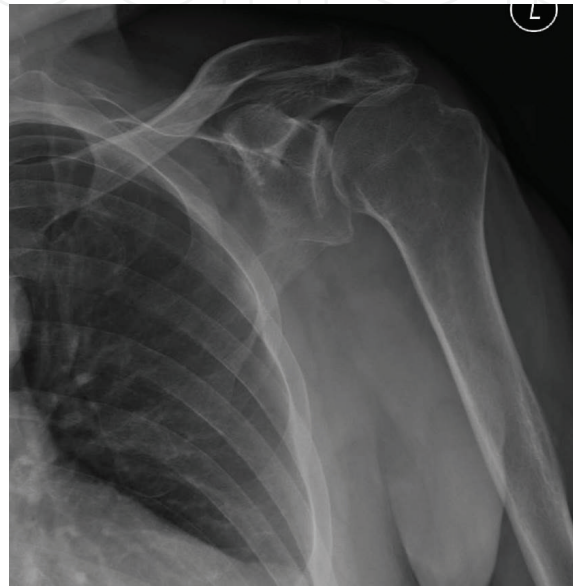

Figure 2. Anterior-posterior plain radiograph of a left shoulder with rotator cuff arthropathy. Note the “high-riding” humeral head, with a decreased acromiohumeral distance, and interrupted Shenton’s line at the inferior aspect of the glenohumeral joint.

3. Etiology of rotator cuff tears

While a significant number of rotator cuff tear cases present to the physician after a traumatic episode, most tears do not occur in a setting of a normal tendon. Preexisting degenerative changes are usually found in the torn tendons, and the injury that leads to clinical presentation is likely the “straw that breaks the camel’s back.” A number of both intrinsic and extrinsic pathways and risk factors are thought to contribute to chronic degeneration and weakening of the cuff tendons, as described below (**Table 1**).

The main intrinsic mechanism pathway is thought to be tenocyte apoptosis and inflammation resulting from chronic microtrauma to the rotator cuff tendons. Advancing age is the most common reason for this mechanism, and age has been found to be the strongest risk factor for rotator cuff disease. This is thought to be due to the combination of age-related degenerative changes and accumulation of microtrauma and macrotrauma over the course of an individual’s lifetime [3, 4]. Older patients are also more likely to develop larger tears; Gumina et al.

Strong association	Controversial or weak association
Age (particularly >60)	Peripartum Hormonal changes
Smoking (dose and time-dependent)	Dominant side
Family history	Postural abnormalities
Previous history of tear	
Trauma	
Hypercholesterolemia	
Heavy labor and overhead athletes (chronic wear-and-tear)	

Table 1. Risk factors for rotator cuff pathology.

reported a mean age of 59 years in a group of 586 patients undergoing arthroscopic tear repair, with those older than 60 being twice as likely to develop large and massive tears [13].

Tendon degeneration and poor healing potential are exacerbated by hypovascularity, which is worsened not only with advancing age, but also with smoking, and certain other conditions [4]. Smoking has a strong dose and time-dependent association with both the prevalence and size of tears; it negatively affects the vascularity of tendons, thereby predisposing them to tears and preventing healing [3, 4]. Similarly, hypercholesterolemia has been implicated in rotator cuff disease. The mechanism here is thought to be deposition of cholesterol by-products within the rotator cuff tendons, leading to worsening of biomechanical properties of the tendon and increasing the risk of tearing [14].

Genetic predisposition may also play a role. Patients diagnosed relatively early in life (before age 40) often have a family history of rotator cuff disease [3]. Particularly in irreparable tears, studies have shown expression of genes that favor fatty atrophy and fibrosis and inhibit myogenesis [15].

The most commonly accepted extrinsic mechanism for rotator cuff disease was originally described by Neer in his classic article from 1972, *Anterior Acromioplasty for the Chronic Impingement Syndrome in the Shoulder: a Preliminary Report*, and has guided clinical approach to management of impingement and rotator cuff tears ever since, although validity of some of these concepts has been challenged in the recent years. Neer suggested that repetitive contact between the rotator cuff tendons and the underside of the coracoacromial arch (which includes the anterolateral acromion, coracoacromial ligament, and the coracoid) results in trauma to the tendon, which produces the clinical entities of subacromial or subcoracoid impingement, and, in its more advanced stages, tendon tears [16]. Acromial morphology (hooked versus flat) and presence of subacromial enthesophytes have also been proposed to be contributing factors to symptomatic cuff disease, and surgical approach directed at increasing the space under coracoacromial arch by way of acromioplasty and coracoacromial ligament release has been advocated [17]. However, recent studies have questioned the benefit of these procedures [18], and attention has been directed to position and dynamic function of the scapula, as a contributor to rotator cuff impingement and tears [19]. Therefore, postural abnormalities and peri-scapular muscle strength have received greater recent attention as potentially contributing risk factor that can and should be addressed in management of rotator cuff disease.

4. Outcomes of rotator cuff repair

Rotator cuff repair was originally performed with open, and subsequently mini-open, techniques, which have produced good results, including restoration of shoulder strength and function. Advent and popularization of arthroscopy have allowed for a less invasive method of rotator cuff repair, contributing to decreased postoperative pain and more rapid return of motion. Other modern advancements, such as improved instrumentation, as well as stronger and more biocompatible suture and anchor materials, have led to new surgical techniques, such as a double-row rotator repair, which may contribute to better healing and possibly improved outcomes, especially for larger tears. Multiple clinical studies of arthroscopic repair have shown good to excellent results in as many as 90% of patients postoperatively, even including those with large and massive tears [20–23]. A recent systemic review and meta-analysis by McElvany et al. [24] included 108 clinical studies and showed postoperative clinical outcomes scores improved by an average of 103% of the preoperative scores. However, despite the overall good results, this same study found that 26.6% of the repairs failed to heal. Failure to heal may not (and often does not) affect short-term results, but may lead to deterioration of shoulder function after 2 years post-repair. Risk factors for failure of the rotator cuff tear to heal after surgery include preoperative fatty infiltration of the muscle, older age, and increased tear size. As many as 50% of larger (≥ 3 cm) tears may fail to heal after repair.

One of the most important predictors for failure of rotator cuff repair, along with tear size, is muscle atrophy and fatty infiltration (**Figure 3**). Most common system used to classify fatty degeneration of rotator cuff muscles was described by Goutallier et al. [25]. Even small and medium tears are at risk for failure after repair with as little as grade 2 muscle degeneration [26]. Shoulders with more severe (grade 3 or 4) degeneration, where more than 50% of muscle volume is replaced by fat, are at a very high risk of poor outcomes, since, even if tendon repair and healing to bone is achieved, dynamic function of the rotator cuff muscle-tendon unit remains compromised.

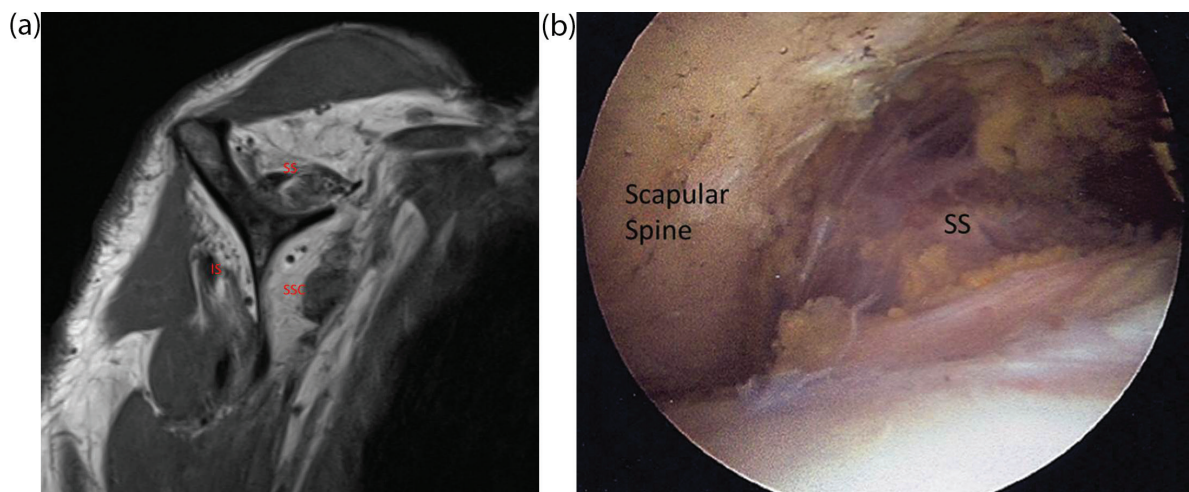


Figure 3. Fatty atrophy of the superior rotator cuff. (A) Sagittal MRI view of a right shoulder showing severe fatty degeneration (more than 50% of muscle volume replaced by fat) of the supraspinatus (SS), infraspinatus (IS), and subscapularis (SSC) muscles. (B) Arthroscopic view of the supraspinatus (SS), demonstrating severe muscle atrophy (view from a posterolateral subacromial portal in the right shoulder).

Therefore, due to poor healing potential and low likelihood of restoration of good cuff function, chronic large (3–5 cm) and massive (>5 cm) tears, especially those with Goutallier 2 or greater atrophy, may be considered irreparable. Other types of tears that are considered irreparable include tears with significant retraction of the tendon (medial to the glenoid), poor tendon quality for repair, and poor bone quality at the greater tuberosity attachment site (**Figure 4**). Attempts at repair of tears with these features should be approached with guarded expectations.

Those rotator cuff tears that fail to heal or are irreparable frequently go on to a clinical condition called cuff tear arthropathy (CTA) (**Figure 2**). This is a specific form of shoulder arthritis resulting from rotator cuff deficiency. Due to the failure and absence of superior restraint, the humeral head typically migrates superiorly, and eventually articulates with the acromion. Over time this leads to wear of the acromion, destruction of the humeral head cartilage, and eventually the glenoid cartilage as well. Patients typically present with significant pain, weakness, and crepitus with range of motion, and sometimes even pseudoparalysis—severe inability to elevate the shoulder. Once advanced CTA develops, the only surgical solution available to treat it (other than fusion of the shoulder joint) is a reverse total shoulder replacement (**Figure 5**).

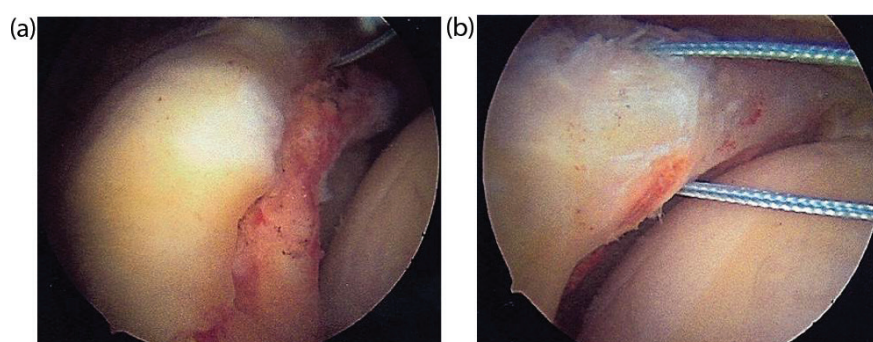


Figure 4. Massive tear of the superior rotator cuff, not amenable to repair. (A) Note poor tissue quality of the tendon stump, and retraction medial to the glenoid rim. (B) Despite extensive releases, this tendon stump could not be mobilized even to the medial margin of the greater tuberosity.

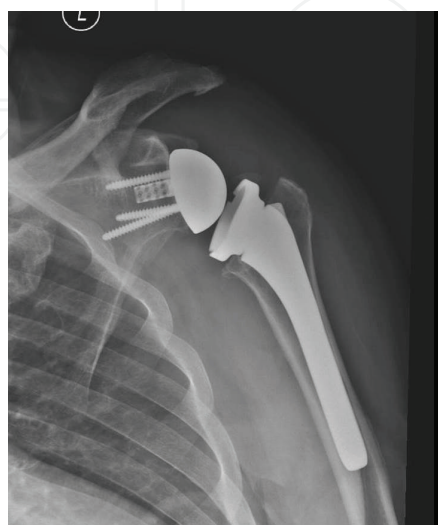

Figure 5. Reverse shoulder replacement in a 60 year-old man, performed for symptomatic advanced cuff-tear arthropathy.

5. Treatment options for irreparable rotator cuff tears

The treatment of massive and irreparable rotator cuff tears is challenging. Surgical options include partial repair with marginal convergence, debridement with biceps tenotomy, graft interposition, tendon transfer, reverse total shoulder, and now superior capsular reconstruction. Partial repair of the inferior half of the infraspinatus was originally described by Burkhart et al. in 1994, with the goal restoring a balanced anterior-posterior force couple in the shoulder [27]. Multiple studies which analyzed surgery for massive cuff tears with combinations of partial repair, marginal convergence, debridement, and biceps tenotomy have shown mixed results, typically with good outcomes early on, but persistent strength deficit in elevation, and deterioration of clinical results over time. For example, Shon et al. performed partial repair and marginal convergence techniques in 31 patients and found initial improvement in clinical outcome scores, whereas 2-year follow-up showed a dissatisfaction rate of 50% [28]. Fatty infiltration of the infraspinatus was found to be a negative predictor of outcome in these patients.

Graft interposition techniques to bridge irreparable rotator cuff defects have been described using autograft, allograft, xenograft, and synthetic materials. A systematic review of these techniques found a lack of high quality comparative studies. The limited studies available show improvement in clinical outcomes in all graft types [29], with allograft, xenograft, and synthetic grafts having the appeal of no harvest site morbidity, compared to autograft. On the other hand, significant inflammatory reactions have been reported with the use of xenografts as well as allografts [30], and therefore caution must be used. Just as with other surgeries for massive cuff tear, significant fatty atrophy leads to significantly lower healing rates after graft interposition repairs. Finally, interpositional grafts may need to be placed through an open approach, which runs the increased risk of damage to the deltoid muscle, potentially making subsequent revision surgery more difficult and less successful. In summary, due to lack of high quality comparative studies on the use of graft interposition for cuff repair, the potential benefits of this procedure must be weighed against the cost, risks, and potential future complications of this approach.

Several tendon transfer procedures have been described for the treatment of massive irreparable rotator cuff tears. Tendon transfers are typically performed in younger patients without glenohumeral arthritis and good range of motion. The most common transfers used for posterosuperior tears are latissimus dorsi and lower trapezius transfers. Clinical studies show latissimus dorsi transfer provides significant pain relief after tendon transfer, whereas functional results are more unpredictable [31]. Lower trapezius transfer anatomically provides a more direct line of pull compared to latissimus dorsi transfer; however, limited clinical evidence is available to show improvement in pain and function.

Reverse total shoulder arthroplasty (RTSA) is a semiconstrained reverse ball and socket prosthesis which helps improve the biomechanical efficiency of the deltoid muscle by lengthening its lever arm. The design provides inherent glenohumeral stability and lowers the humeral head to increase deltoid tension, which allows this muscle to elevate the arm without a functional rotator cuff. While elevation is typically restored after RTSA, active rotation of the shoulder is not as easily recovered as it relies on presence of the anterior-posterior components of the cuff. Overall, clinical studies have shown significant improvements in pain, motion, and functional scores in patients treated for cuff-tear arthropathy. However, implant longevity

is a concern, as are functional limitations imposed by this surgery. Due to these limitations, reverse shoulder arthroplasty is typically reserved for patients in their 60s, 70s, and older [32].

6. Rationale, indications, and contraindications for superior capsule reconstruction (SCR)

The main reason to consider superior capsule reconstruction (SCR) is as an alternative to reverse shoulder arthroplasty or tendon transfers in patients with irreparable superior rotator cuff tears, with or without early cuff tear arthropathy. In this procedure a graft tissue is attached to the superior glenoid and the greater tuberosity, thereby spanning the superior aspect of the glenohumeral joint (**Figure 6**). The biomechanical rationale behind this surgery is debated. One proposed rationale is a tenodesis effect between the glenoid and the humeral head, which helps regain the stabilizing effect to the glenohumeral articulation normally conferred by the superior capsule and the rotator cuff [2]. This has been called the “reverse trampoline” effect. The other proposed mechanism is that the inserted graft acts a spacer between the humeral head and the underside of the acromion, essentially keeping the head depressed by

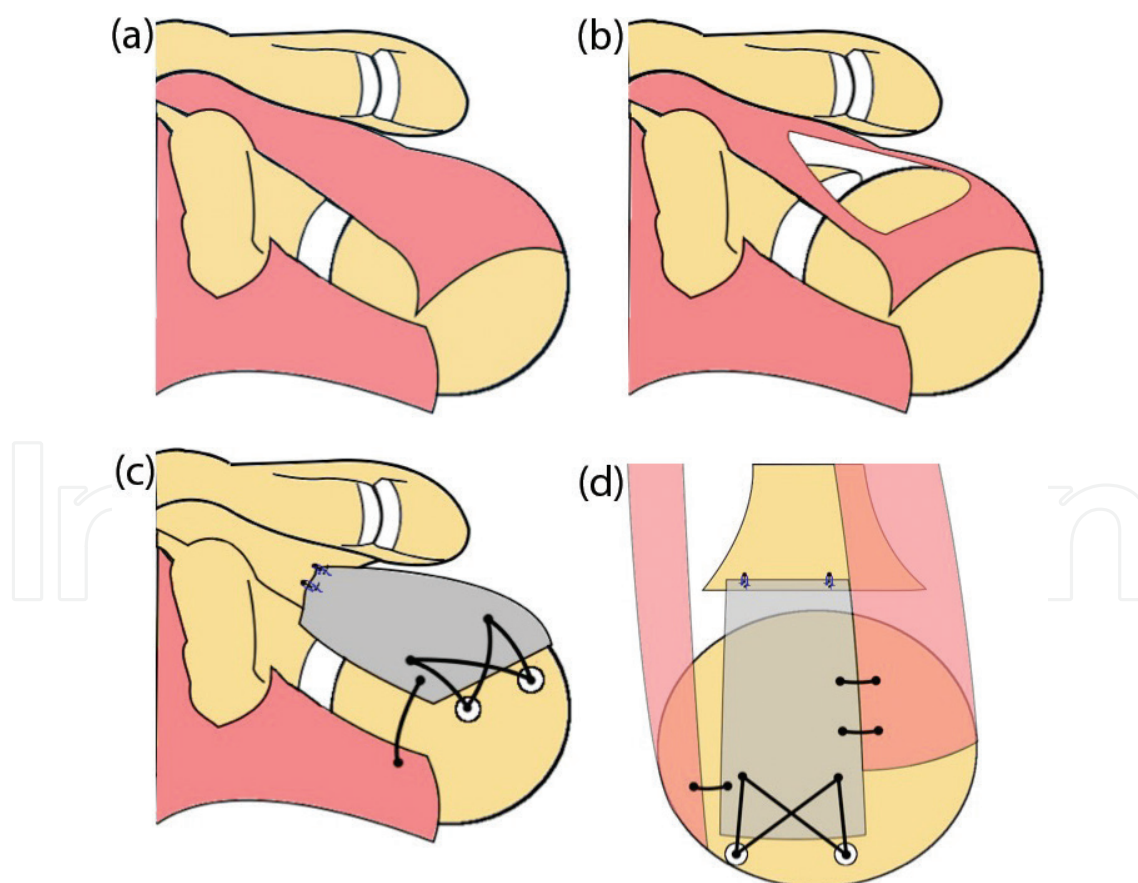


Figure 6. Schematic drawing, showing a shoulder with a normal superior rotator cuff (A), a large and irreparable defect of the superior cuff (B), and after a SCR (C and D).

way occupying the space above it. Biomechanical cadaveric studies by Mihata and colleagues have shown that SCR does restore superior translation to physiologic conditions [33]; and also that increased thickness of the graft improves stability [34]. These studies lend credence to both theories regarding biomechanical function of SCR; indeed both factors may be at play.

Indications for this surgery currently include physiologically young (absolute age has not been determined) and relatively active patients with symptomatic irreparable superior rotator cuff, with intact anterior-posterior force couples, and no or minimal glenohumeral arthritic wear. Young patients with moderate cartilage wear and symptoms primarily related to cuff function may be considered for SCR, in lieu of RTSA, but guarded expectation are warranted with more severe arthritic wear. SCR may also be an attractive option for previous failed cuff repair, in a setting of poor tissue quality, fatty infiltration, and other factors that may result in tear irreparability.

Absolute contraindications include infection, neuropathic disease of the shoulder, and neurologic disorders significantly affecting function of the deltoid muscle. Relative contraindications include advanced arthritis, tears of the anterior/posterior rotator cuff, as well as unwillingness or inability to comply with postoperative immobilization and rehabilitation protocol.

7. Technique

Arthroscopic reconstruction using tensor fascia lata was initially proposed by Mihata et al. [2]. Several other authors have reported SCR using acellular dermal allograft [35–39]. An arthroscopic technique is typically used for this procedure, but an open technique may be used in cases of difficult arthroscopic exposure or for surgeons less familiar with arthroscopic techniques. We describe our preferred technique for arthroscopic superior capsular reconstruction.

7.1. Surgical positioning

Surgery is typically performed in an ambulatory setting, under combination general and regional anesthesia. After induction of anesthesia, and prior to positioning (with the patient supine on the operating table), the shoulder should be examined for passive motion and stability. Manipulation of the shoulder to regain motion should be performed as needed. We prefer a beach-chair position with the arm supported by a hydraulic arm positioner device, but a lateral decubitus with balanced suspension-traction may also be used.

7.2. Diagnostic arthroscopy and associated procedures

Standard posterior portal is used to enter the glenohumeral joint, and an anterior portal is established in the rotator interval. A thorough diagnostic arthroscopy of the glenohumeral joint is performed, and pathologic lesions are addressed as needed. Particular attention must be paid to the integrity of the subscapularis tendon, which needs to be repaired if significantly

torn. If the biceps tendon is still present in the joint (more often than not there is a chronic tear and absence of the long head), it needs to be removed from the superior glenoid, so that it does not block graft placement; a tenotomy or tenodesis is performed. Any loose bodies should be removed, and synovectomy is performed as needed. Chondroplasty may be performed for frayed and unstable cartilage flaps on the humeral head and glenoid.

The camera is then repositioned into the subacromial space. Subacromial portals are created, typically one anterolaterally and one posterolaterally. A bursectomy is performed, and the rotator cuff tear is then carefully evaluated, characterized and mobilized, ensuring that a repair is not possible or not advisable. A superior capsular reconstruction is considered if there is a massive full-thickness tear of the supraspinatus, without or without infraspinatus tear, that cannot be repaired, and the glenohumeral joint does not show severe degenerative changes (**Figure 7**).

Once a decision is made to perform a SCR, an acromioplasty should be performed, to increase working space for graft placement and fixation, and also to decrease the risk of graft tissue abrasion postoperatively [40]. Any osteophytes off the inferior aspect of the AC joint need to be resected as well (**Figure 8**). We always attempt to preserve the CA ligament, if possible, so as not to disrupt the coracoacromial arch.

We also prefer at this time to place #2 braided sutures into the upper borders of the intact cuff posteriorly (teres minor or infraspinatus) and anteriorly (subscapularis or intact anterior fibers of the supraspinatus); these are used, after graft fixation, to repair the native cuff to the patch, side to side. Additionally, if there is any significant cuff tissue remaining medially, overlying the glenoid rim, it can be tagged with a #2 suture through a Neviaser portal, and pulled up for better visualization of the superior glenoid (**Figure 9**).

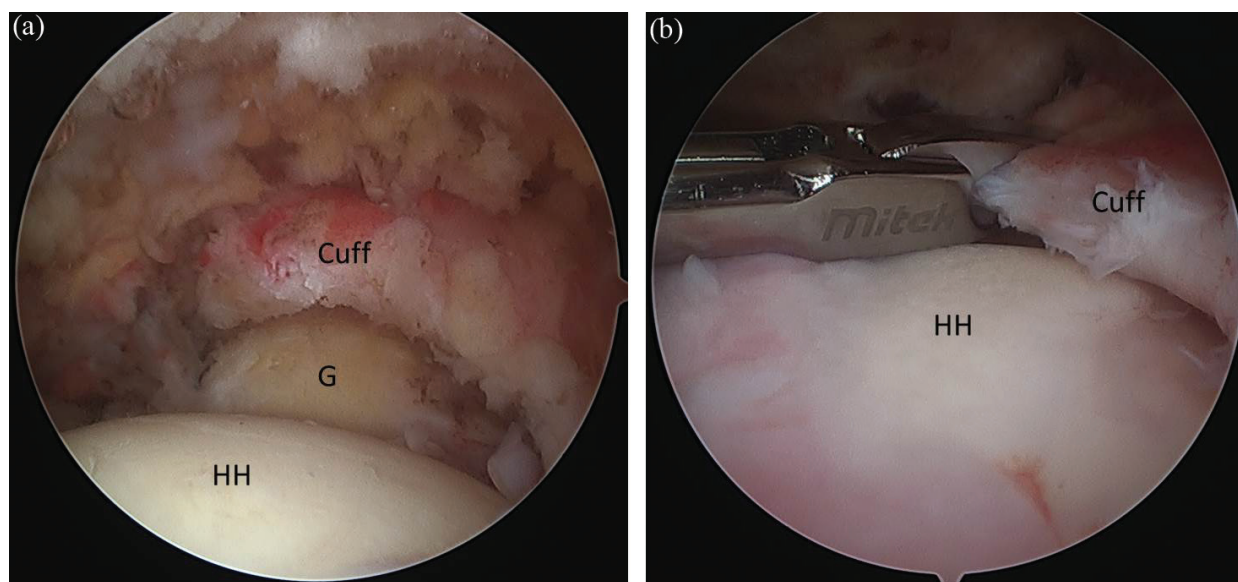


Figure 7. Massive and irreparable rotator cuff tear in the left shoulder of a 70 year old active male (view from posterolateral portal). (A) Note severely retracted massive tear of the superior cuff (SS and IS), with relatively normal articular cartilage both on the glenoid and the humeral head. (B) Even after extensive releases, the tendon stump is not adequately mobile for primary repair (HH—humeral head; G—glenoid).

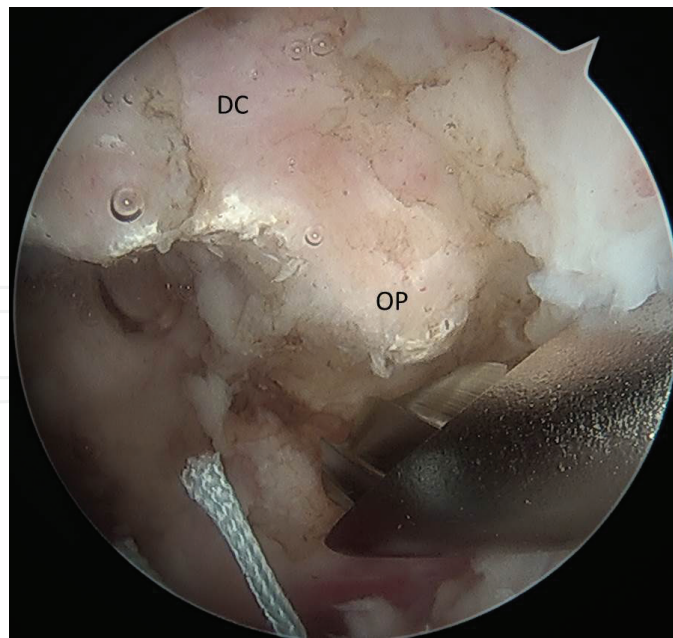


Figure 8. An inferior osteophyte (OP) is being resected off the distal clavicle (DC), to avoid impingement and abrasion of the graft postoperatively.

7.3. Bony preparation, anchor placements

Any residual soft tissue on the superior glenoid neck and greater tuberosity is removed using a motorized shaver and/or electrocautery wand. To maximize healing potential, the superior glenoid neck and greater tuberosity are burred down to bleeding bone.

Medial anchors are placed on the superior glenoid, approximately 2–4 mm medial to the rim, taking care to ensure good bone purchase and avoid intraarticular penetration. Anchors are placed as far anterior and posterior as possible to provide adequate spread and coverage for

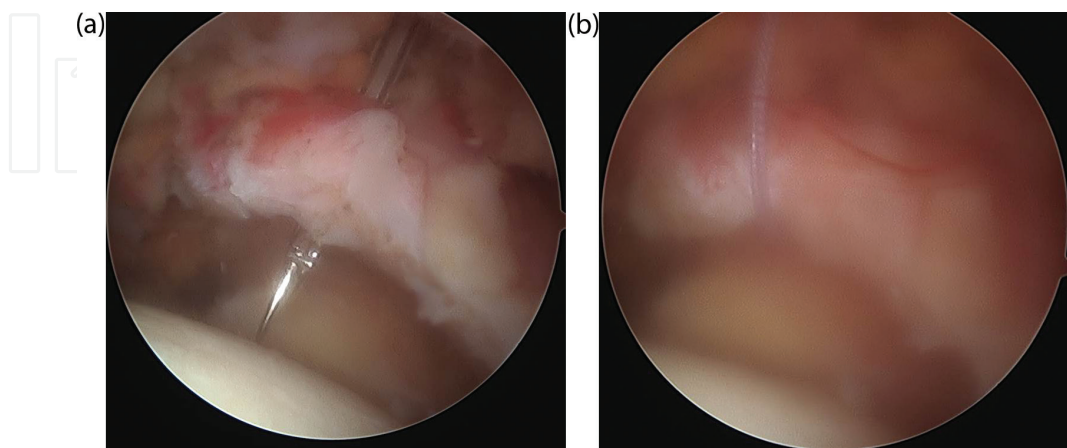


Figure 9. (A) A penetrating suture passer is inserted through the Neviaser portal and is used to pass a tagging suture through the rotator cuff tendon stump. (B) The rotator cuff can then be pulled up, to allow better visualization of and instrumentation on the glenoid neck.

the medial graft fixation on the glenoid. Typically two anchors, each double loaded with a #2 braided suture, are placed, in the region between the 10 and 2 o'clock positions (**Figure 10A and B**), but a third anchor may need to be added for very large defects (**Figure 10C**). Appropriate trajectory for anchor placement should be confirmed prior to drilling, and can typically be achieved from the anterior, posterior and Neviaser portals.

On the humeral head, graft fixation is accomplished using a double row transosseous equivalent technique. Prior to graft passage, medial row greater tuberosity anchors placed, just lateral to the articular margin (**Figure 11**). We prefer to use anchors preloaded with #2 suture-tape, non-sliding. As on the glenoid, two anchors are typically used, but a third one may be needed in large shoulders with large defects.

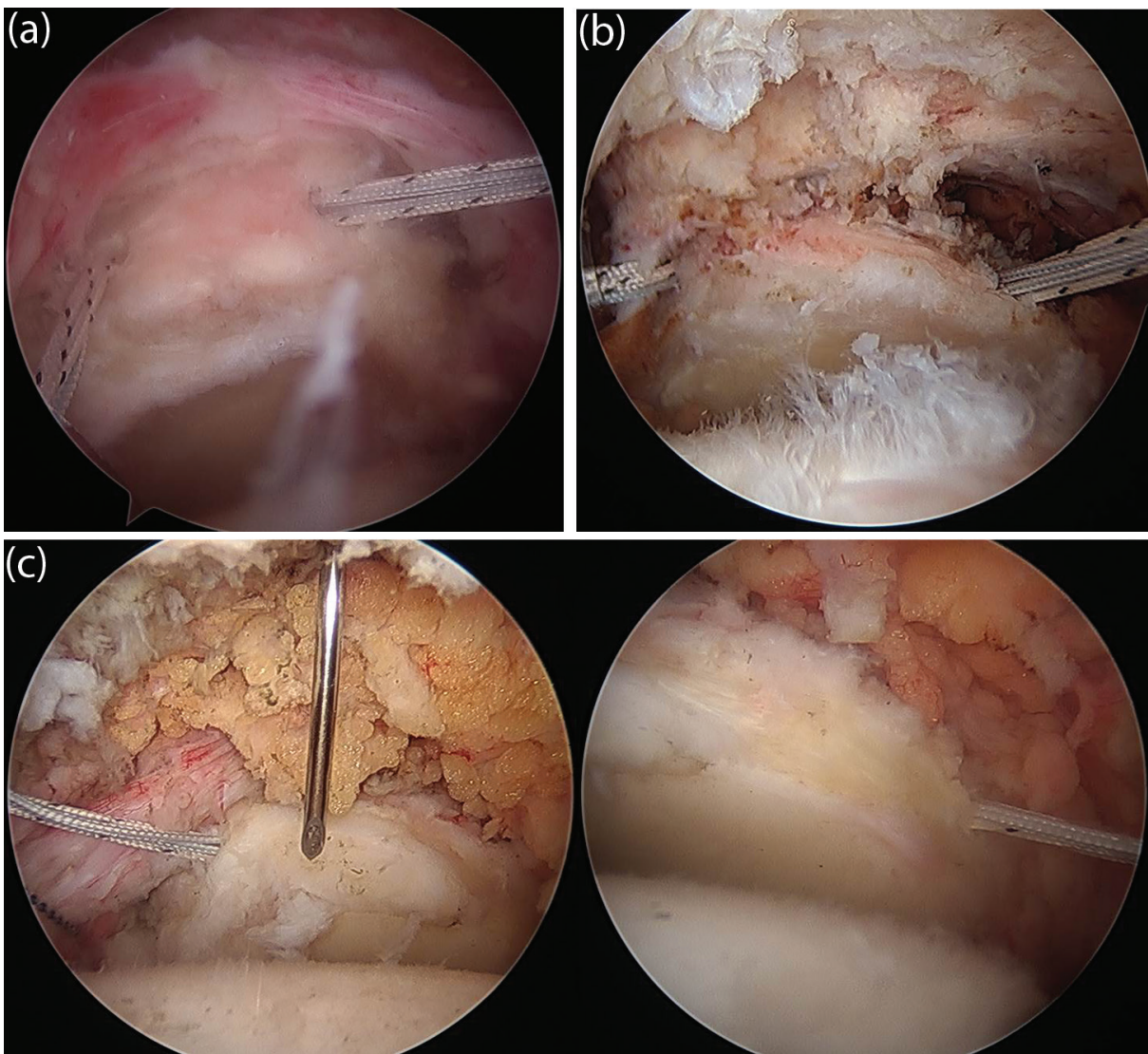


Figure 10. Glenoid anchors. Each one is double-loaded with a #2 braided suture. Note the anchor position approximately 2–4 mm medial to the rim, and the trajectory of insertion (away from the articular cartilage). The spread between the anchors can be narrow (A) for smaller defects, or wide (B) for larger ones. Sometimes three anchors may need to be placed (C), for massive tears involving both the SS and IS. In this case, a Neviaser portal helps with proper trajectory for the middle anchor, as shown by the spinal needle.

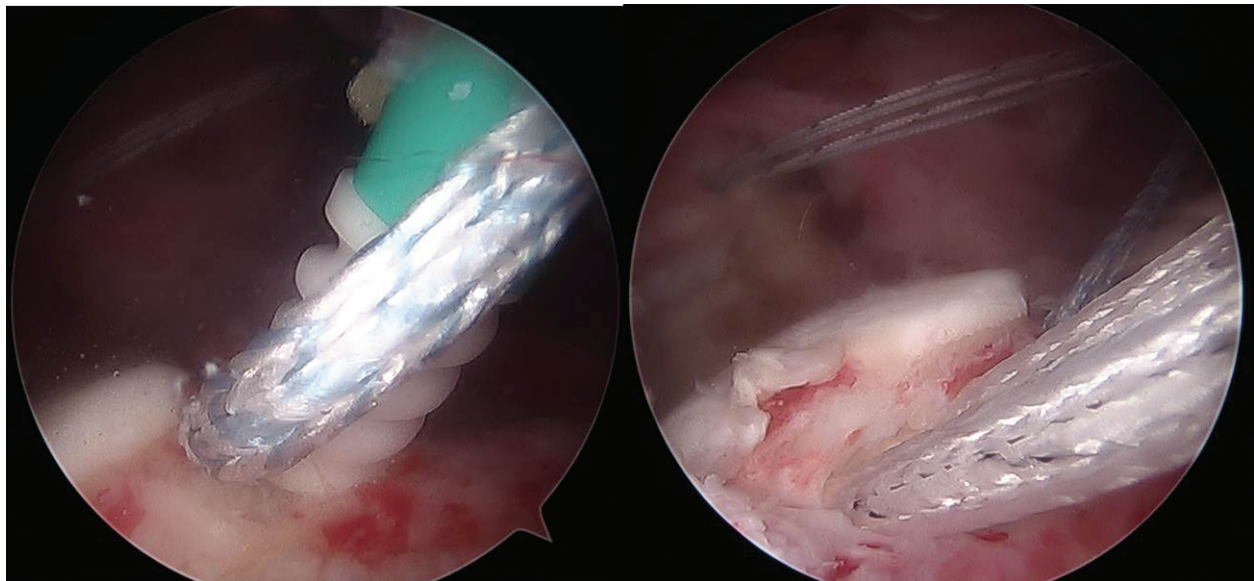


Figure 11. Medial row greater tuberosity (GT) anchors are inserted. The anterior anchor is placed just posterior to the bicipital groove, and the posterior anchor is at the posterior-most extent of the exposed tuberosity. Both are pre-loaded with a suture-tape, and placed adjacent to the articular margin of the humeral head. Note how the surface of the GT has been decorticated down to bleeding bone.

7.4. Graft sizing and preparation

Once all the anchors are placed, distances between them are measured. First the anterior-posterior distance is measured for the glenoid anchors and tuberosity anchors. Then the medial-lateral distance is measured between the glenoid and tuberosity anchors, obtaining one measurement anteriorly, and one posteriorly. A calibrated probe is used to make these measurements (**Figure 12**). In our opinion, in order to obtain the graft size that will provide appropriate stabilizing affect without overtightening the glenohumeral articulation, the shoulder should be positioned in neutral rotation and approximately 20–30° of abduction for the measurement, and during subsequent graft fixation.

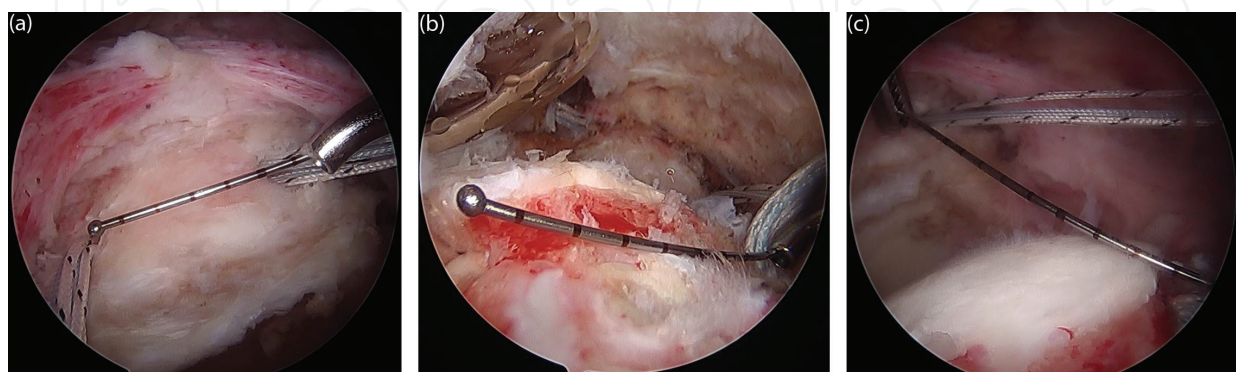


Figure 12. Measuring distances between the anchors using a calibrated probe. (A) Distance between the glenoid anchors. (B) Distance between the medial GT anchors. (C) Distance between the glenoid and GT anchors (posterior, viewing from the anterolateral portal).

Next the graft is prepared. We use an acellular human dermal graft (Arthroflex by Arthrex, Inc., Naples, FL), but an autograft, such as tensor fascia lata, may also be harvested and used. Whichever graft is used, it is now sized and prepared on the back table. The graft is cut to allow a 5 mm margin medially, anteriorly and posteriorly and a 10 mm margin laterally. The dimensions of the anchor configuration are then carefully marked on the graft using a marking pen (**Figure 13**).

At this point, all the sutures must be brought out through one of the subacromial portals in preparation for graft passage. We prefer to view from the posterior or posterolateral portal, and use the anterolateral portal for graft passage. Sometimes this portal must be slightly increased in size, and a flexible cannula, which can be cut along one of its sides (such as the Arthrex Passport) can be helpful.

The graft is brought close to the shoulder, carefully supported on a sterile Mayo stand. The sutures from the glenoid anchors are passed through the medial edge of the graft. Simple configuration can be used, but we prefer to place each set of sutures in a criss-crossing mattress configuration (one vertically and one horizontally), creating a Mason-Allen type configuration. One limb from each suture set is tied to a limb from another suture set (off a different color), and the knot tails are cut. This leaves two suture limbs (one of each color) on the anterior-medial and posterior-medial edges of the graft, which, when tensioned, create a pulley effect on the graft, allowing it to be drawn into the joint (**Figures 14 and 15**).

At this time it is possible to either place the tuberosity medial row sutures through the graft, or instead place a suture loop (such as Arthrex Fiberlink) which would aid with the passage of those sutures later. The advantage of the latter approach is minimizing suture traffic in the lateral subacromial portal, and avoiding suture entanglement. We prefer this technique (**Figure 14**), and temporarily park the medial row tuberosity sutures in the anterior and posterior portals, while the graft is being passed.

7.5. Graft passage

The suture pulley system previously created on the medial side of the graft with the glenoid sutures is now tensioned. The graft may need to be partially folded to allow it to pass through the cannula, or the cannula may be removed (if it was pre-cut). Also, a blunt tissue grasper can be used to pinch the graft medially to ease the delivery and transport of the graft through the cannula. The graft is visualized entering the joint, and moving medially until it sits flush on the superior glenoid neck, covering the rim (**Figure 16A and B**). It may be necessary to help unfold the anterior and posterior edges of the graft once its fully inside, in case they get folded in.

7.6. Graft fixation

The sutures from the glenoid anchors are then tied arthroscopically to secure the graft to the glenoid neck. The tails of those sutures may be passed up through the remnant of the native cuff, to bring it down to the medial edge of the graft, helping create a biologic seal over this area (**Figure 16C**).

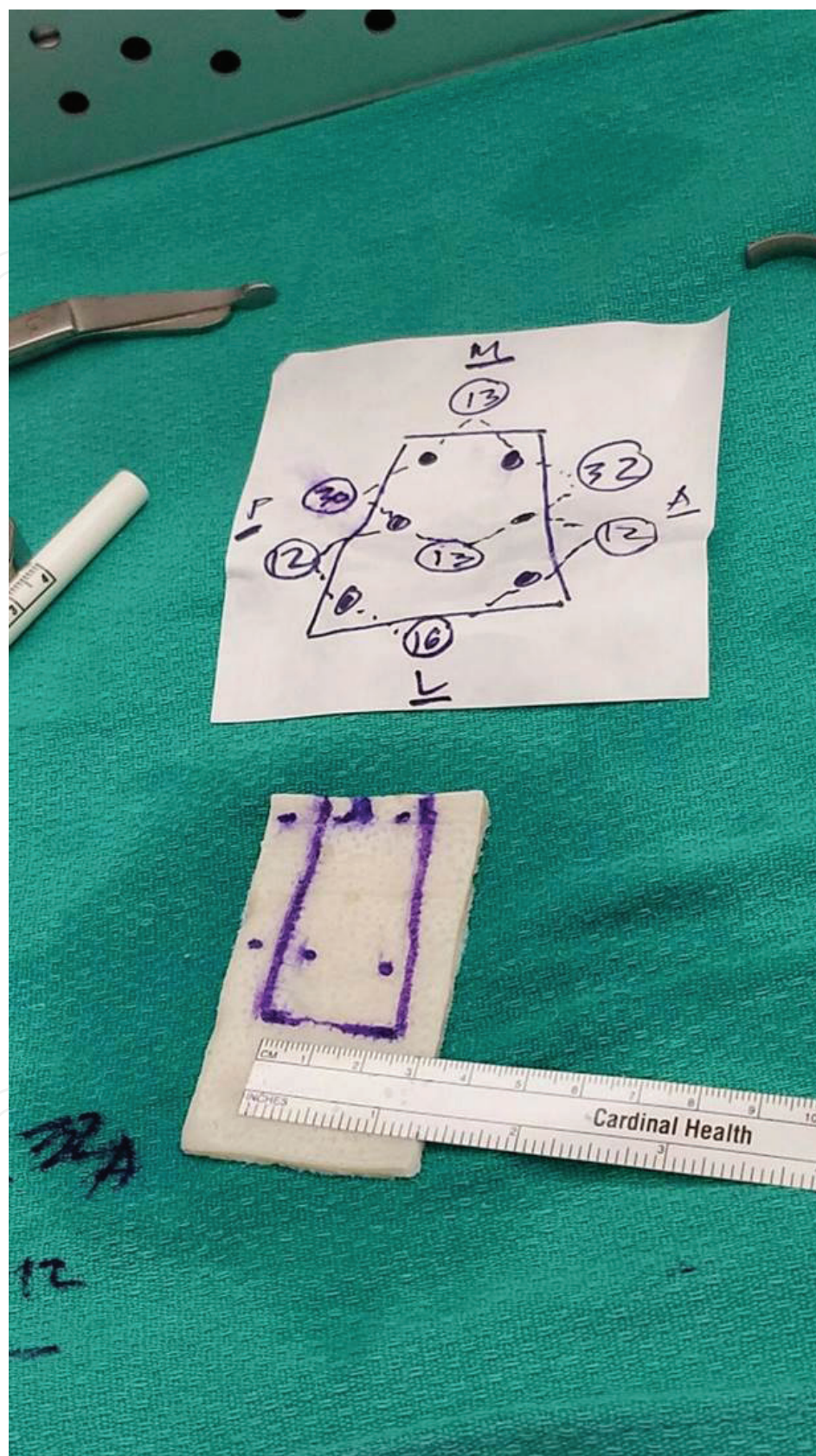


Figure 13. Graft measurement. It is important not to cut the graft too short. 5 mm extra is left on the medial, anterior, and posterior edges, whereas laterally 10 mm extra distance is left to allow coverage over the GT footprint.

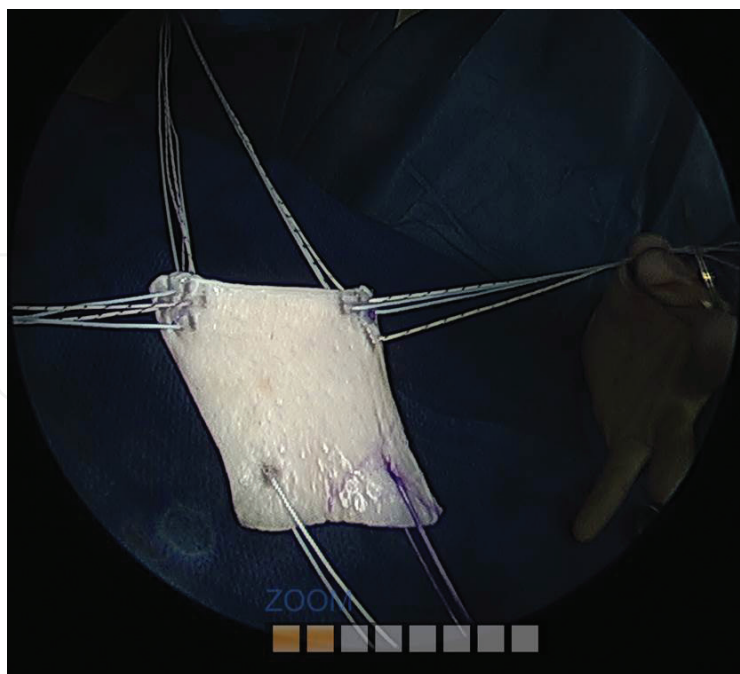


Figure 14. Suture placement into the graft prior to shuttling. Glenoid sutures are placed in a horizontal and vertical mattress configurations, perpendicular to each other. Laterally, we prefer to place a suture-loop (Arthrex Fiberlink), for subsequent shuttling of suture-tapes from the GT medial row anchors.

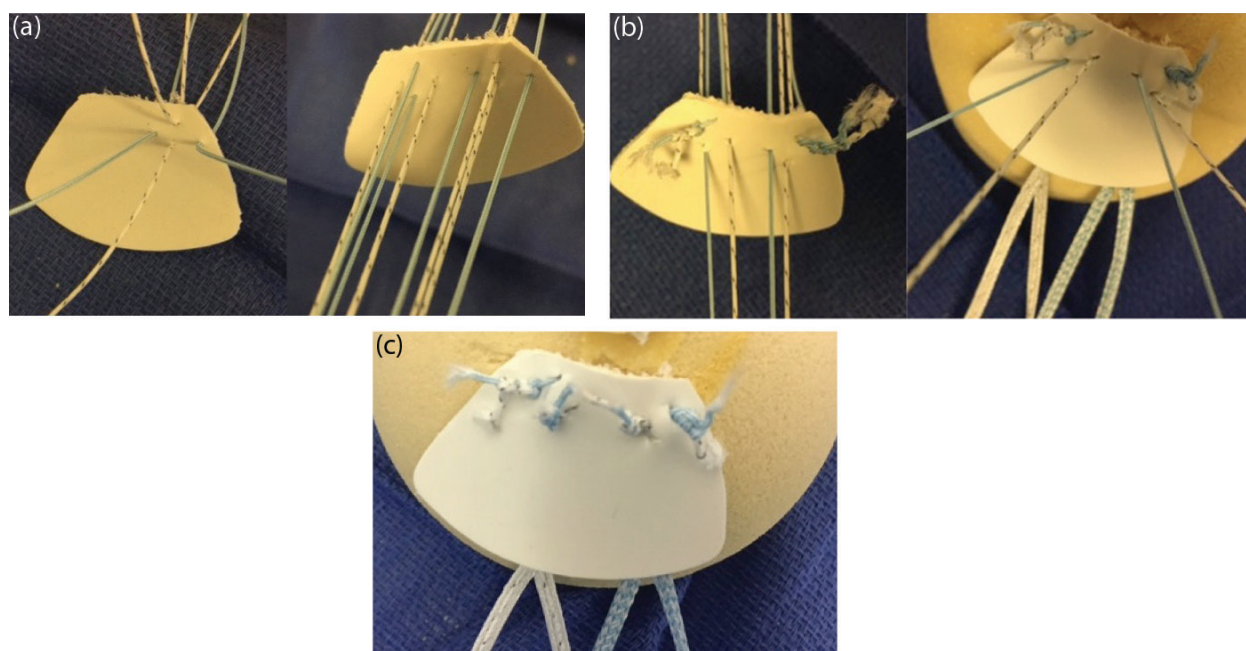


Figure 15. Model demonstration of the step-by-step process of glenoid suture placement and tying. (A) All suture limbs from each anchor are placed in a mattress configuration, perpendicular to each other. (B) One limb from each suture is tied to a limb from the other suture (different color), and this creates a double-pulley system, which helps shuttle the graft to its attachment points on the glenoid. (C) Final construct, with all glenoid sutures tied.

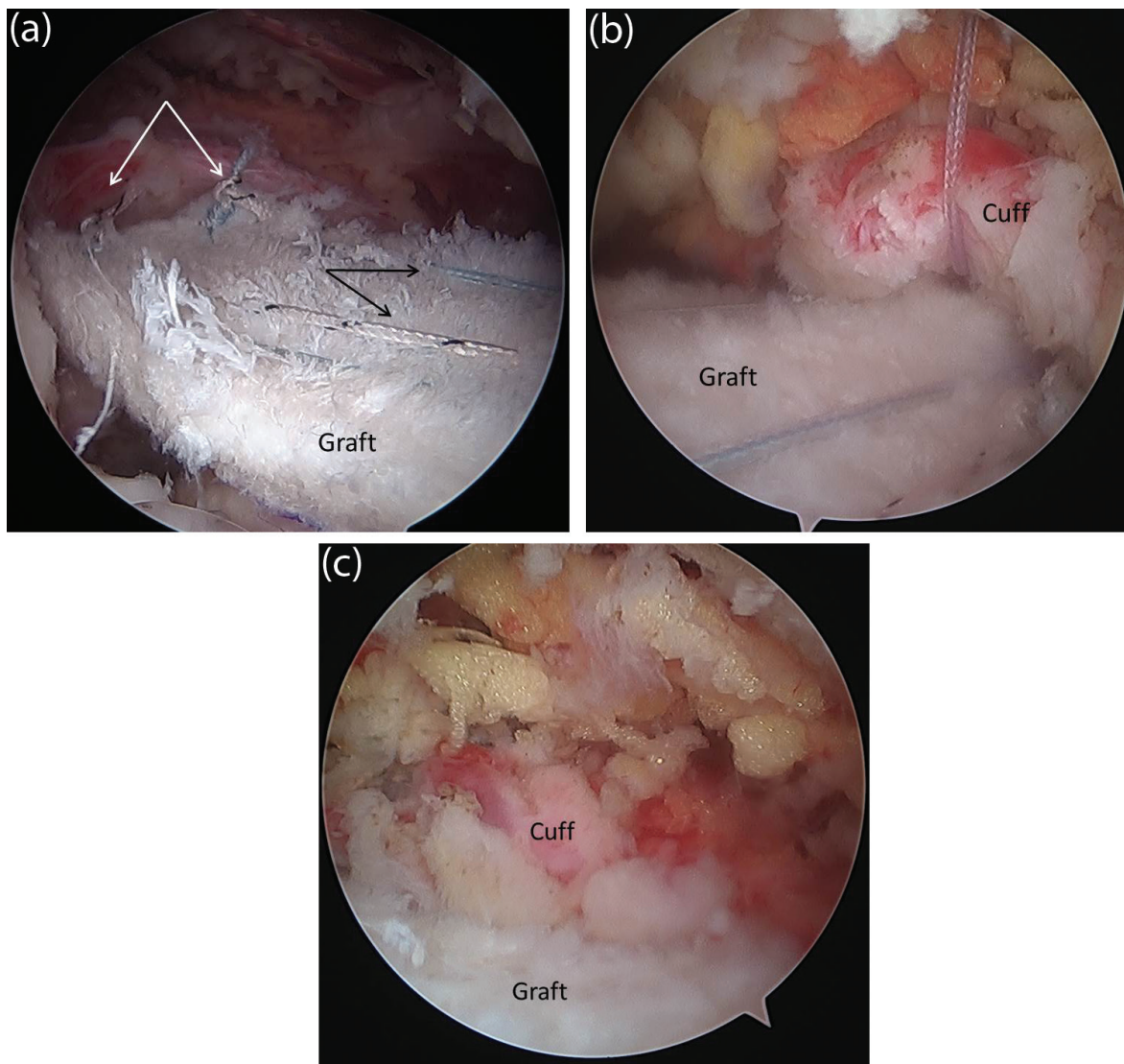


Figure 16. Arthroscopic view of graft fixation to the glenoid. (A) The graft is pulled in using the double-pulley system, which is created by tying one limb of each suture to the other one from the same anchor (white arrows); the remaining limbs act as pulley sutures (black arrows), to cinch the graft onto the superior glenoid rim. (B) Note the ability to pull up the remnant of the superior cuff, with a previously placed free suture, via the Neviaser portal, for improved visualization. (C) After the sutures from the glenoid anchors are tied, securing the graft to the glenoid, the remnant cuff tissue can be tied down to the graft, using those suture tails. This creates a nice biologic seal over the medial part of the SCR construct.

Then the tuberosity medial row sutures are passed through the graft using the previously pre-loaded suture-loop, if they haven't been already placed outside the shoulder. Both limbs of the sutures from the medial GT anchors are passed through the graft, from inferior to superior, one at the anterior and one at the posterior pre-determined spots (**Figure 17A**). Finally, these suture-tapes are brought over the lateral-most extent of the graft in a criss-cross fashion, and secured just past the lateral margin of the tuberosity with knotless anchors (**Figure 17B–D**). Prior to setting final tension and fixating the graft laterally, proper shoulder position of neutral rotation and slight abduction (20–30°) needs to be ensured.

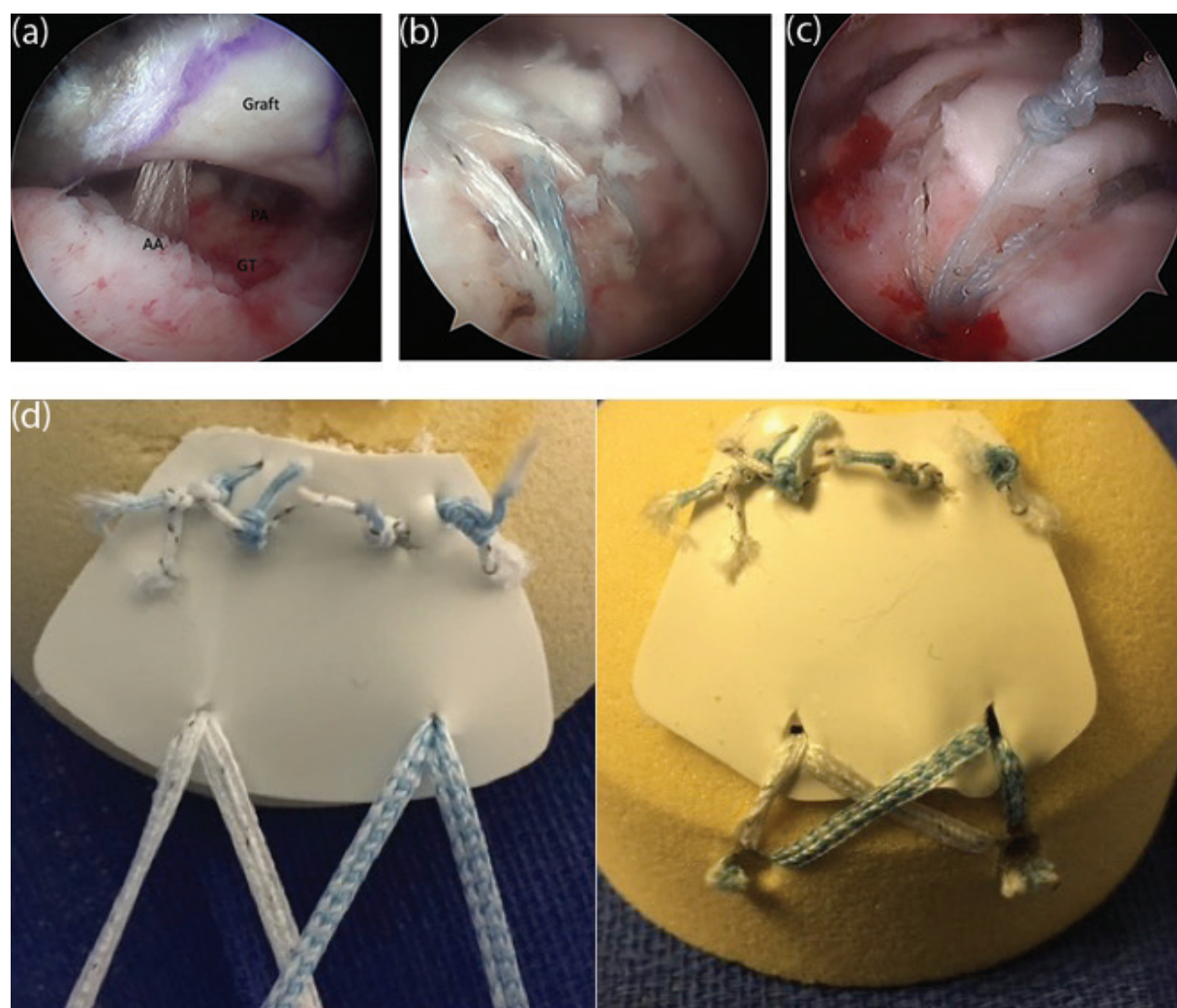


Figure 17. Graft fixation to the humeral head. (A) Suture-tapes from the medial row greater tuberosity anchors are passed up through the graft, using the previously placed suture-loop (left shoulder, view from the anterolateral portal; AA— anterior anchor, PA—posterior anchor, GT—greater tuberosity); (B) Suture tapes are criss-crossed and secured just past the lateral margin of the tuberosity with knotless anchors, providing excellent compression of the graft over the tuberosity footprint. (C) If a small “dog-ear” is noted after lateral graft fixation, a suture preloaded into the lateral-row anchor can be used to tie it down. (D) Model demonstration of graft fixation to the humeral head.

7.7. Anterior and posterior convergence

Once the graft is secured medially and laterally, side-to-side margin convergence sutures are placed to secure the graft to the intact cuff (**Figure 18A and B**). Pre-placed sutures are helpful for this, as discussed above. Typically two side-to-side sutures are used posteriorly, to connect the graft to the intact part of the infraspinatus or to the teres minor. Anteriorly, if the fixation is to the intact remaining supraspinatus, two sutures may be used as well (**Figure 18C**); however, if there is no supraspinatus left, and fixation is to the upper border of the subscapularis, no more than one suture should be used, as laterally as possible, to avoid over-constricting the rotator interval. If the distance between the anterior edge of the graft and the upper border of the subscapularis is too great, no margin convergence sutures are placed here.

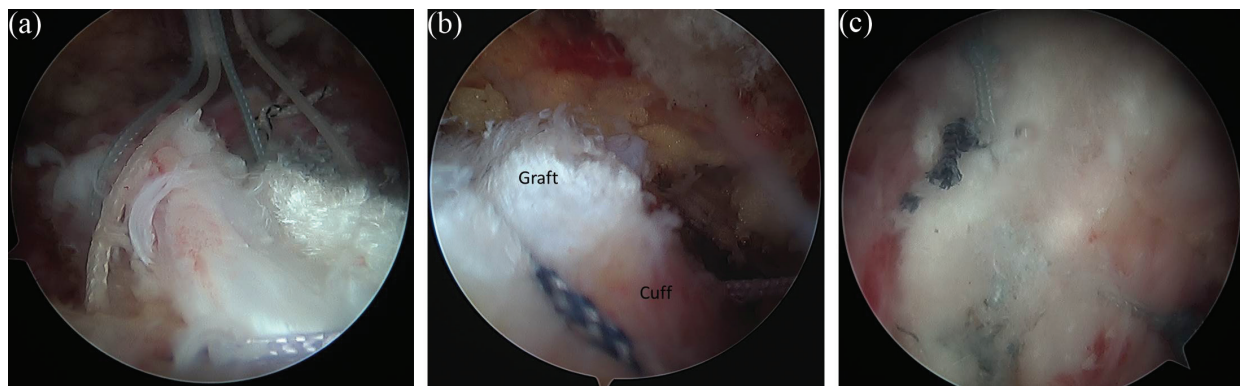


Figure 18. Side-to-side repair to the intact cuff and completion of the SCR. (A) Sutures are passed through the graft and adjacent intact cuff. (B) Sutures are then tied, providing close approximation between the graft and native tissue. (C) Superior view from the Neviaser portal, showing a completed SCR, with excellent coverage of the joint by the graft and native cuff, repaired to the graft.

The shoulder is then taken through a full range of motion to ensure no signs of impingement. And residual spurs on the acromion, or osteophytes off the inferior distal clavicle should be resected (**Figure 8**).

7.8. Postoperative protocol

We follow the same protocol for our SCR cases as for our large rotator cuff repair cases. A shoulder immobilizer sling is worn for 6 weeks, with or without an abduction pillow. Passive range of motion exercises are started at 4–6 weeks postoperatively, active-assisted motion is allowed at 6–8 weeks, and full active motion is allowed after 8 weeks. Strengthening progresses after 12 weeks, and return to activities which require overhead lifting is allowed no earlier than 16 weeks. Typical full return to activities is allowed 6 months postoperatively.

8. Outcomes

Published reports of clinical outcomes following superior capsular reconstruction thus far have been limited to one study, but more such studies are currently either in data collection or already in preparations to report outcomes. In 2013, Mihata et al. reported a case series of 24 shoulders (23 consecutive patients), treated with SCR using fascia lata autograft, with minimum 2-year follow-up [2]. At an average follow-up of 34 months (24–51 months), mean active elevation increased from 84 to 148° and mean external rotation increased from 26 to 40°. All clinical outcomes scores improved significantly, with American Shoulder and Elbow Surgeons score (ASES) score going up from an average of 23.5 to 92.9. Furthermore, imaging showed acromiohumeral distance increased from 4.6 to 8.7 mm, on average. No procedure-related complications were reported [2].

In the United States, most surgeons prefer to use a dermal allograft (Arthrex Arthroflex), which is a thick (3 mm) and durable patch, which requires minimal preparation time and is relatively easy to handle. Several technical reports using this graft have been published, including those

by Hirahara and Adams, Petri et al., Tokish and Beicker, and Burkhart et al. [36–39], but clinical data on the outcomes of this approach is lacking in the published literature. However, personal communication with a number of surgeons currently performing SCR using the dermal allograft patch produced reports of high patient satisfaction rates, excellent improvement in function and pain levels in the short term, and low risk of complications. One of our personal communications has been with a surgeon who now has data on 20 SCR procedures, with a minimum follow-up of 3 months and up to 1.5 years, and reports that Visual Analogue Scale (VAS) scores decreased on average from 6–9 to 0–3 range, while ASES scores went up from the 20–30 range to the 70–90 range. No complications were reported in this patient group (personal communication with Dr. Kevin Kaplan, Jacksonville Orthopedic Institute, Jacksonville, FL).

9. Future direction and conclusion

Large irreparable rotator cuff tears in younger and active patients continue to pose a significant clinical challenge to orthopedic surgeons. Arthroplasty treatment option with a reverse shoulder replacement is not ideal in this patient population. Mihata et al. [33] have shown in biomechanical cadaveric studies that a graft reconstruction can restore superior glenohumeral translation when the graft is attached to the glenoid medially and humeral head laterally. However, many technical aspects of this procedure have not been well studied, such as ideal suture and anchor configuration medially or laterally, ideal graft tissue (allograft versus autograft), ideal graft thickness, or ideal tensioning technique.

In the immediate future, we will need larger clinical studies with short, medium, and long-term outcome data demonstrating the effectiveness of superior capsular reconstruction. Radiographic follow-up studies are needed to document graft incorporation or deterioration after this surgery, as well as to monitor the acromiohumeral distance in this patient population. Clinical indications and contraindications, as well as the ideal patient population, for this procedure need be better defined.

Superior capsular reconstruction is a novel technique that may provide a potentially promising solution to a tough problem in the shoulder region. The procedure should be considered for active and physiologically young patients with high functional demand on their upper extremity, and an irreparable rotator cuff tear, and should be performed by surgeons experienced in treating shoulder pathology. More clinical studies are needed before we can advocate widespread use of this procedure in general orthopedic practice.

Author details

Alexander Golant^{1*}, Daiji Kano², Tony Quach¹, Kevin Jiang¹ and Jeffrey E. Rosen¹

*Address all correspondence to: alg9067@nyp.org

¹ Department of Orthopedics and Rehabilitation, NewYork-Presbyterian Queens, New York City, USA

² Department of Surgery, NewYork-Presbyterian Queens, New York City, USA

References

- [1] Sambandam SN. Rotator cuff tears: An evidence based approach. *World J Orthop.* 2015;**6**(11):902-918. DOI: 10.5312/wjo.v6.i11.902
- [2] Mihata T, Lee TQ, Watanabe C, Fukunishi K, Ohue M, Tsujimura T, Kinoshita M. Clinical results of arthroscopic superior capsule reconstruction for irreparable rotator cuff tears. *Arthroscopy.* 2013;**29**(3):459-470. DOI: 10.1016/j.arthro.2012.10.022
- [3] Tashjian RZ. Epidemiology, natural history, and indications for treatment of rotator cuff tears. *Clinics in Sports Medicine.* 2012;**31**(4):589-604. DOI: 10.1016/j.csm.2012.07.001
- [4] Yadav H, Nho S, Romeo A, Macgillivray JD. Rotator cuff tears: Pathology and repair. *Knee Surgery, Sports Traumatology, Arthroscopy.* 2009;**17**(4):409-421. DOI: 10.1007/s00167-008-0686-8
- [5] Nimura A, Kato A, Yamaguchi K, Mochizuki T, Okawa A, Sugaya H, Akita K. The superior capsule of the shoulder joint complements the insertion of the rotator cuff. *Journal of Shoulder and Elbow Surgery.* 2012;**21**(7):867-872. DOI: 10.1016/j.jse.2011.04.034
- [6] Greene WB, Netter FH. *Netter's Orthopaedics.* Philadelphia, PA; Saunders Elsevier, 2006
- [7] Frank RM, Taylor D, Verma NN, Romeo AA, Mologne TS, Provencher MT. The rotator interval of the shoulder: Implications in the treatment of shoulder instability. *Orthopaedic Journal of Sports Medicine.* 2015;**3**(12):2325967115621494. DOI: 10.1177/2325967115621494
- [8] Jost B, Koch PP, Gerber C. Anatomy and functional aspects of the rotator interval. *Journal of Shoulder and Elbow Surgery.* 2000;**9**(4):336-341
- [9] Burkhart SS, Esch JC, Jolson RS. The rotator crescent and rotator cable: An anatomic description of the shoulder's "suspension bridge". *Arthroscopy.* 1993;**9**(6):611-616
- [10] Ishihara Y, Mihata T, Tamboli M, Nguyen L, Park KJ, McGarry MH, Takai S, Lee TQ. Role of the superior shoulder capsule in passive stability of the glenohumeral joint. *Journal of Shoulder and Elbow Surgery.* 2014;**23**(5):642-648. DOI: 10.1016/j.jse.2013.09.025
- [11] Bouaicha S, Slankamenac K, Moor BK, Tok S, Andreisek G, Finkenstaedt T. Cross-sectional area of the rotator cuff muscles in MRI – Is there evidence for a biomechanical balanced shoulder?. *PLoS One.* 2016;**11**(6):e0157946. DOI: 10.1371/journal.pone.0157946
- [12] Eajazi A, Kussman S, LeBedis C, Guermazi A, Koppel A, Jawa A, Murakami AM. Rotator cuff tear arthropathy: Pathophysiology, imaging characteristics, and treatment options. *AJR Am J Roentgenol.* 2015;**205**(5):W502-W511. DOI: 10.2214/AJR.14.13815
- [13] Gumina S, Carbone S, Campagna V, Candela V, Sacchetti FM, Giannicola G. The impact of aging on rotator cuff tear size. *Musculoskeletal Surgery.* 2013;**97**(Suppl 1):69-72. DOI: 10.1007/s12306-013-0263-2
- [14] Abboud JA, Kim JS. The effect of hypercholesterolemia on rotator cuff disease. *Clinical Orthopaedics and Related Research.* 2010;**468**(6):1493-1497. DOI: 10.1007/s11999-009-1151-9

- [15] Thankam FG, Dilisio MF, Agrawal DK. Immunobiological factors aggravating the fatty infiltration on tendons and muscles in rotator cuff lesions. *Molecular and Cellular Biochemistry*. 2016;**417**(1-2):17-33. DOI: 10.1007/s11010-016-2710-5
- [16] Neer CS. Anterior acromioplasty for the chronic impingement syndrome in the shoulder: A preliminary report. *J Bone Joint Surg Am. American Volume*. 1972;**54**(1):41-50
- [17] Bigliani LU, Ticker JB, Flatow EL, Soslowsky LJ, Mow VC. The relationship of acromial architecture to rotator cuff disease. *Clinics in Sports Medicine*. 1991;**10**(4):823-838
- [18] Song L, Miao L, Zhang P, Wang WL. Does concomitant acromioplasty facilitate arthroscopic repair of full-thickness rotator cuff tears? A meta-analysis with trial sequential analysis of randomized controlled trials. *SpringerPlus*. 2016;**5**(1):685. DOI: 10.1186/s40064-016-2311-5
- [19] Kibler WB. Scapular involvement in impingement: Signs and symptoms. *Instructional Course Lectures*. 2006;**55**:35-43
- [20] Jones CK, Savoie FH 3rd. Arthroscopic repair of large and massive rotator cuff tears. *Arthroscopy*. 2003;**19**(6):564-571
- [21] Burkhart SS, Danaceau SM, Pearce CE Jr. Arthroscopic rotator cuff repair: Analysis of results by tear size and by repair technique-margin convergence versus direct tendon-to-bone repair. *Arthroscopy*. 2001;**17**(9):905-912
- [22] Murray TF Jr, Lajtai G, Mileski RM, Snyder SJ. Arthroscopic repair of medium to large full-thickness rotator cuff tears: Outcome at 2- to 6-year follow-up. *Journal of Shoulder and Elbow Surgery*. 2002;**11**(1):19-24
- [23] Wolf EM, Pennington WT, Agrawal V. Arthroscopic rotator cuff repair: 4- to 10-year results. *Arthroscopy*. 2004;**20**(1):5-12
- [24] McElvany MD, McGoldrick E, Gee AO, Neradilek MB, Matsen FA 3rd. Rotator cuff repair: Published evidence on factors associated with repair integrity and clinical outcome. *The American Journal of Sports Medicine*. 2015;**43**(2):491-500. DOI: 10.1177/0363546514529644
- [25] Goutallier D, Postel JM, Bernageau J, Lavau L, Voisin MC. Fatty muscle degeneration in cuff ruptures. Pre- and postoperative evaluation by CT scan. *Clinical Orthopaedics and Related Research*. 1994;**304**:78-83
- [26] Park JS, Park HJ, Kim SH, Oh JH. Prognostic factors affecting rotator cuff healing after arthroscopic repair in small to medium-sized tears. *The American Journal of Sports Medicine*. 2015;**43**(10):2386-2392. DOI: 10.1177/0363546515594449
- [27] Burkhart SS, Nottage WM, Ogilvie-Harris DJ, Kohn HS, Pachelli A. Partial repair of irreparable rotator cuff tears. *Arthroscopy*. 1994;**10**(4):363-370
- [28] Shon MS, Koh KH, Lim TK, Kim WJ, Kim KC, Yoo JC. Arthroscopic partial repair of irreparable rotator cuff tears: Preoperative factors associated with outcome deterioration over 2 years. *The American Journal of Sports Medicine*. 2015;**43**(8):1965-1975. DOI: 10.1177/0363546515585122

- [29] Lewington MR, Ferguson DP, Smith TD, Burks R, Coady C, Wong IH. Graft utilization in the bridging reconstruction of irreparable rotator cuff tears: A systematic review. *Am J Sports Med*. DOI: 10.1177/0363546517694355. [Epub ahead of print]
- [30] Gillespie RJ, Knapik DM, Akkus O. Biologic and synthetic grafts in the reconstruction of large to massive rotator cuff tears. *The Journal of the American Academy of Orthopaedic Surgeons*. 2016;**24**(12):823-828
- [31] Omid R, Lee B. Tendon transfers for irreparable rotator cuff tears. *The Journal of the American Academy of Orthopaedic Surgeons*. 2013;**21**(8):492-501. DOI: 10.5435/JAAOS-21-08-492
- [32] Ecklund KJ, Lee TQ, Tibone J, Gupta R. Rotator cuff tear arthropathy. *The Journal of the American Academy of Orthopaedic Surgeons*. 2007;**15**(6):340-349
- [33] Mihata T, McGarry MH, Pirolo JM, Kinoshita M, Lee TQ. Superior capsule reconstruction to restore superior stability in irreparable rotator cuff tears: A biomechanical cadaveric study. *The American Journal of Sports Medicine*. 2012;**40**(10):2248-2255
- [34] Mihata T, McGarry MH, Kahn T, Goldberg I, Neo M, Lee TQ. Biomechanical effect of thickness and tension of fascia lata graft on glenohumeral stability for superior capsule reconstruction in irreparable supraspinatus tears. *Arthroscopy*. 2016;**32**(3):418-426. DOI: 10.1016/j.arthro.2015.08.024
- [35] Gupta AK, Hug K, Berkoff DJ, Boggess BR, Gavigan M, Malley PC, Toth AP. Dermal tissue allograft for the repair of massive irreparable rotator cuff tears. *The American Journal of Sports Medicine*. 2012;**40**(1):141-147. DOI: 10.1177/0363546511422795
- [36] Hirahara AM, Adams CR. Arthroscopic superior capsular reconstruction for treatment of massive irreparable rotator cuff tears. *Arthroscopy Techniques*. 2015;**4**(6):e637-e641. DOI: 10.1016/j.eats.2015.07.006
- [37] Petri M, Greenspoon JA, Millett PJ. Arthroscopic superior capsule reconstruction for irreparable rotator cuff tears. *Arthroscopy Techniques*. 2015;**4**(6):e751-e755. DOI: 10.1016/j.eats.2015.07.018
- [38] Tokish JM, Beicker C. Superior capsule reconstruction technique using an acellular dermal allograft. *Arthroscopy Techniques*. 2015;**4**(6):e833-e839. DOI: 10.1016/j.eats.2015.08.005
- [39] Burkhart SS, Adams CR, Denard PJ, Brady PC, Hartzler RU. The arthroscopic superior capsular reconstruction for massive irreparable rotator cuff repair. *Arthroscopy Techniques*. 2016;**5**(6):e1407-e1418. DOI: 10.1016/j.eats.2016.08.024
- [40] Mihata T, McGarry MH, Kahn T, Goldberg I, Neo M, Lee TQ. Biomechanical effects of acromioplasty on superior capsule reconstruction for irreparable supraspinatus tendon tears. *The American Journal of Sports Medicine*. 2016;**44**(1):191-197. DOI: 10.1177/0363546515608652

