

We are IntechOpen, the world's leading publisher of Open Access books Built by scientists, for scientists

6,900

Open access books available

186,000

International authors and editors

200M

Downloads

Our authors are among the

154

Countries delivered to

TOP 1%

most cited scientists

12.2%

Contributors from top 500 universities



WEB OF SCIENCE™

Selection of our books indexed in the Book Citation Index
in Web of Science™ Core Collection (BKCI)

Interested in publishing with us?
Contact book.department@intechopen.com

Numbers displayed above are based on latest data collected.
For more information visit www.intechopen.com



An Overview of Hypospadias Surgery

Wenceslao M. Calonge and Gianluca Sapino

Additional information is available at the end of the chapter

<http://dx.doi.org/10.5772/intechopen.69924>

Abstract

Performed by urologists and paediatric surgeons, hypospadias procedures go unnoticed in many classical treatises of plastic surgery. Hypospadias is a very common malformation that occurs in nearly 1 in 250 male births. It consists of an abnormal opening of the urethral meatus at some point of its dorsal aspect. It is associated with an incomplete, semi-circumferential foreskin and in nearly half of the patients it may be accompanied with a curvature of the penile shaft called chordee. Most classifications differentiate between distal, middle and proximal presentations. Different techniques have been proposed for its treatment; some of the most usual ones are briefly revised. Continued improvement in surgical management has made currently practised one-stage repairs possible. We provide an introduction to the current techniques, as well as operative tips and an overview of the most common pitfalls the surgeon must bear in mind when treating this condition.

Keywords: hypospadias, microsurgery, urethra, penoscrotal transposition, child, paediatrics, urology, congenital malformations

1. Introduction and classification

Derived from the Greek prefix *hypo* (under) and *spadon* (gap, cleft), the word hypospadias refers to a congenital condition in which the urethral meatus appears proximal to its usual location at the tip of the penis.

The urethral orifice may lie at any level on the *embryologic* dorsal¹ surface of penis, scrotum or even perineum. The foreskin lacks an inferior portion in a way that the remaining semi-circumferential

¹Note that the embryological dorsal aspect of the urethra is named as *ventral* or *anterior* in many texts. This confusion probably derives from the surgeon's view of an exposed operative field on the table. A defect on the embryological ventral surface of the urethra corresponds to the condition known as epispadias.

tissue resembles of a hood. The glans itself may be slightly flattened. Moreover, many cases of hypospadias may present with a curvature named chordee (from Latin *chorda*, string) between glans and meatus. This chordee is usually produced by an excess of fibrous tissue.

In order to evaluate the location of the urethral meatus, it should be examined under mild retraction of the foreskin and the skin surrounding the orifice. Though there is no total consensus, most urological texts describe the level of the urethral meatus as follows (**Figure 1**):

- Distal or anterior (glandular and coronal)
- Middle (penile)
- Proximal or posterior (penoscrotal, scrotal and perineal).

All observations should include the degree of curvature. This is usually expressed by the angle between the main axis from basis and the main axis from the apex of the glans (**Figure 2**).

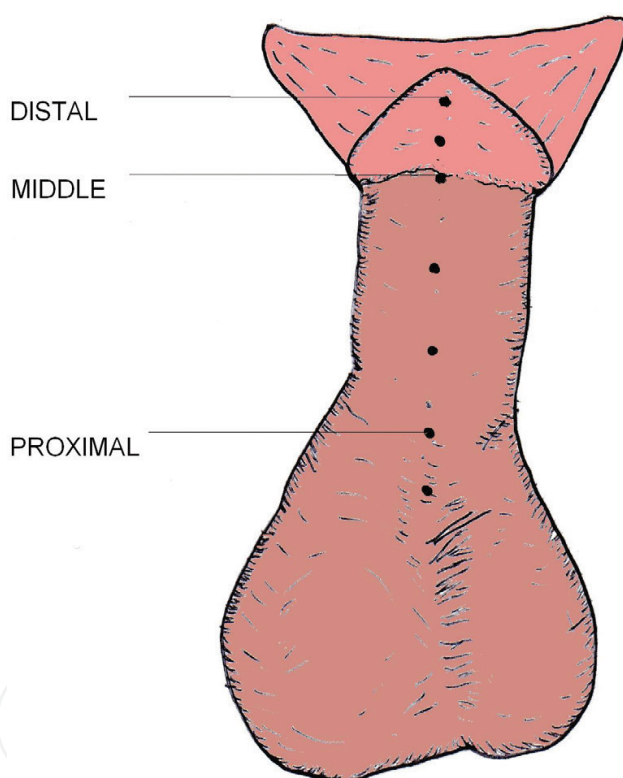


Figure 1. Classification of hypospadias according to level of the urethral meatus.

2. Historical notes

Most historical studies [1–3] refer to Heliodorus and Antyllus, two alexandrine surgeons who proposed total amputation of the penis distal to the orifice. The first description of hypospadias, however, is attributed to Galen (129-ca.199 AD). Several isolated observations and

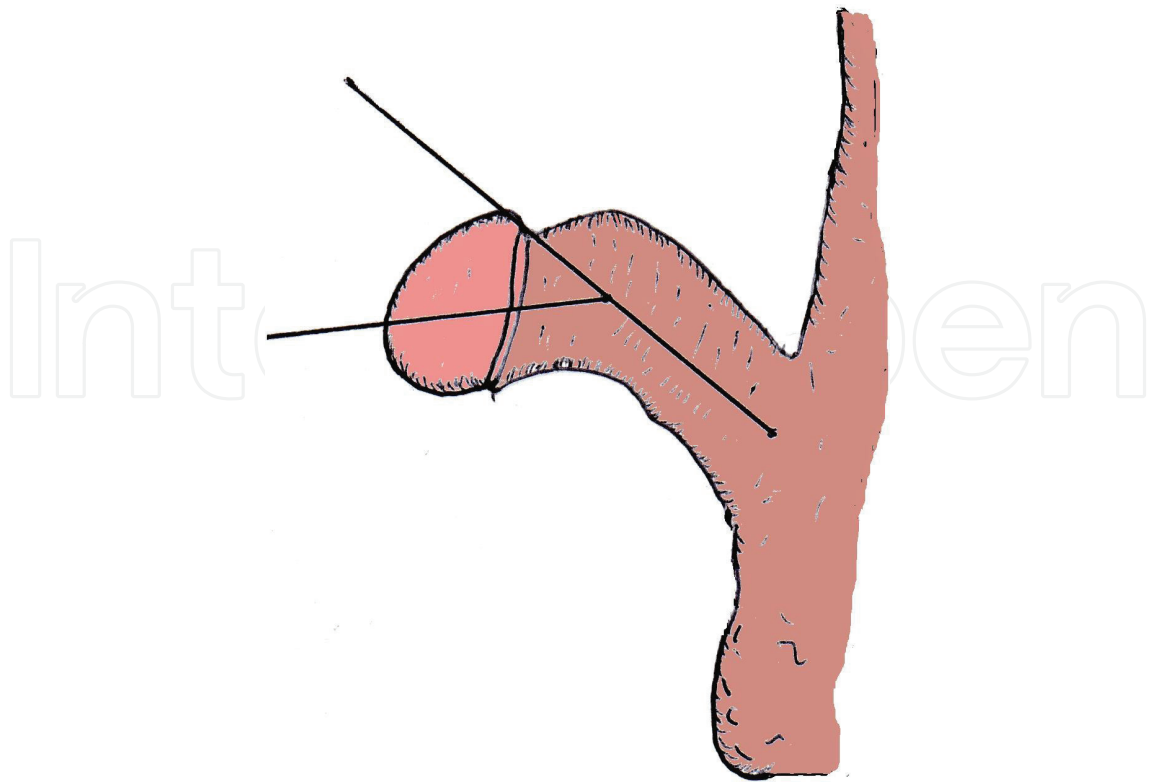


Figure 2. Measurement of the angle of penile curvature.

treatment proposals followed along the next centuries. The Portuguese Amatus Lusitanus (1511–1568) is usually credited as the first to carve a tunnel between the glans and the ectopical meatus. An illustrious patient was King Henry II of France, who presented with a chordee and underwent some kind of procedure in the hands of royal surgeon Jean Fernel. During the eighteenth century, Morgagni compared the condition to the penile groove of turtles and questioned an association between hypospadias and infertility.

The bulk of current techniques derive from conceptual improvements of the nineteenth century. Bouisson proposed a scrotal skin flap to create the inferior wall of the missing urethral segment in 1861. In 1869, Thiersch described tubularised skin grafts as a means to create a neourethra in epispadias (another unrelated urethral malformation). In 1874, Théophile Anger adapted this technique to obtain a successful correction of a penoscrotal hypospadias. In 1880, Duplay described a two-stage repair that included the correction of chordee as the first stage and the urethral reconstruction by means of local flaps from the penile ventral skin as a second stage. Nove-Josserand was the first surgeon to describe free skin grafts to create a neourethra in scrotal hypospadias in 1897.

Former milestones to be cited usually include the works by Matthieu (a flap from proximal skin with parallel sutured lines, 1932), Nesbitt (a technique to treat congenital curvature using fundoplication of the tunica albuginea, 1941), Mustardé (a large flap of perimeatal skin combined with a 'V' incision of the glans, 1965), Duckett [Meatal advancement and glanuloplasty (MAGPI) procedure—1981], Koyanagi (a technique for the more complex

scrotal cases, 1984) and Snodgrass (an incision of the tubularised urethral plate, 1994). A great number of surgeons have contributed to this field in order to achieve an acceptable correction to any kind of hypospadias and any claim for 'a new concept' is difficult to prove.

3. Incidence, aetiology and associated malformations

Hypospadias is a common congenital malformation. A nationwide study from Taiwan [4] for the period from 1997 to 2008 has shown a mean incidence of 3.38 per 1000 live male births. A recent series from Sweden [5] has shown an increase from 4.5 cases per 1000 live male births (1973–1989) to 8 per 1000 live male births (1990–2009).

Fortunately, there is a higher incidence of the less severe variants of the condition. Thus, a Dutch series [6] has shown how 59% of hypospadias are anterior (glanular and coronal), 29% are middle (penile) and 12% are posterior (penoscrotal, scrotal and perineal).

Urethral closing is controlled by androgen receptors that bind to dihydrotestosterone. 5-alpha reductase II catalyses the conversion from testosterone to dihydrotestosterone. Most authors mention a multifactorial aetiology and a putative influence on genes that control androgen metabolism. Endocrine disruptors as anti-androgenic substances, hormones or environmental pollutants are heavily suspected as important factors in the pathogenesis of hypospadias in the prenatal period [7]. It is difficult to extrapolate the findings from animals to human beings, however.

Though some genes have been pointed out as causative factors of hypospadias, not many of them have been examined to the point of allowing unequivocal conclusions. There are contradicting studies about the effects of particular drugs on humans, such as the anti-epileptic valproate or the anti-histaminic loratadine [8].

Hypospadias is more frequent among children of men who themselves have had hypospadias. The risk also rises for the brothers of children with hypospadias [9, 10].

Undescended testis in variable degrees and inguinal hernia are the most common anomalies seen in boys with hypospadias. The more proximal the hypospadias, the more frequent these anomalies.

Diverticula of the prostatic portion of the urethra are seen in severe proximal forms. Infection is a frequent complication of this kind of diverticula and is usually addressed with antibiotic treatment. However, some centres still advise routine explorations of the upper urinary tract in proximal forms [11].

Discovery of intersex states is extremely rare but a karyotype is recommended in case of total cryptorchidism, micropenis, penoscrotal transposition (PST) or biphid scrotum [12].

Imperforate anus and myelomeningocele may be associated with hypospadias. Finally, hypospadias may be part of some complex entities such as McKusick-Kaufman syndrome, Brachmann-de Lange syndrome, Fryns syndrome, Pallister-Hall syndrome, Smith-Lemli-Opitz syndrome, Rapp-Hodgkin syndrome, Marden-Walker syndrome or fronto-facio-nasal dysplasia [13].

4. General surgical principles

4.1. Age for intervention

Technical advances allow operating earlier than in previous decades. Many surgeons advocate intervening in the first 2 years of life for minor distal forms. On the other hand, because increased penile size minimises the risk of producing undesired damage, complicated proximal forms are usually postponed. There is broad consensus to have all procedures done before compulsory school age at 4–5 years with the aim of avoiding psychosocial issues as bullying and comparison with peers [14].

4.2. Optical magnification

Most surgeons think of magnification loupes as a minimal requisite for this kind of surgery; some of them even favour the use of the surgical microscope. Magnification makes the surgeon aware of the importance of minor vessels. In any case, it minimises the rate of complications and it is indispensable in infants and toddlers.

4.3. Instruments and sutures

Many of the instruments used in hypospadias surgery (Castroviejo needle holders, palpebral retractors, microsurgical pincettes) are similar to the ones used in ophthalmic surgery. Depending on centres and individuals, there are some variations but most surgeons apply absorbable polyglactin, polyglycolic acid or monofilament polydioxanone sutures for closing of the neourethra. Nylon or polypropylene are only used in skin sutures and removed after 10–14 days. Surgical calibre of these materials usually varies between 5/0 and 7/0.

4.4. Artificial erection

Introduced in the 1970s [15], the injection of saline solution facilitates correct appreciation of the chordee during the procedure. Some surgeons use it as an ancillary diagnostic procedure before planning an ultimate corrective operation.

4.5. Interposed tissue between skin suture and urethra and biological adhesives

Also starting in the 1970s [16], several techniques have been described to add an extra protective layer of tissue: de-epithelised skin, external spermatic fascia, Buck's fascia, tunica vaginalis or most usually dartos fascia flaps. These procedures decrease significantly the rate of postoperative fistulas [17]. Mobilisation of the dartos muscle over the repair allows 'waterproofing'. Some surgeons use fibrin glue before suturing the final skin layer.

4.6. Haemostasis

As a precaution to prevent undesired burns of the thin penile structures, most surgeons favour bipolar diathermy.

It is generally accepted that using a transient tourniquet to operate in an almost bloodless field eases visualisation and shortens procedure time. (Needless to say, the surgical team must pay attention not to forget tourniquet removal before dressing at the end of the operation.)

4.7. Intraoperative local anaesthesia

A penile block before the end of the operation, using bupivacaine, diminishes pain and the risk of dangerous manipulations of the dressing. Moreover, due to the extensive use of penile block, some minor procedures can be performed as ambulatory day-surgery.

4.8. Catheter drainage

Catheters divert the pressure on the suture zone during the immediate postoperative period. They allow bladder voiding in case of clotting or spasm. As they should be least reactive, silicone is the most favoured catheter or stent material. Catheters and stents provide a priceless protection in middle and proximal hypospadias. Bladder spasm can be reduced by using oxybutynin.

4.9. Dressings

Confection of a mildly compressive dressing deserves special attention at the end of the procedure. A certain degree of pressure is needed to maintain haemostasis and diminish local oedema. A modern trend promotes abstention of any kind of dressing [18]. In any case, all eventual dressings should be non-adhesive to prevent unwanted tearing at the moment of removal.

5. Common surgical procedure

More than 300 techniques have been described for the correction of the diverse types of hypospadias. This great number probably reflects that no single technique can provide an answer to all situations. The average hypospadias surgeon concentrates on mastering a basic arsenal with a certain number of flexible options. Complicated presentations may need complex grafts of mucosa collected from the bladder (introduced by Memmelaar in 1947 [19]) or buccal cavity (first performed by Sapezhko in the nineteenth century [20]).

5.1. The chordee

Correction of chordee should precede any hypospadias surgery to estimate the real length of the straightened urethra (**Figure 3**). A common classification includes four types. Type I is an 'easy' skin tethering. Type II includes a fibrotic fascia. Type III involves corporal disproportion. Type IV consists of a true urethral tethering [21]. The chordee may appear isolated without hypospadias. All fibrous vestiges running along the penile shaft from glans to meatus must be carefully dissected to avoid damage to the urethral plate and the cavernous bodies. Many surgeons prefer a two-stage repair in cases of hypospadias with severe chordee.

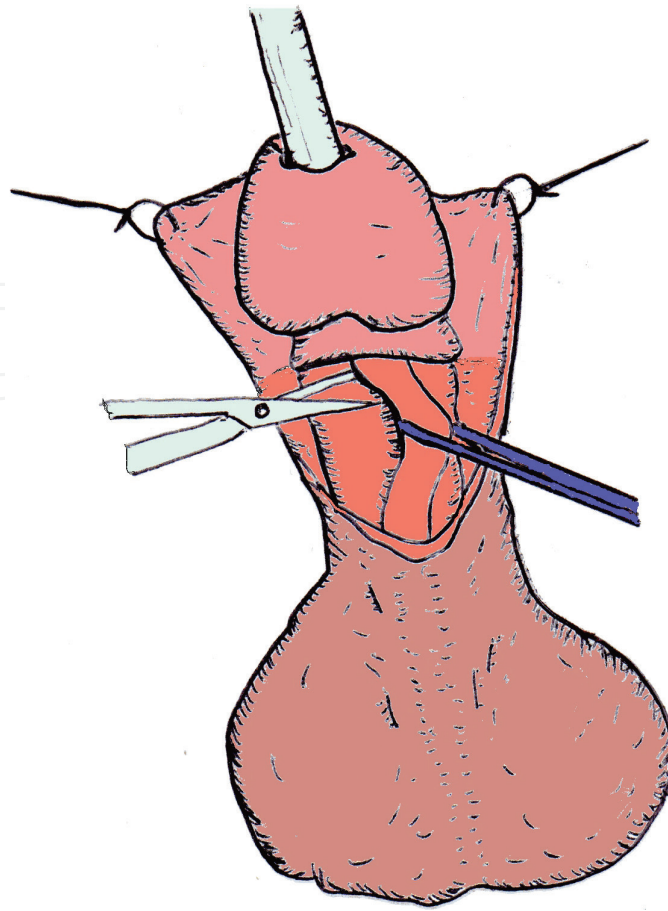


Figure 3. Dissection of a chordee without hypospadias.

5.2. Meatal advancement and glanuloplasty (MAGPI)

The MAGPI technique was described by Duckett in 1981 [22]. It may be useful in the more distal types of hypospadias without chordee that present good skin quality. After liberating the ventral skin, the surgeon performs a triangular suprimeatal incision from the point where the new meatus is intended. The centre of the hypospadiac meatus is sutured to the vertex of the triangle in order to achieve ascension. The preputial frenulum is simulated by suturing in an inverted 'V', the edges of the missing balanopreputial groove (Figure 4).

5.3. Mathieu procedure

Though described by Mathieu in 1932 [23], it bears a strong resemblance to previous operations and has undergone subtle modifications and refinements by surgeons as Gibbons, Devine, Horton, Barcat or van der Meulen to adapt to diverse situations. When the meatus lies subcoronal (or even in the most distal third of the penile shaft), this technique uses a flap of the perimeatal skin to create the missing wall of the urethra in a tubularised way (Figure 5).

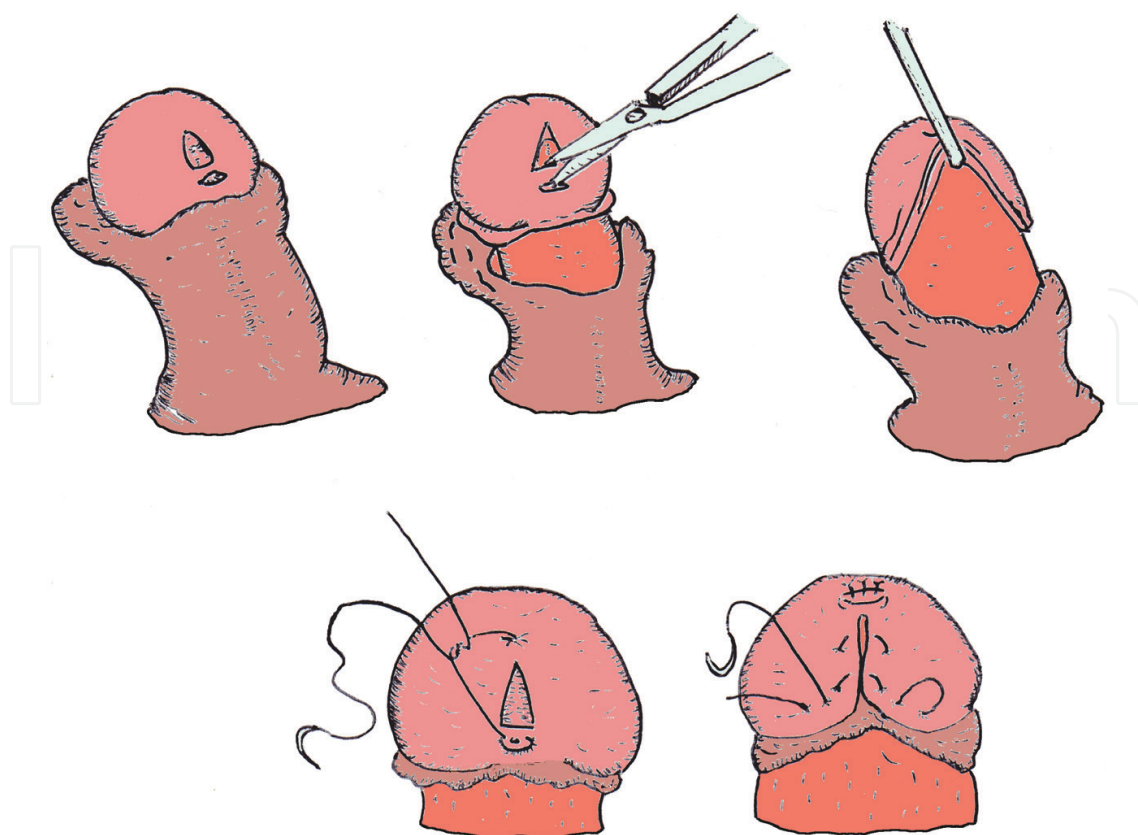


Figure 4. The initial stage and four different phases in the MAGPI technique.

5.4. Byars procedure and Snodgrass adaptation

As described in 1955 [24], this technique is still used on penoscrotal or proximal third types. It is inspired by the concepts of Thiersch and Duplay. The incised edges of the open urethral plate are sewn together and tubularised (**Figure 6**). As usual, there are many variations to this technique.

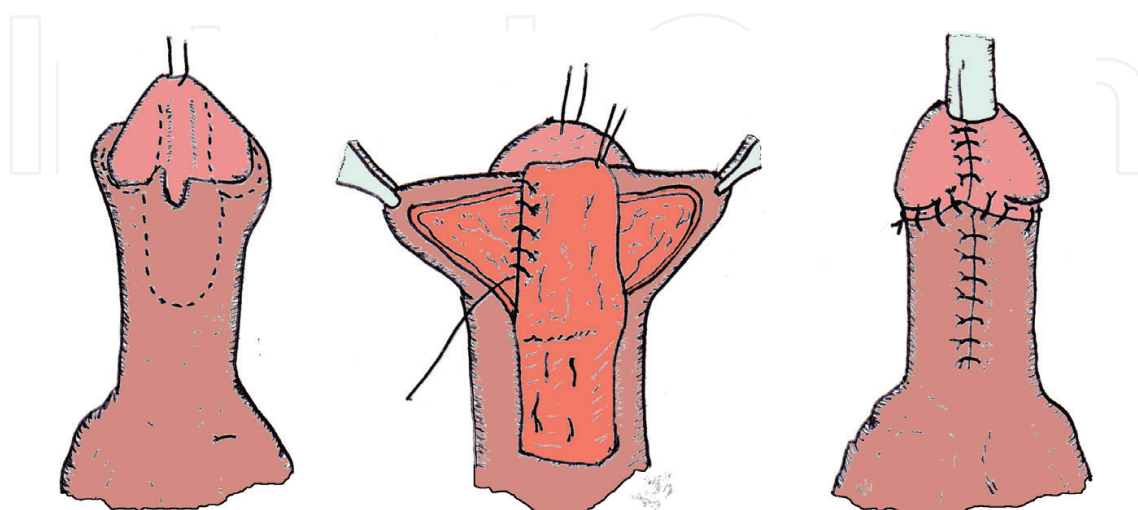


Figure 5. The Mathieu technique.

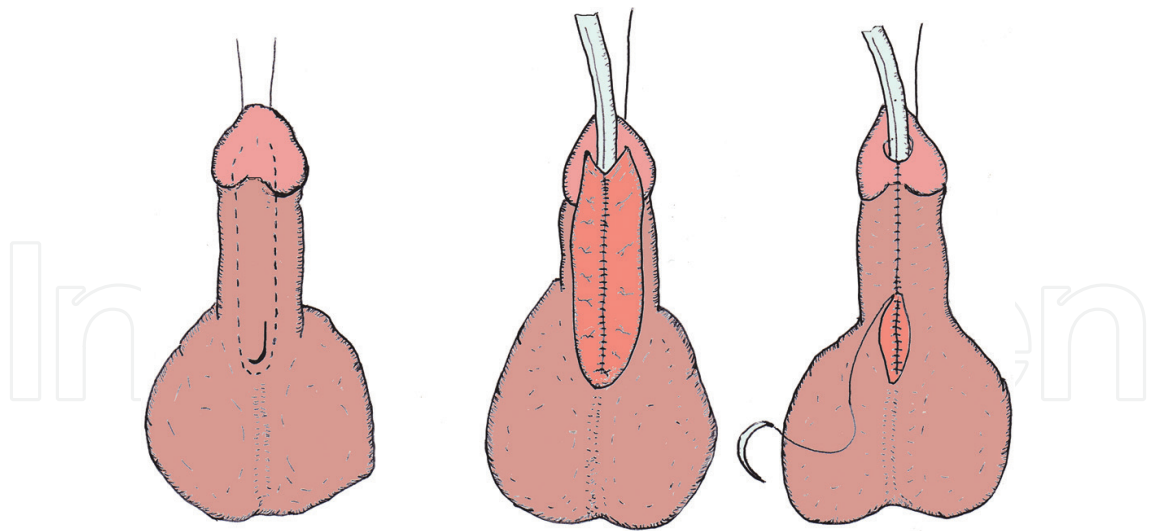


Figure 6. Different stages of the Byars procedure.

Warren Snodgrass introduced a substantial variation [25] that is now becoming the most usual procedure in any kind of hypospadias. He proposed a longitudinal incision of the urethral plate all along the midline. This incision allows easier approaching of the edges of the open urethral plate (**Figure 7**).

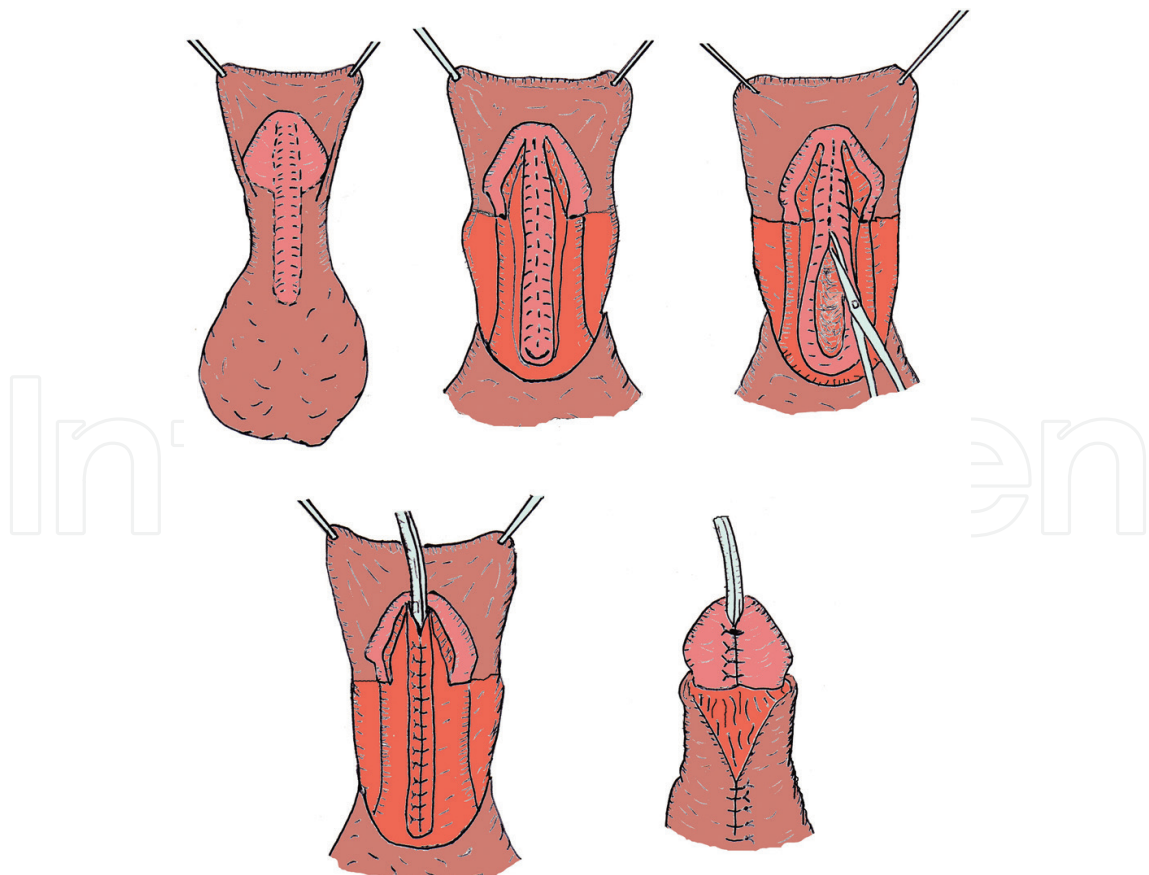


Figure 7. Longitudinal transection of the urethral plate in the Snodgrass procedure.

5.5. Island flap techniques

These are delicate procedures that involve the crafting of a new urethra by using the foreskin [26, 27]. The vascularisation of the preputial flap stems from the basis of the penis and must be preserved to avoid flap necrosis and failure (**Figure 8**). The size of the flap is precisely measured having in sight an undesired retraction (when too short) or diverticula (when too wide). There are different available options for the pedicle.

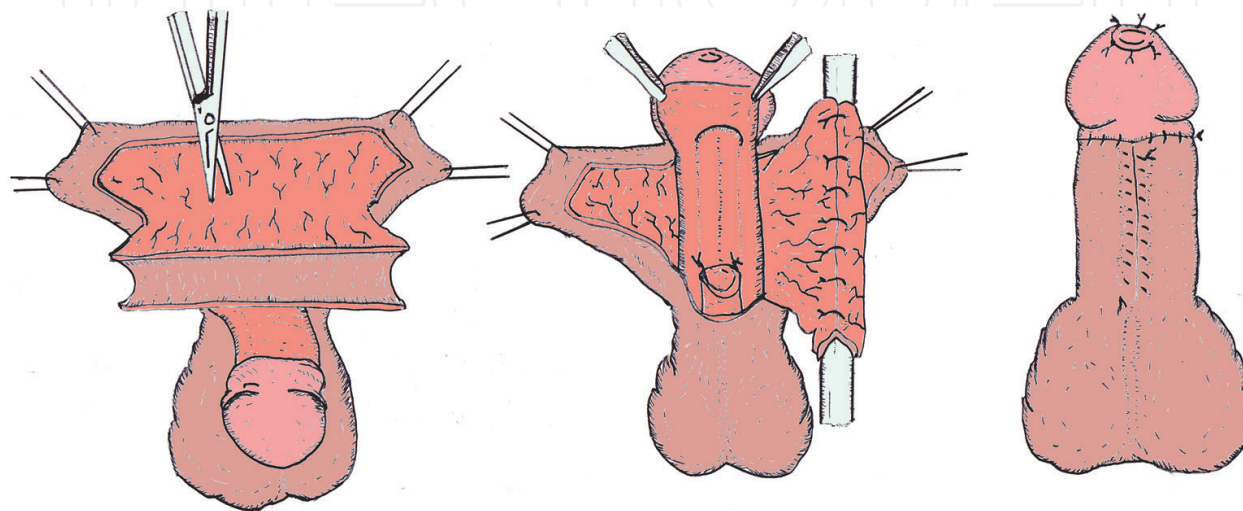


Figure 8. Different stages in the Duckett island flap procedure.

6. Penoscrotal transposition

Penoscrotal transposition (PST) represents a rare congenital abnormality of external genitalia in which the scrotum is positioned superiorly or anteriorly in relation to the penis (**Figure 9**). It includes a large spectrum of anomalies, ranging from the mild bifid scrotum form to the complete penoscrotal transposition (CPST) where the scrotum is located cephalic to the penis [28].

Usually patients present other associated anomalies. Hypospadias, chordee and renal dysplasia as well as anal abnormalities are frequently associated in most patients. Cardiac, gastrointestinal, craniofacial, skeletal and central nervous system malformations have to be ruled out in most severe cases of CPST. Aetiology remains uncertain. A genetic background finds the largest consensus in literature. It is probably linked to an abnormal genital tubercle development around the fifth to sixth week of gestation which might affect the migration and fusion of the scrotum.

Prenatal diagnosis of PST is difficult but it should be considered in the differential diagnosis when ambiguous genitalia or a major urogenital abnormality is suspected on the ultrasound [29].

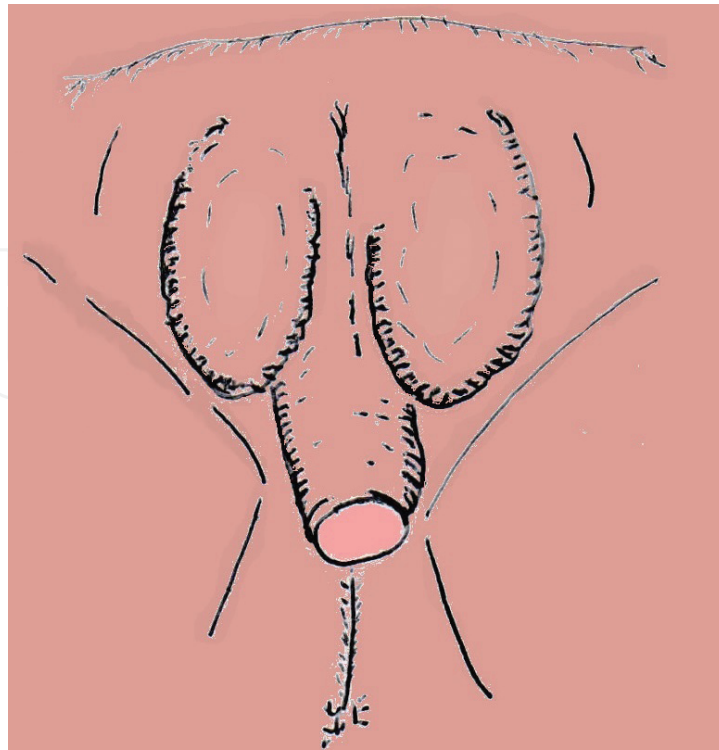


Figure 9. A moderate degree of complete penoscrotal transposition.

Surgical correction is challenging and is usually performed around the 15th–18th month of birth. The size of the phallus and its potential to develop into a sexually satisfactory penis at puberty should be carefully evaluated before surgery. Reassignment to female gender may even be a prudent therapeutic option in a small number of extreme penoscrotal transposition cases due to the unsatisfactory results obtained with penile repositioning and reconstruction [30].

Repairs of penoscrotal transposition rely on the creation of rotational flaps to mobilise the scrotum downwards or transpose the penis to a neo meatus created in the skin of the mons pubis. All procedures entail a complete circular incision around the root of the penis. This usually results in severe and massive oedema of the penile skin, which delays correction of the associated hypospadias and increases the incidence of complications. The skin vascularity and lymphatics may be impaired by the designed incision.

Several surgical techniques are described in the literature for the incomplete PST. The modified Glenn-Anderson [31] techniques are commonly used. In these techniques, the two halves of the scrotum are completely mobilised as a rotational flap and relocated in the right position. The penis can be transposed to a neo hole created in the skin of the mons pubis. To reduce the incidence of oedema of the penile skin consequent upon a circular incision around the root of the penis, Saleh suggests to maintain the penile skin connected to the skin of the lower abdomen by a small strip of skin (**Figure 10**); thus, aids in obtaining a good outcome [32].

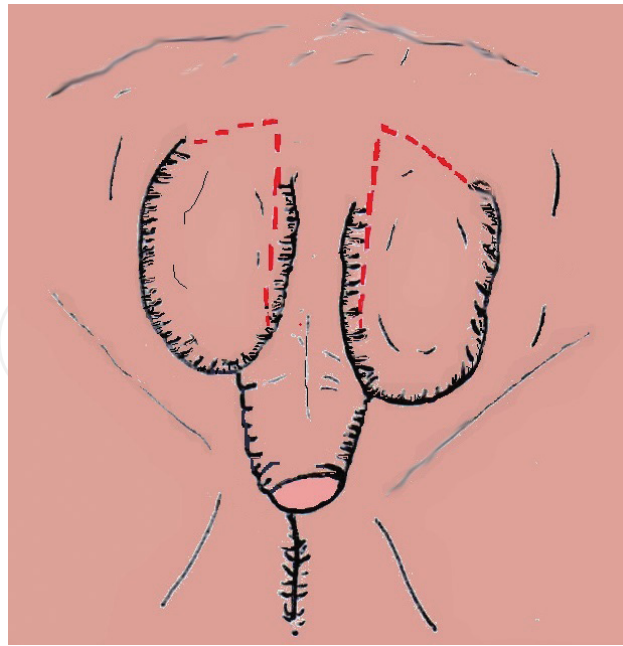


Figure 10. Design of scrotal flaps in a modified Glenn-Anderson procedure.

7. Complications

Many years ago, operating on hypospadias was said to be a sure way to ruin one's reputation in a paediatric department. Complications such as fistulas are unavoidable but fortunately there is remarkable improvement in this area when the above-mentioned general principles are routinely applied [33, 34]. Diverticula are less frequent when appropriate planning is carried out. Skin flap (or even glans!) necrosis and persistent chordee are becoming very rare complications.

7.1. Infection

Perioperative antibiotics may help to reduce the risk of infection, especially with indwelling catheters and adult patients.

7.2. Haemorrhage in the early postoperative period

Usually, it may be prevented with appropriate dressings and non-adherent materials. Instructing the parents and a correct postoperative analgesia would prevent the child to scrub the area.

7.3. Fistulas

Urethrocutaneous fistulas arise from the suture line of the crafted neourethra in all series but their proportion is reported to be from 3 to 20%. Fortunately, this incidence is far from the high values (as much as 45%) observed 40 years ago [35, 36]. Higher fistulisation rates are

observed after tubulised free grafts. The most common causes of fistulisation include ischaemia, infection, intolerance to the suture material, distal obstruction to the urine outflow and poor surgical technique. Most teams prefer a waiting period of 6 months before any reoperation. A little number of small early fistulas seems to heal spontaneously. When repairing a fistula, a well-vascularised layer should cover the area (**Figure 11**).

7.4. Stenosis

Most cases of narrow urethra may be treated by dilation in the first preoperative months. Complicated cases may require a new operation that may involve mucosal grafts.

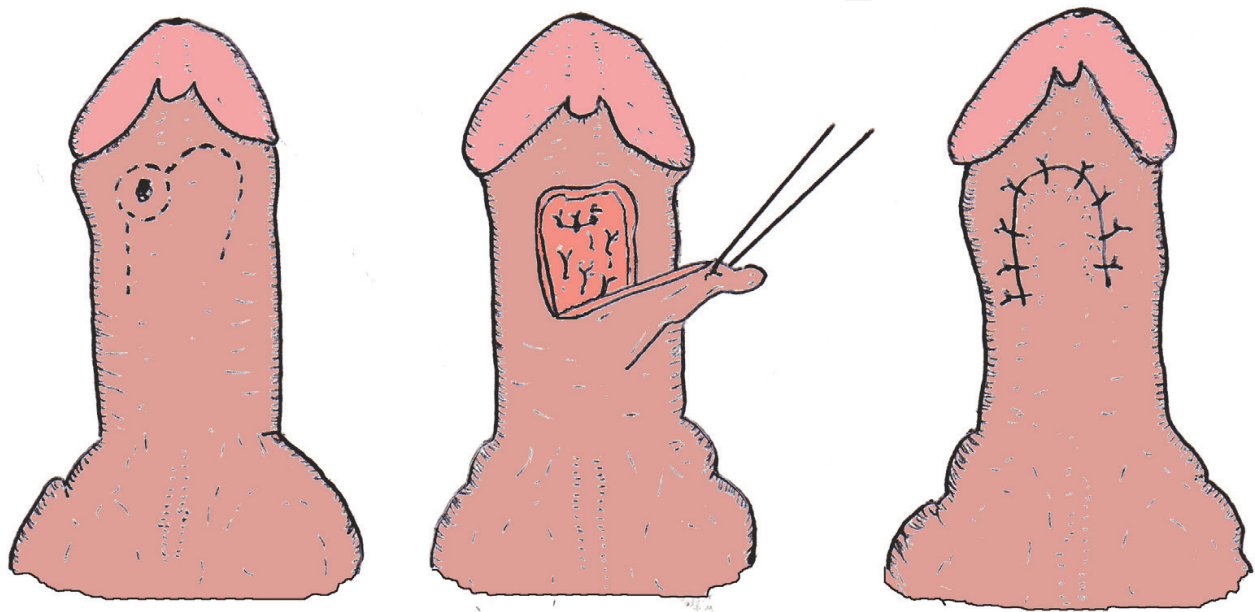


Figure 11. Closing of urethral fistula with a rotating flap.

Author details

Wenceslao M. Calonge^{1*} and Gianluca Sapino²

*Address all correspondence to: wcalonge@yahoo.es

1 Department of Surgery, Établissements Hospitaliers du Nord Vaudois, Switzerland

2 Department of Plastic, Reconstructive and Aesthetic Surgery, Azienda Ospedaliero–Universitaria di Modena, Italy

References

- [1] Hauben DJ. The history of hypospadias. *Acta Chirurgica Plastica*. 1984;**26**:196-199

- [2] Smith ED. The history of hypospadias. *Pediatric Surgery International*. 1997;**12**:81-85
- [3] Thomas DFM. Hypospadiology: Science and surgery. *British Journal of Urology International*. 2004;**93**:470-473
- [4] Huang WY, Chen YF, Guo YJ, Lan CF, Chang HC, Chen SC, Huang KH. Epidemiology of hypospadias and treatment trends in Taiwan: A nationwide study. *Journal of Urology*. 2011;**185**(4):1449-1454
- [5] Nordenvall AS, Frisén L, Nordenström A, Lichtenstein P, Nordenskjöld A. A population-based nationwide study of hypospadias in Sweden, 1973-2009: Incidence and risk factors. *J Urol*. 2014 Mar;**191**(3):783-789
- [6] van Rooij IA, van der Zanden LF, Brouwers MM, Knoers NV, Feitz WF, Roeleveld N. Risk factors for different phenotypes of hypospadias: Results from a Dutch case-control study. *British Journal of Urology International*. 2013;**112**(1):121-128
- [7] Wolf C, Lambright C, Mann P, Price M, Cooper RL, Ostby J, Gray LE. Administration of potentially antiandrogenic pesticides (procymidone, linuron, iprodione, chlozolinate, p,p'-DDE, and ketoconazole) and toxic substances (dibutyl- and diethylhexyl phthalate, PCB 169, and ethane dimethane sulphonate) during sexual differentiation produces diverse profiles of reproductive malformations in the male rat. *Toxicology and Industrial Health*. 1999;**15**(1-2):94-118
- [8] Carmichael SL, Shaw GM, Lammer EJ. Environmental and genetic contributors to hypospadias: A review of the epidemiologic evidence. *Birth Defects Research and Clinical Molecular Teratology*. 2012;**94**(7):499-510
- [9] Angerpointner TA. Hypospadias – genetics, epidemiology and other possible aetiological influences. *Zeitschrift Kinderchirurgie (European Journal of Pediatric Surgery)*. 1984;**39**:112-118
- [10] Wilcox DT, Mouriquand PDE. Hypospadias. In: Thomas DFM, Duffy PG, Rickwood AMK, editors. *Essentials of pediatric urology*. London: Informa Healthcare; 2008. pp. 213-232
- [11] Cerasaro TS, Brock WA, Kaplan GW. Upper urinary tract anomalies with congenital hypospadias: Is screening necessary? *Journal of Urology*. 1986;**135**:537-538
- [12] McAleer IM, Kaplan GW. Is routine karyotyping necessary in the evaluation of hypospadias and cryptorchidism? *Journal of Urology*. 2001;**165**:2029-2031
- [13] Boehmer AL, Nijman RJ, Lammers BA. Etiological studies of severe or familial hypospadias. *Journal of Urology*. 2001;**165**:1246-1254
- [14] Hadidi AT. Principles of hypospadias surgery. In: Hadidi AT, Azmy AF, editors. *Hypospadias Surgery. An Illustrated Guide*. Berlin: Springer; 2004. pp. 99-105
- [15] Gittes RF, McLaughlin III AP. Injection technique to induce penile erection. *Urology*. 1974;**4**:473-474

- [16] Smith D. A de-epithelialized overlap flap technique in the repair of hypospadias. *British Journal of Plastic Surgery*. 1973;**26**:106-114
- [17] Gapany C, Grasset N, Tercier S, Ramseyer P, Frey P, Meyrat BJ. A lower fistula rate in hypospadias surgery. *Journal of Pediatric Urology*. 2007;**3**(5):395-397
- [18] van Savage JG, Palanca LG, Slaughenhaupt BL. A prospective randomized trial of dressings versus no dressings for hypospadias repair. *Journal of Urology*. 2000;**164**:981-983
- [19] Memmelaar J. Use of bladder mucosa in a one-stage repair of hypospadias. *Journal of Urology*. 1947;**58**(1):68-73
- [20] Korneyev I, Ilyin D, Schultheiss D, Chapple C. The first oral mucosal graft urethroplasty was carried out in the 19th century: The pioneering experience of Kirill Sapezhko (1857-1928). *European Urology*. 2012;**62**(4):624-627
- [21] Donnahoo KK, Cain MP, Pope JC, Casale AJ, Keating MA, Adams MC, Rink RC. Etiology, management and surgical complications of congenital chordee without hypospadias. *Journal of Urology*. 1998;**160**(3):1120-1122
- [22] Duckett JW. MAGPY (meatal advancement and glanuloplasty), a procedure for subcoronal hypospadias. *Urologic Clinics of North America*. 1981;**5**:513-520
- [23] Mathieu MP. Traitement en un temps de l'hypospadias balanique ou yuxtabalanique. *Journal de Chirurgie*. 1932;**39**:481-486
- [24] Byars LT. A technique for consistently satisfactory repair of hypospadias. *Surgical Gynecology and Obstetrics*. 1955;**100**(2):184-190
- [25] Snodgrass WT. Tubularized incised plate hypospadias repair. In: Frank D, Gearhart JP, Snyder HM, editors. *Operative Pediatric Urology*. London: Churchill Livingstone; 2002. pp. 161-164
- [26] Duckett JW. The island-flap technique for hypospadias repair. *Urologic Clinics of North America*. 1981;**8**:503
- [27] Duckett JW. Hypospadias repair. In: Frank D, Gearhart JP, Snyder HM, editors. *Operative Pediatric Urology*. London: Churchill Livingstone; 2002. pp. 149-160
- [28] Avolio L, Karmarkar SJ, Martucciello G. Complete penoscrotal transposition. *Urology*. 2006;**67**(6):1287
- [29] Sexton P, Thomas JT, Petersen S, Brown N, Arms JE, Bryan J, Harraway J, Gardener G. Complete penoscrotal transposition: Case report and review of the literature. *Fetal Diagnosis and Therapy*. 2015;**37**(1):70-74
- [30] Naren SD, Soren C, Subbarao PV. Penoscrotal transposition: A case report. *Indian Journal of Surgery*. 2013;**75**(1):64-65
- [31] Saleh A. Correction of incomplete penoscrotal transposition by a modified Glenn-Anderson technique. *African Journal of Paediatric Surgery*. 2010;**7**(3):181-184

- [32] Glenn JF, Anderson EE. Surgical correction of incomplete penoscrotal transposition. *Journal of Urology*. 1973;**110**(5):603-605
- [33] Shapiro SR. Complications in hypospadias repair. *Journal of Urology*. 1973;**131**:518-522
- [34] Retik AB, Keating MA, Mandell J. Complications of hypospadias surgery. *Urologic Clinics of North America*. 1981;**8**:223-236
- [35] Horton CE, Devine CJ. Urethral fistula. In: Horton CE, editor. *Plastic and reconstructive surgery of the genital area*. Boston: Little & Brown Co; 1973. pp. 397-403
- [36] Baskins LS. Hypospadias. In: Stringer MD, Oldham KT, Mouriquand PDE, editors. *Paediatric Surgery and Urology. Long-term Outcomes*. Cambridge; Cambridge University Press; 2006. pp. 611-620